



HAL
open science

EZHIP is a specific diagnostic biomarker for posterior fossa ependymomas, group PFA and diffuse midline gliomas H3-WT with EZHIP overexpression

C Antin, A Tauziède-Espariat, M-A Debily, D Castel, J Grill, M Pagès, O Ayrault, F Chrétien, A Gareton, F Andreiuolo, et al.

► To cite this version:

C Antin, A Tauziède-Espariat, M-A Debily, D Castel, J Grill, et al.. EZHIP is a specific diagnostic biomarker for posterior fossa ependymomas, group PFA and diffuse midline gliomas H3-WT with EZHIP overexpression. *Acta Neuropathologica Communications*, 2020, 8, pp.183. 10.1186/s40478-020-01056-8. hal-03405547

HAL Id: hal-03405547

<https://hal.science/hal-03405547>

Submitted on 27 Oct 2021

HAL is a multi-disciplinary open access archive for the deposit and dissemination of scientific research documents, whether they are published or not. The documents may come from teaching and research institutions in France or abroad, or from public or private research centers.

L'archive ouverte pluridisciplinaire **HAL**, est destinée au dépôt et à la diffusion de documents scientifiques de niveau recherche, publiés ou non, émanant des établissements d'enseignement et de recherche français ou étrangers, des laboratoires publics ou privés.

LETTER TO THE EDITOR

Open Access



EZHIP is a specific diagnostic biomarker for posterior fossa ependymomas, group PFA and diffuse midline gliomas H3-WT with EZHIP overexpression

C. Antin¹, A. Tauziède-Espariat^{1*}, M.-A. Debily^{2,3}, D. Castel^{2,4}, J. Grill^{2,4}, M. Pagès¹, O. Ayrault^{5,6}, F. Chrétien¹, A. Gareton¹, F. Andreiuolo¹, E. Lechapt¹ and P. Varlet¹

In the central nervous system (CNS), the loss of H3K27me3 expression constitutes the hallmark of two different tumor types: diffuse midline glioma (DMG), H3K27-mutant and posterior fossa ependymoma, group PFA (PFA-EPN). In the former, mutations in histone genes (mostly *H3F3A* K27M and *HIST1H3B* K27M), present in about 97% of DMG, inhibit the activity of the Polycomb Repressive Complex 2 (PRC2) methyltransferase [1]. However, these mutations are rare in PFA-EPN (accounting for ≈4% of cases) [2]. Recent molecular advances have shown that the Enhancer of Zest Homologs Inhibitory Protein (EZHIP) is overexpressed (due to gene overexpression rather than mutations of the *CXorf67* gene) in the large majority of PFA-EPN, and in the remaining cases of DMG showing H3K27me3 loss but lacking histone gene (*H3*) mutations [1–3]. Indeed, this overexpression mimics the mechanism of histone gene mutations on PRC2 [4]. Usually, the current routine immunohistochemical (IHC) panel in pediatric neuropathology includes H3K27me3 and H3K27M antibodies but not EZHIP. The aim of our study was to evaluate the sensitivity and specificity of the EZHIP biomarker in a large cohort of pediatric tumors, including the most

common tumor types, which arise in the brainstem and the posterior fossa.

We performed IHC for EZHIP using the CXorf67 antibody (Polyclonal; 1:75 dilution; Sigma-Aldrich; Bromma, Sweden) on 3 μm-thick sections of formalin-fixed, paraffin-embedded tissue samples of these tumors, performed on an Omnis automate. Our study included a total of 311 cases: 298 pediatric tumors of different subtypes (gliomas, embryonal, and ependymal tumors with a morphomolecular diagnosis including DNA-methylation profiling), and 13 posterior fossa ependymomas, Group PFB (for details see Table 1). This series includes some of the tumors previously reported [1]. The IHC were performed on whole sections in 266 cases and on a TMA (tissue microarray) of 45 ependymomas as a validation cohort which included PFA (n = 37), H3K27-mutant (n = 2) and PFB (n = 6). The IHC stainings were scored by three neuropathologists (ATE, PV and EL) independently.

The IHC results (including the validation cohort) are detailed in Table 1. A strong and diffuse EZHIP nuclear staining (>90% of immunopositive tumor cells) was observed in all DMG, H3-wildtype with EZHIP overexpression (n = 13) (Fig. 1A–C) and all PFA-EPN (n = 47) (Fig. 2A–C and Additional file 1: Figure S1), except the two EPN, H3K27-mutants (Fig. 2G–I). The majority of germinomas exhibited a strong nuclear immunostaining (94%, 29/31 cases) associated with a loss of H3K27me3 trimethylation (Fig. 1G–I and Additional file 2: Figure S2). In all other diagnoses, tumor cells were

*Correspondence: a.tauziède-espariat@ghu-paris.fr

¹ Department of Neuropathology, GHU Paris-Neurosciences, Sainte-Anne Hospital, 1, rue Cabanis, 75014 Paris, France

Full list of author information is available at the end of the article

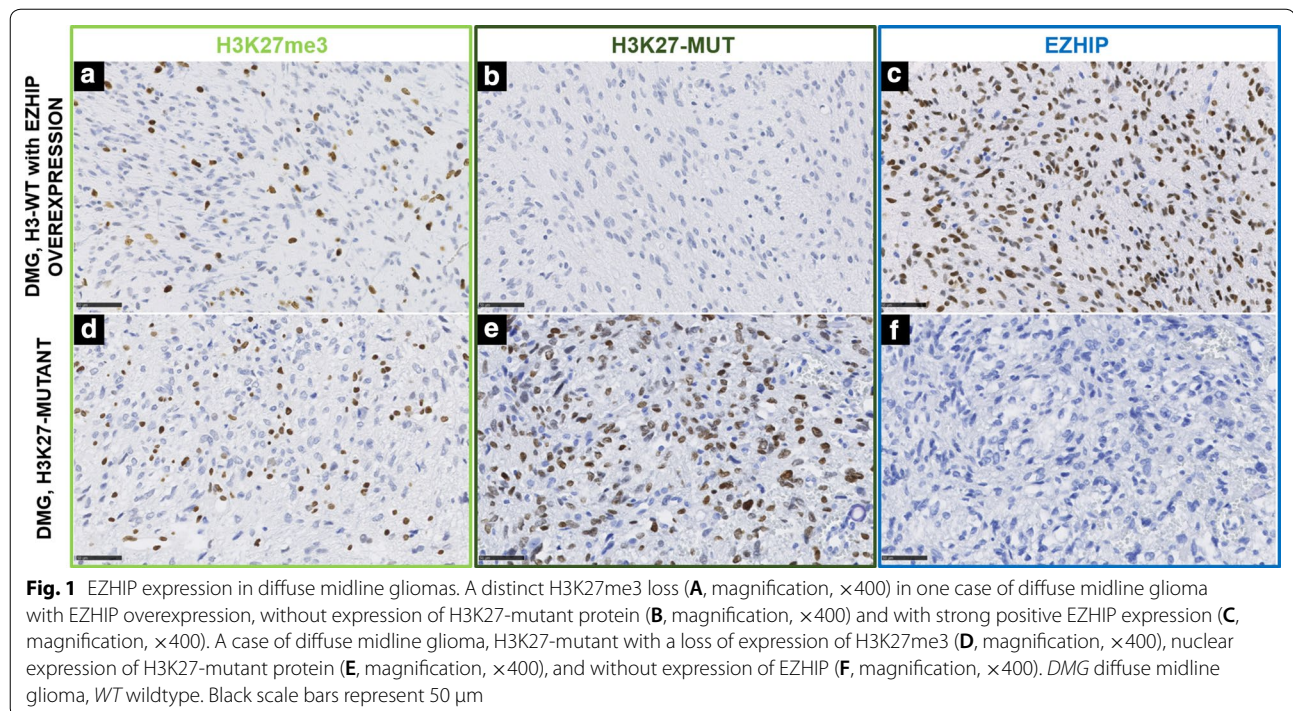


Table 1 Immunohistochemical results of EZHIP in our series

Tumor types	EZHIP [n (%)]
Diffuse astrocytic and oligodendroglial tumors	
Astrocytoma, <i>IDH</i> -mutant, grade 2	0/2 (0)
Oligodendroglioma, <i>IDH</i> -mutant and 1p19q codeleted, grade 2	0/3 (0)
Epithelioid glioblastoma	0/1 (0)
Astrocytoma, <i>IDH</i> -mutant, grade 4	0/3 (0)
DMG, H3K27-mutant	0/24 (0)
DMG, H3K27-WT with EZHIP overexpression	13/13 (100)
HGG with MSI	
CMMRD	0/6 (0)
Lynch syndrome	0/4 (0)
Diffuse glioma, H3.3 G34-mutant	0/10 (0)
HGG, <i>MYCN</i> -amplified	0/9 (0)
Glioblastoma, <i>IDH</i> -WT	0/10 (0)
Other astrocytic tumors	
Pilocytic astrocytoma	0/10 (0)
High-grade astrocytoma with piloid features	0/1 (0)
Pleomorphic xanthoastrocytoma with anaplastic features	0/9 (0)
Ependymal tumors	
Myxopapillary ependymoma	0/6 (0)
Posterior fossa ependymoma	
Group PFA	47/47 (100)
Group PFA, H3K27-mutant	0/2 (0)
Group PFB	0/19 (0)
Supratentorial EPN	
<i>YAP1</i> -fusion-positive	0/5 (0)
<i>C11orf95</i> fusion-positive	0/17 (0)
Subependymoma	0/2 (0)
Neuronal and mixed neuronal-glial tumors	
Diffuse leptomeningeal glioneuronal tumor	0/1 (0)
Tumors of the pineal region	
Pineoblastoma	0/10 (0)
Embryonal tumors	
Medulloblastoma, group 3	0/5 (0)
Medulloblastoma, group 4	0/5 (0)
Medulloblastoma, SHH-activated	0/10 (0)
Medulloblastoma, WNT-activated	1/10 (10) ^a
Embryonal tumors with multilayered rosettes, <i>C19MC</i> -amplified	0/10 (0)
AT/RT	
AT/RT MYC	1/3 (33) ^a
AT/RT SHH	0/4 (0)
AT/RT TYR	0/3 (0)
CNS tumor with <i>BCOR</i> internal tandem duplication	0/8 (0)
CNS high-grade neuroepithelial tumor with <i>MN1</i> alteration	0/8 (0)
Germ cell tumors	
Germinoma	29/31 (94)

AT/RT atypical teratoid/rhabdoid tumor, CNS central nervous system, EPN ependymoma, HGG high-grade glioma, MSI microsatellite instability, WT wildtype

^a 1 case presents a focal expression of EZHIP (< 1% of tumor cells)



immunonegative except for two cases: one atypical teratoid/rhabdoid tumor (AT/RT) belonging to the *MYC* methylation class and one medulloblastoma, WNT-activated. These two cases exhibited only focal expression (<1% of immunopositive tumor cells) (data not shown). This low protein expression of EZHIP was correlated with a normal level of *CXorf67* gene expression at the mRNA level. Thus, the specificity and the sensitivity of the IHC were evaluated as 99% and 98% respectively.

This work constitutes the first study of the sensitivity/specificity of EZHIP immunoexpression in a large cohort of CNS tumors. Our results highlighted that nuclear EZHIP expression must be diffuse and strong to be interpreted as overexpressed. Thus, EZHIP IHC constitutes a fast, low-cost and conservative tissue-consuming method to detect *CXorf67* overexpression, suitable for small samples (particularly in brainstem biopsies), but also in samples that contain few tumor cells. The IHC may also help to evaluate the quality of resection (surgical limits). Indeed, a nuclear immunopositivity is easier to interpret than the loss of H3K27me3. Our work highlighted the robust specificity

of EZHIP staining in all PF ependymomas, group PFA and in all DMG, H3-wildtype with EZHIP overexpression, ruling out the main differential diagnoses encountered in children in the brainstem and in the posterior fossa (Table 1). All germinomas except two exhibited a strong positivity for EZHIP concomitant with a loss of H3K27me3 as published previously [2, 7]. Concerning HGG, *MYCN*-amplified none of our 9 cases (confirmed by DNA-methylation profiling and previously reported [5, 6]), were immunopositive, contrarily to a previous study which reported an expression of EZHIP in 13% of cases [1]. Moreover, this biomarker may represent a diagnostic but also a prognostic tool. Indeed, PFA-EPN were associated with a poorer prognosis than PFB-EPN, and patients with DMG overexpressing EZHIP presented a better overall survival compared to DMG, H3K27-mutant [1].

To conclude, we demonstrated that EZHIP IHC is a highly specific and sensitive biomarker for identifying PFA-EPN and DMG, H3-wildtype, with EZHIP overexpression, and should be part of the neuropathologist's routine panel of antibodies.

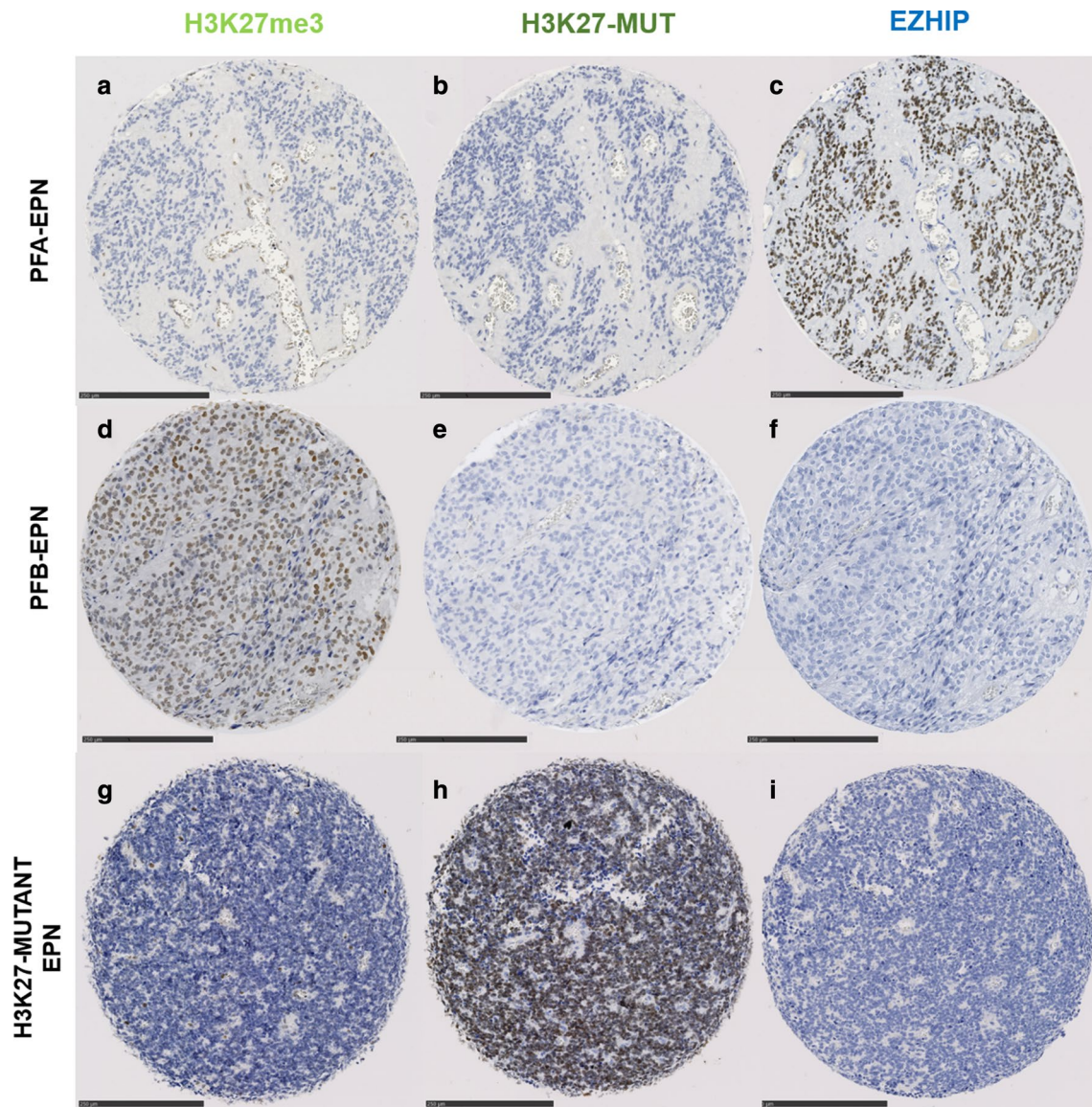


Fig. 2 EZHIP expression in ependymomas. The first line shows immunohistochemical analyses of a case of PFA-EPN exhibiting a loss of H3K27me3 (A, magnification, $\times 170$), no H3K27-mutant protein (B, magnification, $\times 170$) and an EZHIP overexpression with a strong and diffuse nuclear staining (C, magnification, $\times 170$). The second line represents a case of PFB-EPN with, as expected, no loss of H3K27me3 expression (D, magnification, $\times 170$), no H3K27-mutant protein expression (E, magnification, $\times 170$), and negative EZHIP immunostaining (F, magnification, $\times 170$). The last case (line 3) corresponds to a variant of PFA-EPN with H3K27-mutation exhibiting an H3K27me3 loss (G, magnification, $\times 170$), a strong positive staining for H3K27-mutant protein (H, magnification, $\times 170$) and no EZHIP expression (I, magnification, $\times 170$). Black scale bars represent 250 μm

Supplementary information

Supplementary information accompanies this paper at <https://doi.org/10.1186/s40478-020-01056-8>.

Additional file 1: Figure S1. EZHIP expression in ependymomas of different grades. The first line shows immunohistochemical analyses of a case of grade 2 PFA-EPN (**A**, HPS magnification, 400x) exhibiting a loss of H3K27me3 (**B**, magnification, 400x), and an EZHIP overexpression with a strong and diffuse nuclear staining (**C**, magnification, 400x). The second line represents a case of grade 3 PFA-EPN with microvascular proliferation and mitoses (white arrowheads) (**D**, HPS magnification, 400x), with a loss of H3K27me3 expression (**E**, magnification, 400x), and strong and diffuse EZHIP immunopositivity (**F**, magnification, 400x). HPS: Hematoxylin Phloxin Saffron. Black scale bars represent 50 μ m.

Additional file 2: Figure S2. EZHIP expression in germinomas. A case of germinoma with H3K27me3 loss (**A**, magnification, 400x), no expression of H3K27-mutant protein (**B**, magnification, 400x), and strong and diffuse nuclear immunoreexpression of EZHIP (**C**, magnification, 400x). Black scale bars represent 50 μ m.

Funding

MAD was supported by a grant from the Kick Cancer/Innovative Therapies for Children with Cancer (ITCC). JG was supported by a grant from Imagine for Margo for the BIOMEDE trial. DC was supported by a grant from L'Etoile de Martin and the Fondation Carrefour "Les Boucles du Coeur".

Competing interests

The authors declare that they have no conflict of interest directly related to the topic of this article.

Author details

¹ Department of Neuropathology, GHU Paris-Neurosciences, Sainte-Anne Hospital, 1, rue Cabanis, 75014 Paris, France. ² UMR8203, Vectorologie et thérapeutiques anticancéreuses, CNRS, Gustave Roussy, Univ. Paris-Sud, Univ. Paris-Saclay, 94805 Villejuif Cedex, France. ³ Univ. Evry, Université Paris-Saclay, 91057 Evry Cedex, France. ⁴ Department of Pediatric Oncology, Gustave Roussy Institute, Univ. Paris-Sud, Université Paris-Saclay, 94805 Villejuif, France. ⁵ CNRS UMR, INSERM, Institut Curie, PSL Research University, 91898 Orsay, France. ⁶ CNRS UMR 3347, INSERM U1021, Université Paris Sud, Université Paris-Saclay, 91898 Orsay, France.

Received: 19 August 2020 Accepted: 10 October 2020
Published online: 05 November 2020

References

- Castel D, Kergrohen T, Tauziède-Espariat A, Mackay A, Ghermaoui S, Lechapt E et al (2020) Histone H3 wild-type DIPG/DMG overexpressing EZHIP extend the spectrum diffuse midline gliomas with PRC2 inhibition beyond H3-K27M mutation. *Acta Neuropathol (Berl)* 139:1109–1113
- Pajtler KW, Wen J, Sill M, Lin T, Orisme W, Tang B et al (2018) Molecular heterogeneity and CXorf67 alterations in posterior fossa group A (PFA) ependymomas. *Acta Neuropathol (Berl)* 136:211–226
- Pratt D, Quezado M, Abdullaev Z, Hawes D, Yang F, Garton HJL et al (2020) Diffuse intrinsic pontine glioma-like tumor with EZHIP expression and molecular features of PFA ependymoma. *Acta Neuropathol Commun* 8:37
- Hübner J-M, Müller T, Papageorgiou DN, Mauermann M, Krijgsveld J, Russell RB et al (2019) EZHIP/CXorf67 mimics K27M mutated oncohistones and functions as an intrinsic inhibitor of PRC2 function in aggressive posterior fossa ependymoma. *Neuro-Oncol* 21:878–889
- Tauziède-Espariat A, Debily M-A, Castel D, Grill J, Puget S, Sabel M et al (2019) An integrative radiological, histopathological and molecular analysis of pediatric pontine histone-wildtype glioma with MYCN amplification (HGG-MYCN). *Acta Neuropathol Commun* 7:87
- Tauziède-Espariat A, Debily M-A, Castel D, Grill J, Puget S, Roux A et al (2020) The pediatric supratentorial MYCN-amplified high-grade gliomas methylation class presents the same radiological, histopathological and molecular features as their pontine counterparts. *Acta Neuropathol Commun* 8:104
- Ragazzini R, Pérez-Palacios R, Baymaz IH, Diop S, Ancelin K, Zielinski D et al (2019) EZHIP constrains Polycomb Repressive Complex 2 activity in germ cells. *Nat Commun* 10:3858

Publisher's Note

Springer Nature remains neutral with regard to jurisdictional claims in published maps and institutional affiliations.

Ready to submit your research? Choose BMC and benefit from:

- fast, convenient online submission
- thorough peer review by experienced researchers in your field
- rapid publication on acceptance
- support for research data, including large and complex data types
- gold Open Access which fosters wider collaboration and increased citations
- maximum visibility for your research: over 100M website views per year

At BMC, research is always in progress.

Learn more biomedcentral.com/submissions

