



HAL
open science

Change in shoulder external rotation strength and motion after lower trapezius transfer to the infraspinatus in children with obstetric brachial plexus palsy

Charline Garcon, Hicham Abdelnour, Clément Jeandel, Djamel Louahem, Isabelle Laffont, Jérôme Cottalorda, Karen Lambert, Bertrand Coulet, Marion Delpont

► To cite this version:

Charline Garcon, Hicham Abdelnour, Clément Jeandel, Djamel Louahem, Isabelle Laffont, et al.. Change in shoulder external rotation strength and motion after lower trapezius transfer to the infraspinatus in children with obstetric brachial plexus palsy. *International Orthopaedics*, 2021, 10.1007/s00264-021-05247-3 . hal-03388624

HAL Id: hal-03388624

<https://hal.science/hal-03388624>

Submitted on 23 Jun 2023

HAL is a multi-disciplinary open access archive for the deposit and dissemination of scientific research documents, whether they are published or not. The documents may come from teaching and research institutions in France or abroad, or from public or private research centers.

L'archive ouverte pluridisciplinaire **HAL**, est destinée au dépôt et à la diffusion de documents scientifiques de niveau recherche, publiés ou non, émanant des établissements d'enseignement et de recherche français ou étrangers, des laboratoires publics ou privés.

Change in shoulder external rotation strength and motion after lower trapezius transfer to the infraspinatus in children with obstetric brachial plexus palsy

GARÇON Charline¹, M.D., ABDELNOUR Hicham¹, M.D., JEANDEL Clément², M.D., LOUAHEM Djamel², M.D., LAFFONT Isabelle^{3,4}, M.D., PhD., COTTALORDA Jérôme², M.D., PhD., LAMBERT Karen⁵, Ph.D., COULET Bertrand^{1,4}, M.D., PhD., DELPONT Marion^{2,5}, M.D.

1 Department of Hand and Upper Extremity Surgery, Peripheral Nerves Surgery, Lapeyronie Hospital, University of Montpellier, Montpellier, France

2 Department of Pédiatric Orthopedic Surgery, Lapeyronie Hospital, University of Montpellier, Montpellier, France

3 Department of Physical Medicine and Rehabilitation. University of Montpellier, Montpellier, France

4 EuroMov Digital Health in Motion, University of Montpellier, Montpellier, France

5 PhyMedExp, CNRS UMR 9214, INSERM U1046, University of Montpellier, Montpellier, France

Corresponding author:

Marion DELPONT

Address: Department of Pediatric surgery, CHU Lapeyronie. 191 av du Doyen Gaston Giraud, 34295 Montpellier Cedex 5, France.

e-mail:

m-delpont@chu-montpellier

Declarations:

Acknowledgments

None

Funding

No funds, grants, or other support was received.

Conflicts of interest

None

Code availability

Not applicable

Authors' contributions

All authors contributed to the study conception and design. Conceptualization: Bertrand Coulet, Isabelle Laffont, Jérôme Cottalorda; Material preparation, data collection and analysis: Charline Garçon, Hicham Abdelnour, Marion Delpont, Karen Lambert; First draft of the manuscript: Charline Garçon, Hicham Abdelnour; Writing review: Djamel Louahem, Marion Delpont, Jérôme Cottalorda, Karen Lambert. All authors read and approved the final manuscript.

Consent to participate

Written informed consent to participate in the study was obtained from legal guardians.

Consent to publish

Informed consent to participate to the publication was obtained from legal guardians.

Trial registration:

18/07/31/5783, December 22, 2018

Level of evidence:

IV (case series)

Keywords:

lower trapezius transfer; obstetric palsy; isokinetic; muscle strength; muscle transfer; children

Abstract

Purpose:

Quantifying changes in shoulder external rotation range of motion and strength after lower trapezius transfer in children with obstetric brachial plexus palsy (OBPP).

Methods:

This prospective study included five children with sequelae of OBPP, with a mean age of 6.4 years (range: 4–12 years) who underwent lower trapezius tendon transfer to restore active external rotation (ER) of the shoulder. Preoperatively and at a 12-month follow-up assessment, we analyzed the passive and active shoulder ER, the modified Mallet score, and the shoulder rotator muscles strength using an isokinetic device.

Results:

Clinical parameters improved significantly after trapezius transfer preoperative passive ER from -8° (range: $-20-0^{\circ}$) to 37° (range: $15-50^{\circ}$) ($p = 0.035$), the modified Mallet score from 13 (range: 10–15) to 18 (range: 17–19) ($p = 0.035$). Strength testing revealed improved ER muscle strength in all five cases; the mean Peak Torque increased from 1.95 to 4.46 N·m, albeit non-significantly ($p = 0.062$). Two patients exhibited a winged scapula postoperatively.

Conclusion:

Lower trapezius transfer seems encouraging to restore shoulder external rotation in OBPP children but with non-significant strength improvement.

--

Introduction

Obstetric brachial plexus palsy (OBPP) affects approximately one in 2,000 live births and 20% have persistent deficits [1]. The main deficits are in shoulder elevation and external rotation (ER). A deficit in ER can elicit an imbalance between the external rotator muscles (infraspinatus, teres minor), which are initially paralyzed, and the internal rotators (subscapularis, pectoralis major, latissimus dorsi), which are less affected [2]. In the case of a persistent deficit, glenohumeral dysplasia may occur with posterior subluxation of the humeral head, as well as shoulder stiffness and decreased passive ER, especially with the arm at the side [3-5]. This stiffness can be treated via anterior arthrolysis, while severe dysplasia can be treated via glenoid osteotomy [5-10].

Tendon transfer to restore active ER can be performed either in isolation or in addition to concomitant surgical procedures. The most common procedure is latissimus dorsi transfer, first described by L'Episcopo [11] and later modified by Hoffer [12], transferring the tendon to the rotator cuff. Some authors have reported good long-term clinical results regarding the restoration of active external rotation [13]. However, internal rotation (IR) stiffness recurrence has been reported after surgery in several cases, even after latissimus dorsi transfer [14-17].

Latissimus dorsi muscle transfer to the cuff might have a tenodesis effect, whether or not it is associated with the teres major [18].

Lower trapezius tendon transfer on the infraspinatus is increasingly used to restore active ER of the shoulder in adults with massive unrepairable rotator cuff tears [19-23]. It has also been applied in patients with paralytic shoulders, and more recently, in children with OBPP [7,18,24-26]. However, even if clinical results seem encouraging, no studies have quantified changes in shoulder rotator muscle strength after this transfer. Moreover, there is a need for pediatric series, especially in children with OBPP using the gold standard, i.e. isokinetic dynamometer, for objectively evaluating shoulder muscle strength and balance [27]. Then, the objective of this study was to quantify changes in shoulder external rotation range of motion and strength after transfer of the lower trapezius to the infraspinatus in children with OBPP.

Materials and Methods

Study design.

We report the results of a prospective single-center, single-surgeon study of children with sequelae of OBPP who underwent an operation to transfer the lower trapezius tendon to the infraspinatus tendon. Patients were assessed after a 12-month follow-up period.

Participants.

Inclusion criteria were children between 3 and 15 years with OBPP sequelae requiring trapezius transfer surgery. Exclusion criteria were children who did not undergo lower trapezius transfer, those with other neuromuscular or traumatic disorders interfering with voluntary upper limb use, and those with a follow-up period of less than 12 months.

The indication for surgery was the absence of active ER with the arm at the side, with at least 15% deficit in the muscle strength of the ER force compared to the contralateral side (as assessed via an isokinetic device), despite having undergone rehabilitation or a previous surgery.

The protocol followed the guidelines of the Helsinki Convention. Written informed consent was obtained from the children and their legal representatives. The study was approved by an independent ethics committee (number 18.07.31.5783).

Surgical technique.

The patient was placed in the lateral decubitus position on the side opposite to the one being operated on. Stability was achieved using pubic and buttock supports. The entire upper limb was in the operative field. No traction device was used, and when traction was needed it was done manually by one of the surgical assistants. In cases with shoulder stiffness, the first step was anterior arthroscopic release, as described by Pearl [9]. Then, for transfer of the lower trapezius to the infraspinatus tendon, a posterior approach was used, and an incision was made along the spine of the scapula. The lower trapezius tendon was identified, dissected up to the insertion point at the medial edge of the spine of the scapula, and then disinserted using a periosteal tab taken from the spine of the scapula. During musculotendinous lifting, care was taken not to injure the spinal accessory nerve (XI), which runs vertically along the deep

side of the body of the trapezius muscle. The transplant was threaded using non-absorbable braided thread (Fig. 1).

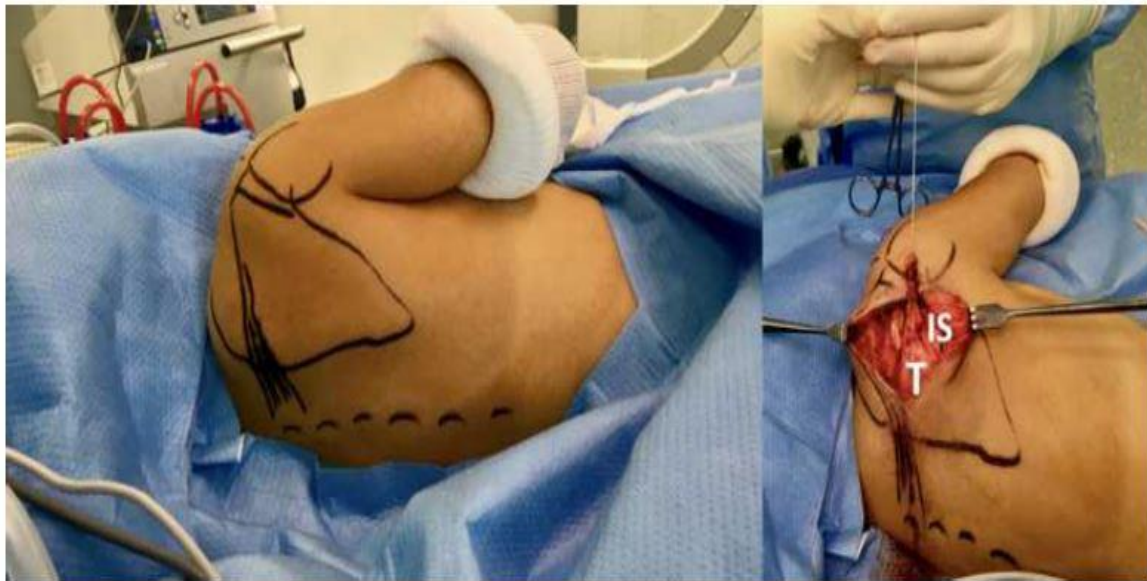


Fig.1 a. The patient was placed in the lateral decubitus position. b. The lower trapezius transfer (T) was extended by a periosteal tab taken from the spine of the scapula and threaded. The lower trapezius transfer was then attached through the infraspinatus tendon (IS) while maintaining maximum external rotation of the shoulder.

The infraspinatus tendon was identified after lifting the posterior head of the deltoid muscle. Removal of the periosteal tab allowed direct transfer to the tendon of the infraspinatus muscle.

The transferred tendon of the lower trapezius was attached to the infraspinatus tendon while maintaining maximum

ER using trans-tendinous sutures.

The patient was immobilized via a chest cast for five weeks postoperatively in abduction and maximum ER. Then, physiotherapy was initiated in a rehabilitation center. During the first two weeks of rehabilitation, the shoulder was passively mobilized and IR was not permitted. Active mobilization without restriction began at two months postoperatively.

Variables.

We collected data preoperatively and at a 12-month follow-up assessment. Specifically, a clinical examination was done with the examination of the passive external rotation and the determination of modified Mallet score [28]. Shoulder rotator muscle strength was determined using an isokinetic device and peak torque (PT, in N·m), was measured. We used the PT values to calculate the strength deficit of the paralyzed limb compared to the healthy limb in ER and IR using the following formula: % deficit = $100 * [1 - (PT \text{ paralyzed limb} / PT \text{ non paralyzed limb})]$. The muscular balance during ER versus IR was calculated using the following formula: $(PT \text{ in ER}) / (PT \text{ in IR})$.



Fig.2 Strength testing of shoulder rotator muscles using an isokinetic dynamometer.

Measurements.

Modified mallet score.

The Mallet score assesses upper extremity function in activities of daily living by evaluating five active shoulder movements which are: active abduction, external rotation, hand placement behind the neck, hand placement as high as possible on the spine, and hand placement toward the mouth. Each movement is scored from 1 (no movement) to 5 (normal and symmetrical movement to the contralateral, unaffected side), giving a maximum score of 25 [28].

Muscle strength.

Measurements were performed using a CON-TREX® MJ isokinetic dynamometer (CMV AG, Dubendorf, Switzerland) in isometric mode with continuous correction of gravitational movement. The children were seated in the Davies position [29] with support provided between the backrest and the back of the subject and/or with a wedge at the elbow (Fig. 2). The dynamometer was connected to a computer running software for recording the measurements. The axis of external–internal rotation of the scapulohumeral joint was in line with the axis of rotation of the dynamometer.

The child was asked to apply as much force as possible in one direction of rotation (external or internal) for five seconds. There was a 30-s rest interval between trials. Three measurements were taken for each direction of rotation. The same protocol was performed on the contralateral side.

Using the CON-TREX® software, we measured the peak torque (PT, in N·m), which is the highest moment force achieved during the measurement period. We excluded the highest and lowest values from each series of three PT measurements thus, only the intermediate value was analyzed.

Statistical methods

The non-normal distribution of our data was assessed with the Shapiro-Wilk test. Wilcoxon test was used for paired sample comparison to compare preoperative and postoperative measurements. We considered that significance was reached when $P \leq 0.05$. Correlations were determined by Spearman analysis. Statistical tests were performed using R software (version 3.1.0, 2014-04-10, The R Foundation for Statistical Computing, Vienna, Austria).

Table 1 Epidemiological and clinical data.

| Patient | Sex | OBPP | Side | Age at time of surgery (years) | ER passive preoperative (°) | ER passive 12-months follow-up (°) | Modified Mallet score preoperative | Modified Mallet score 12-months follow-up |
|--------------------|-----|----------|------|--------------------------------|-----------------------------|------------------------------------|------------------------------------|---|
| 1 | M | Complete | L | 8 | -20 | 15 | 15 | 19 |
| 2 | F | C5-C6 | R | 4 | 0 | 45 | 15 | 18 |
| 3 | F | Complete | L | 4 | 0 | 50 | 12 | 17 |
| 4 | M | C5-C6-C7 | R | 12 | -20 | 25 | 14 | 18 |
| 5 | F | C5-C6-C7 | L | 4 | -20 | 50 | 10 | 20 |
| mean | | | | 6.4 | -12 | 37 | 13.2 | 18.4 |
| standard deviation | | | | 3.58 | 10.95 | 16.04 | 2.17 | 0.84 |
| <i>P</i> | | | | | 0.035 | | 0.035 | |

ER = external rotation, F = female, M = male, L = left, R = right.

Results

Participants.

Five children with 6.4 years (range: 4–12 years) mean age at the time of surgery were included in this study (Table 1). The injury concern two children with a complete brachial plexus palsy, two with C5-C6-C7 palsy, and one with C5-C6 palsy.

Clinical examination.

Preoperative clinical data illustrated an alteration of mean passive (Table 1) ER: -12° (range -20-0) associated with a low modified Mallet score: mean score 13.2/25 which was the maximum value (Fig.3a).

At 12 months follow-up after transfer of the lower trapezius to the infraspinatus, all patients exhibited significant clinical improvement. Passive ER was improved to reach 37° (range: $15-50^{\circ}$) ($p = 0.035$) at 12 months post-surgically. Modified Mallet score also was improved from 13.2 (range: 10–15) preoperatively to 18.4 (range: 17–20) at 12 months post-surgically ($p = 0.035$) (Table 1, Fig.3b).

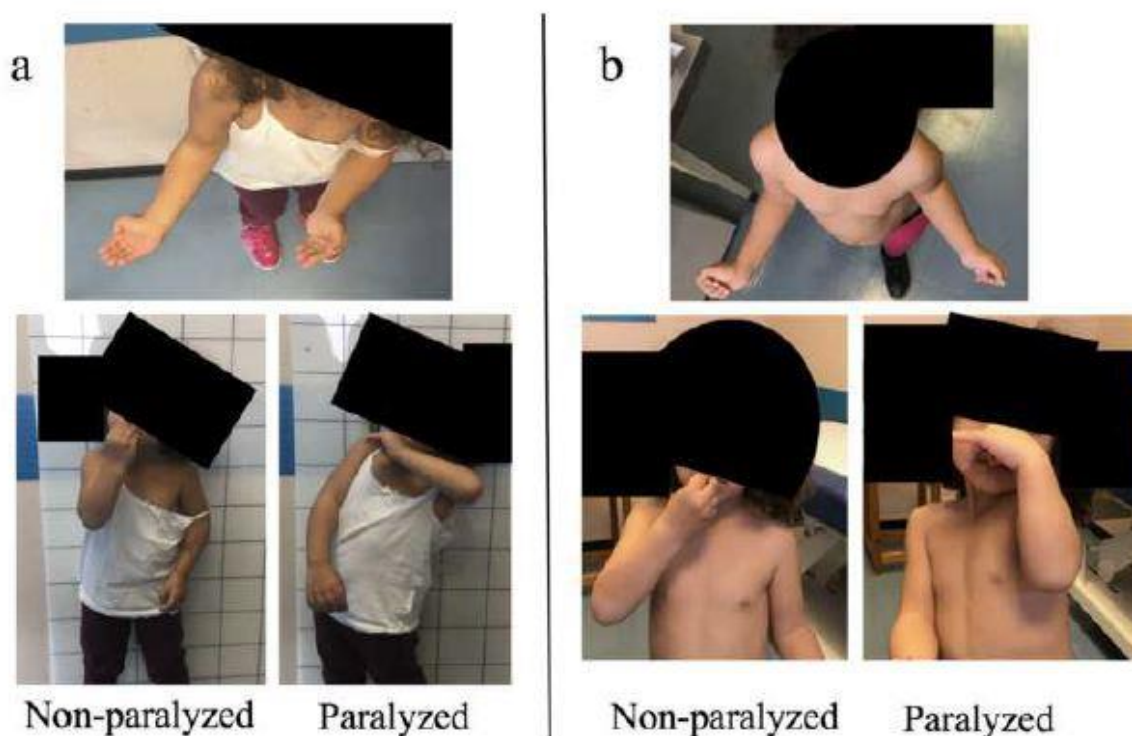


Fig.3 a. Active external rotation and hand to mouth movement of each upper limb before surgery of a four-year-old girl with left OBPP (Patient 5). There is a deficit in active external rotation and the abduction is important when she brings the hand to the mouth (trumpet sign). b. Postoperative result. Active external rotation is normalized. It allows to better perform the hand to mouth movement.

Muscle strength measurements.

The mean PT values in ER was significantly decreased in paralyzed side compared to the non-paralyzed side preoperatively ($p = 0.008$, table 2) or at 12 months post-surgically ($p=0.010$, table 2) whereas there was no significant alteration in IR ($p = 0.209$ and $p=0.253$ in

preoperatively and at 12 months post-surgically, respectively, table 2). Although not statistically significant ($p = 0.062$), there was a PT improvement in ER at 12 months post-surgery from 1.95 N·m (range: 0.30–5.60 N·m) to 4.46 N·m (range: 3.13–6.27 N·m) (Table2).

Table 2 Preoperative and at last follow-up peak torque (PT, N.m) in external rotation (ER) and internal rotation (IR) of the paralyzed limb compared to the non-paralyzed side.

| | | PT Preoperative (N.m) | | | | PT 12-months follow-up (N.m) | | | |
|--------------------|-----------|-----------------------|-----------|---------------|-----------|------------------------------|-----------|---------------|-------|
| | | ER | | IR | | ER | | IR | |
| Limb Patient | Paralyzed | Non-paralyzed | Paralyzed | Non-paralyzed | Paralyzed | Non-paralyzed | Paralyzed | Non-paralyzed | |
| | 1 | 2.03 | 3.54 | 7.03 | 6.40 | 5.23 | 10.90 | 9.57 | 12.40 |
| 2 | 0.30 | 2.50 | 1.90 | 3.80 | 3.60 | 4.23 | 3.63 | 4.50 | |
| 3 | 1.20 | 1.73 | 1.40 | 1.90 | 4.07 | 4.70 | 1.60 | 5.40 | |
| 4 | 5.60 | 12.50 | 6.23 | 21.67 | 6.27 | 18.40 | 6.30 | 20.47 | |
| 5 | 0.62 | 2.70 | 1.37 | 3.13 | 3.13 | 4.47 | 3.93 | 5.50 | |
| Mean | 1.95 | 4.60 | 3.59 | 7.38 | 4.46 | 8.54 | 5.01 | 9.65 | |
| Standard Deviation | 1.92 | 3.99 | 2.51 | 7.29 | 1.14 | 5.53 | 2.72 | 6.11 | |
| <i>p</i> | 0.008 | | 0.209 | | 0.010 | | 0.253 | | |

Two patients were older than the other patients because they had a late management of their paralysis (patients 1 and 4). Therefore, they had higher PT values than younger patients. Despite the above-mentioned improvements in clinical parameters, it is to note that these patients presented a greater percentage of deficit in the strength of the paralyzed limb compared to the healthy limb in ER (from 42.6 to 52.3% and 55.2 to 65.9% for patient 1 and 4, respectively, Table 3) although the PT in ER was concomitantly increased (Table 2) after surgery. Interestingly, these two patients presented a winged scapula postoperatively that increased in IR (Fig. 4).

We also depicted a muscular balance “inversion” in Patient 3 at 12 months post-surgery with stronger external rotator strength compared to internal rotator strength muscles. In paralyzed side, patient 3 presented a PT value of 1.20 N.m in ER before surgery reaching 4.07 N.m after surgery whereas PT values for IR were unmodified by surgery (Table 2). Indeed, the ER was substantially improved illustrated by a large decrease in percentage of deficit ranging from 30.8% to 14.0% after surgery (Table 3).

Table 3 Preoperative and at last follow-up comparison of the shoulder rotator muscles strength, balance (PT in ER / PT in IR) and the percentage of deficit in external rotation (ER) and internal rotation (IR) of the paralyzed limb compared to the non-paralyzed side.

| Limb Patient | Preoperative | | | | 12-months follow-up | | | |
|--------------------|------------------|---------------|-----------|-------|---------------------|---------------|-----------|-------|
| | Muscular balance | | % Deficit | | Muscular balance | | % Deficit | |
| | Paralyzed | Non-paralyzed | ER | IR | Paralyzed | Non-paralyzed | ER | IR |
| 1 | 0.29 | 0.55 | 42.6 | -9.9 | 0.56 | 0.90 | 52.3 | 22.8 |
| 2 | 0.16 | 0.66 | 88.0 | 50.0 | 0.99 | 0.94 | 15.0 | 19.3 |
| 3 | 0.86 | 0.91 | 30.8 | 26.0 | 2.54 | 0.87 | 14.0 | 71.0 |
| 4 | 0.90 | 0.58 | 55.2 | 71.2 | 0.99 | 0.90 | 65.9 | 69.2 |
| 5 | 0.45 | 0.86 | 77.0 | 56.4 | 0.80 | 0.81 | 29.9 | 28.5 |
| Mean | 0.53 | 0.71 | 58.72 | 38.74 | 1.18 | 0.88 | 35.41 | 42.15 |
| Standard Deviation | 0.33 | 0.16 | 23.70 | 31.71 | 0.78 | 0.05 | 23.05 | 25.74 |
| <i>p</i> | 0.640 | | 0.328 | | 0.877 | | 0.774 | |

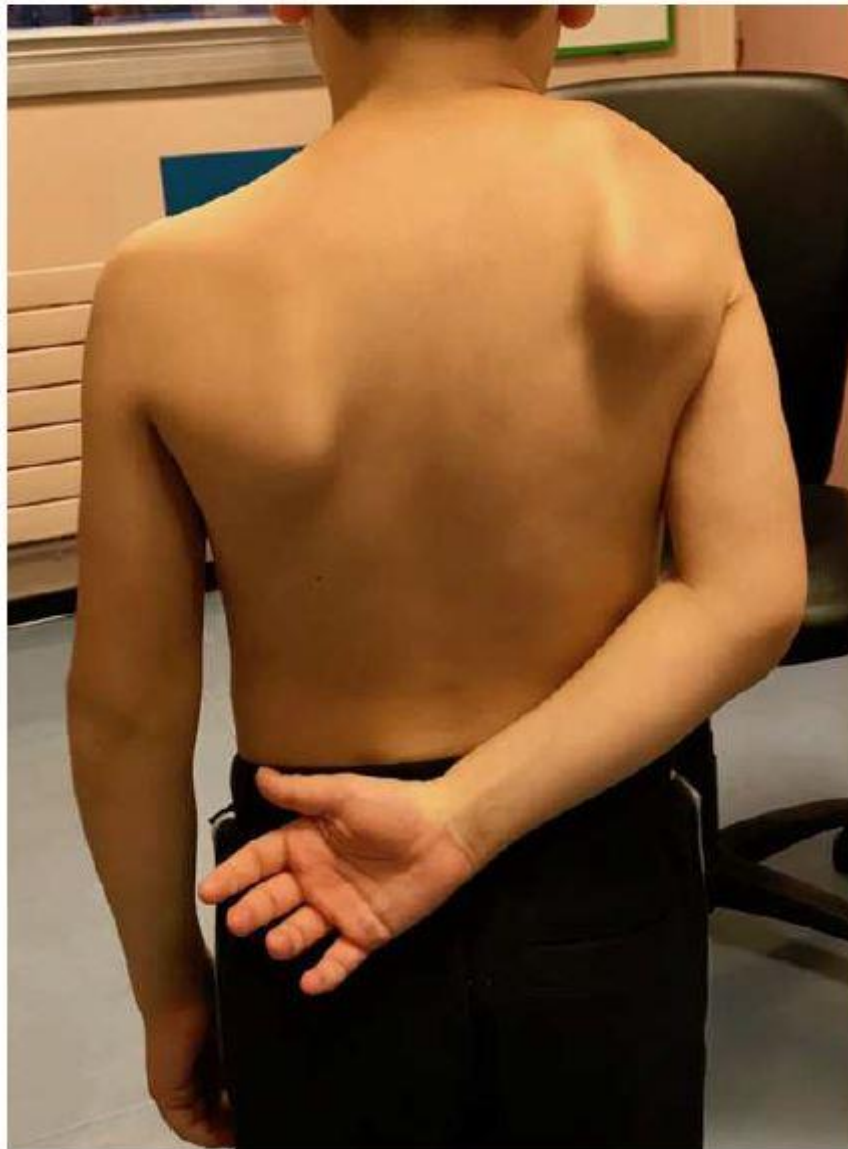

Fig.4 Winged scapula increased in internal rotation (patient 1).

Discussion

Our clinical results regarding lower trapezius transfer are encouraging for the restoration of active shoulder ER in children with OBPP whereas strength improvement wasn't significant. The isokinetic device enabled us to precisely quantify the deficits and improvements in muscle strength, and also unmasked some abnormalities that are difficult to detect during a physical examination. Although all patients exhibited improved postoperative strength during ER, the fact that change was not statistically significant made us qualify our results. Firstly, since patients 1 and 4, who were older, presented a smaller improvement in strength after surgery, it could mask the beneficial effect on muscle strength. Furthermore, although all of the patients exhibited significant clinical improvements in passive ER and the Mallet score, the deficit in ER compared to the non-paralyzed side increased in two patients. We suspect that this deficit could increase over time, potentially abolishing the beneficial effects of muscle transfer. Although the clinical results appeared to be good in one patient, isokinetic testing revealed postoperative inversion of the muscular balance caused by a concomitant strength deficit during IR. This could predispose to a spontaneous bad positioning of the shoulder in ER.

Unfortunately, long-term data from large cases series using this surgery technique are not available, especially in children. Thus, we do not know whether the clinical outcomes of these patients will be affected by growth. Most researchers involved in development of the lower transfer trapezius technique have not yet published data from pediatric series. However, Bertelli et al. [6] reported data from a 2-year follow-up study showing that seven children with OBPP who underwent lower trapezius transfer had good clinical outcomes, although strength testing was not conducted. Overall, data on muscle strength after muscle transfer are lacking. At a 6-month follow-up assessment, Crepaldi et al. [9] found no significant increase in shoulder ER rotation or strength in 10 adults with a brachial plexus injury who underwent lower trapezius transfer. However, strength was only assessed using Lovett and Sunderland's standardization [30]. Few studies have assessed shoulder muscle strength in young children with paralytic conditions using an isokinetic device [2,31-33]. To our knowledge, our study is the first to describe changes in shoulder rotator muscle strength after lower trapezius transfer in OBPP pediatric patients.

The scapular winging effect is not part of the usual complications of this procedure. It can occur without surgery in some OBPP patients [34] as the long thoracic nerve arises from the superior trunk of the brachial plexus. However, in our two cases, the winged scapula appeared postoperatively in the older children. A winged scapula can also be a consequence of spinal accessory nerve palsy [35] but this cranial nerve is preserved in OBPP. Trapezius weakness could be due to an iatrogenic injury to the spinal accessory nerve during dissection, or to the fact that in some cases the trapezius muscle may also be partially innervated by the brachial plexus [36]. The trapezius may also have been weakened due to removal of its lower portion when performing the transfer. However, data concerning this type of transfer in OBPP children are limited. One of our two patients also had a glenoid osteotomy, but again, the winged scapula has not been described as a common complication after this surgery [10]. A further possibility is that the winged scapula was a consequence of postoperative posterior adhesion. In children, shoulder immobilization with a chest cast is generally recommended for several weeks postoperatively maintaining the shoulder in ER and moderate abduction. In adults, removable orthotics are often used to initiate early gentle mobilization, thus limiting

postoperative stiffness and adhesion formation. In our young patients, if the orthosis is removed early, there is a risk of transfer rupture. There are no pediatric-sized thoraco-brachial orthoses on the market for this type of immobilization. Crepaldi et al. used a custom-made orthosis [7]; a similar brace may have been useful in the present case. However, this would be contraindicated in cases of glenoid osteotomy. It is also possible that the transfer was too tight, which could limit passive IR. No clear consensus regarding the amount of tension that should be applied to the transferred tendon has been reached. Very low tensioning increases the risk of an inefficient transfer, while excessive tensioning might cause a tenodesis effect. Additionally, excessive tensioning might prevent efficient contraction of muscle fibers [37,38].

Although the clinical improvement observed in the present study was satisfactory, precise testing of muscle strength revealed anomalies that were considered during subsequent monitoring of these patients. As a result, we now routinely use isokinetic testing during the follow-up of OBPP patients. This helps us to accurately establish the indication for muscle transfer surgery. It is already established that correcting shoulder stiffness and/or a lack of external active rotation can facilitate the treatment of glenoid growth disorders in children with OBPP [39]. In long-term follow-up assessments, it would be interesting to determine whether improving shoulder rotator muscle balance can attenuate the progression of glenoid dysplasia and posterior glenohumeral subluxation/dislocation. Although the etiology of this dysplasia is still debatable, the imbalance of muscle forces of the shoulder rotators probably plays a role in destabilizing glenoid growth [40,41]. In contrast, if there is an inversion of the balance such that the external rotators become stronger than the internal rotators, patients may develop a spontaneous bad positioning of the shoulder in ER. This ER pattern has already been described in OBPP patients who either had a tenotomy or excessive lengthening of the subscapularis tendon [40].

This study had several limitations. First, the patient group was small, and the cases were heterogeneous; some patients had concomitant glenoid osteotomy. It can be challenging to obtain a homogeneous sample for rare pathologies and there are very few data available in the literature regarding the effect of this type of transfer on shoulder strength. Second, the follow-up period was only 12 months nevertheless, it is sufficient to obtain information that could lead to operative and postoperative technical improvements. Furthermore, even if clinical results seem encouraging, the data alerted us to the necessity of longer-term follow-ups to monitor any decreases in the efficiency of the transfer, or signs of overcorrection. Although it would be interesting to compare strength testing data between patients who had undergone a lower trapezius transfer and those who had undergone a latissimus dorsi transfer, we no longer practice the latter because we were disappointed with its mid-to-long-term clinical results.

Conclusions

Our preliminary clinical results regarding lower trapezius transfer are encouraging in restoring active shoulder ER in children with OBPP with strength improvement which didn't reach significance. Our data suggest that such surgery in a younger age (before 8 years-old) seems to induce a higher benefit on muscle rotator strength. Muscle strength enabled us to precisely quantify the deficits and improvements of muscle strength even after lower trapezius transfer, and also revealed some abnormalities that are difficult to detect via physical examination.

Acknowledgments

None

Conflicts of interest

None

Bibliography

- [1] Hoeksma AF, ter Steeg AM, Nelissen RGHH, van Ouwerkerk WJR, Lankhorst GJ, de Jong BA (2004) Neurological recovery in obstetric brachial plexus injuries: an historical cohort study. *Dev Med Child Neurol* 46:76–83. <https://doi.org/10.1017/s0012162204000179>
- [2] Pons C, Sheehan FT, Im HS, Brochard S, Alter KE (2017) Shoulder muscle atrophy and its relation to strength loss in obstetrical brachial plexus palsy. *Clin Biomech (Bristol, Avon)* 48:80–87. <https://doi.org/10.1016/j.clinbiomech.2017.07.010>
- [3] Beischer AD, Simmons TD, Torode IP (1999) Glenoid version in children with obstetric brachial plexus palsy. *J Pediatr Orthop* 19:359–361.
- [4] Pearl ML. Shoulder problems in children with brachial plexus birth palsy: evaluation and management (2009) *J Am Acad Orthop Surg* 17:242–254. <https://doi.org/10.5435/00124635-200904000-00005>
- [5] Pearl ML, Edgerton BW (1998) Glenoid deformity secondary to brachial plexus birth palsy. *J Bone Joint Surg* 80:659–667. <https://doi.org/10.2106/00004623-199805000-00006>
- [6] Abid A, Kany J, Accabed F, Darodes P, Knorr G, Sales de Gauzy (2008) Arthroscopic anterior capsular release in medial contracture of the shoulder secondary to brachial plexus birth palsy. Preliminary results. *Rev Chir Orthop Reparatrice Appar Mot* 94:643–648. <https://doi.org/10.1016/j.rco.2008.01.003>
- [7] Crepaldi BE, Neto JQL, Rezende MR, Júnior RM, Scarcella DS (2019) Lower Trapezius Transfer for Patients With Brachial Plexus Injury. *Hand (N Y)* 14:179–186. <https://doi.org/10.1177/1558944717735944>
- [8] Kozin S, Boardman M, Chafetz R, Williams G, Hanlon A. Arthroscopic treatment of internal rotation contracture and glenohumeral dysplasia in children with brachial plexus birth palsy. *J Shoulder Elbow Surg* 2010;19:102–110. [dot:10.1016/j.jse.2009.05.011](https://doi.org/10.1016/j.jse.2009.05.011)
- [9] Pearl ML (2003) Arthroscopic release of shoulder contracture secondary to birth palsy: an early report on findings and surgical technique. *Arthroscopy* 19:577–582. [https://doi.org/10.1016/s0749-8063\(03\)00390-6](https://doi.org/10.1016/s0749-8063(03)00390-6)
- [10] Dodwell E, O’Callaghan J, Anthony A, Jellicoe P, Shah M, Curtis C, et al. (2012) Combined glenoid anteversion osteotomy and tendon transfers for brachial plexus birth palsy: early outcomes. *J Bone Joint Surg Am* 94:2145–2152. <https://doi.org/10.2106/JBJS.K.01256>

- [11] L'Episcopo JB (1934) Tendon transplantation in obstetrical paralysis. *Am J Surg* 25:122–125. [https://doi.org/10.1016/S0002-9610\(34\)90143-4](https://doi.org/10.1016/S0002-9610(34)90143-4)
- [12] Hoffer MM, Wickenden R, Roper B (1978) Brachial plexus birth palsies. Results of tendon transfers to the rotator cuff. *J Bone Joint Surg Am* 60:691–695
- [13] Pagnotta A, Haerle M, Gilbert A (2004) Long-term results on abduction and external rotation of the shoulder after latissimus dorsi transfer for sequelae of obstetric palsy. *Clin Orthop Relat Res* 426:199-205. <https://doi.org/10.1097/01.blo.0000138957.11939.70>
- [14] Al-Qattan MM (2003) Latissimus dorsi transfer for external rotation weakness of the shoulder in obstetric brachial plexus palsy. *J Hand Surg Br* 28:487–490. [https://doi.org/10.1016/s0266-7681\(02\)00393-5](https://doi.org/10.1016/s0266-7681(02)00393-5)
- [15] Kambhampati SBS, Birch R, Cobiella C, Chen L (2006) Posterior subluxation and dislocation of the shoulder in obstetric brachial plexus palsy. *J Bone Joint Surg Br* 88:213-219. <https://doi.org/10.1302/03/01-620.88B2.17185>
- [16] Kirkos JM, Kyrkos MJ, Kapetanios GA, Haritidis JH (2005) Brachial plexus palsy secondary to birth injuries. *J Bone Joint Surg Br* 87:231–235. <https://doi.org/10.1302/0301-620x.87b2.14739>
- [17] Phipps GJ, Hoffer MM (1995) Latissimus dorsi and teres major transfer to rotator cuff for Erb's palsy. *J Shoulder Elbow Surg* 4:124–129. [https://doi.org/10.1016/s1058-2746\(05\)80066-7](https://doi.org/10.1016/s1058-2746(05)80066-7)
- [18] Bertelli JA (2009) Lengthening of subscapularis and transfer of the lower trapezius in the correction of recurrent internal rotation contracture following obstetric brachial plexus palsy. *J Bone Joint Surg Br* 91:943–948. <https://doi.org/10.1302/0301-620X.91B7.21795>
- [19] Flury M, Kwisda S, Kolling C, Audigé L (2019) Latissimus dorsi muscle transfer reduces external rotation deficit at the cost of internal rotation in reverse shoulder arthroplasty patients: a cohort study. *J Shoulder Elbow Surg* 28:56–64. <https://doi.org/10.1016/j.jse.2018.06.032>
- [20] Elhassan BT, Sanchez-Sotelo J, Wagner ER (2020) Outcome of arthroscopically assisted lower trapezius transfer to reconstruct massive irreparable posterior-superior rotator cuff tears. *J Shoulder Elbow Surg* 29:2135–2142. <https://doi.org/10.1016/j.jse.2020.02.018>
- [21] Stoll LE, Codding JL (2019) Lower Trapezius Tendon Transfer for Massive Irreparable Rotator Cuff Tears. *Orthop. Clin. North Am* 50:375–382. <https://doi.org/10.1016/j.ocl.2019.03.004>
- [22] Valenti P, Werthel J-D (2018) Lower trapezius transfer with semitendinosus tendon augmentation: Indication, technique, results. *Obere Extremit* 13:261–268. <https://doi.org/10.1007/s11678-018-0495-8>

- [23] Wagner ER, Woodmass JM, Welp KM, Chang MJ, Elhassan BT, Higgins LD, et al. (2018) Novel Arthroscopic Tendon Transfers for Posterosuperior Rotator Cuff Tears: Latissimus Dorsi and Lower Trapezius Transfers. *JBJS Essent Surg Tech* 8(2):e12. <https://doi.org/10.2106/JBJS.ST.17.00062>
- [24] Elhassan B (2014) Lower trapezius transfer for shoulder external rotation in patients with paralytic shoulder. *J Hand Surg Am* 39:556–562. <https://doi.org/10.1016/j.jhsa.2013.12.016>
- [25] Elhassan B, Bishop AT, Hartzler RU, Shin AY, Spinner RJ (2012) Tendon transfer options about the shoulder in patients with brachial plexus injury. *J Bone Joint Surg Am* 94:1391–1398. <https://doi.org/10.2106/JBJS.J.01913>
- [26] Allard R, Fitoussi F, Azarpira MR, Bachy M, Grimberg J, Le Hanneur M (2020) Shoulder internal rotation contracture in brachial plexus birth injury: proximal or distal subscapularis release? *J Shoulder Elbow Surg* S1058-2746(20)30675-3. <https://doi.org/10.1016/j.jse.2020.08.001>
- [27] Bernard PL, Codine P, Minier J (2004) Isokinetic shoulder rotator muscles in wheelchair athletes. *Spinal Cord* 42:222–229. <https://doi.org/10.1038/sj.sc.3101556>
- [28] Mallet J (1972) Obstetrical paralysis of the brachial plexus. *Rev Chir Orthop Reparatrice Appar Mot* 58:Suppl 1:201-204.
- [29] Davies G (1992) *Compendium of isokinetics in clinical usage*. S&G Publications. La Crosse, Wisconsin.
- [30] Lovett K, Sunderland K (2002) Classic grading for muscle strength. In: Daniels and Worthingham's muscle testing: techniques of manual examination. Philadelphia: WB Saunders; 2002. p. 1–10.
- [31] Brochard S, Alter K, Damiano D (2014) Shoulder strength profiles in children with and without brachial plexus palsy. *Muscle Nerve* 50:60–66. <https://doi.org/10.1002/mus.24099>
- [32] Hulleberg G, Elvrum A-KG, Brandal M, Vik T (2014) Outcome in adolescence of brachial plexus birth palsy. 69 individuals re-examined after 10–20 years. *Acta Orthop* 85:633–640. <https://doi.org/10.3109/17453674.2014.964614>
- [33] Im HS, Alter KE, Brochard S, Pons C, Sheehan FT (2014) In vivo pediatric shoulder muscle volumes and their relationship to 3D strength. *J Biomech* 47:2730–2737. <https://doi.org/10.1016/j.jbiomech.2014.04.049>
- [34] Terzis JK, Papakonstantinou KC (2002) Outcomes of scapula stabilization in obstetrical brachial plexus palsy: a novel dynamic procedure for correction of the winged scapula. *Plast Reconstr Surg* 109:548–561. <https://doi.org/10.1097/00006534-200202000-00022>
- [35] Seror P, Lenglet T, Nguyen C, Ouaknine M, Lefevre-Colau MM (2018) Unilateral winged scapula: Clinical and electrodiagnostic experience with 128 cases, with special attention to long thoracic nerve palsy. *Muscle Nerve* 57:913–920. <https://doi.org/10.1002/mus.26059>

- [36] Dailana ZH, Mehdian H, Gilbert A (2001) Surgical anatomy of spinal accessory nerve: is trapezius functional deficit inevitable after division of the nerve? *J Hand Surg Br* 26:137-141. <https://doi.org/10.1054/jhsb.2000.0487>
- [37] Fitoussi F, Bachy M (2015) Tendon lengthening and transfer. *Orthop Traumatol Surg Res* 101:S149-157. <https://doi.org/10.1016/j.otsr.2014.07.033>
- [38] Herzberg G, Urien JP, Dimnet J (1999) Potential excursion and relative tension of muscles in the shoulder girdle: relevance to tendon transfers. *J Shoulder Elbow Surg* 8:430-437. [https://doi.org/10.1016/s1058-2746\(99\)90072-1](https://doi.org/10.1016/s1058-2746(99)90072-1)
- [39] Jönsson K, Werner M, Roos F, Hultgren T (2019) Development of the glenohumeral joint after subscapular release and open relocation in children with brachial plexus birth palsy: long-term results in 61 patients. *J Shoulder Elbow Surg* 28:1983–1990. <https://doi.org/10.1016/j.jse.2019.02.025>
- [40] Kozin S, Chafetz R, Barus D, Filipone L (2006) Magnetic resonance imaging and clinical findings before and after tendon transfers about the shoulder in children with residual brachial plexus palsy. *J Shoulder Elbow Surg* 15:554–61. <https://doi.org/10.1016/j.jse.2005.11.004>
- [41] Vuvu TM, Dorniol M, Le Nen D, Thépaut M, Brochazrd S, Pons C (2021) Effect of arthroscopic shoulder release on shoulder mobility and bone deformity following brachial plexus birth injury: a systematic review and meta-analysis. *J Shoulder Elbow Surg* S1058-2746(21)00081-1. <https://doi.org/10.1016/j.jse.2020.12.021>
- [42] Strecker WB, McAllister JW, Manske PR, Schoenecker PL, Dailey LA (1990) Sever-L'Episcopo transfers in obstetrical palsy: a retrospective review of twenty cases. *J Pediatr Orthop* 10(4):442–444.