



HAL
open science

Long-term Outcome of Chilblains Associated with SARS-CoV-2

Florence Poizeau, Sébastien Barbarot, Yannick Le Corre, Emilie Brenaut, Mahtab Samimi, Hélène Aubert, Alexis Toubel, Alain Dupuy

► **To cite this version:**

Florence Poizeau, Sébastien Barbarot, Yannick Le Corre, Emilie Brenaut, Mahtab Samimi, et al.. Long-term Outcome of Chilblains Associated with SARS-CoV-2. *Acta Dermato-Venereologica*, 2021, 101 (12), pp.adv00614. 10.2340/00015555-3930 . hal-03369972

HAL Id: hal-03369972

<https://hal.science/hal-03369972>

Submitted on 26 Oct 2021

HAL is a multi-disciplinary open access archive for the deposit and dissemination of scientific research documents, whether they are published or not. The documents may come from teaching and research institutions in France or abroad, or from public or private research centers.

L'archive ouverte pluridisciplinaire **HAL**, est destinée au dépôt et à la diffusion de documents scientifiques de niveau recherche, publiés ou non, émanant des établissements d'enseignement et de recherche français ou étrangers, des laboratoires publics ou privés.



Distributed under a Creative Commons Attribution - NonCommercial 4.0 International License

Title: The long-term outcome of patients with chilblains associated with SARS-CoV-2

F Poizeau^{1,2}; S Barbarot³; Y Le Corre⁴; E Brenaut⁵; M Samimi⁶; H Aubert³; A Toubel²; A Dupuy^{1,2}

¹ EA 7449 REPERES (Pharmacoepidemiology and Health Services Research), Rennes 1 University, Rennes, France

² Department of Dermatology, CHU Rennes, Rennes, France

³ Department of Dermatology, CHU Nantes France

⁴ Department of Dermatology, CHU Angers, France

⁵ Department of Dermatology, CHU Brest, France

⁶ Department of Dermatology, CHU Tours, France

Short title: The long-term outcome of SARS-CoV-2-induced chilblains

Manuscript word count: 2293

Figures: 4

Tables: 1

Conflict of Interest Disclosures: Mahtab Samimi has received reimbursement for travel and/or accommodation expenses for attending medical meetings from Bristol Myers Squibb, Lilly, Galderma International, Janssen, Abbvie, MSD, outside the submitted work. Alain Dupuy reports reimbursement for travel and/or accommodation expenses for attending medical meetings from Sanofi, and personal fees from Sanofi and Leo Pharma, outside the submitted work.

Funding: None

Legal requirements: The study was approved by the CHU Rennes Ethics Committee on June 24th (Ref 20.79).

SIGNIFICANCE

Reports on the long-term outcome of patients with chilblains associated with SARS-CoV-2 are rare and fragmentary. We provided comprehensive follow-up data about 82 patients having reported chilblains during spring 2020. Two-thirds of patients reported chilblains recurrences or persistence of acral manifestations over a 10 to 12-month follow-up duration. Chilblain recurrences occurred mostly during autumn and winter, suggesting that either weather conditions or further contact with SARS-CoV-2 could act as new triggers. Women have a higher risk to experience incomplete recovery.

ABSTRACT

Numerous cases of chilblains have been observed in the beginning of the COVID-19 pandemic. Our objectives were to provide comprehensive follow-up data for patients reporting chilblains and determine risk factors for incomplete recovery. Patients referred to 5 Hospitals in France between March and May 2020 for chilblains were surveyed on December 2020. A teleconsultation was offered. Among 82 patients having reported chilblains, 27 (33%) reported complete recovery, 33 (40%) had chilblain recurrences after their hands and feet returned to normal, and 22 (27%) developed persistent acral manifestations, mostly acrocyanosis, with or without further chilblain recurrences. Most chilblains recurrences occurred during the following autumn and winter. A past history of chilblains was not associated with recurrences or persistent acral manifestations. Women had a significantly higher risk of developing recurrences or persistent acral manifestations (OR=1.30; 95%CI [1.06-1.59]). To conclude, two-thirds of patients experienced persistent or recurrent acral manifestations after a 10-month follow-up.

Acta Dermato-Venereologica

Corresponding author: Alain Dupuy, MD, PhD

Department of Dermatology, CHU Rennes, 2 rue Henri le Guilloux 35000 Rennes, France,

Tel: + 33 2 99 28 43 49, Fax: + 33 2 99 28 41 00

Mailto: alain.dupuy@chu-rennes.fr

Keywords: chilblains; pernio; perniosis; acral manifestations; SARS-CoV-2; COVID-19; recurrence

INTRODUCTION

Numerous cases of chilblains were reported throughout Europe and North America during the early months of the COVID-19 pandemic (1–9). The association of these acral manifestations with SARS-CoV-2 infection has been a subject of debate since most patients did not have virological confirmation of SARS-CoV-2 infection. It has been hypothesized that a strong antiviral type I interferon response could account for a rapid viral clearance explaining the low levels of anti-SARS-CoV-2 antibodies. This immune response could also be responsible for interferon-induced skin lesions resembling chilblains, as seen in genetic interferonopathies (8,10–13). The outcome of cutaneous manifestations related to SARS-CoV-2 infection is currently arousing increasing interest (14–20). The present study provides a 10 to 12-month follow-up of patients with chilblains who were included in a previous case-control study (21). We also sought to determine the risk factors associated with incomplete recovery.

MATERIALS AND METHODS

Participants and information collection

Individuals referred for chilblains during the first lockdown (March 17 to May 11, 2020) in Western France were included in a case-control study exploring the aetiologic role of SARS-CoV-2 exposure (21). They were referred to 5 University Hospitals (Rennes, Brest, Nantes, Angers and Tours) and all diagnoses were validated by a dermatologist as being chilblains, with the presence of localized erythema and swelling involving acral sites, persistent for more than 24 hours. Information on these chilblains was collected as part of the case-control study. The present study aimed to describe the follow-up from the onset of the reported chilblains (between January 31 and May 3, 2020, according to patients) to an end date between December 31, 2020 and February 4, 2021, according to patients. An online questionnaire was sent to them on December 31, 2020, and patients with incomplete recovery from their chilblains were offered a teleconsultation in January 2021 to collect detailed clinical and virological information. This information was further updated between January 29, 2021 and February 4, 2021.

Statistical analysis

Continuous variables were described using means and standard deviation (SD) or medians and range. Categorical variables were described using frequencies (%). The median duration

of chilblain recurrences with 95% confidence interval (CI) was computed using the Kaplan-Meier method (data censored for ongoing chilblains between January 29 and February 4, 2021). A univariate logistic regression analysis was used to assess the association between incomplete recovery (i.e., persistent or recurrent acral manifestations) and patient characteristics or features related to the initial flare of chilblains. Type 1 error was set at 5%. For patients who experienced persistent or recurrent acral manifestations and had a teleconsultation, a time-line graph covering the period from January 29, 2020 to January 29, 2021 was plotted. Statistical analyses and graphical plot were performed using RStudio Version 1.0.136 (RStudio Inc., Boston, MA, USA).

RESULTS

Study participants

Among the 102 individuals with chilblains who participated in the case-control study (21), 82 (80%) gave information on follow-up via a questionnaire. The 55 patients who reported persistent acral manifestations or recurrence of chilblains were solicited for a teleconsultation and 43 accepted. The study flowchart is presented in [Figure 1](#).

Overview of the follow-up: 3 phases

To provide a synthetic description of the follow-up of patients who reported chilblains during the first lockdown resulting from the COVID-19 pandemic, 3 successive periods were defined diagrammatically:

- i. A first phase during spring 2020 (depicted as the inner ring in [Figure 2](#)), corresponding to chilblains reported during the COVID-19 first wave.
- ii. A second phase during summer 2020 (depicted as the intermediate ring in [Figure 2](#)), following the resolution of the chilblains. Most patients recovered. However, for a fraction of them, chronic acral manifestations distinct from chilblains developed.
- iii. A third phase, roughly during the autumn and the early winter months of 2020-2021 (depicted as the outer ring in [Figure 2](#)), during which recurrences of chilblains were observed.

First phase (spring 2020)

The clinical characteristics of the 82 patients having reported chilblains during the first lockdown (March 17 to May 11, 2020) are presented in [Table 1](#).

Second phase (summer 2020)

All 82 patients reported the resolution of their chilblains. For a majority of patients (n=60), their hands and feet returned to normal. However, 22 patients (27%) evolved towards persistent acral manifestations, distinct from chilblains, including acrocyanosis (n=14), erythromelalgia (n=4), Raynaud phenomenon (n=3), with toe oedema and stiffness in one case, and cold toes (n=1).

Third phase (autumn and winter 2020/2021)

A total of 46 patients (56%) had recurrent chilblains after 10 months of follow-up (Figure 2). Examples of persistent acral manifestations associated with chilblain recurrences are shown in Figure 3. Most chilblain recurrences (n=38, 83%) occurred after October 1, 2020. They reported 2 (n=36) or 3 (n=10) flares of chilblains. Recurrences were less, equally or more severe than the first flare in 32 (70%), 7 (15%) and 7 (15%) cases respectively. The lesions were located on the feet, the hands or both in 34 (74%), 7 (15%), and 5 (11%) cases respectively. Regarding the context of chilblain recurrences, 6 (13%) occurred after acknowledged exposure to cold. Five patients (11%) reported possible viral symptoms (influenza-like illness, diarrhoea, headache) during the recurrences, and 2 patients underwent rt-PCR testing for SARS-CoV-2 with a negative result.

Three evolution profiles: recovery, chilblain recurrences and persistent acral manifestations

From this synthetic description of the follow-up in 82 patients, three evolution profiles can be distinguished among patients having reported chilblains during the first lockdown of the COVID-19 pandemic. In the first group (n=27, 33%), the patients recovered from their chilblains with no recurrence observed within the study time-frame (“recovery” profile); the second group (n=33, 40%) gathered patients who recovered from their chilblains in the spring, but experienced chilblain recurrences in the autumn/winter (“recurrence” profile); the third group (n=22, 27%) gathered patients who, after their chilblains in the spring, presented persistent acral manifestations throughout the study period, with or without chilblain recurrences (“persistence” profile). These 3 profiles are depicted in Figure 2. Figure 4 presents on a time-line the individual follow-up of the 43 patients with a “recurrence” or “persistence” profile for whom detailed information was collected by teleconsultation.

Characteristics of patients with chilblain recurrences or persistent acral manifestations

Among the 67% of patients who developed chilblain recurrences or persistent acral manifestations (i.e., “recurrence” and “persistence” profiles), the median age was 29 years (range 12-84), and 38 patients (69%) were women. Complete information regarding medical history and clinical manifestations was obtained from 43 patients (Figure 2). Five had a history of autoimmune disease, including thyroiditis (n=3), ulcerative colitis (n=1) and Sjögren’s syndrome (n=1). Two patients had inflammatory arthralgia of the knees, wrists and elbows at the time of their chilblain recurrence. Six patients reported persistent extra-dermatological manifestations within the study time-frame: 4 (9%) had a new onset of sicca syndrome, 1 patient had hematuria and leucocyturia, and 1 reported persistent diarrhoea (Figure 4).

Risk factors for chilblain recurrences or persistent acral manifestations

Risk factors for incomplete recovery following chilblains (i.e., a “recurrence” or “persistence” profile) were sought, including age, sex, history of chilblains, previous Raynaud syndrome, positive anti-SARS-CoV-2 serology, systemic COVID-19 symptoms, localization and duration of the first flare of chilblains. Women had a significantly higher risk of developing recurrences or persistent acral manifestations (OR=1.30 ; 95% CI [1.06-1.59]). Neither a past history of chilblains (OR=1.02 ; 95% CI [0.79-1.32]), nor any other characteristics were associated with chilblain recurrences or persistent acral manifestations (Supplementary Table 1).

DISCUSSION

Among the 82 patients who had chilblains during the first lockdown (21), 33% recovered without further acral manifestations over a 10-month period. In contrast, 40% had chilblain recurrences after initial recovery, mostly during autumn and winter, and 27% had persistent acral manifestations from the summer following the chilblains (acrocyanosis, erythromelalgia, Raynaud phenomenon, toe oedema and stiffness, and cold toes), with or without additional chilblain recurrences. Female sex was associated with chilblain recurrences or persistent acral manifestations.

Numerous series of patients with chilblains during the early months of the COVID-19 pandemic in various countries have been reported (1–9). Follow-up data are important because idiopathic chilblains and acral manifestations usually develop in chronic or recurrent mode (22). With nearly one year of follow-up, our estimation of 56% of patients experiencing chilblain recurrences is in line with the proportion recently suggested (19,20). Even assuming that all 20% of the patients who did not answer the follow-up questionnaire recovered, the percentage of patients who experienced chilblain recurrences would still amount to 45%. Previous studies reported only 3 to 18% of recurrences (15–17), but provided very fragmentary follow-up data. In addition, the percentage of chilblain recurrences could also depend on exposure to other triggers (e.g., cold and wet weather) which vary across different geographical areas. Percentages are also liable to change with increasing follow-up duration, since patients classified as having a “recovery” profile could experience chilblain recurrences later on.

Our diagrammatic presentation based on 3 phases (in the spring at the COVID-19 pandemic onset, the following summer, and the following autumn/winter), and 3 evolution profiles (recovery, recurrence or persistence) has the advantage of synthesizing follow-up information. We are aware, however, that not all individuals perfectly fit into this pattern (for instance, some patients experienced chilblain recurrences during the summer), but a time-line graph with individualized information highlights both the exceptions and the common characteristics. The most salient common characteristic lies in the temporal clustering of chilblain recurrences after October 1, 2020. Because they occurred in a colder and damper period in Western France, and also at the time when there was a “second wave” of intense viral circulation in the country –leading to a second national lockdown– no unequivocal

interpretation can be made. Both exposure to weather conditions and increased exposure to SARS-CoV-2 could be the answers to the “why now?” question for this temporal clustering of chilblain recurrences. Regarding the conditions specifically associated with lockdown (e.g., conditions leading to a certain type of viral exposure within households), they may have had a role, but their specific contribution could not be analyzed in our case-control study (21). In addition, we limited our study to the follow-up of chilblains that occurred during the first lockdown and we did not collect new cases at the time of the second lockdown. Data regarding *ex novo* occurrences of chilblains are scarce, which could be explained either by a truly low incidence or by underreporting (16–18). Furthermore, it would have been interesting to evaluate the COVID-19 vaccines as a potential trigger for acral manifestations in these patients (23). However, at the time of evaluation, COVID-19 vaccines were not widely available.

We advocate the term “chilblains” (or “pernio”) to refer to what were previously called “chilblains-like” lesions, because in all series (8,9,24,25), they do not differ from classic chilblains on clinical and histological grounds (22). The specificity can be seen in the causal relationship between SARS-CoV-2 and chilblains (21,26). Classic chilblains occur as recurrent episodes, generally after exposure to cold and wet conditions, which exemplifies how exposure can trigger specific clinical manifestations in predisposed individuals (not everybody develops chilblains when exposed to cold). In our series, 20% of the patients had a past history of chilblains and 80% experienced a flare of chilblains for the first time during the COVID-19 pandemic. We suggest that in individuals with a past history of chilblains, exposure to SARS-CoV-2 in confined homes could act as a new trigger, and in others, as a sufficient cause. The identification of an infectious trigger for chilblains could even lead to the suggestion that other seasonal viruses, possibly human coronaviruses, have a role in triggering seasonal chilblains.

One striking finding in our follow-up study is that about a quarter of the patients who had chilblains during the first lockdown evolved towards a variety of acral manifestations during the summer season. Although it is well-known that some people have acral manifestations all year round, the development of persistent acrocyanosis following chilblains is unusual (22). Pathophysiologically, the more substantiated hypothesis to link exposure to SARS-CoV-2 and chilblains relates to a strong antiviral interferon immune response (8,13,27). In medical

circumstances when abnormally high interferon levels are reached, acral manifestations have been observed: chilblains are one of the hallmarks of genetic type I interferonopathies (28), and acrocyanosis as well as Raynaud phenomenon have been reported following treatment with interferon- α (29,30). Persistent acral manifestations could be promoted by a long-lasting interferon-driven immunological response, which could also account for other manifestations, possibly related to auto-immunity, as observed in some of our patients. Whether these persistent or recurrent acral manifestations, sometimes accompanied by extra-dermatological manifestations, belong to the “long COVID” spectrum is an open question waiting for a better understanding of the pathophysiology of post-COVID syndromes (15,19,31–35).

We have summarized different evolution profiles among patients who had chilblains during the first lockdown of the COVID-19 pandemic, and highlighted persistent and recurrent acral manifestations. The underlying biological and immunological substratum remains to be investigated. These acral manifestations require follow-up, with a specific attention to extra-dermatological manifestations, and auto-immunity in particular.

Acknowledgements: Angela Verdier, MA, and Sarah Leyshon, MA, SARL L' Auracoise, revised the article for the English language. They received compensation for their contribution.

References

1. Recalcati S, Barbagallo T, Frasin LA, Prestinari F, Cogliardi A, Provero MC, et al. Acral cutaneous lesions in the time of COVID-19. *J Eur Acad Dermatol Venereol* 2020; 34: e346–347.
2. Freeman EE, McMahon DE, Lipoff JB, Rosenbach M, Kovarik C, Takeshita J, et al. Pernio-like skin lesions associated with COVID-19: A case series of 318 patients from 8 countries. *J Am Acad Dermatol* 2020; 83: 486–492.
3. Le Cleach L, Dousset L, Assier H, Fourati S, Barbarot S, Boulard C, et al. Most chilblains observed during the COVID-19 outbreak occur in patients who are negative for COVID-19 on polymerase chain reaction and serology testing. *Br J Dermatol* 2020; 183: 866–874.
4. Fernandez-Nieto D, Jimenez-Cauhe J, Suarez-Valle A, Moreno-Arrones OM, Saceda-Corrado D, Arana-Raja A, et al. Characterization of acute acral skin lesions in nonhospitalized patients: A case series of 132 patients during the COVID-19 outbreak. *J Am Acad Dermatol* 2020; 83: e61–63.
5. de Masson A, Bouaziz J-D, Sulimovic L, Cassius C, Jachiet M, Ionescu M-A, et al. Chilblains is a common cutaneous finding during the COVID-19 pandemic: A retrospective nationwide study from France. *J Am Acad Dermatol* 2020; 83: 667–670.
6. Galván Casas C, Català A, Carretero Hernández G, Rodríguez-Jiménez P, Fernández-Nieto D, Rodríguez-Villa Lario A, et al. Classification of the cutaneous manifestations of COVID-19: a rapid prospective nationwide consensus study in Spain with 375 cases. *Br J Dermatol* 2020; 183: 71–77.
7. Piccolo V, Neri I, Filippeschi C, Oranges T, Argenziano G, Battarra VC, et al. Chilblain-like lesions during COVID-19 epidemic: a preliminary study on 63 patients. *J Eur Acad Dermatol Venereol* 2020; 34: e291–293.
8. Hubiche T, Cardot-Leccia N, Le Duff F, Seitz-Polski B, Giordana P, Chiaverini C, et al. Clinical, Laboratory, and Interferon-Alpha Response Characteristics of Patients With Chilblain-like Lesions During the COVID-19 Pandemic. *JAMA dermatology* 2021; 157: 202–206.
9. Herman A, Peeters C, Verroken A, Tromme I, Tennstedt D, Marot L, et al. Evaluation of Chilblains as a Manifestation of the COVID-19 Pandemic. *JAMA dermatology* 2020; 156: 998–1003.
10. Bessis D. Impaired type I interferon response in SARS-CoV-2 infection: looking through the cutaneous window. *Br J Dermatol* 2021; 184: 11–12.

11. Magro CM, Mulvey JJ, Laurence J, Sanders S, Crowson AN, Grossman M, et al. The differing pathophysiologies that underlie COVID-19-associated perniosis and thrombotic retiform purpura: a case series. *Br J Dermatol* 2021; 184: 141–150.
12. Lipsker D. Paraviral eruptions in the era of COVID-19: Do some skin manifestations point to a natural resistance to SARS-CoV-2? *Clin Dermatol* 2020; 38: 757–761.
13. Damsky W, Peterson D, King B. When interferon tiptoes through COVID-19: Pernio-like lesions and their prognostic implications during SARS-CoV-2 infection. *J Am Acad Dermatol* 2020; 83: e269–270.
14. Maanaoui S, Salez F, Carpentier O. Recurrence of chilblains during a second contact with SARS-CoV-2: a case report. *Br J Dermatol* 2021; 185: 227–228.
15. McMahon DE, Gallman AE, Hruza GJ, Rosenbach M, Lipoff JB, Desai SR, et al. Long COVID in the skin: a registry analysis of COVID-19 dermatological duration. *Lancet Infect Dis* 2021; 21: 313–314.
16. Freeman EE, McMahon DE, Lipoff JB, Rosenbach M, Desai SR, Fassett M, et al. Cold and COVID: recurrent pernio during the COVID-19 pandemic. *Br J Dermatol* 2021; 185: 214–216.
17. Signa S, Sementa AR, Coccia MC, Pastorino C, Viglizzo G, Viola S, et al. Recurrence of previous chilblain lesions during the second wave of COVID-19: can we still doubt the correlation with SARS-CoV-2? *J Eur Acad Dermatol Venereol* 2021; 35: e475–477.
18. Recalcati S, Barbagallo T, Tonolo S, Milani M, Fantini F. Relapse of chilblain-like lesions during the second wave of coronavirus disease 19. *J Eur Acad Dermatol Venereol* 2021; 35: e315–316.
19. Moghadam P, Frumholtz L, Jaume L, De Masson A, Jachiet M, Begon E, et al. Frequency of relapse and persistent cutaneous symptoms after a first episode of chilblain-like lesion during the COVID-19 pandemic. *J Eur Acad Dermatol Venereol* 2021; doi: 10.1111/jdv.17393.
20. Hubiche T, Le Duff F, Fontas E, Rapp J, Chiaverini C, Passeron T. Relapse of chilblain-like lesions during the second wave of the COVID-19 pandemic: a cohort follow-up. *Br J Dermatol* 2021; doi: 10.1111/bjd.20584.
21. Poizeau F, Oger E, Barbarot S, Le Corre Y, Samimi M, Brenaut E, et al. Chilblains during lockdown are associated with household exposure to SARS-CoV-2. A multicentre case-control study. Submitted. 2021;
22. Creamer D. Reactions to cold. In: Burns T, Breathnach S, Cox N, Griffiths C, editors.

- Rook's textbook of Dermatology. Eighth edi. 2010. p. 28.65-67.
23. McMahon DE, Amerson E, Rosenbach M, Lipoff JB, Moustafa D, Tyagi A, et al. Cutaneous reactions reported after Moderna and Pfizer COVID-19 vaccination: A registry-based study of 414 cases. *J Am Acad Dermatol* 2021; 85: 46–55.
 24. Kanitakis J, Lesort C, Danset M, Jullien D. Chilblain-like acral lesions during the COVID-19 pandemic (“COVID toes”): Histologic, immunofluorescence, and immunohistochemical study of 17 cases. *J Am Acad Dermatol* 2020; 83: 870–875.
 25. Aschoff R, Zimmermann N, Beissert S, Günther C. Type I Interferon Signature in Chilblain-Like Lesions Associated with the COVID-19 Pandemic. *Dermatopathol (Basel, Switzerland)* 2020; 7: 57–63.
 26. Ortega-Quijano D, Fernandez-Nieto D, Jimenez-Cauhe J, Cortes-Cuevas JL, Marcos-Mencia D, Rodriguez-Dominguez M, et al. Association between COVID-19 and chilblains: a case-control study. *J Eur Acad Dermatol Venereol* 2021; 35: e359–361.
 27. Jabalameli N, Rajabi F, Firooz A, Rezaei N. The Overlap between Genetic Susceptibility to COVID-19 and Skin Diseases. *Immunol Invest* 2021; 1–8.
 28. Volpi S, Picco P, Caorsi R, Candotti F, Gattorno M. Type I interferonopathies in pediatric rheumatology. *Pediatr Rheumatol Online J* 2016; 14: 35.
 29. Campo-Voegeli A, Estrach T, Marti RM, Corominas N, Tuset M, Mascaró JM. Acrocyanosis induced by interferon alpha(2a). *Dermatology*. 1998;196(3):361–3.
 30. Kruit WH, Eggermont AM, Stoter G. Interferon-alpha induced Raynaud's syndrome. *Ann Oncol* 2000; 11: 1501–1502.
 31. Carfi A, Bernabei R, Landi F, Gemelli Against COVID-19 Post-Acute Care Study Group. Persistent Symptoms in Patients After Acute COVID-19. *JAMA* 2020; 324: 603–605.
 32. Petersen MS, Kristiansen MF, Hanusson KD, Danielsen ME, á Steig B, Gaini S, et al. Long COVID in the Faroe Islands: A Longitudinal Study Among Nonhospitalized Patients. *Clin Infect Dis*. 2020 Nov 30; doi: 10.1093/cid/ciaa1792.
 33. Logue JK, Franko NM, McCulloch DJ, McDonald D, Magedson A, Wolf CR, et al. Sequelae in Adults at 6 Months After COVID-19 Infection. *JAMA Netw open* 2021; 4: e210830.
 34. Salmon-Ceron D, Slama D, De Broucker T, Karmochkine M, Pavie J, Sorbets E, et al. Clinical, virological and imaging profile in patients with prolonged forms of COVID-19: A cross-sectional study. *J Infect* 2021; 82: e1–4.
 35. Nasserie T, Hittle M, Goodman SN. Assessment of the Frequency and Variety of

Persistent Symptoms Among Patients With COVID-19. *JAMA Netw Open* 2021; 4:
e2111417.

Table 1. Characteristics of patients reporting chilblains during the first lockdown

Characteristics, n (%)	Patients (N=82)
Age in years, mean (sd)	30.4 (14.9)
Sex, women	49 (59.8)
History of chilblains	16 (19.5)
History of Raynaud syndrome	16 (19.5)
SARS-CoV-2 serology	
Positive	3 (4.9)
Negative	58 (95.1)
Localization of chilblains	
Feet	59 (72.0)
Hands	13 (15.9)
Both	10 (12.2)
Symptoms suggesting COVID-19^a	28 (34.1)
Duration of chilblains in days, mean (sd)	33.7 (24.6)

^a among anosmia, ageusia, fever, asthenia, rhinitis, sore throat, cough, dyspnea

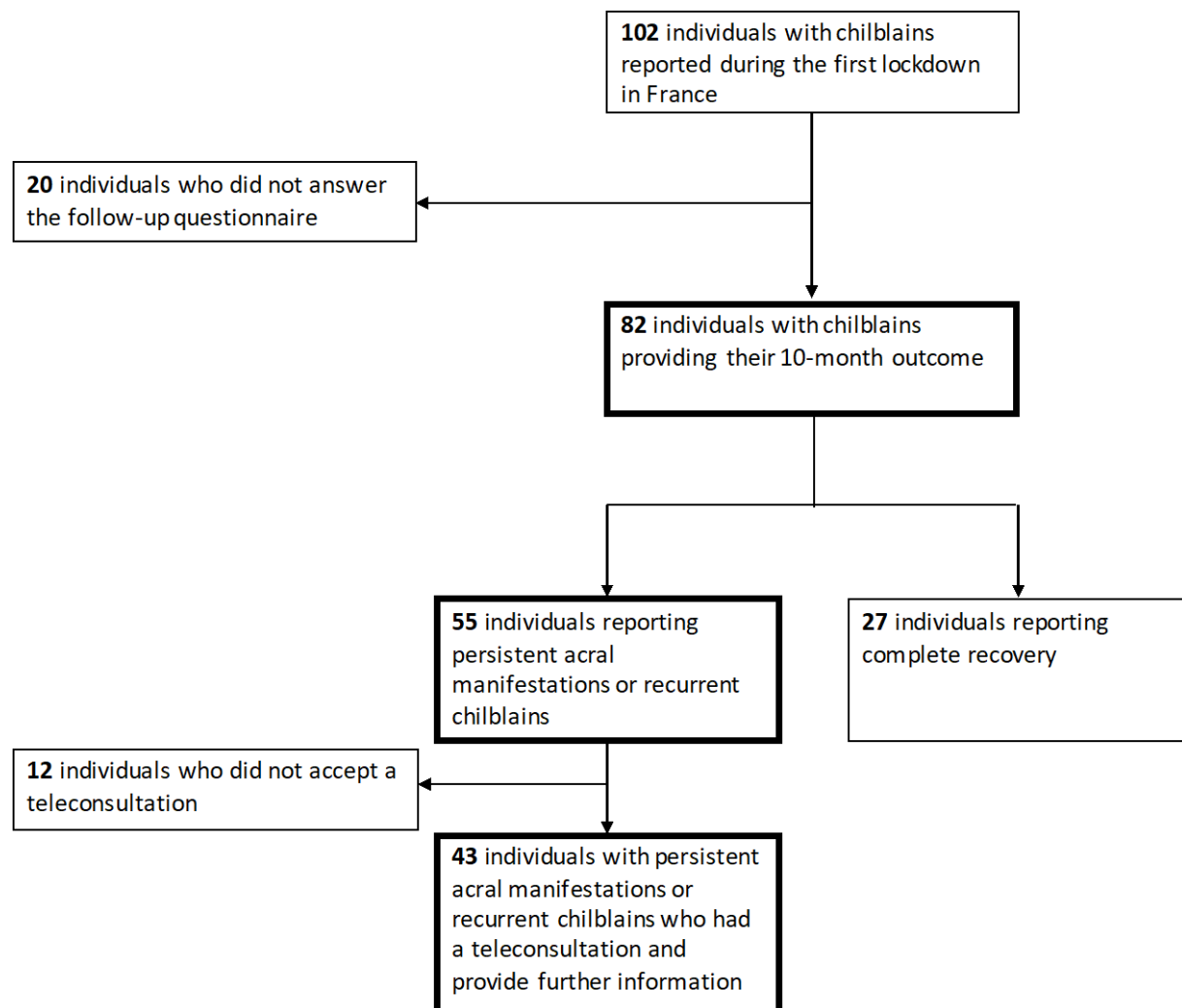
Figure 1. Study flowchart

Figure 2. Diagrammatic sequence of acral manifestations during follow-up

Among patients with chilblains during the first lockdown in spring 2020 (n=82 [100%]; inner ring of the donut chart), chilblains resolved in all cases. During the following weeks (intermediate ring - summer), hands and feet returned to normal (n=60 [73%]) or evolved towards persistent acral manifestations (n=22 [27%], including acrocyanosis, erythromelalgia, Raynaud phenomenon, toe oedema and stiffness, and cold toes). After 10 to 12 months of follow-up (outer ring - mostly in the autumn and winter), 27 [33%] patients remained free of lesions, 46 [56%] had chilblain recurrences (including 33 [40%] patients whose hands and feet had returned to normal), and 9 [11%] had persistent acral manifestations without recurrence of chilblains (outer ring). This description enables 3 evolution profiles to be identified (recovery, recurrence or persistence).

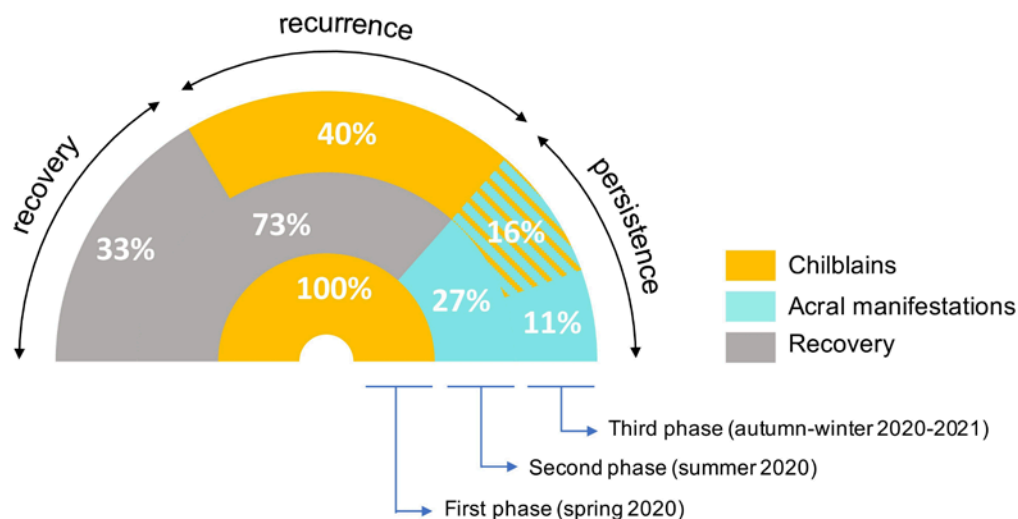


Figure 3. Examples of patients with persistent acral manifestations who experienced chilblain recurrences.

A, B Distal erythema of multiple toes with some oedema in a symmetric pattern, leaving persistent cyanotic discoloration (patient #3 and #35). **C** Violaceous and erythematous papules and patches on the toes (patient #29).

Patient numbers are reported in [Figure 4](#).

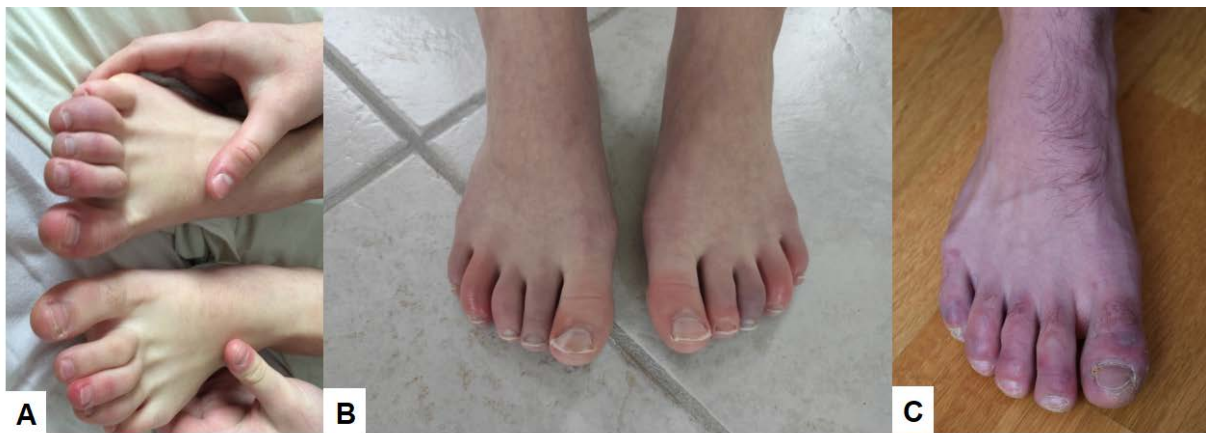

Figure 4. Time-line plot showing the chronology of clinical manifestations over 12 months for patients reporting persistent or recurrent acral manifestations (patients with a “persistence” or “recurrence” profile)

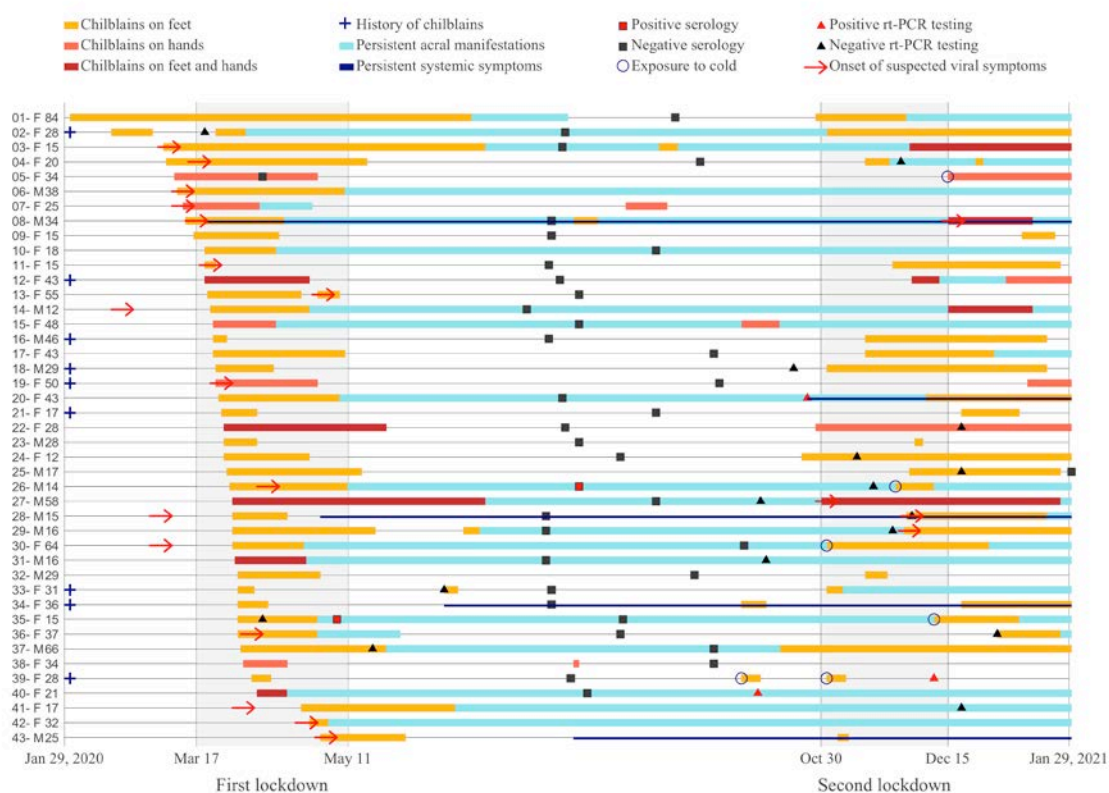
Sex (F: female; M: male) and age are specified at the start of the line for each patient reported.

Persistent systemic manifestations were as follow:

Patients #8 #20 #34 #43 reported a sicca syndrome since the first flare of chilblains or beginning after a rt-PCR-confirmed COVID-19, associated with a persistent hyposmia in one (patient #20).

Patient #42 had hematuria and leucocyturia associated with chilblains, which receded over 7 months.

Patient #28 reported diarrhoea after his first flare of chilblains (normal abdominal ultrasound, normal stool test for bacteria and parasites), which persisted thereafter.



Supplementary Table 1. Risk factors for persistent or recurrent acral manifestations following chilblains

	Odds-ratio	95% Confidence Interval	P-value
Age , for one year	1.003	0.996-1.010	0.41
Sex , for women	1.3	1.06-1.59	0.01
History of chilblains	1.02	0.79-1.32	0.88
History of Raynaud syndrome	1.02	0.79-1.32	0.88
Seropositivity for SARS-CoV-2^a	0.99	0.57-1.73	0.98
Duration of the initial flare of chilblains , for one day	1.003	0.999-1.007	0.20
Symptoms possibly related to COVID-19^b	1.07	0.86-1.33	0.55
Localization of chilblains (ref=hands)			0.15
Feet	1.31	0.99-1.73	
Feet and hands	1.15	0.78-1.69	

^a serological tests performed between May and August 2020

^b among anosmia, ageusia, fever, asthenia, rhinitis, sore throat, cough, dyspnea