



Denosumab in the management of Aneurysmal bone cyst

Julien Maximen, François Robin, Alexandre Tronchot, Adrien Rossetti,
Mickaël Ropars, Pascal Guggenbuhl

► To cite this version:

Julien Maximen, François Robin, Alexandre Tronchot, Adrien Rossetti, Mickaël Ropars, et al.. Denosumab in the management of Aneurysmal bone cyst. Joint Bone Spine, 2022, 89 (1), pp.105260. 10.1016/j.jbspin.2021.105260 . hal-03369670

HAL Id: hal-03369670

<https://hal.science/hal-03369670>

Submitted on 22 Nov 2021

HAL is a multi-disciplinary open access archive for the deposit and dissemination of scientific research documents, whether they are published or not. The documents may come from teaching and research institutions in France or abroad, or from public or private research centers.

L'archive ouverte pluridisciplinaire **HAL**, est destinée au dépôt et à la diffusion de documents scientifiques de niveau recherche, publiés ou non, émanant des établissements d'enseignement et de recherche français ou étrangers, des laboratoires publics ou privés.



Distributed under a Creative Commons Attribution - NonCommercial 4.0 International License

Denosumab in the management of Aneurysmal bone cyst: a literature review

Julien Maximen^a, François Robin^b, Alexandre Tronchot^c, Adrien Rossetti^d, Mickaël Ropars^e, Pascal Guggenbuhl^f

^a Department of Orthopedic surgery, Pontchaillou University Hospital, 2 rue Henri Le Guilloux, 35033, Rennes, France.

^b INSERM, Univ Rennes, INRA, Rheumatology department CHU Rennes, Institut NUMECAN (Nutrition Metabolisms and Cancer), 35000 Rennes

^c Department of Orthopedic surgery, Pontchaillou University Hospital, 2 rue Henri Le Guilloux, 35033, Rennes, France.

^d Department of Orthopedic surgery, Pontchaillou University Hospital, 2 rue Henri Le Guilloux, 35033, Rennes, France.

^e Department of Orthopedic surgery, Pontchaillou University Hospital, 2 rue Henri Le Guilloux, 35033, Rennes, France.

^f INSERM, Univ Rennes, INRA, Rheumatology department CHU Rennes, Institut NUMECAN (Nutrition Metabolisms and Cancer), F-35000 Rennes.

Corresponding Author : Julien Maximen

E-mail : julien.maximen@chu-rennes.fr

Highlights

- 1) There is no current standard of denosumab therapy in aneurysmal bone cyst.
- 2) Denosumab appears to be effective in pain relief and neurological improvement.
- 3) Side effects such as hypercalcemia might be life threatening.

4) Recurrence rate after discontinuation needs further research.

Journal Pre-proof

Abstract

Background

Aneurysmal bone cyst (ABC) is a benign, locally aggressive tumour that arises predominantly in long bones and spine. Following the encouraging results of Denosumab use in Giant Cell Tumors (GCT) and the histological similarities between ABC and GCT, the interest on the role of Denosumab in the therapeutic arsenal of the most advanced ABC is growing.

The purpose of this literature review is to investigate the current state of knowledge about the use of denosumab in ABCs.

Methods

A literature research was conducted through PUBMED, COCHRANE and GOOGLE SCHOLAR using the keywords “aneurysmal bone cyst” AND “denosumab”. Seventeen articles were included.

Results

A total of 43 cases were reported in the literature. There were 23 males, 20 females. The mean age was $15,9 \pm 8,1$ year. Pain relief and neurological improvement were rapid and sustained. Radiological assessment showed ossification and/or volume reduction in 36/39 patients. Eight patients (18,6%) presented a recurrence after or during denosumab therapy of whom 7 were adults. Adverse events occurred in 11 patients, 5 of them were admitted to the intensive care unit due to hypercalcemia.

Conclusion

Denosumab use in non-surgical ABCs has shown a positive impact in pain and neurological symptoms. The oncological outcome remains unclear with a recurrence rate of 18,6% during/after denosumab therapy, mostly in adults. However, regarding the potential clinical benefits, its use might be discussed in the most advanced cases.

Further research and clinical trials are mandatory to precise its belonging in the therapeutic arsenal.

Keywords: aneurysmal bone cyst, denosumab, recurrence, review,

Journal Pre-proof

1 Introduction

Aneurysmal bone cyst (ABC) is a rare, benign, potentially locally aggressive bone lesion. Its main characteristics are a rapid growth and a local bone destruction which can compromise bone integrity and stability, hence secondary fractures. ABCs represent 1-2 % of total primitive bone tumors [1,2]. People in their first two decades represent 80% of the cases. The man/woman sex-ratio is 0,84 [2,3]. The most frequent localizations are the humerus, femur, tibia, fibula and spine/pelvis [1–3]. The latter represents a serious challenge for the management due to the proximity with nerves and vessels.

Histologically, ABC is characterized by blood-filled cavities separated by fibrous septa. There are different cell types: fibroblasts, Osteoclasts-like Giant cells (similar to those found in giant cell tumors), and a population of mitotically active spindle cells [1]. ABCs were thought to be caused by a local disruption in blood flow and venous pressure, but a study reported the presence of a balanced chromosomal translocation t(16;17) (q22;p13) in 75% of the cases causing a perturbation in the ubiquitin carboxyl-terminal hydrolase 6 (USP6). This promotes the production of TRE17, a protease increasing the activity of two matrix metalloproteinase, MMP-9 and MMP-10 and inhibiting the osteoblasts maturation through an autocrine mechanism with an increase in VEGF production, explaining the hyper vascularisation of those tumors [4]. Primitive ABC must be differentiated from secondary ABC, which represents 30% of cases, but arises from other bone tumor like Giant Cell Tumors (GCT), cortical defects, osteoblastoma or enchondroma [5,6].

The treatment gold standard is surgery. “En bloc” resection offers a local control in 100 % of the cases, but sometimes at a high functional cost [3,7,8]. Moreover, En bloc resection is often non-feasible in pelvic and spine ABCs due to an unbearable morbidity. Therefore, less morbid surgery has been developed such as curettage combined with adjuvant therapy (cryotherapy, phenol...) that allows a local control rate of 80 to 90 % [9]. The main remaining problem is

the management of the most advanced lesion and the one localized in areas such as cervical spine or pelvis. Surgery is often too harmful and do not offer a sufficient control rate regarding the potential complications and disabilities induced. Consequently, new therapies were recently developed to allow clinical and functional improvement while maintaining a satisfactory local control rate. Sclerotherapy offers a control rate of up to 85%, but with serious adverse events such as thromboembolism when using Ethibloc®.[10,11]

Most recent studies have reported, as in GCT, the overexpression of the receptor activator of nuclear factor kappa-B ligand (RANKL) in ABCs [12,13]. RANKL is a ligand playing a central role in bone remodelling by binding to RANK and therefore stimulating osteoclastogenesis and bone resorption. Due to the histological similarities and the encouraging results of denosumab use in GCT [14], denosumab has recently shown increased interest in the management of ABC.

The present review aimed to review the literature about ABC and denosumab use.

2 Methods

We followed the recommendations of the Preferred Reporting Items for Systematic Reviews and Meta- analyses statement (PRISMA)[15]

2.1 Inclusion criteria

All articles presenting the outcomes of denosumab used in the treatment of ABC were screened. To be included in the study, they must report demographic data (age, sex) of the patient, location of the ABC, all management of the tumor, all relapses, the delay of recurrence and the precise regimen of denosumab administration.

PubMed, Cochrane library databases and Google scholar search software were used to identify all relevant publications. Articles including « denosumab » AND « aneurysmal bone cyst » terms were initially selected. Papers references were also manually reviewed.

Figure 1 illustrates the search strategy.

Each article has been reviewed by two authors and disagreements were resolved through discussion.

2.2 Data extraction

Demographic, clinical and tumour characteristics were extracted.

Outcomes of denosumab therapy were defined as pain improvement defined as diminished pain measured using any valid method or as reported by the patient. If initially present, improvement or not of neurological symptoms using any valid measure method or as reported by the patient. If available, radiological results (such as ossification and volume reduction), histological examination after denosumab were extracted. As well as recurrence and delay of recurrence.

The data extracted about denosumab were: precise dosage, any pre denosumab management, duration of denosumab, recurrence after or under denosumab, any adverse event due to denosumab, duration of follow-up. Data are reported raw and further divided in two broad categories, on the one hand patients aged under 15 years old (paediatric population), on the other hand patients older than 15 years old (adult population).

2.3 Quality assessment:

The eligibility criteria for each article were assessed by two authors.

2.4 Statistical analysis:

The means and standard deviations of demographic information and eligible outcomes were calculated and reported.

Fisher's exact Test has been used to compare recurrence rate between the paediatric and the adult population, significance was set at $p < 0,05$.

3 Results

Out of a total of 585 articles, 18 articles underwent full text analysis [12,16–32] because the other papers were about other diseases or were reviews. All the analysed articles were case reports or case series. Of those 18 articles, 17 were included in the review due to insufficient data in the article published by Grahneis and al [20]

3.1 Demographic data

The study population consisted of 43 patients with an average age of $15,9 \pm 8,1$ years, 23 males (53%) and 20 females (47%). Twenty-one patients were younger and twenty-two older than 15 years old. The location of the aneurysmal bone cysts were: Skull base, mandible, thoracic spine, distal fibula, talus, costo vertebral junction, ulna: 1, radius, humerus, tibia: 2, spine w/o precision: 3, Lumbar spine: 4, cervical spine: 6, pelvis: 7, sacrum: 8.

Table 1 and Table 2 report the demographic data, clinical presentation of the different cases included in the study.

3.2 Characteristics of denosumab therapy

Twenty patients received denosumab as first line treatment. Three patients received denosumab combined with another therapy such as chemotherapy [17], selective embolization [24], selective embolization and surgery [18] as first line of treatment.

Eighteen patients underwent denosumab therapy after one or more recurrence: 9 after one, 8 after two and 1 patient after three.

The two remaining patients received denosumab due to a non-response to the first treatment: a 16 years old male with a cervical spine ABC received denosumab 2 months after a failed treatment with corticosteroids and calcitonin injection [26], an 18 years old male with a sacral ABC underwent denosumab therapy 3 months after a non-response to polidocanol injection and selective embolization [19].

The status of denosumab therapy at the time of publication varied across, but also within the different studies: 14 patients were still under denosumab at the time of publication, 6 at long course due to recurrence, 8 because the report was published before the end of treatment while 29 patients completed their denosumab therapy with a mean duration of $13,3 \pm 8,1$ month.

3.3 Clinical Outcomes (tables 1 and 2)

3.3.1

Pain: 42/43 patients were initially reported as painful, data about pain improvement was available for 38 patients, all of them presented pain improvement under denosumab therapy. The time to pain improvement was available for 21 patients, its mean time was $1,8 \pm 1,3$ months.

3.3.2

Neurological symptoms: 11/43 patients presented neurological complications at presentation, all of them presented clinical improvement under denosumab. [12,18,22,24,25,28,29]

3.4 Radiological Outcomes (tables 1 and 2)

Thirty-nine cases reported radiological outcomes: 36 associated with volume decrease and/or ossification of the lesion, 2 remained stable. One patient presented an increased volume of the tumour during denosumab therapy and was further treated with surgery due to a non-response to denosumab.

3.5 Recurrence (tables 3,4 and 5)

Overall, eight recurrences were reported in our literature review. Six of them occurred after denosumab discontinuation [19,23,24,27,29]: 4 females and 2 males with a mean age of $19,2 \pm 8,9$ years old. Three of the recurrences (50%) occurred at the pelvis, the 3 others occurred at the distal radius, the 7th costo vertebral junction, the cervical spine. The patients had received denosumab for a mean duration of $13,2 \pm 6,1$ months following different regimen (**table 5**). Recurrence occurred at a mean time of 11 ± 6 months after discontinuation. Thereafter, 5/6 patients were managed with a restart and a longer course denosumab, 1/6 with sclerotherapy. The two other patients have presented a recurrence during denosumab therapy. Raux and al [29] reported a 17 years old male with a lumbar spine ABC initially treated with sclerotherapy and surgery who presented a recurrence at 6 months post-surgery. He was further treated with denosumab 70 mg/m² weekly one month, then monthly but presented a recurrence at 23 months that contributed to the maintain of denosumab at long course. The case of a 30 years old woman with a pelvis ABC reported by Durr and al [19] is a unique medical history due to pregnancy. She underwent two surgical procedures that led to a recurrence 42 months after the second procedure, managed with denosumab therapy 120 mg sc weekly during 1 month then monthly. She presented a recurrence after 8 months of denosumab that was managed by surgery. After this third surgery, she became pregnant for the first time, denosumab was

discontinued. She presented another recurrence 18 months later, managed with a new round of denosumab for 18 months that was then discontinued due to a second pregnancy. Another recurrence occurred 36 months after this discontinuation leading to a long course denosumab. The paediatric population presented one recurrence while the adult population presented seven recurrences which is statistically significant using the Fisher's exact test with a p value of 0,046.

3.6 Histology

Histological examination after denosumab therapy was available for 8 patients. All of them presented the same histological result: new bone formation, hypo cellular fibrous stroma containing scattered mononuclear cells, no giant cell. [16,23,25,27,29–31]

3.7 Adverse events (tables 3 and 4)

Eleven patients (25%) presented one or many adverse events related to denosumab. Tables 3 and 4 gather the adverse events reported across the studies.

During denosumab therapy, four patients of the paediatric population with a mean age of $9,8 \pm 2,4$ years old presented asymptomatic hypocalcaemia (2 measures available: 2,03 and 1,9 mmol/l). Two hypocalcaemias occurred even with an initial calcium and vitamin D supplementation and were treated by increased supplementation [12,29]. The two remaining patients did not receive initial supplementation, Marcus and al introduced the supplementation after the discovery of the hypocalcaemia [21], Upfill-Brown[32] did not introduce any treatment and the hypocalcaemia self-resolved 2 months later. Those hypocalcaemia occurred in the first two months of treatment. The other adverse events reported were the following: one child presented an ossification of his lower limb growth plate[21], two adults reported

fatigue [23], one adult reported muscle pain [23], one child and one adult reported vomiting or gastro-intestinal disorders.[23,25]

After discontinuation, six patients of the paediatric population with a mean age of $9\pm 3,2$ years old presented hypercalcemia, diagnosed at a mean time of $5,3\pm 0,52$ months after cessation of denosumab of whom 5 (83%) needed an admission in an intensive care unit (ICU). [19,21,23,29,32]

4 Discussion

Denosumab is a fully human monoclonal antibody binding RANKL and inhibiting its effect. It results in the inhibition of the proliferation of the osteoclasts and interestingly in the case of ABCs, the proliferation of giant cells [33,34]. Denosumab has a powerful inhibitory effect on bone turnover.

Denosumab was approved by the FDA in 2013 and by the EMA in 2014 for the treatment of GCT in “adults and skeletally mature adolescents with giant cell tumor of bone unresectable or when surgical resection is likely to result in severe morbidity”, following encouraging results in a phase 2 trial. [35]. Denosumab is only validated in children skeletally matured due to concerns about linear growth, teeth eruption and growth plate ossification [36].

ABCs mostly occur in young adults and children, and the use of denosumab is theoretically contraindicated.

However, its use has been described in osteogenesis imperfecta, juvenile Paget’s Disease, fibrous dysplasia with reassuring tolerance in children and encouraging results regarding clinical improvement [37,38].

The 43 patients with ABC reported so far presented demographic and clinical features consistent with the literature [2,3]. However, there was a slightly different location of tumors. Mankin and al [3] reported 37/150 tibial ABC, 26/150 femoral ABC while our most represented locations were spine: 14/43 and the pelvis/sacrum with 15/43 cases. This difference is probably due to the more aggressive disease at spine and pelvic/sacrum sites, more susceptible to lead to an unacceptable surgery at once, and therefore be eligible to denosumab.

To the best of our knowledge, there is currently no published clinical trial about the use of denosumab in ABC. Our literature search found only case reports and cases series with different denosumab regimen. Some authors decided to use the GCT denosumab protocol [14,35] while others proposed protocols based on previous studies evaluating for example the use of denosumab in children presenting fibrous dysplasia [39].

This makes any comparison difficult, but most of all, it highlights the need of well conducted clinical trials to investigate the optimal dosage of denosumab in ABC.

About the analysed outcomes, it is noteworthy that no matter the denosumab regimen, every patient with available data presented rapid and sustained pain relief and neurological improvement under denosumab. This is of particular importance in those mostly young patients to preserve their function and quality of life.

When available, radiological follow up reported a positive response in 26/29 patients treated by denosumab. This radiological improvement can be compared to the one in GCT where denosumab induces new bone formation in the lesion [40–42].

The bone filling is particularly important in pelvic and spine regions as it can improve the local stability and reduce the risk of fractures related to the local aggressiveness of the ABCs. It can also facilitate a secondary surgical management even if curettage following denosumab therapy is still under discussion in GCT [33,40]. One must notice that only 6 cases underwent

surgery after denosumab. Three of them presented a recurrence after surgery. This result should be interpreted with caution, but it is noteworthy that the intra-lesional bony formation under denosumab seems to be a problem for surgery as in GCT. It has been hypothesized that some tumor cells could be trapped in the new bone formation, not in reach of the surgeon, causing an incomplete procedure [40,43]. This supposition needs further research in ABCs.

Histological examination after denosumab therapy was consistent with what is known about GCT modification under denosumab therapy: disappearance of Giant cell, new woven bone formation and lamellar cortical bone at the surroundings of the lesion [33]. The cysts were also filled with a collagen rich, ossified connective tissue. The typical aspect of ABC was lost. This supports the ABCs response to denosumab therapy and its effectiveness in controlling, at least in part, the disease. It is important to note the presence of a hypo cellular stroma but we did not find a more precise description in the reports, despite the fact that it is of importance because the residual presence of spindle cells could reflect that denosumab brought the suspension of the disease but not its cure as it was previously reported those stromal cells are the one producing the RANKL.

Overall, recurrence occurred in 8 cases (18%) during or after denosumab therapy. The 6 recurrences after discontinuation occurred in the first 2 years post denosumab. None of those patients had received another treatment before the recurrence. The fact that most recurrences occurred in the first two years after discontinuation is in line with what was also found with other treatments (sclerotherapy, surgery) used in ABCs [3]. This is also similar to the delay of recurrence seen in GCT after denosumab therapy [33]. Firstly, this might be explained by the rapidly reversed effect of the denosumab after discontinuation [44] and secondly it must be kept in mind that denosumab suspends the progression of the disease through the inhibition of the RANK/RANKL pathway but do not destroy the stromal cells. Finally, the question can be

asked about the role in tumour recurrence of the sometimes very significant increase in bone remodelling after denosumab cessation.

This 2-year cut-off has a huge impact on the validity of the cases reported in the present study because of the 37 remaining cases, only 8 reported a duration of follow up of more than 2 years after denosumab discontinuation. Thus, 29 cases were either still treated or reported a follow-up < 2 year. This might underestimate the recurrence rate of ABCs after denosumab discontinuation and needs further investigations.

An important aspect of the results is the statistically significant difference of recurrence rate between the adult and paediatric population. One point of particular interest is the regimen of denosumab found in the recurrences after denosumab discontinuation: 4/6 of the patients underwent a denosumab therapy with lowered adapted dosage but most of all, $\frac{3}{4}$ of those recurrences were adults which could signify that this decreased dosage has a deleterious effect and could strongly diminish the efficacy of denosumab. Moreover, the dosage adaptation is currently not recommended by the FDA nor the EMA. This increased risk of recurrence in patients treated with low dosage denosumab needs further confirmation.

It is however also important to remember that denosumab is used in the most severe cases of ABCs and that 82% of stable and controlled disease is still an acceptable result in those difficult cases.

Studies about the use of denosumab in osteoporosis and GCT reported an increased risk of osteonecrosis of the jaw (ONJ) (1,1 – 2,0%), arthralgia, anaemia, or gastrointestinal disorders [14,45–47]. In our literature review, 6 patients reported low grade and transient adverse events: fatigue, muscle pain and gastrointestinal disorders. Those mild adverse events appear to affect mostly adults. No ONJ was reported.

About the calcium levels perturbation, our review highlights that all the cases are reported in the paediatric population.

Four patients with a mean age of $9,8 \pm 2,4$ years presented asymptomatic hypocalcaemia ranging from 1,9 to 2,03 mmol/l during the early stage of denosumab therapy, none of the patients required a denosumab dosage adaptation nor discontinuation. A routine dosage of calcium, phosphate, creatinine and vitamin D levels at the initial stage of treatment seems necessary to assess this complication and adapt the supplementation dosage.

When regarding serious adverse events reported in our review, 6 cases of symptomatic hypercalcemia were diagnosed 5 to 6 months after denosumab was stopped in patients aged of $9 \pm 3,2$ years. Among these 6 cases, 5 patients were admitted in ICU. Hypercalcemia after denosumab discontinuation is a potential life-threatening side effect which should be systematically investigated and managed with attention, firstly because of the increased use of denosumab in children [45,48], and secondly because this post treatment hypercalcemia has already been described in children after stopping denosumab in GCT or fibrous dysplasia [45,49]. It is supposed to be caused by a rebound of the bone remodelling, particularly osteoclasts activity hence a huge increase in bone resorption and calcium release [50]. Levels of bone resorption markers C-Telopeptide rebound to 60% above the pre denosumab level in post-menopausal women [44] while it was increased to 250% from pre denosumab levels in a child suffering of fibrous dysplasia [49]. This difference in the level of bone resorption after denosumab cessation explains why hypercalcemia mostly affects children. Harcus and al [21] proposed a close monitoring of calcium levels every 2 months after denosumab discontinuation that could be most widely used by clinicians. This is probably not enough and bone-remodelling markers, such as serum crosslaps, could be used to monitor the cessation of denosumab. Maybe the use of bisphosphonates to reduce the risk of remodelling rebound, as it is advised in osteoporosis could be useful. Another concern could be the consequences of this huge increase of bone resorption, as post denosumab withdrawal vertebral fractures have been reported in post-menopausal women [51,52].

There are concerns about denosumab inducing skeletal perturbation in skeletally immature patients such as linear and teeth growth disturbance, growth plate ossification [36]. In our review, we only found one case of growth plate ossification without reported clinical consequences, Wang and al published a histopathologic study highlighting that denosumab did not adversely affect growth plates [38]. No case of dental growth disturbance was reported. However, one must note that the mean duration of follow up was <2 years and indeed long-term consequences of denosumab use in those patients are still widely unknown.

5 Conclusion

Our literature review supports the use of denosumab for lesions that are unresectable or with multiple recurrences and no alternative. In the short term, denosumab appeared to be highly effective in pain relief and neurological improvement, fulfilling the goal of the therapy: allow a return to a pain free life for those young and active patients. There was a significant radiological response in most of the reported cases and the new ossification allowed a less morbid surgery in some patients. However, the success must be appreciated with caution because even if it appeared to be well tolerated, on the one hand five patients (11%) developed a symptomatic hypercalcemia with admission in ICU and on the other hand, the recurrence rate after or under denosumab is 18% but with a mean reported follow-up duration after cessation < 2 years, which could underestimate the real recurrence rate. Most of the recurrences occurred in a population of adults treated with low dosage denosumab, bearing in mind that dosage adaptation is not recommended by the FDA and EMA.

Still, this 18 % of local recurrence rate is similar to the other reported method of treatment in non-operable disease. If denosumab in ABC seems very promising, many questions remain unresolved, particularly risk factors of recurrence and potentially life-threatening side effects

such as hypercalcemia. There is a need for a careful collaborative evaluation in clinical trials before routinely using it in hospital facilities. The results of an ongoing Phase 2 clinical trial could answer many pending questions [53].

This research did not receive any specific grant from funding agencies in the public, commercial, or not-for-profit sectors.

The authors declare that they have no competing interest.

References

- [1] Fletcher CDM, World Health Organization. WHO Classification of Tumours of Soft Tissue and Bone. IARC Press; 2013. (IARC WHO Classification of Tumours Series)
- [2] Leithner A, Windhager R, Lang S, Haas OA, Kainberger F, Kotz R. Aneurysmal bone cyst. A population based epidemiologic study and literature review. Clin Orthop. 1999;176-9.
- [3] Mankin HJ, Hornicek FJ, Ortiz-Cruz E, Villafuerte J, Gebhardt MC. Aneurysmal Bone Cyst: A Review of 150 Patients. J Clin Oncol. 2005;23:6756-62
- [4] Ye Y, Pringle LM, Lau AW, Riquelme DN, Wang H, Jiang T, et al. TRE17/USP6 oncogene translocated in aneurysmal bone cyst induces matrix metalloproteinase production via activation of NF- κ B. Oncogene. 2010;29:3619-29
- [5] Martinez V, Sissons H. Aneurysmal bone cyst. A review of 123 cases including primary lesions and those secondary to other bone pathology. 1988;61:14
- [6] Mendenhall WM, Zlotecki RA, Gibbs CP, Reith JD, Scarborough MT, Mendenhall NP. Aneurysmal Bone Cyst: Am J Clin Oncol. 2006;29:311-5
- [7] Vergel De Dios AM, Bond JR, Shives TC, McLeod RA, Unni KK. Aneurysmal bone cyst. A clinicopathologic study of 238 cases. Cancer. 1992;69(12):2921-31
- [8] Flont P, Kolacinska-Flont M, Niedzielski K. A comparison of cyst wall curettage and en bloc excision in the treatment of aneurysmal bone cysts. World J Surg Oncol. 2013;11:109
- [9] Dormans JP, Hanna BG, Johnston DR, Khurana JS. Surgical Treatment and Recurrence Rate of Aneurysmal Bone Cysts in Children: Clin Orthop. 2004;421:205-11
- [10] Falappa P, Fassari FM, Fanelli A, Genovese E, Ascani E, Crostelli M, et al. Aneurysmal Bone Cysts: Treatment with Direct Percutaneous Ethibloc Injection. Long-Term Results. Cardiovasc Intervent Radiol. 2002;25(4):282-90
- [11] Topouchian V, Mazda K, Hamze B, Laredo J-D, Penneçot G-F. Aneurysmal Bone

Cysts in Children: Complications of Fibrosing Agent Injection. *Radiology*. 2004;232:522-6

[12] Lange T, Stehling C, Fröhlich B, Klingenhöfer M, Kunkel P, Schneppenheim R, et al.

Denosumab: a potential new and innovative treatment option for aneurysmal bone cysts. *Eur Spine J*. 2013;22:1417-22

[13] Yamagishi T, Kawashima H, Ogose A, Ariizumi T, Sasaki T, Hatano H, et al.

Receptor-Activator of Nuclear KappaB Ligand Expression as a New Therapeutic Target in Primary Bone Tumors. Reddy SV, éditeur. *PLOS ONE*. 2016;11:e0154680

[14] Chawla S, Blay J-Y, Rutkowski P, Le Cesne A, Reichardt P, Gelderblom H, et al.

Denosumab in patients with giant-cell tumour of bone: a multicentre, open-label, phase 2 study. *Lancet Oncol*. 2019;20:1719-29

[15] Liberati A, Altman DG, Tetzlaff J, Mulrow C, Gøtzsche PC, Ioannidis JPA, et al. The

PRISMA statement for reporting systematic reviews and meta-analyses of studies that evaluate health care interventions: explanation and elaboration. *J Clin Epidemiol*.

2009;62:e1-34

[16] Fontenot PB, Jesurajan J, Bui M, Reed D, Binitie O. Recurrent Aneurysmal Bone Cyst

of the Distal Fibula Treated with Denosumab and Curettage. *Case Rep Oncol Med*.

2018;2018:1-6

[17] Asi KW, Abdelmeguid A, Bell D, Hanna EY. Massive aneurysmal bone cyst of the

skull base treated with denosumab. *Head Neck*. 2018;40:E107-13

[18] Dubory A, Missenard G, Domont J, Court C. Interest of Denosumab for the Treatment

of Giant-cells Tumors and Aneurysmal Bone Cysts of the Spine. About Nine Cases. *Spine*. 1

2016;41:E654-60

[19] Dürr HR, Grahneis F, Baur-Melnyk A, Knösel T, Birkenmaier C, Jansson V, et al.

Aneurysmal bone cyst: results of an off label treatment with Denosumab. *BMC*

Musculoskelet Disord. déc 2019;20:456

[20] Grahneis F, Klein A, Baur-Melnyk A, Knösel T, Birkenmaier C, Jansson V, et al.

Aneurysmal bone cyst: A review of 65 patients. J Bone Oncol. 2019;18:100255

[21] Harcus M, Aldridge S, Abudu A, Jeys L, Senniappan S, Morgan H, et al. The Efficacy of Denosumab in the Management of a Tibial Paediatric Aneurysmal Bone Cyst

Compromised by Rebound Hypercalcaemia. Karagüzel G, éditeur. Case Rep Pediatr.

2020;2020:1-6

[22] Kulkarni AG, Patel A. Denosumab: A potential new treatment option for recurrent

Aneurysmal Bone Cyst of the spine. SICOT-J. 2019;5:10

[23] Kurucu N, Akyuz C, Ergen FB, Yalcin B, Kosemehmetoglu K, Ayvaz M, et al.

Denosumab treatment in aneurysmal bone cyst: Evaluation of nine cases. Pediatr Blood

Cancer. 2018;65:e26926

[24] Ntalos D, Priemel M, Schlickewei C, Thiesen DM, Rueger JM, Spiro AS. Therapeutic

Management of a Substantial Pelvic Aneurysmatic Bone Cyst Including the Off-Label Use of

Denosumab in a 35-Year-Old Female Patient. Case Rep Orthop. 2017;2017:1-5

[25] Palmerini E, Ruggieri P, Angelini A, Boriani S, Campanacci D, Milano GM, et al.

Denosumab in patients with aneurysmal bone cysts: A case series with preliminary results.

Tumori J. 2018;104(5):344-51

[26] Patel RS, Dhamne CA, Gopinathan A, Kumar N, Kumar N. Denosumab: a potential

treatment option for aneurysmal bone cyst of the atlas. Eur Spine J. 2018;27:494-500

[27] Pauli C, Fuchs B, Pfirrmann C, Bridge JA, Hofer S, Bode B. Response of an

aggressive periosteal aneurysmal bone cyst (ABC) of the radius to denosumab therapy. World

J Surg Oncol. 2014;12:17

[28] Pelle DW, Ringler JW, Peacock JD, Kampfschulte K, Scholten DJ, Davis MM, et al.

Targeting receptor-activator of nuclear kappaB ligand in aneurysmal bone cysts: verification

of target and therapeutic response. *Transl Res.* 2014;164:139-48

[29] Raux S, Bouhamama A, Gaspar N, Brugières L, Entz-Werlé N, Mallet C, et al.

Denosumab for treating aneurysmal bone cysts in children. *Orthop Traumatol Surg Res.*

2019;105(6):1181-5

[30] Skubitz KM, Peltola JC, Santos ER, Cheng EY. Response of Aneurysmal Bone Cyst

to Denosumab: *Spine.* 2015;40:E1201-4

[31] Chaitanya Sahini S, Subramanyam K, Kumar S. Denosumab role in sacral aneurysmal

bone cyst: A rare case report. *IP Int J Med Paediatr Oncol.* 2019;5:108-11

[32] Upfill-Brown A, Bukata S, Bernthal NM, Felsenfeld AL, Nelson SD, Singh A, et al.

Use of Denosumab in Children With Osteoclast Bone Dysplasias: Report of Three Cases.

JBMR Plus. 2019 doi/10.1002/jbm4.10210

[33] Luengo-Alonso G, Mellado-Romero M, Shemesh S, Ramos-Pascua L, Pretell-Mazzini

J. Denosumab treatment for giant-cell tumor of bone: a systematic review of the literature.

Arch Orthop Trauma Surg. 2019;139:1339-49

[34] Montgomery C, Couch C, Emory C, Nicholas R. Giant Cell Tumor of Bone: Review

of Current Literature, Evaluation, and Treatment Options. *J Knee Surg.* 2019;32:331-6

[35] Thomas D, Henshaw R, Skubitz K, Chawla S, Staddon A, Blay J-Y, et al. Denosumab

in patients with giant-cell tumour of bone: an open-label, phase 2 study. *Lancet Oncol.*

2010;11:275-80

[36] Kong Y-Y, Yoshida H, Sarosi I, Tan H-L, Timms E, Capparelli C, et al. OPGL is a

key regulator of osteoclastogenesis, lymphocyte development and lymph-node organogenesis.

Nature. 1999;397:315-23

[37] Boyce AM. Denosumab: an Emerging Therapy in Pediatric Bone Disorders. *Curr*

Osteoporos Rep. 2017;15:283-92

- [38] Wang HD, Boyce AM, Tsai JY, Gafni RI, Farley FA, Kasa-Vubu JZ, et al. Effects of Denosumab Treatment and Discontinuation on Human Growth Plates. *J Clin Endocrinol Metab.* 2014;99:891-7
- [39] Chapurlat RD, Gensburger D, Jimenez-Andrade JM, Ghilardi JR, Kelly M, Mantyh P. Pathophysiology and medical treatment of pain in fibrous dysplasia of bone. *Orphanet J Rare Dis.* 2012;7:S3
- [40] Errani C, Tsukamoto S, Leone G, Righi A, Akahane M, Tanaka Y, et al. Denosumab May Increase the Risk of Local Recurrence in Patients with Giant-Cell Tumor of Bone Treated with Curettage: *J Bone Jt Surg.* 2018;100:496-504
- [41] Brodowicz T, Hemetsberger M, Windhager R. Denosumab for the treatment of giant cell tumor of the bone. *Future Oncol.* 2015;11:1881-94
- [42] Engellau J, Seeger L, Grimer R, Henshaw R, Gelderblom H, Choy E, et al. Assessment of denosumab treatment effects and imaging response in patients with giant cell tumor of bone. *World J Surg Oncol.* 2018;16:191
- [43] Li H, Gao J, Gao Y, Lin N, Zheng M, Ye Z. Denosumab in Giant Cell Tumor of Bone: Current Status and Pitfalls. *Front Oncol.* 2020;10:580605
- [44] Bone HG, Bolognese MA, Yuen CK, Kendler DL, Miller PD, Yang Y-C, et al. Effects of Denosumab Treatment and Discontinuation on Bone Mineral Density and Bone Turnover Markers in Postmenopausal Women with Low Bone Mass. *J Clin Endocrinol Metab.* 2011;96:972-80
- [45] Uday S, Gaston CL, Rogers L, Parry M, Joffe J, Pearson J, et al. Osteonecrosis of the Jaw and Rebound Hypercalcemia in Young People Treated With Denosumab for Giant Cell Tumor of Bone. *J Clin Endocrinol Metab.* 2018;103:596-603
- [46] Miller PD. A review of the efficacy and safety of denosumab in postmenopausal

women with osteoporosis. *Ther Adv Musculoskelet Dis*. 2011;3:271-82

[47] Hernandez M, Phulpin B, Mansuy L, Droz D. Use of new targeted cancer therapies in children: effects on dental development and risk of jaw osteonecrosis: a review. *J Oral Pathol Med*. 2017;46:321-6

[48] Koldkjær Sølling AS, Harsløf T, Kaal A, Rejnmark L, Langdahl B. Hypercalcemia after discontinuation of long-term denosumab treatment. *Osteoporos Int*. 2016;27:2383-6

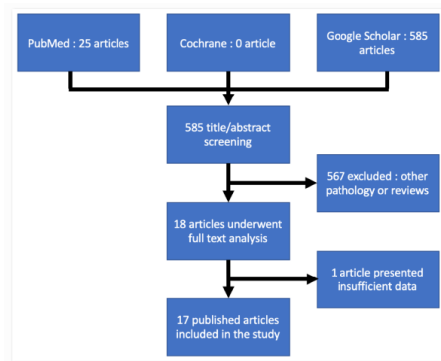
[49] Boyce AM, Chong WH, Yao J, Gafni RI, Kelly MH, Chamberlain CE, et al. Denosumab treatment for fibrous dysplasia. *J Bone Miner Res*. 2012;27:1462-70

[50] Grasemann C, Schündeln MM, Hövel M, Schweiger B, Bergmann C, Herrmann R, et al. Effects of RANK-Ligand Antibody (Denosumab) Treatment on Bone Turnover Markers in a Girl With Juvenile Paget's Disease. *J Clin Endocrinol Metab*. 2013;98:3121-6

[51] Polyzos SA, Terpos E. Clinical vertebral fractures following denosumab discontinuation. *Endocrine*. oct 2016;54:271-2

[52] Popp AW, Zysset PK, Lippuner K. Rebound-associated vertebral fractures after discontinuation of denosumab from clinic and biomechanics. *Osteoporos Int*. 2016;27:1917-21

[53] Denosumab in Subjects With Giant Cell Rich Tumors of Bone - Full Text View - ClinicalTrials.gov. <https://clinicaltrials.gov/ct2/show/NCT03605199>

Figure 1: Flow Chart

Patient Number	Author	Age	Gender	Location	Clinical presentation	Denosumab regimen	Reported clinical outcomes	Reported Radiological outcomes	Histological examination after denosumab
1	Fontenot	13	F	Distal fibula	Pain	Denosumab sc 120 mg day 1-8-15-29 one month then monthly	Pain relief	Ossification at 12 months	+
2	Kulkorni	14	F	Thoracic spine	Pain and neurological symptoms	Denosumab sc 120 mg day 1-8-15-29 one month then monthly	Pain relief after 1 month, no neurological symptoms after 2 months	Ossification at 12 months	-
3	Durr	15	F	Radius	Pain	Denosumab sc 120 mg day 1-8-15-29 one month then monthly	-	-	-
4	Kurucu	5	F	Cervical spine	Pain	Denosumab sc 70 mg/m ² weekly 1 month then monthly	Pain improvement after 1 month, pain relief at 3 months	50,7% volume decrease	-

5	Kurucu	10	F	Lombar spine	Pain	Denosumab sc 70 mg/m2 weekly 1 month then monthly	Pain improvement after 1 month, pain relief at 3 months	37 % volume increase	-
6	Palmerini	14	F	Sacrum	-	Denosumab sc 120 mg day 1-8-15-29 one month then monthly	-	Ossification	-
7	Raux	14	F	Sacrum	Pain	Denosumab sc 70 mg/m2 weekly 1 month then monthly	Pain relief	Ossification	-
8	Raux	7	F	Femur	Pain	Denosumab sc 70 mg/m2 weekly 1 month then monthly	Pain relief after 2 months	Ossification	-
9	Subramanyam	13	F	Sacrum	Pain	Denosumab sc 60 mg monthly	Pain relief after 2 months	Ossification at 6 months	+
10	Upfill-Brown	10	F	Pelvis	Pain	Denosumab sc 120 mg day 1-8-15-29 one month then monthly	Pain relief	Ossification	-

11	Pelle	5	M	Sacrum	Pain and neurological symptoms	Denosumab sc 1,2 mg/kg/dose weekly 1 month then 1,6 mg/kg/dose monthly	Pain improvement at 2 weeks, no neurological symptoms at 6 months	30 % volume decrease at 7 months	-
12	Durr	6	M	Sacrum	Pain	Denosumab sc 120 mg day 1-8-15-29 one month then monthly	Pain relief after 2 months	Ossification at 2 months	-
13	Kurucu	12	M	Pelvis	Pain	Denosumab sc 70 mg/m2 weekly 1 month then monthly	Pain improvement after 1 month, pain relief at 3 months	45 % volume decrease.	-
14	Kurucu	6	M	Pelvis	Pain	Denosumab sc 70 mg/m2 weekly 1 month then monthly	Pain improvement after 1 month, pain relief at 3 months	Stable volume	-
15	Kurucu	8	M	Humerus	Pain	Denosumab sc 70 mg/m2 weekly 1 month then monthly	Pain improvement after 1 month, pain relief at 3 months	Stable volume	-

16	Lange	8	M	Cervical spine	Pain and neurological symptoms	Denosumab sc 70 mg/m2 monthly	Pain and neurological symptoms relief	Ossification at 2 months	-
17	Lange	8	M	Cervical spine	Pain and neurological symptoms	Denosumab sc 70 mg/m2 monthly	Pain relief	Ossification at 4 months	-
18	Palmerini	12	M	Ulna	Pain	Denosumab sc 120 mg day 1-8-15-29 one month then monthly	Pain relief	Ossification	-
19	Raux	8	M	Lombar spine	Pain and neurological symptoms	Denosumab sc 70 mg/m2 weekly 1 month then monthly	Pain and neurological symptoms improvement	Ossification	-
20	Raux	8	M	Cervical spine	Pain and neurological symptoms	Denosumab sc 70 mg/m2 weekly 1 month then monthly	Pain and neurological symptoms improvement at 2 months	Ossification	-

21	Harcus	13	M	Tibia	Pain	Denosumab sc 70 mg/m ² weekly 1 month then monthly for 6 months. After 6 months : 1 dose every 2 months. At 12 months : 1 dose every 3 months. At 27 months : 2 doses at 6 months interval then discontinuation.	Pain relief at 6 months	Volume reduction and ossification at 6 months	-
----	--------	----	---	-------	------	---	-------------------------	---	---

Table 1: Clinical presentation and clinical outcomes by age <15 years

Patient Number	Author	Age	Gender	Location	Clinical presentation	Denosumab regimen	Reported clinical outcomes	Reported Radiological outcomes	Histological examination after denosumab
22	Dubory	26	F	Cervical spine	Pain and neurological symptoms	Denosumab sc 120 mg monthly	Pain relief and neurological improvement at 4 months	Volume reduction and ossification at 3 months	-
23	Pauli	21	F	Radius	Pain	Denosumab sc 120 mg monthly	Pain relief	Ossification at 1 month	+
24	Durr	30	F	Pelvis	Pain	Denosumab sc 120 mg day 1-8-15-29 one month then monthly	-	-	-
25	Durr	16	F	Talus	Pain	Denosumab sc 120 mg day 1-8-15-29 one month then monthly	-	-	-

26	Durr	16	F	Femur	Pain	Denosumab sc 120 mg day 1-8-15- 29 one month then monthly	-	-	-
27	Kurucu	17	F	Pelvis	Pain	Denosumab sc 70 mg/m2 weekly 1 month then monthly	Pain improvement after 1 month, pain relief at 3 months	18% volume reduction	-
28	Kurucu	16	F	7th costo vertebral junction	Pain	Denosumab sc 70 mg/m2 weekly 1 month then monthly	Pain improvement after 1 month, pain relief at 3 months	81,7% volume reduction	-
29	Ntalos	35	F	Pelvis	Pain and neurological symptoms	Denosumab sc 60 mg monthly	Pain relief	Volume reduction and ossification	-

30	Palmerini	17	F	Tibia	Pain	Denosumab sc 120 mg day 1-8-15- 29 one month then monthly	Pain relief	Ossification	+
31	Palmerini	16	F	Pelvis	Pain	Denosumab sc 120 mg day 1-8-15- 29 one month then monthly	Pain relief	Ossification	-
32	Asi	32	M	Skull base	Pain and epistaxis	Denosumab sc 120 mg day 1-8-15- 29 one month then monthly	Pain relief	Volume reduction at 3 months, ossification at 18 months	-
33	Patel	16	M	Cervical spine	Pain and neurological symptoms	Denosumab sc 120 mg monthly	Pain relief, no neurological symptoms at 7 months	Ossification at 12 months	-

34	Skubitz	27	M	Sacrum	Pain	Denosumab sc 120 mg day 1-8-15- 29 one month then monthly	Pain relief at 2 months	Ossification at 4 months	+
35	Durr	18	M	Sacrum	Pain	Denosumab sc 120 mg day 1-8-15- 29 one month then monthly	-	Ossification	-
36	Kurucu	16	M	Mandible	Pain	Denosumab sc 70 mg/m ² weekly 1 month then monthly	Pain improvement after 1 month, pain relief at 3 months	47,3% volume reduction	-
37	Kurucu	16	M	Sacrum	Pain	Denosumab sc 70 mg/m ² weekly 1 month then monthly	Pain improvement after 1 month, pain relief at 3 months	35% volume reduction	-

38	Palmerini	19	M	Humerus	Pain	Denosumab sc 120 mg day 1-8-15- 29 one month then monthly	Pain relief	Ossification	+
39	Palmerini	42	M	Spine	Pain and neurological symptoms	Denosumab sc 120 mg day 1-8-15- 29 one month then monthly	Pain relief	Ossification	-
40	Palmerini	25	M	Spine	Pain and neurological symptoms	Denosumab sc 120 mg day 1-8-15- 29 one month then monthly	Pain relief	Ossification	-
41	Palmerini	19	M	Spine	Pain and neurological symptoms	Denosumab sc 120 mg day 1-8-15- 29 one month then monthly	Pain relief	Ossification	-

42	Palmerini	16	M	Lombar spine	Pain	Denosumab sc 120 mg day 1-8-15-29 one month then monthly	Pain relief	Ossification -
43	Raux	17	M	Lombar spine	Pain and neurological symptoms	Denosumab sc 70 mg/m ² weekly 1 month then monthly	Pain relief, no neurological symptoms at 15 months	Ossification -

Table 2: Clinical presentation and clinical outcomes by age >15 years

Patient Number	Author	Age	Gender	Location	Duration of denosumab therapy (months)	Recurrence	Receiving denosumab at publication	Follow-up period (months)	Adverse event
1	Fontenot	13	F	Distal fibula	12	No	No	36	-
2	Kulkorni	14	F	Thoracic spine	6	No	No	24	-
3	Durr	15	F	Radius	6	No	No	36	-
4	Kurucu	5	F	Cervical spine	12	No	No	12	Severe hypercalcemia at discontinuation
5	Kurucu	10	F	Lombar spine	6		Non responsive to denosumab		
6	Palmerini	14	F	Sacrum	Not reported	No	Yes	Not reported	Grade 1 vomiting
7	Raux	14	F	Sacrum	4	No	No	24	-
8	Raux	7	F	Femur	4	No	No	28	-
9	Subramanyam	13	F	Sacrum	12	No	No	12	-
10	Upfill-Brown	10	F	Pelvis	12	No	No	13	Mild hypocalcemia during denosumab, severe hypercalcemia at discontinuation
11	Pelle	5	M	Sacrum	12	No	No	12	-
12	Durr	6	M	Sacrum	12	No	No	12	Severe hypercalcemia at discontinuation
13	Kurucu	12	M	Pelvis	14	No	No	10	Severe hypercalcemia at discontinuation
14	Kurucu	6	M	Pelvis	9	No	No	20	-
15	Kurucu	8	M	Humerus	12	No	No	12	-

16	Lange	8	M	Cervical spine	2	No	Yes	2	Mild hypocalcemia during denosumab therapy
17	Lange	8	M	Cervical spine	4	No	Yes	4	-
18	Palmerini	12	M	Ulna	8	No	No	12	-
19	Raux	8	M	Lombar spine	17	No	No	6	Mild hypocalcemia during denosumab therapy
20	Raux	8	M	Cervical spine	12	Yes 10 months after first discontinuation	Yes at long course	12	Mild hypercalcemia 5 months after first discontinuation
21	Harcus	13	M	Tibia	34	No	No	16	Mild hypocalcemia during denosumab therapy, growth plate ossification, Severe hypercalcemia at discontinuation

Table 3: Recurrence and adverse events by age <15 years

Patient Number	Reference Numer	Age	Gender	Location	Duration of denosumab therapy (months)	Recurrence	Receiving denosumab at publication	Follow-up period	Adverse event
22	Dubory	26	F	Cervical spine	16	No	No	19,5	-
23	Pauli	21	F	Radius	5	Yes 19 months after discontinuation	Yes at long course	Not reported	-
24	Durr	30	F	Pelvis	Multiple denosumab therapies	Yes 1 during denosumab, 2 after discontinuation	Yes at long course	Not reported	-
25	Durr	16	F	Talus	12	No	No	24	-
26	Durr	16	F	Femur	24	No	No	24	-
27	Kurucu	17	F	Pelvis	14	Yes 3 months after discontinuation	No	15	Fatigue, muscle pain
28	Kurucu	16	F	7th costo vertebral junction	12	Yes 16 months after discontinuation	Yes at long course	21	-
29	Ntalos	35	F	Pelvis	12	Yes at 6 months after discontinuation	No, underwent another 17 months of denosumab	15	-

30	Palmerini	17	F	Tibia	9	No	No	17	-
31	Palmerini	16	F	Pelvis	Not reported	No	Yes	Not reported	-
32	Asi	32	M	Skull base	18	No	Yes	18	-
33	Patel	16	M	Cervical spine	12	No	No	12	-
34	Skubitz	27	M	Sacrum	12	No	No	12	-
35	Durr	18	M	Sacrum	24	Yes 12 months after discontinuation	Yes	18	-
36	Kurucu	16	M	Mandible	11	No	No	20	Fatigue, mild gastro intestinal disorder
37	Kurucu	16	M	Sacrum	14	No	No	12	-
38	Palmerini	19	M	Humerus	5	No	No	11	-
39	Palmerini	42	M	Spine	Not reported	No	Yes	Not reported	-
40	Palmerini	25	M	Spine	Not reported	No	Yes	Not reported	Grade 1 vomiting
41	Palmerini	19	M	Spine	Not reported	No	Yes	Not reported	-
42	Palmerini	16	M	Lombar spine	36	No	No	24	-

43	Raux	17	M	Lombar spine	23	Yes at 23 months of denosumab therapy	Yes	Not reported	-
----	------	----	---	--------------	----	---------------------------------------	-----	--------------	---

Table 4: Recurrence and adverse events by age >15 years

Patient Number	1	2	3	4	5	6	7	
Study	Pauli [27]	Durr [19]	Kurucu [23]	Kurucu [23]	Ntalos [24]	Raux [29]	Durr [19]	Ra
Age (year)	21	18	16	17	35	8	30	
Sex	F	M	F	F	F	M	F	
Localisation	Distal radius	Sacrum	7th costo vertebral junction	Pelvis	Pelvis	Cervical spine	Pelvis	Lomb
Precedent management	Surgery. Recurrence 2 months after surgery.	Polidicanol injection and embolization: no response at 3 months.	None	None	Arterial embolization AND denosumab	None	Surgery. Recurrence 12 months after surgery. Second surgery. Recurrence 42 months after second surgery	Sclerot surgery. at 6
Denosumab Regimen	Sc 120 mg monthly	Sc 120 mg weekly 1 month then monthly 12 months. Dose decreased 12 more months	Sc 70 mg/m2 weekly 1 month then monthly	Sc 70 mg/m2 weekly 1 month then monthly	Sc 60 mg monthly	Sc 70 mg/m2 weekly 1 month then monthly	Sc 120 mg weekly 1 month then monthly	Sc 70 mg 1 mo mo
Radiological response (if available)	Size reduction, bony rim and ossification	-	Volume reduction of 81,7%	Volume reduction reduction of 18%	Volume reduction, ossification	Ossification	-	Ossi
Duration of Denosumab	5 months	24 months	12 months	14 months	12 months	12 months	8 months	23 m

Discontinuation ?	Yes and surgery at the end of the 5 months	Yes	Yes	Yes	Yes and surgery at the end of the 12 months	Yes	No	
Date of recurrence	19 months after the second surgery	12 months after discontinuation	16 months after discontinuation	3 months after discontinuation	6 months after discontinuation	10 months after discontinuation	At 8 months	At 23
Management of recurrence	Denosumab 120 mg monthly at long course	Denosumab 120 mg monthly at long course	Denosumab 70 mg/m2 monthly at long course	Sclerotherapy 9 months after recurrence	Denosumab 60 mg monthly 17 months and discontinuation	Denosumab 70 mg/m2 monthly at long course	Surgery. 18 months later : new recurrence treated by denosumab sc 120 mg monthly 18 months. Then discontinued. 36 months later : new recurrence. Actually treated by Denosumab sc 120 mg monthly at long course	Denosumab 70 mg/m2 monthly at long course

Table 5: Demographic, clinical characteristics and medical history of the 8 recurrences reported in the studies.

Patient Number	1	2	3	4	5	6	7	
Study	Pauli [27]	Durr [19]	Kurucu [23]	Kurucu [23]	Ntalos [24]	Raux [29]	Durr [19]	Ra
Age (year)	21	18	16	17	35	8	30	
Sex	F	M	F	F	F	M	F	
Localisation	Distal radius	Sacrum	7th costo vertebral junction	Pelvis	Pelvis	Cervical spine	Pelvis	Lomb
Precedent management	Surgery. Recurrence 2 months after surgery.	Polidicanol injection and embolization: no response at 3 months.	None	None	Arterial embolization AND denosumab	None	Surgery. Recurrence 12 months after surgery. Second surgery. Recurrence 42 months after second surgery	Scleroti surgery. at 6
Denosumab Regimen	Sc 120 mg monthly	Sc 120 mg weekly 1 month then monthly 12 months. Dose decreased 12 more months	Sc 70 mg/m2 weekly 1 month then monthly	Sc 70 mg/m2 weekly 1 month then monthly	Sc 60 mg monthly	Sc 70 mg/m2 weekly 1 month then monthly	Sc 120 mg weekly 1 month then monthly	Sc 70 mg 1 mo
Radiological response (if available)	Size reduction, bony rim and ossification	-	Volume reduction of 81,7%	Volume reduction of 18%	Volume reduction, ossification	Ossification	-	Ossi
Duration of	5 months	24 months	12 months	14 months	12 months	12 months	8 months	23 m

Denosumab								
Discontinuation ?	Yes and surgery at the end of the 5 months	Yes	Yes	Yes	Yes and surgery at the end of the 12 months	Yes	No	
Date of recurrence	19 months after the second surgery	12 months after discontinuation	16 months after discontinuation	3 months after discontinuation	6 months after discontinuation	10 months after discontinuation	At 8 months	At 23
Management of recurrence	Denosumab 120 mg monthly at long course	Denosumab 120 mg monthly at long course	Denosumab 70 mg/m ² monthly at long course	Sclerotherapy 9 months after recurrence	Denosumab 60 mg monthly 17 months and discontinuation	Denosumab 70 mg/m ² monthly at long course	Surgery. 18 months later : new recurrence treated by denosumab sc 120 mg monthly 18 months. Then discontinued. 36 months later : new recurrence. Actually treated by Denosumab sc 120 mg monthly at long course	Denos. mg/m ² long

Table 5: Demographic, clinical characteristics and medical history of the 8 recurrences reported in the studies.

Journal Pre-proof