



HAL
open science

Qafzeh 9 Early Modern Human from Southwest Asia: age at death and sex estimation re-assessed

Dany Coutinho-Nogueira, H el ene Coqueugniot, Anne-Marie Tillier, Dany
Coutinho Nogueira

► **To cite this version:**

Dany Coutinho-Nogueira, H el ene Coqueugniot, Anne-Marie Tillier, Dany Coutinho Nogueira. Qafzeh 9 Early Modern Human from Southwest Asia: age at death and sex estimation re-assessed. *HOMO, Journal of Comparative Human Biology*, 2021, 72 (4), pp.293-305. 10.1127/homo/2021/1513 . hal-03368602

HAL Id: hal-03368602

<https://hal.science/hal-03368602>

Submitted on 6 Oct 2021

HAL is a multi-disciplinary open access archive for the deposit and dissemination of scientific research documents, whether they are published or not. The documents may come from teaching and research institutions in France or abroad, or from public or private research centers.

L'archive ouverte pluridisciplinaire **HAL**, est destin ee au d ep ot et  a la diffusion de documents scientifiques de niveau recherche, publi es ou non,  emanant des  tablissements d'enseignement et de recherche fran ais ou  trangers, des laboratoires publics ou priv es.



Distributed under a Creative Commons Attribution 4.0 International License

1 **Qafzeh 9 Early Modern Human from Southwest Asia: age at death and sex estimation**
2 **re-assessed**

3 Dany Coutinho-Nogueira ^{1,2,3}, H el ene Coqueugniot ^{1,2}, Anne-marie Tillier¹

4

5 1 – University of Bordeaux . CNRS, MCC, PACEA, UMR 5199, F-33600 Pessac, France

6 2 - EPHE- PSL University, PACEA, F-75014 Paris, France

7 3 – University of Coimbra, CIAS - Research Centre for Anthropology and Health,

8 Department of Life Science, PT-3000-456 Coimbra, Portugal

9

10 Corresponding author: Dany Coutinho Nogueira

11 e-mail adress: dany.nogueira@uc.pt

12 Address: CIAS - Research Centre for Anthropology and Health, Departamento de Ci ncias da

13 Vida, Universidade de Coimbra, Cal ada Martim de Freitas, 3000-456 Coimbra, Portugal

14

15 with 5 figures and 6 tables

16

17 **Keywords**

18 Early modern human; Southwestern Asia; sex estimation; age at death estimation; biological

19 profile

20

21 **Abstract**

22 Qafzeh 9 is an almost complete skeleton commonly employed as representative of the
23 population of the eponymous site. However, its biological profile is still largely based on the
24 age at death and sex estimation methods in use at the time of its discovery. Moreover, post-
25 mortem damage to the skeleton has made difficult the observation of some morphoscopic
26 features, particularly pelvic ones currently used in sex estimation.

27 Here, we apply recent methods and paleoimaging to re-evaluate the biological profile of
28 Qafzeh 9, taking into account post-mortem damage. The results suggest a young age at death,
29 indicating that Qafzeh 9 died before reaching complete dental and bone maturity; they also
30 support a male sex assignment.

31

32 1. Introduction

33 The period between 220-45 ka B.P. is crucial for understanding the evolution and dispersal of
34 early anatomically modern humans from Africa, especially in Southwestern Asia (Bar Yosef
35 2000). In this context, Qafzeh Cave in Lower Galilee (Israel) is of particular interest
36 (Vandermeersch and Bar Yosef 2017) with regard to its anthropological documentation.
37 Dated to 92 ± 5 ka B.P. (Schwarcz et al. 1988; Valladas et al. 1988), the site yielded a unique
38 sample of individuals (Vandermeersch 1981; Tillier 1999; Tillier 2014) that represent all age
39 classes from perinatal to adulthood. In addition, the site provides evidence for unique Middle
40 Palaeolithic funerary practices, the presence of engraved artefacts and the use of ochre and
41 marine shells (Vandermeersch 1969a, b; Tillier 1995; Hovers et al. 1997, Hovers et al. 2003;
42 Bar Yosef Mayer et al. 2009).

43 Qafzeh 9 was discovered together with a child ca. 6 yrs old at death (Qafzeh 10) in a double
44 burial found during the third excavation season (Vandermeersch 1969). As it is one of the
45 most complete skeletons, Qafzeh 9 is often used as the “type” of the Qafzeh group. However,
46 partly due to post-mortem distortions, the biological profile of Qafzeh 9 has sometimes been
47 questioned, primarily its sex. Various analyses favoured identification as a female
48 (Vandermeersch 1981; Brůžek and Vandermeersch 1997) or probably female (Trinkaus
49 1984). Vandermeersch (1981) used several pelvic morphological features such as the
50 Schultz's ischio-pubic index (Schultz 1930), the opening of the sciatic notch, the cotylo-sciatic
51 width as well as the subpubic angle. Finally, Vandermeersch (1981) noted the general level of
52 gracility of the cranial and infracranial skeleton. The pelvic morphologic observations were
53 later confirmed in a metric and statistical study (Brůžek and Vandermeersch 1997).

54 A number of researchers supported a male diagnosis, based on other pelvic morphoscopic
55 features (Rosenberg 1986; Rosenberg et al. 1988; Rak 1990; Frayer et al. unpublished). For
56 example, Rak (1990) drew attention to the similarities with contemporary male pelves,
57 quoting several indices calculated from measurements taken on the pubis and ischium that lie
58 within the range of male variation. For Rosenberg (1986: 114), several characters of the
59 hipbone "leave little doubt that it is a male specimen". In particular, she pointed to the
60 morphology of the ischio-pubic rami, the absence of ventral arch and the concavity of the
61 lower pubic ramus. She also noted that the index determined from the length of the pubis in
62 relation to the diameter of the femoral head squared was completely outside the range of
63 female variation (Rosenberg et al. 1988). Furthermore, in her doctoral dissertation, Rosenberg
64 mentioned an unpublished study conducted by Frayer and colleagues (n.d.) that suggested the
65 young age of the individual could be the reason for the overall gracility of the skeleton. Later,
66 these authors also identified Qafzeh 9 as a male (Frayer et al. 2006: 1999, note 10).
67 Coqueugniot et al. (2000) also suggested a male assignment, based on the mandibular ramus
68 posterior flexure.

69 These differing sexual diagnoses can, in fact, be partly explained by the young age at death of
70 Qafzeh 9, "at the limit between adolescence and adulthood" (Vandermeersch 1981:49), but
71 also by the distortions of the pelvic bones due to post-mortem processes and sediment weight
72 (Fig.1).

73 Despite the first study indicating a young age at death, Qafzeh 9 is often described as an adult
74 (e.g. Ponce de Leon and Zollikofer, 2001; Vandermeersch and Bar-Yosef, 2009; Schwartz
75 and Tattersall, 2010; Quam et al. 2011; Franciscus and Holliday, 2013), or with an age at
76 death of 20-21 years (Rak, 1990).

77 Given the number of differing interpretations of the biology of the Qafzeh 9 specimen, we
78 propose to re-evaluate its age at death and sex employing recently developed methods.

79 **2. Material and methods**

80 Qafzeh 9 is housed at the Department of Anatomy and Anthropology, Sackler Faculty of
81 Medicine, Tel Aviv University. In order to re-evaluate the biological parameters of this fossil,
82 we examined the original bones and used radiographs and micro-CT scans (Coutinho
83 Nogueira 2019). Micro-CT-scans of the Qafzeh 9 mandible (isometric voxel size of 80 μm)
84 and skull (voxel isometric voxel size of 200 μm) were employed to estimate its dental age at
85 death. Micro-CT slices and 3D reconstructions were analyzed using TIVMI® software
86 (Dutailly et al., 2009; Guyomarc'h et al., 2012) based on the HMH (Half Maximum Height)
87 algorithm (Sporer et al., 1993). A plain X-ray of the mandible was also used for observing of
88 the degree of calcification of the teeth.

89 **2.1. Age at death estimation**

90 Several sources of information can be used for estimating the age at death of Qafzeh 9. The
91 dental age of Qafzeh 9 was re-evaluated from micro-CT images and radiographs according to
92 the charts of tooth formation stages developed by Moorrees *et al* (1963), AlQahtani *et al*
93 (2010) and Esan (2017), studies involving population samples from different continents. Only
94 complete teeth preserved in the alveolar bone are included in the analysis, as post-mortem
95 damage may bias the observations. It is not possible to observe and score the complete dental
96 series of Qafzeh 9, which excludes the methodological approach proposed by Demirjian *et al.*
97 (1973).

98 Skeletal age and infracranial bone maturation were evaluated following the practical criteria
99 of developmental osteology published by Coqueugniot and Weaver (2007) and Coqueugniot
100 *et al.* (2010). The estimation was calculated by the BAE package (Bayesian Age Estimation
101 for Anthropological Purposes, v. 1.3.1) in R and with the MACROS ARCHEO software
102 (Coqueugniot *et al.* 2018). In addition, radiographs of the two hand bones were employed to
103 evaluate ossification of the metacarpal heads and fusion of the phalangeal epiphyses; the age
104 at death estimation is given according to Birkner (1978) and Scheuer and Black (2000).

105 Previous paleopathological studies carried out on the Qafzeh 9 infracranial bones (Dastugue
106 1981; Arensburg *et al.* 2006) did not reveal any conditions that might involve a change in
107 maturation rate. Minor bone growth disorders were detected on the mandible (Coutinho
108 Nogueira *et al.* 2019).

109 **2.2. Sex estimation**

110 It is primarily pelvic morphology that provides a reliable sex estimation. We use the method
111 of Probabilistic Sexual Diagnosis version 2 that takes into account hip bone measurements
112 (Brůžek *et al.* 2017). Measurements were taken on the Qafzeh 9 hip bones housed in Tel Aviv
113 and then by other observers on a high quality cast at the PACEA laboratory (University of
114 Bordeaux). Because of the plastic deformations suffered by the fossil, two of the authors
115 (DCN and HC) as well as three other observers familiar with the DSP2 method took
116 measurements to account for inter-observer error. No instructions were given to the observers
117 concerning the management of distortions.

118 We also applied the methodological approach employed by Klales and colleagues for adults
119 and non-adults individuals (Klales *et al.*, 2012; 2017) adapted from Phenice (1969) and based
120 on a small number of pelvis morphological features.

121 Finally, as the talus and calcaneus of Qafzeh 9 are well preserved, we applied discriminant
122 function equations recently developed for paleoanthropological purposes and sex assignment
123 by Alonso-Llamazares and Pablos (2019). Dimensions of the left bones were used
124 preferentially.

125 **3. Results**

126 3.1. Age at death estimation from dental maturation

127 The micro-CT slices allowed a precise visualization of tooth development, especially the most
128 advanced stages of root apex closure. The observations were performed on the left side of the
129 mandible and maxilla, the alveolar bone being less affected by post-mortem processes. The
130 two permanent incisors, the first premolar and the first mandibular molar with complete
131 maturation were scored Ac (apical closure complete), according to the stages listed by
132 Moorrees et al (1963). Two mandibular teeth, the canine and the second premolar, have roots
133 whose apex is not completely closed; they are scored A $\frac{1}{2}$ (Apex half closed). As the roots of
134 the second and third molars are affected by post-mortem damage, and the underlying alveolar
135 bone is no longer present, M2 was scored as between Rc (root length complete) and Ac and
136 M3 was scored Rc in order to provide a minimal stage of development. The roots of the two
137 maxillary premolars are complete (Fig.2).

138 Accurate observations on the plain X-ray of the mandible show the taphonomic damage on
139 the lower part of the mandibular body and the uncertainties concerning the apex
140 opening/closure of M2 and M3 roots (Fig.3). Tooth formation stages are given in table 1.

141 The method of Moorrees et al (1963), based solely on mandibular teeth, provides a broad
142 estimation of the age at death, around 14.5 by combining the two sexes (12-14.5 for a female
143 individual and 13.5-15.5 for a male individual). Clearly, the lower limit of this variation,
144 based on the non-closure of the canine and 2nd premolar root apex, underestimates the age at
145 death of the individual. Including upper premolars and reference to the tables of AlQahtani et
146 al. (2010), the minimal estimation is 14.5 years. If we exclude the canine and 2nd premolar,
147 whose stage of development could be influenced by the quality of our images (micro-CT
148 scan) compared to the radiographs used for developing the two methods, we can only propose
149 a minimal age of 13.5 according to Moorrees et al (1963) and at least 17.5 according to
150 AlQahtani et al. (2010).

151 The WITS Atlas of tooth formation and emergence (Esan 2017) gives an age estimation
152 ranging between 14.5 and 16.5 years. If we exclude the canine and the 2nd premolar, a
153 minimal age of 15.5 years can be proposed. As the WITS Atlas only provides a mean age for
154 the M3 occlusion, maturation stage of M3 was not considered.

155

156 3.2. Bone maturation and age at death

157 X-ray examination of the Qafzeh 9 hand bones permits an evaluation of ossification stages.
158 The distal phalanges of left digits 1 to 4 and that of the right digits 1 and 3 show evidence of
159 an endochondral ossification line. The status of some proximal phalanges is more difficult to
160 evaluate due to the normal shape of the proximal articular facet of the base as illustrated by
161 the right third digit (fig.4).

162 In modern populations, the completion of hand bone osseous development occurs between 13
163 and 14.5 for the female sub-adults; 13 and 16.5 for the male ones (Birkner, 1978; quoted by

164 Scheuer and Black 2000). As the visibility of a fusion line can persist radiographically after
165 full fusion, these observations provide a minimal age of 13 for Qafzeh 9.

166 The scoring of bone fusion of other infracranial remains was carried out taking into account
167 their state of preservation. Stages of fusion are given in table 2.

168
169 Ossification of Qafzeh 9 lower limbs appears more advanced than that of the upper limbs.
170 Some epiphyseal fusion is complete on the lower limbs while still in progress on the upper
171 limbs. For example, the distal and proximal extremities on the left tibia are fused while the
172 distal end of the ulna is still clearly in the process of fusion (Fig.5)

173 The BAE package (Coqueugniot and Weaver 2007) estimates the age of Qafzeh 9 between 18
174 and 21 years with a higher probability for 19 years ($p=0.557$).

175 The MACROS software (Coqueugniot et al. 2018) estimates the age of Qafzeh 9 between
176 18.5 and 20.3 years (estimate: 19.4195; Mean Error: 1.843811; Pseudo R^2 : 0.8592267) from a
177 sample of 211 individuals.

178 The results between the BAE package and the MACROS software are therefore similar with
179 an estimated age around 19 years, the range being slightly smaller with MACROS.

180 From the results, it appears that Qafzeh 9 died before reaching complete bone maturity,
181 however epiphyseal union was ongoing before death; in this context we can expect to sex the
182 skeleton with some degree of reliability.

183 3.3. Sex estimation

184 For sex estimation, we first examined the coxal bones and the DSP2; the results including
185 inter-observer variation are summarized in table 3:

186 For all observers, a reasonable conclusion is a male with a probability of more than 95%. The
187 test with the maximum and minimum values of each variable also results in a male sex
188 identification. Adding or removing the two less discriminating variables, SIS and VEAC,
189 slightly alters the probabilities of observers 2 and 3, increasing the probability of a male
190 result.

191 The results of macroscopic methods (Klales et al 2012, 2017) adapted from Phenice (1969)
192 are summarized in table 4.

193 In Klales et al (2012) ordinal scores range from 1 (female) to 5 (male). In Klales et al (2017)
194 ordinal scores range from 1 (female) to 3 (male). The VA is not scored on non-adults. Our
195 observations confirm Rosenberg's (1986) descriptions concerning the subpubic concavity and
196 ventral arc. However, due to taphonomic distortions, we do not score the medial aspect of the
197 ischio-pubic ramus. Overall, the results are consistent with a male assignment.

198 Of the 24 discriminant equations using the tarsal bones tested on Qafzeh 9, 18 give a male
199 result and 6 a female result, i.e. 75% male and 25% female. Taking into account only the
200 multivariate equations that have a slightly higher rate of an accurate determination on
201 average, 91.6% of the equations give a male result (Table 5).

202 From the application of three methods of sex estimation, we thus obtain a male attribution for
203 Qafzeh 9.

204 **4. Discussion**

205 The cross-checking of the different methods of age at death estimation provide an age
206 estimation comprised between 18.5-20.5 years old (Table 6). Indeed, this range age is
207 provided by all used methods. However some differences can be noted between the different
208 methods.

209 There may be several reasons for the differences between methods. Age estimation methods
210 are population-dependent and lose precision when they are applied to other populations
211 (Franklin 2010). The collection studied by Moorrees et al (1963) consisted of 346 North
212 American children who lived in the 20th century. The London Atlas proposed by AlQahtani et
213 al. (2010) refers to truly documented samples and radiographs from dental institutes: 704
214 individuals from the 18th to the 20th century (children from England and Bangladesh). The
215 recent study reported on 540 South African children (Esan 2017) provides evidence of
216 discrepancies with the London Atlas established by AlQahtani and colleagues. However, there
217 are some inconsistencies in the ages of M3 eruptions in this work, so the estimations should
218 be taken with caution.

219 The dental ageing developed by Moorrees et al. (1963) refers to radiographic observations.
220 We have established our analysis on three types of images: a classical X-ray, a radiograph
221 made from a micro-CT scan and on micro-CT sections directly. The plain X-ray of Qafzeh 9
222 mandible shows the opening of the canine apex. The microtomodensitometric sections allow a
223 finer observation of the apex of the second premolar and its scoring. In the case of Qafzeh 9,
224 the method of observation could have influenced the scoring, and under estimate the age when
225 using the canine and the 2nd premolar maturation stages.

226 The age estimation based on the third molar maturation is significantly different using either
227 Moorrees et al (1963) or AlQahtani et al (2010) charts. The reasons for this could be different
228 maturation rates between populations. Indeed, Liversidge (2008) noted that Southern African
229 have significant faster maturation rates for the third molar than White and Bangladeshi
230 children. A similar observation was noted by Blankenship et al (2007) with Black Americans
231 having faster maturation rates compared to White Americans, and Legović et al (2010)
232 discussed differences in maturation between Croatian children and those of several other
233 populations (Sweden, Japan, South Africa, Israel, Turkey, etc.). In a comparative study of
234 dental development in Upper Pleistocene hominins (Neanderthals/archaic Homo sapiens and
235 Early Modern/Upper Paleolithic samples) and two recent samples, Tompkins (1996:113)
236 underlined “similarities between the two fossil groups and Southern Africans in advanced
237 relative M2 and especially M3 development” compared to French-Canadians. Regarding
238 Qafzeh 9, the M3 is fully erupted, while the lower canine and second premolar have roots
239 whose apex is not completely closed. Besides population differences, sex, health status and
240 diet have also to be considered in the variation of third molar development and eruption (Garn
241 et al. 1961, Garn et al 1965).

242 The parameters from the definition of ossification stages (Coqueugniot and Weaver 2007;
243 Coqueugniot et al 2010) are implemented after the study of the Coimbra documented
244 collection in Portugal (137 individuals aged between 7 and 29 years old from the 20th
245 century). Accuracy of age estimation from skeletal development is thought to be more
246 sensitive to environmental factors (Lewis and Garn 1960; Liversidge et al 1998; Cardoso
247 2007; Colombo et al 2013). In addition, as for the use of dental references, bone maturation
248 criteria originate from current populations and might therefore lead to slight discrepancies in
249 age estimations of prehistoric populations having different lifeways.

250 Based on a combination of the results brought by examination of tooth and bone
251 development, it appears that Qafzeh 9 was an individual who had not achieved full skeletal
252 and dental maturity at the time of death. An average of between 18.5 and 20.5 years at the
253 time of death would appear to be most reasonable.

254 The application of the DSP2 method provides some discrepancies between the measurements
255 made by different observers, due in part to post-mortem distortions of the pelvic bone. Yet all
256 results favour identification as a male. Sex estimation methods based on pelvic parameters
257 defined on recent populations has already been tested on early modern humans. Indeed, the 1st
258 version of the DSP (Murail et al 2005), using the same variables as for the DSP2, was applied
259 to European Upper Palaeolithic and Mesolithic adult hominins (Gambier et al 2006; Hansen et
260 al 2017); in the case of the Danish study, molecular analyses confirmed the sex estimation
261 following the DSP2 (Hansen et al op. cit.). Interestingly, sex estimation based on pelvic
262 morphology applied to young Upper Palaeolithic individuals (same age class as Qafzeh 9)
263 from Dolní Věstonice (Brůžek 2002; Brůžek et al., 2006) has also been confirmed by DNA
264 data (Mittnik et al. 2016). The 3D reconstruction methods do not currently permit the
265 correction of these distortions; the measurements are dependent on the interpretation of the
266 observers, even if the 5 observers are familiar with the method. It is therefore advisable to
267 exercise caution and to cross-validate the DSP2 with other methods, both on the pelvis and on
268 other anatomical regions.

269 The methods adapted by Klales et al (2012; 2017) for adult and non-adults result in the
270 identification of Qafzeh 9 as male, supporting the results of the DSP 2. The discriminant
271 equations developed on the posterior tarsal bones (Alonso-Llamazares and Pablos 2019) are
272 established from a Northern American recent population (United States). Again, their
273 application to fossil specimens may be subject to discussion. The biomechanical constraints
274 on the foot bones of current sedentary populations are different from those of ancient nomadic
275 peoples. Nevertheless, 75% of the equations result in the identification of Qafzeh 9 as a male,
276 a percentage that rises to 91.6% when the equations include several variables. In cases where
277 the results were negative and therefore female, the values are always close to 0 (between -
278 0.521 and -0.0032), while the positive results are in some cases much higher than 0 (between
279 0.419 and 2.59). This would appear to give greater weight to the identification as male. Sexual
280 dimorphism of tarsal bones is strongly correlated with size, with male individuals having
281 larger bones (Steele 1976; Inrona et al. 1997; Bidmos and Asala 2003, 2004). If the
282 maturation of Qafzeh 9 was not fully achieved, measurements taken on the bones would then
283 be underestimated. Higher values would increase the results of the equations.

284 The results and observations based on metric and morphologic analyses of the pelvis and
285 tarsal bones presented here suggest Qafzeh 9 was a male, in agreement with previous
286 publications on the pelvis (Rosenberg 1986, 1988; Rak 1990; Frayer et al. 2006) and on the
287 mandible (Coqueugniot et al 2000).

288 It is widely accepted that the pelvic morphometrics furnish the best indications of sex. Yet, a
289 few traits of Qafzeh 9 skull do not clearly align it with other Qafzeh adult hominins (6 and 25)
290 who were referred to as male using the general cranial robusticity (Vandermeersch 1981,
291 Schuh et al., 2017, Coutinho Nogueira et al. 2021). The age reached by Qafzeh 9 cannot
292 constitute an argument for interpreting the morphology of the skull distinct from that of other
293 Qafzeh males, ignoring post-mortem alterations (Tillier in preparation). Such results lead to
294 a reconsideration of the importance previously given to skull features in female sex
295 determination of Qafzeh 9, as in those of many other fossil hominins. As a consequence, the
296 choice of Qafzeh 9 as the “holotype”(type specimen) can be challenged regarding the mixture

297 of traits and the differences with other Qafzeh male individuals. These observations affect the
298 homogeneity of the Qafzeh sample.

299 **Conclusion**

300 While the discovery of new fossils is crucial for the understanding of the evolutionary
301 processes of our species, the re-examination of previously discovered fossils with new
302 methods can provide valuable information.

303 The sex identification of the Qafzeh 9 skeleton has been debated in the literature. It was even
304 suggested that the Qafzeh 9-10 double burial represented a mother and her baby buried
305 together soon after their death during or just after childbirth (Cohen, 2003:29). Qafzeh 9 was
306 later nicknamed Eve (Waddell, 2015). The application of improved methods based on
307 biological identity parameters provides evidence that in fact this individual was a male with
308 an age at death estimated between 18.5 and 20.5 years.

309 Certainly, a paleogenetical investigation, using SRY gene detection (Sinclair et al. 1990) or
310 DNA shotgun sequencing (Skoglund et al., 2013), might support male sex assessment based
311 on morphometric traits. Unfortunately, at the present time, genetic studies on the Qafzeh
312 hominin sample, as well as those of other hominins from Southwest Asia, have to confront
313 technical problems due to the biochemical preservation of the bones and thus require some
314 improvements of the methods. It might be also possible in the future to use enamel proteins,
315 which may preserve ancient biogenetic data more effectively than DNA, to more confidently
316 confirm sex assignment (Parker et al 2019; Welker et al 2020).

317

318 **Acknowledgments**

319 We are grateful to the Prof. Israel Hershkovitz, Curator of the anthropological collection of
320 the Tel Aviv University, for the access to the original fossil and for the 3D images, also to
321 Julia Abramov, collection manager, for the reception and the logistics support (Dan David
322 Center, Department of Anatomy, Sackler School of Medicine, Tel Aviv University). The
323 Irene Levi Sala Care Archaeological Foundation financially supported D. Coutinho Nogueira.
324 Additional support was provided by the LaScArBx (ANR-10-LABX-52)

325 We would like to thank Olivier Dutour, Antony Colombo (Chaire d'Anthropologie biologique
326 Paul Broca, EPHE-PSL) and Patrice Courtaud (UMR 5199 PACEA), confirmed users of the
327 DSP2 method, for accepting to take measurements for inter-observer tests.

328 We are grateful to Alan E. Mann who provided valuable comments and gave his time to
329 improve the English version of the manuscript.

330 **References**

331 AlQahtani, S. J., Liversidge, H. M. & Hector, M. P. (2010): Atlas of tooth development and
332 eruption. *American Journal of Physical Anthropology* 142(3), 481-90

333 Alonso-Llamazares, C. & Pablos, A. (2019): Sex estimation from the calcaneus and talus
334 using discriminant function analysis and its possible application in fossil remains.
335 *Archaeological and Anthropological Sciences*, 1-20.

- 336 Arensburg, B., Duday, H. & Tillier, A.-m. (2006): Approche paléopathologique de la
 337 sépulture double de Qafzeh (Israël). *Communication au colloque du Groupement des*
 338 *Paleopathologistes de Langue Française*, Lille, 25-26 mars 2006
- 339 Bar-Yosef, O. (2000): The Middle and Early Upper Paleolithic in Southwest Asia and
 340 neighbouring regions. In: Bar-Yosef O, Pilbeam D (eds) *The geography of Neandertals and*
 341 *modern humans in Europe and the Greater Mediterranean*. Peabody Museum 8, Harvard
 342 University, Cambridge, 107–56
- 343 Bar-Yosef Mayer, D.E., Vandermeersch, B. & Bar-Yosef, O. (2009): Shells and ochre in
 344 Middle Paleolithic Qafzeh Cave, Israel: indications for modern behavior. *Journal of Human*
 345 *Evolution* 56, 307–314
- 346 Bidmos, M. A. & Asala, S. A. (2003): Discriminant function sexing of the calcaneus of the
 347 South African whites. *Journal of Forensic Science* 48, 1213–1218.
- 348 Bidmos, M. A. & Asala, S. A. (2004): Sexual dimorphism of the calcaneus of South African
 349 Blacks. *Journal of Forensic Science*, 49, 446–450.
- 350 Birkner, R. (1978): *Normal radiologic patterns and variances of the human skeleton. An X-*
 351 *ray atlas of adults and children*. Urban & Schwarzenberg, München Baltimore 536 pages
- 352 Blankenship, J.A., Mincer, H.H. & Anderson, K.M. (2007): Third molar development in the
 353 estimation of chronologic age in american blacks as compared with whites. *J Forensic Sci*,
 354 52(2), 428–33.
- 355 Bräuer, G. (1988): Osteométrie, In: R. Knussman dir., *Anthropologie: Handbuch der*
 356 *vergleichenden Biologie des Menschen*, Band1, Stuttgart, Éd. Gustav Fischer Verlag, 160-
 357 232.
- 358 Brůžek, J. & Vandermeersch, B. (1997): Reassessment of the sex of the Qafzeh 9 individual
 359 based on multivariate statistical analysis. *American Journal of Physical Anthropology*,
 360 Supplement, 24, 84
- 361 Brůžek, J. (2002): A method for visual determination of sex, using the human hip bone.
 362 *American Journal of Physical Anthropology*, 117, 157-168.
- 363 Brůžek, J., Franciscus, R.G., Novotny, V. & Trinkaus, E. (2006): The Assessment of Sex In:
 364 Trinkaus, E, Svoboda, J, editors. *Early Modern Human Evolution in Central Europe: The*
 365 *People of Dolní Věstonice and Pavlov*. Dolní Věstonice Studies 12. New York: Oxford
 366 University Press; 46–62.
- 367 Brůžek, J., Cunha, E., Dutailly, B., Murail, P. & Santos, F. (2017): Validation and reliability
 368 of the sex estimation of the human os coxae using freely available DSP2 software for
 369 bioarchaeology and forensic anthropology, *American Journal of Physical Anthropology*,
 370 164(2), 440-449
- 371 Brůžek, J. & Murail, P. (2006): Methodology and reliability of sex determination from the
 372 skeleton. In: A. Schmitt, E. Cunha, and J. Pinheiro, eds. *Forensic Anthropology and*
 373 *Medicine: Complementary Sciences from Recovery to Cause of Death*. New York: Springer,
 374 225-242.

- 375 Cardoso, H. F. V. (2007): Environmental effects on skeletal versus dental development: using
376 a documented subadult skeletal sample to test a basic assumption in human osteological
377 research. *American Journal of Physical Anthropology*, 132, 223–233
- 378 Cohen, C. (2003): *La femme des origines. Images de la femme dans la préhistoire*
379 *occidentale*, Belin-Herscher, Paris
- 380 Colombo, C., Coqueugniot, H., Dutailly, B., Desbarats, P. & Tillier, A.-m., (2013): Nouvelles
381 données sur l'édification des molaires et l'estimation de l'âge dentaire des enfants par
382 imagerie médicale et 3D : apports et perspectives. *Bulletins et Mémoires de la Société*
383 *d'Anthropologie de Paris*, 25, 127-146.
- 384 Coqueugniot, H., Tillier, A.-m. & Bruzek, J. (2000): Mandibular ramus posterior flexure: a
385 sex indicator in Homo sapiens fossil hominids? *International Journal Osteoarchaeology* 10,
386 6, 426-431
- 387 Coqueugniot, H. & Weaver, T.D. (2007): Brief communication: infracranial maturation in the
388 skeletal collection from Coimbra, Portugal: New Aging Standards for Epiphyseal Union.
389 *American Journal of Physical Anthropology*, 134, 424–437
- 390 Coqueugniot, H., Weaver, T.D. & Houët, F. (2010): A probabilistic approach to age
391 estimation from infracranial sequences of maturation. *American Journal of Physical*
392 *Anthropology*, 142, 655-664.
- 393 Coqueugniot, H., Colombo, A., Dutailly, B., Dutour, O., Ritemard, C. & Santos, F. (2018):
394 Logiciel MACROS ARCHEO: IDDN.FR.001.500008.000.S.P.2018.000.31230
395
- 396 Coutinho-Nogueira, D., Dutour, O., Coqueugniot, H. & Tillier, A.-m. (2019): Qafzeh 9
397 mandible (ca 90–100 kyrs BP, Israel) revisited: μ -CT and 3D reveal new pathological
398 conditions, *International Journal of Paleopathology*, 26, 104-110,
399 <https://doi.org/10.1016/j.ijpp.2019>.
- 400
- 401 Coutinho-Nogueira, D. (2019): *Paléomagerie appliquée aux Homo sapiens de Qafzeh*
402 *(Paléolithique moyen, Levant sud). Variabilité normale et pathologique*. Thèse de Doctorat de
403 l'Université PSL, Ecole Doctorale 472 de l'Ecole Pratique des Hautes Etudes, Spécialité
404 Anthropologie
- 405
- 406 Coutinho-Nogueira, D., Coqueugniot, H. & Tillier, A.-m. (2021): The bony labyrinth of
407 Qafzeh 25 *Homo sapiens* from Israel, *Archaeological and Anthropological Sciences* (in press)
- 408
- 409 Dastugue, J. (1981): Pièces pathologiques de la nécropole moustérienne de Qafzeh.
410 *Paléorient*, 7, 135–140
- 411 Demirjian, A., Goldstein, H. & Tanner, J. M. (1973): A new system of dental age assessment.
412 *Human Biology*, 45, 211–27.
- 413 Dutailly, B., Coqueugniot, H., Desbarats, P., Gueorguieva, S & Synave, R. (2009): 3D surface
414 reconstruction using HMH algorithm. *Proceedings of the 16th IEEE International Conference*
415 *on Image Processing*, 2505-2508.

- 416 Esan, T.A., (2017): *Dental development in a Southern African sub adult population:*
 417 *Determination of reference values for permanent tooth formation and emergence.* (doctoral
 418 dissertation), University of the Witwatersrand, Johannesburg
- 419 Franciscus, R.G. & Holliday, T.W. (2013): Crossroads of the Old World. In *The Origins of*
 420 *Modern Humans* (eds F.H. Smith and J.C.M.
 421 Ahern). <https://doi.org/10.1002/9781118659991.ch2>
- 422 Franklin, D., (2010): Forensic age estimation in human skeletal remains: current concepts and
 423 future directions. *Legal Medicine*, 12, 1–7
- 424 Frayer, D.W., Jelinek, N., Minugh, N., Smith, F.H. & Wolpoff, M.H., unpublished, *Upper*
 425 *Pleistocene human remains from Backova Dira Cave at Mladeč (Lautsch), Moravia: Burnt,*
 426 *trampled and ignored, they now return to haunt.*
- 427 Frayer, D.W., Jelinek, N., Oliva, M. & Wolpoff, M.H. (2006): Aurignacian Male Crania,
 428 Jaws and Teeth from the Mladeč Caves, Moravia, Czech Republic. In: M. Teschler-Nicola
 429 (Ed.) *Early Modern Humans at the Moravian Gate. The Mladeč Caves and their remains.*
 430 Springer-Verlag/Wien: 185-272.
- 431 Gaillard, J. (1960) : Détermination sexuelle d'un os coxal fragmentaire. *Bulletins Et Mémoires*
 432 *De La Société D'Anthropologie De Paris, XIe Série, 2, 255–267.*
- 433 Gambier, D., Bruzek, J, Schmitt, A, Houet F., & Murail P. (2006): Révision du sexe et de
 434 l'âge au décès des fossiles de Cro-Magnon (Dordogne, France) à partir de l'os coxal. *Compte*
 435 *Rendu Palevol, 5, 735-741.*
 436
- 437 Garn S.M., Lewis, A.B. & Bonn   B. (1961): Third molar polymorphism and the timing of
 438 tooth formation. *Nature*, 192, 989
 439
- 440 Garn, S.M., Lewis, A.B. & Kerewsky R.S. (1965): Genetic, nutritional and maturational
 441 correlates of dental development. *Journal of Dental Research*, 44, 228-242
- 442 Gr  n R. & Stringer C. B, (2000): Electron spin resonance dating and the evolution of modern
 443 humans. *Archaeometry* 33, 153–99
- 444 Guyomarc'h, P., Santos, F., Dutailly, B., Desbarats, P., Bou, C. & Coqueugniot, H. (2012):
 445 Three-dimensional computer-assisted craniometrics: A comparison of the uncertainty in
 446 measurement induced by surface reconstruction performed by two computer programs, In
 447 *Forensic Science International*, 219, Issues 1–3: 221-227,
 448 doi.org/10.1016/j.forsciint.2012.01.008
- 449 Hansen, J., Petersen H.C., Frei, K.M., Courtaud, P., Tillier, A-m., Fischer, A. & Allentoft,
 450 M.E. (2017): The Maglemosian skeleton from Koelbjerg, Denmark revisited: identifying sex
 451 and provenance. *Danish Journal of Archaeology*, DOI .org. 10.1080 :21662282.2017
- 452 Hovers, E., Vandermeersch, B. & Bar-Yosef, O. (1997): A Middle Palaeolithic engraved
 453 artefact from Qafzeh Cave, Israel. *Rock Art Research*, 14, 79-87
- 454 Hovers, E., Ilani, S., Bar-Yosef, O. & Vandermeersch, B. (2003): An Early Case of Color
 455 Symbolism: Ochre Use by Modern Humans in Qafzeh Cave. *Current Anthropology* 44, n  4,
 456 491-522.
 457

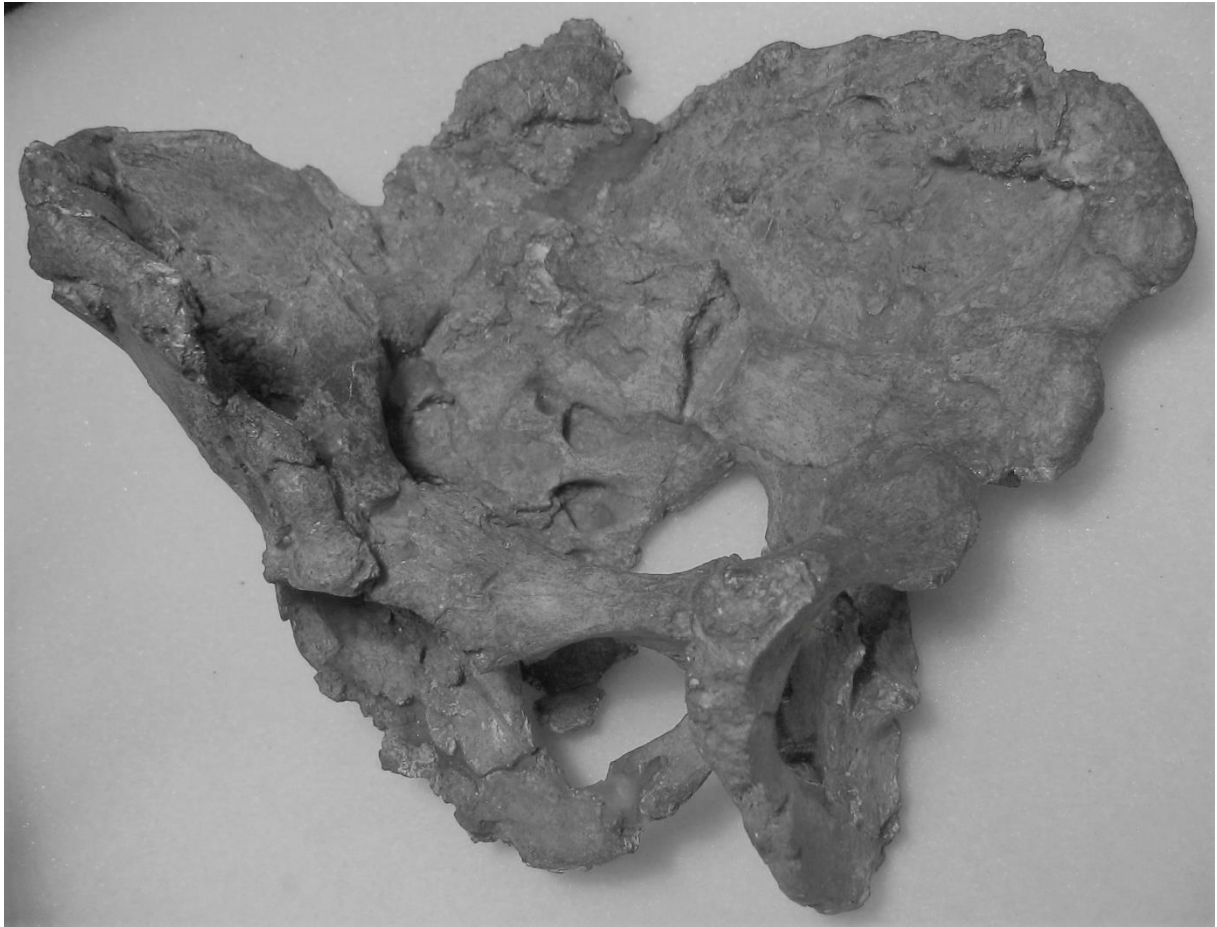- 458 Introna, F., Divella, G., Campobasso, C., Dragone, M., (1997): Sex determination by
459 discriminant analysis of Calcanei measurements. *Journal of Forensic Science*, 42, 725–728.
- 460 Klales, A.R., Ousley, S.D. & Vollner, J.M. (2012): A revised method of sexing the human
461 innominate using Phenice's nonmetric traits and statistical methods. *Am. J. Phys. Anthropol.*,
462 149, 104-114. doi:[10.1002/ajpa.22102](https://doi.org/10.1002/ajpa.22102)
- 463 Klales, A.R. & Burns T.L. (2017): Adapting and Applying the Phenice (1969) Adult
464 Morphological Sex Estimation Technique to Subadults. *J Forensic Sci*, 62: 747-752.
465 doi:[10.1111/1556-4029.13332](https://doi.org/10.1111/1556-4029.13332)
- 466 Legović, M, Sasso, A, Legovic, I, Brumini, G, Cabov, T, Slaj, M et al. (2010): The reliability
467 of chronological age determination by means of mandibular third molar development in
468 subjects in Croatia. *J Forensic Sci.*, 55 14–8
- 469 Lewis, A. B. & Garn, S. M. (1960): The relationship between tooth formation and other
470 maturational factors. *Angle Orthodontist*, 30, 70–74.
- 471 Liversidge, H. M., Herdeg, B. & Rösing, F. W. (1998): Dental age estimation of non-adults.
472 A review of methods and principles. In: Sprin-ger (ed) *Dental anthropology: fundamentals,*
473 *limits and prospects*, 419–42
- 474 Liversidge, H. M. (2008): Timing of human third molar formation, *Annals of Human Biology*
475 35(3), 294-32
- 476 Mittnik, A, Wang, CC, Svoboda J. & Krause, J. A (2016): Molecular Approach to the Sexing
477 of the Triple Burial at the Upper Paleolithic Site of Dolní Věstonice. *PLoS One*,
478 11(10):e0163019.. doi:10.1371/journal.pone.0163019
- 479 Moorrees, C.F.A., Fanning, E.A. & Hunt, E.E. (1963): Age Variation of Formation Stages for
480 Ten Permanent Teeth. *Journal of Dental Research*. 42, 1490–1502.
- 481 Murail, P., Bruzek, J., Houët, F. & Cunha, E. (2005): DSP: a probabilistic sex diagnosis tool
482 using worldwide variability in hip bone measurements. *Bulletins et Mémoires de la Société*
483 *d'Anthropologie de Paris*, 1.17, 3-4, 167-176
- 484 Parker, G. J., Yip, J. M., Eerikens, J. W., Salemi, M., Durbin-Johnson, B., Kiesow, C., Haas,
485 R., Buikstra, J. E., Klaus, H., Regan, L. A., Rocke, D. M., & Phinney, B. S. (2019): Sex
486 estimation using sexually dimorphic amelogenin protein fragments in human enamel. *Journal*
487 *of Archaeological Science* **101**, 169–180
- 488 Phenice, T.W. (1969): A newly developed visual method for sexing the os pubis. *Am J Phys*
489 *Anthropol*, 30, 297–302.
- 490 Ponce de León, M. & Zollikofer, C. (2001): Neanderthal cranial ontogeny and its implications
491 for late hominid diversity. *Nature* **412**, 534–538. <https://doi.org/10.1038/35087573>
- 492 Quam, R., Martínez, I., & Arsuaga, J., (2011): New Observations on the Human Fossils from
493 Petit-Puymoyen (Charente). *Paleoanthropo*, 95–105
- 494 Rak, Y. (1990): On the differences between two pelvises of Mousterian context from the
495 Qafzeh and Kebara caves, Israel. *American Journal of Physical Anthropology*, 81, 323–332
- 496 Rosenberg, K. (1986): *The functional significance of Neandertal pubic morphology*, PhD
497 Dissertation, University of Michigan

- 498 Rosenberg, K. (1988): The functional significance of Neandertal pubic length. *Curent*
499 *Anthropology*, 29, 595–617.
- 500 Scheuer, L. & Black, S. (2000): *Developmental Juvenile Osteology*. Elsevier Academic Press,
501 San Diego, CA
- 502 Schuh A., Dutailly B., Coutinho Nogueira D., Santos F., Arensburg B., Vandermeersch B.,
503 Coqueugnot H., Tillier A.-m., (2017) La mandibule de l'adulte Qafzeh 25 (Paléolithique
504 moyen), Basse Galilée : reconstruction virtuelle 3D et analyse morphométrique. *Paléorient*
505 43-1:49-59
- 506 Schuler-Ellis, F.P., Schmidt, D.J., Hayek, L.C. & Craig J. (1983): Determination of sex with
507 a discriminant analysis of new pelvic bone measurements: Part I. *Journal of Forensic*
508 *Sciences*, 28, 169–180.
- 509 Schultz, A. H. (1930): The skeleton of trunk and limbs of higher primates. *Human biology*, 2,
510 303 - 348.
- 511 Schwarcz H, Grün R, Vandermeersch B, Bar Yosef O., Valladas H. & Tchernov E. (1988):
512 ESR dates for the hominid burial site of Qafzeh in Israel, *Journal of Human Evolution*, 17, 8,
513 733738
- 514 Schwartz, J.H. & Tattersall, I. (2010): Fossil evidence for the origin of *Homo sapiens*. *Am. J.*
515 *Phys. Anthropol.*, 143, 94-121. <https://doi.org/10.1002/ajpa.21443>
- 516 Sinclair, A., Berta, P., Palmer, M., Hawkins, J.R., Griffiths, B.L., Smith, M., Foster, J.W.,
517 Frischauf, A.M., Lovell-Badge, R. & Goodfellow, P.N. (1990): A gene from the human sex-
518 determining region encodes a protein with homology to a conserved DNA-binding motif.
519 *Nature* 346, 240–244 <https://doi.org/10.1038/346240a0>
- 520 Skoglund, P., Stora, J., Gotherstrom, A. & Jakobsson, M. (2013): Accurate sex identification
521 of ancient human remains using DNA shotgun sequencing, *Journal of Archaeological*
522 *Sciences*, 40, 4477-4482
- 523 Spoor, C.F., Zonneveld, F.W. & Macho, G.A. (1993): Linear measurements of cortical bone
524 and dental enamel by computed tomography: applications and problems. *American Journal of*
525 *Physical Anthropology* 91, 469-484.
- 526 Steele, D. G. (1976): The estimation of sex on the basis of Sex Assessment from Talus and
527 Calcaneus 47 the talus and calcaneus. *American Journal of Physical Anthropology*, 45, 581–
528 588.
- 529 Tillier, A.-m. (1995): Paléoanthropologie et pratiques funéraires au Levant méditerranéen
530 durant le Paléolithique moyen : le cas des sujets non adultes. *Anthropologie du Proche-Orient*,
531 Données récentes. *Paléorient*, 21 n°2, 63-76.
- 532 Tillier, A.-m. (1999): *Les enfants moustériens de Qafzeh. Interprétation phylogénétique et*
533 *paléoauxologique*. Paris: Cahiers de Paléoanthropologie, CNRS Editions. 239 pages.
- 534 Tillier, A.-m. (2014): New Middle Palaeolithic Hominin Dental Remains from Qafzeh, Israel.
535 In: *Paléorient*, vol. 40, n°1, 13-24
- 536 Tillier, A.-m. (in preparation) Middle Paleolithic hunter-gatherers in Southwest Asia and
537 demographic indicators. The Qafzeh hominins.

- 538 Tompkins, R.L. (1996): Relative dental development of Upper Pleistocene hominids
539 compared to human population variation. *American Journal of Physical Anthropology*, 99,
540 103-118.
- 541 Trinkaus, E. (1984): Neandertal pubic morphology and gestation length. *Current*
542 *Anthropology*, 4, 509-514. DOI: 10.1086/203173
- 543 Valladas, H., Reyss, J.L., Joron, J.L., Valladas, G., Bar Yosef, O. & Vandermeersch, B.
544 (1988): Thermoluminescence dates for the Mousterian Proto-Cro-Magnons from Qafzeh Cave
545 (Israel), *Nature*, 331, 614-616.
- 546 Vandermeersch, B. (1969a): Les nouveaux squelettes moustériens découverts à Qafzeh et leur
547 signification. *Comptes Rendus l'Académie des Sciences de Paris*. 268, D, 2562-2565
- 548 Vandermeersch, B. (1969b): Découverte d'un objet en ocre avec traces d'utilisation dans le
549 Moustérien de Qafzeh (Israël). *Bulletin de la Société préhistorique française. Comptes rendus*
550 *des séances mensuelles*, tome 66, n°5, 157-158.
- 551 Vandermeersch, B. (1981): *Les hommes fossiles de Qafzeh*, Cahiers de Paléanthropologie,
552 CNRS Editions, Paris
- 553 Vandermeersch, B. & Bar-Yosef, O. (2017): Qafzeh Cave and Terrace In: Enzel Y., Bar-
554 Yosef O. (eds), *Quaternary of the Levant: environments, climate change, and humans*.
555 Cambridge: Cambridge University Press, 251-253.
- 556 Vandermeersch, B. & Bar-Yosef, O. (2019): The Paleolithic Burials at Qafzeh Cave,
557 Israel, *PALEO*, 30, 256-275
- 558 Waddell, P. J. (2015): Expanded Distance-based Phylogenetic Analyses of Fossil Homo Skull
559 Shape Evolution, *arXiv*, 1512.09115
- 560 Walker, P.L., Dean, G. & Shapiro, P. (1991): Estimating age from tooth wear in
561 archaeological populations. In: Kelley, M.A. and Larsen, C.S., Eds., *Advances in Dental*
562 *Anthropology*, WileyLiss, Chichester, 13-31.
- 563 Weber, G.W., Schäfer, K., Prossinger, H., Gunz, P., Mitteröcker, P. & Seidler, H. (2001):
564 Virtual anthropology: the digital evolution in anthropological sciences. *Journal of*
565 *Physiological anthropology and Applied Human Science*, 20, 69– 80.
- 566 Weber, G.W. & Bookstein, F.L. (2011): *Virtual Anthropology. A guide to a new*
567 *interdisciplinary field*. Wien, New York: Springer Verlag, Welker, F., Ramos-Madriral, J.,
568 Gutenbrunner, P., Mackie, M., Tiwary, S., Rakownikow Jersie-Christensen, R., Chiva, C.,
569 Dickinson, M.R., Kuhlwilm, M., de Manuel, M., Gelabert, P., Martínón-Torres, M.,
570 Margvelashvili, A., Arsuaga, J.L., Carbonell, E., Marques-Bonet, T., Penkman, K., Sabidó,
571 E., Cox, J., Olsen, J.V., Lordkipanidze, D., Racimo, F., Lalueza-Fox, C., Bermúdez de Castro,
572 J.M., Willerslev, E. & Cappellini, E. (2020): The dental proteome of Homo antecessor,
573 *Nature*, 580(7802):235-238. doi: 10.1038/s41586-020-2153-8.
- 574

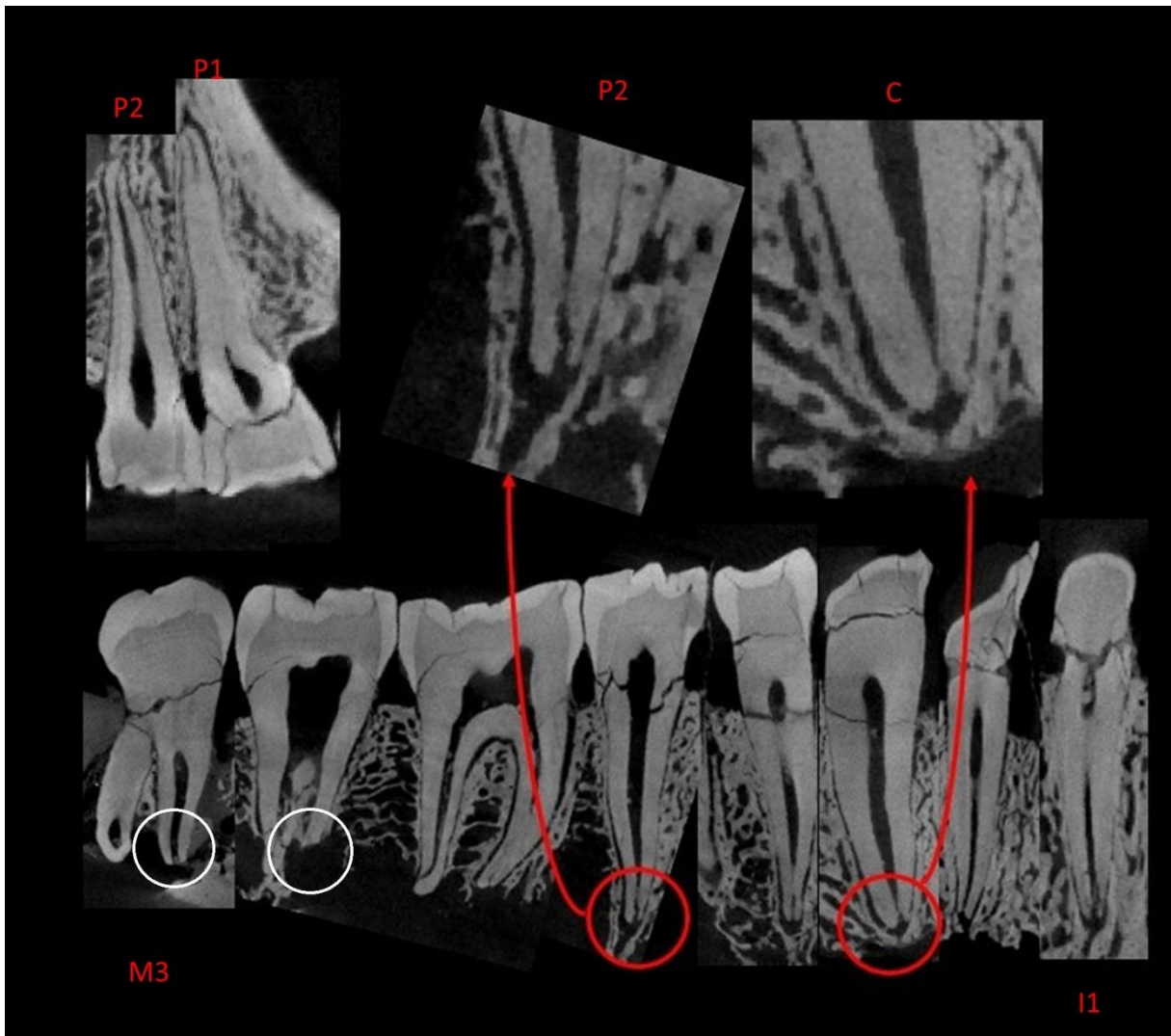
575 **Figures and captions**

576



577

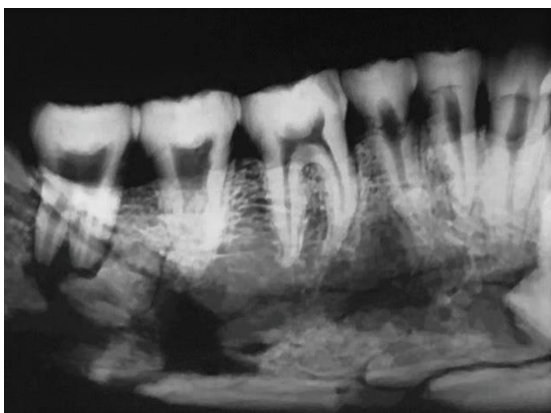
578 Fig.1 Qafzeh 9 bony pelvis (Anne-marie Tillier)



579

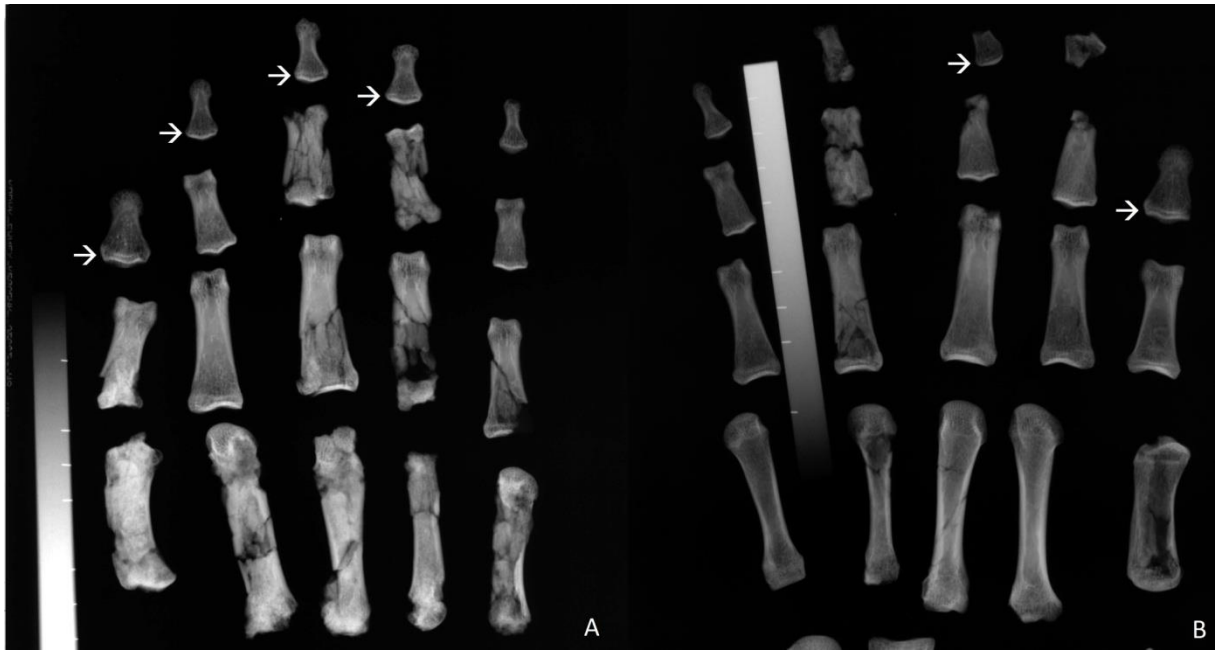
580 Fig.2: CT sections showing the dental roots of Qafzeh 9 (white circles indicate taphonomic
581 alterations) (Dany Coutinho Nogueira)

582



583

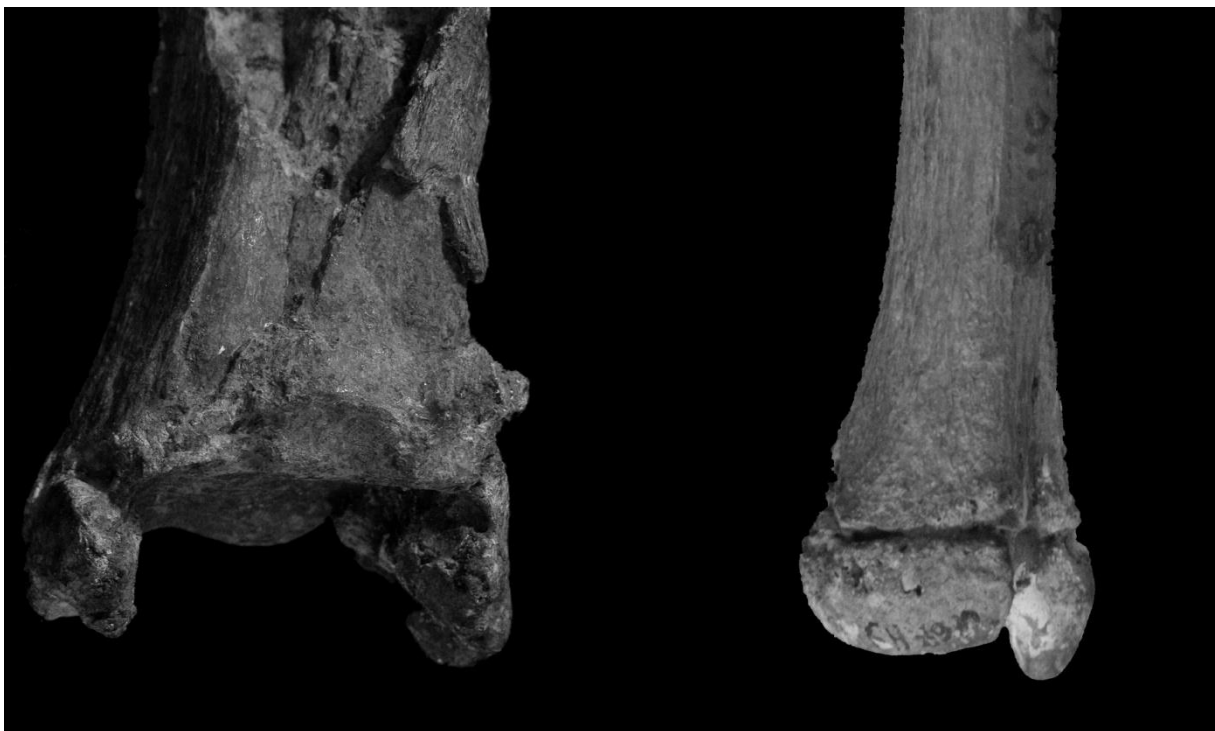584 Fig.3: Plain X-ray of Qafzeh 9 mandible showing the bone damage under the second and third
585 molars (Anne-marie Tillier)



586

587 Fig. 4: Radiographs of the left (A) and right (B) metacarpals and phalanges of Qafzeh 9.
 588 Arrows show endochondral lines indicating the very end of ossification of distal phalanges
 589 (Anne-marie Tillier)

590



591

592 Fig.5 Distal extremities of the left tibia and ulna showing different degrees of bone maturation
 593 (Dany Coutinho Nogueira)

594

595

Mandible (Moorrees et al 1963)		Age in years	
tooth	stage	Females	Males
I1	Ac	>6	>6.5
I2	Ac	>7	>7.5
C	A1/2	8 – 12	9.5 - 14.5
P1	Ac	>10	>11
P2	A1/2	9.5 – 14.5	10 - 15.5
M1	Ac	>7	>7.5
M2	Rc to Ac	9 – 18	9.5 - 18
M3	Rc	14 - 21	13.5 - 20.5

Mandible (AlQahtani et al 2010)		Age in years
tooth	stage	combine sex
I1	Ac	> 8.5
I2	Ac	> 8.5
C	A1/2	11.5 – 14.5
P1	Ac	> 12.5
P2	A1/2	11.5 -15.5
M1	Ac	> 9.5
M2	Rc to Ac	>14.5
M3	Rc	>17.5

Maxilla (AlQahtani et al 2010)		Age in years
tooth	stage	combine sex
P1	Ac	>13.5
P2	Ac	>13.5

597

598 *Table 1: tooth formation stages and age estimation according to Moorrees et al (1963) and*

599 *AlQahtani et al (2010)*

600

	Right	Left
Os Coxae		
Ilium-Pubis	F	/
Upper Ischium-Pubis	/	/
Lower Ischium-Pubis	/	/
Iliac crest	F	F
Ischial Tuberosity	F	F
Anterior inferior iliac spine	/	TF
Sacrum		
Medial Sacral Segments 1_2	/	
Lateral Sacral Segments 1_2	/	/
Posterior Sacral Segments 1_2	/	/

Medial Sacral Segments 2_3	F	
Lateral Sacral Segments 2_3	/	F
Posterior Sacral Segments 2_3	/	/
Medial Sacral Segments 3_4	F	
Lateral Sacral Segments 3_4	/	F
Posterior Sacral Segments 3_4	/	/
Medial Sacral Segments 4_5	F	
Lateral Sacral Segments 4_5	/	/
Posterior Sacral Segments 4_5	/	/
Scapula-Clavicle		
Coracoid process	/	/
Acromion	/	/
Sternal End	NF	NF
Upper Limb		
Humerus Head	/	F
Humerus Medial Epicondyle	/	TF
Humerus distal End	/	/
Radius Proximal End	/	/
Radial Distal End	F	F
Ulna Proximal End	/	.
Ulna Distal End	F	F
Lower Limb		
Femur Head	/	TF
Femur Greater Trochanter	/	F
Femur Lesser Trochanter	/	F
Femur Distal End	TF	/
Tibia Proximal End	/	TF
Tibia Distal End	/	TF

Fibula proximal End	/	/
Fibula Distal End	F	/
Calcaneus Posterior End	F	F

601

602 Table 2: Maturation stages of Qafzeh 9 infracranial bones following parameters proposed by
603 Coqueugniot and Weaver (2007). NF: Non fused; F: Fusing; TF: Totally fused; /:
604 unobservable
605

Obs	PUM	SPU	DCOX	IIMT	ISMM	SCOX	SS	SA	Female probability	Male probability	SEX
Obs 1 original	62.80	28.00	201.00	33.33	101.15	155.00	78.41	78.82	0.001	0.999	Male
Obs 1 cast	61.30	26.60	201.00	34.80	101.50	155.00	78.90	78.40	0.001	0.999	Male
Obs 2	62.40	26.90	194.00	28.10	99.20	153.00	65.40	76.50	0.016	0.984	Male
Obs 3	59.00	23.40	197.00	36.00	97.00	155.00	78.00	73.00	0.026	0.974	Male
Obs 4	58.80	26.50	194.00	26.90	101.20		78.90	80.10	0	1	Male
Obs 5	57.94	25.30	192.00	38.84	104.50		76.70	79.80	0.001	0.999	Male
max	62.80	28.00	201.00	36.00	104.50	155.00	78.90	80.10	0	1	Male
min	57.94	23.40	192.00	26.90	99.20	153.00	65.40	76.50	0.007	0.993	Male

606

607 Table 3: Results of the DSP v2 achieved by five observers and inter-observer variation. Pelvic
608 variables are defined in Brůžek *et al* (2017). Abbreviations: PUM (M14)- Acetabulo-
609 symphyseal pubic length (Bräuer, 1988); SPU- Cotylo-pubic width (Gaillard, 1960); DCOX
610 (M1)- Innominate or coxal length (Bräuer, 1988); IIMT (M15.1)- Greater sciatic notch height
611 (Bräuer, 1988); ISMM- Ischium post-acetabular length (Schulter-Ellis et al., 1983); SCOX
612 (M12)- Iliac or coxal breadth (Bräuer, 1988); SS- Spino-sciatic length (Gaillard, 1960); SA-
613 Spino-auricular length (Gaillard, 1960); SIS (M14.1): Cotylo-sciatic breadth (Bräuer, 1988);
614 VEAC (M22): Vertical acetabular diameter (Bräuer, 1988)

615

	Klales et al. (2012), adults	Klales et al. (2017) non-adults
SPC (subpubic concavity)	4 (left) and 5 (right)	3
MA (medial aspect of the ischio-pubic ramus)	distorted	distorted
VA (ventral arc)	5	-
	Male	Male

616

617 *Table 4: Ordinal scores using the two Klales methods for adult and non-adult individuals*

618

discriminant equations	Results	Estimated sex
CM1 x 0.216-17.003	-0.371	F
CM3 x 0.471-12.259	0.5522	M
CM5 x 0.263-14.977	-0.3542	F
CM9 x 0.465-13.755	1.125	M
CM10 x 0.681-14.669	1.8112	M
CM3 x 0.219 + CM9 x 0.238 + CM10 x 0.297 - 19.260 (stepwise)	1.5002	M
CM1 x 0.020 + CM3 x 0.210 + CM5 x 0.032 + CM9 x 0.199 + CM10 x 0.265 - 20.568	1.2442	M
CM1 x 0.040 + CM3 x 0.207 + CM9 x 0.209 + CM10 x 0.267 - 20.528	1.3318	M
CM1 x 0.065 + CM3 x 0.235 + CM9 x 0.242 - 18.511	0.63	M
CM5 x 0.057 + CM9 x 0.302 + CM10 x 0.327 - 19.206	1.5406	M
CM9 x 0.348 + CM10 x 0.358 - 18.014	1.7856	M
M1 x 0.390-20.567	-0.521	F
M2 x 0.430-17.491	2.59	M
M4 x 0.533-17.620	-0.1376	F
M6 x 1.103-9.276	1.754	M
M9 x 0.249-8.021	-0.0032	F

M12 x 0.540-16.753	0.419	M
M13 x 0.687-14.629	2.1338	M
M1 x 0.177 + M6 x 0.279 + M12 x 0.226 + M13 x 0.210 - 23.155 (stepwise)	0.8333	M
M1 x 0.205 + M12 x 0.226 + M13 x 0.201 - 22.138	0.4082	M
M4 x 0.212 + M12 x 0.246 + M13 x 0.279 - 20.569	1.0574	M
M1 x 0.245 + M12 x 0.289 - 21.939	-0.2538	F
M6 x 0.476 + M13 x 0.623 - 17.265	2.4582	M
M6 x 0.418 + M12 x 0.497 - 18.934	0.8416	M

619

620 *Table 5: The discriminant equations of Alonso-Llamazares and Pablos (2019) applied to*
621 *Qafzeh 9 ankle. Talus and calcaneus measurements were defined by Martin and Saller (see*
622 *Braüer 1988).*

623

		13	13.5	14	14; 5	15	15; 5	16	16; 5	17	17.5	18	18.5	19	19.5	20	20.5	21	21.5	22	
dental age	upper premolars and lower teeth (1)																				
	lower teeth (2)																				
	upper premolars and lower teeth (3)																				
Bone maturation	Hand bones (4)																				
	long bones and pelvis (5)																				
	long bones and pelvis (6)																				
	ulna (distal end, fusing) (5)																				
	radius (distal end, fusing) (5)																				
	tibia (distal end complete fusion) (5)																				

624

625 *Table 6: Comparison of ranges of individual age estimates according to different methods (1-*
626 *AlQahtani et al. 2010; 2- Moorrees et al. 1963; 3- Esan 2017; 4- Birkner 1978; 5-*
627 *Coqueugniot and Weaver 2007; 6- Coqueugniot et al. 2018)*