



HAL
open science

SARS-CoV-2, polymyalgia rheumatica and giant cell arteritis: COVID19 vaccine shot as a trigger? Comment on: "Can SARS-CoV-2 trigger relapse of polymyalgia rheumatica?" by Manzo et al. Joint Bone Spine 2021;88:105150

Simon Cadiou, Aleth Perdriger, Samuel Ardois, Jean-David Albert, Olivia Berthoud, Alain Lescoat, Pascal Guggenbuhl, François Robin

► **To cite this version:**

Simon Cadiou, Aleth Perdriger, Samuel Ardois, Jean-David Albert, Olivia Berthoud, et al.. SARS-CoV-2, polymyalgia rheumatica and giant cell arteritis: COVID19 vaccine shot as a trigger? Comment on: "Can SARS-CoV-2 trigger relapse of polymyalgia rheumatica?" by Manzo et al. Joint Bone Spine 2021;88:105150. Joint Bone Spine, 2022, 89 (1), pp.105282. 10.1016/j.jbspin.2021.105282. hal-03368354

HAL Id: hal-03368354

<https://hal.science/hal-03368354v1>

Submitted on 26 Oct 2021

HAL is a multi-disciplinary open access archive for the deposit and dissemination of scientific research documents, whether they are published or not. The documents may come from teaching and research institutions in France or abroad, or from public or private research centers.

L'archive ouverte pluridisciplinaire **HAL**, est destinée au dépôt et à la diffusion de documents scientifiques de niveau recherche, publiés ou non, émanant des établissements d'enseignement et de recherche français ou étrangers, des laboratoires publics ou privés.



Distributed under a Creative Commons Attribution - NonCommercial 4.0 International License

SARS-CoV-2, polymyalgia rheumatica and giant cell arteritis: COVID19 vaccine shot as a trigger?

Comment on : "Can SARS-CoV-2 trigger relapse of polymyalgia rheumatica?" by Manzo et al. *Joint Bone Spine* 2021;88:105150

Simon Cadiou (1), Aleth Perdriger (1), Samuel Ardois (2), Jean-David Albert (1,3), Olivia Berthoud (1), Alain Lescoat (2,4), Pascal Guggenbuhl (1,3), François Robin (1,3).

(1) Univ Rennes, Department of Rheumatology, Rennes University Hospital, France.

(2) Univ Rennes, Department of Internal Medicine and Clinical Immunology, Rennes University Hospital, France.

(3) Univ Rennes, INSERM UMR 1241, INRA, 35000, Rennes, France. Institut NUMECAN (Nutrition Metabolisms and Cancer).

(4) Univ. Rennes, Inserm, EHESP, Irset (Institut de recherche en santé, environnement et travail) - UMR_S 1085, Rennes, France.

Corresponding author: Simon CADIOU, simon.cadiou@chu-rennes.fr, Hôpital Sud Rennes 16 Boulevard de Bulgarie, 35000 Rennes.

Keywords: SARS-CoV-2, COVID19, vaccine, polymyalgia rheumatica, giant cell arteritis

We read with high interest the article by Manzo et al. [1] about SARS-CoV-2 triggering polymyalgia rheumatica (PMR). SARS-CoV-2 triggering giant cell arteritis (GCA) have also been described [2]. Interleukin 6 (IL-6) is a key pathway in the pathogenesis of SARS-CoV-2 disease [3], PMR and [4] and IL-6 blockage has been used in all three diseases [3,4].

COVID-19 vaccine is crucial for patients, especially with chronic rheumatic diseases (CRD). There is only a few data on vaccine tolerance in these population, but recent reports showed reassuring [5-7] results with at least 85% of patient without flares after the first dose. However, data are scarce regarding COVID-19 vaccine and PMR or GCA. Here we report three cases of PMR and GCA developed soon after COVID-19 vaccine (fig 1).

The first patient was a 71-year-old man with grade 1 obesity, atrial fibrillation, bypass surgery and aortic bioprosthesis. Fourteen days after his first shot, he developed a mild pain in his left shoulder. One month later, he got his second shot. Pain was persistent, but CRP was normal. Slowly, pain worsened with involvement of both shoulders and morning stiffness lasting at least 2 hours. He also developed thigh, neck and lumbar pain. CRP increased at 55 mg/L. Shoulders ultrasound showed subdeltoid bursitis and biceps tenosynovitis. Thoraco-abdominal-pelvic computed tomography (TAP-CT) with injection did not show any carcinologic process or large vessel arteritis. Considering his clinical and biological presentation, the patient met the EULAR 2012 classification criteria of PMR (6 points) [8]. Prednisone was started at 15 mg/day, increased at 20 mg/day after 7 days (54% of improvement of PMR-AS) with good efficiency.

The second patient was a 70 year-old women with a PMR diagnosed in December 2019. One-year later, under 8 mg of prednisone per day, CRP was slightly increased at 10 mg/L without other symptom. She received her first and second shots on March 15 and June 8, respectively. About 10 days after the first shot, she developed an important fatigue and had high CRP levels at 104 mg/l. This systemic inflammation was not associated with typical symptoms of cephalic GCA. A positron emission tomography/computed tomography (PET-CT) showed large vessel vasculitis (fig 2). Prednisone at 40 mg/day was introduced. One month later, symptoms had decreased and CRP was at 15 mg/L

The last patient was a 74 year-old women with advanced ovarian cancer, stable since 2009. She was vaccinated on 11 May. She slowly developed headache in May 2021, *i.e.* 7 days after her shot. Gradually, headaches worsened and she developed jaw claudication. Biology showed elevated CRP at 190 mg/L. She was diagnosed with GCA based on the results of her temporal artery biopsy showing granuloma and fragmentation of the internal elastic lamina. Prednisone was initiated at 60 mg *per* day with improvement of clinical and biological features.

To our knowledge, these cases are the first cases of PMR or GCA diseases shortly developed after Covid 19 vaccination. A specific attention regarding signs of these CRD may be needed in post approval observational studies evaluating vaccine tolerance. The potential role of COVID19 vaccine in relapse of pre-existing PMR and ACG is yet to be determined.

Informed consent

Consent for publication of clinical details was obtained from patients.

Declaration of interest

The authors declare that they have no competing interest.

References

- [1] Manzo C, Castagna A, Ruotolo G. Can SARS-CoV-2 trigger relapse of polymyalgia rheumatica? *Joint Bone Spine* 2021;88:105150.
- [2] Riera-Martí N, Romani J, Calvet J. SARS-CoV-2 infection triggering a giant cell arteritis. *Med Clin (Engl Ed)* 2021;156:253–4.
- [3] Tharmarajah E, Buazon A, Patel V, Hannah JR, Adas M, Allen VB, et al. IL-6 inhibition in the treatment of COVID-19: A meta-analysis and meta-regression. *J Infect* 2021;82:178–85.
- [4] Spiera R, Unizony SH, Bao M, Luder Y, Han J, Pavlov A, et al. Tocilizumab vs placebo for the treatment of giant cell arteritis with polymyalgia rheumatica symptoms, cranial symptoms or both in a randomized trial. *Semin Arthritis Rheum* 2021;51:469–76.
- [5] Barbhaiya M, Levine JM, Bykerk VP, Jannat-Khah D, Mandl LA. Systemic rheumatic disease flares after SARS-CoV-2 vaccination among rheumatology outpatients in New York City. *Ann Rheum Dis* 2021:annrheumdis-2021-220732. <https://doi.org/10.1136/annrheumdis-2021-220732>.
- [6] Braun-Moscovici Y, Kaplan M, Braun M, Markovits D, Giryas S, Toledano K, et al. Disease activity and humoral response in patients with inflammatory rheumatic diseases after two doses of the Pfizer mRNA vaccine against SARS-CoV-2. *Ann Rheum Dis* 2021:annrheumdis-2021-220503. <https://doi.org/10.1136/annrheumdis-2021-220503>.
- [7] Cherian S, Paul A, Ahmed S, Alias B, Manoj M, Santhosh AK, et al. Safety of the ChAdOx1 nCoV-19 and the BBV152 vaccines in 724 patients with rheumatic diseases: a post-vaccination cross-sectional survey. *Rheumatol Int* 2021;41:1441–5.
- [8] Dasgupta B, Cimmino MA, Maradit-Kremers H, Schmidt WA, Schirmer M, Salvarani C, et al. 2012 provisional classification criteria for polymyalgia rheumatica: a European League Against Rheumatism/American College of Rheumatology collaborative initiative. *Ann Rheum Dis* 2012;71:484–92. <https://doi.org/10.1136/annrheumdis-2011-200329>.

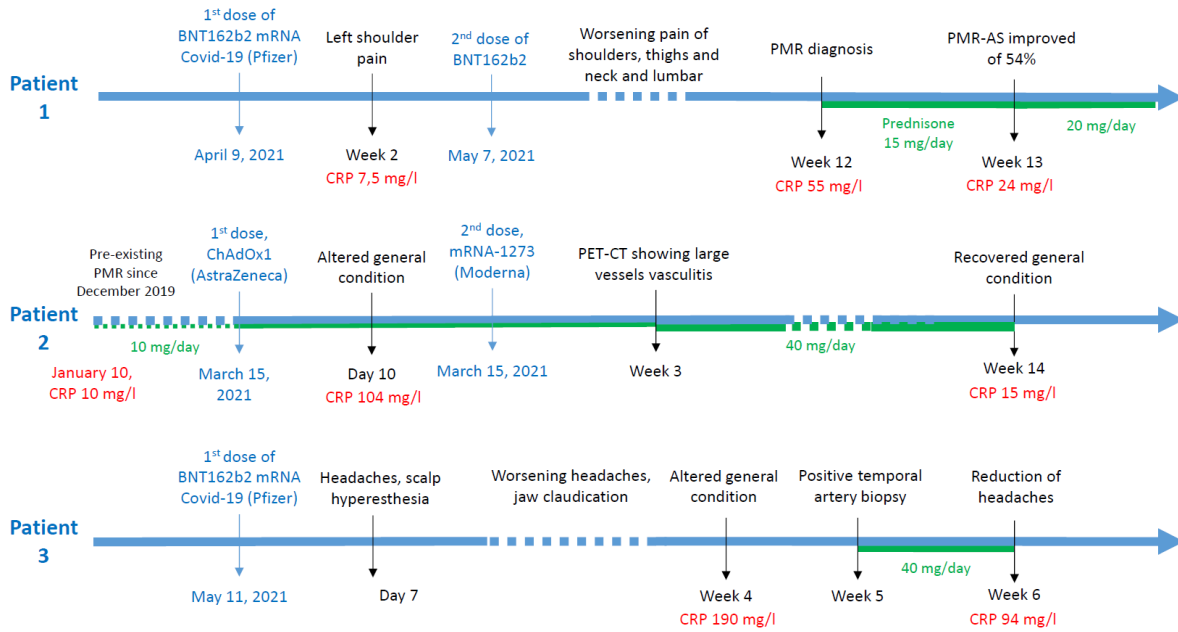


Figure 1. Patient's timelines of vaccines and PMR or GCA symptoms.

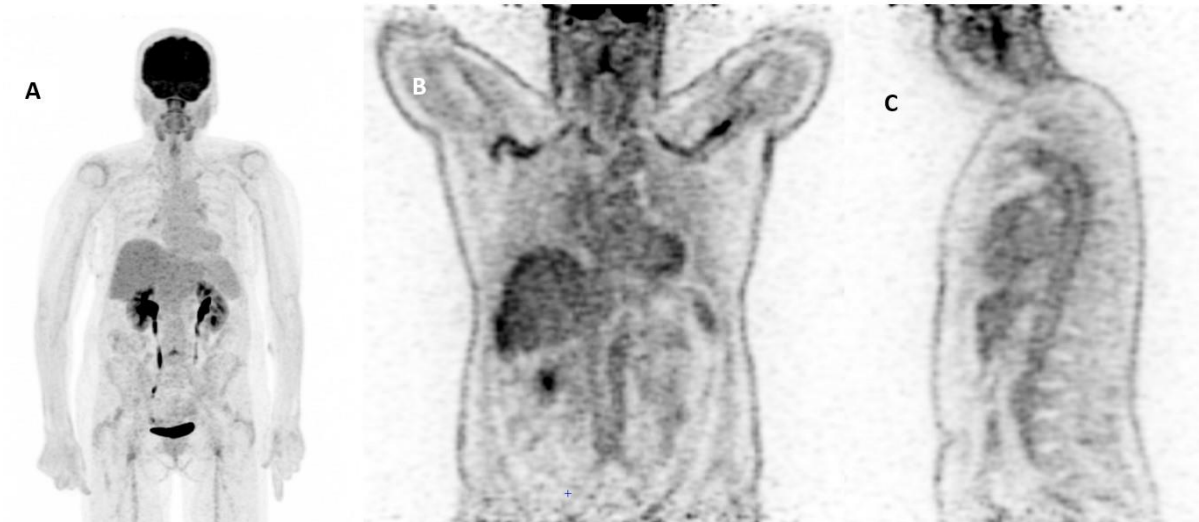

Figure 2. PET-CT of patient n°2

A: PET-CT at diagnosis in December 19, showing slight hypermetabolism of glenohumeral and coxofemoral joints without vascular hypermetabolism. **B and C:** PET-CT 2 years later and 23 days after her first dose of COVID19 vaccine, showing a panaortic and supra-aortic vasculitis.