



HAL
open science

Increased choroidal thickness: a new indicator for monitoring diabetic macular oedema recurrence

Thibaud Mathis, Maud Mendes, Corinne Dot, Victor Bouteleux, Zainab Machkour-Bentaleb, Hussam El Chehab, Emilie Agard, Philippe Denis, Laurent Kodjikian

► To cite this version:

Thibaud Mathis, Maud Mendes, Corinne Dot, Victor Bouteleux, Zainab Machkour-Bentaleb, et al.. Increased choroidal thickness: a new indicator for monitoring diabetic macular oedema recurrence. *Acta Ophthalmologica*, 2020, 98 (8), pp.E968-E974. 10.1111/aos.14447 . hal-03367371

HAL Id: hal-03367371

<https://hal.science/hal-03367371>

Submitted on 31 Jan 2023

HAL is a multi-disciplinary open access archive for the deposit and dissemination of scientific research documents, whether they are published or not. The documents may come from teaching and research institutions in France or abroad, or from public or private research centers.

L'archive ouverte pluridisciplinaire **HAL**, est destinée au dépôt et à la diffusion de documents scientifiques de niveau recherche, publiés ou non, émanant des établissements d'enseignement et de recherche français ou étrangers, des laboratoires publics ou privés.



Distributed under a Creative Commons Attribution 4.0 International License

Increased choroidal thickness: a new indicator for monitoring diabetic macular oedema recurrence

Thibaud Mathis,^{1,2}  Maud Mendes,^{1,3} Corinne Dot,^{3,4} Victor Bouteleux,^{1,3} Zainab Machkour-Bentaleb,¹ Hussam El Chehab,³  Emilie Agard,³  Philippe Denis¹ and Laurent Kodjikian^{1,2}

¹Service d'ophtalmologie, Hôpital de la Croix Rousse, Lyon, France

²UMR-CNRS 5510 Matéis, Villeurbanne, France

³Service d'ophtalmologie, Hôpital des Instructions des Armées de Desgenettes, Lyon, France

⁴Ecole du Val-de-Grâce, Paris, France

ABSTRACT.

Purpose: The aim of this study was to determine whether choroidal thickness (CT) increases at the time of exudative recurrence in diabetic patients with unilateral diabetic macular oedema (DME) treated with intravitreal injections of anti-VEGF or dexamethasone.

Methods: A real-life, prospective, two-centre study was conducted over a 9-month period investigating diabetic patients presenting with unilateral DME treated with anti-VEGF or dexamethasone intravitreal injections, and CT was measured manually, using the enhanced depth imaging module of the spectral domain optical coherence tomography. Choroidal thickness (CT) was measured in the morning, in both the affected and healthy eye of each patient at two timepoints: when the macula was 'dry' (T0) and at the time of exudative recurrence (T1).

Results: A total of 51 patients with unilateral DME were included. Mean CT in the affected eye was significantly thicker at the time of exudative recurrence ($210.8 \pm 44.1 \mu\text{m}$ at T0 versus $238.0 \pm 49.0 \mu\text{m}$ at T1, $p < 0.001$). There was no significant variation in CT in the fellow eye ($214.4 \pm 52.3 \mu\text{m}$ at T0 versus $218.9 \pm 53.4 \mu\text{m}$ at T1, $p = 0.53$). The type of intravitreal injection, the number of injections and the CT at T0 had no influence on the change in CT.

Conclusion: This study found that CT increased significantly in the affected eye at the time of recurrence of DME treated with anti-VEGF or dexamethasone injections. Choroidal thickness (CT) could constitute an interesting new indicator for monitoring patients with DME.

Key words: choroidal thickness – enhanced depth imaging – diabetic macular oedema – optical coherence tomography – recurrence

Introduction

Diabetic macular oedema (DME) is the main cause of visual impairment in diabetic patients. The treatment of diffuse DME is well-established and consists of managing systemic factors and treatment with intravitreal

injections (IVI) of anti-VEGF or dexamethasone (Kodjikian, Bellocq & Mathis 2018). Its pathophysiology is complex and multifactorial and is still not yet fully understood, although current data show it to be associated with diabetes and hypertension management as well as sleep apnoea

syndrome (Vié et al. 2019). The main underlying mechanism is the rupture of the blood–retinal barrier (BRB) partly caused by inflammatory mediators, VEGF, in particular, which results in diffuse hyperpermeability. As well as altering the retina, diabetic retinopathy (DR) also affects the choroid, a phenomenon termed 'diabetic chorioidopathy' (Yanoff 1969; Hidayat & Fine 1985; McLeod & Luty 1994; Luty, Cao & McLeod 1997; Cao et al. 1998). This is characterized by endothelial atrophy in the choriocapillaris, a reduction in choroidal blood flow, an increase in the tortuosity of the choroidal vessels with dilation and narrowing of the latter, the formation of sinus structures between lobes and areas of non-perfusion in the choriocapillaris, along with ghost vessels. The choroid has a dense vascular network and plays a vital role in the metabolic supply of the outer retina and in removing waste from the retinal pigment epithelium (RPE).

Spectral domain optical coherence tomography (SD-OCT) with enhanced depth imaging (EDI) is the first non-invasive, reproducible, high-resolution imaging technique capable of accurately analysing choroidal thickness (CT). The EDI module has made it possible to better understand the role played by the choroid in the pathogenesis of several chorioretinal diseases. Several studies have investigated CT analysis and demonstrated that CT is influenced by a number of factors: reduction with age (Margolis & Spaide

2009; Barteselli et al. 2012; Li, Yang & Dong 2012; Ho et al. 2013; Wei et al. 2013; Ruiz-Medrano et al. 2014), and negative correlations with axial length (Margolis & Spaide 2009; Barteselli et al. 2012; Tan et al. 2012; Wei et al. 2013). The choroid's precise role in the pathophysiology of DME remains unknown, but its potential involvement in DME has been discussed in a number of studies (Gerendas et al. 2014, Nickla & Wallman 2010, Querques et al. 2012, Unsal et al. 2014). To date, no studies have investigated transitory variations in CT at the time of exudative recurrence in patients with DME.

The main purpose of this study was to analyse CT and assess variations in CT at the time of exudative recurrence in diabetic patients with DME, treated with IVI.

Materials and Methods

Subjects and follow-up

A prospective, observational, two-centre study was conducted in routine practice at the Croix-Rousse University Hospital (Lyon, France) and the Desgenettes Military Hospital (Lyon, France), from October 2017 to July 2018. Diabetic patients receiving unilateral IVI to manage DME were identified in the medical databases of the two participating hospital units. Data for the subsequent statistical analysis were collected using Microsoft Excel (v15.31). An international review board approved the study (Ethics Committee of the French Society of Ophthalmology, IRB 00008855 Société Française d'Ophtalmologie IRB#1).

The inclusion criteria were as follows: patients aged over 18 years old with type 1 or type 2 diabetes with unilateral diffuse DME, treated with IVI of bevacizumab, ranibizumab, aflibercept or dexamethasone, IVI naive or non-naive, regardless of the treatment regimen (pro re nata (PRN) or treat and extend (TE)). Non-naive patients switched to a new treatment regimen were included 6 months after the switch to ensure the effects analysed resulted from the most recent molecule. The cross-sections obtained using SD-OCT in EDI mode had to be sufficiently high quality to allow for the accurate measurement of choroidal thickness and, in particular, the external limiting membrane had to be

visible. All patients had to have at least one episode defined as a time when the macula was dry (time T0) followed by a recurrence of fluid (time T1) in the affected eye. Dry macula was defined as the absence of cystoid macular oedema and exudative retinal detachment. Exudative recurrence was defined as the re-appearance of intraretinal spaces and/or subretinal fluid in the affected eye. It was therefore possible for one single patient to experience several episodes (T0-T1) over the 9-month follow-up period. Each patient was their own control, and the healthy (without DME) fellow eye constituted the control for the affected eye. Patients meeting one or more of the following criteria were excluded from the study: DME requiring bilateral treatment, patients with only one eye, proliferative diabetic retinopathy, high myopia (more than -6 dioptres and/or axial length of more than 26 mm), anisometropia of more than 3 dioptres, an associated retinal pathology, chronic glaucoma, glycosylated haemoglobin (HbA1c) over 12%, or hypertension over 160/95 mmHg, patients having undergone cataract surgery or vitrectomy within the last six months, patients with vitreomacular traction syndrome or an epiretinal membrane affecting the macula, prior laser treatment of the macula, patients having undergone panretinal photocoagulation or focal laser treatment within the last 4 months before inclusion and during the study.

For each patient, we took into account the relevant demographic data (age and sex), the type of diabetes, their diabetes management including HbA1c level, any insulin treatment, history of hypertension, presence of related diabetic retinopathy and the stage of the disease according to the American Academy of Ophthalmology classification, previous panretinal photocoagulation, phakic or pseudophakic status, the status of the vitreous (posterior vitreous detachment or not), DME laterality, the number of IVI on inclusion and when the macula was dry (time T0), the molecule administered by IVI and finally the patient's follow-up regimen. All patient consultations took place in the morning to eliminate as far as possible the bias of nycthemeral variations in CT. At each visit, visual acuity (ETDRS), intraocular pressure, fundus examination and SD-

OCT EDI mode of the macular area were performed for both eyes. Blood pressure was measured prior to SD-OCT using an automatic blood pressure monitor with an adapted cuff.

OCT and measurements of choroidal thickness

At each visit, a macular OCT scan was performed on both eyes using a Spectralis® SD-OCT device (Heidelberg Engineering, Heidelberg, Germany). The images were acquired in EDI mode, using the posterior pole pattern, that is 61 horizontal line B-scans at 120 μm intervals over a $30^\circ \times 25^\circ$ zone centred on the fovea. All the tomography images were acquired using follow-up mode which uses an eye-tracking system to ensure good reproducibility between the measurements taken on different visits. The measurements of CT were taken manually on the same B-scan cross-section passing through the fovea for each patient (thanks to the follow-up mode), using a cursor placed vertically from the external side of the hyper-reflective layer corresponding to the pigment epithelium-Bruch membrane complex and the external side of the choroidoscleral interface. Contrast and clarity were adjusted as required to visualize as clearly as possible the outer limits of the choroid.

Three CT measurements were taken in each eye: subfoveal; 1500 μm nasal; and 1500 μm temporal. Each measurement was made by two experienced, blinded examiners. The mean of the two measurements obtained in μm was used for the final statistical analysis. We compared mean CT in each eye between T0 and T1. Central retinal thickness (CRT) in the central 1000 μm was also taken into account as well as the presence of fluid.

Primary and secondary endpoints

The primary outcome endpoint was the variation in mean CT from T0 to T1, that is the variation in CT associated with exudative recurrence of DME. The first secondary endpoint assessed was the impact of repeat IVI on CT. This was done by monitoring changes in CT during dry periods (T0) in the same patient, according to the number of IVI received and the therapeutic class used for treatment (patients

treated by ranibizumab, aflibercept and bevacizumab were analysed as a whole versus dexamethasone-implant). We also investigated a possible correlation between the variation in CT in the affected eye and final visual acuity.

Statistical analysis

Paired *t*-tests were used to compare eye characteristics. The variation of choroidal thickness (VCT) variable corresponds to the variation in CT between T0 and T1. A univariate model was used to analyse CT at the two time-points. A paired Wilcoxon test was used to compare CT at the time of the first T0 or the first T1. Variation of choroidal thickness (VCT) was modelled using a mixed model taking into consideration the correlation between the values for the two eyes in each patient. The following factors were taken into consideration when modelling the variations in CT: the eye (affected or healthy); the treatment; and the total number of injections received. Correlations were assessed using Pearson's correlation coefficient and Spearman's rank correlation coefficient. The VCT logarithm (plus 13, to account for negative values) ($\log(VCT)$) was modelled to satisfy the conditions of normality of model residuals. The distribution was represented visually as scatter plots. When a patient had more than 1 episode, we have analysed the VCT for all episodes. We adjusted our results to the total number of IVI received and the type of treatment. All statistical analyses were conducted using the R-software environment. Quantitative variables were given as the mean and standard deviation and qualitative variables as percentages. The level of statistical significance was set at $p < 0.05$.

Results

Seventy diabetic patients had unilateral DME. Out of these 70 patients, 5 were lost to follow-up, 2 patients underwent cataract surgery, and 1 had a vitrectomy for tractional retinal detachment. For 4 patients, visualization of the choroid was poor on the OCT images obtained, and finally there was no T1 for 4 patients and no T0 for 3 patients. A total of 51 patients were therefore included in our study. Out of the 51 patients included, 44 patients had 1 episode (T0 then T1), 5

patients had 2 episodes and 2 patients had 3 episodes. A total of 60 episodes were analysed for 51 patients.

General patient characteristics

The mean age of patients was 68.3 ± 9.9 years (range: 40–87). Patients with type 2 diabetes represented 92.2% of the sample, and 80.4% of patients were insulin dependent. Mean glycated haemoglobin was $7.8 \pm 1.0\%$. The duration of DME was 2.6 ± 2.2 years. Out of the patients included, 72.5% had panretinal photocoagulation. The number of IVI prior to inclusion was 9.6 ± 7.1 injections and the number of IVI prior to the first T0 was 10.1 ± 7.05 injections. A total of 30 patients were treated with anti-VEGF (58.8%): 17 patients were treated with ranibizumab (33.1%), 13 patients with aflibercept (25.5%) and none with bevacizumab. Twenty-one patients were injected with dexamethasone (41.2%) (Table 1).

There was no significant difference between the affected eye and the fellow eye in terms of axial length ($p = 0.34$), intraocular pressure ($p = 0.79$) and CT at T0 ($p = 0.49$) (Table 2).

Choroidal thickness and exudative recurrence

The interobserver reproducibility of the manual measurements of CT was high, with a concordance correlation coefficient of 0.92 ($p < 0.001$). Mean CT in the affected eye was significantly thicker at the first T1 compared to the first T0 ($210.8 \pm 44.1 \mu\text{m}$ at T0 versus $238.0 \pm 49.0 \mu\text{m}$ at T1 $p < 0.001$). There was no significant change in mean CT in the fellow eye between the first T0 and the first T1 ($214.4 \pm 52.3 \mu\text{m}$ versus $218.9 \pm 53.4 \mu\text{m}$ $p = 0.53$) (Table 3). The variation in mean CT between T0 and T1 (VCT) was greater in the affected eye group ($25.1 \pm 21.7 \mu\text{m}$) than in the healthy eye ($3.8 \pm 19.6 \mu\text{m}$) (Figure 1). The

Table 1. Patient characteristics.

Characteristics	N = 51
Age (years)	68.3 (9.90)
Sex	
Male/Female (<i>n</i>)	20/31
Diabetes	
Type 1/Type 2 (<i>n</i>)	4 (7.8%)/47 (92.2%)
Insulin	
No/Yes (<i>n</i>)	10 (19.6%)/41 (80.4%)
HbA1c (%)	7.8 (1.05)
Duration of DME (years)	2.6 (2.2)
Type NPDR (<i>n</i>)	
Mild	5 (9.8%)
Moderate	7 (13.7%)
Severe	39 (76.5%)
PRP	
Yes/No (<i>n</i>)	37 (72.5%)/14 (27.5%)
Hypertension	
Yes/No (<i>n</i>)	39 (76.5%)/12 (23.5%)
Phakic/ pseudophakic (<i>n</i>)	30 (58.8%)/ 21 (41.2%)
Number of IVI prior to inclusion (<i>n</i>)	9.6 (7.1)
Number of IVI before the first T0 (<i>n</i>)	10.1 (7.05)
Type of IVI (<i>n</i>)	
Anti-VEGF	30 (58.8%)
Ranibizumab	17 (33.3%)
Aflibercept	13 (25.5%)
Dexamethasone	21 (41.2%)
Treatment protocol	
PRN/TE (<i>n</i>)	46 (90.2%)/5 (9.8%)
Laterality OD/OS (<i>n</i>)	23 (45.1%)/28 (54.9%)
Baseline visual acuity (ETDRS, SD)	64.1 (20.0)
Final visual acuity (ETDRS, SD)	69.6 (18.8)

Mean (standard deviation).

DME = Diabetic macular oedema, DR = Diabetic retinopathy, IVI = intravitreal injection, NPDR = Non-proliferative diabetic retinopathy, PRP = Pan retinal photocoagulation, PRN = Pro-Renata, TE = Treat and Extend.

Table 2. Comparison of eye characteristics.

Characteristics	Affected eye	Fellow eye	p-value
Axial length, mm	23.5 (1.0)	24.0 (1.0)	0.34
Intraocular pressure, mmHg	12.8 (2.1)	13.6 (3.3)	0.79
Choroidal thickness T0, μm			
Mean	210.8 (44.1)	214.4 (52.3)	0.49
Subfoveal thickness	224.6 (49.7)	225.5 (50.7)	0.06
1500 μm nasal	188.9 (51.2)	196.2 (60.7)	0.23
1500 μm temporal	218.9 (42.4)	221.3 (54.9)	0.55

Mean (standard deviation).

mixed model revealed a significant difference in $\log(\text{VCT})$ between the affected and the healthy eye ($p < 0.001$) for a comparable number of injections at T0, regardless of the molecule used for treatment (Table 4). There was no significant difference in $\log(\text{VCT})$ between IVI of dexamethasone or anti-VEGF, for a comparable number of IVI at T0 ($p = 0.45$)

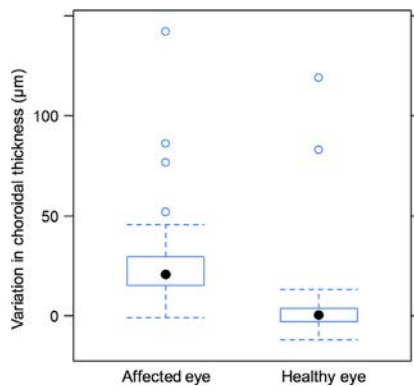


Fig. 1. Variation in choroidal thickness (VCT) at the time of recurrence compared to T0. VCT is greater in the affected eye than the fellow eye. The mixed model showed a significant difference in $\log(\text{VCT})$ between the affected and the healthy eye ($p < 0.001$).

(Figure 2). The number of IVI at T0 did not significantly affect VCT between T0 and T1 for the same eye (affected or healthy) in patients under the same treatment ($p = 0.35$) (Table 4). There was no significant correlation between the VCT and final visual acuity in the affected eye (Spearman's rank correlation: -0.13 , $p = 0.327$), nor between the VCT and the CT at the first T0 (Spearman's rank correlation: 0.08 , $p = 0.549$, Figure 3).

Correlation CT - IVI

Mean CT at the first T0 was $210.8 \pm 44.1 \mu\text{m}$ in the affected eye. Mean CT at the last T0 during follow-up was $208.4 \pm 57.4 \mu\text{m}$. This variation in CT between the first and the last T0 was significant ($p = 0.03$). No significant variation in CT was found during follow-up in the healthy eye ($214.4 \pm 52.3 \mu\text{m}$ versus $215.6 \pm 48.3 \mu\text{m}$, $p = 0.45$). The reduction in CT during treatment of the affected eye is significant regardless of the molecule injected: in the dexamethasone group, CT at the first T0 was $211.1 \pm 49.7 \mu\text{m}$ versus $207.1 \pm 49.7 \mu\text{m}$ at the last T0 ($p = 0.003$). The same was true in the

anti-VEGF group in which a significant reduction in CT was observed at the end of the study period: CT at the first T0 was $211.5 \pm 42.4 \mu\text{m}$, and CT at the last T0 was $207.4 \pm 49.3 \mu\text{m}$ ($p = 0.01$) (Table 5).

No correlation was found between CT at the first T0 and the number of IVI received by each patient prior to inclusion in the study ($r = 0.068$), nor was there any correlation between the variation in CT during follow-up and the number of IVI received during the study ($r = -0.0052$).

Discussion

This study shows a significant increase in CT in the affected eye at the time of exudative recurrence in patients treated with IVI for DME. At the same time, there is no significant change in CT in the healthy fellow eye. Ting et al. defined a significant variation in CT as a change of $16 \mu\text{m}$ or more (Ting et al. 2016), equivalent to 10 times the annual physiological thinning of the choroid ($1.56 \mu\text{m}/\text{an}$) (Margolis & Spaide 2009). Our finding of a mean thickening of $25 \mu\text{m}$ meets this significance threshold.

To our knowledge, this is the first study to find a variation in CT at the time of exudative recurrence in DME. Our hypothesis is that this is due to vascular hyperpermeability which plays a key role in the pathophysiology of DME. Indeed, in cases of DR the choroid is altered by diabetic choroidopathy characterized, in particular, by atrophy of the choriocapillaris (Yanoff 1969; Hidayat & Fine 1985; McLeod & Luty 1994; Luty, Cao & McLeod 1997; Cao et al. 1998) which could explain the reduction in CT found in these patients over time. In response to this degenerative mechanism, VEGF expression increases (Nagaoka et al. 2004). The latter, secreted on the basal side of the RPE, is required for the formation of choroidal vessels, to maintain the choriocapillaris and plays a key role in vascular hyperpermeability (Campos et al. 2017). VEGF receptors have been identified in the choriocapillaris and large diameter choroidal vessels (Saint-Geniez, Maldonado & D'Amore 2006). This VEGF-mediated vasodilation of the choroidal vessels could account for the thickening of the choroid at the time of recurrence. This would explain

Table 3. Choroidal thickness (CT) values at T0 and T1 in the affected and healthy fellow eyes.

Period	T0 N = 60	T1 N = 60	p-value
CT affected eye, μm			
Mean	210.8 (44.1)	238.0 (49.0)	<0.001 (Paired Wilcoxon)
Subfoveal thickness	224.6 (51.2)	254.9 (57.1)	<0.001
1500 μm nasal	188.9 (51.2)	217.8 (53.2)	<0.001
1500 μm temporal	218.9 (42.4)	241.3 (46.9)	<0.001
CT fellow eye, μm			
Mean	214.4 (52.3)	218.9 (53.4)	0.53 (Paired Wilcoxon)
Subfoveal thickness	225.5 (50.7)	230.9 (51.2)	0.32
1500 μm nasal	196.2 (60.7)	220.2 (52.5)	0.075
1500 μm temporal	221.3 (54.9)	205.6 (64.3)	0.076

Mean (standard deviation).

Table 4. Multivariate analysis of log VCT (variation of choroidal thickness) using a mixed model

	Coefficient	Std Error	p-value
Affected eye/fellow eye	0.996	0.092	<0.001
Treatment Ozurdex/anti-VEGF	-0.097	0.128	0.452
Number of injections	-0.008	0.009	0.353

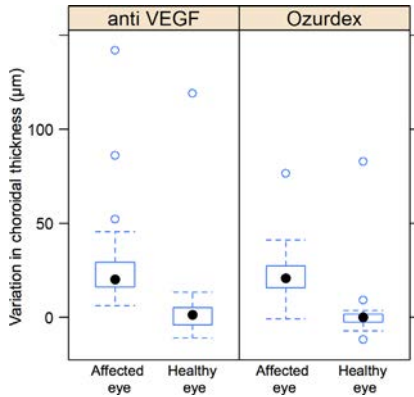


Fig. 2. Variation in choroidal thickness (VCT) at the time of recurrence compared to T0 according to type of intravitreal injection. The mixed model showed no significant difference in log(VCT) between IVI of dexamethasone or anti-VEGF, for a comparable number of IVI at T0 ($p = 0.45$).

the significant increase in CT found in our study in affected eyes at the time of exudative recurrence. Conversely, the absence of any alteration in VEGF expression in the healthy fellow eye could explain the absence of changes in CT.

Several studies have analysed CT using SD-OCT in EDI mode using comparable methodologies. These studies have shown that CT can be influenced by a number of factors: thinning with age (Margolis & Spaide

2009; Li, Yang & Dong 2012; Ho et al. 2013; Ho et al. 2013; Wei et al. 2013), axial length (Margolis & Spaide 2009; Barteselli et al. 2012; Tan et al. 2012; Wei et al. 2013), refractive power, high myopia (El Matri et al. 2013; Ho et al. 2013) and after panphotocoagulation laser treatment (Lee, Lim & Shin 2013, Okamoto, Matsuura & Ogata 2016, Regatieri et al. 2012, Unsal et al. 2014, Zhang et al. 2015). Anti-VEGF or dexamethasone IVI also induces a reduction in CT immediately after injection (Lains et al. 2014; Yiu et al. 2014; Rayess et al. 2015; Kim et al. 2016; Kniggendorf et al. 2016). In our study, the variation in CT was not affected by the number of IVI received and CT at the dry time did not correlate with the number of IVI received. This suggests that the reduction in CT immediately after treatment is linked to a return to normal levels of choroidal permeability under the action of the therapy and that these treatments are safe in terms of their impact on the choroid. Choroidal thickness is also subject to nyctemeral variations which were limited in our study as measurements were deliberately only taken in the morning for all patients (Tan et al. 2012; Usui et al. 2012). IOP and refractive power also correlate with CT but were controlled in our study by the patient selection criteria

and the requirement for comparable baseline characteristics in both eyes. Finally, the impact of hypertension on the choroid remains unclear (Tan et al. 2012; Usui et al. 2012; Akay et al. 2016).

The change in CT is still debating in patients with diabetes mellitus. Some authors described thicker choroid (Kim et al. 2013; Xu et al. 2013; Rewbury et al. 2016), while numerous other authors have reported thinner CT in case of DR (Esmaeelpour et al. 2011, Lee, Lim & Shin 2013, Querques et al. 2012, Regatieri et al. 2012, Ruiz-Medrano et al. 2014, Unsal et al. 2014, Vujosevic et al. 2012). This phenomenon is aggravated in cases of DME (Querques et al. 2012; Regatieri et al. 2012, Unsal et al. 2014) due to diabetic choroidopathy. Nonetheless, our study shows that the choroid in diabetic patients conserves its capacity for expansion, acting as a vascular reservoir, called on at the time of recurrence. The treatment molecule and the number of injections have no impact on the choroid's capacity for expansion. To assess the long-term effect of IVI on the choroid, we analysed the OCT B-scan slices from dry timepoints, which showed more clearly the outer limits of the choroid. We did not have access to baseline CT at the start of treatment (mean duration of follow-up 2.6 years prior to the study). However, we did observe a statistically significant thinning of the CT in the affected eye at the different T0 over the course of the prospective 9-month follow-up period. Although this does not seem clinically significant (5 µm) over a short 9-month period, this thinning can be explained in theory either by disease progression or the effect of the IVI

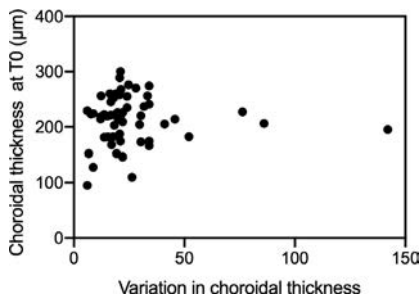


Fig. 3. Analysis of the relationship between the variation in choroidal thickness (VCT) and the choroidal thickness at the first T0 in the affected eye (Spearman's rank correlation: 0.08, $p = 0.549$).

Table 5. Comparison of the mean choroidal thickness (CT) measurements between the first T0 and last T0 during the 9-month follow-up period

Time	First T0	Last T0	p-value	IVI before inclusion	IVI during study
CT-treated eye (µm)	210.8 (44.1)	208.4 (57.4)	0.03	9.9 (7.1)	2.7 (1.3)
CT fellow eye (µm)	214.4 (52.3)	215.6 (48.3)	0.45		
Dexamethasone					
CT-treated eye (µm)	211.1 (49.7)	207.1 (49.7)	0.003	10.1 (7.1)	1.7 (0.7)
CT fellow eye (µm)	212.8 (54.8)	213.7 (52.8)	0.34		
Anti-VEGF					
CT-treated eye (µm)	211.5 (42.4)	207.4 (49.3)	0.01	9.70 (7.4)	3.4 (1.1)
CT fellow eye (µm)	219.0 (53.2)	217.0 (55.9)	0.53		

Mean (standard deviation).

Paired Wilcoxon test.

IVI = Intravitreal injection, VCT = Variation of choroidal thickness.

received, or by their combined effect. Baseline CT did not correlate to the number of IVI received prior to inclusion and the variation in CT during the study was not affected by the number of IVI. This suggests that the thinning is linked to the disease and that treatment with either anti-VEGF or DEX implants is safe.

Our study has a number of limitations linked to the small population size. We wanted each patient to serve as their own control in order to limit the numerous biases relating to CT, but as diabetic macular disease is often bilateral, this limited the number of patients eligible for inclusion. Moreover, many patients in our study received prior PRP before inclusion and it has been shown that subfoveal choroidal thickness may decrease after the PRP (Kim et al. 2013, Kim & Park 2020). To avoid any choroidal modifications associated with laser photocoagulation, we have excluded patients who underwent PRP and focal laser therapy within the last 4 months before inclusion and during the study. Patient follow-up was relatively short, lasting less than one year. However, this limited duration only affected the analysis of changes in CT over time, which was not the primary aim of this study. CT was measured manually, but this is the case in most studies in the literature. We had no access to an automatic analysis software program, but we observed a high level of reproducibility between the two blinded observers. The concordance correlation coefficient between measurements was 0.92 which is very good and demonstrates the relevance of our study. This finding concurs with several studies which have shown that manual measurements of CT are reproducible and have a good level of intra-observer repeatability with a high interobserver concordance correlation coefficient (Rahman et al. 2011; Chhablani et al. 2012; Shao et al. 2013; Karaca et al. 2014). Furthermore, one of the exclusion criteria for our study was the no or poor visualization of the external side of the choroidoscleral interface on OCT, which helped to avoid errors when measuring CT. Finally, although this was a prospective study it was also a real-life study, we were therefore only able to analyse changes in CT as an associated factor of exudative recurrence and not as a

predictive factor. It would be interesting to investigate this aspect further in future studies. We did not study whether the patient's baseline CT affected changes in CT between T0 and T1. We can assume that the higher the baseline CT, the greater the variation in CT at the time of exudative recurrence. Another recently published study (Bouteleux et al. 2019) demonstrated that the variation in CT at the time of recurrence in age-related macular degeneration (AMD) was lower (by around 10 μm), in choroids which were thinner at baseline. This supports this hypothesis but should be investigated in prospective studies on larger populations.

Conclusion

To our knowledge, this is the first study to demonstrate an increase in CT at the time of recurrence of DME. This increase only occurs in the affected eye, regardless of the type of treatment received. With the advances in OCT technology, monitoring CT could become a useful new indicator for inclusion in the follow-up of patients with DME.

References

Akay F, Gundogan FC, Yolcu U, Toyran S & Uzun S (2016): Choroidal thickness in systemic arterial hypertension. *Eur J Ophthalmol* **26**: 152–157.

Barteselli G, Chhablani J, El-Emam S et al. (2012): Choroidal volume variations with age, axial length, and sex in healthy subjects: a three-dimensional analysis. *Ophthalmology* **119**: 2572–2578.

Bouteleux V, Kodjikian L, Mendes M et al. (2019): Increased choroidal thickness: a new feature to monitor age-related macular degeneration recurrence. *Graefes Arch Clin Exp Ophthalmol Albrecht Von Graefes Arch Klin Exp Ophthalmol* **257**: 699–707.

Campos A, Campos EJ, Martins J, Ambrósio AF & Silva R (2017): Viewing the choroid: where we stand, challenges and contradictions in diabetic retinopathy and diabetic macular oedema. *Acta Ophthalmol (Copenh)* **95**: 446–459.

Cao J, McLeod S, Merges CA & Luty GA (1998): Choriocapillaris degeneration and related pathologic changes in human diabetic eyes. *Arch Ophthalmol Chic Ill* **116**: 589–597.

Chhablani J, Barteselli G, Wang H et al. (2012): Repeatability and reproducibility of manual choroidal volume measurements using enhanced depth imaging optical

coherence tomography. *Invest Ophthalmol Vis Sci* **53**: 2274–2280.

El Matri L, Bouladi M, Chebil A, Kort F, Lagueche L & Mghaieth F (2013): Macular choroidal thickness assessment with SD-OCT in high myopia with or without choroidal neovascularization. *J Fr Ophthalmol* **36**: 687–692.

Esmaeelpour M, Považay B, Hermann B et al. (2011): Mapping choroidal and retinal thickness variation in type 2 diabetes using three-dimensional 1060-nm optical coherence tomography. *Invest Ophthalmol Vis Sci* **52**: 5311–5316.

Gerendas BS, Waldstein SM, Simader C et al. (2014): Three-dimensional automated choroidal volume assessment on standard spectral-domain optical coherence tomography and correlation with the level of diabetic macular edema. *Am J Ophthalmol* **158**: 1039–1048.

Hidayat AA & Fine BS (1985): Diabetic choroidopathy. Light and electron microscopic observations of seven cases. *Ophthalmology* **92**: 512–522.

Ho M, Liu DTL, Chan VCK & Lam DSC (2013): Choroidal thickness measurement in myopic eyes by enhanced depth optical coherence tomography. *Ophthalmology* **120**: 1909–1914.

Karaca EE, Özdek Ş, Yalçın NG & Ekici F (2014): Reproducibility of choroidal thickness measurements in healthy Turkish subjects. *Eur J Ophthalmol* **24**: 202–208.

Kim JT, Lee DH, Joe SG, Kim J-G & Yoon YH (2013): Changes in choroidal thickness in relation to the severity of retinopathy and macular edema in type 2 diabetic patients. *Invest Ophthalmol Vis Sci* **54**: 3378–3384.

Kim M, Cho YJ, Lee CH & Lee SC (2016): Effect of intravitreal dexamethasone implant on retinal and choroidal thickness in refractory diabetic macular oedema after multiple anti-VEGF injections. *Eye Lond Engl* **30**: 718–725.

Kim JT & Park N (2020): Changes in choroidal vascular parameters following pan-retinal photocoagulation using swept-source optical coherence tomography. *Graefes Arch Clin Exp Ophthalmol Albrecht Von Graefes Arch Klin Exp Ophthalmol* **258**: 39–47.

Kniggenndorf VF, Novais EA, Kniggenndorf SL, Xavier C, Cole ED & Regatieri CV (2016): Effect of intravitreal anti-VEGF on choroidal thickness in patients with diabetic macular edema using spectral domain OCT. *Arq Bras Oftalmol* **79**: 155–158.

Kodjikian L, Bellocq D & Mathis T (2018): Pharmacological management of diabetic macular edema in real-life observational studies. *Bio Med Res Int* **2018**: 8289253.

Laíns I, Figueira J, Santos AR et al. (2014): Choroidal thickness in diabetic retinopathy: the influence of antiangiogenic therapy. *Retina* **34**: 1199–1207.

Lee HK, Lim JW & Shin MC (2013): Comparison of choroidal thickness in patients with diabetes by spectral-domain optical

- coherence tomography. *Korean J Ophthalmol* **27**: 433–439.
- Li L, Yang Z & Dong F (2012): Choroidal thickness in normal subjects measured by enhanced depth imaging optical coherence tomography. *Zhonghua Yan Ke Za Zhi Chin J Ophthalmol* **48**: 819–823.
- Lutty GA, Cao J & McLeod DS (1997): Relationship of polymorphonuclear leukocytes to capillary dropout in the human diabetic choroid. *Am J Pathol* **151**: 707–714.
- Margolis R & Spaide RF (2009): A pilot study of enhanced depth imaging optical coherence tomography of the choroid in normal eyes. *Am J Ophthalmol* **147**: 811–815.
- McLeod DS & Lutty GA (1994): High-resolution histologic analysis of the human choroidal vasculature. *Invest Ophthalmol Vis Sci* **35**: 3799–3811.
- Nagaoka T, Kitaya N, Sugawara R, Yokota H, Mori F, Hikichi T, Fujio N & Yoshida A (2004): Alteration of choroidal circulation in the foveal region in patients with type 2 diabetes. *Br J Ophthalmol* **88**: 1060–1063.
- Nickla DL & Wallman J (2010): The multifunctional choroid. *Prog Retin Eye Res* **29**: 144–168.
- Okamoto M, Matsuura T & Ogata N (2016): Effects of panretinal photocoagulation on choroidal thickness and choroidal blood flow in patients with severe nonproliferative diabetic retinopathy. *Retina* **36**: 805–811.
- Querques G, Lattanzio R, Querques L, Del Turco C, Forte R, Pierro L, Souied EH & Bandello F (2012): Enhanced depth imaging optical coherence tomography in type 2 diabetes. *Invest Ophthalmol Vis Sci* **53**: 6017–6024.
- Rahman W, Chen FK, Yeoh J, Patel P, Tufail A & Da Cruz L (2011): Repeatability of manual subfoveal choroidal thickness measurements in healthy subjects using the technique of enhanced depth imaging optical coherence tomography. *Invest Ophthalmol Vis Sci* **52**: 2267–2271.
- Rayess N, Rahimy E, Ying G-S, Bagheri N, Ho AC, Regillo CD, Vander JF & Hsu J (2015): Baseline choroidal thickness as a predictor for response to anti-vascular endothelial growth factor therapy in diabetic macular edema. *Am J Ophthalmol* **159**(85–91): e1–3.
- Regatieri CV, Branchini L, Carmody J, Fujimoto JG & Duker JS (2012): Choroidal thickness in patients with diabetic retinopathy analyzed by spectral-domain optical coherence tomography. *Retina* **32**: 563–568.
- Rewbury R, Want A, Varughese R & Chong V (2016): Subfoveal choroidal thickness in patients with diabetic retinopathy and diabetic macular oedema. *Eye Lond Engl* **30**: 1568–1572.
- Ruiz-Medrano J, Flores-Moreno I, Peña-García P, Montero JA, Duker JS & Ruiz-Moreno JM (2014): Macular choroidal thickness profile in a healthy population measured by swept-source optical coherence tomography. *Invest Ophthalmol Vis Sci* **55**: 3532–3542.
- Saint-Geniez M, Maldonado AE & D'Amore PA (2006): VEGF expression and receptor activation in the choroid during development and in the adult. *Invest Ophthalmol Vis Sci* **47**: 3135–3142.
- Shao L, Xu L, Chen CX et al. (2013): Reproducibility of subfoveal choroidal thickness measurements with enhanced depth imaging by spectral-domain optical coherence tomography. *Invest Ophthalmol Vis Sci* **54**: 230–233.
- Tan CS, Ouyang Y, Ruiz H & Sadda SR (2012): Diurnal variation of choroidal thickness in normal, healthy subjects measured by spectral domain optical coherence tomography. *Invest Ophthalmol Vis Sci* **53**: 261–266.
- Ting DSW, Ng WY, Ng SR et al. (2016): Choroidal thickness changes in age-related macular degeneration and polypoidal choroidal vasculopathy: a 12-month prospective study. *Am J Ophthalmol* **164**: 128–136.e1.
- Unsal E, Eltutar K, Zirtioğlu S, Dinçer N, Özdoğan Erkul S & Güngel H (2014): Choroidal thickness in patients with diabetic retinopathy. *Clin Ophthalmol Auckl NZ* **8**: 637–642.
- Usui S, Ikuno Y, Akiba M, Maruko I, Sekiryu T, Nishida K & Iida T (2012): Circadian changes in subfoveal choroidal thickness and the relationship with circulatory factors in healthy subjects. *Invest Ophthalmol Vis Sci* **53**: 2300–2307.
- Vié A-L, Kodjikian L, Agard E, Voirin N, El Chehab H, Denis P, Coste O & Dot C (2019): Evaluation of obstructive sleep apnea syndrome as a risk factor for diabetic macular edema in patients with type II diabetes. *Retina* **39**: 274–280.
- Vujosevic S, Martini F, Cavarzeran F, Pilotto E & Midena E (2012): Macular and peripapillary choroidal thickness in diabetic patients. *Retina* **32**: 1781–1790.
- Wei WB, Xu L, Jonas JB et al. (2013): Subfoveal choroidal thickness: the Beijing Eye Study. *Ophthalmology* **120**: 175–180.
- Xu J, Xu L, Du KF et al. (2013): Subfoveal choroidal thickness in diabetes and diabetic retinopathy. *Ophthalmology* **120**: 2023–2028.
- Yanoff M (1969): Ocular pathology of diabetes mellitus. *Am J Ophthalmol* **67**: 21–38.
- Yiu G, Manjunath V, Chiu SJ, Farsiu S & Mahmoud TH (2014): Effect of anti-vascular endothelial growth factor therapy on choroidal thickness in diabetic macular edema. *Am J Ophthalmol* **158**: 745–751.e2.
- Zhang Z, Meng X, Wu Z, Zou W, Zhang J, Zhu D, Chen T & Zhang Q (2015): Changes in choroidal thickness after panretinal photocoagulation for diabetic retinopathy: a 12-week longitudinal study. *Invest Ophthalmol Vis Sci* **56**: 2631–2638.