



HAL
open science

Left ventricular torsion obtained using equilibrated warping in patients with repaired Tetralogy of Fallot

Daniel Alexander Castellanos, Kateřina Škardová, Abhijit Bhattaru, Gerald Greil, Animesh Tandon, Jeanne Dillenbeck, Barbara Burkhardt, Tarique Hussain, Martin Genet, Radomir Chabiniok

► **To cite this version:**

Daniel Alexander Castellanos, Kateřina Škardová, Abhijit Bhattaru, Gerald Greil, Animesh Tandon, et al.. Left ventricular torsion obtained using equilibrated warping in patients with repaired Tetralogy of Fallot. SCMR 23rd Annual Scientific Sessions, 2020, Orlando, United States. hal-03364763

HAL Id: hal-03364763

<https://hal.science/hal-03364763>

Submitted on 4 Oct 2021

HAL is a multi-disciplinary open access archive for the deposit and dissemination of scientific research documents, whether they are published or not. The documents may come from teaching and research institutions in France or abroad, or from public or private research centers.

L'archive ouverte pluridisciplinaire **HAL**, est destinée au dépôt et à la diffusion de documents scientifiques de niveau recherche, publiés ou non, émanant des établissements d'enseignement et de recherche français ou étrangers, des laboratoires publics ou privés.

Title

Left ventricular torsion obtained using equilibrated warping in patients with repaired Tetralogy of Fallot

Authors

Daniel Alexander Castellanos MD¹

Kateřina Škardová MS²

Abhijit Bhattaru³

Gerald Greil MD PhD^{1,4}

Animesh Tandon MD^{1,4}

Jeanne Dillenbeck MD⁴

Barbara Burkhardt MD⁵

Tarique Hussain MD PhD^{1,4}

Martin Genet PhD^{6,7}

Radomir Chabiniok MD PhD^{6,7,8}

Institutions

¹Division of Pediatric Cardiology, Department of Pediatrics, University of Texas Southwestern Medical Center, Dallas, TX, USA.

²Department of Mathematics, Faculty of Nuclear Sciences and Physical Engineering, Czech Technical University in Prague, Prague, CZ

³The College of New Jersey, Ewing, NJ, USA

⁴Division of Pediatric Radiology, Department of Radiology, University of Texas Southwestern Medical Center, Dallas, TX, USA.

⁵Pediatric Heart Center, University Children's Hospital Zürich, Zürich, CH.

⁶Solid Mechanics Laboratory (LMS), École Polytechnique / CNRS / Polytechnic Institute of Paris, France

⁷Inria, Paris-Saclay University, France

⁸School of Biomedical Engineering & Imaging Sciences (BMEIS), St Thomas' Hospital, King's College London, United Kingdom

Category:

Congenital Heart Disease - Translational

Conflict of Interest: None

Character count: 2,957 (limit of 3,000, including spaces)

Images: Maximum of 3 with no word count penalty (.png or .jpg)

Tables: Maximum of 2 with no word count penalty

Images and Tables: Limited to a combined total of 3

Submission deadline: Tuesday, September 17, 2019 at 1:00 PM Eastern Daylight Time (EDT)

Background

Patients after surgical repair of Tetralogy of Fallot (rTOF) have right ventricular (RV) dysfunction and may subsequently suffer a decrease in left ventricular (LV) function. Previous studies evaluating the assessment of LV torsion in this group have shown poor reproducibility using cardiovascular magnetic resonance imaging (CMR) [1]. The aim of our study is to evaluate a novel finite element method of image registration to assess LV torsion in patients with rTOF

and explore the relationship between LV torsion and cardiac parameters routinely obtained with CMR.

Methods

The assessment of torsion is based on the finite element method for image registration, and the equilibrium gap principle for problem regularization, known as equilibrated warping [2–4]. It has been shown to be able to predict global torsion in regular cine images as well in 3D tagged images, despite low contrast [2]. Seventy-six cases of rTOF and ten controls were included. The group of control patients were assessed for reproducibility using equilibrated warping and standard tissue tracking software (cvi42, version 5.10.1, Calgary, Canada). RV end-systolic volume (RVESV), RV end-diastolic volume (RVEDV), RV ejection fraction (RVEF), LVESV, LVEDV, LVEF, LV peak systolic torsion and peak systolic torsion gradient (normalized by mesh length) were obtained for each patient with rTOF. Patients were dichotomized into two groups: those with normal torsion (systolic basal clockwise rotation and apical counterclockwise rotation, representative example is shown in **Image 1**) and those with loss of torsion, defined as a reversal of normal systolic basal clockwise rotation (representative example is shown in **Image 2**).

Results

Torsion by equilibrated warping was successfully obtained in 68 of 76 (89%) patients with rTOF and 9 of 10 (90%) normal controls. For equilibrated warping, the intra- and inter-observer coefficients of variation were 0.095 and 0.117, respectively; compared to 0.668 and 0.418 for tissue tracking by standard clinical software. The intra- and inter-observer intraclass correlation coefficients for equilibrated warping were 0.862 and 0.831, respectively; compared to 0.250 and 0.621 for tissue tracking. Loss of torsion was noted in 32 of the 68 (47%) patients with rTOF and there was a significant difference in peak systolic torsion gradient between patients with normal torsion and loss of torsion (**Table 1**). There was no difference in LV or RV volumes or function between these groups.

Conclusion

The equilibrated warping method of image registration to assess LV torsion is feasible in patients with rTOF and shows good reliability. Loss of torsion is common in patients with rTOF. In our study, there was no significant association between loss of torsion and other ventricular parameters indicative of a worsening cardiac condition. Future studies committed to the long-term follow-up of this population are needed to assess the role of torsion in predicting ventricular dysfunction and death.

References

1. Burkhardt BEU, Velasco Forte MN, Durairaj S, Rafiq I, Valverde I, Tandon A, et al. Timely Pulmonary Valve Replacement May Allow Preservation of Left Ventricular Circumferential Strain in Patients with Tetralogy of Fallot. *Front Pediatr.* 2017;5:39.
2. Genet M, Stoeck CT, von Deuster C, Lee LC, Kozerke S. Equilibrated warping: Finite element image registration with finite strain equilibrium gap regularization. *Med Image Anal.* 2018;50:1–22.
3. Lee LC, Genet M. Validation of Equilibrated Warping—Image Registration with Mechanical Regularization—On 3D Ultrasound Images. In: Coudière Y, Ozenne V, Vigmond E, Zemzemi

N, editors. Functional Imaging and Modeling of the Heart: FIMH 2019. Cham, Switzerland: Springer; 2019. p. 334–41.

4. Genet M. GENET Martin / dolfin_dic [Internet]. GitLab at INRIA. [cited 2019 Sep 10]. Available from: https://gitlab.inria.fr/mgenet/dolfin_dic

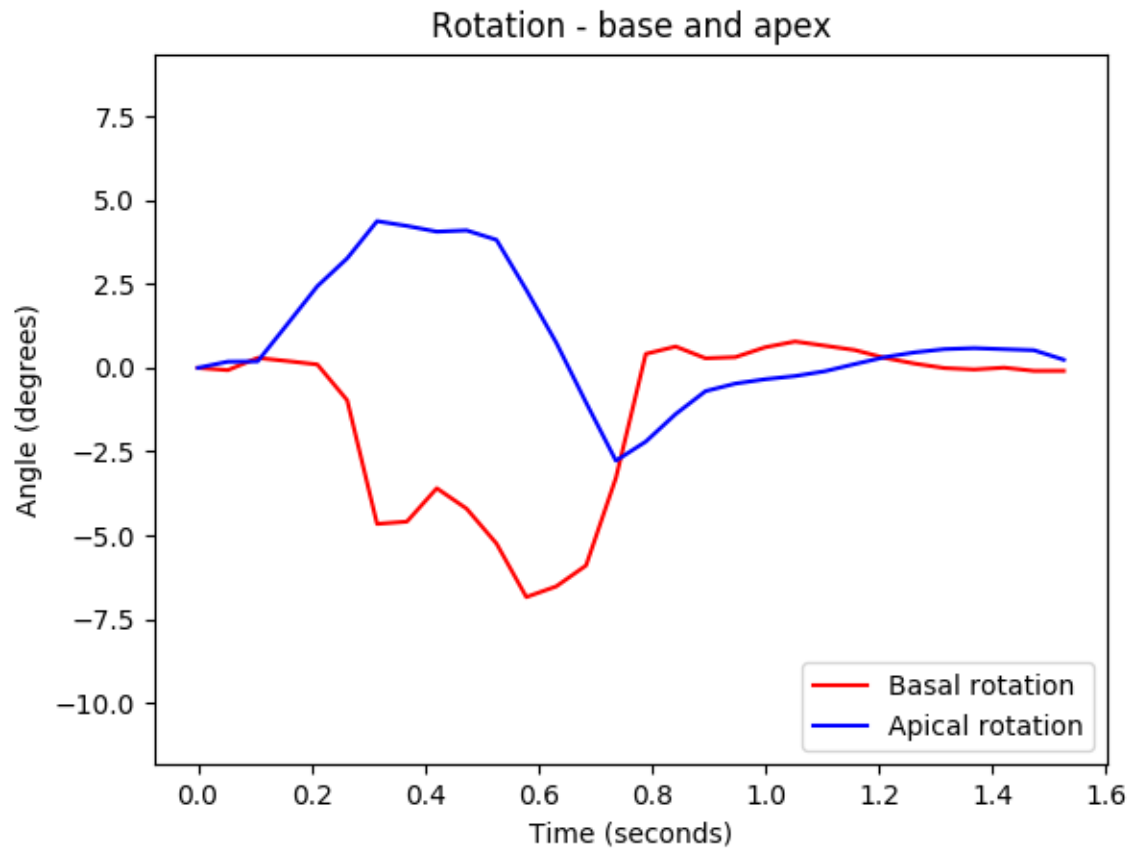


Image 1: An image depicting normal torsion in a patient with repaired Tetralogy of Fallot. The x-axis represents time (seconds) during the cardiac cycle and the y-axis represents torsion (degrees). During systole, the base undergoes clockwise rotation (negative values) while the apex undergoes counterclockwise rotation (positive values). Peak systolic torsion is 9.16 degrees and occurs at 0.32 seconds. When normalized to mesh length, the peak systolic torsion gradient is 0.12 degrees/cm.

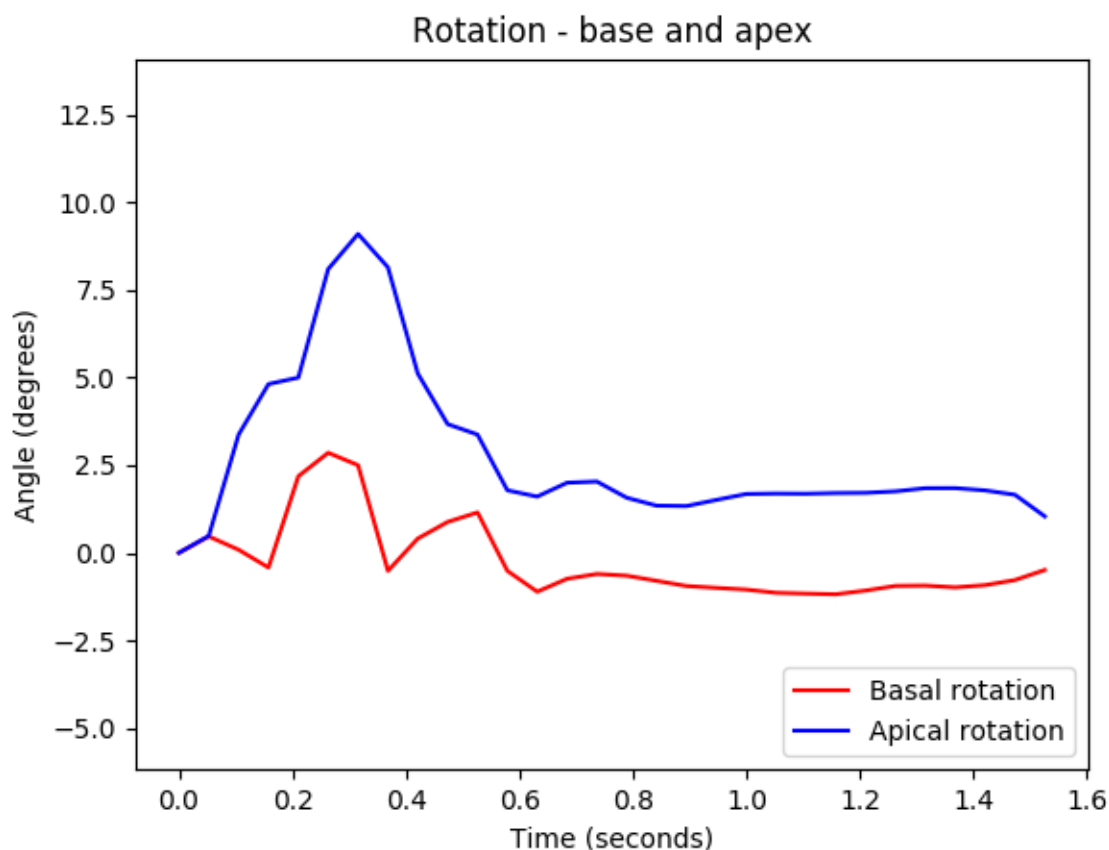


Image 2: An image depicting reversal of normal basal systolic rotation in a patient with repaired Tetralogy of Fallot. During systole, both the base and apex undergo counterclockwise rotation. Peak systolic torsion is 8.65 degrees and occurs at 0.36 seconds. When normalized to mesh length, the peak systolic torsion gradient is 0.10 degrees/cm.

Variable	Normal torsion (n=36)	Abnormal torsion (n=32)	P-value
Peak systolic torsion (degrees)	10.19 (3.82-23.60)	6.42 (1.71-17.19)	<0.001
Peak systolic torsion gradient (degrees/cm)	0.16 (0.06-0.35)	0.01 (-0.08-0.28)	<0.001
RVEDVi (ml/m ²)	135 +/- 36	134 +/- 37	0.880
RVESVi (ml/m ²)	66 (37-121)	68 (27-125)	0.731
RVEF (%)	47.6 +/- 6.8	49.2 +/- 8.3	0.367
LVEDVi (ml/m ²)	75 +/- 12	78 +/- 15	0.485
LVESVi (ml/m ²)	32 +/- 8	34 +/- 10	0.540
LVEF (%)	57 (49-68)	57 (41-72)	0.892
RVEDV:LVEDV	1.8 +/- 0.4	1.8 +/- 0.5	0.712

Normally distributed variables are reported as mean +/- standard deviation and non-normally distributed variables are reported as median (range).

Table 1: Characteristics of patients with rTOF with normal torsion and reversal of basal clockwise rotation (labeled abnormal torsion). RV= right ventricle, LV= left ventricle, ESVi=

end-systolic volume indexed to body surface area, EDVi= indexed end-diastolic volume, EF= ejection fraction.