



**HAL**  
open science

# Reversible widespread brain $^{18}\text{F}$ -FDG PET hypometabolism in chronic fatigue syndrome treated by hyperbaric oxygen therapy

E. Mairal, B. Barberon, N. Laine, M. Coulange, Eric Guedj

## ► To cite this version:

E. Mairal, B. Barberon, N. Laine, M. Coulange, Eric Guedj. Reversible widespread brain  $^{18}\text{F}$ -FDG PET hypometabolism in chronic fatigue syndrome treated by hyperbaric oxygen therapy. *European Journal of Nuclear Medicine and Molecular Imaging*, 2021, 48 (5), pp.1680-1681. 10.1007/s00259-020-05122-0 . hal-03364260

**HAL Id: hal-03364260**

**<https://hal.science/hal-03364260>**

Submitted on 13 May 2022

**HAL** is a multi-disciplinary open access archive for the deposit and dissemination of scientific research documents, whether they are published or not. The documents may come from teaching and research institutions in France or abroad, or from public or private research centers.

L'archive ouverte pluridisciplinaire **HAL**, est destinée au dépôt et à la diffusion de documents scientifiques de niveau recherche, publiés ou non, émanant des établissements d'enseignement et de recherche français ou étrangers, des laboratoires publics ou privés.



# Reversible widespread brain $^{18}\text{F}$ -FDG PET hypometabolism in chronic fatigue syndrome treated by hyperbaric oxygen therapy

E. Mairal<sup>1</sup> · B. Barberon<sup>2</sup> · N. Laine<sup>2</sup> · M. Coulange<sup>2</sup> · Eric Guedj<sup>3</sup>

Received: 18 October 2020 / Accepted: 15 November 2020  
© Springer-Verlag GmbH Germany, part of Springer Nature 2021

An indication of 50 sessions of hyperbaric oxygen therapy (HBOT) over a period of 6 weeks was retained in a 31-year-old man presenting with a chronic fatigue syndrome (CFS) evolving for 15 months with asthenia, memory complaints, dizziness, and muscle/joint pains. This CFS followed an EBV (Epstein-Barr virus) infectious mononucleosis.

Brain  $^{18}\text{F}$ -FDG PET/CT scans were performed before and after HBOT, using GE Discovery 710 camera, at resting state, after fasting of at least 4 h and checking of normal blood glucose, 30 min after intravenous injection of 110 MBq of  $^{18}\text{F}$ -FDG. Brain images are displayed using anatomical convention (the left hemisphere is on the left side), after metabolic normalization to the pons with a color scale ranged from 0 to 3 (3-fold the metabolism of the pons). Whole-brain voxel-based SPM analysis was used to compare the metabolism to 20 healthy subjects of the same age acquired locally in the same department with the same protocol (31.25 years  $\pm$  5.94, 21–41 years;  $p$ -voxel  $<$  0.001,  $k$ -cluster  $>$  85; metabolic normalization to the pons; clinical trial registration: NCT00484523).

Initial brain  $^{18}\text{F}$ -FDG PET/CT demonstrated widespread hypometabolism (A: axial slices; C: SPM 3D-rendered of brain hypometabolism), reversible after treatment (B: axial slices; D: SPM 3D-rendered of brain hypometabolism; E: axial slices of metabolic improvement of at least 5%), concomitant with an improvement of quality of life measured by SF-36 scale (the physical and mental functioning scales of the SF-36 were, respectively, of 70 and 69 after HBOT versus 57 and 48 initially), without hyperbaric complication. In more details, brain hypometabolisms initially involved bilateral cortex with a right-sided predominance, including the amygdala and hippocampus/parahippocampus regions, as well as the bilateral basal ganglia, thalamus, midbrain, and cerebellum, with persistence of the right opercular frontal and left cerebellar hypometabolisms after HBOT. This profile is mostly concordant with previous  $^{18}\text{F}$ -FDG reports in CFS patients identifying hypometabolisms in the frontal cortex [1, 2], and extensively in the posterior cortical regions (precuneus, parietal, temporal, and occipital), amygdala-hippocampal complexes, and cerebellum [3].

HBOT is suggested as a potential indication for several treatment-resistant functional brain disorders, such as CFS or fibromyalgia [4–6]. Increasing oxygen concentration and hyperbaric pressure is supposed to induce neuroplasticity, and consequently, to improve brain metabolism and glial function through also an anti-inflammatory effect [7].

This report exhibits brain PET hypometabolism as previously shown in CFS [1–3], and also in fibromyalgia [8], reversible after clinical improvement with possible positive impact of HBOT.

$^{18}\text{F}$ -FDG brain PET could be used as a metabolic biomarker to assess brain dysfunction in HBOT indications of functional disorders and evaluate therapeutic effects.

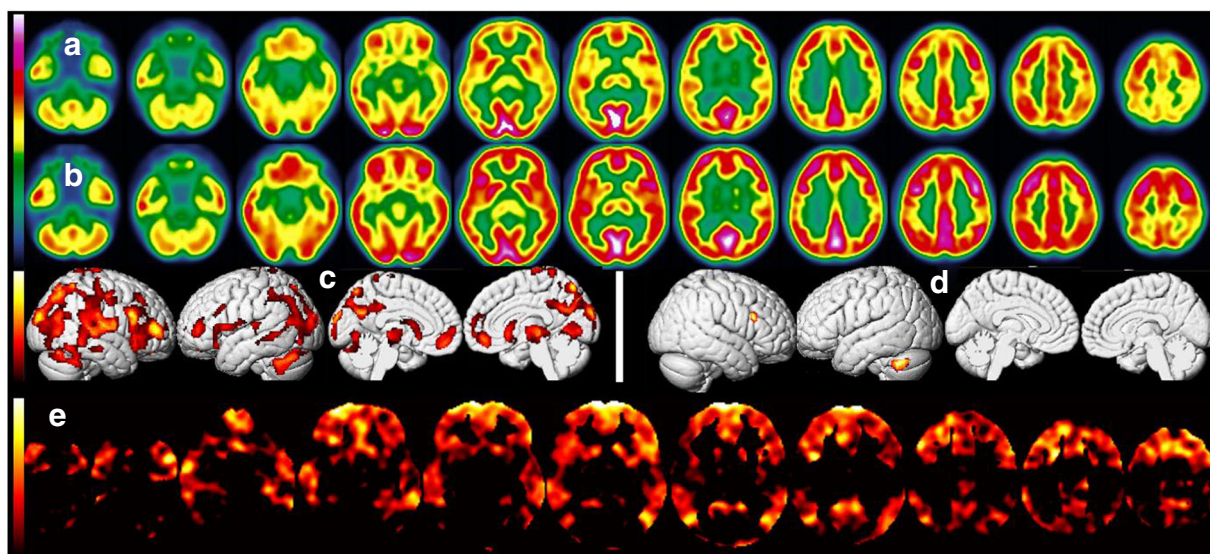
This article is part of the Topical Collection on Neurology

✉ Eric Guedj  
eric.guedj@ap-hm.fr

<sup>1</sup> Department of Nuclear Medicine and Nancyclotep Imaging Platform, CHRU Nancy, Université de Lorraine, 54000 Nancy, France

<sup>2</sup> APHM, INSERM 1263 - INRA 1260, TEAM V: Adenosinergic System and Cardiovascular Disease, Sainte-Marguerite Hospital, Marseille, Pôle RUSH, Hyperbaric Medicine Centre, Aix Marseille University, Marseille, France

<sup>3</sup> Aix Marseille Univ, APHM, CNRS, Centrale Marseille, Institut Fresnel, Timone Hospital, CERIMED, Nuclear Medicine Department, Marseille, France



**Funding** The local PET database of healthy controls was funded by APHM (regional PHRC; NCT00484523).

**Data availability** The PET data that support the findings are available from the corresponding author upon reasonable request.

### Compliance with ethical standards

**Conflict of interest** The authors declare that they have no conflict of interest.

**Ethics approval** The case report is a retrospective observation with no ethical approval requirement other than the informed written consent.

The local PET database of healthy controls was acquired in accordance with the Declaration of Helsinki, with informed written consent of patients and approval from “CPP Sud Méditerranée V” ethics committee.

**Consent to participate** Informed written consent was obtained from all individual participants included in the study.

**Consent for publication** Informed written consent was obtained from all individual participants included in the study.

**Code availability** Not applicable.

### References

1. Tirelli U, Chierichetti F, Tavio M, Simonelli C, Bianchin G, Zanco P, et al. Brain positron emission tomography (PET) in chronic fatigue syndrome: preliminary data. *Am J Med.* 1998;105:54S–8S. [https://doi.org/10.1016/s0002-9343\(98\)00179-x](https://doi.org/10.1016/s0002-9343(98)00179-x).
2. Siessmeier T, Nix WA, Hardt J, Schreckenberger M, Egle UT, Bartenstein P. Observer independent analysis of cerebral glucose metabolism in patients with chronic fatigue syndrome. *J Neurol Neurosurg Psychiatry.* 2003;74:922–8. <https://doi.org/10.1136/jnnp.74.7.922>.
3. Sahbai S, Kauv P, Abrivard M, Blanc-Durand P, Aoun-Sebati M, Emsen B, et al. Severe posterior hypometabolism but normal perfusion in a patient with chronic fatigue syndrome/myalgic encephalomyelitis revealed by PET/MRI. *Eur J Nucl Med Mol Imaging.* 2019;46:531–2. <https://doi.org/10.1007/s00259-018-4229-3>.
4. Efrati S, Golan H, Bechor Y, Faran Y, Daphna-Tekoah S, Sekler G, et al. Hyperbaric oxygen therapy can diminish fibromyalgia syndrome—prospective clinical trial. *PLoS One.* 2015;10:e0127012. <https://doi.org/10.1371/journal.pone.0127012>.
5. Akarsu S, Tekin L, Ay H, Carli AB, Tok F, Simsek K, et al. The efficacy of hyperbaric oxygen therapy in the management of chronic fatigue syndrome. *Undersea Hyperb Med.* 2013;40:197–200.
6. Yildiz S, Uzun G, Kiralp MZ. Hyperbaric oxygen therapy in chronic pain management. *Curr Pain Headache Rep.* 2006;10:95–100. <https://doi.org/10.1007/s11916-006-0019-x>.
7. Hui J, Zhang ZJ, Zhang X, Shen Y, Gao YJ. Repetitive hyperbaric oxygen treatment attenuates complete Freund's adjuvant-induced pain and reduces glia-mediated neuroinflammation in the spinal cord. *J Pain.* 2013;14:747–58. <https://doi.org/10.1016/j.jpain.2013.02.003>.
8. Guedj E, Cammilleri S, Niboyet J, Dupont P, Vidal E, Dropinski JP, et al. Clinical correlate of brain SPECT perfusion abnormalities in fibromyalgia. *J Nucl Med.* 2008;49:1798–803. <https://doi.org/10.2967/jnumed.108.053264>.

**Publisher's note** Springer Nature remains neutral with regard to jurisdictional claims in published maps and institutional affiliations.