



HAL
open science

Decrease in the cortex/striatum metabolic ratio on [18F]-FDG PET: a biomarker of autoimmune encephalitis

Nicolas de Leiris, Berangère Ruel, Jean Vervandier, José Boucraut, Stephan Grimaldi, Tatiana Horowitz, Jean Pelletier, Frederique Fluchere, Jacques-Yves Campion, Elsa Kaphan, et al.

► To cite this version:

Nicolas de Leiris, Berangère Ruel, Jean Vervandier, José Boucraut, Stephan Grimaldi, et al.. Decrease in the cortex/striatum metabolic ratio on [18F]-FDG PET: a biomarker of autoimmune encephalitis. *European Journal of Nuclear Medicine and Molecular Imaging*, 2021, 97 (8), pp.e836-e848. 10.1007/s00259-021-05507-9 . hal-03363845

HAL Id: hal-03363845

<https://hal.science/hal-03363845v1>

Submitted on 8 Jun 2022

HAL is a multi-disciplinary open access archive for the deposit and dissemination of scientific research documents, whether they are published or not. The documents may come from teaching and research institutions in France or abroad, or from public or private research centers.

L'archive ouverte pluridisciplinaire **HAL**, est destinée au dépôt et à la diffusion de documents scientifiques de niveau recherche, publiés ou non, émanant des établissements d'enseignement et de recherche français ou étrangers, des laboratoires publics ou privés.

Decrease in the cortex/striatum metabolic ratio on ¹⁸F-FDG PET: a biomarker of autoimmune encephalitis

De Leiris Nicolas, MD^{1,2}; Ruel Berangère, MD³; Vervandier Jean, MD¹; Boucraut José, MD, PhD⁴; Grimaldi Stephan, MD, MSc⁵; Horowitz Tatiana, MD⁶; Pelletier Jean, MD, PhD³; Fluchere Frederique, MD⁵; Jacques-Yves Campion, MSc⁶; Alzheimer's Disease Neuroimaging Initiative; Kaphan Elsa MD³; Guedj Eric MD, PhD⁶

1 Nuclear Medicine department, Grenoble Alpes University Hospital, Grenoble, France

2 Univ. Grenoble Alpes, INSERM, Laboratoire Radiopharmaceutiques Biocliniques, 38000 Grenoble, France

3 Aix Marseille Univ, APHM, Hôpital de la Timone, Pôle de Neurosciences Cliniques, Service de Neurologie, 13005 Marseille, France

4 Aix Marseille University, CNRS, AP-HM, INT, Immunology laboratory, Marseille, France

5 Aix-Marseille Univ, APHM, CHU Timone, Department of Neurology and Movement Disorders, 13385 Marseille Cedex 05, France.

6 Aix Marseille Univ, APHM, CNRS, Centrale Marseille, Institut Fresnel, Timone Hospital, CERIMED, Nuclear Medicine Department, Marseille, France

Corresponding author:

Pr Eric Guedj, Service Central de Biophysique et Médecine Nucléaire, Hôpital de la Timone, APHM, 13005 Marseille, France.

Tel: (+33) 4 91 38 55 58 Fax (+33) 4 91 38 47 69

E-mail: eric.guedj@ap-hm.fr

The authors have no funding source and no conflict of interest to disclose.

Word count: 6,611 words

Abstract

Purpose: The aim of this ^{18}F -FDG PET study was to determine the diagnostic value of the cortex/striatum metabolic ratio in a large cohort of patients suffering from autoimmune encephalitis (AE) and to search for correlations with the course of the disease.

Methods: We retrospectively collected clinical and paraclinical data of patients with AE, including brain ^{18}F -FDG PET/CT. Whole-brain statistical analysis was performed using SPM8 software after activity parametrization to the striatum in comparison to healthy subjects. The discriminative performance of this metabolic ratio was evaluated in patients with AE using receiver operating characteristic curves against 44 healthy subjects and a control group of 688 patients with MCI. Relationship between cortex/striatum metabolic ratios and clinical/paraclinical data was assessed using univariate and multivariate analysis.

Results: Fifty-six patients with AE were included. In comparison to healthy subjects, voxel-based statistical analysis identified one large cluster (p -cluster <0.05 , FWE corrected) of widespread decreased cortex/striatum ratio in patients with AE. The mean metabolic ratio was significantly lower for AE patients (1.16 ± 0.13) than for healthy subjects (1.39 ± 0.08 ; $p < 0.001$) and than for MCI patients (1.32 ± 0.11 ; $p < 0.001$). A ratio threshold of 1.23 allowed to detect AE patients with a sensitivity of 71 %, and a specificity of 82% against MCI patients and 98% against healthy subjects. A lower cortex/striatum metabolic ratio had a trend towards shorter delay before ^{18}F -FDG PET/CT ($p = 0.07$) in multivariate analysis.

Conclusion: The decrease in the cortex/striatal metabolic ratio has a good early diagnostic performance for the differentiation of AE patients from controls.

Key words: Encephalitis; ^{18}F -FDG PET/CT; statistical parametric mapping; biomarker; inflammation; MCI

Introduction

Autoimmune encephalitis (AE) is a rare and complex condition consisting of severe inflammatory brain damage caused by autoantibodies targeting intracellular or cell-surface antigens. AE is clinically characterized by the subacute onset of various unspecific symptoms such as confusion, behavioural changes, psychiatric troubles, short-term memory loss and seizures [1]. Such symptoms may, however, overlap with those of other disorders.

There is a need to identify accurate biomarkers allowing the diagnosis of AE as the early initiation of immunosuppressive treatment is associated with improved outcomes [2–4].

AE diagnosis currently relies on a set of arguments based on clinical symptoms, standard diagnostic tests (brain imaging, cerebrospinal fluid (CSF) analysis) and autoantibody testing. This diagnosis remains challenging because of polymorphic clinical presentations and limitations of usual additional tests [5]. The collection of antibody results may be delayed for several weeks, thereby impairing the early initiation of treatment. Moreover, although many antibodies have been increasingly identified as associated with AE, many cases of genuine AE, estimated at approximately 50% [6], remain seronegative without detected antibodies. In addition, the CSF white blood cell count and protein level are within the normal range in up to 20% of patients with AE [7,8].

Brain magnetic resonance imaging (MRI) is the most widely used imaging modality for AE diagnosis, typically showing T2-FLAIR hyperintensity of medial temporal lobes [9]. However, it has been shown that a significant proportion of patients - for example, 70% of patients with anti-NMDAR antibody encephalitis - have normal brain MRI or non-specific abnormalities [1].

[18F]Fluorodeoxyglucose positron emission tomography/computed tomography (^{18}F -FDG PET/CT) could be a valuable biomarker of suspected AE [10,11]. While whole-body ^{18}F -FDG PET/CT is often performed to detect occult malignancies [12], brain ^{18}F -FDG PET/CT can also support the diagnosis of AE by providing information on synaptic activity. According to the currently available diagnostic criteria by Graus et al. [5], three levels of evidence exist in the initial diagnosis workup, i.e., possible, probable and definite AE. In this context, the role of ^{18}F -FDG PET/CT is limited to the diagnosis of definite AE through the evidence of bilateral medial temporal hypermetabolism, as an alternative to cerebral MRI, with no contribution of ^{18}F -FDG PET/CT for the definition of possible or probable AE, and, as mentioned, only limbic metabolic anomalies are considered. In clinical practice, the Graus criteria seem to lack sensitivity and to be too narrow to allow the diagnosis of all AE whose spectrum no longer relates only to limbic encephalitis [13,14].

Several studies have nevertheless addressed the role of ^{18}F -FDG PET/CT in the early diagnosis process of suspected AE, with also a recent meta-analysis [15], suggesting that ^{18}F -FDG PET/CT is more sensitive for this purpose than brain MRI [16]. Indeed, hypometabolism or hypermetabolism is observed in patients with normal MRI [17–19], as well as extra-limbic PET abnormalities [16]. These previous studies highlighted distinct ^{18}F -FDG PET/CT patterns in AE patients, including medial temporal and striatal hypermetabolism contrasting with diffuse cortical hypometabolism [20–24]. However, these previous studies included a substantial proportion of case reports [25–31] and were mostly limited to the identification of specific autoantibodies [21,32,33]. Above all, the methodology used for brain PET analysis in this issue is highly heterogeneous and hampered by several considerations: reduced spatial resolution of brain data extracted from whole-body ^{18}F -FDG PET/CT [34,35], lack of reproducibility of visual interpretation, and absence of standards for semi-quantitative analyses [36–38]; methods for intensity normalization are especially variable. Whereas some authors performed a standardization on global cerebral activity (i.e., proportional scaling) [32,34,35], others normalized to a supposedly preserved region of interest (for example the pons), which is always difficult to select in cases of encephalic impairment [39]; finally, the method used is not specified in some studies [33,40]. In this context, larger cohort studies of patients suspected of AE are required, along with the standardization of ^{18}F -FDG PET/CT interpretation based on reproducible and efficient biomarkers to clarify the potential role of ^{18}F -FDG PET/CT in the diagnosis of AE [16].

Since absolute quantification is inappropriate in this clinical setting, the choice of intensity normalization method appears to be a crucial step for the semi-quantitative analysis, with a potential impact on the sensitivity and specificity of obtained results. Semi-quantitative analyses have been successfully applied in neurodegenerative disorders such as Alzheimer's disease, where biomarkers correspond to hypometabolism, by proportional scaling or intensity normalization on a preserved reference region such as the cerebellum or the pons. Nevertheless, in patients with abnormally low cerebral glucose metabolic rates, the proportional scaling method has shown limitations, underestimating the extent of hypometabolic areas and falsely identifying 'hypermetabolism' corresponding to brain regions that were best metabolically preserved [41]. As mentioned, intensity normalization is therefore alternatively performed on regions known to be preserved in this disease (e.g., the pons or the sensory-motor cortex) [42,43]. In the context of AE, this method of normalization cannot be applied because diffuse hypometabolism coexists with regional hypermetabolism. Specifically, few reports have suggested that the increase in the metabolic ratio between the striata and the cortex was a potential biomarker of AE [23]. To overcome the methodological limitation of activity normalization in this population, we thus suggest

dividing brain metabolism by those of the striatum to obtain parametric images, assuming that the metabolic ratio of cortex/striatum would be decreased in patients in comparison to controls.

Therefore, the aim of this study was to determine the diagnostic value of this ^{18}F -FDG PET/CT cortex/striatum metabolic biomarker in a large cohort of patients suffering from AE, in comparison to healthy subjects and additionally in comparison to a control group of patients with MCI, and to search for clinical/paraclinical correlations with the course of the disease.

Materials and methods

Study design and patients:

We conducted a single-centre retrospective study at Timone Hospital, Marseille, since 2011. This research project retrospectively includes data acquired in clinical settings after information of patients and absence of opposition (MR-004 French research type).

Patients had subacute onset of neurological (anterograde memory disorders, confusion for more than 24 hours, unexplained inaugural seizure, unexplained vigilance disorders, subacute cerebellar syndrome, unexplained dysautonomia or abnormal movements), or psychiatric symptoms (disturbances in behaviour, mood or character, psychosis or hallucinations) with atypia (lack of sensitivity or poor tolerance to psychotropic treatment, occurrence of catatonia, visual hallucinations, presence of associated somatic or neurological symptoms). AE cases were identified as those meeting Graus' criteria. A complete clinical and paraclinical evaluation, including a lumbar puncture, an autoantibody test, a brain MRI and a brain ^{18}F -FDG PET/CT, was also required for inclusion. Brain MRI were interpreted by expert neuroradiologist in clinical settings, and were considered positive when a bilateral temporal T2 FLAIR hypersignal was identified according to Graus' criteria. The data concerning the population (age, sex), associated neoplasia, clinical symptoms, cerebrospinal fluid analysis (cellularity, proteinorrhachia, intrathecal immunoglobulin synthesis), autoantibody testing in the serum and CSF, brain MRI, brain ^{18}F -FDG PET/CT, treatments and clinical evolution, the delay as expressed in months between the onset of symptoms and positive diagnostic of encephalitis (also corresponding to the delay between the onset of symptoms and the ^{18}F -FDG PET/CT) were collected for all patients using our institution database. Patients were excluded if an alternative aetiology was identified, such as herpetic encephalitis, Gayet-Wernicke encephalopathy, neurodegenerative disease or focal brain lesion. Patients for which ^{18}F -FDG PET/CT was required for the positive diagnostic of encephalitis were also excluded. In details, on the 89 patients initially identified on clinical criteria, 14 patients didn't meet Graus' criteria, 3 were excluded because the diagnostic

criteria #2 from Graus' criteria was only supported by ^{18}F -FDG PET/CT data, 3 were excluded because of lack of CSF results, and 13 in absence of ^{18}F -FDG PET/CT. The final cohort included 56 patients.

^{18}F -FDG PET/CT

^{18}F -FDG PET/CT was performed for each patient during hospitalization at time of positive diagnostic and before the initiation of treatment. Dedicated ^{18}F -FDG brain PET scans were acquired at the same center with an acquisition protocol conforming to European guidelines; the measurements were performed in a resting state after at least 4 hours of fasting with control of normal glycaemic levels. An integrated PET/CT General Electric camera (Waukesha, WI) was used, and ^{18}F -FDG was administered intravenously at 3 MBq/Kg per 15 min acquisition, with each acquisition beginning at 30 to 40 min post-injection. All included patients had also a whole-body ^{18}F -FDG PET/CT in addition to the brain PET to search a paraneoplastic origin. Images were reconstructed on a 192×192 matrix using the ordered subset expectation maximization algorithm and corrected for attenuation using a CT transmission scan.

Thereafter, whole-brain statistical analysis was performed at the voxel level using SPM8 software (Wellcome Department of Cognitive Neurology, University College, London, UK). The PET images were spatially normalized to the Montreal Neurological Institute (MNI) atlas. The dimensions of the resulting voxels were $2 \times 2 \times 2$ mm. The images were smoothed with a Gaussian filter (8 mm full width at half-maximum) to blur individual variations in gyral anatomy and to increase the signal-to-noise ratio. As mentioned, the limitations of normalization methods for the efficient detection of diffuse hypometabolism associated with regional hypermetabolism have thus led to the evaluation of the activity parameterization to the striata to improve the discrimination of AE patients from controls. This choice was based on the demonstration of a decreased cortex/striatum ratio in previous studies [23] with the hypothesis that encephalitis is indeed characterized by striatal hypermetabolism and cortical hypometabolism, and that the ratio of these two variables could have a diagnostic value. The individual bilateral striatal value was obtained for each subject using the "Anatomical ROIs (regions of interest) Analysis" toolbox of SPM, allowing the automatic extraction of the labelled region mean value from the Anatomical Automatic Labeling (AAL) atlas [44].

This data set was compared to that of two control groups. The first control group included 44 healthy subjects from a local database of normal ^{18}F -FDG PET/CT previously acquired under the same technical conditions, comparable in age and sex to our sample of patients with AE ($p > 0.05$, 24 women (54%), median age 56 years, range 35-78 years). These individuals were free of neurologic and psychiatric disease and had normal brain MRI.

The second control group was a group of MCI (mild cognitive impairment) patients from Alzheimer's Disease Neuroimaging Initiative (ADNI) study, and included 688 patients (277 women (40%), median age 73 years, range 55-91 years, median MMSE 28, with range 16-30).

Whole-brain group analysis (two-sample t-test) was performed to evaluate the ^{18}F -FDG PET/CT metabolic ratio in AE patients in comparison to healthy subjects. The threshold was set at $p < 0.05$, FWE (family-wise error) corrected for multiple comparisons, for the voxel and for the cluster. The metabolic ratio of found cluster was extracted for each AE patients and controls, using MarsBaR (<http://marsbar.sourceforge.net/>)

Statistical analysis

Continuous variables are reported as means and interquartile ranges (IQRs) or as medians and ranges (min, max), and categorical variables are reported as frequencies and percentages. Differences in mean values were tested with Wilcoxon – Mann Whitney test. The performance of the metabolic ratio for the differentiation of AE patients from controls was assessed using the receiver operating characteristic (ROC) curve allowing the calculation of the area under the curve (AUC) and to identify an optimal threshold based on sensitivity and specificity. The relationship between the metabolic ratio and clinical or paraclinical data was assessed by Spearman's correlation coefficient for quantitative variables (age, delay between the onset of symptoms and ^{18}F -FDG PET/CT) and by Mann-Whitney test for binary variables. A linear regression model for multivariate analysis was performed including the variables with a p value < 0.2 in univariate analyses. A two-sided p-value of < 0.05 was considered to indicate statistical significance.

Results

Patient characteristics

Patients' characteristics are summarized in **Table 1**. The median age of the population was 60 years (range 16-83). The patients comprised 29 women (52%) and 27 men (48%). According to the existing diagnostic criteria from Graus and colleagues, 37 patients (66%) had definite encephalitis, 5 patients (9%) had probable encephalitis, and 14 patients (25%) had possible encephalitis.

At the initial stage of the disease, the main symptoms of subacute onset as described by patients were cognitive impairments, including confusion and anterograde amnesia for 41 patients (73%), seizures for 30 patients (54%), atypical psychiatric symptoms for 23 patients (41%) and cerebellar ataxia for 9 patients (16%).

The oncological work-up including whole-body ^{18}F -FDG PET/CT initially identified an underlying tumour in 16 patients (29%). These cancers were located to the lungs of 5 patients (3 adenocarcinoma and 2 small cell lung cancers) and were of gynaecologic origin in 4 patients (2 ovarian, 1 breast, 1 cervical neoplasm), urologic origin in 3 patients (2 prostatic adenocarcinomas and 1 seminoma) and digestive origin in 1 patient (pancreatic neuroendocrine tumour). We also found 2 lymphomas and a thymoma.

Characteristics	Values
N	56
Age, years, median (range)	60 (16-83)
Sex, female, n (%)	29 (52)
Level of evidence for autoimmune encephalitis*, n (%)	
Possible	14 (25)
Probable	5 (9)
Definite	37 (66)
Clinical symptoms, n (%)	
Seizures	30 (54)
Cognitive disorders, confusion, amnesia	41 (73)
Psychiatric symptoms	23 (41)
Cerebellar ataxia	9 (16)
Cancer, n (%)	16 (29)
CSF abnormalities, n (%)	
Hyperproteinorrhachia (≥ 0.5 g/L)	25 (45)
Pleocytosis	16 (29)
Intrathecal Ig synthesis	25 (45)
Normal CSF	15 (27)
Autoantibodies, n (%)	
Positive	31 (55)
Negative	25 (45)
Brain MRI findings, n (%)	
Temporal mesial T2 FLAIR hypersignal	23 (41)
Normal or non-specific MRI	33 (59)
Treatment response, n (%)	
Full response	20 (36)
Partial response	14 (25)
No response	16 (29)
Not evaluable	6 (11)
Death, n (%)	7 (12)

Table 1. Clinical and paraclinical characteristics of patients with autoimmune encephalitis.

Abbreviations: CSF: cerebrospinal fluid; Ig: immunoglobulin; MRI: magnetic resonance imaging; FLAIR: fluid attenuated inversion recovery.

* According to Graus' criteria (Graus F, Titulaer MJ, Balu R, Benseler S, Bien CG, Cellucci T, et al. A clinical approach to diagnosis of autoimmune encephalitis. *Lancet Neurol.* 2016;15:391–404)

Other paraclinical findings

Concerning paraclinical data (**Table 1**), cerebrospinal fluid analysis was normal in 15 patients (27%), while abnormalities were detected in 41 patients (73%). Among these abnormalities, hyper-proteinorrhachia was observed in 25 patients (45%), pleocytosis in 16 patients (29%) and intrathecal immunoglobulin synthesis in 25 patients (45%).

Autoantibodies were identified in 31 patients (55%), while 25 patients (45%) had seronegative encephalitis. Of the antibodies detected, 13 targeted intracellular antigens and 18 targeted cell-surface antigens (**Table 2**). Among the seronegative encephalitis patients, 7 patients had normal CSF analysis results.

On average, brain MRI was performed 7 ± 9 months after the onset of symptoms. Bilateral mesial temporal lobe T2 FLAIR hypersignal was observed in 23 patients (41%). Thirty-three patients (59%) had normal brain MRI or non-specific findings with hypersignal outside the medial temporal lobe, thus corresponding to a negative MRI.

Five patients (9%) in the group of possible AE had normal CSF analysis, normal brain MRI and seronegative encephalitis.

Autoantibodies, n (%)	
Against intracellular antigens (total)	13 (23)
YO	3 (5)
GAD	4 (7)
Ma2	2 (4)
SOX1	3 (5)
Hu	1 (2)
Against cell-surface antigens (total)	18 (32)
CASPR2	4 (7)
LGI1	2 (4)
VGKC	4 (7)
NMDAR	8 (14)
Seronegative AE	25 (45)
Total	56 (100)

Table 2. Antibody status of patients with autoimmune encephalitis

Abbreviations: GAD: glutamic acid decarboxylase; CASPR2: contactin-associated protein-like 2; LGI1: leucine-rich glioma inactivated 1; NMDAR: N-methyl-D-aspartate receptor; VGKC: voltage-gated potassium channel-complex; AE: autoimmune encephalitis.

Brain ^{18}F -FDG PET/CT and SPM analysis

In comparison to the healthy subjects, voxel-based statistical analysis identified a large cluster of decreased cortex/striatum metabolic ratio in patients with autoimmune encephalitis ($p < 0.05$, FWE corrected; **Figure 1**), predominant in associative cortices, involving the frontal, parietal, occipital and temporal cortices, as well as in the anterior and posterior cingulate. The preserved regions were the rolandic and temporal limbic regions. No increased metabolic ratio was identified in patients.

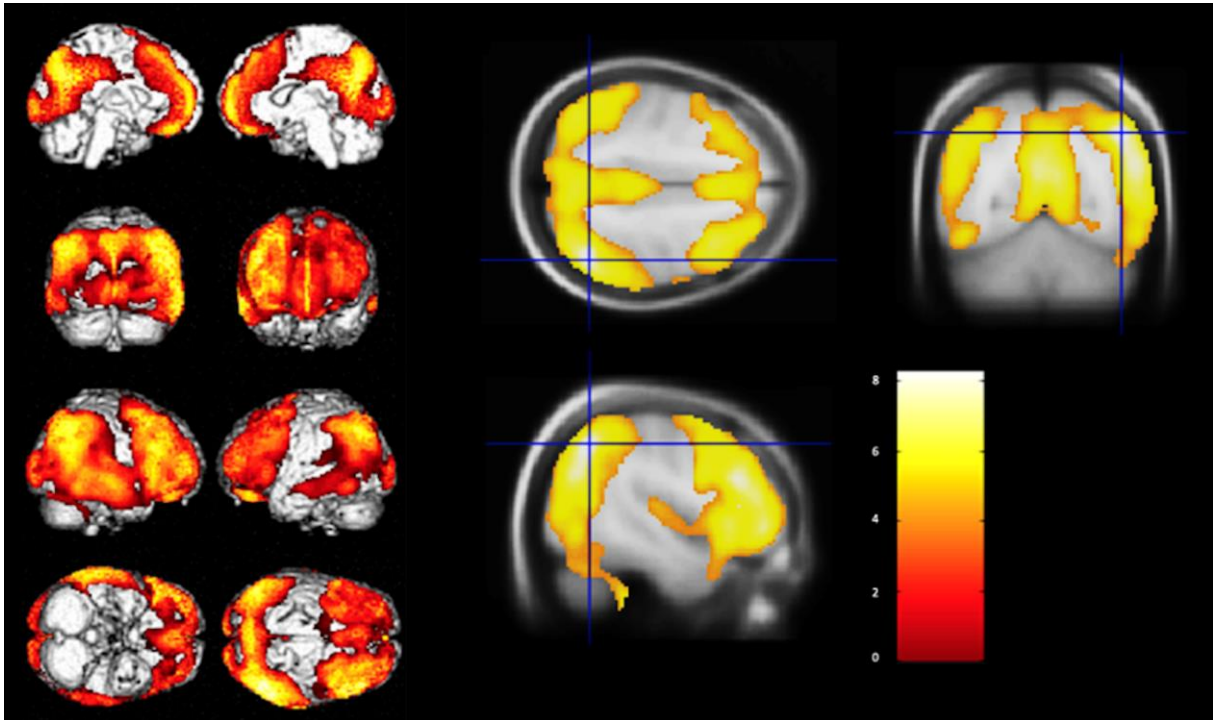


Figure 1. Voxel-based analysis of brain ^{18}F -FDG PET/CT following parametrization to the striatum. Widespread decrease of cortex/striatum metabolic ratio in patients with autoimmune encephalitis, in comparison to healthy subjects ($p\text{-voxel} < 0.05$, FWE corrected).

Discriminant function analysis

For AE patients, the mean cortex/striatum metabolic ratio was 1.16 ± 0.13 , with a range from 0.94 to 1.53. In the control groups, the mean cortex/striatum metabolic ratio was significantly higher, with a mean value of 1.39 ± 0.08 and a range from 1.21 to 1.60 for healthy subjects ($p < 0.001$) and a mean value of 1.32 ± 0.11 and a range from 1.04 to 1.74 for MCI patients ($p < 0.001$). Thirty-eight patients (68 %) of the AE group had a cortex/striatum metabolic ratio lower than the lowest value in the healthy subjects group, and 10 (18%) had a cortex/striatum metabolic ratio lower than the lowest value of the MCI patients (**Figure 2**).

The discriminant value of the cortex/striatum metabolic ratio was evaluated. The ROC curves summarizing the accuracy of ^{18}F -FDG PET/CT cortex/striatum metabolic ratio to discriminate AE patients from controls are

depicted in **Figure 3**. To differentiate AE patients from healthy subjects, the AUC was 0.935 indicating excellent diagnostic accuracy. To differentiate AE from MCI patients, the AUC was slightly lower while maintaining a good accuracy (0.830). According to the ROC curve, the best threshold of cortex/striatum metabolic ratio to differentiate AE from controls was 1.23 allowing a sensitivity of 71% (correct classification of 40/56 AE patients), a specificity of 82% against MCI patients (correct classification of 565/688 MCI patients) and a specificity of 98% against healthy subjects (correct classification of 43/44 healthy subjects). By lowering the value of the cortex/striatum metabolic ratio, the specificity increased but the sensitivity was rapidly degraded.

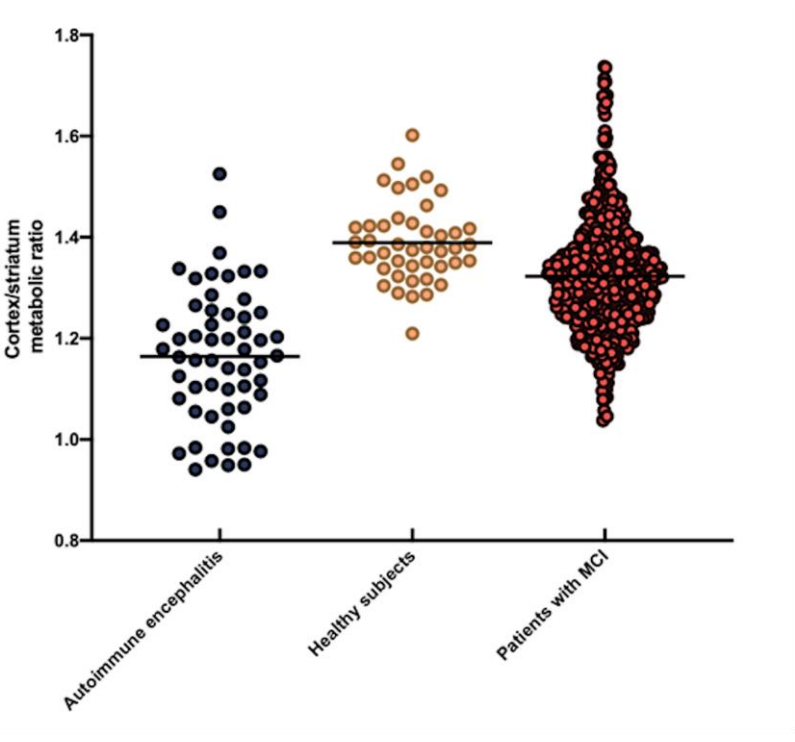


Figure 2. Distribution of cortex/striatum metabolic ratio in patients with autoimmune encephalitis, in comparison to healthy subjects and patients with mild cognitive impairment (MCI). The black line represents the mean of each group.

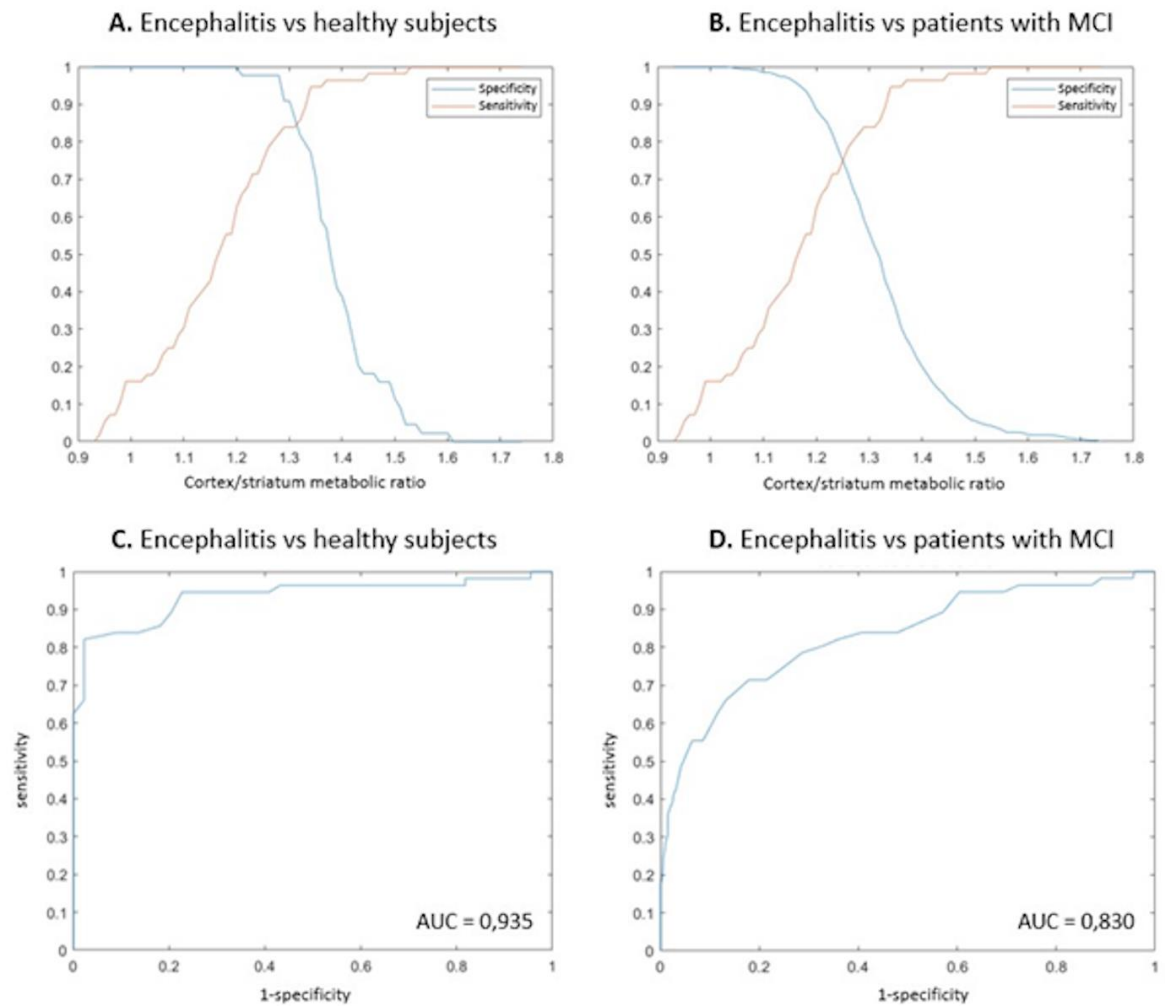


Figure 3. Sensitivity, specificity and ROC curves to identify patients with autoimmune encephalitis (AE) from healthy subjects and from patients with mild cognitive impairment (MCI) according to the cortex/striatum metabolic ratio.

A. Sensitivity and specificity of the cortex/striatum metabolic ratio to identify patients with AE from healthy subjects according to different threshold values. B. Sensitivity and specificity of the cortex/striatum metabolic ratio to identify patients with AE from patients with MCI according to different threshold values. C. Receiver operating characteristic curve of the cortex/striatum metabolic ratio to identify patients with AE from healthy subjects. D. Receiver operating characteristic curve of the cortex/striatum metabolic ratio to identify patients with AE from patients with MCI.

Relationship between cortex/striatum metabolic ratio and clinical/paraclinical data

The metabolic ratio data did not show any statistically significant association in univariate analysis with clinical and paraclinical (p -value > 0.05). Considering a p -value threshold of 0.2 for further multivariate analyses, the cortex/striatum metabolic ratio was lower for patients with positive MRI (1.141 versus 1.197; $p = 0.18$), for deceased patients (1.103 versus 1.179; $p = 0.17$) and when the delay between the onset of symptoms and ^{18}F -

FDG PET/CT was shorter (Spearman's Rho = 0.188; p value = 0.17). In multivariate analysis, a trend towards an association between a lower metabolic ratio and an earlier ¹⁸F-FDG PET/CT was identified (p = 0.07). The association of a low metabolic ratio with a higher risk of death (p = 0.21) or with a bilateral mesial temporal lobe hypersignal on MRI (p = 0.16) was not statistically significant on the multivariate analysis. No significant association was finally found with clinical symptoms or clinical course under treatment (p > 0.05) (**Table 3**). Moreover, no significant correlation was observed between the ratio and either the presence of intrathecal immunoglobulin synthesis or a suspected humoral or cellular pathophysiology of encephalitis deduced from the types of antibodies (against cell surface antigens (mean value = 1.106) or against intracellular antigens (mean value = 1.205)), even though there was a trend towards a lower ratio in patients with antibodies against cell surface antigens (p = 0.11).

N (%)	P value			
	Mean metabolic ratio in the positive group	Mean metabolic ratio in the negative group	Univariate analysis	Multivariate analysis
Sex (female)	1.179	1.138	0.24	
Cancer	1.180	1.161	0.32	
Seizures	1.188	1.145	0.36	
Cognitive disorders	1.178	1.157	0.90	
Psychiatric symptoms	1.153	1.179	0.67	
Cerebellar ataxia	1.199	1.157	0.46	
Pleocytosis	1.159	1.171	0.62	
Hyperproteinorrhachia	1.157	1.179	0.83	
Detected autoantibodies	1.163	1.166	0.88	
MRI profile of encephalitis	1.141	1.197	0.18	0.16
Full response	1.161	1.171	0.66	
No clinical benefit	1.127	1.187	0.45	
Death	1.103	1.179	0.17	0.21
Spearman's Rho				
Age		-0.090	0.51	
Delay between onset and PET		0.188	0.17	0.07

Table 3. Relationships between PET cortex/striatum metabolic ratio and clinical/paraclinical data

The correlation between PET cortex/striatum metabolic ratio and continuous variables (age and the delay between symptoms onset and FDG-PET) was assessed using Spearman's correlation coefficient. The relationships with the binary clinical or paraclinical data (positive vs negative group) were assessed by Mann-Whitney test. Only variables with a p value < 0.2 have been included in the multivariable analysis (linear regression model): MRI profile of encephalitis, Death, and Delay between onset and PET.

Discussion

This brain ¹⁸F-FDG PET/CT voxel-based analysis demonstrates a large decreased of cortex/striatum metabolic ratio in patients with AE in comparison to healthy subjects and MCI patients. This ratio correctly identified patients with AE at individual levels, and could thus be used as a biomarker.

In the present study, we retrospectively evaluated a cohort of 56 patients with a diagnosis of AE according to Graus criteria who underwent a complete clinical and paraclinical evaluation including ¹⁸F-FDG PET/CT. AE is a relatively rare but serious disease with the potential to cause disability. Since immunosuppressive therapeutics have been shown to have a major impact on prognosis, the early diagnosis of AE is essential. However, it is consensually acknowledged that such a diagnosis remains problematic since it is often missed or delayed in patients with heterogeneous and unspecific clinical presentations. Furthermore, standard additional tests may be within normal limits in a significant proportion of patients. Accordingly, in our population of 56 patients with a validated diagnosis of AE, the analysis of cerebrospinal fluid was normal in 15 patients (27%). Similarly, in a recently published study evaluating the prevalence of CSF markers associated with inflammation in patients with active AE, Hebert et al. [7] identified 26/95 (27%) patients with white blood cell counts and protein levels within normal limits, comparable to the values found in our study. Likewise, brain MRI showed a bilateral mesial temporal lobe T2-FLAIR hypersignal in only 23 of our patients (41%) as well as some non-specific findings. The suboptimal sensitivity of brain MRI has been described in several studies [36,45]. Probasco et al. [24] found only 23 MRIs (40%) consistent with the diagnosis of AE in a retrospective study including 57 autoimmune encephalitis patients. A meta-analysis by these same authors identified 68/114 (60%) patients for whom MRI was supposedly consistent with AE without describing the image abnormalities justifying such a diagnosis. The rather variable delay before MRI, which can extend up to several years following symptom onset, may have contributed to the decrease in sensitivity. Finally, seronegative AE constitutes a major diagnostic issue, estimated at approximately 50% of cases [6] and comparable to what is observed in our population (25/56 patients with seronegative AE). Consequently, the identification of a sensitive biomarker would be relevant in establishing the diagnosis of AE.

The role of brain ¹⁸F-FDG PET/CT in the currently used diagnostic criteria [5] is restricted because it represents an alternative to brain MRI for the diagnosis of definite encephalitis only, and because it is limited to the demonstration of temporal lobe hypermetabolism. Graus and colleagues underlined two major drawbacks for the use of brain ¹⁸F-FDG PET/CT, namely, the lack of large studies with homogeneous patient cohorts and the lack of image standardization using more objective semi-quantitative measures.

Recent studies [39,46] have shown a significant diagnostic contribution of semi-quantification in comparison to visual analysis alone in this context, leading to more comparable and accurate results. For example, Lv et al. identified striatal hypermetabolism upon semi-quantitative analysis in 73% of patients who did not present with a visual metabolic striatal abnormality. Indeed, visual analysis is a subjective process that depends on the physician's experience, and has limitations in evaluating hypermetabolism. Visual analysis requires auto-windowing of the image according to a reference region with the greatest ^{18}F -FDG uptake (e.g., the striatum). This point may partly account for the great heterogeneity of the metabolic profiles described in the literature [20,24,36], since most of these descriptions were based on qualitative analysis in which some hypometabolism probably corresponded to a relative decrease in cortical metabolism in comparison with the striatum or limbic hypermetabolism.

Heterogeneity of results was also observed among studies that investigated AE by means of a semi-quantitative analysis. Such heterogeneity may be explained by methodologies not suited for the combined detection of hypometabolism and hypermetabolism in AE patients. More precisely, some investigators have carried out their analysis following proportional scaling [32,34,35], while others have used intensity normalization on a region of interest [39]. However, it is now acknowledged that the intensity normalization method could lead to poor detection of hypometabolic areas or to the artefactual identification of hypermetabolism in the best-preserved areas, as demonstrated in the field of dementia.

Based on 3 cases of autoimmune encephalitis with anti-VGKC antibodies, Rey et al. [23] detected a common ^{18}F -FDG PET/CT pattern of relative striatal hypermetabolism contrasting with diffuse cortical hypometabolism. Moloney et al. [28] also performed qualitative and semi-quantitative analysis of brain ^{18}F -FDG PET/CT in one patient over the course of the symptomatic phase of VGKC encephalitis. They identified an increase in the metabolic gradient between the striatum and cortex in semi-quantitative analysis and hypothesized that such a pattern may be specific for encephalitis, at least in the setting of VGKC encephalitis. In a cohort of 24 patients with anti-NMDAR, anti-GAD and anti-VGKC encephalitis, Tripathi et al. [47] identified heterogeneous metabolic profiles, with more often cortical parieto-occipital hypometabolism and striatal hypermetabolism, on semi-quantitative analysis.

In our study, the objective was to validate a PET biomarker with a discriminant value for diagnosis of AE. We do not aim at identifying a biological biomarker to clarify the pathophysiology of encephalitis. Consequently, we parameterized the intensity of all ^{18}F -FDG PET/CT images on striatal activity, which was justified on the hypothesis that encephalitis is characterized by striatal hypermetabolism and cortical hypometabolism, and that

the ratio of these two variables could thus enhance a discriminant diagnosis. In comparison to healthy subjects, and secondarily confirmed in a large independent group of patients with MCI, voxel-based statistical analysis identified a widespread cortical decreased metabolism compared to the striata, predominant on the associative cortex and essentially preserving the rolandic and temporal limbic regions. This aspect confirms a decrease in the metabolic gradient between the cortex and the striata in patients with AE, regardless of the type of antibody.

The cortex/metabolic ratio was significantly lower in patients with AE than in controls. This cortex/striatum metabolic ratio allowed an effective classification of AE patients versus healthy subjects (AUC = 0.935).

However, the specificity of brain FDG patterns is often questionable, especially for diffuse hypometabolism which can be observed in different diseases (for instance, in the field of neurodegenerative disorders) [15,16]. To assess the specificity of our metabolic ratio, we chose to add a control group corresponding to MCI patients of various origins from ADNI that are expected to have regions of hypometabolism but likely less extended than the AE patients, and without areas of hypermetabolism. Compared to MCI patients, the discriminating performance of the ratio remains good (AUC = 0.830) and a threshold of 1.23 appeared to be effective for the practice probably in association with other criteria, allowing AE patients to be identified with a sensitivity of 71% and a specificity of 82%. At this threshold, the sensitivity is moderately lower than that identified for brain ¹⁸F-FDG PET/CT in the recent meta-analysis of Bordonne et al. (overall detection sensitivity of 87% (80-92%)) based on 21 publications in which the specificity of ¹⁸F-FDG PET/CT is not assessed. In our study, an equivalent sensitivity could be obtained with a slightly higher threshold whereas the choice of a lower ratio makes it possible to gain in specificity while degrading the sensitivity of the test. Indeed, the patients with the lowest ratio all belonged to the AE group (10/56 AE patients had a lower ratio than the lowest value of the MCI group). This metabolic gradient was more frequently affected than other paraclinical parameters evaluated. ¹⁸F-FDG PET/CT with semi-quantitative analysis therefore appears to be an effective biomarker in AE.

A lower cortex/striatum metabolic ratio was not significantly correlated with clinical or paraclinical data. A trend towards an association with a disease diagnosed earlier as evidenced by the link with shorter delay between the onset of symptoms and ¹⁸F-FDG PET/CT ($p = 0.07$ in multivariate analysis) was described. The performances of ¹⁸F-FDG PET/CT in AE are known to be clearly influenced by the time from the onset of symptoms [15]. The identification of a lower ratio at the beginning of the disease is suited for the objective of an early diagnosis.

The prognostic value of the ratio could not be demonstrated although the ratio appeared lower in the group of patients who died because of the disease ($p = 0.21$ in multivariate analysis). The rather small simple size of our cohort of AE patients explained by the low incidence of this disease and the restrictive nature of Graus' criteria

limits the statistical power of the correlation analyzes between the ratio and clinical/paraclinical data and did not allow an analysis by antibody subtype.

Beyond its diagnostic role, brain ^{18}F -FDG PET/CT likely has the potential for the assessment of therapeutic responses associated with an improvement in the cortex/striatum ratio [22,23,34] and for the identification of recurrence [40]. Further studies are required to elucidate the potential of ^{18}F -FDG PET/CT for these indications.

There are several limitations to the present study. First, this is a single-centre retrospective study performed in a tertiary referral hospital, and there is a risk of selection bias. A significant difference in disease duration prior to ^{18}F -FDG PET/CT was noted, and some patients were evaluated years after the onset of symptoms. The observed metabolic patterns are probably variable depending on the stages of the disease. However, this variable mirrors clinical practice with a diagnosis that remains difficult and sometimes delayed. Finally, we do not aim at identifying a biological biomarker to clarify the pathophysiology of encephalitis, nor to demonstrate a hypo or hypermetabolism. Beyond clinical settings, such demonstration could be supported by absolute quantification, considering obvious limitations of semi-quantification.

Future prospective studies are now warranted to confirm the diagnostic performance of the decreased cortex/striatum metabolic ratio in AE patients. The currently used Graus criteria lack sensitivity, and this justifies the development of new diagnostic criteria integrating ^{18}F -FDG PET/CT.

Conclusion

This voxel-based study performed on a large cohort of AE patients allowed us to identify a diffuse decrease cortical/striatum metabolic ratio. This ratio demonstrated good diagnostic performance for the differentiation of encephalitis patients from different control groups including healthy subjects and patients with MCI. Brain ^{18}F -FDG PET/CT with semi-quantitative analysis of the cortex/striatum ratio provides an effective biomarker that should be used in the diagnosis of AE.

Declarations

Funding

The local PET database of healthy controls was funded by APHM (regional PHRC; NCT00484523)

Conflicts of interest/Competing interests

The authors declare that they have no conflicts of interest

Ethics approval

The retrospective observations required no ethical approval requirement other than informed consent and non-opposition (MR-004 french type).

The local PET database of healthy controls was acquired in accordance with the Declaration of Helsinki, with informed written consent from the patients and approval from the “CPP Sud Méditerranée V” ethics committee.

Consent to participate

Informed written consent was obtained from all individual participants included in the study

Consent for publication

Informed written consent was obtained from all individual participants included in the study

Availability of data and material

The PET data that support the findings are available from the corresponding author upon reasonable request

Code availability

Not applicable

References

1. Dalmau J, Graus F. Antibody-Mediated Encephalitis. *N Engl J Med*. 2018;378:840–51.
2. Titulaer MJ, McCracken L, Gabilondo I, Armangué T, Glaser C, Iizuka T, et al. Treatment and prognostic factors for long-term outcome in patients with anti-NMDA receptor encephalitis: an observational cohort study. *Lancet Neurol*. 2013;12:157–65.
3. Balu R, McCracken L, Lancaster E, Graus F, Dalmau J, Titulaer MJ. A score that predicts 1-year functional status in patients with anti-NMDA receptor encephalitis. *Neurology*. 2019;92:e244–52.
4. Hébert J, Day GS, Steriade C, Wennberg RA, Tang-Wai DF. Long-Term Cognitive Outcomes in Patients with Autoimmune Encephalitis. *Can J Neurol Sci*. 2018;45:540–4.
5. Graus F, Titulaer MJ, Balu R, Benseler S, Bien CG, Cellucci T, et al. A clinical approach to diagnosis of autoimmune encephalitis. *Lancet Neurol*. 2016;15:391–404.
6. Ducray F, Demarquay G, Graus F, Decullier E, Antoine J-C, Giometto B, et al. Seronegative paraneoplastic cerebellar degeneration: the PNS Euronetwork experience. *Eur J Neurol*. 2014;21:731–5.
7. Hébert J, Gros P, Lapointe S, Amtashar FS, Steriade C, Maurice C, et al. Searching for autoimmune encephalitis: Beware of normal CSF. *J Neuroimmunol*. 2020;345:577285.
8. Dubey D, Pittock SJ, Kelly CR, McKeon A, Lopez-Chiriboga AS, Lennon VA, et al. Autoimmune encephalitis epidemiology and a comparison to infectious encephalitis. *Ann Neurol*. 2018;83:166–77.
9. Gultekin SH, Rosenfeld MR, Voltz R, Eichen J, Posner JB, Dalmau J. Paraneoplastic limbic encephalitis: neurological symptoms, immunological findings and tumour association in 50 patients. *Brain*. 2000;123 (Pt 7):1481–94.
10. Ances BM, Vitaliani R, Taylor RA, Liebeskind DS, Voloschin A, Houghton DJ, et al. Treatment-responsive limbic encephalitis identified by neuropil antibodies: MRI and PET correlates. *Brain*. 2005;128:1764–77.
11. Morbelli S, Djekidel M, Hesse S, Pagani M, Barthel H, Neuroimaging Committee of the European Association of Nuclear Medicine (EANM), et al. Role of (18)F-FDG-PET imaging in the diagnosis of autoimmune encephalitis. *Lancet Neurol*. 2016;15:1009–10.
12. Sheikhabaehi S, Marcus CV, Fragomeni RS, Rowe SP, Javadi MS, Solnes LB. Whole-Body 18F-FDG PET and 18F-FDG PET/CT in Patients with Suspected Paraneoplastic Syndrome: A Systematic Review and Meta-Analysis of Diagnostic Accuracy. *J Nucl Med*. 2017;58:1031–6.
13. Wagner JN, Kalev O, Sonnberger M, Krehan I, von Oertzen TJ. Evaluation of Clinical and Paraclinical Findings for the Differential Diagnosis of Autoimmune and Infectious Encephalitis. *Front Neurol*. 2018;9:434.
14. Li L, Sun L, Du R, Zheng Y, Dai F, Ma Q, et al. Application of the 2016 diagnostic approach for autoimmune encephalitis from *Lancet Neurology* to Chinese patients. *BMC Neurol*. 2017;17:195.
15. Bordonne M, Chawki MB, Doyen M, Kas A, Guedj E, Tyvaert L, et al. Brain 18F-FDG PET for the diagnosis of autoimmune encephalitis: a systematic review and a meta-analysis. *Eur J Nucl Med Mol Imaging* [Internet]. 2021 [cited 2021 Mar 8]; Available from: <https://doi.org/10.1007/s00259-021-05299-y>
16. Morbelli S, Arbizu J, Booij J, Chen M-K, Chetelat G, Cross DJ, et al. The need of standardization and of large clinical studies in an emerging indication of [18F]FDG PET: the autoimmune encephalitis. *Eur J Nucl Med Mol Imaging*. 2017;44:353–7.
17. Cistaro A, Caobelli F, Quartuccio N, Fania P, Pagani M. Uncommon 18F-FDG-PET/CT findings in patients affected by limbic encephalitis: hyper-hypometabolic pattern with double antibody positivity and migrating foci of hypermetabolism. *Clin Imaging*. 2015;39:329–33.

18. Turpin S, Martineau P, Levasseur M-A, Meijer I, Décarie J-C, Barsalou J, et al. 18F-Fluorodeoxyglucose positron emission tomography with computed tomography (FDG PET/CT) findings in children with encephalitis and comparison to conventional imaging. *Eur J Nucl Med Mol Imaging*. 2019;46:1309–24.
19. Fisher RE, Patel NR, Lai EC, Schulz PE. Two different 18F-FDG brain PET metabolic patterns in autoimmune limbic encephalitis. *Clin Nucl Med*. 2012;37:e213-218.
20. Quartuccio N, Caobelli F, Evangelista L, Alongi P, Kirienko M, De Biasi V, et al. The role of PET/CT in the evaluation of patients affected by limbic encephalitis: A systematic review of the literature. *J Neuroimmunol*. 2015;284:44–8.
21. Probasco JC, Solnes L, Nalluri A, Cohen J, Jones KM, Zan E, et al. Decreased occipital lobe metabolism by FDG-PET/CT: An anti-NMDA receptor encephalitis biomarker. *Neurol Neuroimmunol Neuroinflamm*. 2018;5:e413.
22. Wei Y-C, Tseng J-R, Wu C-L, Su F-C, Weng W-C, Hsu C-C, et al. Different FDG-PET metabolic patterns of anti-AMPA and anti-NMDAR encephalitis: Case report and literature review. *Brain Behav*. 2020;10:e01540.
23. Rey C, Koric L, Guedj E, Felician O, Kaphan E, Boucraut J, et al. Striatal hypermetabolism in limbic encephalitis. *J Neurol*. 2012;259:1106–10.
24. Probasco JC, Solnes L, Nalluri A, Cohen J, Jones KM, Zan E, et al. Abnormal brain metabolism on FDG-PET/CT is a common early finding in autoimmune encephalitis. *Neurol Neuroimmunol Neuroinflamm*. 2017;4:e352.
25. Castagnoli H, Manni C, Marchesani F, Rossi G, Fattori S, Capocchetti F. The role of 18F-FDG PET/CT in management of paraneoplastic limbic encephalitis combined with small cell lung cancer: A case report. *Medicine (Baltimore)*. 2019;98:e16593.
26. Cózar Santiago MDP, Sanchez Jurado R, Sanz Llorens R, Aguilar Barrios JE, Ferrer Rebolleda J. Limbic Encephalitis Diagnosed With 18F-FDG PET/CT. *Clin Nucl Med*. 2016;41:e101-103.
27. Maffione AM, Chondrogiannis S, Ferretti A, Al-Nahhas A, Rubello D. Correlative imaging with (18)F-FDG PET/CT and MRI in paraneoplastic limbic encephalitis. *Clin Nucl Med*. 2013;38:463–4.
28. Moloney P, Boylan R, Elamin M, O’Riordan S, Killeen R, McGuigan C. Semi-quantitative analysis of cerebral FDG-PET reveals striatal hypermetabolism and normal cortical metabolism in a case of VGKCC limbic encephalitis. *Neuroradiol J*. 2017;30:160–3.
29. Moubtakir A, Dejust S, Godard F, Messaoud L, Morland D. 18F-FDG PET/CT in Anti-NMDA Receptor Encephalitis: Typical Pattern and Follow-up. *Clin Nucl Med*. 2018;43:520–1.
30. Scheid R, Lincke T, Voltz R, von Cramon DY, Sabri O. Serial 18F-fluoro-2-deoxy-D-glucose positron emission tomography and magnetic resonance imaging of paraneoplastic limbic encephalitis. *Arch Neurol*. 2004;61:1785–9.
31. Gaeta MC, Godani M, Nunziata R, Capellini C, Ciarmiello A. Early detection of encephalitis with (18)F-FDG PET/CT. *Rev Esp Med Nucl Imagen Mol*. 2015;34:188–90.
32. Liu X, Shan W, Zhao X, Ren J, Ren G, Chen C, et al. The Clinical Value of ¹⁸F-FDG-PET in Autoimmune Encephalitis Associated With LGII Antibody. *Front Neurol*. 2020;11:418.
33. Dodich A, Cerami C, Iannaccone S, Marcone A, Alongi P, Crespi C, et al. Neuropsychological and FDG-PET profiles in VGKC autoimmune limbic encephalitis. *Brain Cogn*. 2016;108:81–7.
34. Leyboldt F, Buchert R, Kleiter I, Marienhagen J, Gelderblom M, Magnus T, et al. Fluorodeoxyglucose positron emission tomography in anti-N-methyl-D-aspartate receptor encephalitis: distinct pattern of disease. *J Neurol Neurosurg Psychiatry*. 2012;83:681–6.

35. Wegner F, Wilke F, Raab P, Tayeb SB, Boeck A-L, Haense C, et al. Anti-leucine rich glioma inactivated 1 protein and anti-N-methyl-D-aspartate receptor encephalitis show distinct patterns of brain glucose metabolism in 18F-fluoro-2-deoxy-d-glucose positron emission tomography. *BMC Neurol.* 2014;14:136.
36. Baumgartner A, Rauer S, Mader I, Meyer PT. Cerebral FDG-PET and MRI findings in autoimmune limbic encephalitis: correlation with autoantibody types. *J Neurol.* 2013;260:2744–53.
37. Lee BY, Newberg AB, Liebeskind DS, Kung J, Alavi A. FDG-PET findings in patients with suspected encephalitis. *Clin Nucl Med.* 2004;29:620–5.
38. Masangkay N, Basu S, Moghbel M, Kwee T, Alavi A. Brain 18F-FDG-PET characteristics in patients with paraneoplastic neurological syndrome and its correlation with clinical and MRI findings. *Nucl Med Commun.* 2014;35:1038–46.
39. Moreno-Ajona D, Prieto E, Grisanti F, Esparragosa I, Sánchez Orduz L, Gállego Pérez-Larraya J, et al. 18F-FDG-PET Imaging Patterns in Autoimmune Encephalitis: Impact of Image Analysis on the Results. *Diagnostics (Basel).* 2020;10.
40. Novy J, Allenbach G, Bien CG, Guedj E, Prior JO, Rossetti AO. FDG-PET hyperactivity pattern in anti-NMDAr encephalitis. *J Neuroimmunol.* 2016;297:156–8.
41. Yakushev I, Landvogt C, Buchholz H-G, Fellgiebel A, Hammers A, Scheurich A, et al. Choice of reference area in studies of Alzheimer’s disease using positron emission tomography with fluorodeoxyglucose-F18. *Psychiatry Res.* 2008;164:143–53.
42. Yakushev I, Hammers A, Fellgiebel A, Schmidtman I, Scheurich A, Buchholz H-G, et al. SPM-based count normalization provides excellent discrimination of mild Alzheimer’s disease and amnesic mild cognitive impairment from healthy aging. *Neuroimage.* 2009;44:43–50.
43. Nugent S, Croteau E, Potvin O, Castellano C-A, Dieumegarde L, Cunnane SC, et al. Selection of the optimal intensity normalization region for FDG-PET studies of normal aging and Alzheimer’s disease. *Sci Rep.* 2020;10:9261.
44. Tzourio-Mazoyer N, Landeau B, Papathanassiou D, Crivello F, Etard O, Delcroix N, et al. Automated anatomical labeling of activations in SPM using a macroscopic anatomical parcellation of the MNI MRI single-subject brain. *Neuroimage.* 2002;15:273–89.
45. Solnes LB, Jones KM, Rowe SP, Pattanayak P, Nalluri A, Venkatesan A, et al. Diagnostic Value of 18F-FDG PET/CT Versus MRI in the Setting of Antibody-Specific Autoimmune Encephalitis. *J Nucl Med.* 2017;58:1307–13.
46. Lv R-J, Pan J, Zhou G, Wang Q, Shao X-Q, Zhao X-B, et al. Semi-quantitative FDG-PET Analysis Increases the Sensitivity Compared With Visual Analysis in the Diagnosis of Autoimmune Encephalitis. *Front Neurol.* 2019;10:576.
47. Tripathi M, Tripathi M, Roy SG, Parida GK, Ihtisham K, Dash D, et al. Metabolic topography of autoimmune non-paraneoplastic encephalitis. *Neuroradiology.* 2018;60:189–98.