



HAL
open science

Neurological outcome in WDR62 primary microcephaly

Lyse Ruaud, Séverine Drunat, Monique Elmaleh-bergès, Anais Ernault, Sophie Guilmin Crepon, Vincent El Ghouzzi, Stéphane Auvin, Alain Verloes, Lionel van Maldergem, Camille Engel, et al.

► **To cite this version:**

Lyse Ruaud, Séverine Drunat, Monique Elmaleh-bergès, Anais Ernault, Sophie Guilmin Crepon, et al.. Neurological outcome in WDR62 primary microcephaly. *Developmental Medicine and Child Neurology*, 2022, 10.1111/dmnc.15060 . hal-03357164

HAL Id: hal-03357164

<https://hal.science/hal-03357164>

Submitted on 28 Sep 2021

HAL is a multi-disciplinary open access archive for the deposit and dissemination of scientific research documents, whether they are published or not. The documents may come from teaching and research institutions in France or abroad, or from public or private research centers.

L'archive ouverte pluridisciplinaire **HAL**, est destinée au dépôt et à la diffusion de documents scientifiques de niveau recherche, publiés ou non, émanant des établissements d'enseignement et de recherche français ou étrangers, des laboratoires publics ou privés.

Neurological outcome in *WDR62* primary microcephaly

LYSE RUAUD¹ | SÉVERINE DRUNAT¹ | MONIQUE ELMALEH-BERGÈS² | ANAIS ERNAULT³ |
SOPHIE GUILMIN CREPON⁴ | VINCENT EL GHOUZZI⁵ | STÉPHANE AUVIN⁶ | ALAIN VERLOES¹ |
THE MCPH CONSORTIUM* | SANDRINE PASSEMARD⁶

1 Département de Génétique, UMR 1141 NEURODIDEROT, INSERM, APHP, Hôpital Universitaire Robert Debré, Université de Paris, Paris; **2** Service d'Imagerie Pédiatrique, APHP, Hôpital Universitaire Robert Debré, Paris; **3** Département de Génétique, APHP, Hôpital Universitaire Robert Debré, Paris; **4** Unité d'Epidémiologie Clinique, APHP, Hôpital Universitaire Robert Debré, Paris; **5** UMR 1141 NEURODIDEROT, INSERM, Université de Paris, Paris; **6** Service de Neurologie Pédiatrique, UMR 1141 NEURODIDEROT, INSERM, APHP, Hôpital Universitaire Robert Debré, Université de Paris, Paris, France.

Correspondence to Sandrine Passemard at Service de Neurologie Pédiatrique, Hôpital Robert Debré, 48 Boulevard Sérurier, 75019 Paris, France. E-mail: sandrine.passemard@aphp.fr

*Members of the MCPH consortium are listed in the Acknowledgements.

PUBLICATION DATA

Accepted for publication 2nd August 2021.
Published online

ABBREVIATIONS

ASPM	Abnormal spindle-like microcephaly-associated
OFC	Occipitofrontal circumference
VABS	Vineland Adaptive Behavior Scales
<i>WDR62</i>	WD repeat domain 62

AIM To characterize the cortical structure, developmental, and cognitive profiles of patients with WD repeat domain 62 (*WDR62*)-related primary microcephaly.

METHOD In this observational study, we describe the developmental, neurological, cognitive, and brain imaging characteristics of 17 patients (six males, 11 females; mean age 12y 3mo standard deviation [SD] 5y 8mo, range 5y–24y 6mo) and identify 14 new variants of *WDR62*. We similarly analyse the phenotypes and genotypes of the 59 previously reported families.

RESULTS Brain malformations, including pachygyria, neuronal heterotopia, schizencephaly, and microlissencephaly, were present in 11 out of 15 patients. The mean full-scale IQ of the 11 assessed patients was 51.8 (standard deviation [SD] 12.6, range 40–70). Intellectual disability was severe in four patients, moderate in four, and mild in three. Scores on the Vineland Adaptive Behavior Scales obtained from 10 patients were low for communication and motor skills (mean 38.29, SD 7.74, and 37.71, SD 5.74 respectively). The socialization score was higher (mean 47.14, SD 12.39). We found a significant difference between scores for communication and daily living skills (mean 54.43, SD 11.6; $p=0.001$, one-way analysis of variance). One patient displayed progressive ataxia.

INTERPRETATION *WDR62*-related cognitive consequences may be less severe than expected because 3 out of 11 of the assessed patients had only mild intellectual disability and relatively preserved abilities of autonomy in daily life. We identified progressive ataxia in the second decade of life in one patient, which should encourage clinicians to follow up patients in the long term.

Primary microcephaly caused by WD repeat domain 62 gene (*WDR62*) variants (*WDR62*-PM), also called microcephaly primary hereditary type 2, with or without cortical malformations, is the second most common type of primary microcephaly, after type 5 caused by abnormal spindle-like microcephaly-associated (*ASPM*) variants.

In humans and rodents, *WDR62* is highly expressed in the forebrain during neurogenesis, especially in the ventricular and subventricular zones.^{1,2} *WDR62* is a microtubule minus-end mitotic spindle pole protein, located in dividing neural progenitors in humans^{1,3} and plays a crucial role in spindle pole organization and orientation^{1,4} during embryonic brain development.^{4–6} In different rodent or human models, *WDR62* depletion leads to fewer neural progenitors.^{4,6–8} What remains controversial is whether this is due to premature differentiation^{6–8} or to mitotic delay and consequent death of these neural progenitors.⁴

Unlike other primary microcephaly genes, *WDR62*-PM is associated with a reduction in brain volume and cortical malformations in almost all patients investigated by magnetic resonance imaging (MRI).^{1–3} *WDR62*-PM is considered severe with a poor prognosis: severe intellectual disability, epilepsy, and motor handicap, especially when identified before birth.^{1–3} Since its identification, 52 pathogenic homozygous or compound heterozygous *WDR62* variants have been reported in 137 affected individuals from 59 families (Table S1, online supporting information), across many single case reports, often with insufficient phenotypic description. Motor and intellectual outcomes in adulthood are still poorly delineated.

Here we report genotypes, detailed brain imaging, and neuropsychological phenotypes in 17 patients with *WDR62*-PM. Our study demonstrates that the *WDR62*-PM phenotype is more variable than commonly reported.

We also discuss a potential neurological decline with age as observed in at least one patient.

METHOD

Patient ascertainment

Patients with biallelic variants in *WDR62* were identified through Microfanc and EuroMicro, two national and European research projects conducted between 2011 and 2020. Inclusion criteria were an occipitofrontal circumference (OFC) below -2 standard deviations (SDs) at birth or after 12 months of age. Patients were evaluated by a geneticist and a child neurologist in both protocols. All investigations described above were not necessarily performed at last examination; some patients were still followed after being included in the study.

The research projects were approved by the National Ethics Committee (Comité de Protection des Personnes Ile-de-France II, number 2010AO1481-38) and registered at ClinicalTrials.gov (NCT01565005). Written informed consent for DNA and data analyses was obtained from patients or their legal guardians.

Genetic investigations

Genotyping was performed by next-generation sequencing of a panel of 150 genes involved in microcephaly or by whole-exome sequencing using routine methods. Confirmation and segregation of variants into pedigrees were done by Sanger sequencing. Targeted *WDR62* Sanger sequencing was also performed after identification of either a region of homozygosity, including the *WDR62* locus on SNP array, or familial variants from previous cases.

Patients' clinical, neuroimaging, and neuropsychological assessments

Brain MRI

MRI studies were performed on a 1.5T Philips (Best, Netherlands), GE (Milwaukee, WI, USA), or Siemens (Oxford, UK) MRI scanner, using the same protocol including coronal T2-weighted, axial FLAIR, and T1-weighted three-dimensional sequences with millimetre slices (10 out of 15 patients). Brain MRI was performed several times for some patients, in the absence of general anaesthesia authorization for this protocol, and therefore was occasionally dissociated from the rest of the clinical and neuropsychological assessment. The mean age at brain MRI was 6 years 7 months (median 6y [range 7d–16y 10mo]). Patients' MRI examinations were reviewed by a single neuroradiologist (MEB) to collect the significant imaging data. The gyral pattern was considered simplified when the number of gyri was reduced, the sulci were very shallow (less than half the normal depth) on several sections (frontal, parietal, and occipital coronal sections; and axial sections), and no tertiary gyri were visible.⁹

Cognitive and adaptive assessment

Developmental skills were assessed using the Vineland Adaptive Behavior Scales (VABS, mean age at assessment

What this paper adds

- Seventy per cent of *WRD62*-related microcephaly was associated with cortical malformations.
- Twenty-seven per cent of patients exhibited mild intellectual disabilities and preserved daily living skills.
- Progressive ataxia was found in one patient with a *WDR62* variant.

9y 11mo, median 7y 6mo [5y 11mo–15y]) (First, or Second Edition, informant interview or forms completed by parents), which quantifies four domains: communication, daily living or autonomy, socialization, and motor.

Neurocognitive abilities were assessed using the Wechsler Intelligence Scales for Children according to age (scales IV and V: 6y–16y 11mo; or Wechsler Preschool and Primary Scale of Intelligence III or IV: 4y–7y 3mo). The mean age at assessment was 8 years 5 months (median 6y [5y 6mo–14y 4mo]).

Literature review

PubMed was searched for peer-reviewed articles published in English using the keywords 'WDR62', 'microcephaly', 'primary microcephaly', 'MCPH', 'MCPH2', and 'genetic variants'.

Statistical analysis

Data are presented as mean (SD) or median and interquartile range. A *t*-test was used to compare the variable 'OFC' between birth and 12 years 3 months (mean age at last examination). Repeated measures one-way analysis of variance was performed to compare the variable 'developmental quotient' between the four groups or domains, or the variable 'IQ' between five different scores, using the *t*-test as a post hoc test for multiple pairwise comparisons, and a Bonferroni correction for adjusting the significance level for multiple pairwise comparisons. A χ^2 test was used to compare the variable 'inside' or 'outside' WD-domain variants and the presence or absence of cortical malformations, as well as the variable 'high' or 'moderate' impact variant and the presence or absence of cortical malformations.

RESULTS

Patients

We identified 17 patients with *WDR62*-PM from 14 pedigrees. Seven were identified by a next-generation sequencing panel, one by exome sequencing, and nine by targeted sequencing of *WDR62* (Table S2, online supporting information).

Molecular investigations

All *WDR62* variants (reported in previous studies and in the current study) are listed in Tables S1 and S2, and Figure 1a using the NM_001083961 reference sequence (GRCh37). We identified 18 variants (four nonsense, nine missense, three frameshift, and two splice), among which 14 were absent from public databases. Twelve patients carried homozygous and five carried compound heterozygous variants. Patient 3 was reported previously by Nicholas et al.¹

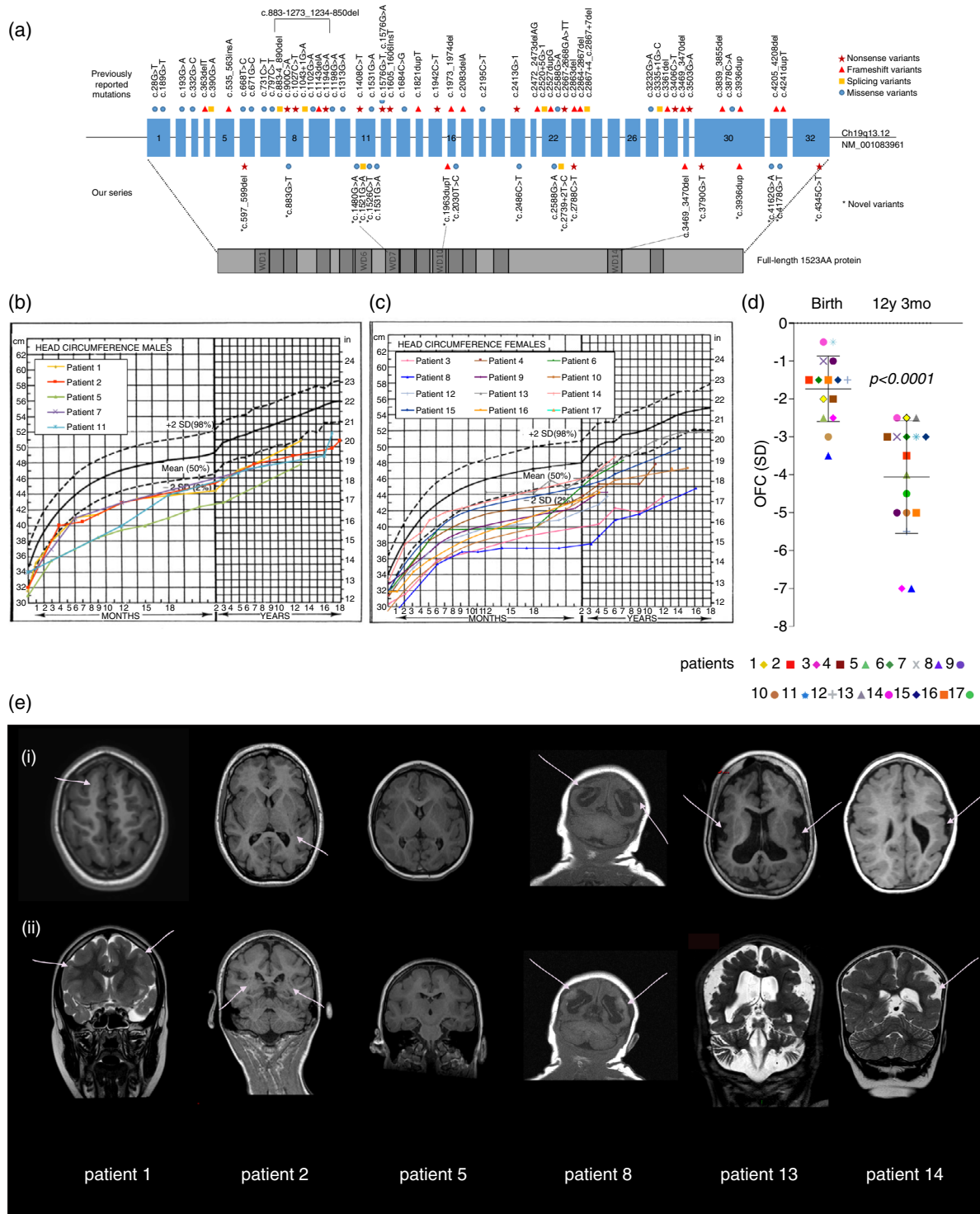


Figure 1: Distribution of *WDR62* variants, brain growth evolution, and structural neuroanatomy of patients with *WDR62*-related microcephaly. (a) Human *WDR62* gene and protein with its different domains. (b,c) Occipitofrontal circumference (OFC) curves of patients of our series. (d) OFC at birth and at last examination. Microcephaly is inconstant at birth and worsened with age (t -test: $p < 0.001$). (e) Main structural brain abnormalities. Axial (i) (except for patient 8) and coronal (ii) T1- and T2-weighted images in patients 1, 2, 5, 8, 13, and 14 illustrating the main cortical malformations related to *WDR62* variants. Gyral simplification in all cases. Subcortical band heterotopia (arrows) in patient 2. Bilateral pachygyria is very obvious in patient 5. Bilateral schizencephaly (a) (white arrows) associated with bilateral parietal polymicrogyria is similar to the schizencephaly in patient 8 (b). Bilateral or unilateral (white arrows) polymicrogyria, with small gyri and shallow sulci (patients 13 and 14). Almost all patients have large Virchow–Robin spaces as in patient 1 (arrows).

Brain development and neuroanatomy

OFC kinetics are summarized in Table S2 and Figure 1b, c. Microcephaly was present at birth for 6 out of 15 patients (OFC mean -1.7 , SD 0.8) and was detected in the third trimester of pregnancy in half of them. Brain growth velocity reduced during childhood, with an OFC mean of -4 (1.5) in the last examination (mean age at last examination $12\text{y } 3\text{mo}$, median $13\text{y } [4\text{y}–24\text{y } 6\text{mo}]$). However, we observed two kinetic patterns (Fig. 1b,c): while the OFC grew constantly following the $-2/-3$ SD curve from birth to last examination in patients 1, 2, 13, 14, and 15, brain growth velocity decreased with age (leading to an increased z -score) in all others, causing a marked difference in OFC z -score between birth and childhood (see Fig. 1d; $p < 0.001$; t -test).

Brain imaging was performed in 15 patients (mean age $6\text{y } 8\text{mo}$, median $6\text{y } [7\text{d}–16\text{y } 10\text{mo}]$) and considered normal in only 2 out of the 15 (patients 6 and 7), although it showed visible or expanded Virchow–Robin spaces (Fig. S2, online supporting information), non-specific findings also observed both in typically developing children or in neurodevelopmental disorders.¹⁰ Except for these two patients, expanded Virchow–Robin spaces in the periventricular and/or subcortical white matter (Table S2 and Fig. 1e) were associated with other cortical anomalies. Pachygyria predominating in the frontal lobes was present in 11 out of 15 patients (Table S2 and Fig. 1e), associated with gyral simplification (see ‘Method’). Other cortical anomalies included bilateral schizencephaly (patient 8), unilateral or bilateral polymicrogyria (patients 13 and 14), and nodular heterotopia in the white matter (patient 2) (Fig. 1e and Figs S1–S3, online supporting information). Vermis and cerebellar atrophy/hypoplasia were identified in patient 13, whose MRI was only performed at age 12 years (Figs 1e and S3). Patient 2 had two different MRI scans (at 11y and 23y) without any modification.

Neurological examination

Six out of 17 patients exhibited pyramidal syndrome, ranging in severity from hyperreflexia without spasticity to a unilateral (right) spastic hemiparesis (patient 14) and spastic bilateral cerebral palsy (patients 8 and 13; Table S2). Seven patients exhibited a cerebellar syndrome: congenital ataxia/dysmetria for six patients, and progressive ataxia with tremor, dysmetria, and dysarthria for patient 2. This progressive cerebellar syndrome was diagnosed at 13 years.

This first resulted in the deterioration of drawing and writing skills between the age of 8 and 14 years (Fig. 2f,g) and secondly in a clinically obvious motor decline, highlighted by a decline in the motor domain on successive VABS (Fig. 2e).

Cognitive profile

Fifteen of the 17 patients acquired independent walking at a median age of 19 months (Fig. 2a). Among them, 6 out of 15 walked independently before 18 months of age. Language was delayed in 11 out of 15 patients (median age at first words 30mo ; Fig. 2b) and systematically associated with speech disorder. In the last examination (mean age $12\text{y } 3\text{mo}$, median $13\text{y } [4\text{y}–24\text{y } 6\text{mo}]$), 11 out of 17 patients could use short, understandable sentences (Table S2). Two had no speech at 16 years of age.

Developmental and cognitive assessments were proposed to all patients, using VABS and/or Wechsler scales, as applicable. Parents of patients 3, 4, and 17 refused to participate. Finally, 14 patients were assessed: seven with both the VABS and Wechsler scales, four with Wechsler scales only, and three with the VABS only (Table S2). Cognitive abilities were analysed using data from 11 patients, and developmental abilities using data from 10 patients.

Cognitive abilities

Four patients could not undertake the Wechsler scales (patients 5, 8, 11, and 13, $n=4$ out of 11) and were considered to have severe intellectual disability.¹¹ The assessment of the seven patients who were amenable to Wechsler scale testing ($n=7$ out of 11: patients 1, 2, 6, 7, 9, 12, and 14) showed mild to moderate intellectual disability. Average full-scale IQ was 51.8 (SD 12.6 , range $40–70$; Fig. 2c). Irrespective of the subtest assessed, we observed interindividual variability and intraindividual homogeneity. The intellectual abilities of 3 out of 11 patients (patients 6, 12, and 14) were relatively spared, with full-scale IQ scores ranging from 57 to 70 suggesting mild intellectual disability (Fig. 2c), according to the Diagnostic and Statistical Manual of Mental Disorders, Fifth Edition.¹¹



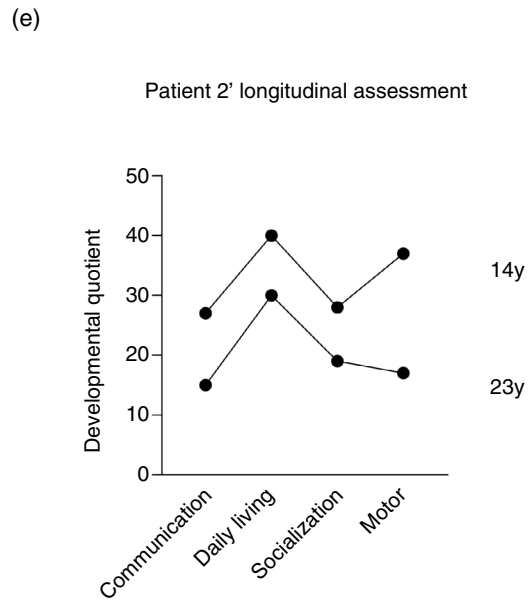
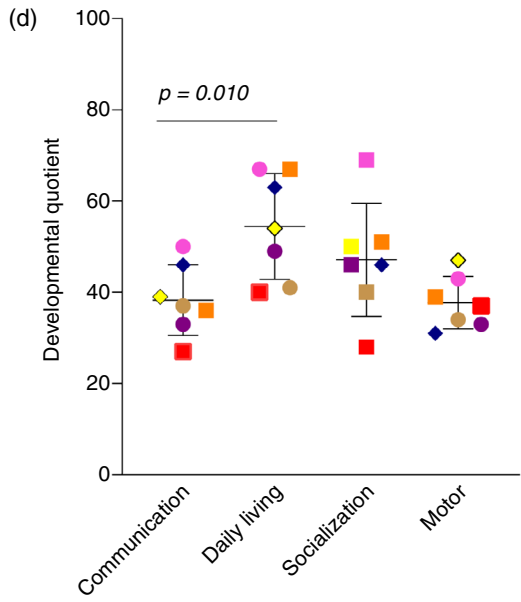
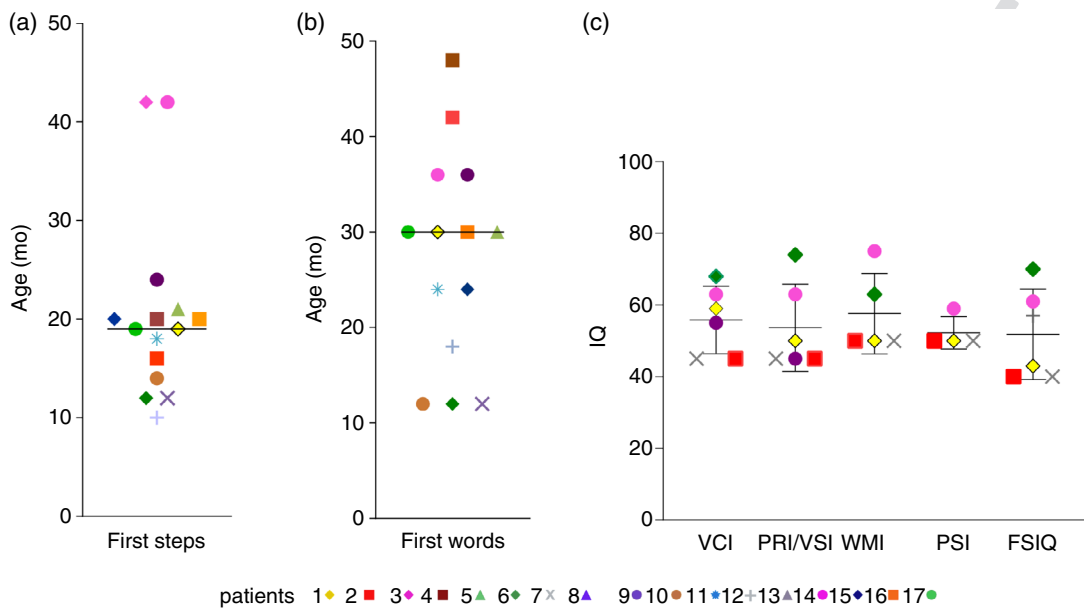
Developmental abilities

VABS scores were obtained for 10 patients (patients 1, 2, 5, 7, 8, 9, 10, 14, 15, and 16). However, parents of patients 5, 7, and 8 had difficulties in understanding the VABS questionnaire, and their contributions were discarded. The

Figure 2: Neurodevelopmental skills, cognitive abilities, and adaptive behavioural skills of patients with *WDR62*. Median age at (a) independent walk and (b) first words in our series. Patients 8 and 13 are not depicted because they were still unable to walk and speak at the last examination, i.e. respectively at age 16 and 20 years. (c) Cognitive abilities. Scores are depicted by indices (Verbal Reasoning Index: VCI, Verbal Quotient or Verbal Comprehension Index. Nonverbal reasoning, Performance Quotient: PRI/VSI, Perceptive Reasoning or Visual Spatial Index; WMI, Working Memory Index; PSI, Processing Speed Index) and full-scale IQ (FSIQ) according to age (Wechsler Preschool and Primary Scale of Intelligence, Third or Fourth, Wechsler Intelligence Scales for Children, Fourth or Fifth Edition). (d) Developmental quotient (calculated from developmental age/real age $\times 100$, Vineland Adaptive Behavior Scales). (e) Patient 2’s longitudinal assessment. Drawing and writing deterioration in patient 2 between the ages of (f) 8 years and (g) 14 years.

1
2
3
4
5
6
7
8
9
10
11
12
13
14
15
16
17
18
19
20
21
22
23
24
25
26
27
28
29
30
31
32
33
34
35
36
37
38
39
40
41
42
43
44
45
46
47
48
49
50
51
52
53
54
55
56
57

COLOR



developmental quotients of the seven patients who performed the VABS were in the deficiency range (score <80). Communication and motor scores were the lowest (Fig. 2d; mean 38.29, SD 7.74, and 37.71, SD 5.74 respectively). Despite expressive language and motor disabilities, we noticed a significant difference between ‘communication’ and ‘autonomous in daily life’ scores ($p=0.001$, repeated measures one-way analysis of variance, multiple paired samples t -test; average quotient in daily living skills 54.43, SD 11.6; Fig. 2d). We observed a similar tendency for the socialization domain (mean score 47.14, SD 12.39), although it was non-significant when compared with the communication skills domain. In addition, the questionnaire confirmed motor disability in all patients (Fig. 2d), even those without ataxia or unilateral cerebral palsy.

Patient 2 had a clinically obvious motor decline, caused by the occurrence of a progressive ataxia, dysmetria, and tremor. A deterioration in drawing and writing skills was noted by parents, teachers, and doctors between the age of 8 and 14 years (Fig. 2f,g). This motor decline was highlighted on successive VABS assessments by a 20-point difference in the motor domain, whereas it was inferior to 12 points in the three other domains (communication, 12 points; daily living, 10 points; and socialization, nine points; Fig. 2e). Between the two assessments (14y and 23y), the decline in gross motor skills resulted in a reduced score or a loss in the ability to succeed in the tasks ‘runs smoothly, changing speed and direction’ and ‘hops forward on one foot with ease without support’. A decline in fine motor skills was appreciated through the ‘use an eraser without tearing the paper’ score.

Literature review

We identified 27 articles mentioning one of the keywords detailed in the Method section. In total, these articles reported 137 patients carrying *WDR62*-PM. Clinical data are detailed in Tables S1 and S3 (online supporting information).

The OFC was mentioned in 72 out of 137 cases and ranged from -0.2 SD to -12.5 SD (mean -6.3 SD, median -6 SD) on last examination (mean 12y 10mo, median 8y [3mo–59y]). Brain imaging was available in 52 out of 137 cases, reported normal in four, and showed severe cortical malformations in 18. Information about epilepsy was available for 109 out of 137 patients. Among them, epilepsy was present in 41 out of 109. Response to antiseizure medication was not documented.

Combined developmental skills including both walking and talking were reported in 53 out of 137 cases. Taken individually, 44 out of 60 patients were able to walk independently, and 44 out of 59 patients were able to talk with simple sentences. Objective evaluation of cognitive abilities was only reported for 3 out of 137 patients, for one of whom IQ was assessed using the Korean–Leiter International Performance Scale – Revised test¹² and for two of whom a developmental quotient was calculated from VABS.^{1,13}

DISCUSSION

The outcome of patients with *WDR62*-PM seems difficult to predict in light of the limited clinical, neuroradiological, and cognitive data available in the literature (respectively found for 29 out of 137, 52 out of 137, and 3 out of 137 of the reported patients). To inform families about the long-term prognosis of *WDR62*-PM, we undertook a prospective study of patients carrying *WDR62* variants as well as a comprehensive literature review.

Our data show that *WDR62*-PM is associated with severe microcephaly (OFC ≤ -4 SD) in childhood in only 8 out of 17 patients. We especially highlight that, despite the high proportion of patients with *WDR62*-PM exhibiting cortical malformations ($n=11$ out of 15), 5 out of 17 had normal motor and language developmental skills and 3 out of 11 assessed had mild intellectual disability, allowing a degree of autonomy in daily life. Finally, we observed progressive ataxia in one patient that occurred after the age of 13 years, associated with motor decline and cerebellar atrophy in another. Neurodegeneration has not been reported so far in patients with *WDR62*-PM. It would be of interest to confirm this trend by re-evaluating patients, considering the obvious impact on their long-term management.

Molecular landscape of *WDR62*-PM

Four variants were previously reported (c.1531G>A,^{1,14} c.2588G>A,¹³ c.3469_3470delGC,¹ and c.3936dup¹⁵) but most of the *WDR62* variants we identified are novel. All variants, including those in our series, are missense (25 out of 66), nonsense (15 out of 66), frameshift (17 out of 66), and splicing (8 out of 66) variants, in addition to one intragenic deletion (1 out of 66). On the basis of data from the teams that first identified *WDR62*-PM,^{1–3} we compared the phenotype ‘presence or absence of severe cortical malformations’ with the genotype ‘high or moderate impact variant’ (homozygous nonsense/frameshift/splicing vs missense variants) using a χ^2 test (Fig. S4a, online supporting information). This comparison revealed a significant increase of severe cortical malformations in patients carrying high-impact variants. Since then, this entity has probably been considered as severe. However, when adding together all available data including ours, the analysis revealed no phenotype/genotype correlation (Fig. S4b). All reported variants were spread across the gene, although sparing exons 5, 19, 24, 25, and 26 out of 32 (Fig. 1a). Thirty-one out of 66 of the variants are located in the WD protein domains, and do not cluster in hotspots, unlike *ASPM* variants.¹⁶ We compared the phenotype ‘presence or absence of severe cortical malformations’ with the genotype ‘inside or outside WD-domains variants’ from available data of our series and of previous reports, using a χ^2 test (Fig. S4c), and found significantly fewer severe cortical malformations in patients carrying inside WD-domain variants.

How is *WDR62* important for brain development?

WDR62-related microcephaly has been categorized as a primary microcephaly in previous reports (18 out of 20 of

1 reported patients had microcephaly at birth; Table S1). An
2 unexpected finding of our study is that primary micro-
3 cephalo may not be detectable in utero or even at birth (9
4 out of 15 patients in our series displayed OFCs within the
5 normal range at birth), which may explain the low rate of
6 prenatal diagnosis despite access to fetal ultrasound scans.
7 This unexpected finding has perhaps been overlooked, as
8 previous reports reviewing the average OFC associated
9 with *WDR62* variants relied on available data that only
10 represented 72 of the 137 reported patients (Table S1). A
11 longitudinal study of OFC showed that *WDR62*-PM has
12 distinctive brain growth kinetics relative to *ASPM* and
13 *CDK5RAP2*-related primary microcephaly:^{16,17} micro-
14 cephalo (expressed in z-score) worsens during the first 2
15 years, but remains stable thereafter, at an average OFC of
16 -4 (1.5) which, irrespective of brain volume reduction,
17 makes *WDR62*-PM less severe than *ASPM* and
18 *CDK5RAP2*-PMs (OFC of -8.2 and -6 SD respec-
19 tively)^{16,17} in elder patients.

20 Brain imaging of most patients (11 out of 15) in our ser-
21 ies showed classic features of primary microcephaly: (1)
22 reduction in brain volume; (2) gyral simplification patterns
23 that probably reflect the reduction in cortical volume and
24 surface area; and (3) thickened cortex, especially in the
25 frontal lobe, similar to our description of *ASPM*-primary
26 microcephaly.¹⁸ Gyral simplification with broad gyri asso-
27 ciated with thickened cortex define what is called pachy-
28 gyria, a term not always mentioned so precisely in the
29 literature (Table S1). In patients 6 and 7 who had mild
30 microcephaly (-3 SD at 3y and 9y respectively), gyral sim-
31 plification and cortical thickening were absent.

32 Beyond these classic features, we confirm the previously
33 reported impact of *WDR62* variants on neuronal migration,
34 leading to neuronal heterotopias and cortical malformations
35 including schizencephaly, lissencephaly, and polymicrogy-
36 ria. These more severe cortical malformations affected one-
37 quarter of our patients ($n=4$ out of 15), reflecting previous
38 reports ($n=18$ out of 52; Tables S1 and S3).

39 Most *MCPH* (microcephaly primary hereditary) genes
40 modulate human cerebral cortex size by regulating neural
41 mitotic division during neurogenesis.¹⁹ After initial prolif-
42 erative divisions producing a neural progenitor pool, mito-
43 tic divisions switch to neurogenic divisions to generate
44 neurons.²⁰ This switch relies on several mechanisms,
45 including spindle pole orientation and asymmetric inheri-
46 tance of the mother centriole^{21,22} (for a review, see
47 Marthiens and Basto²³). The cerebral cortex of *WDR62*-
48 depleted progenitors in rats shows reduced size and abnor-
49 mal architecture, with a redistribution of newly born neu-
50 rons in the intermediate zone.⁵ The abnormal neuronal
51 migration described in this model may be at the origin of
52 the cortical malformations observed in patients with
53 *WDR62* variants.

54 **Is *WDR62*-PM a neurodegenerative disease?**

55 Before our study, only one patient had been reported with
56 ataxia.²⁴ In our study, one patient (patient 2, 24y 6mo) had

progressive ataxia and/or dysmetria appearing in the sec-
ond decade of life. Brain MRI performed between age 11
and 23 years revealed no cerebellar atrophy. Sequential
assessment with VABS showed a greater decrease in scores
compared with the other domains. However, vermis and
cerebellar atrophy were obvious in brain MRI scans of
patient 13, but their severe general status made the evalua-
tion of cerebellar dysfunction impossible. Considering that
patients from our series (mean age at last examination 12y
3mo) and more generally all reported patients (mean age at
last examination 11y 9mo) are still young, more data are
required to confirm the possible motor degeneration with
age from the second and third decade. Nevertheless, this
finding should prompt clinicians to monitor patients in the
long term and look for signs of neurodegeneration.

57 **Are *WDR62* patients able to become independent?**

Until now, no reliable information has been published on
the ability to live independently in individuals with
WDR62 variants as neuropsychological assessments were
only available for 3 out of 137 patients. The absence of
IQ evaluations may be related to the severity of intel-
lectual disability, or, more likely, to the lack of access to
evaluation tools. Despite limited available knowledge,
WDR62-PM has been presented as the most severe
primary microcephaly.²

To date, cognitive abilities have been assessed using
VABS in only 3 out of 137 patients. We made an unprece-
dented effort to cognitively assess all patients in our series.
The reluctance of some parents and the unfavourable
COVID-19 situation limited the smooth conduction of our
study. Nevertheless, 11 out of 17 of parents allowed the
evaluation of their children by Wechsler scales. Among
these, 4 out of 11 were considered as exhibiting severe
intellectual disability as they could not be assessed accord-
ing to the Wechsler scales. The last 7 out of 11 had mild
to moderate intellectual disability (mean full-scale IQ
51.8), similar to patients with *ASPM* and *CDK5RAP2*
mutations (full-scale IQ at 64 and 54.5 respectively),^{16,17}
with 3 out of 11 having mild intellectual disability and 4
out of 11 moderate intellectual disability. We were also
surprised by the degree of autonomy of the patients with
mild to moderate intellectual disability. Despite the intel-
lectual disability and their communication and motor dis-
abilities, these patients displayed a significant degree of
autonomy in their daily lives and could develop good social
interactions (Fig. 2d). Remarkably, patients affected by
Williams–Beuren or Down syndromes, who exhibit a simi-
lar range of intellectual disability, do not reach a similar
degree of autonomy.^{25,26} As shown in Figure S5 (online
supporting information), with similar full-scale IQ (mean
59.39, 51.22, and 51.8 for Williams–Beuren syndrome,
Down syndrome, and our series respectively), the score in
daily living skills for patients with *WDR62*-PM in our ser-
ies was 1.5 times higher than for patients with Williams–
Beuren or Down syndromes. Surprisingly, 1 out of 3
patients with mild intellectual disability also exhibited a

severe cortical malformation (unilateral left fronto-parietal polymicrogyria) responsible for right hemiparesis and infantile spasms (patient 14).

In conclusion, we provide a natural history of patients with *WDR62*-PM with intellectual and adaptive abilities. Our study demonstrates that *WDR62*-PM is usually not as severe as previously believed, since 3 out of 11 of patients in our series only exhibited mild intellectual disability. Moreover, VABS scales suggest that patients could acquire practical skills conducive to their autonomy in daily life.

ACKNOWLEDGEMENTS

The members of the MCPH consortium are as follows: Lionel Van Maldergem, Camille Engel, Cecilia Altuzarra, Charlie Lami-dieu, Allan Bayat, Stéphanie Moortgat, Karine Pelc, Isabelle Maystadt, Marc Abramowicz, Isabelle Pirson, Sarah Duerinckx, Nino Rostomashvili, Christiane Zweier, Rami Abou Jamra, Imke Lorenz, Damien Haye, Khaoula Zaafrane-Khachnaoui, Sandrine Vaessen, Yline Capri, Laurent Servais, Emilio Di Maria, Jürgen Kohlhasse, Thomas Bast, Najoua Miladi, and Selma Dali. We thank all patients and their families, the CIC team (CIC 1426, INSERM) at Robert Debré Hospital in Paris who organized the families' visits and ensured the implementation of the clinical research protocol and coordination between collaborators. We also thank the MCPH consortium for collecting and sharing data and, during the COVID-19 critical period, for having organized the neuropsychological assessments of their patients. Several authors of this publication are members of the European

Reference Network for Developmental Anomalies and Intellectual Disability. This study was supported by the Microfanc project (number NCT01565005) and European e-Rare Euromicroproject (ANR-13-RARE-0007-01). The authors have stated that they had no interests that might be perceived as posing conflict or bias.

DATA AVAILABILITY STATEMENT

All anonymized data and related documentation from this study are available on reasonable request.

SUPPORTING INFORMATION

The following additional material may be found online:

Figure S1: Brain imaging of *WDR62* microcephaly in our series.

Figure S2: Brain imaging of *WDR62* microcephaly in our series.

Figure S3: Brain imaging of *WDR62* microcephaly in our series.

Figure S4: Search for genotype/phenotype correlations.

Figure S5: Comparison of skills in socialization, daily living, and communication between *WDR62* patients of this series, and patients affected by Williams Beuren and Down syndromes.

Table S1: Molecular, developmental, neurological and neuroimaging data of previously 137 reported patients.

Table S2: Molecular data, clinical, and neuroimaging features of the 17 patients from our series.

Table S3: Phenotypic comparison between previous reports and this series.

REFERENCES

- Nicholas AK, Khurshid M, Désir J, Carvalho OP, Cox JJ, Thornton G, et al. *WDR62* is associated with the spindle pole and is mutated in human microcephaly. *Nat Genet* 2010; **42**: 1010–4.
- Bilgüvar K, Öztürk AK, Louvi A, Kwan KY, Choi M, Tath B, et al. Whole-exome sequencing identifies recessive *WDR62* mutations in severe brain malformations. *Nature* 2010; **467**: 207–10.
- Yu TW, Mochida GH, Tischfield DJ, Sgaier SK, Flores-Sarnat L, Sergi CM, et al. Mutations in *WDR62*, encoding a centrosome-associated protein, cause microcephaly with simplified gyri and abnormal cortical architecture. *Nat Genet* 2010; **42**: 1015–20.
- Chen J-F, Zhang Y, Wilde J, Hansen KC, Lai F, Niswander L. Microcephaly disease gene *Wdr62* regulates mitotic progression of embryonic neural stem cells and brain size. *Nat Commun* 2014; **5**: 3885.
- Xu D, Zhang F, Wang Y, Sun Y, Xu Z. Microcephaly-associated protein *WDR62* regulates neurogenesis through JNK1 in the developing neocortex. *Cell Rep* 2014; **6**: 1176–7.
- Xu D, Yao M, Wang Y, Yuan L, Hoeck JD, Yu J, et al. MEKK3 coordinates with FBW7 to regulate *WDR62* stability and neurogenesis. *PLoS Biol* 2018; **16**: e2006613.
- Jayaraman D, Kodani A, Gonzalez DM, Mancias JD, Mochida GH, Vagnoni C, et al. Microcephaly proteins *Wdr62* and *Aspm* define a mother centriole complex regulating centriole biogenesis, apical complex, and cell fate. *Neuron* 2016; **92**: 813–28.
- Alshawaf AJ, Antonic A, Skafidas E, Ng DC-H, Dottori M. *WDR62* regulates early neural and glial progenitor specification of human pluripotent stem cells. *Stem Cells Int* 2017; **2017**: 7848932.
- Passemard S, Titomanlio L, Elmaleh M, Afenjar A, Alessandri J-L, Andria G, et al. Expanding the clinical and neuroradiologic phenotype of primary microcephaly due to *ASPM* mutations. *Neurology* 2009; **73**: 962–9.
- Groeschel S, Chong WK, Surtees R, Hanefeld F. Virchow-Robin spaces on magnetic resonance images: normative data, their dilatation, and a review of the literature. *Neuroradiology* 2006; **48**: 745–54.
- American Psychiatric Association. Diagnostic and statistical manual of mental disorders. 5th ed. Washington, DC: American Psychiatric Association; 2013.
- Yi YG, Lee D-W, Kim J, Jang J-H, Lee S-M, Jang D-H. Two novel mutations (c.883-4_890del and c.1684C>G) of *WDR62* gene associated with autosomal recessive primary microcephaly: a case report. *Front Pediatr* 2019; **7**: 457.
- Poulton CJ, Schot R, Seufert K, Lequin MH, Accogli A, Annunzio GD, et al. Severe presentation of *WDR62* mutation: is there a role for modifying genetic factors? *Am J Med Genet A* 2014; **164**: 2161–71.
- Kousar R, Hassan MJ, Khan B, Basit S, Mahmood S, Mir A, et al. Mutations in *WDR62* gene in Pakistani families with autosomal recessive primary microcephaly. *BMC Neurol* 2011; **11**: 119.
- Rasool S, Baig JM, Moawia A, Ahmad I, Iqbal M, Waseem SS, et al. An update of pathogenic variants in *ASPM*, *WDR62*, *CDK5RAP2*, *STIL*, *CENPJ*, and *CEP135* underlying autosomal recessive primary microcephaly in 32 consanguineous families from Pakistan. *Mol Genet Genomic Med* 2020; **8**: e1408.
- Létard P, Drunat S, Vial Y, Duerinckx S, Ernault A, Amram D, et al. Autosomal recessive primary microcephaly due to *ASPM* mutations: an update. *Hum Mutat* 2018; **39**: 319–32.
- Nasser H, Vera L, Elmaleh-Bergès M, Steindl K, Letard P, Teissier N, et al. *CDK5RAP2* primary microcephaly is associated with hypothalamic, retinal and cochlear developmental defects. *J Med Genet* 2020; **57**: 389–99.
- Passemard S, Verloes A, Billette de Villemeur T, Boespflug-Tanguy O, Hernandez K, Laurent M, et al. Abnormal spindle-like microcephaly-associated (*ASPM*) mutations strongly disrupt neocortical structure but spare the hippocampus and long-term memory. *Cortex* 2016; **74**: 158–76.
- Kriegstein A, Noctor S, Martínez-Cerdeño V. Patterns of neural stem and progenitor cell division may underlie evolutionary cortical expansion. *Nat Rev Neurosci* 2006; **7**: 883–90.

- 1
2
3
4
5
6
7
8
9
10
11
12
13
14
15
16
17
18
19
20
21
22
23
24
25
26
27
28
29
30
31
32
33
34
35
36
37
38
39
40
41
42
43
44
45
46
47
48
49
50
51
52
53
54
55
56
57
20. Kaindl AM, Passemard S, Kumar P, Kraemer N, Issa L, Zwirner A, et al. Many roads lead to primary autosomal recessive microcephaly. *Prog Neurobiol* 2010; **90**: 363–83.
21. Paridaen JTML, Wilsch-Bräuninger M, Huttner WB. Asymmetric inheritance of centrosome-associated primary cilium membrane directs ciliogenesis after cell division. *Cell* 2013; **155**: 333–44.
22. Wang X, Tsai J-W, Imai JH, Lian W-N, Vallee RB, Shi S-H. Asymmetric centrosome inheritance maintains neural progenitors in the neocortex. *Nature* 2009; **461**: 947–55.
23. Marthiens V, Basto R. Centrosomes: the good and the bad for brain development. *Biol Cell* 2020; **112**: 153–72.
24. Farag HG, Froehler S, Oexle K, Ravindran E, Schindler D, Staab T, et al. Abnormal centrosome and spindle morphology in a patient with autosomal recessive primary microcephaly type 2 due to compound heterozygous *WDR62* gene mutation. *Orphanet J Rare Dis* 2013; **8**: 178.
25. Del Cole CG, Caetano SC, Ribeiro W, Kümmer AMEE, Jackowski AP. Adolescent adaptive behavior profiles in Williams-Beuren syndrome, Down syndrome, and autism spectrum disorder. *Child Adolesc Psychiatry Ment Health* 2017; **11**: 40.
26. Sabat C, Tassé M, Tenorio M. Adaptive behavior and intelligence in adolescents with Down syndrome: an exploratory investigation. *Intellect Dev Disabil* 2019; **57**: 79–94.
27. Woods CG, Parker A. Investigating microcephaly. *Arch Dis Child* 2013; **98**: 707–13.