



**HAL**  
open science

## Sex identification in immature Eurasian perch ( *Perca fluviatilis* ) using ultrasonography

Yannick Ledoré, Anastasia Bestin, Pierrick Haffray, Romain Morvezen, Maud Alix, Bérénice Schaerlinger, Pascal Fontaine, Dominique Chardard

► **To cite this version:**

Yannick Ledoré, Anastasia Bestin, Pierrick Haffray, Romain Morvezen, Maud Alix, et al.. Sex identification in immature Eurasian perch ( *Perca fluviatilis* ) using ultrasonography. *Aquaculture Research*, 2021, 52 (12), pp.6046-6051. 10.1111/are.15465 . hal-03346049

**HAL Id: hal-03346049**

**<https://hal.science/hal-03346049v1>**

Submitted on 16 Jan 2023

**HAL** is a multi-disciplinary open access archive for the deposit and dissemination of scientific research documents, whether they are published or not. The documents may come from teaching and research institutions in France or abroad, or from public or private research centers.

L'archive ouverte pluridisciplinaire **HAL**, est destinée au dépôt et à la diffusion de documents scientifiques de niveau recherche, publiés ou non, émanant des établissements d'enseignement et de recherche français ou étrangers, des laboratoires publics ou privés.



Distributed under a Creative Commons Attribution 4.0 International License

# Sex identification in immature Eurasian perch (*Perca fluviatilis*) using ultrasonography

Yannick Ledoré <sup>a</sup>, Anastasia Bestin <sup>b</sup>, Pierrick Haffray <sup>b</sup>, Romain Morvezen <sup>b</sup>, Maud Alix <sup>a</sup>, Bérénice Schaerlinger <sup>a</sup>, Pascal Fontaine <sup>a</sup>, Dominique Chardard <sup>a</sup>.

**a** : URAFFPA, University of Lorraine-INRAe, 54500 Vandoeuvre, France

**b** : SYSAAF, LPGP INRAE, Rennes, France

*Published in Agriculture Research. Available online: <https://doi.org/10.1111/are.15465>*

## Keywords

Eurasian perch, *perca fluviatilis*, sex identification, ultrasound.

## Abstract

One of the keys for an optimal Eurasian perch aquaculture broodstock management is being able to determine the sex of individuals. For Eurasian perch, compared with other methods of sex identification of fish and according to the 3R principle (replacement, reduction and refinement), ultrasonography is a rapid, non-lethal, non-invasive and accurate method. During two successive experiments, we used ultrasound to identify the gender of two immature Eurasian perch broodstock. In the last experiment, females were identified with 98.9% accuracy (n = 180) and males with 98.8% accuracy (n = 92). This method can be very beneficial for perch fish farmers or aquaculture research.

## Introduction

*Perca fluviatilis*, whose domestication began in the 1990s, is an inter-esting fish species to diversify and develop freshwater aquaculture in Europe. For more than 20 years, research undertaken to develop the control of its reproduction in RAS (recirculating aquaculture system) (Abdulfatah et al., 2011 and Abdulfatah et al., 2013; Fontaine et al., 2015) has led the Eurasian perch to be one of the most important species produced in Western Europe in these conditions (Fontaine, 2009; Fontaine & Teletchea, 2019). However, in order to ensure a better productivity and reduce production costs, several husbandry conditions have to be optimized. Among them, the ability to identify gender is essential for fish farms management or aquaculture research (e.g. selection of females, which have a faster growth (Stejskal et al., 2009); control of the broodstock sex ratio; reduction in the number of animals required for experimentation according to 3R principle (Directive 2010/63/EU). It is, therefore, important to find a fast, precise and inexpensive method for sexing individuals or even assessing fish maturity.

Current techniques for sexing or characterizing maturation in fish include biopsy of the gonads (Ritchie, 1965), plasma analysis of steroids, sex hormones and proteins levels (Le Bail & Breton, 1981), genetic techniques (Griffiths et al., 2000), external urogenital characterization (Vecsei et al., 2003), palpation (Kano, 2005), endoscopy (Hurvitz et al., 2007), coelioscopy (Melillo Filho et al., 2016) or urogenital

catheterization (Zarski et al., 2019). Except for external urogenital characterization and palpation techniques, these non-lethal but invasive methods are generally time-consuming, expensive and sometimes dependent on the maturity of the fish. In addition, many of them are assessed during gametogenesis progression, preventing any broodstock selection before the reproductive cycle induction.

Before testing the ultrasound technology, live perch used to be sexed using plasma 11-ketotestosterone levels analysis (Castets, 2011), by morphometric characters (Sirakov et al., 2012; Ulićević et al., 2017) or after euthanasia by dissection to assess ovarian maturation. It should be clarified that the gonads of male Eurasian perch consist of a pair of testicles, while female Eurasian perch have the particularity of having only one ovarian mass (and the same goes for yellow perch, *Perca flavescens*) (Craig, 2000; Treasurer & Holliday, 1981), and oocytes are structured as a gelatinous, accordion-like ribbon (Formicki et al., 2009; Probst et al., 2009).

In fish, ultrasonography (which is a non-invasive method) has been used to study internal structures, the thyroid gland, diseases (tumour and internal disorders), ocular lesions (Novelo & Tiersch, 2012), in-vivo prediction of lethal traits such as carcass yields in rainbow trout (Haffray et al., 2013) or common carp (Prchal et al., 2018) and determination of fat content (Maas et al., 2019). In the same way, since early

1980s, ultrasonography has been mainly used to determine the sex of numerous fish species, for conservation, research or aquaculture purposes. Among them, we can list coho salmon *Oncorhynchus kisutch* (Martin et al., 1983), Pacific herring *Clupea pallasii* (Bonar et al., 1989), Atlantic salmon *Salmo salar* (Mattson, 1991; Næve et al., 2018), rainbow trout *Oncorhynchus mykiss* (Reimers et al., 1987), Atlantic halibut *Hippoglossus hippo-glossus* (Martin- Robichaud & Rommens, 2001; Shields et al., 1993), striped bass *Morone saxatilis* (Blythe et al., 1994), Atlantic cod *Gadus morhua* (Karlsen & Holm, 1994; McEvoy et al., 2009), stellate sturgeon *Acipenser stellatus* (Moghim et al., 2002), shovelnose sturgeon *Scaphirhynchus platyrhynchus* (Colombo et al., 2004; Wildhaber et al., 2005), Murray cod *Maccullochella peelii peelii* (Newman et al., 2008), hapuku *Polyprion oxygeneois* (Kohn et al., 2013), European eel *Anguilla Anguilla* (Kucharczyk et al., 2016) or Chinese sturgeon *Acipenser sinensis* (Du et al., 2016).

In case of Eurasian perch, ultrasonography was first used in URAFPA laboratory (University of Lorraine, Nancy, France) in 2014, to try to characterize ovary growth during vitellogenesis, with 94% of success in sex identification 3 months after the induction of reproduction cycle, on fish of 391g mean body weight (Schaeerlinger et al., 2015). In 2016, a French hatchery (Lucas Perches, Hampont, France) started in-house sexing using ultrasonography altogether with the French Poultry and Aquaculture Breeders Technical Center (SYSAAF, Rennes, France). Promising preliminary data (on average 87% of success at first attempt on immature fish of 217g mean body weight, P. Haffray, personal communication), let us to improve the methodology in order to reduce the variability of sex identification rate success and develop a precise method directly usable for fish farmers and researchers involved in this field. Hence, the goal of our work was to show that using ultrasonography is an accurate and non-invasive way for immature Eurasian perch sex identification.

## Material and Methods

### 2.1. Fish and rearing conditions

Ultrasonography technique was used for sexing in 2 successive experiments performed in April 2018 and August 2019. Immature RAS-reared perch, which had not previously spawned, were provided by Asialor farm (Dieuze, France) and were placed under constant conditions (photoperiod: 16L:8D, temperature: 21°C and light intensity: 100 lux) to avoid gonadogenesis induction, in RAS facilities (aquaculture experimental platform, registration number for animal experimentation C54- 547- 18) belonging to the URAFPA laboratory.

Fish were tagged with passive integrated transponders (Transponder Biolog- id FDX- B, D 2.12 mm × 12 mm). For the first experiment, the total batch of 1200 perch (210 ± 73 g) was submitted to ultrasonography in June 2018 to determine their sex.

For the second experiment, a second independent batch of 950 perch (243 ± 51 g) was treated in the same way in April 2020. Among them, 270 fish were later sampled during gonadogenesis progression to confirm ultrasonography data.

Fish handling was performed following 24 hours of fasting and anaesthesia in a tricaine pharmaq solution at a dose of 150 mg/L, while making sure to buffer the solution with an equal weight of sodium bicarbonate.

All fish treatments and procedures used in this study were in accordance with the guidelines of the European Parliament

## Results

### 3.1. Ovary identification

Before gonadogenesis induction, the ovary looked on ultrasound as a dark mass in which layered transversal structures (oocytes) appeared lighter (Figure 2a). They can be easily observed in most hydrated ovaries (Figure 2c, d). After dissection, ovaries retract and appear wider and shorter than on the ultrasound scanning of the live animal (Figure 2b).

and of the Council (2010/63/EU) and the French Animal Care Guidelines

### 2.2. Ultrasonography procedure

Ultrasonography experiments were performed using a portable Esaote MyLab TM One, which is a lightweight ultrasound device with a 12" touchscreen, combined with an Esaote SL3323 linear probe operating at a frequency range of 4 to 13 MHz (maximum depth 22– 103 mm). This system can be used in complete autonomy and by a single operator. Control settings were adjusted according to the size of the fish. We used ultrasound frequency of 13 MHz, a penetration depth between 30 and 50 mm and a focus between 10 and 30 mm. In the first experiment, the probe was used on the ventral side of the fish, along the antero-posterior axis to obtain longitudinal views of the gonad (Figure 1). In the second experimentation, this longitudinal view was combined with a transversal view of the gonads performed on the ventral side of the fish perpendicularly to the antero-posterior axis.

### 2.3. Sex validation

For the first experiment, the validation of the ultrasound sex identification was obtained through dissection for organs sampling between August 2018 and March 2019 and during the reproduction season in April/May 2019. For the second experiment, sex identification was confirmed by the dissection of fish sampled between April 2020 and October 2020.

During the second experiment, data obtained with the transversal view allowed confirming that the ovary appears as a dark mass (Figure 3c, d).

### 3.2. Testis identification

During the first experiment, fish were merely determined as male when this pear-shaped ovary structure was absent from

the ultrasound scanning. Instead, only white stripes were visible (Figure 2e) potentially corresponding either to testes (Figure 2f) or other organs (e.g. digestive tract and lobes of adipose tissue). Hence, identification of males was more likely done by default as a result of the lack of visualization of the distinctive homogeneous mass of the ovary. During the second experiment, combining longitudinal and trans-versal views allowed a better visualization of the white stripes (supposed to evidence the testis) and, therefore, an improvement in the detection of the males (Figure 3a, b).

### 3.3. Sex identification validation

#### Discussion

Ultrasonography methodology has proven to be a very efficient tool to identify fish sex in several species (Blythe et al., 1994; Moghim et al., 2002; Newman et al., 2008). Therefore, this non-invasive, fast (less than 1 minute is needed to identify perch sex on anaesthetized animals) technique should reduce the fish manipulation and thus the stress compared with other methods (Guitreau et al., 2012; Novelo & Tiersch, 2012). Another advantage is that it allows to sex the fish before the initiation of gonadogenesis, at a stage where it is impossible to morphologically differentiate males from females (Zarski et al., 2015). Thus, this is useful to refine experimental designs by knowing in advance the sex ratio in batch and at the same time, to reduce the number of individuals needed in experiments (because no more oversizing is needed to end with the required number of males and females) in agreement with the 3R principle (replacement, reduction and refinement). Also, it allows to specifically target females or males, depending on the goal of the study, during fish sampling. Indeed, the sexing reliability of females is very close of 100% with criteria used in the current study, instead of randomly sampling fish and sorting males and females after dissection. Martin-Robichaud and Rommens (2001) underline the difficulty of determining the testis in several species (e.g. winter flounder, yellowtail flounder, Atlantic halibut and haddock). With perch, these same difficulties encountered in the first experiment disappeared in the second, using the transverse view. Combining longitudinal and transverse views led to high power of sex identification. Indeed, when the probe is moved transversely all along the abdomen of the fish, the homogeneous ovarian mass is clearly visible over its entire length, particularly when approaching the papilla; and in the case of a male, the white stripes seen in longitudinal views are clearly visible in cross-section. The combination of both views makes the diagnostic characters less prone to variation and the diagnosis of both sexes is improved. Previously published ultrasound studies have reported results on the accuracy of sex identification between 42 and 100%, (Blythe et al., 1994; Novelo & Tiersch, 2012), depending on species, age and maturity. When fish are immature, the identification accuracy is lower. This is the case for hybrid striped bass (Blythe et

al., 1994), Atlantic cod (Karlsen & Holm, 1994), stellate sturgeon (Moghim et al., 2002), shovelnose sturgeon (Wildhaber et al., 2005) or Chinese sturgeon (Du et al., 2016) with, respectively, 42%, 70%–80%, 76%, 56%–76% and 72%–76% accuracy. Being very close to 100% efficiency, the accuracy of the sex identification of immature perch by ultrasonography is better than those obtained with the species mentioned above. Such an effectiveness has rarely been achieved in immature individuals (sometimes even in mature fish) excepted in European river lamprey, *Lampetra fluviatilis* (Kujawa et al., 2019) and will be useful for Eurasian perch research. Being directly applicable in fish farms, the present results will significantly contribute to productivity enhancement as well as reducing production costs and, therefore, result in the improvement of Eurasian perch aquaculture. Moreover, this method may also be effective on species very close to *Perca fluviatilis* such as *Perca flavescens*.

To go further, having the possibility of evaluating ovarian maturation or gonadosomatic index (GSI) would allow further refinement of experimental protocols for scientific purposes, mainly by avoiding stressing and sacrificing fish. To do this, Esaote MyLab™ One is not precise enough to performed 3d gonad analyses or measure oocyte size. Therefore, it would be interesting to test another device to measure other parameters related to the reproduction cycle. Some studies have demonstrated that ultrasound can be used as a non-invasive tool to estimate these parameters. Næve et al., (2018) proved that GSI estimation in female Atlantic salmon is possible, and similarly, Macbeth et al., (2011) used ultrasound to determine GSI and fecundity in white sucker.

In conclusion, given these good results, ultrasound seems to be the best method that offers the possibility of improving the management of broodstock, being suitable for animal welfare requirements.

**Table 1. Titre de la Table**

Compound	TEF (WHO05)	Chemical characteristics			Transfer to milk		Transfer to hen eggs		Transfer to duck eggs TR4, % (n=1)
		Cln	Log Kow1	MW	TR2, % (n=8)	Level3	TR, % (n=4)	Level	
2,3,7,8-TCDD	1	4	6.6	322	34.0 ± 6.3	High	39.1 ± 12.6	High	2.0
1,2,3,7,8 -PeCDD	1	5	7.2	340	26.7 ± 7.1	High	35.8 ± 12.2	High	3.4
1,2,3,4,7,8-HxCDD	0.1	6	7.6	391	17.8 ± 8.0	Medium	43.3 ± 16.5	High	2.3
1,2,3,6,7,8-HxCDD	0.1	6	7.6	391	22.7 ± 7.1	Medium	40.6 ± 14.4	High	3.0
1,2,3,7,8,9-HxCDD	0.1	6	7.6	391	13.2 ± 3.4	Medium	29.1 ± 12.4	High	1.3
1,2,3,4,6,7,8-HpCDD	0.01	7	8.0	425	4.1 ± 1.3	Low	16.2 ± 6.2	Medium	1.1
OCDD	0.0003	8	8.4	460	1.2 ± 0.8	Low	6.8 ± 4.8	Low	1.0
2,3,7,8-TCDF	0.1	4	6.5	306	3.4 ± 2.9	Low	39.1 ± 16.8	High	6.4
1,2,3,7,8-PeCDF	0.03	5	7.0	340	4.9 ± 4.5	Low	38.0 ± 7.4	High	4.5
2,3,4,7,8-PeCDF	0.3	5	7.1	340	35.6 ± 14.8	High	40.0 ± 10.1	High	4.8
1,2,3,4,7,8-HxCDF	0.1	6	7.5	375	19.3 ± 8.9	Medium	39.8 ± 13.0	High	2.5
1,2,3,6,7,8-HxCDF	0.1	6	7.6	375	17.7 ± 6.0	Medium	37.3 ± 16.1	High	2.4
1,2,3,7,8,9-HxCDF	0.1	6	7.7	375	10.7 ± 7.0	Medium	25.6 ± 13.0	High	1.9
2,3,4,6,7,8-HxCDF	0.1	6	7.6	375	11.6 ± 8.7	Medium	23.0 ± 16.5	Medium	0.8
1,2,3,4,6,7,8-HpCDF	0.01	7	8.0	409	3.1 ± 1.1	Low	16.6 ± 10.7	Medium	0.7
1,2,3,4,7,8,9-HpCDF	0.01	7	8.2	409	4.6 ± 1.3	Low	17.8 ± 8.7	Medium	1.1
OCDF	0.0003	8	8.6	443	1.0 ± 1.3	Low	4.0 ± 2.5	Low	0.1

**Bold mean integrated article in our dataset**

1 Statement of steady state (SS) given by the authors or in brackets when statement was made by us.

2 TR- transfer rate, BCF – bioconcentration factor, BA- bioavailability, BTF- biotransfer factor. MISS – missing data. Values of the parameters taken from the authors or in brackets when re-calculated by us.

3 C – concentrations, Q-quantities where ✓ = given in the article; (✓) = Recalculated; X= not available

4 Compounds that below limit of quantification (LQ)

5 Decision of integration (✓) or not (X) of the given study in our dataset.

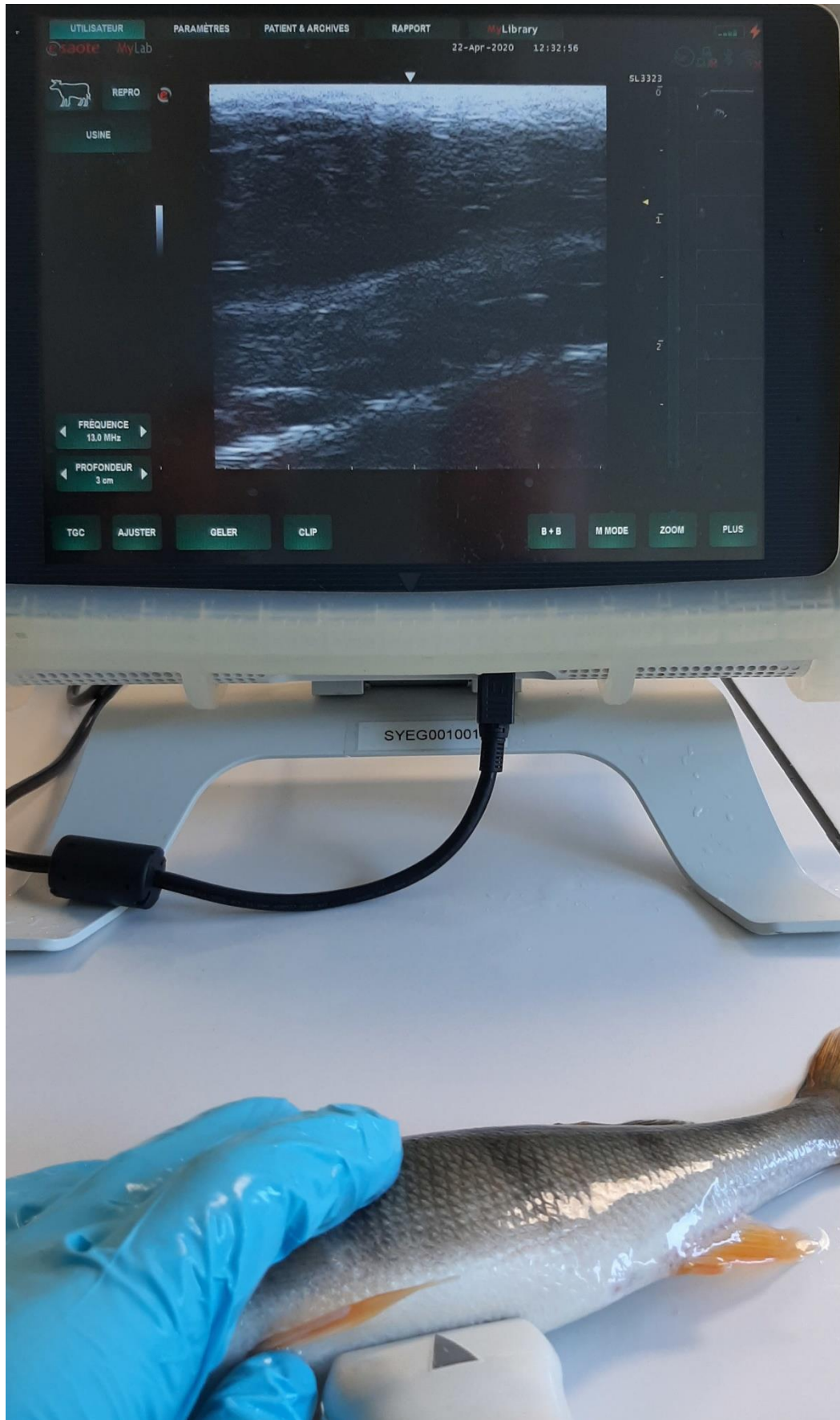
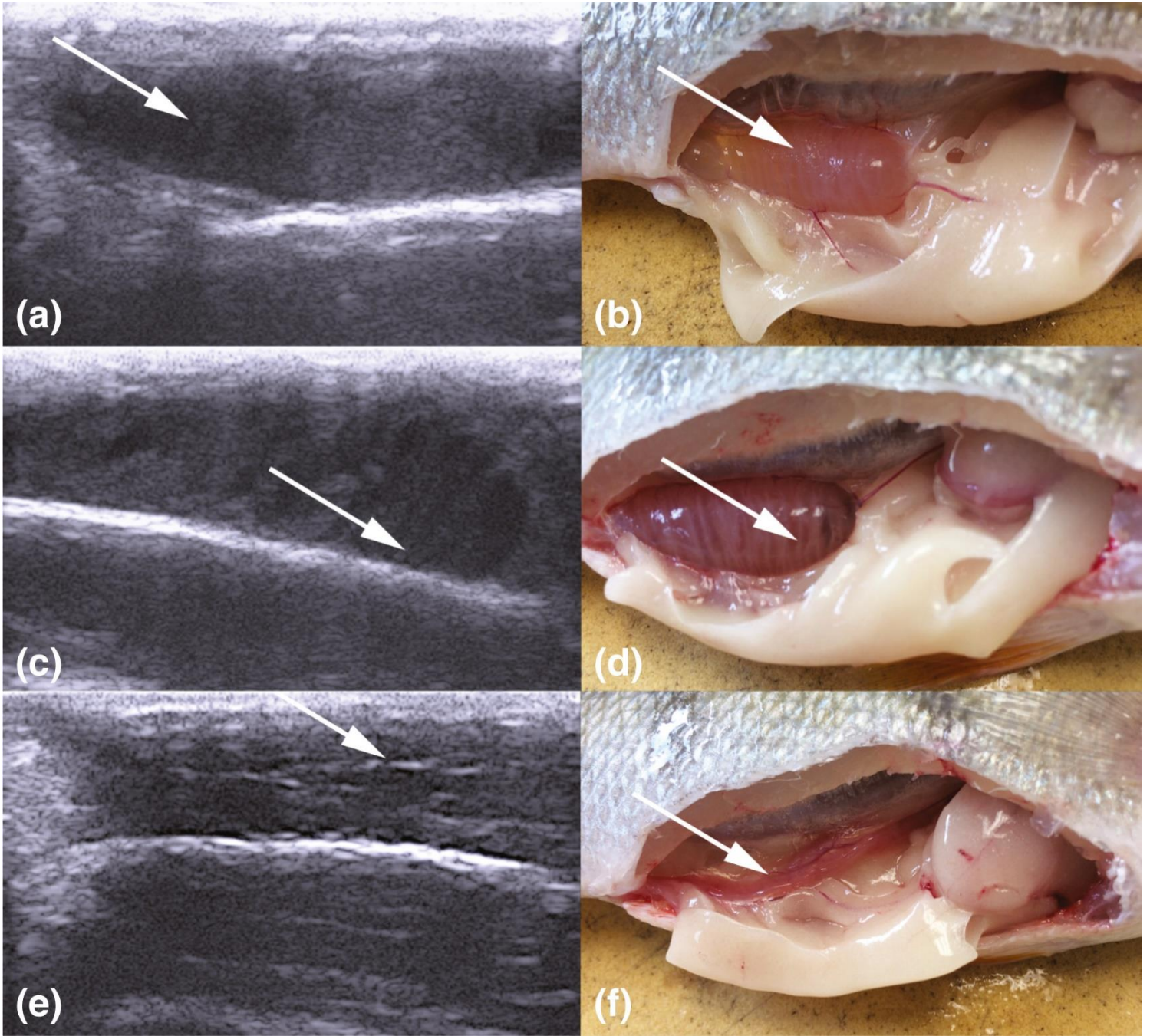
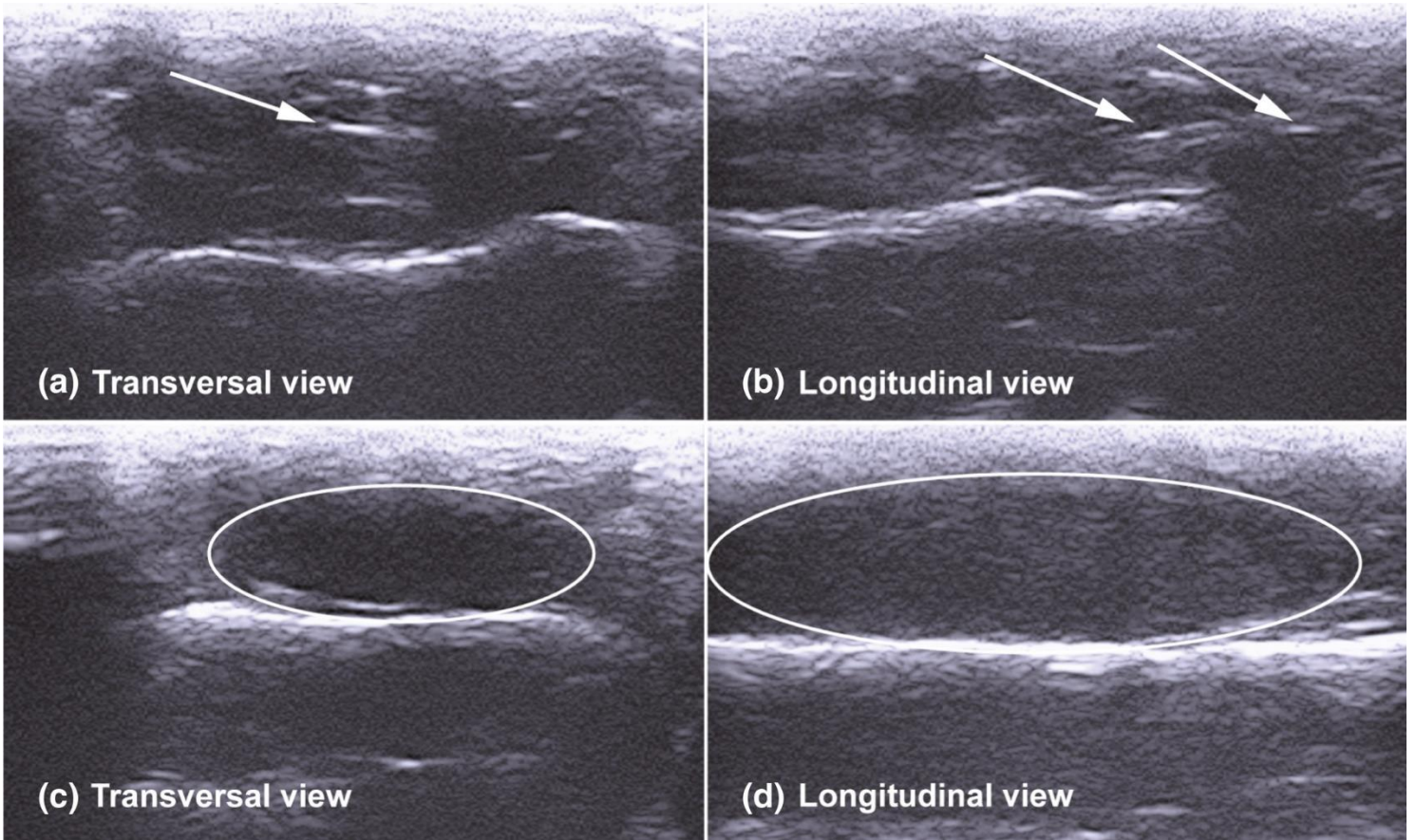


Figure 1. Ultrasound device and scanning area on an anaesthetized Eurasian perch (*Perca fluviatilis*)





**Figure 2. Comparison of gonad dissection and corresponding ultrasonic images in Eurasian perch (*Perca fluviatilis*)**  
 Ultrasonic image of ovary in longitudinal view; (b) Dissection of the corresponding female; (c) Ultrasonic image of highly hydrated ovary in longitudinal view; (d) Dissection of the corresponding female; (e) Ultrasonic images of testis in longitudinal view; (f) Dissection of the corresponding male. White arrows indicate visible oocyte layers in a-d, characteristic white stripes in (e) and the testis in (f)



**Figure 3. Ultrasonic images of male (a, b) and female (c, d) gonads in Eurasian perch (*Perca fluviatilis*), in both longitudinal (b, d) and transversal views (a, c)**  
Ovary is circled and arrows indicate distinctive white stripes (testis)



## References

- Abdulfatah, A., Fontaine, P., Kestemont, P., Gardeur, J. N., & Marie, M. (2011). Effects of photothermal kinetics and amplitude of photoperiod decrease on the induction of the reproduction cycle in female Eurasian perch *Perca fluviatilis*. *Aquaculture*, 322, 169–176. <https://doi.org/10.1016/j.aquaculture.2011.09.002>.
- Abdulfatah, A., Fontaine, P., Kestemont, P., Milla, S., & Marie, M. (2013). Effects of the thermal threshold and the timing of temperature reduction on the initiation and course of oocyte development in cultured female of Eurasian perch *Perca fluviatilis*. *Aquaculture*, 376, 90–96. <https://doi.org/10.1016/j.aquaculture.2012.11.010>.
- Blythe, W. G., Helfrich, L. A., Beal, W. E., Bosworth, B., & Libey, G. S. (1994). Determination of sex and maturational status of striped bass (*Morone saxatilis*) using ultrasonic imaging. *Aquaculture*, 125, 175–184. [https://doi.org/10.1016/0044-8486\(94\)90294-1](https://doi.org/10.1016/0044-8486(94)90294-1).
- Bonar, S. A., Thomas, G. L., Pauley, G. B., & Martin, R. W. (1989). Use of ultrasonic images for rapid nonlethal determination of sex and maturity of Pacific herring. *North American Journal of Fisheries Management*, 9, 364–366.
- Castets, M. D. (2011). Fonction de reproduction et régulation de la qualité chez la perche commune *Perca fluviatilis*. *Sciences agricoles*. Institut National Polytechnique de Lorraine.
- Colombo, R. E., Wills, P. S., & Garvey, J. E. (2004). Use of ultrasound imaging to determine sex of shovelnose sturgeon. *North American Journal of Fisheries Management*, 24, 322–326. <https://doi.org/10.1577/M03-016>.
- Craig, J. F. (2000). *Percid fishes: Systematics, ecology and exploitation*. Blackwell Science.
- Du, H., Zhang, X., Leng, X., Zhang, S., Luo, J., Liu, Z., Qiao, X., Kynard, B., & Wei, Q. (2016). Gender and gonadal maturity stage identification of captive Chinese sturgeon, *Acipenser sinensis*, using ultrasound imagery and sex steroids. *General and Comparative Endocrinology*, 245, <https://doi.org/10.1016/j.ygcen.2016.08.004>.
- Fontaine, P. (2009). Développement de la pisciculture continentale européenne et domestication de nouvelles espèces. *Cahiers Agricoles*, 18, 144–147. <https://doi.org/10.1684/agr.2009.0288>.
- Fontaine, P., & Teletchea, F. Domestication of the Eurasian Perch (*Perca fluviatilis*). 2019. In *Animal Domestication*. <https://doi.org/10.5772/intechopen.85132>
- Fontaine, P., Wang, N., & Hermelink, B. (2015). Broodstock management and control of the reproductive cycle. *Biology and culture of percid fishes* (pp. 103–122). Springer.
- Formicki, K., Smaruj, I., Szulc, J., & Winnicki, A. (2009). Microtubular network of the gelatinous egg envelope within the egg ribbon of European perch, *Perca fluviatilis* L. *Acta Ichthyologica Et Piscatoria*, 39(2), 147.
- Griffiths, R., Orr, K. L., Adam, A., & Barber, I. (2000). DNA sex identification in the three-spined stickleback. *Journal of Fish Biology*, 57, 1331–1334.
- Guitreau, A. M., Eilts, B. E., Novelo, N. D., & Tiersch, T. R. (2012). Fish handling and ultrasound procedures for viewing the ovary of submersed, nonanesthetized, unrestrained Channel catfish. *North American Journal of Aquaculture*, 74(2), 182–187. <https://doi.org/10.1080/15222055.2012.655852>.
- Haffray, P., Bugeon, J., Rivard, Q., Quittet, B., Puyo, S., Allamellou, J.-M., Vandeputte, M., & Dupont-Nivet, M. (2013). Genetic parameters of in-vivo prediction of carcass, head and fillet yields by internal ultrasound and 2D external imagery in large rainbow trout (*Oncorhynchus mykiss*). *Aquaculture*, 410–411, 236–244. <https://doi.org/10.1016/j.aquaculture.2013.06.016>.
- Hurvitz, A., Jackson, K., Degani, G., & Levavi-Sivan, B. (2007). Use of endoscopy for gender and ovarian stage determinations in Russian sturgeon (*Acipenser gueldenstaedtii*) grown in aquaculture. *Aquaculture*, 270, 158–166.
- Kano, Y. (2005). Sexing fish by palpation: A simple method for gonadal assessment of fluvial salmonids. *Journal of Fish Biology*, 66, 1735–1739. <https://doi.org/10.1111/j.0022-1112.2005.00706.x>.
- Karlson, O., & Holm, J. C. (1994). Ultrasonography, a noninvasive method for sex determination in cod (*Gadus morhua*). *Journal of Fish Biology*, 44, 965–971.
- Kohn, Y. Y., Lokman, P., Kilimnik, A., & Symonds, J. E. (2013). Sex identification in captive hāpuku (*Polyprion oxygeneios*) using ultrasound imagery and plasma levels of vitellogenin and sex steroids. *Aquaculture*, 384–387, 87–93.
- Kucharczyk, D., Żarski, D., Krejszef, S., Nowosad, J., Bilas, M., Targonska, K., & Palinska-Zarska, K. (2016). Use of an ultrasound device to determine sex and to perform gonad biopsy in the European eel *Anguilla anguilla*. *Brazilian Journal of Veterinary Research and Animal Science*, 53(2), 199. <https://doi.org/10.11606/issn.1678-4456.v53i2p199-206>.
- Kujawa, R., Nowosad, J., Biegaj, M., Cejko, B. I., & Kucharczyk, D. (2019). Use of ultrasonography to determine sex in sexually immature European river lamprey *Lampetra fluviatilis* (L.). *Animal Reproduction Science*, 204, 95–100. <https://doi.org/10.1016/j.anire.2019.03.009>.
- Le Bail, P. Y., & Breton, B. (1981). Rapid determination of the sex of puberal salmonid fish by a technique of immunoagglutination. *Aquaculture*, 22, 367–375. [https://doi.org/10.1016/0044-8486\(81\)90163-0](https://doi.org/10.1016/0044-8486(81)90163-0).
- Maas, P., Grzegorzóka, B., Kreß, P., Oberle, M., & Kremer-Rücker, P. V. (2019). In vivo – determination of the fat content in mirror carps (*Cyprinus carpio*) using ultrasound, microwave and linear measurements. *Aquaculture*, 512, 734359. <https://doi.org/10.1016/j.aquaculture.2019.734359>.
- Macbeth, B. J., Frimer, H. D., Muscatello, J. R., & Janz, D. M. (2011). Use of portable ultrasonography to determine ovary size and fecundity non-lethally in northern pike (*Esox lucius*) and white sucker (*Catostomus commersoni*). *Water Quality Research Journal of Canada*, 46, 43–51. <https://doi.org/10.2166/wqrj.2011.011>.
- Martin, R. W., Myers, J., Sower, S. A., Phillips, D. J., & McAuley, C. (1983). Ultrasonic imaging a potential tool for sex determination of live fish. *North American Journal of Fisheries Management*, 3, 258–264.
- Martin-Robichaud, D. J., & Rommens, M. (2001). Assessment of sex and evaluation of ovarian maturation of fish using ultrasonography. *Aquaculture Research*, 32, 113–120. <https://doi.org/10.1046/j.1365-2109.2001.00538.x>.
- Mattson, N. S. (1991). A new method to determine sex and gonad size in live fishes by using ultrasonography. *Journal of Fish Biology*, 39, 673–677. <https://doi.org/10.1111/j.1095-8649.1991.tb04397.x>.
- McEvoy, F. J., Tomkiewicz, J., Støttrup, J. G., Overton, J. L., McEvoy, C., & Svalastoga, E. (2009). Determination of fish gender using fractal analysis of ultrasound images. *Veterinary Radiology and Ultrasound*, 50, 519–524. <https://doi.org/10.1111/j.1740-8261.2009.01568.x>.
- Melillo Filho, R., Gheller, V. A., Chaves, G. V., de Souza e Silva, W., Costa, D. C., Figueiredo, L. G., da Costa Julio, G. S., & Luz, R. K. (2016). Early sexing techniques in *Lophosilurus alexandri* (Steindachner, 1876), a freshwater carnivorous catfish. *Theriogenology*, 86, 1523–1529. <https://doi.org/10.1016/j.theriogenology.2016.05.011>.
- Moghim, M., Vajhi, A. R., Veshkini, A., & Masoudifard, M. (2002). Determination of sex and maturity in *Acipenser stellatus* by using ultrasonography. *Journal of Applied Ichthyology*, 18, 325–328. <https://doi.org/10.1046/j.1439-0426.2002.00423.x>.
- Næve, I., Mommens, M., Arukwe, A., & Kjærsvik, E. (2018). Ultrasound as a noninvasive tool for monitoring reproductive physiology in female Atlantic salmon (*Salmo salar*). *Physiology Reports*, <https://doi.org/10.14814/phy2.13640>.
- Newman, D. M., Jones, P. L., & Ingram, B. A. (2008). Sexing accuracy and indicators of maturation status in captive Murray cod *Maccullochella peelii peelii* using non-invasive ultrasonic imagery. *Aquaculture*, 279, 113–119. <https://doi.org/10.1016/j.aquaculture.2008.03.032>.
- Novelo, N. D., & Tiersch, T. R. (2012). A review of the use of ultrasonography in fish reproduction. *North American Journal of Aquaculture*, 74, 169–181. <https://doi.org/10.1080/15222055.2012.672370>.
- Prchal, M., Bugeon, J., Vandeputte, M., Kause, A., Vergnet, A., Zhao, J., Gela, D., Genestout, L., Bestin, A., Haffray, P., & Kocour, M. (2018). Potential for genetic improvement of the main slaughter yields in common carp with in vivo morphological predictors. *Frontiers in Genetics*, 9, 283. <https://doi.org/10.3389/fgene.2018.00283>.
- Probst, W. N., Stoll, S., Hofmann, H., Fischer, P., & Eckmann, R. (2009). Spawning site selection by eurasian perch (*Perca fluviatilis* L.) in relation to temperature and wave exposure. *Ecology of Freshwater Fish*, 18, 1–7.
- Reimers, E., Landmark, P., Sorsdal, T., Bohmer, E., & Solum, T. (1987). Determination of salmonids' sex, maturation and size: an ultra-sound and photocell approach. *Aquaculture*, 13, 41–44.
- Ritchie, D. E. (1965). Sex determination of live striped bass, *Roccus saxatilis* (Walbaum), by biopsy technique. *Chesapeake Science*, 6(3), 141–145. <https://doi.org/10.2307/1350845>.
- Schaerlinger, B., Staub, C., Touze, J. C., Chardard, D., Krauss, D., Ledore, Y., Alix, M., & Fontaine, P. (2015). Sex determination and egg quality evaluation in the Eurasian perch, *Perca fluviatilis*, using ultrasonography. 5. International Workshop on the Biology of Fish Gametes, Università Politecnica delle Marche. ITA., Sep 2015, Ancona, Italy. 290 p. hal-02739567.
- Shields, R. J., Davenport, J., Young, C., & Smith, P. L. (1993). Oocyte maturation and ovulation in the Atlantic halibut, *Hippoglossus hippoglossus* (L.), examined using ultrasonography. *Aquaculture Research*, 24, 181–186.
- Sirakov, I., Staykov, Y., Ivancheva, E., Nikolov, G., & Atanasoff, A. (2012). Morphometric characteristic of European perch (*Perca fluviatilis*) related to sex dimorphism. *Agriculture Science and Technology*, 4, 203–207.
- Stejskal, V., Kouril, J., Musil, J., Hamackova, J., & Policar, T. (2009). Growth pattern of all-female perch (*Perca fluviatilis* L.) juveniles – is monosex perch culture beneficial? *Journal of Applied Ichthyology*, 25, 432–437.
- Treasurer, J. W., & Holliday, F. G. T. (1981). Some aspects of the reproductive biology of perch *Perca fluviatilis* L. A histological description of the reproductive cycle. *Journal of Fish Biology*, 18, 359–376.
- Uličević, M., Mrđak, D., Talevski, T., & Milošević, D. (2017). Sexual Dimorphism of European Perch, *Perca fluviatilis* Linnaeus, 1758 from Lake Skadar (Montenegro) Based on Morphometric Characters. *Turkish Journal of Fisheries and Aquatic Sciences*, 18, [https://doi.org/10.4194/1303-2712-v18\\_2\\_13](https://doi.org/10.4194/1303-2712-v18_2_13).
- Vecsei, P., Litvak, M. K., Noakes, D. L. G., Rien, T., & Hockleithner, M. (2003). A noninvasive technique for determining sex of live adult North American sturgeons. *Environmental Biology of Fishes*, 68, 333–338. <https://doi.org/10.1023/B:EBFI.000005732.98047.f3>.
- Wildhaber, M. L., Papoulias, D. M., DeLonay, A. J., Tillitt, D. E., Bryan, J. L., Annis, M. L., & Allert, J. A. (2005). Gender identification of shovel-nose sturgeon using ultrasonic and endoscopic imagery and the application of the method to the pallid sturgeon. *Journal of Fish Biology*, 67, 114–132. <https://doi.org/10.1111/j.0022-1112.2005.00719.x>.
- Żarski, D., Horváth, A., Held, J. A., & Kucharczyk, D. (2015). Artificial reproduction of percid fishes. *Biology and culture of percid fishes* (pp. 123–161). Springer.
- Żarski, D., Palinska-Zarska, K., Krejszef, S., Krol, J., Milla, S., Fontaine, P., Bokor, Z., & Urbanyi, B. (2019). A novel approach for induced out-of-season spawning of Eurasian perch, *Perca fluviatilis*. *Aquaculture*, 512(1), 734300.

## Acknowledgements

This study was partly supported by the PERCIHATCH program (funding by the European Maritime and Fisheries Fund and FranceAgrimer project) and Sex'NPerch program (funding by the European Maritime and Fisheries Fund and FranceAgrimer

project). We thank Guillaume Boucaud, Federica Ferrando and Nicolas Santos from Lucas Perches for their enthusiasm to test and develop this sexing technique on their fish