



**HAL**  
open science

## Further refining the critical region of 10q26 microdeletion syndrome: A possible involvement of INSYN2 and NPS in the cognitive phenotype

Florian Cherik, Mathis Lepage, Ganaelle Remerand, Christine Francannet,  
Amélie Delabaere, Gaëlle Salaun, Céline Pebrel-Richard, Laetitia Gouas,  
Philippe Vago, Andrei Tchirkov, et al.

### ► To cite this version:

Florian Cherik, Mathis Lepage, Ganaelle Remerand, Christine Francannet, Amélie Delabaere, et al.. Further refining the critical region of 10q26 microdeletion syndrome: A possible involvement of INSYN2 and NPS in the cognitive phenotype. *European Journal of Medical Genetics*, 2021, 64 (9), pp.104287. 10.1016/j.ejmg.2021.104287 . hal-03345219

**HAL Id: hal-03345219**

**<https://hal.science/hal-03345219v1>**

Submitted on 2 Aug 2023

**HAL** is a multi-disciplinary open access archive for the deposit and dissemination of scientific research documents, whether they are published or not. The documents may come from teaching and research institutions in France or abroad, or from public or private research centers.

L'archive ouverte pluridisciplinaire **HAL**, est destinée au dépôt et à la diffusion de documents scientifiques de niveau recherche, publiés ou non, émanant des établissements d'enseignement et de recherche français ou étrangers, des laboratoires publics ou privés.



Distributed under a Creative Commons Attribution - NonCommercial 4.0 International License

**Title: Further refining the critical region of 10q26 microdeletion syndrome: a possible involvement of *INSYN2* and *NPS* in the cognitive phenotype**

**Authors and institutions:**

**Florian Cherik<sup>4</sup>, Mathis Lepage<sup>1</sup>, Ganaelle Remerand<sup>5</sup>, Christine Francannet<sup>4</sup>, Amélie Delabaere<sup>3</sup>, Gaëlle Salaun<sup>1,2</sup>, Céline Pebrel-Richard<sup>1</sup>, Laetitia Gouas<sup>1,2</sup>, Philippe Vago<sup>1,2</sup>, Andrei Tchirkov<sup>1,2</sup>, Carole Goumy<sup>1,2</sup>**

<sup>1</sup>*Cytogénétique Médicale, CHU Clermont-Ferrand, CHU Estaing, F-63000, France*

<sup>2</sup>*Université Clermont Auvergne, INSERM, U1240 Imagerie Moléculaire et Stratégies Théranostiques, F-63000 Clermont Ferrand, France*

<sup>3</sup>*Unité de Médecine Fœtale, CHU Clermont-Ferrand, France*

<sup>4</sup>*Service de Génétique Médicale, CHU Clermont-Ferrand, CHU Estaing, F-63000, France*

<sup>5</sup>*Service de Pédiatrie, CHU Clermont-Ferrand, CHU Estaing, F-63000, France*

**Corresponding author:**

Doctor Carole GOUMY

Cytogénétique Médicale

CHU Estaing

1 place Lucie et Raymond Aubrac

63003 Clermont-Ferrand Cedex 1 – France

Tel: +33 (0)4 73 750 708

Fax: +33 (0)4 73 750 704

E-mail: [cgoumy@chu-clermontferrand.fr](mailto:cgoumy@chu-clermontferrand.fr)

## **Abstract**

**Background:** The 10q26 subtelomeric microdeletion syndrome is a rare and clinically heterogeneous disorder. The precise relationships between the causative genes and the phenotype are unclear.

**Case presentation:** We report two new cases of 860 kb deletion of 10q26.2 identified by array CGH in a fetus with intrauterine growth retardation and his mother. The deleted region encompassed only four coding genes, *DOCK1*, *INSYN2*, *NPS* and *FOX12*. The proband had dysmorphic facies characterized by a high forehead, malformed ears, a prominent nose, and retrognathia. He had bilateral club feet, clinodactily and mild psychomotor retardation. His mother had a short stature, microcephaly, a long face with a high forehead and bitemporal narrowing, arched and sparse eyebrows, strabismus, prominent nose and chin, a thin upper lip and large protruding ears, and mild intellectual disability.

**Conclusions:** This study presents the smallest 10q26.2 deletion so far identified, which further refines the minimal critical region associated with the 10q26 microdeletion syndrome. It focuses on three genes potentially responsible for the phenotype: *DOCK1*, which is the major candidate gene, and *INSYN2* and *NPS*, which could be involved in cognitive functions.

**Key Words:** 10q26 deletion, minimal critical region, *DOCK1*, *INSYN2*, *NPS*, intellectual disability, growth failure

**Running title:** GOUMY et al: CRITICAL REGION OF 10q26 MICRODELETION SYNDROME

## **Background**

More than 100 cases of 10q26 deletion syndrome have been reported in the literature. The location and size of the deletions vary. A minimal critical region corresponding to the smallest region of deletion overlap has been proposed by Yatsenko et al. (2009). However, the precise relationships between the causative genes and the phenotype are unclear and this critical region is still controversial. The most common clinical features of 10q26 deletion syndrome include craniofacial anomalies, prenatal and/or postnatal growth retardation, microcephaly, intellectual disability, and developmental delay (Plaisancié et al., 2014; Iourov et al., 2014; Tanteles et al., 2015; Faria et al., 2016; Laudier et al., 2016; Lin et al., 2016). Urogenital anomalies, congenital heart disease and ophthalmologic defects are also observed (Sutani et al., 2019). The present study reports two new cases of 10q26.2 deletion in a proband and his mother, which contribute to further refine the critical region and identify two potential novel candidate genes.

## **Case presentation**

A 21-year-old pregnant woman was referred for prenatal diagnosis because fetal ultrasound examination at 28 weeks of gestation showed IUGR and bilateral club feet. Fetal biometry measurements at 30 weeks (and 5 days) were as follows: biparietal diameter of 68.5 mm (5<sup>th</sup> < centile), the abdominal circumference of 225.3 mm (5<sup>th</sup> < centile) and femur length of 51.1 mm (5<sup>th</sup> < centile). Amniotic fluid volume was normal. Amniocentesis was performed and conventional cytogenetic analysis showed a 46,XY karyotype at a 400 band resolution level. Array-CGH analysis (Agilent Human genome CGH 60K microarray, Agilent technologies, Santa Clara, CA, USA) showed an 860 kb interstitial deletion at chromosome band 10q26.2: arr[GRCh37] 10q26.2(128771757\_129634868)x1 (Fig. 1A). The deletion was confirmed by FISH using BAC clone RP-348P18 (Fig. 1A). Parental FISH analyses showed that the deletion was inherited from the mother. Also, array-CGH performed in the mother confirmed that the deletion size was the same in the mother and proband. The copy-number variant and patient data were submitted to the ClinVar database (Accession number: VCV000992896.1, variation ID: 992896) and publicly available.

The parents decided to continue the pregnancy after receiving counseling based on the results of cytogenetic testing. A boy (proband) was born prematurely at 34 WA + 5 days with a birth weight of 1420 g (-2.4 SD), length of 40.5 cm (-2.1 SD) and head circumference of 27.5 cm (-2.8 SD). SDs for birth measurements were calculated using the Fenton growth charts (Fenton and Kim, 2013). APGAR score was 4-8-6-10. He was transferred to pediatric intensive care because of respiratory distress. He had a high forehead, malformed ears (left ear: cleft helix; right ear: overfolded helix, the serpiginous stem of antihelix), a prominent nose, a flat philtrum, a thin vermilion of the upper lip, retrognathia, bilateral club feet and clinodactyly (Fig. 2, A and B). Ultrasonic cardiography showed patent foramen ovale (normalized at 6 months), and abdominal ultrasound mild bilateral pyelectasis. Transfontanellar and spinal cord ultrasound examinations were normal as were ophthalmoscopy and auditory evoked response. He required parenteral nutrition in the early postnatal period.

The proband was the first child of non-consanguineous parents. He had a mild delay in psychomotor development: head control was normal, he was able to sit at 9 months, to move on all fours at 15 months, to stand at 17 months but was still unable to walk at 20 months because of leg hypotonia (with abolished tendon reflexes) and his bilateral club feet. He was fitted with a Ponseti splint and underwent orthopedic surgery. His spine column was straight. His fine motor skills were also delayed. His arm tonus was normal, he was able to grasp with the thumb and index at 12 months, to play with construction toys at 15 months, but could not eat with a spoon on his own. His language at 20 months was delayed consisting of only a few syllables and no finger-pointing. He did not have any feeding or sleeping difficulties. Brunet-Lézine Scale (French scale of psychomotor development of children) performed at the age of 19 months confirmed the presence of developmental delay. The developmental quotient (DQ) for gross motor function, language and sociability corresponded to the age of 10 months. For fine motor function, DQ corresponded to an age of 12 months. The global DQ corresponded to the age of 10 months.

On the last clinical examination, at 21.5 months of age, his length, weight and head circumference were respectively 80 cm (-1.5 SD), 10kg (-1.7 SD) and 45cm (-3 SD). The weight-for-length Z score was in the normal range. Cardiopulmonary and abdominal assessments were normal. Neurological examination showed hypotonia and absent tendon reflexes in the lower limbs. There was no other neurological feature. Following facial features were observed: occipital plagiocephaly, high forehead with slight temporal retraction, palpebral edema, short nose with anteverted nostrils, long and flat philtrum with thin

vermilion of the upper lip, slightly everted lower lip and micrognathia (Fig 2, C and D). Palmar creases were deep. Bilateral patellar and sacral dimples were observed.

The proband's mother presented walking disorders and running difficulties in infancy. At the age of 9 and 15 years, she underwent orthopedic surgery for progressive bilateral equinovarus hollow feet. Her father and brother also had hollow feet. The electromyogram performed at the age of 23 years showed axonal motor neuropathy without demyelinating features and sensory impairment. Club feet have never been described in the 10q26 deletion syndrome. They are possibly linked to Charcot-Marie-Tooth disease. The sequencing of a panel of genes involved in Charcot-Marie-Tooth diseases was requested. At the time of writing this paper, the result is not yet available. She had significant school difficulties. She refused consent for IQ testing.

On the last examination, at the age of 23 years, her height and head circumference were respectively 153.5cm (-1.5 SD) and 52,5cm (-1.9 SD). She had the following facial features: a long face with a high forehead and bitemporal narrowing, arched and sparse eyebrows, divergent strabismus of the right eye, prominent nose and chin, a thin vermilion of the upper lip and large protruding ears. (Fig 2, E and F). She had joint hyperlaxity, tapered lower extremities, and short high-arched feet with significant overlap of the 5<sup>th</sup> toe on the 4<sup>th</sup>. Tendon reflexes were present.

## **Discussion**

We report the smallest 10q26.2 deletion documented so far in the literature. This 860 kb deletion encompassed seven genes of which only four were coding genes: *DOCK1*, *INSYN2* (*FAM196A*), *NPS* (neuropeptide S) and *FOXI2* (Fig. 1). Yatsenko et al. [1] proposed a 600 kb critical region encompassing two coding genes (*DOCK1* and *C10orf90*) (Fig. 1B). All the patients with a deletion including this smallest critical region have craniofacial dysmorphism, various degrees of mental retardation and growth failure. Strabismus is also a frequent feature. However, wide clinical heterogeneity associated with variability in deletion size has been reported [Plaisancié et al., 2014; Iourov et al., 2014; Tanteles et al., 2015; Faria et al, 2016; Laudier et al., 2016; Lin et al., 2016; Sutani et al., 2019].

The phenotype of the proband's mother was similar to that of a patient of the same age reported by Tanteles et al. who had a 6.3 Mb deletion including *CALY* and partially deleted *DOCK1* associated with a very mild neurocognitive deficit, strabismus and similar facial features (Tanteles et al., 2015). The patient described by Laudier et al. had a deletion of 6.5

Mb with similar breakpoints. She was of short stature at birth and in adulthood and had no intellectual disability or behavioral problems (Laudier et al., 2016). Such observations show the phenotypic variability of the 10q26 deletion and in particular the variable degree of intellectual disability. The overlapping deleted region of these two cases and that of our patients is about 500 kb (129,142,062-129,634,868) and encompasses only three coding genes, *DOCK1*, *INSYN2* and *NPS*. (Fig 1B).

Five DECIPHER patients have an overlapping deletion of short size (<6 Mb) with reported phenotype and without another pathogenic CNV (Fig 1B, Table 1). Among them, two are < 400 kb and are of particular interest to establish phenotype-genotype correlations. Patient 269388 is a boy with a deletion of 390.2 kb, encompassing *DOCK1* and *INSYN2A*, who present long face, convex nasal ridge, downslanted palpebral fissures, thick upper lip vermilion, low-set ears, prominent ear helix, hypertelorism, ptosis, strabismus, renal agenesis, anal atresia, clinodactyly of the 5<sup>th</sup> finger, macrocephaly and muscular hypotonia. He had cognitive impairment and emotional lability and an EEG with generalized polyspikes. Patient 386949 is a girl with a 336 kb deletion encompassing *NPS* and *FOXI2* presenting behavioral abnormality.

Previous studies identified *DOCK1* (MIM: 601403) as the major candidate gene in the 10q26 deletion syndrome. *DOCK1* encodes an exchange factor for Rho GTPase, which is involved in the regulation of several cellular activities including control of cell morphology, polarity, migration, adhesion to extracellular matrix proteins or other cells, proliferation, apoptosis, tumorigenesis, phagocytosis, vesicular transport and transcription (Gadea and Blangy, 2014). Its deregulation was described as being linked to central nervous system disorders (Cook et al., 2014). Recently, Cunningham *et al.* (2018) showed that mutations in *DOCK1* result in defects in Schwann cell development and myelination in zebrafish. Despite the biologically important role of *DOCK1*, this gene is not expected to cause a dominant disease since the loss-of-function intolerance score (pLI) for this gene is equal to 0 (gnomAD).

Urogenital anomalies are occasional findings in patients with 10q26 deletion syndrome (Ogata et al., 2000; Irving et al., 2003; Miller et al., 2009; Vera-Carbonell et al., 2015). Yatsenko et al. (2009) narrowed the critical region for urogenital defects to the segment between the *DOCK1* and *TCERGIL* genes. Although the *DOCK1* gene has been previously proposed as a possible candidate for causing genitourinary anomalies, Vera-Carbonell et al. (2015) suggested that two other genes, *CTBP2* and *FGFR2*, could also play a role in urinary tract

development. No genital nor renal/urinary tract malformation was observed in our two patients, suggesting that *DOCK1* is not involved in the genitourinary tract phenotype.

Plaisancié et al. (2014) described four patients with a distal 10q26 deletion who had attention-deficit/hyperactivity disorder (ADHD) and suggested that haploinsufficiency of the *CALY* gene could play a crucial role in the development of behavioral troubles in these patients. *CALY* was not deleted in our patients (Fig 1B) and the mother had no behavioral problems, suggesting that *DOCK1* and the three other coding genes included in the deletion of our patients are not involved in the development of behavioral disturbances.

Of the other three genes in the deleted region, two could also play a role in the development of cognitive functions. *INSYN2* (MIM: 617129) is a component of a protein complex that regulates postsynaptic inhibition in the newborn mouse brain and could contribute to developmental brain disorder (Uezu et al., 2016). This gene has a high probability of belonging to the haploinsufficient class with the pLI score of 0.91. *NPS* (MIM: 609513) is a bioactive neuropeptide that modulates the expression of selected emotional and social behavior (Grund and Neumann, 2018 and 2019). However, the signaling mechanisms underlying the behavioral effects of *NPS* and the interaction with other brain neuropeptides are still unknown. The pLI score of this gene is equal to 0. *FOXI2* (MIM: 617202) is a forkhead transcription factor. Forkhead transcription factors are key regulators of embryonic development. They share a highly conserved DNA-binding forkhead domain and are conserved in a large variety of species (Wijchers et al., 2005). The pLI score of *FOXI2* is equal to 0.

In conclusion, investigation of these two additional patients has defined an 860 kb critical interval for 10q26 microdeletion syndrome that harbors only four coding genes, *DOCK1*, *INSYN2* (*FAM196A*), *NPS* and *FOXI2*, and delineated the clinical spectrum of the syndrome comprising growth failure, microcephaly, moderate intellectual disability, strabismus and craniofacial dysmorphism with prominent nose and chin, malformed or large ears and a thin upper lip. The overlapping of the deleted region in our patients with that of previously reported cases determines a novel minimal critical region of about 500 kb encompassing only three coding genes, *DOCK1*, *INSYN2* and *NPS*. Thus, this study reinforces the hypothesis that haploinsufficiency of *DOCK1* is the major cause of the 10q26.2 microdeletion syndrome. However, it is also possible that *NPS*, or especially *INSYN2*, which had a high pLI score, are involved in the neurodevelopmental phenotype of this syndrome. The disruption of several



genes may contribute to specific phenotypic features discussed in our patients, suggesting the possibility of a contiguous gene syndrome.

**Funding:** None

**Authors' contributions:** CG interpreted the data and wrote the manuscript. ML, GR, CF and AD carried out the clinical prenatal and postnatal investigations. GS, CPR, PV and AT contributed to the revision of the article. All authors read and approved the final manuscript.

**Competing interests:** The authors declare that they have no competing interests.

**Consent for publication:** We had the consent of the patient's parents for including images and other information relating to the case report in the manuscript submitted for consideration of publication. The parents provided informed consent for participation in the study and gave permission to publish their child's photographs.

**Acknowledgments:** We thank the patient and the family for their contribution to this study, Delphine Voisin for technical support in the FISH study and Eleonore Eymard-Pierre for performing the a-CGH study.

## **References**

- Cook, D.R., Rossman, K.L., Der, C.J. Rho Guanine Nucleotide Exchange Factors: Regulators of Rho GTPase Activity in Development and Disease. *Oncogene*. 2014 33(31):4021-35.
- Cunningham, R.L., Herbert, A.L., Harty, B.L., Ackerman, S.D., Monk, K.R. 2018. Mutations in dock1 disrupt early Schwann cell development. *Neural Dev*. 13:17.
- Faria, Á.C., Rabbi-Bortolini, E., Rebouças, M.R.G.O., de S Thiago Pereira, A.L.A., Frasson, M.G.T., Atique, R., Lourenço N.C.V., Rosenberg, C., Kobayashi G.S., Passos-Bueno

- M.R., Errera, F.I.V. Craniosynostosis in 10q26 deletion patients: A consequence of brain underdevelopment or altered suture biology? *Am J Med Genet A*. 2016;170A(2):403-409.
- Fenton, T.R., Kim, J.H. 2013. A systematic review and meta-analysis to revise the Fenton growth chart for preterm infants. *BMC Pediatr* 13: 59.
- Gadea, G., Blangy, A. 2014. Dock-family exchange factors in cell migration and disease. *Eur J Cell Biol* 93:466-77.
- Grund, T., Neumann, I.D. 2018. Neuropeptide S Induces Acute Anxiolysis by Phospholipase C-Dependent Signaling within the Medial Amygdala. *Neuropsychopharmacology* 43:1156-1163.
- Grund, T., Neumann, I.D. 2019. Brain neuropeptide S: via GPCR activation to a powerful neuromodulator of socio-emotional behaviors. *Cell Tissue Res* 375:123-132.
- Iourov, I.Y., Vorsanova, S.G., Kurinnaia, O.S., Yurov, Y.B. An interstitial deletion at 10q26.2q26.3. *Case Rep Genet*. 2014; 505832
- Irving, M., Hanson, H., Turnpenny, P., Brewer, C., Ogilvie, C.M., Davies, A., Berg, J. 2003. Deletion of the distal long arm of chromosome 10; is there a characteristic phenotype? A report of 15 de novo and familial cases. *Am J Med Genet A* 123A:153-63.
- Laudier, B., Epiais, T., Pâris, A., Menuet, A., Briault, S., Ozsancak, C., Perche, O. 2016. Molecular and clinical analyses with neuropsychological assessment of a case of del(10)(q26.2qter) without intellectual disability: Genomic and transcriptomic combined approach and review of the literature. *Am J Med Genet A* 170:1806-12.

- Lin, S., Zhou, Y., Fang, Q., Wu, J., Zhang, Z., Ji, Y., Luo, Y. 2016. Chromosome 10q26 deletion syndrome: Two new cases and a review of the literature. *Mol Med Rep* 14:5134-5140.
- Miller, N.D., Nance, M.A., Wohler, E.S., Hoover-Fong, J.E., Lisi, E., Thomas, G.H., Pevsner, J. 2009. Molecular (SNP) analyses of overlapping hemizygous deletions of 10q25.3 to 10qter in four patients: evidence for HMX2 and HMX3 as candidate genes in hearing and vestibular function. *Am J Med Genet A* 149A:669-80.
- Ogata, T., Muroya, K., Sasagawa, I., Kosho, T., Wakui, K., Sakazume, S., Ito, K., Matsuo, N., Ohashi, H., Nagai, T. 2000. Genetic evidence for a novel gene(s) involved in urogenital development on 10q26. *Kidney Int* 58:2281-90.
- Plaisancié, J., Bouneau, L., Cances, C., Garnier, C., Benesteau, J., Leonard, S., Bourrouillou, G., Calvas, P., Vigouroux, A., Julia, S., Bieth, E. 2014. Distal 10q monosomy: new evidence for a neurobehavioral condition? *Eur J Med Genet* 57:47-53.
- Sutani, A., Shima, H., Hijikata, A., Hosokawa, S., Katoh-Fukui, Y., Takasawa, K., Suzuki, E., Doi, S., Shirai, T., Morio, T., Fukami, M., Kashimada, K. 2019. WDR11 is another causative gene for coloboma, cardiac anomaly and growth retardation in 10q26 deletion syndrome. *Eur J Med Genet*. 31.
- Tanteles, G.A., Nikolaou, E., Christou, Y., Alexandrou, A., Evangelidou, P., Christophidou-Anastasiadou, V., Sismani, C., Papacostas, S.S. Mild phenotype in a patient with a *de novo* 6.3 Mb distal deletion at 10q26.2q26.3. *Case Rep Genet*. 2015; 242891
- Uezu, A., Kanak, D.J., Bradshaw, T.W., Soderblom, E.J., Catavero, C.M., Burette, A.C., Weinberg, R.J., Soderling, S.H. 2016. Identification of an elaborate complex mediating postsynaptic inhibition. *Science* 353:1123-9.

- Vera-Carbonell, A., López-González, V., Bafalliu, J.A., Ballesta-Martínez, M.J., Fernández, A., Guillén-Navarro, E., López-Expósito, I. 2015. Clinical comparison of 10q26 overlapping deletions: delineating the critical region for urogenital anomalies. *Am J Med Genet A* 167A:786-90.
- Wijchers, P. J. E. C., Hoekman, M. F. M., Burbach, J. P. H., Smidt, M. P. 2005. Cloning and analysis of the murine Foxi2 transcription factor. *Biochim. Biophys. Acta* 1731: 133-138.
- Yatsenko, S.A., Kruer, M.C., Bader, P.I., Corzo, D., Schuette, J., Keegan, C.E., Nowakowska, B., Peacock, S., Cai, W.W., Peiffer, .DA., Gunderson, K.L., Ou, Z., Chinault, A.C., Cheung, S.W. 2009. Identification of critical regions for clinical features of distal 10q deletion syndrome. *Clin Genet* 761:54-62.

**Figure 1:**

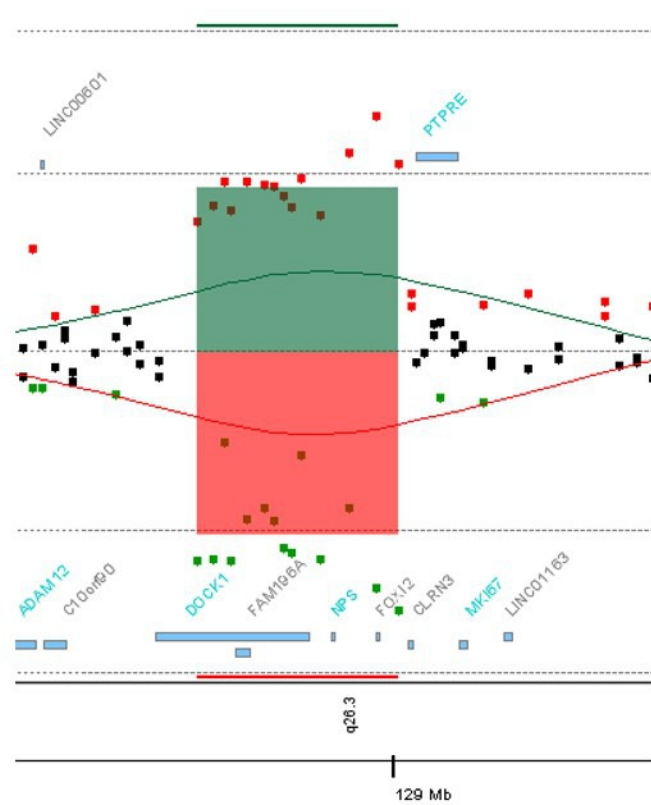
**A.** Agilent Human genome CGH 60K microarray results showing the deletion encompassing a 860 kb segment containing seven genes including four coding genes: *DOCK1*, *FAM196A* (*INSYN2*), *NPS* and *FOXI2* and FISH analysis with 10pTEL control probe (Vysis, green signal) and a specific BAC clone RP11-384P18 probe (red signal), confirming the deletion identified in the proband by array CGH.

**B.** Schematic physical map of the chromosome 10q26 region. The genes of interest and the patients who helped to define a novel minimal critical region of ~500kb are given. The black horizontal bars represent the deleted segment in each patient. Clinical features of the patients are described in Table 1.

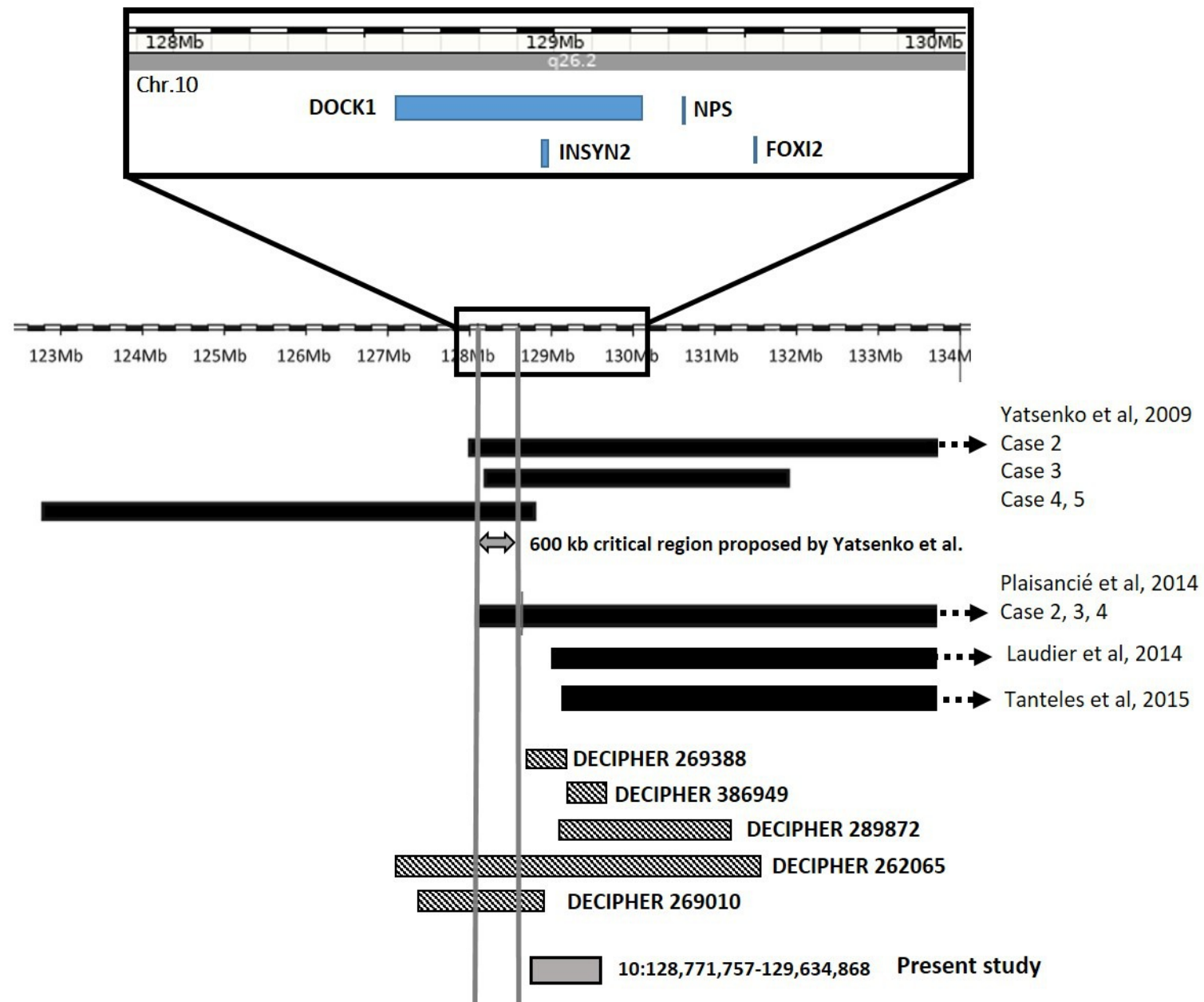
**Figure 2:** Photographs of the proband at birth (A and B) and at the age of 21.5 months (B and C), and his mother (E and F): Note the long face of the mother, with a high forehead and bitemporal narrowing, sparse eyebrows, strabismus, prominent nose and chin, the thin vermilion of the lips and large protruding ears. At birth, the proband had a high forehead, malformed ears, and a prominent nose.

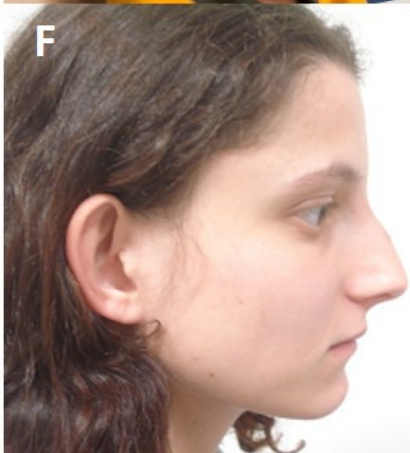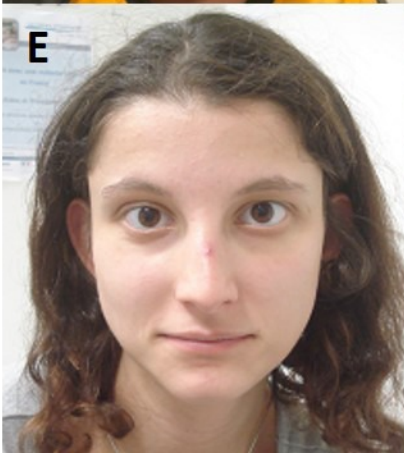
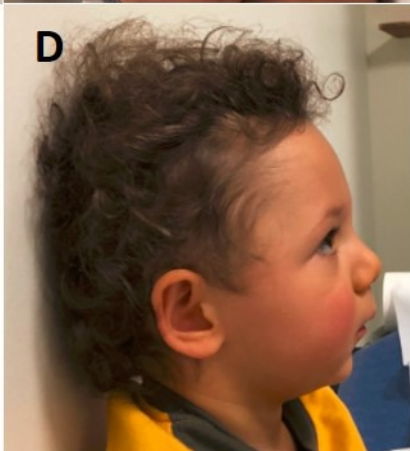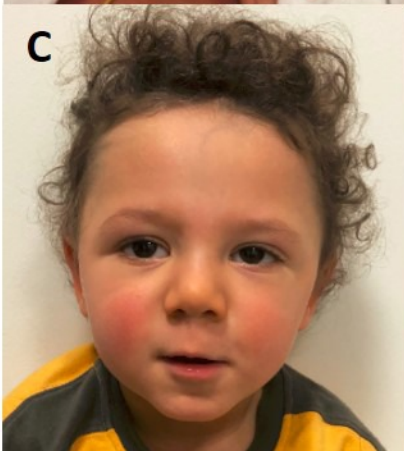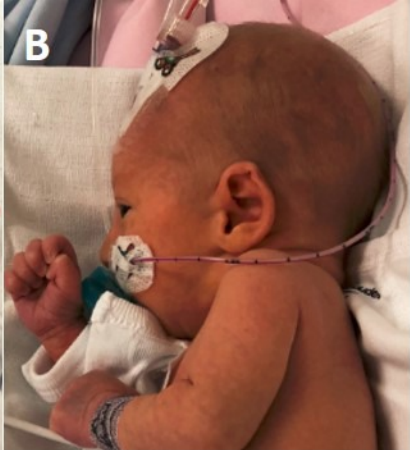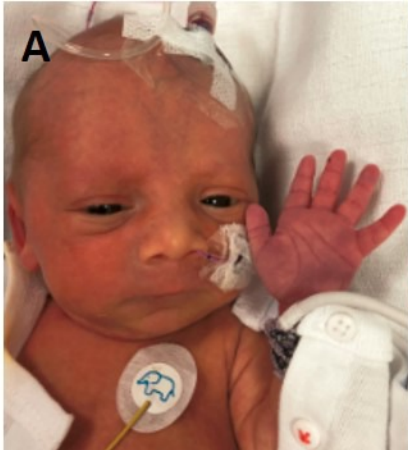**Table 1:** Clinical features of the proband and his mother from the present study and previously reported patients with pure 10q26 deletion.

A



B





**Table I:** Clinical features of the proband and his mother from the present study and previously reported patients with pure 10q26 deletion.

	Tanteles et al, 2015	Laudier et al, 2016	Plaisancié et al, 2013			Yatsenko et al, 2009				Decipher					Present study		Frequency
			2	3	4	2	3	4	5	269388	386949	289872	262065	269010	Proband	Mother	
<b>Deletion information</b>																	
Location (chr 10)	q26-qter	q26.2-qter	q26.2-q26.3	q26.2-q26.3	q26.2-q26.3	q26-qter	q26.2-q26.3	q26.12-q26.2	q26.12-q26.2	q26.2	q26.2	q26.2-q26.3	q26.13-q26.3	q26.2	q26.2	q26.2	
Size (Mb)	6.3	6.53	4.97	4.97	4.97	7.29	3.51	5.8	5.8	0.39	0.336	2.0	4.55	1.6	0.86	0.86	
<b>Growth</b>																	
IUGR	-	-	+	na	+	na	na	na	na	na	na	na	na	na	+	-	3/6
Short stature	-	+	+	+	+	+	-	+	-	na	na	na	+	na	- (-1,5SD)	- (-1,5SD)	7/12
Microcephaly	-	+	+	-	-	+	-	+	+	Macrocephaly	na	na	na	na	+	borderline	6/12
<b>Neurological features</b>																	
Developmental delay	-	-	+	+	+	+	+	+	na	+	na	na	na	na	+	+	9/11
Intellectual disability	-	-	Mod	Mod	Mod	Mild	na	+	+	+	na	na	na	+	na	Mild	9/11
Behavioral disorders	-	-	+	+	+	+	-	+	+	na	+	+	na	na	-	-	8/13
<b>Facial features</b>																	
Long face	+	na	+	+	+	+	na	-	+	+	na	na	na	na	-	+	8/10
Bitemporal narrowing	+	+	+	+	+	-	na	-	+	na	na	na	na	na	+	+	8/10
Ear anomalies	+	-	+	+	+	-	+	+	+	+	na	na	na	na	+	+	10/12
High forehead	+	-	+	+	+	-	na	-	+	na	na	na	na	na	+	+	7/10
Hypertelorism	-	-	+	+	+	-	-	+	+	+	na	na	na	na	-	-	6//12
Prominent nose	+	-	+	+	+	+	+	+	+	+	na	na	na	na	+	+	11/12
Long philtrum	-	na	+	+	+	+	na	-	-	na	na	na	na	na	+	+	6/9
Thin vermilion of up. lip	+	-	+	+	+	-	na	+	-	thick	na	na	na	na	+	+	7/11
Broad chin	+	na	+	+	+	+	na	-	+	na	na	na	na	na	Micrognathia	+	7/9
Clinodactyly	+	+	na	+	+	+	+	+	na	+	na	na	na	na	+	-	9/10
<b>Other anomalies</b>																	
Refractive errors	-	+	+	+	+	na	na	na	na	na	na	na	na	na	-	-	4/7
Strabismus	+	-	-	-	-	+	+	-	-	+	na	na	na	na	-	+	5/11
Cleft palate	-	-	+	-	-	-	-	-	-	na	na	na	na	na	-	-	1/11
Congenital heart disease	+	-	-	-	-	+	-	na	+	na	na	na	na	na	-	-	3/10
Urogenital anomalies	-	-	-	-	-	+	-	-	-	+	na	na	na	na	-	-	2/12

+, feature present; -, feature absent; na, not available; Mod, moderate; IUGR, intrauterine growth retardation; SD, standard deviation