



**HAL**  
open science

**Correspondence in reference to the previously published  
Epub manuscript: immune thrombocytopenic purpura  
after SARS-CoV-2 vaccine**

Quentin Scanvion, Marc Lambert, Eric Hachulla, Louis Terriou

► **To cite this version:**

Quentin Scanvion, Marc Lambert, Eric Hachulla, Louis Terriou. Correspondence in reference to the previously published Epub manuscript: immune thrombocytopenic purpura after SARS-CoV-2 vaccine. *British Journal of Haematology*, 2021, 194 (6), pp.e93-e95. 10.1111/bjh.17628 . hal-03343588

**HAL Id: hal-03343588**

**<https://hal.science/hal-03343588v1>**

Submitted on 18 May 2022

**HAL** is a multi-disciplinary open access archive for the deposit and dissemination of scientific research documents, whether they are published or not. The documents may come from teaching and research institutions in France or abroad, or from public or private research centers.

L'archive ouverte pluridisciplinaire **HAL**, est destinée au dépôt et à la diffusion de documents scientifiques de niveau recherche, publiés ou non, émanant des établissements d'enseignement et de recherche français ou étrangers, des laboratoires publics ou privés.

**Correspondence in reference to the previously published Epub manuscript:**  
***Immune thrombocytopenic purpura after SARS-CoV-2 vaccine***

**Authors:**

Quentin SCANVION<sup>1</sup>, Marc LAMBERT<sup>1</sup>, Eric HACHULLA<sup>1</sup>, Louis TERRIOU<sup>1</sup>.

**Author affiliations:**

<sup>1</sup>Department of Internal Medicine and Clinical Immunology, University of Lille, CHU Lille, F-59000 Lille, France.

**Corresponding author:**

Dr Louis TERRIOU

Department of Internal Medicine and Clinical Immunology, CHU Lille, F-59000 Lille, France

E-mail: [louis.terriou@chru-lille.fr](mailto:louis.terriou@chru-lille.fr)

**Article type:** Letter to the Editor

**Word count:** 673

**Number of figures:** 1

**Keywords:** immune thrombocytopenic purpura, primary immune thrombocytopenia, SARS-CoV-2, anti-PF4 antibodies, vaccine

## Letter to the Editor

Dear Sir,

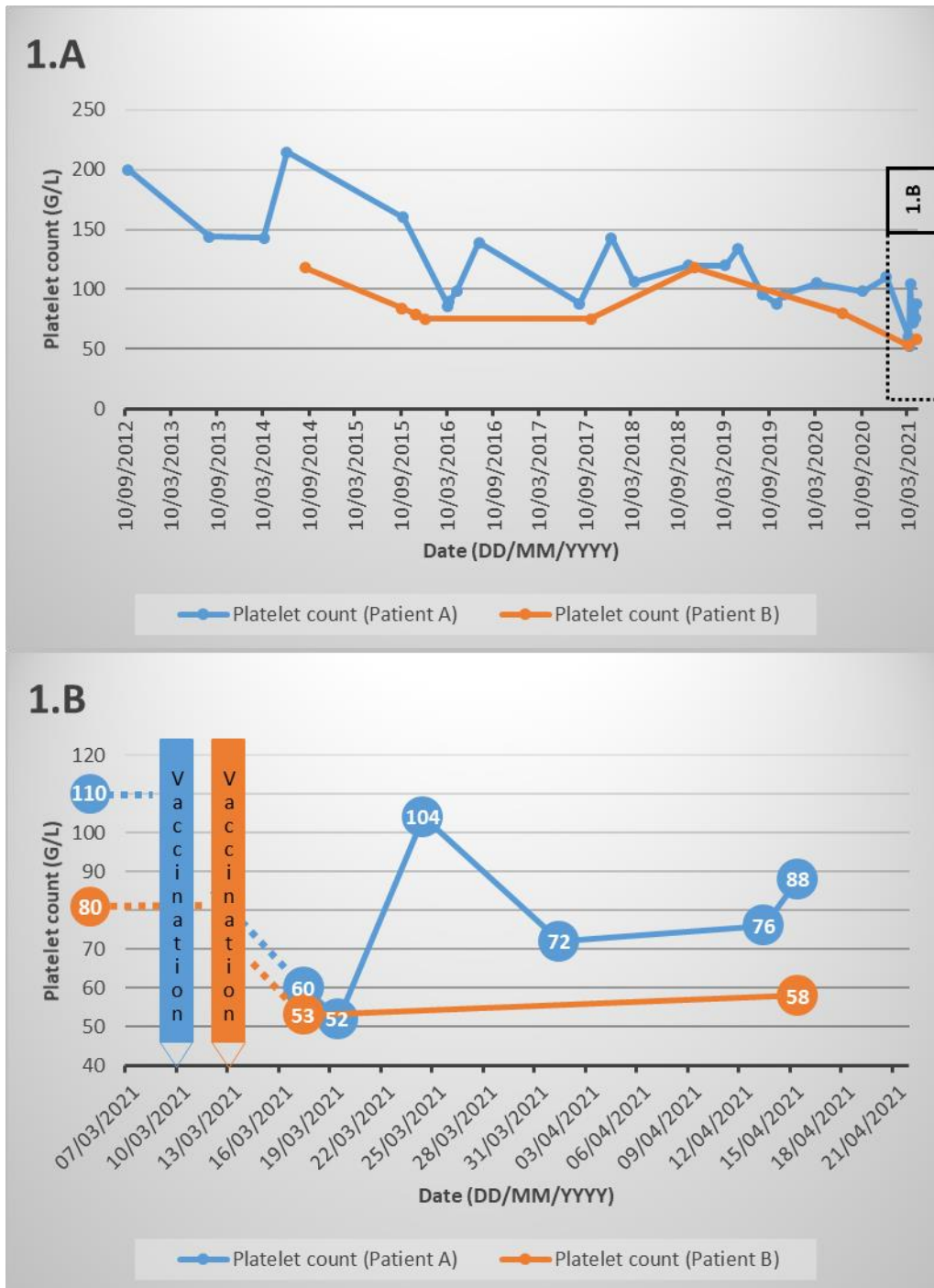
We read with great interest the correspondence published recently by Candelli *et al.* (Candelli *et al.*). The authors describe the possible first case of immune thrombocytopenic purpura (ITP) subsequent to an injection of ChadOx1 nCov-19 vaccine. The latter is based on a chimpanzee adenovirus vaccine vector that has been modified to contain the genetic information needed to reproduce SARS-CoV-2 spike proteins. The authors consider the chronology and, after having excluded several alternative etiologies, retain the diagnosis of ITP induced by vaccination. They rightly specify that they cannot completely rule out the possibility of a random temporal association between the onset of primary ITP and vaccination. However, we believe there are two further possible causes of ITP that could be considered or discussed.

Our first hypothesis is that the patient described by Candelli *et al.* may have already had primary immune thrombocytopenia before vaccination. Any mild and asymptomatic form of immune thrombocytopenia prior to vaccination could have remained undetected. The authors agree that the concomitant detection of a lupus anticoagulant and immune thrombocytopenic purpura could indicate a pre-existing autoimmune disorder, as lupus anticoagulant is closely associated with primary immune thrombocytopenia (Diz-Küçükkaya *et al.*, 2001). The authors' observation that the patient had no medical history is not discordant, as this healthy 28-year-old man had previously had no medical reason to check his platelet count. Vaccination would therefore be an aggravating factor. It is not uncommon to observe transient drops in platelet counts post-vaccination for patients with ITP and other causes of thrombocytopenia (Lee *et al.*, 2021). We can illustrate this with two recent cases. Two women with primary immune thrombocytopenia presented a transient or moderate worsening of their thrombocytopenia after vaccination by ChadOx1 nCov-19 (data not published). The first woman (A) was 62 years old and had been diagnosed with asymptomatic thrombocytopenia 8 years earlier. She was

overweight and had dyslipidemia and hypertension. The second woman (B) was 45 years old. She had no medical history other than a known asymptomatic primary immune thrombocytopenia diagnosed 7 years earlier. The kinetics of their platelet counts are shown in Figure 1. Questioning, clinical examination and biological controls (especially immunological and infectious) did not reveal any other factors that could exacerbate thrombocytopenia. These patients reported a very brief and moderate influenza-like syndrome (without fever) 48 hours after vaccination. Unlike the case of Candelli *et al.*, our patients did not have purpura or hemorrhagic syndrome. No treatment was necessary.

Alternatively, another adverse effect of the vaccine could have played a role for the patient of Candelli *et al.* (Candelli *et al.*). In recent weeks, several cases of unusual thrombocytopenia and thrombotic events have been described after vaccination with ChAdOx1 nCov-19 (Schultz *et al.*, 2021; Greinacher *et al.*, 2021). A novel underlying mechanism associated with these complications is in the process of being identified. A pathogenic PF4-dependent syndrome, unrelated to the use of heparin therapy, can occur after the administration of the ChAdOx1 nCoV-19 vaccine (Scully *et al.*, 2021). In the cohort studied by Scully *et al.* to identify this mechanism, one patient (case 14) had severe acute thrombocytopenia (14 days after vaccination) associated with elevated D-dimer levels (admittedly much higher than the patient of Candelli *et al.*) and bleeding symptoms only, without thrombosis. PF4-IgG testing was positive. The absence of thrombosis does not therefore rule out this diagnosis. Moreover, when considered in the light of the algorithm suggested by Scully *et al.*, the case report of Candelli *et al.* is located in the ambiguous zone (acute isolated thrombocytopenia, D-dimer levels between 2000 and 4000 UI/L, low or normal fibrinogen). In this clinical situation of ITP occurring 5 to 30 days after a ChadOx1 nCov-19 vaccination, it could therefore be interesting to carry out biological explorations for the detection of pathological anti-PF4 antibodies.

Additional investigation is needed to determine the incidence and the etiologies of thrombocytopenia post vaccination. In our opinion, the benefit-risk balance remains in favor of vaccination for patients with primary immune thrombocytopenia. A systematic control of platelet count 7 days after vaccination could be proposed.



**Figure 1: Platelet count kinetics. 1.A** Since diagnosis. **1.B** Focus on the period after the first injection of the ChadOx1 nCov-19 vaccine.

**Conflicts of interest:**

The authors declare no conflicts of interest.

**Funding source:** No specific funding was received from any bodies in the public, commercial or not-for-profit sectors to carry out the work described in this manuscript.

**Author Contributions:** Q.S. and L.T. designed the paper. QS wrote the first draft of the paper with input from M.L., É.H. and L.T. All authors revised the manuscript and approved the final form.

**Patient consent statement:** The patients had been informed beforehand in their letters of consultation that unless they expressed an objection, their medical data could be used in an anonymous form for medical publications. No objections were expressed by any of the included patients.

**References**

- Candelli, M., Rossi, E., Valletta, F., Stefano, V.D. & Franceschi, F. Immune thrombocytopenic purpura after SARS-CoV-2 vaccine. *British Journal of Haematology*, **n/a**, Available at: <http://onlinelibrary.wiley.com/doi/abs/10.1111/bjh.17508> [Accessed May 4, 2021].
- Diz-Küçükkaya, R., Hacıhanefioğlu, A., Yenerel, M., Turgut, M., Keskin, H., Nalçacı, M. & İnanç, M. (2001) Antiphospholipid antibodies and antiphospholipid syndrome in patients presenting with immune thrombocytopenic purpura: a prospective cohort study. *Blood*, **98**, 1760–1764.
- Greinacher, A., Thiele, T., Warkentin, T.E., Weisser, K., Kyrle, P.A. & Eichinger, S. (2021) Thrombotic Thrombocytopenia after ChAdOx1 nCov-19 Vaccination. *New England Journal of Medicine* Available at: <https://www-nejm-org.ressources-electroniques.univ-lille.fr/doi/10.1056/NEJMoa2104840> [Accessed May 4, 2021].
- Lee, E., Cines, D.B., Gernsheimer, T., Kessler, C., Michel, M., Tarantino, M.D., Semple, J.W., Arnold, D.M., Godeau, B., Lambert, M.P. & Bussel, J.B. (2021) Thrombocytopenia following Pfizer and Moderna SARS-CoV-2 vaccination.

*American Journal of Hematology* Available at:  
<https://www.ncbi.nlm.nih.gov/pmc/articles/PMC8014568/> [Accessed May 4, 2021].

Schultz, N.H., Sørvoll, I.H., Michelsen, A.E., Munthe, L.A., Lund-Johansen, F., Ahlen, M.T., Wiedmann, M., Aamodt, A.-H., Skattør, T.H., Tjønnfjord, G.E. & Holme, P.A. (2021) Thrombosis and Thrombocytopenia after ChAdOx1 nCoV-19 Vaccination. *New England Journal of Medicine* Available at: <https://www-nejm-org.ressources-electroniques.univ-lille.fr/doi/10.1056/NEJMoa2104882> [Accessed May 4, 2021].

Scully, M., Singh, D., Lown, R., Poles, A., Solomon, T., Levi, M., Goldblatt, D., Kotoucek, P., Thomas, W. & Lester, W. (2021) Pathologic Antibodies to Platelet Factor 4 after ChAdOx1 nCoV-19 Vaccination. *New England Journal of Medicine* Available at: <https://www-nejm-org.ressources-electroniques.univ-lille.fr/doi/10.1056/NEJMoa2105385> [Accessed May 4, 2021].