



HAL
open science

Treatment of hidradenitis suppurativa using a long-pulsed hair removal neodymium:yttrium-aluminium-garnet laser: A multicenter, prospective, randomized, intraindividual, comparative trial

Michael Naouri, Annabel Maruani, Sylvie Lagrange, Olivier Cogrel, Amandine Servy, Anne Marie Collet Vilette, Sabrina Fourcade, Nathalie Gral, Yvon Perrillat, Regine Bousquet Rouaud, et al.

► **To cite this version:**

Michael Naouri, Annabel Maruani, Sylvie Lagrange, Olivier Cogrel, Amandine Servy, et al.. Treatment of hidradenitis suppurativa using a long-pulsed hair removal neodymium:yttrium-aluminium-garnet laser: A multicenter, prospective, randomized, intraindividual, comparative trial. *Journal of The American Academy of Dermatology*, 2021, 84 (1), pp.203-205. 10.1016/j.jaad.2020.04.117 . hal-03342722

HAL Id: hal-03342722

<https://hal.science/hal-03342722>

Submitted on 15 Dec 2022

HAL is a multi-disciplinary open access archive for the deposit and dissemination of scientific research documents, whether they are published or not. The documents may come from teaching and research institutions in France or abroad, or from public or private research centers.

L'archive ouverte pluridisciplinaire **HAL**, est destinée au dépôt et à la diffusion de documents scientifiques de niveau recherche, publiés ou non, émanant des établissements d'enseignement et de recherche français ou étrangers, des laboratoires publics ou privés.



Distributed under a Creative Commons Attribution - NonCommercial 4.0 International License

Treatment of hidradenitis suppurativa using long-pulsed hair removal Nd:Yag laser. A multicentric prospective randomized intra-individual comparative trial

Michael Naouri ^{1,2}, MD, Annabel Maruani ^{3,4}, MD, PhD, Sylvie Lagrange⁵, MD, Olivier Cogrel ⁶, MD, Amandine Servy ¹, MD, Anne Marie Collet Vilette ⁷ MD, Sabrina Fourcade ⁷, MD, Nathalie Gral ⁸, MD, Yvon Perrillat ⁸, MD, Regine Bousquet Rouaud ^{9,10} MD, Hugues Cartier ¹¹, MD, Cyril Maire ¹¹, MD, Dominique Boineau ¹², MD, Gerard Toubel ¹³, MD, Isabelle Ollivier ¹⁴, MD, Anne Le Pillouer-Prost ¹⁵, MD Thierry Passeron ^{5,16}, MD, PhD

1. Dermatological and esthetical laser center, Nogent sur Marne, France
2. Laser center, Department of Dermatology, Hôpital Saint Louis, Paris France
3. Department of Dermatology, CHRU Tours, Tours, France
4. University of Tours, Inserm 1246-SPHERE, Tours, France
5. Université Côte d'Azur, Department of Dermatology, CHU Nice, Nice France
6. Dermatologic surgery, Mohs surgery and laser unit, Dermatology department, University hospital of Bordeaux, France
7. Dermatological laser center, hôpital de la Conception, Marseille, France
8. Dermatological and esthetical laser center, Grenoble, France
9. Dermatological and esthetical laser center of Arche, Montpellier, France
10. Millénaire clinic, Montpellier, France
11. Saint-Jean Medical Center, Arras, France
12. Aesthetic Dermatology Office, Bordeaux, France
13. Private Office, Rennes, France
14. Private Office, Rennes, France
15. Clairval private hospital, Marseille, France
16. Université Côte d'Azur, INSERM U1065, C3M, Nice, France

Corresponding author:

Thierry Passeron, MD, PhD,
Centre Hospitalier Universitaire de Nice,
Service de Dermatologie
151, Route de Saint Antoine de Ginestière,
Hôpital Archet 2,
06200 Nice, France

Conflicts of interest: None

Funding sources: This study was supported by a grant from the French Society of Dermatology

Acknowledgment: We thank Dr Luc Duteil for his help

ANSM (French Agency for Medicine Security) approval: Id-RCB: 2016-A00471-50

IRB approval: 16.031

[Tapez ici]

Manuscript word count: 500

Number of References: 5

Number of Figures: 1

Number of Tables: 1

Key words: Nd:YAG laser; hair removal, hidradenitis suppurativa

[Tapez ici]

Several studies suggested that a follicular occlusion could be the initial trigger leading to the development of the inflammatory lesions in hidradenitis suppurativa(HS)¹. Thus, the selective destruction of the hair follicles appears as an appealing approach in the treatment of HS. Only one prospective randomized study using laser^{2,3} and one using intense pulse-light⁴, have been conducted. In the two studies, the treated site showed better improvement of HS lesions compared to control. However, in none of these studies, the evaluation was performed by physicians truly blinded to the site treated with laser as the untreated side wasn't shave before the evaluations. Since these early studies, no prospective trial has been conducted. Recent systematic guidelines graded the use of Nd:YAG laser with the same level of evidence (level II) as wide excision⁵.

We conducted a randomized, evaluator blind, intra-individual controlled study performed among eight centers in France to assess the efficacy and the tolerance of laser hair removal for mild to moderate HS. Patients received a total of 4 Nd:YAG laser treatments at 6-week intervals. Settings of laser were chosen based on Fitzpatrick skin type as follows: for skin type I to III, pulse duration 20ms, fluence 45J/cm² and for skin type IV to VI, pulse duration 35ms, fluence 30J/cm². Fluences could be +/-10% adjusted according to the tolerance and the clinical response. Spot size was comprised between 10 and 15mm. The treated site was randomized by coin toss and the contralateral side served as untreated control. Patients could use topical antiseptic and topical antibiotics during the study. The main criterion of evaluation was number of inflammatory lesions. The secondary criteria included the proportion of responders to Hidradenitis Suppurativa Clinical Response(HiSCR). The number of flare-up was also monitored. All patients were asked to shave both sides, 3 days before each visit. In each center, the evaluation was performed at baseline and each time point by a physician blinded to the side treated with laser and who was different from the one who treated the patient.

[Tapez ici]

Thirty-seven patients were screened to participate and 36 were randomized in the study.

Twenty-seven patients were treated on the inguinal area and 9 on the axillary area (Figure 1).

The number of inflammatory lesions decreased significantly on laser-treated area compared to untreated one at 1-month follow-up (-1.25 vs. +1.69, $p=0.017$). A difference persisted but was no longer significant at 3-months follow-up (-2.56 vs. -0.81, $p=0.10$) (Table 1). The percent of HiSCR responders 1 month after the end of the sessions was 73.7% on the treated side and 52.6% on the control side ($p=0.29$). After 3 months, the responders were 52.6% in both groups. There was no statistically significant difference in the number of flares between treated and untreated sites at 1 and 3-month follow-up. The mean pain during the laser sessions was 5.42/10. One patient reported a prolonged burning sensation and an irritation after one session. No other side-effect was reported.

Laser hair removal is effective for reducing the number of inflammatory lesions of HS at 1 month, but the efficacy decreases with time. The laser has no effect on disease flares.

[Tapez ici]

References

1. Prens E , Deckers I. Pathophysiology of hidradenitis suppurativa: An update. *Journal of the American Academy of Dermatology* 2015;73:S8-11.
2. Tierney E, Mahmoud BH, Hexsel C, Ozog D , Hamzavi I. Randomized control trial for the treatment of hidradenitis suppurativa with a neodymium-doped yttrium aluminium garnet laser. *Dermatol Surg* 2009;35:1188-98.
3. Mahmoud BH, Tierney E, Hexsel CL, Pui J, Ozog DM , Hamzavi IH. Prospective controlled clinical and histopathologic study of hidradenitis suppurativa treated with the long-pulsed neodymium:yttrium-aluminium-garnet laser. *Journal of the American Academy of Dermatology* 2010;62:637-45.
4. Highton L, Chan WY, Khwaja N , Laitung JK. Treatment of hidradenitis suppurativa with intense pulsed light: a prospective study. *Plast Reconstr Surg* 2011;128:459-65.
5. Alikhan A, Sayed C, Alavi A, Alhusayen R, Brassard A, Burkhart C et al. North American clinical management guidelines for hidradenitis suppurativa: A publication from the United States and Canadian Hidradenitis Suppurativa Foundations: Part I: Diagnosis, evaluation, and the use of complementary and procedural management. *Journal of the American Academy of Dermatology* 2019;81:76-90.

[Tapez ici]

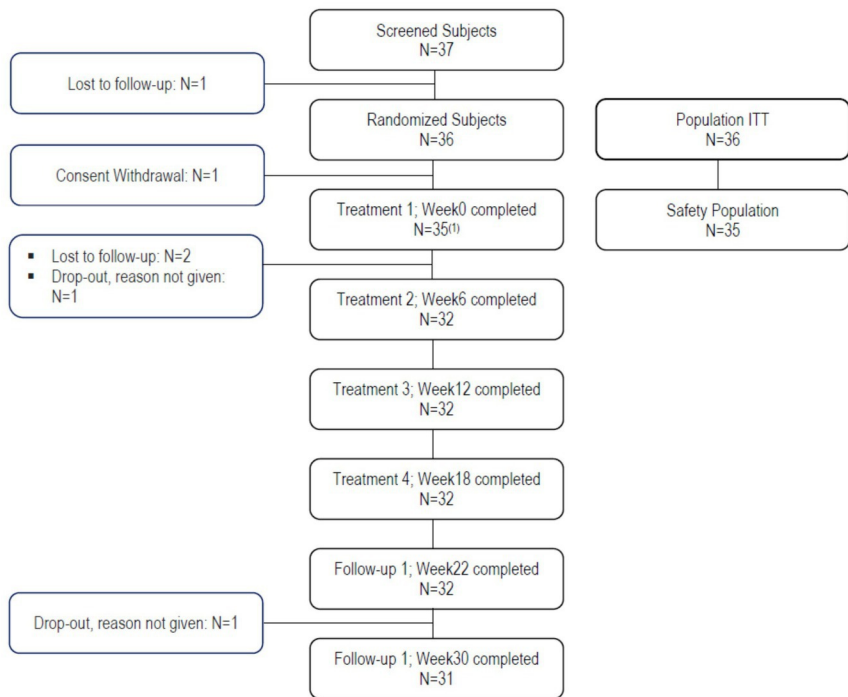
Table 1. Number of inflammatory lesions at Week 0 and evolution of inflammatory lesions at Week 22 and Week 30 compared to baseline

		Inflammatory Lesions	
		Untreated	Treated
Week0	N	36	36
	Mean±std	5.86±6.29	5.89±4.68
	Median	3.0	4.5
	(Min,Max)	(0.0, 24.0)	(0.0, 15.0)
Week 22 – Week 0	N	36	36
	Mean±std	1.69±15.01	-1.25±10.77
	Median	0.0	-1.0
	(Min,Max)	(-18.0, 80.0)	(-15.0, 56.0)
	p ^a	0.017	
Week 30 – Week 0	N	36	36
	Mean±std	-0.81±6.08	-2.56±4.22
	Median	-1.0	-1.0
	(Min,Max)	(-15.0, 15.0)	(-15.0, 3.0)
	p ^a	0.100	

P^a: (Treated versus Untreated)

N : Number of patients

Figure 1. Flow diagram of the study



(1): inguinal area (n=26), axillary area (n=9)