



HAL
open science

Acute acral eruptions in children during the COVID-19 pandemic: Characteristics of 103 children and their family clusters

T. Hubiche, A. Phan, S. Leducq, J. Rapp, L. Fertitta, H. Aubert, S. Barbarot, C. Chiaverini, B. Giraudeau, A. Lasek, et al.

► To cite this version:

T. Hubiche, A. Phan, S. Leducq, J. Rapp, L. Fertitta, et al.. Acute acral eruptions in children during the COVID-19 pandemic: Characteristics of 103 children and their family clusters. *Annales de Dermatologie et de Vénérologie*, 2021, 148 (2), pp.94-100. 10.1016/j.annder.2020.11.005 . hal-03342667

HAL Id: hal-03342667

<https://hal.science/hal-03342667v1>

Submitted on 9 May 2023

HAL is a multi-disciplinary open access archive for the deposit and dissemination of scientific research documents, whether they are published or not. The documents may come from teaching and research institutions in France or abroad, or from public or private research centers.

L'archive ouverte pluridisciplinaire **HAL**, est destinée au dépôt et à la diffusion de documents scientifiques de niveau recherche, publiés ou non, émanant des établissements d'enseignement et de recherche français ou étrangers, des laboratoires publics ou privés.



Distributed under a Creative Commons Attribution - NonCommercial 4.0 International License

ANN DER

Original article

Acute acral eruptions in children during the COVID-19 pandemic: characteristics of 103 children and their family clusters

Short title: Familial clusters and cutaneous signs of COVID-19 in children

T. Hubiche¹⁺, A. Phan²⁺, S. Leducq^{3,4}, J. Rapp¹, L. Fertitta⁵, H. Aubert⁶, S. Barbarot⁶, C. Chiaverini¹, B. Giraudeau^{3,7}, A. Lasek⁸, S. Mallet⁹, A. Labarelle⁹, M. Piram¹⁰, C. McCuaig¹⁰, L. Martin¹¹, L. Monitor¹², I. Nicol⁹, M. Bissuel³, A. Bellissen⁹, D. Jullien¹⁴, C. Lesort¹⁴, P. Vabres¹⁵, A. Maruani^{3,4,7} *

For the Research Group of the Société Française de Dermatologie Pédiatrique (French Society of Pediatric Dermatology)

+Equal contributors

¹Nice University Hospital, Department of Dermatology, 06000 Nice, France

²Lyon University Hospital, Department of Pediatric Dermatology, Hospices Civils de Lyon, 69500 Bron, France

³Universities of Tours and Nantes, INSERM 1246 – SPHERE, 37000 Tours, France

⁴Tours University Hospital, Department of Dermatology, 37044 Tours Cedex 9, France

⁵AP-HP (Paris Hospitals), Paris-Necker Hospital, Department of Dermatology, 75015 Paris, France

⁶Nantes University Hospital, Department of Dermatology, 44000 Nantes, France

⁷Tours University Hospital, Clinical Investigation Center-INSERM 1415, 37000 Tours, France

⁸Saint Vincent de Paul Hospital, Université catholique de Lille, 59000 Lille, France

⁹Marseille University Hospital, Department of Dermatology, 13000 Marseille, France

¹⁰Sainte-Justine University Hospital, Division of Dermatology, Montreal, Quebec, Canada

¹¹Angers Hospital University, Department of Dermatology, 49000 Angers, France

¹²Nancy University Hospital, Department of Dermatology, 54511 Vandœuvre-lès-Nancy, France

¹³Casamance Private Hospital, Department of Pediatrics, 13400 Aubagnes, France

¹⁴Lyon University Hospital, Department of Dermatology, Hospital Edouard Herriot, 69003 Lyon, France

¹⁵Dijon University Hospital, Department of Dermatology, 21000 Dijon, France

*Corresponding author

E-mail address: annabel.maruani@univ-tours.fr (Annabel Maruani)

CHRU de Tours, Service de Dermatologie, Unité de Dermatologie Pédiatrique, Hôpital Gatién de Clocheville, 39 boulevard Béranger, 37000 Tours, France

Funding: none

Conflicts of interest: none

This study was approved by the Ethics Committee of Nice

Abstract

Background: A marked increase in frequency of acute acral eruptions (AAE) was observed in children during the COVID-19 pandemic in the spring period.

Objectives: In this observational multicenter study, based on children with AAE, we aimed to assess the proportion of household members possibly infected by SARS-CoV-2.

Methods: We collected data from all children observed with AAE, prospectively from April 7, 2020 to June 22, 2020, and retrospectively since February 28, 2020. The primary outcome was the household infection rate, defined as the proportion of family clusters having at least one member with COVID-19 infection other than the child with AAE (“index child”). The definition of a case was based on characteristic clinical signs and a positive PCR or serology.

Results: The study included 103 children in 10 French departments and in Quebec. The median age was 13 years and the interquartile range [8-15], with a female-to-male ratio of 1/1.15. In children with AAE, all PCR tests were negative (n=18), and serology was positive in 2/14 (14.3%) cases. We found no significant anomalies in the lab results. 66 of the 103 families (64.1%) of included children had at least one other infected member apart from the index child. The total number of household members was 292, of whom 119 (40.8%) were considered possibly infected by SARS-CoV-2. No index children or households exhibited severe COVID-19.

Discussion: Among the 103 households included, 64.1% had at least one infected member. Neither children with AAE nor their households showed severe COVID-19.

Keywords: COVID-19; Chilblains; Acral erythema; Cutaneous; Children; Familial transmission.

Several cutaneous signs are associated with COVID-19, but the mechanisms are not fully understood [1,2]. They have been observed in both adults and children. Severe COVID-19 is less frequent in children than adults. Davies *et al.* showed that general clinical symptoms manifest in only 21% of young people aged 10 to 19 years with COVID-19 versus 69% of people aged > 70 years old [3]. However, numerous cutaneous signs have been reported in children with COVID-19, such as acute acral eruptions (AAE) [4,5]. Published cases of AAE display heterogeneous features, including pseudo-chilblains, acral vesicles or papules, and papular-purpuric gloves and socks syndrome [1,2,4,5]. These signs appear late in the course of COVID-19 [5]. Identified risk factors for severe COVID-19 include increased age, male gender, being overweight, and chronic diseases. Genetic risk factors have also been suspected [6]. The high contagiousness of the disease warrants the study of family clusters [7]. Intrafamilial transmission is still incompletely understood and requires documentation, particularly as children have been more exposed since the reopening of schools as of May 2020 in several European countries [3,8].

In this study, based on children with AAE, we aimed to assess the proportion of household members possibly infected by SARS-CoV-2 with COVID-19 and to describe demographic, clinical, biological and histological signs in these entities.

Methods

Design and setting

This multicenter observational study included centers in France and Quebec, Canada. The study involved all dermatologists belonging to the Group of Research of the French Society of Pediatric Dermatology (GRSFDP) and began on April 7, 2020.

Data collection

We collected data from all children with observed AAE prospectively from April 7, 2020 to June 22, 2020 and retrospectively since February 28, 2020. Data comprised demographic and clinical data (cutaneous and extracutaneous signs) for the child and the household at baseline (at the consultation) and at approximately 1-month of follow-up (all parents were contacted by telephone). Parents were then orally informed about the study and gave their oral consent to participate. Results were also collected for additional examinations, including lab results, virology (SARS-Cov-2 PCR and serology), imaging, and microscopy of skin biopsy.

Investigators entered the data into a standardized electronic case report form (e-CRF). Using the criteria of the European Centre for Disease Prevention and Control, we defined a COVID-19 case as any person presenting fever, cough, shortness of breath, sudden onset of anosmia, ageusia or dysgeusia, or having characteristic CT-scan pulmonary images, or exhibiting positivity for SARS-Cov-2 on PCR (from nasopharyngeal or oropharyngeal swabs) or serology [9]. We used the WHO scale for progression of COVID-19 infection to assess severity (from 0, no infection, to 8, death): severe infection was defined as stage > 3 [10].

Participants

All children (< 18 years old) assessed for AAE were eligible. We excluded children for whom personal or family data was available. The study was approved by the Ethics Committee of Nice, France.

Outcomes

The primary outcome was the proportion of household members possibly infected by SARS-CoV-2 with COVID-19 other than the child with AAE (“index child”). Secondary outcomes were the proportion of severe COVID-19 within the family cluster and the description of demographic, clinical, virology and microscopy data for children with AAE.

Statistical approach

Quantitative data are expressed using mean, standard deviation (SD), median and interquartile range (IQR); categorical data are described with frequency (%). We used the Wilcoxon test to compare cutaneous features of AAE by age of the children. $P < 0.05$ was considered statistically significant. We used R v3.6.2 for calculations.

Results

The study included 103 children from 10 French departments and from Quebec (Fig. 1). Median age was 13 years [IQR 8; 15] and 55 subjects (53.4%) were male (i.e., female/male ratio 1/1.15) (Table 1). Demographic characteristics are given in Tables 1 and 2. Among the 103 children, 66 (64.1%) were in families having at least one member other than the index child with possible COVID-19. The total number of household members was 292; 119 (40.8%) possibly had COVID-19 according to the previously mentioned diagnostic criteria (Table 3, Fig. 2) [8]. Among these 119 households, 77 had signs of infection before the index child was seen for AAE, and 16 had signs after the 1-month follow-up for the index child (data missing for 26 cases, Table 3). Cutaneous signs were present in 8 children other than the index cases in 7 families. No significant differences in age or sex were observed between these 8 children and those without cutaneous signs in their families. In total, all household members were aged < 60 years. No children or household members exhibited severe infection (no hospitalizations). 3 cases among household members were in stage 1 of the WHO scale (2.5%), 113 were in stage 2 (95.0%) and 3 were in stage 3 (2.5%). No children showed multisystem inflammatory disease of childhood [11].

The semiological characteristics of cutaneous signs in the 103 children (Fig. 3) are given in Tables 1, 2 and 4. AAE cases showed heterogeneous features, with chilblain-like lesions (erythematous and violaceous papules and macules) being the most frequent (79.6%). These

features occurred on both hands and feet in 69.6% (n=71) of cases and were associated in 21 cases (20.4%) with other cutaneous signs such as urticarial flares. Of these 103 children, 51 (49.5%) had at least 2 different acral skin signs and 20 (19.4%) had at least 3. In most cases, AAE was not painful and was slightly itchy. Regarding age, chilblain-like AAE was more common in older children (median age 14, [IQR 11-15] with chilblains vs. 5 [IQR 2-11] without, $p<0.01$), as were acrocyanosis and acral edema (Table 2). Pulpitis and eccrine-hidradenitis-like eruptions were more frequent in younger children (median age 3 years [IQR 2-7] and 6.5 years [IQR 4.3-8] respectively).

At 1 month of follow-up, 36 of 71 (50.7%) contactable children with AAE showed complete recovery. AAE partially regressed in 25 (35.2%) children, was stable in 8 (11.3%), and worsened in 2 (2.8%). Median time from the onset of AAE to complete regression was 62.0 days [IQR 47.0-76.0]. The characteristics of AAE in the children did not differ significantly according to whether or not household members were infected with SARS-CoV-2 (Table 4). Regarding complementary examinations in children with AAE, standard lab results and levels of inflammatory markers and coagulation markers were all either normal or not significantly increased (Table 5). Antinuclear antibodies were detected in 13 of 54 (24.1%) children. SARS-Cov-2 serology was positive for IgG in 2 of 14 (14.3%) children, and PCR results were negative in all children (n=18). Skin samples of chilblains were analyzed in 5 children (Table 6). Microscopy showed dermal perivascular lymphocytic infiltrates of differing intensity in all 5 children, as well as spongiosis (n=4) and lymphocytic vasculitis (n=2). Two children exhibited mucinosis.

Discussion

In our study of 103 children with AAE, COVID-19 was possibly present in 40.8% (119/291) of household members, and for 66/103 (64.1%) of children, at least one family member than the index child had infectious signs. AAE characteristics differed according to age. Host characteristics related to patient age appeared to be an important factor in skin lesions observed in children during the COVID-19 pandemic.

Since the beginning of the COVID-19 pandemic, many cases of AAE were observed during the same period in different areas in France and Quebec. A causal link between COVID-19 and AAE has not yet been demonstrated and remains debated. Such a link appears likely since the period during which we observed AAE in France and Quebec was associated with COVID-19 progression and was chiefly during the spring months [12,13].

Evidence of the presence of COVID-19 in skin biopsies of chilblains has recently been reported [14,15]. However, several studies based on serological results have found no evidence of a causal link between COVID-19 and AAE [16-18]. Confirmation of COVID-19 in patients presenting AAE may not be based on classical tests such as PCR (since AAE usually occur after the infectious symptoms) or serology. Indeed, serology appears to have diagnostic efficacy, especially in asymptomatic and paucisymptomatic patients [19].

Neither index children nor households showed severe signs of COVID-19. Where available, laboratory data showed no significant abnormalities. The types of clinical manifestations associated with COVID-19 were associated with host factors, with age being the most important [20]. Severe COVID-19 is more frequent in older people. Neither chilblains nor other acral eruptions have been reported in older people but are associated rather with younger subjects [16,18]. These data underline the importance of host characteristics in COVID-19-associated medical conditions. Efficient innate immune response and/or cross T-

cell immunity induced by previous infection with α coronavirus were explored in patients and relatives presenting such dermatological conditions [21-23]. Patients with chilblains related to COVID-19 may have an efficient immune response not associated with the development of specific COVID-19 antibodies. The estimated percentage of individuals in contact with SARS-CoV-2 is based on serology. If a causal link between COVID-19 and AAE is confirmed, this condition could provide a relevant marker of COVID-19 circulation.

Regarding AAE, chilblain-like lesions were predominant in the children in our study (79.6%); however, we observed a variety of other acral manifestations on the hands or feet, or both, sometimes coexisting in the same patient (49.5%). This finding suggests that AAE could represent a continuous clinical spectrum in which eccrine-hidradenitis-like eruptions or desquamative pulpitis are frequent in infants and chilblain-like lesions are more common in teenagers. The histological findings in our patients were consistent with data from previous larger studies. Findings from chilblain biopsies showed a pattern of interferon (IFN) type I-induced inflammation and vasculitis induced by COVID-19 [4,17,24,25]. Of note is the fact that this skin condition has not been reported in severe COVID-19 patients, who might have impaired IFN type I activity compared to mild COVID-19 cases and to controls [26].

Furthermore, it has been reported that patients with chilblains observed during the COVID-19 pandemic had a significantly higher IFN alpha response compared to severe COVID-19 patients [25]. Some authors have thus hypothesized that patients with chilblains might present an efficient antiviral response triggered by SARS-CoV-2 [27]. Furthermore, in our young population, clinical presentation differed according to age. Host factors play a central role in the clinical presentation of COVID-19. Vessel characteristics and immune status in the host may play a key role. Vessel characteristics and IFN type I response vary according to host characteristics, including age [28]. Such factors could account for the differences between dermatological presentations observed between children and adults as well as those between

infants and adolescents. We observed no acral ischemia in our study. This serious complication reported in adults is associated with a pro-thrombotic condition. Values for coagulation markers in the children in our study were normal. Such thrombotic complications observed in COVID-19 may be driven by other factors related to host characteristics.

Only scant data are available on the evolution of acral lesions. Unlike general signs, such as fever or anosmia, which are presenting symptoms of COVID-19, AAE seems to occur later during the disease, from 0 to several weeks after the first symptoms of suspected viral infection or after presumed contact with a carrier of the virus, as reported in previous studies [5,17,29]. This finding could account for the negative PCR results in our study and in most previously reported cases. However, 3 adolescents with chilblains recently proved positive on RT-PCR with nasopharyngeal swabs [30]. Most lesions had a long but benign course, with complete spontaneous regression after a median of 47 days.

The main limitation of the study is the absence of a control group to confirm intrafamilial contamination. Further, COVID-19 was based on serology, PCR or clinical symptoms according to criteria of the European Centre for Disease Prevention and Control, which may have either over- or underestimated the proportion of households infected. Family members did not undergo systematic PCR testing with nasopharyngeal swabs, which was only performed in hospitalized patients or in patients with severe respiratory symptoms during the inclusion period. In addition, not all patients or household members underwent serology testing, and the serologic techniques themselves were heterogeneous.

In conclusion, AAE exhibit heterogeneous semiological features in children. Confirmation of their link with COVID-19 requires further investigation. The absence of AAE in severe COVID-19 cases and differences in clinical presentation by age group underline the role of host characteristics in skin conditions associated with COVID-19.

References

1. Galvan Cases C, Catala A, Carretero Hernandez G, Rodriguez-Jimenez P, Fenandez-Nieto D, Rodriguez-Villa Lario A, et al. Classification of the cutaneous manifestations of COVID-19: a rapid prospective nationwide consensus study in Spain with 375 cases. *Br J Dermatol* 2020;183:71-7.
2. Fernandez-Nieto D, Ortega-Quijano D, Segurado-Miravalles G, Pindado-Ortega C, Prieto-Barrios M, Jimenez-Cauhe JJ. Cutaneous manifestations in COVID-19: a first perspective. Safety concerns of clinical images and skin biopsies. *J Eur Acad Dermatol Venereol* 2020;34:e252-4.
3. Davies NG, Klepac P, Liu Y, Prem K, Jit M, CMMID COVID-19 working group, Eggo RM. Age-dependent effects in the transmission and control of COVID-19 epidemics. *Nat Med* 2020. <https://doi.org/10.1038/s41591-020-0962-9>.
4. Andina D, Noguera-Morel L, Bascuas-Arribas M, Gaitero-Trista J, Alonso-Cadenas JA, Escalada-Pellitero S, et al. Chilblains in children in the setting of COVID-19 pandemic. *Pediatr Dermatol* 2020;37:406-11.
5. Colonna C, Monzani NA, Rocchi A, Gianotti R, Boggio F, Gelmetti C. Chilblains-like lesions in children following suspected Covid-19 infection. *Pediatr Dermatol* 2020. doi: 10.1111/pde.14210.
6. Zhang X, Tan Y, Ling Y, Lu G, Liu F, Yi Z, et al. Viral and host factors related to the clinical outcome of COVID-19. *Nature* 2020;583:437-40.
7. Zheng Z, Peng F, Xu B, Zhao J, Liu H, Peng J, et al. Risk factors of critical & mortal COVID-19 cases: a systematic literature review and meta-analysis. *J Infect* 2020;S0163-4453(20)30234-6. doi: 10.1016/j.jinf.2020.04.021.

8. Cordoro KM, Reynolds SD, Wattier R, Mccalmont TH. Clustered cases of acral perniois: clinical features, histopathology and relationship to COVID-19. *Pediatr Dermatol* 2020. doi: 10.1111/pde.14227.
9. Case definition for coronavirus disease 2019 (COVID-19), as of 29 May 2020. European Centre for Disease Prevention and Control <https://www.ecdc.europa.eu/en/covid-19/surveillance/case-definition> (consulted on July 2, 2020).
10. WHO scale for severity of COVID-19 infection. https://www.google.com/url?sa=t&rct=j&q=&esrc=s&source=web&cd=&ved=2ahUKEwjvuJzD48npAhVL0uAKHajJBjMQFjAAegQIBRAB&url=https%3A%2F%2Fwww.who.int%2Fdocs%2Fdefault-source%2Fblue-print%2F-covid-19-therapeutic-trial-synopsis.pdf%3Fsfvrsn%3D44b83344_1%26download%3Dtrue&usg=AOvVaw3eoPFdtgzO-xJtyYEIxnfx (consulted on May 23, 2020).
11. Capone CA, Subramony A, Sweberg T, Schneider J, Shah S, Rubin L, et al. Characteristics, cardiac involvement, and outcomes of multisystem inflammatory disease of childhood (MIS-C) associated with SARS-CoV-2 infection. *J Pediatr* 2020.pii: S0022-3476(20)30746-0. doi: 10.1016/j.jpeds.2020.06.044.
12. COVID-19 Point épidémiologique hebdomadaire du 25 juin 2020. file:///C:/Users/5003131/Downloads/COVID19_PE_20200625.pdf. (consulted on July 10, 2020)
13. Données COVID-19 au Quebec; <https://www.inspq.qc.ca/covid-19/donnees>. (consulted on July 10, 2020)
14. Colmenero I, Santonja C, Alonso-Riaño M, Noguera-Morel L, Hernandez-Martin A, Andina D, et al. SARS-CoV-2 endothelial infection causes COVID-19 chilblains: histopathological, immunohistochemical and ultrastructural study of 7 paediatric cases. *Br J Dermatol* 2020;10.1111/bjd.19327. doi:10.1111/bjd.19327.

15. Santonja C, Heras F, Núñez L, Requena L. COVID-19 chilblain-like lesion: immunohistochemical demonstration of SARS-CoV-2 spike protein in blood vessel endothelium and sweat gland epithelium in a PCR-negative patient. *Br J Dermatol* 2020;10.1111/bjd.19338. doi:10.1111/bjd.19338.
16. Le Cleach L, Dousset L, Assier H, Fourati S, Barbarot S, Boulard C, et al. Most chilblains observed during the COVID-19 outbreak occur in patients who are negative for COVID-19 on PCR and serology testing. *Br J Dermatol* 2020;10.1111/bjd.19377. doi:10.1111/bjd.19377.
17. El Hachem M, Diociaiuti A, Concato C, Carsetti R, Carnevale C, Ciofi Degli Atti M, et al. A clinical, histopathological and laboratory study of 19 consecutive Italian paediatric patients with chilblain-like lesions: lights and shadows on the relationship with COVID-19 infection. *J Eur Acad Dermatol Venereol* 2020;10.1111/jdv.16682. doi:10.1111/jdv.16682.
18. Herman A, Peeters C, Verroken A, Tromme I, Tennstedt D, Marot L, et al. Evaluation of chilblains as a manifestation of the COVID-19 pandemic. *JAMA Dermatol* 2020; e202368. doi:10.1001/jamadermatol.2020.2368.
19. Deeks JJ, Dinnes J, Takwoingi Y, Davenport C, Spijker R, Taylor-Phillips S, et al. Antibody tests for identification of current and past infection with SARS-CoV-2. *Cochrane Database Syst Rev* 2020;6:CD013652.
20. Salje H, Tran Kiem C, Lefrancq N, Courtejoie N, Bosetti P, Paireau J, et al. Estimating the burden of SARS-CoV-2 in France. *Science* 2020;369:208-211.
21. Netea MG, Giamarellos-Bourboulis EJ, Domínguez-Andrés J, Curtis N, van Crevel R, van de Veerdonk FL, et al. Trained immunity: a tool for reducing susceptibility to and the severity of SARS-CoV-2 Infection. *Cell* 2020;181:969-77.

22. Grifoni A, Weiskopf D, Ramirez SI, Mateus J, Dan JM, Moderbacher CR, et al. Targets of T cell responses to SARS-CoV-2 coronavirus in humans with COVID-19 disease and unexposed individuals. *Cell* 2020 May 20:S0092-8674(20)30610-3. doi: 10.1016/j.cell.2020.05.015.
23. Braun J, Loyal L, Frensch M, Wendisch D, Georg P, Kurth F, et al. Presence of SARS-CoV-2-reactive T cells in COVID-19 patients and healthy donors. <https://www.medrxiv.org/content/10.1101/2020.04.17.20061440v1>
24. Kanitakis J, Lesort C, Danset M, Jullien D. Chilblain-like acral lesions during the COVID-19 pandemic (“COVID toes”): histologic, immunofluorescence and immunohistochemical study of 17 cases. *J Am Acad Dermatol* 2020;S0190-9622(20)31022-7.
25. Hubiche T, Cardot-Leccia N, Le Duff F, Giordana P, Chiaverini C, Seitz-Polski B, et al. Clinical, laboratory and interferon-alpha response characteristics of patients with chilblain-like lesions during the SARS-CoV-2 pandemic. *JAMA Dermatol (In press)*
26. Hadjadj J, Yatim N, Barnabei L, Corneau A, Boussier J, Smith N, et al. Impaired type I interferon activity and inflammatory responses in severe COVID-19 patients. *Science* 2020;369:718-24.
27. Lipsker D. A chilblain epidemic during the COVID-19 pandemic. A sign of natural resistance to SARS-CoV-2? *Med Hypotheses* 2020;144:109959.
28. Li G, Ju J, Weyand CM, Goronzy JJ. Age-associated failure to adjust type I IFN Receptor signaling thresholds after T cell activation. *J Immunol* 2015;195:865-74.
29. Hubiche T, Le Duff F, Chiaverini C, Giordanengo V, Passeron T. Negative SARS-CoV-2 PCR in patients with chilblain-like lesions. *Lancet Infect Dis* 2020;S1473-3099(20)30518-1.

30. Guarneri C, Rullo EV, Pavone P, Berretta M, Ceccarelli M, Natale A, et al. Silent COVID-19: what your skin can reveal. *Lancet Infect Dis* 2020;S1473-3099(20)30402-3.

Figure 1. Geographical distribution of children included

Figure 2. Number of infected cases by number of members in each family

Figure 3. Clinical features of acute acral eruptions in children: 3a and b) chilblain-like lesions of the hands and feet; 3c) chilblain-like lesions; 3d) palmar erythema; 3e) acral vesicles; 3f) purpura; 3g) eccrine hidradenitis-like lesions; 3h) pulpitis; 3i) acral papular eruption.

Table 1. Characteristics of children with acute acral eruptions (AAE) (n=103)

Characteristics	Number of available data	N (%)
Age, years Mean \pm SD – Median [IQR]	103	11.1 \pm 5.2 – 13 [8-15]
Sex, males	103	55 (53.4)
Phototype	88	
I		3 (3.4)
II		21 (23.4)
III		49 (55.7)
IV		9 (10.2)
V		2 (2.3)
VI		4 (4.5)
Overweight/obesity (body mass index > 25 kg/m²)	62	3 (4.8)
Passive smoking (second-hand smoke)	69	11 (15.9)
Personal history of chilblains	4	11 (11.1)
Semiological description of AAE*	103	
Chilblain-like		82 (79.6)
Vesicles		19 (18.4)
Palmar/plantar erythema		42 (40.8)
Acrocholosis		7 (6.8)
Acrocholosis		3 (2.9)
Purpura		9 (8.7)
Eccrine hidradenitis-like		6 (5.8)
Pulpitis		7 (6.8)
Acrocyanosis		13 (12.6)
Hyperhidrosis		10 (9.7)
Telangiectasia		4 (3.9)
Acral edema		14 (13.6)
Erythema multiform-like		3 (2.9)
Papules		2 (1.9)
Pain, numeric scale 0 to 10 Mean \pm SD – Median [IQR] Patients with pain (score > 0)	103	1.9 \pm 2.7 – 0 [0-3] 50 (48.5)
Pruritus, numeric scale 0 to 10 Mean \pm SD – Median [IQR] Patients with acral pruritus (score > 0)	103	2.6 \pm 3.0 – 1 [0-5] 58 (56.3)
Location	102	
Hands		15 (14.7)
Feet		16 (15.7)
Hands and feet		71 (69.6)
Patients with other skin manifestations*†	103	21 (20.4)
Fever	102	9 (8.8)
Extracutaneous infectious signs	102	20 (19.6)

*Individual patients may present several signs; †Skin manifestations included urticaria (n=3), maculopapular eruptions (n=3), erythema nodosa (n=2), erythema of the face (n=10), cheilitis (n=1), livedo (n=6); individual patients may present several signs

Table 2. Age of children with acute acral cutaneous signs

Data are median (IQR); IQR: interquartile range; data were compared by Wilcoxon test

Chilblain-like +; n = 82	Chilblain-like -; n= 21	P value
14.0 [11.0-15.0]	5.0 [2.0-11.0]	<0.001
Vesicles +; n = 19	Vesicles -; n = 84	
14.0 [11.5-15.0]	13.0 [8.0-15.0]	0.37
Palmar/plantar erythema +; n = 42	Palmar/plantar erythema -; n = 61	
13.5 [3.0-15.0]	13.0 [9.0-15.0]	0.61
Acrochigosis +; n = 7	Acrochigosis -; n = 96	
14.0 [13.0-16.8]	13.0 [8.3-15.0]	0.09
Purpura +; n = 9	Purpura -; n= 94	
12.0 [2.0-14.0]	13.0 [8.3-15.0]	0.30
Eccrine hidradenitis-like +; n= 6	Eccrine hidradenitis-like -; n= 97	
6.5 [4.3-8.0]	13.0 [9.0-15.0]	0.02
Pulpitis +; n = 7	Pulpitis -; n = 96	
3.0 [2.0-7.0]	13.0 [9.0-15.0]	0.02
Acrocyanosis +; n = 13	Acrocyanosis -; n = 90	
14.0 [13.0-16.0]	13.0 [8.0-15.0]	0.048
Hyperhidrosis +; n = 10	Hyperhidrosis -; n = 93	
14.0 [13.0-15.8]	13.0 [5.0-15.0]	0.10
Acral edema +; n = 14	Acral edema -; n = 89	
14.0 [13.3-16.5]	13.0 [5.0-15.0]	0.03

Table 3. Number of cases within family clusters

	N total	0 cases	1 case	2 cases	3 cases	4 cases	5 cases	6 cases
Families with 1 member*	16	10	6					
Families with 2 members*	24	9	6	9				
Families with 3 members*	34	10	13	7	4			
Families with 4 members*	21	5	4	3	5	4		
Families with 5 members*	7	3	1	2	1	0	0	
Families with 6 members*	1	0	1	0	0	0	0	0
Total number of families	103	37	31	21	10	4	0	0
Total number of households	291	93	84	61	37	16	0	0
Total number of infected cases among households	119	0	31	42	30	16	0	0
Total number of infected cases among households before the index child	77	0	17	31	18	11	0	0
Total number of infected cases among households after the index child at 1-month follow-up†	16	0	3	7	4	2	0	0

*Other than the index child; † 26 infected cases had missing data for time to onset of symptoms

Household infection rate: number of infected cases among households/total number of households = $119/291= 40.9\%$

Percentage of families with COVID-19: $66 (103-37)/103$ children = 64.1%

Table 4. Characteristics of acute acral eruptions (AAE) according to whether household members were infected with SARS-CoV-2

Characteristics	Children from household having at least one case (N = 66)	Children from household having 0 cases (N = 37)	P value
Semiological description of AAE*, n (%)			
Chilblain-like	55 (83.3)	27 (73.0)	0.211
Vesicles	13 (19.7)	6 (16.2)	0.662
Palmar/plantar erythema	28 (42.4)	14 (37.8)	0.650
Acrocholosis	3 (4.5)	4 (10.8)	
Acrocholosis	2 (3.0)	1 (2.7)	
Purpura	7 (10.6)	2 (5.4)	
Eccrine hidradenitis-like	3 (4.5)	3 (8.1)	
Pulpitis	5 (7.6)	2 (5.4)	
Acrocyanosis	11 (16.7)	2 (5.4)	0.128
Hyperhidrosis	3 (4.5)	7 (18.9)	
Telangiectasia	4 (6.1)	0 (0.0)	
Acral edema	7 (10.6)	7 (18.9)	
Erythema multiform-like	3 (4.5)	0 (0.0)	
Papules	0 (0.0)	2 (5.4)	
Evolution**, n (%)			0.888
Complete regression	23 (47.9)	13 (56.5)	
Partial regression	17 (35.4)	8 (34.8)	
Stable	6 (12.5)	2 (8.7)	
Aggravation	2 (4.2)	0 (0.0)	

* Individual patients may present several signs

** Data are missing for 18 patients in the “Children from household having at least one case” group and 14 patients in the “Children from household having no cases” group

Table 5. Laboratory and virology results for children with acute acral eruptions

	Number of tests performed	Anomalies N (%)
Standard lab results	60	2 ^a (3.3)
Creatine phosphokinase	48	2 ^b (4.2)
Inflammatory markers	57	1 ^c (1.8)
Coagulation markers	40	1 ^d (2.5)
Antinuclear antibodies	54	13 ^e (24.1)
Cryo-globulinemia/fibrinogenemia	32	1 ^f (3.1)
PCR SARS-Cov-2 (nasopharyngeal swab)	18	0
SARS-Cov-2 serology	14	2 ^g (13.3)

^aOne case of slight thrombocytosis ($532\ 000/\text{mm}^3$, $N < 450\ 000$) and one case of slight anemia (Hb 11.2g/dl, $N > 11.5$)

^bSlight increase: 183 and 262 ($N < 170$)

^cC-reactive protein level increased in one case (CRP 49.3 mg/l, $N < 5$)

^dVery slight elevation of D-dimers (512, $N > 500$)

^eWhen positive, antinuclear antibodies ranged from 1/80 to 1/640

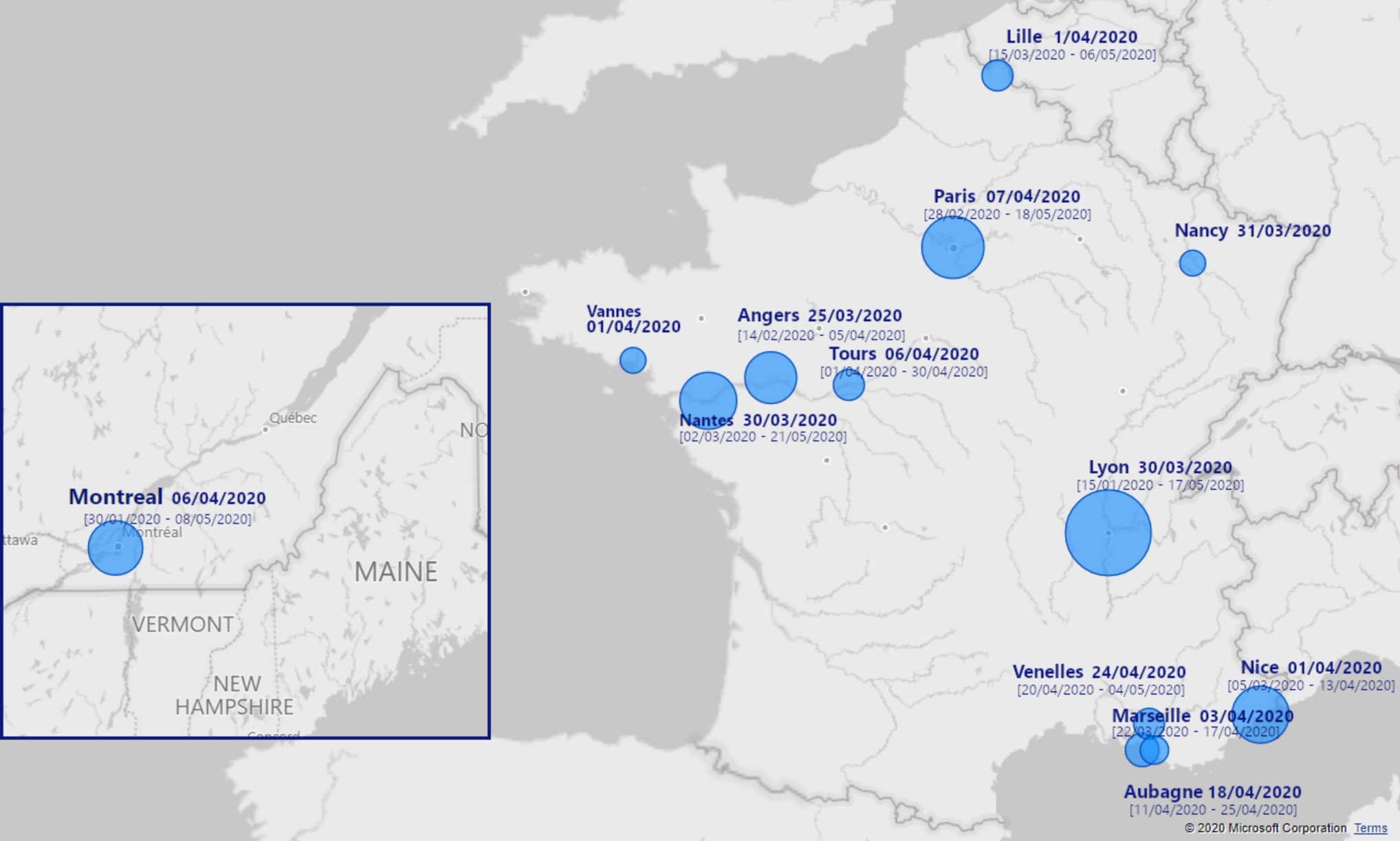
^fModerate polyclonal IgM cryoglobulinemia type 3 (9.80 mg/l)

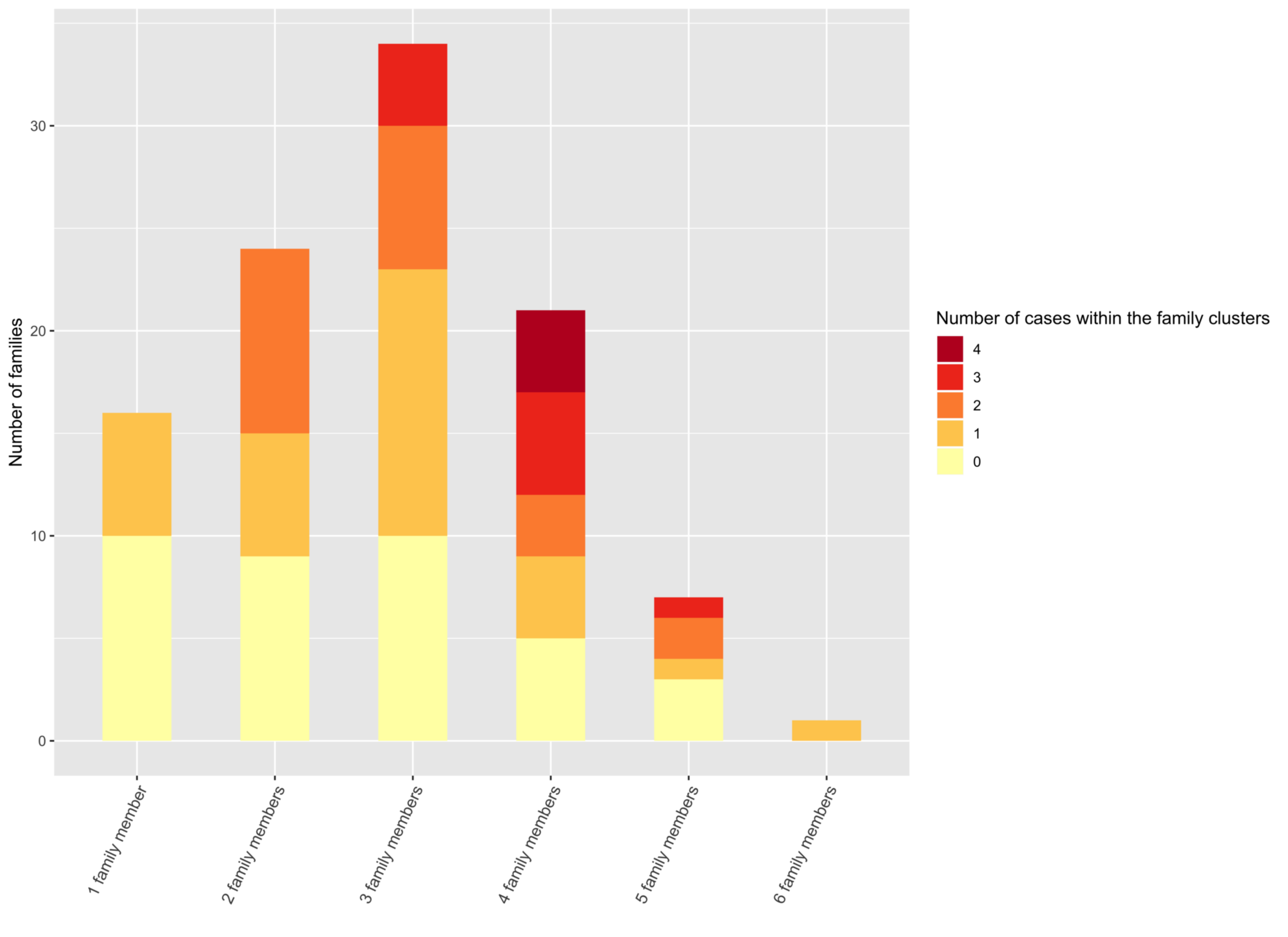
^gPositive IgG, IgM (-)

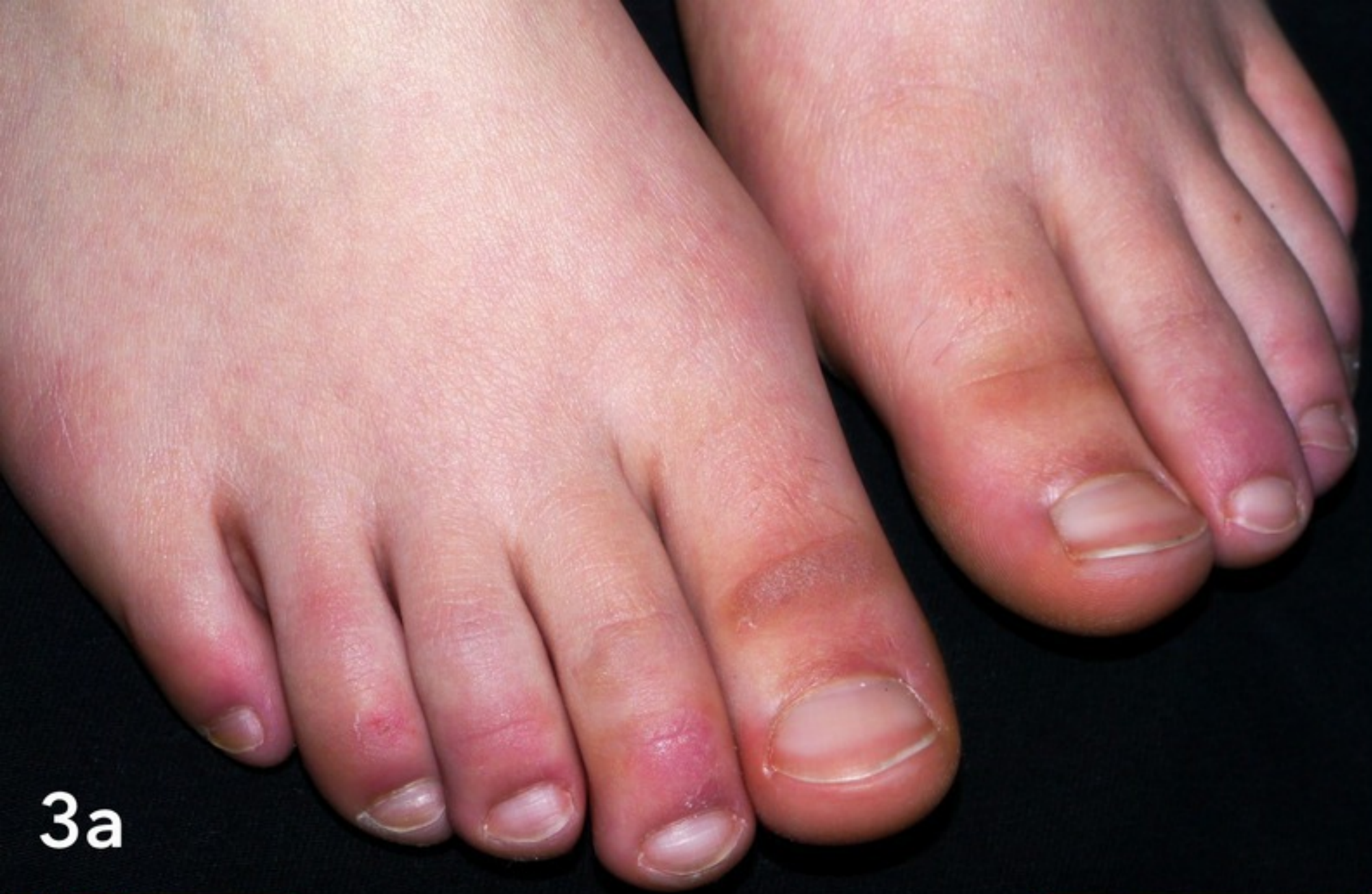Table 6. Microscopy features of skin samples (5 cases of chilblains)

Vacuolization of basal layer	Dermal perivascular lymphocytic infiltrate	Infiltrate of polynuclear eosinophils		Lymphocytic vasculitis	Keratinocytes necrosis	Spongiosis	DIF*	Mucin deposition (Alcian blue staining)
+	+++	-		+	+	-	-	+
-	+	+++		-	-	+	-	+
-	++	+		-	-	+	±	NP [†]
-	+++	-		-	-	+	+	NP [†]
-	++	-		+	-	+	+	-

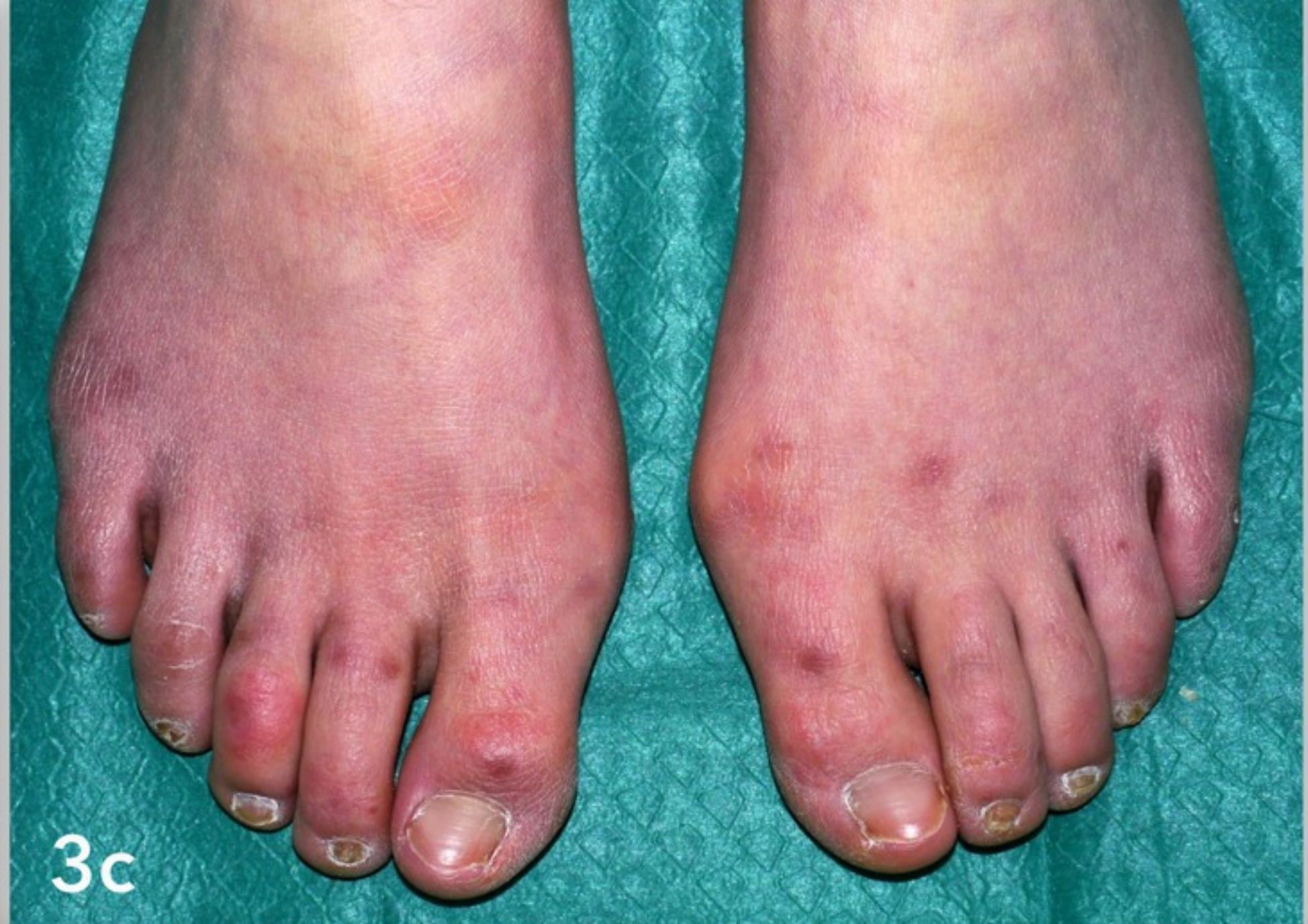*DIF: IgM deposition, no IgA, no IgG, no C3; [†]NP: not performed



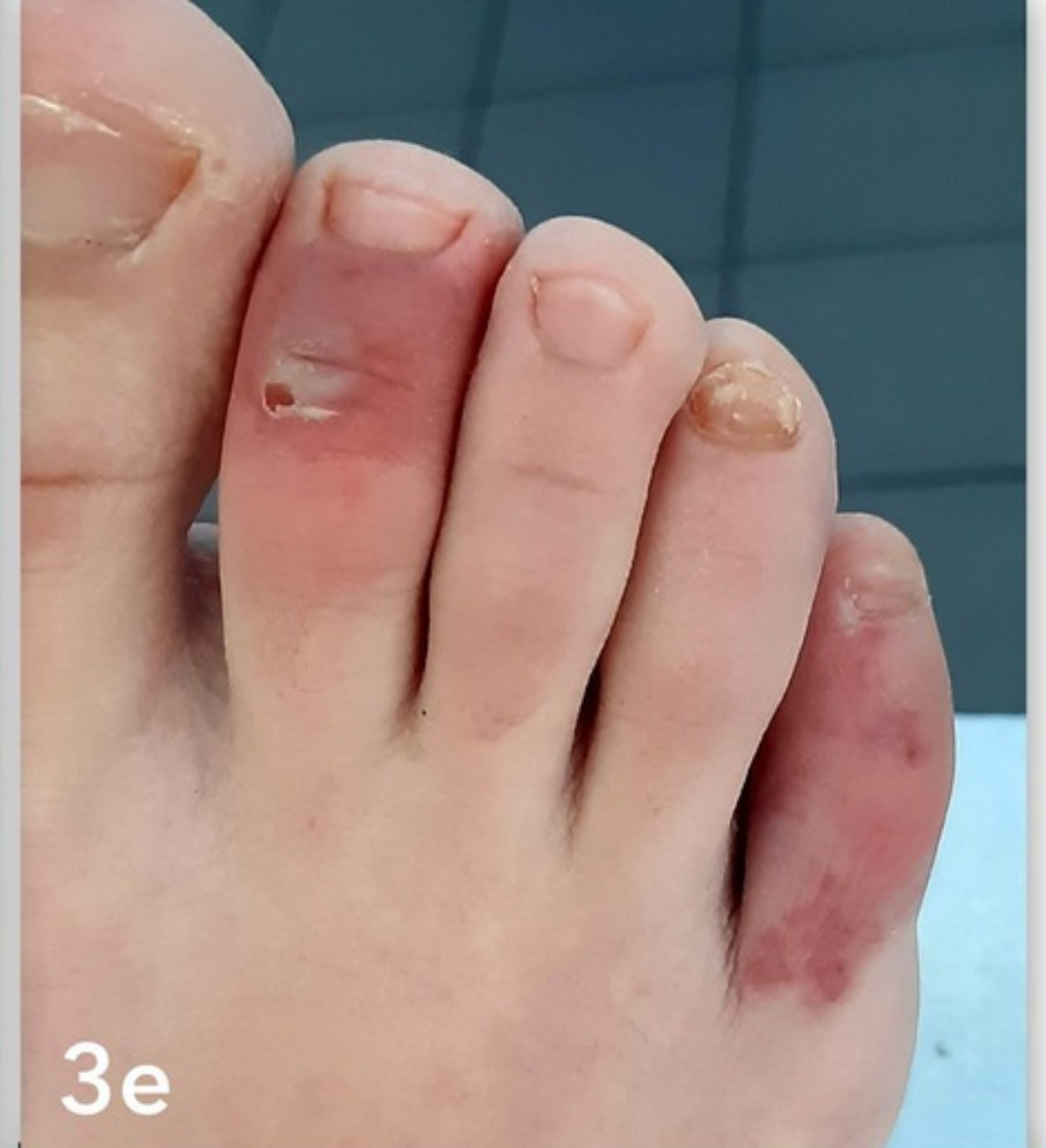



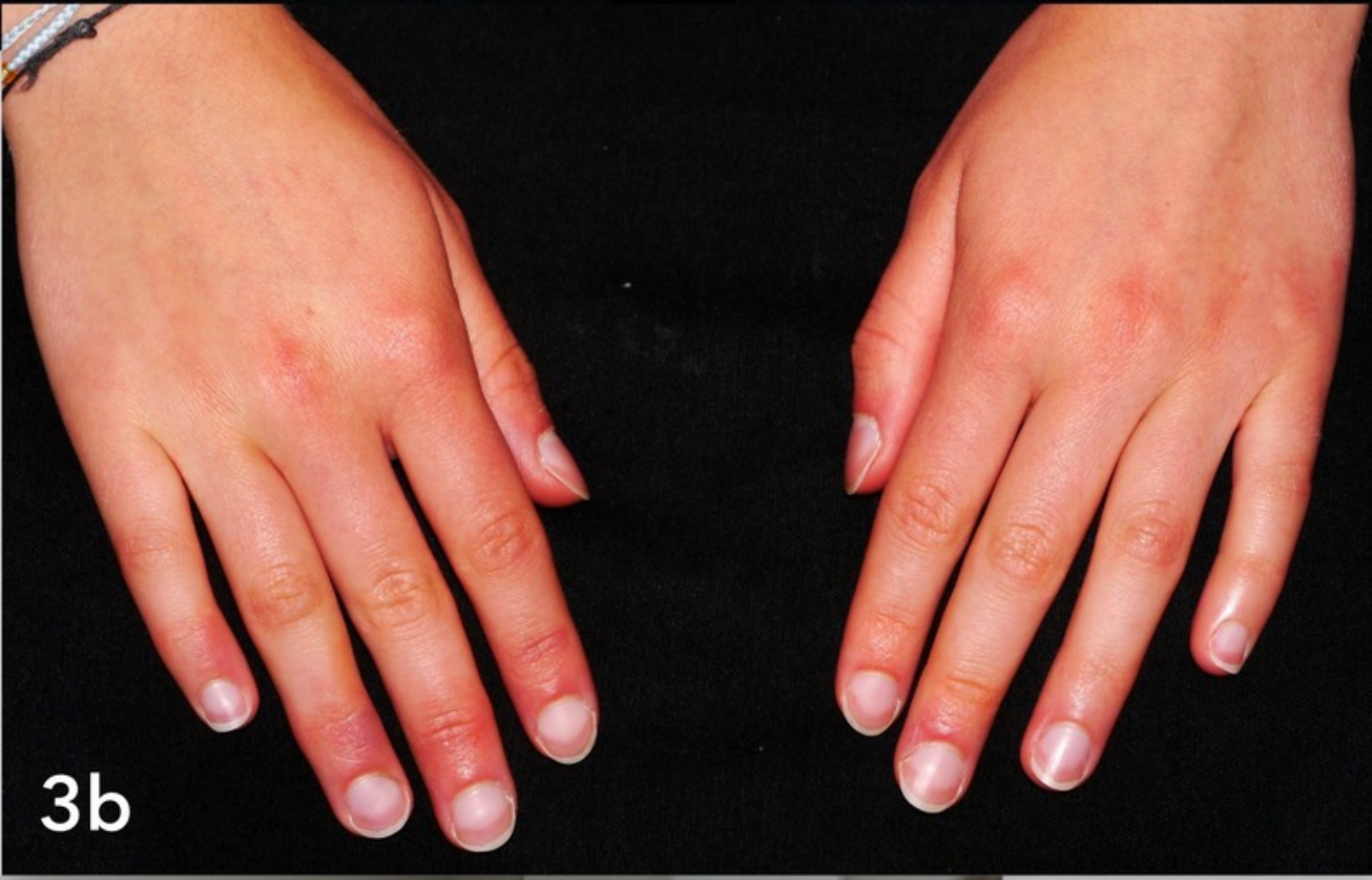3a



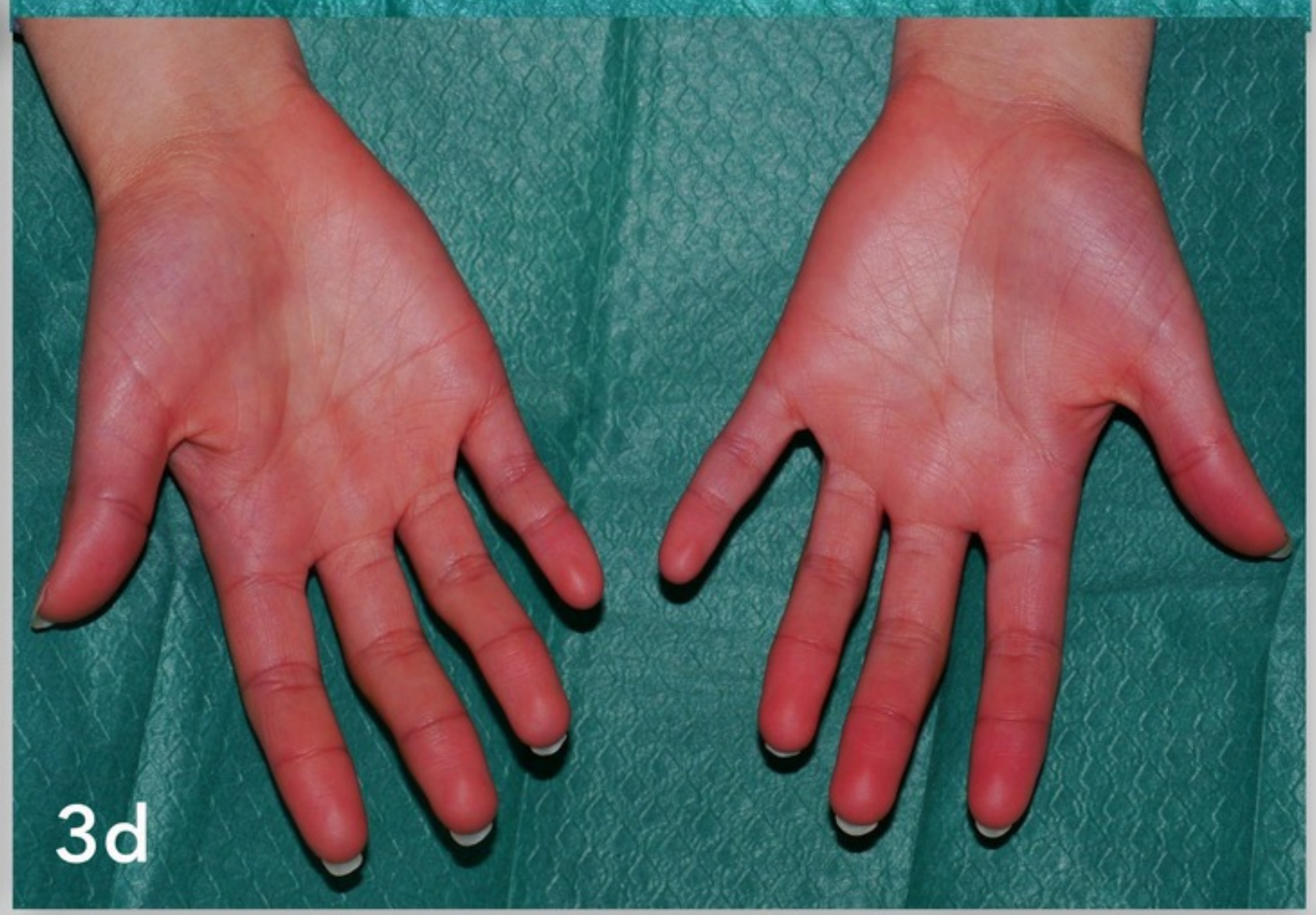3c



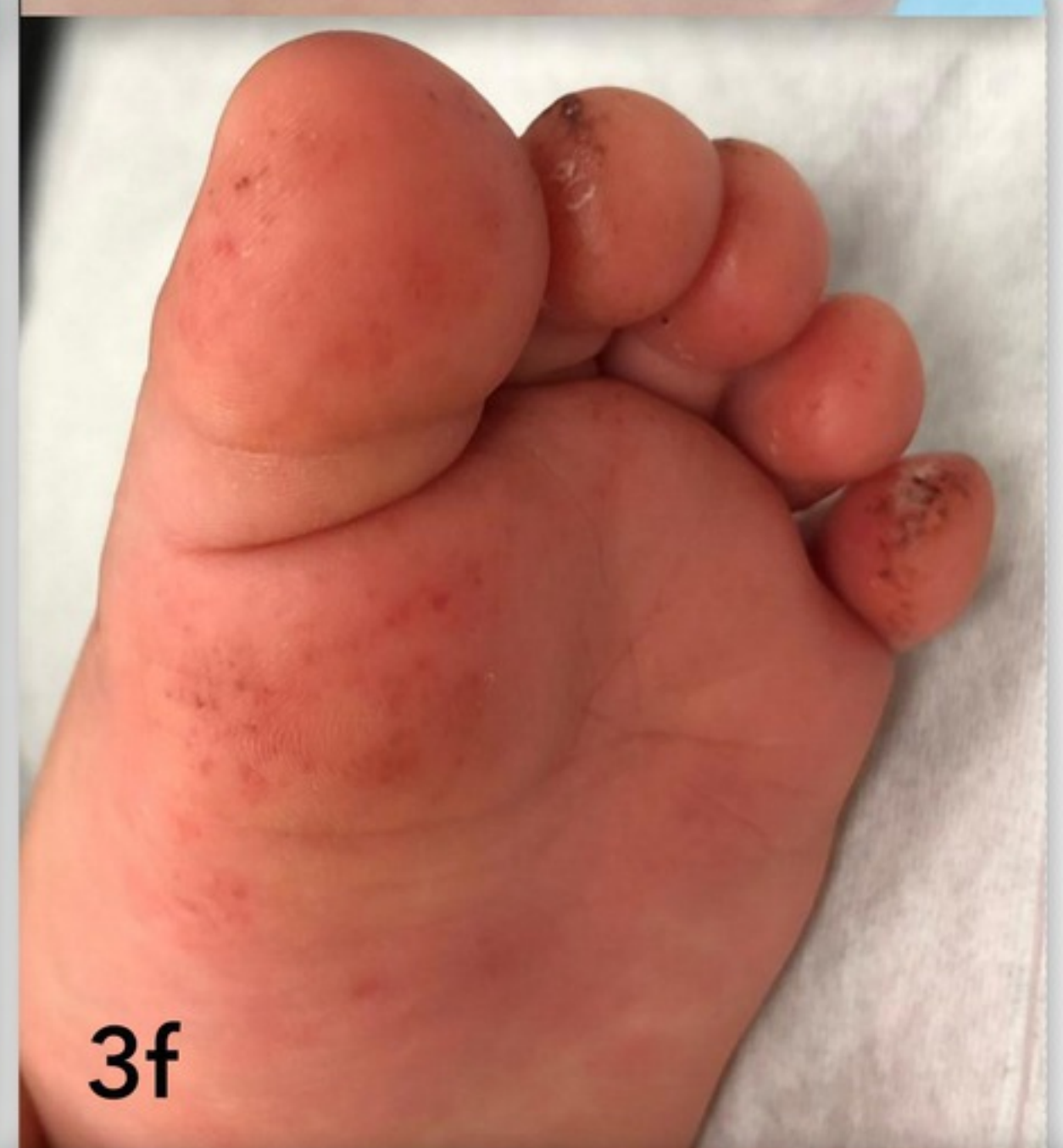3e



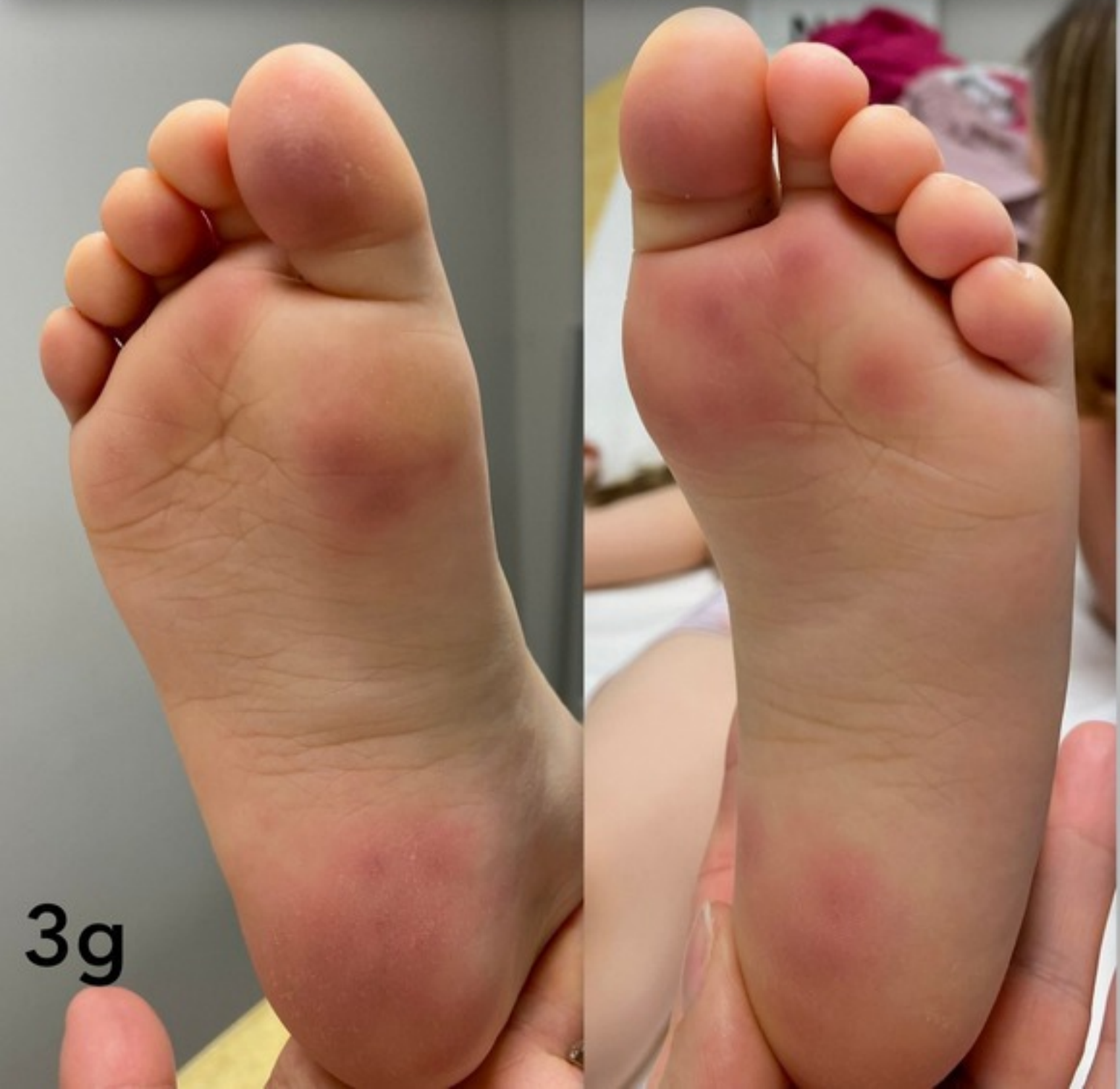3b



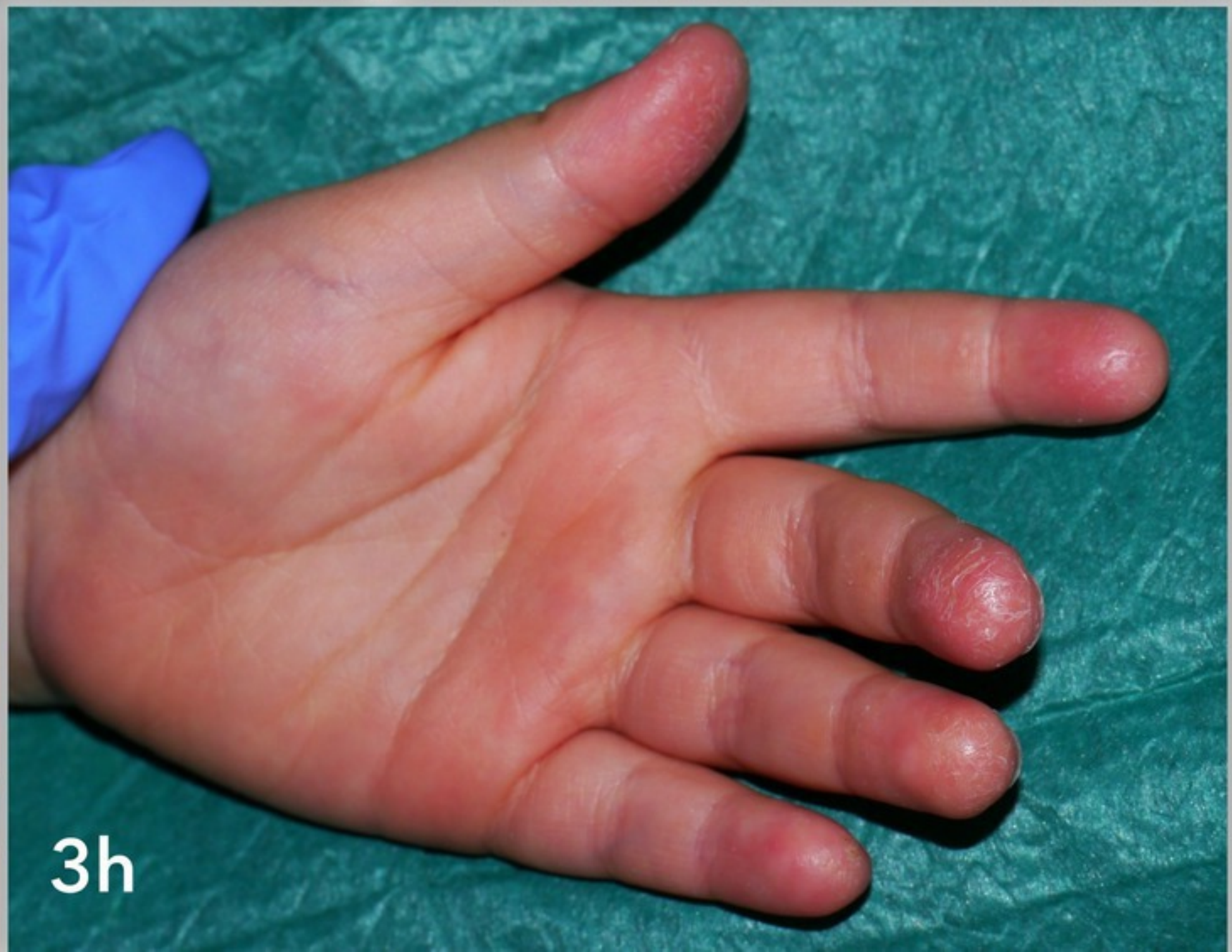3d



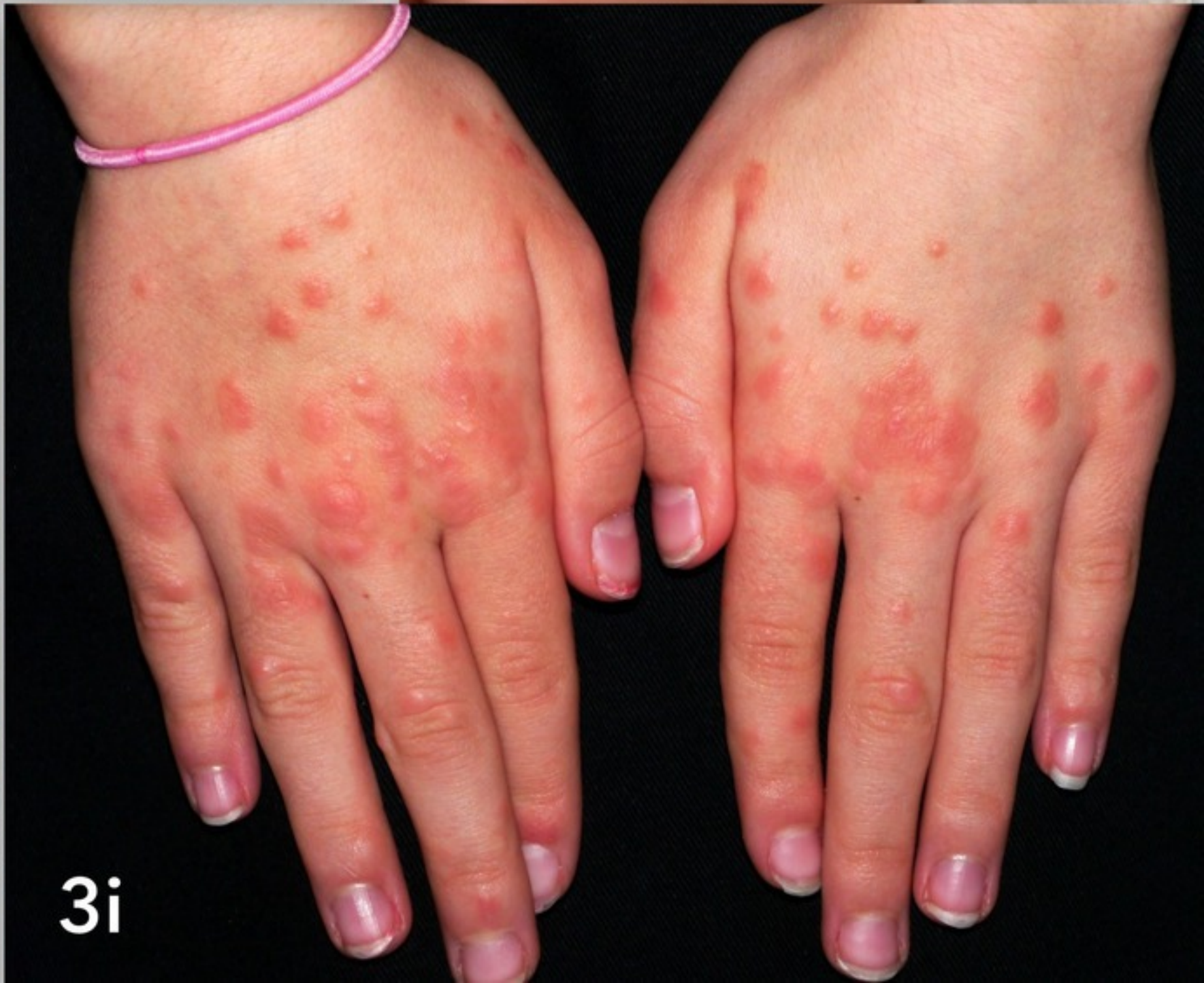3f



3g



3h



3i