



Shear wave elastography reveals different degrees of passive and active stiffness of the neck extensor muscles

Angela Dieterich, Ricardo Andrade, Guillaume Le Sant, Deborah Falla, Frank Petzke, François Hug, Antoine Nordez

► To cite this version:

Angela Dieterich, Ricardo Andrade, Guillaume Le Sant, Deborah Falla, Frank Petzke, et al.. Shear wave elastography reveals different degrees of passive and active stiffness of the neck extensor muscles. *European Journal of Applied Physiology*, 2017, 117 (1), pp.171-178. 10.1007/s00421-016-3509-5 . hal-03337491

HAL Id: hal-03337491

<https://hal.science/hal-03337491>

Submitted on 17 May 2022

HAL is a multi-disciplinary open access archive for the deposit and dissemination of scientific research documents, whether they are published or not. The documents may come from teaching and research institutions in France or abroad, or from public or private research centers.

L'archive ouverte pluridisciplinaire **HAL**, est destinée au dépôt et à la diffusion de documents scientifiques de niveau recherche, publiés ou non, émanant des établissements d'enseignement et de recherche français ou étrangers, des laboratoires publics ou privés.

Shear wave elastography reveals different degrees of passive and active stiffness of the neck extensor muscles

Dieterich, Angela V; Andrade, Ricardo J; Le Sant, Guillaume; Falla, Deborah; Petzke, Frank; Hug, François; Nordez, Antoine

DOI:

[10.1007/s00421-016-3509-5](https://doi.org/10.1007/s00421-016-3509-5)

Document Version

Peer reviewed version

Citation for published version (Harvard):

Dieterich, AV, Andrade, RJ, Le Sant, G, Falla, D, Petzke, F, Hug, F & Nordez, A 2016, 'Shear wave elastography reveals different degrees of passive and active stiffness of the neck extensor muscles', *European Journal of Applied Physiology*. <https://doi.org/10.1007/s00421-016-3509-5>

[Link to publication on Research at Birmingham portal](#)

Publisher Rights Statement:

Checked for eligibility: 16/12/2016

The final publication is available at Springer via

DOI: [10.1007/s00421-016-3509-5](https://doi.org/10.1007/s00421-016-3509-5)

Dieterich, Angela V., et al. "Shear wave elastography reveals different degrees of passive and active stiffness of the neck extensor muscles." *European Journal of Applied Physiology* (2016): 1-8.

General rights

Unless a licence is specified above, all rights (including copyright and moral rights) in this document are retained by the authors and/or the copyright holders. The express permission of the copyright holder must be obtained for any use of this material other than for purposes permitted by law.

- Users may freely distribute the URL that is used to identify this publication.
- Users may download and/or print one copy of the publication from the University of Birmingham research portal for the purpose of private study or non-commercial research.
- User may use extracts from the document in line with the concept of 'fair dealing' under the Copyright, Designs and Patents Act 1988 (?)
- Users may not further distribute the material nor use it for the purposes of commercial gain.

Where a licence is displayed above, please note the terms and conditions of the licence govern your use of this document.

When citing, please reference the published version.

Take down policy

While the University of Birmingham exercises care and attention in making items available there are rare occasions when an item has been uploaded in error or has been deemed to be commercially or otherwise sensitive.

If you believe that this is the case for this document, please contact UBIRA@lists.bham.ac.uk providing details and we will remove access to the work immediately and investigate.

Shear wave elastography reveals different degrees of passive and active stiffness of the neck extensor muscles

Angela V. Dieterich PhD^a, Ricardo J. Andrade MSc^{b,c}, Guillaume Le Sant MSc^{b,c}, Deborah Falla PhD^e, Frank Petzke MD^a, François Hug PhD^{b,f}, Antoine Nordez PhD^b

^a Schmerzmedizin, Klinik für Anästhesiologie, University Medical Center, Göttingen, Germany

^b Laboratory "Movement, Interactions, Performance" (EA 4334), University of Nantes, Faculty of Sport Sciences, France

^c University of Lisboa, Faculty of Human Movement, Cruz Quebrada - Dafundo, Portugal

^d School of Physiotherapy (IFM3R), Nantes, France

^e Centre of Precision Rehabilitation for Spinal Pain (CPR Spine), School of Sport, Exercise and Rehabilitation Sciences, College of Life and Environmental Sciences, University of Birmingham, UK

^f The University of Queensland, NHMRC Centre of Clinical Research Excellence in Spinal Pain, Injury and Health, School of Health and Rehabilitation Sciences, Brisbane, Australia

Corresponding author: A.V. Dieterich, Schmerzklinik, Universitätsmedizin Göttingen; Von-Siebold-

Str.3, 37075 Göttingen; tel: +49551 3920 408; fax: +49551 3920 110; email:

angela.dieterich@bccn.uni-goettingen.de

Acknowledgement

A. Dieterich is a Dorothea-Schlözer Research Fellow of the Georg-August Universität Göttingen, Germany.

Abstract

Purpose: The neck extensor muscles contribute to spinal support and posture while performing head and neck motion. Muscle stiffness relates to passive elasticity (support) and active tensioning (posture and movement) of muscle. It was hypothesized that support and motion requirements are reflected in the distribution of stiffness between superficial and deep neck extensor muscles.

Methods: In ten healthy participants shear modulus (stiffness) of five neck extensor muscles was determined in prone at rest and during isometric head lift at three intensities using shear wave elastography.

Results: Shear modulus differed between muscles ($P < 0.001$), and was larger for the deeper muscles: (median (interquartile range) trapezius 7.7 kPa (4.4), splenius capitis 6.5 kPa (2.5), semispinalis capitis 8.9 kPa (2.8), semispinalis cervicis 9.5 kPa (2.5), multifidus 14.9 kPa (1.4). Shear modulus differed between the resting condition and head lift ($P < 0.001$) but not between levels of head lift intensity.

Conclusion: Shear wave elastography revealed highest passive and active stiffness of the deep neck extensor muscles most close to the spine. The highest active increase of stiffness during the head lift was found in the semispinalis cervicis muscle. The non-invasive, clinically applicable estimates of muscle stiffness have potential for the assessment of muscular changes associated with neck pain/injury.

Key words

Muscle activation, cervical spine, ultrasound, shear wave elastography, neck, shear modulus, synergist

Abbreviations

CV	Coefficient of variation
fMRI	Functional magnetic resonance imaging
Hz	Hertz
kPa	Kilopascal
ROI	Region of interest
s	Second(s)
SD	Standard deviation

Introduction

The cervical spine is the most mobile and delicate region of the spine. It balances the head while enabling the 3-dimensional orientation of the sensory organs over a wide range of motion, which requires both postural and movement-related muscular control. Chronic neck pain is a common and costly health condition (Holm et al. 2009; Hogg-Johnson et al. 2009) which involves an individually different, altered muscular control of the neck (Boudreau and Falla 2014; Juul Kristensen et al. 2013; Gizzi et al. 2015). Long-term, the altered use of muscles entails structural changes of muscle including changed elasticity (Lieber 2010; Lieber and Ward 2013). While this has been shown as a general principle, it has been scarcely examined in the cervical region (Kuo et al. 2013). A better understanding of the interplay of neck muscle activation and muscle elasticity for controlling the cervical spine may further the specific diagnosis of individual conditions and their targeted treatment.

The neck extensor muscles counterbalance the weight of the head during the many daily activities that involve a forwardly orientated head position. Five layers of neck extensor muscles connect the head and neck to the thorax and shoulder region. These are, from superficial to deep, the trapezius, splenius capitis, semispinalis capitis, semispinalis cervicis and multifidus. The muscular control of posture suggests passive muscle properties are adapted for support (Loram et al. 2007; Sakanaka et al. 2016; Keshner et al. 1999; Bergmark 1989) and protection against un-physiological joint translations (Panjabi 2003) and overstretching (Herzog et al. 2015) while wide-range motion requires muscular flexibility. It is hypothesized that these opposing requirements are reflected in the distribution of stiffness in the neck extensor muscles. This implies that changes of neck muscle activation that result in an altered stiffness distribution may affect cervical passive stability as well as the passive and active range of motion.

Ultrasound imaging enables non-invasive measurements of all five layers of the neck extensor muscles (Peolsson et al. 2010; Rezasoltani et al. 2013; Lee et al. 2009). However, conventional ultrasound imaging (B-mode, M-mode and Doppler) reveal shape, thickness, deformation, strain and motion of muscles, not their stiffness. The recent development of ultrasound

shear wave elastography has opened possibilities to measure shear modulus, an estimation of the muscle's stiffness (Hug et al. 2015; Eby et al. 2013), in a localized muscle region from the speed of remotely induced shear waves (Brandenburg et al. 2014; Gennisson et al. 2013; Hug et al. 2015). Measurements of passive muscle shear modulus have been validated in specimens (Eby et al. 2013; Koo et al. 2013) and phantoms (Yoshitake et al. 2014; Miyamoto et al. 2015). Excellent reliability has been documented (Lacourpaille et al. 2012; Dubois et al. 2015). Measurements of active muscle shear modulus have been validated against torque (Yavuz et al. 2015; Bouillard et al. 2011; Yoshitake et al. 2014) and electromyography measurements (Nordez and Hug 2010; Bouillard et al. 2011; MacDonald et al. 2016) with fair to excellent reliability (MacDonald et al. 2016; Yavuz et al. 2015; Yoshitake et al. 2014).

The aim of the present exploratory study was to examine the influence of the layered organization (muscle depth) on muscle stiffness in the resting state and during a head lift. As biomechanical modelling suggests higher stiffness in deep muscles close to the spine (Bergmark 1989) increased resting and active muscle stiffness in the deep muscles was hypothesized. In contrast, lower stiffness was expected from the superficial muscles with the largest distance from the centre of rotation.

Materials and Methods

Ethical approval was obtained from the institutional ethics committee (CPP-MIP-08). Eleven healthy volunteers (4 females; age: 21.7 years [SD 3.2], height: 175 cm [SD 9], body weight 71.0 kg [SD 12.1]) participated. Participants were informed of the purpose of the study and the methods used, and provided informed written consent. Exclusion criteria were neck pain, a history of neck trauma, car accident or neck surgery, unusually increased or decreased cervical lordosis and systemic musculoskeletal diseases. All procedures were performed in accordance with the Declaration of Helsinki. Measurements on one individual were stopped due to insufficient measurement quality, which is indicated by lacking stiffness values (black regions) in the elastogram. Based on the signal-to-

Stiffness of Neck Extensor Muscles

noise ratio, the elastography system creates a quality mask that deletes potentially faulty stiffness measurements from image regions with insufficient image quality (Deffieux et al 2012).

Procedure

Participants were lying prone with their shoulders in abduction and external rotation and with their head resting on their hands. The chest was supported for participants' comfort and such that the cervical spine was in a neutral position. A folded blood pressure cuff was partially inflated and positioned under the lower hand to measure the pressure from the head on the cuff (Fig. 1). Shear modulus of each neck extensor muscle was measured during the resting state, a lift of 1/3 and 2/3 of the head's weight, and a lift of full head weight. In order to achieve quasi isometric neck extensor activation, participants were instructed "Feel the contact and the weight of your head on your hands. While keeping skin contact between forehead and hand, lighten very gently and slowly the weight of your head on your hands until G.S. will tell you to stay. Stay for about 6 s until you are told to relax for a break." This task was chosen because managing the weight of the head is the main function of the neck extensor muscles and deemed a relevant task for potential later comparisons with clinical samples, e.g. individuals with neck pain. Individual target values of 1/3 and 2/3 head lift were calculated from the difference between the pressure of the resting head and the lifted head. One examiner provided auditory guidance on the exerted pressure and the target pressure. Head lifts were sustained over 6 s with rest of at least 30 s between trials. The duration of 6 s was chosen to ensure a period of static activation and, if needed, enable an initial slight adjustment of the transducer angle for improving the image. Recordings in each condition (resting state, three levels of effort) were repeated three times, single repetitions were in randomized order.

Shear-wave elastography

Ultrasound shear wave elastography (Aixplorer version 7; Supersonic Imagine, Aix-en-Provence, France) was recorded at 1 Hz on the right neck extensor muscles (Fig. 2a,b) using a linear transducer with 4 cm footprint (SL10-2 MHz, Supersonic imagine, France). Elastography was set to the musculoskeletal preset, high penetration, smoothing 4, and a range of shear modulus up to 200

Stiffness of Neck Extensor Muscles

kPa. The transducer was orientated longitudinal, centred at the 4th cervical vertebra, positioned 2 cm lateral to the spinous process and aligned closely with the muscle shortening direction of the target muscles (Eby et al. 2013). (Fig. 1). Due to difficulties to include all five muscle layers in a single region of interest (ROI) over which shear modulus was calculated, multifidus and semispinalis cervicis were scanned together, semispinalis capitis was recorded selectively, and splenius capitis and trapezius were scanned together. Care was taken to minimize probe pressure and to position the probe on the same location for each trial.

Using focussed acoustic radiation force, the elastography system produces “push beams” which induce the dispersion of shear waves through the tissue. Subsequently the speed of the shear waves is detected using ultra-high frame rate ultrasound imaging and cross-correlation (Gennisson et al. 2013; Gennisson et al. 2010). Based on shear wave speed (V_s), muscle shear elastic modulus (μ) was calculated as follows: $\mu = \rho V_s^2$, where ρ is the density of muscle (1000 kg/m^3) (Hug et al. 2015; Eby et al. 2013; Gennisson et al. 2013). Videos of the elastograms (Fig. 1) were exported from the software (v7, Supersonic Imagine, Aix-en-Provence, France) in mp4 format. A custom Matlab script (R2013a, MathWorks, Massachusetts, USA) was used to manually define a ROI for each muscle from which the average shear modulus was calculated (Fig. 1). The muscle ROI included the largest visible muscle area that avoided fascia, bone, hypoechoic regions and regions without stiffness values (Deffieux et al. 2012; Bouillard et al. 2011).

Muscle shear modulus was determined for each muscle as the average of the initial 3 s in each condition. Each muscle’s shear modulus during head lift was normalized to the muscle’s smallest shear modulus during the resting state in order to compare the increase of stiffness during head lift between muscles. Absolute shear modulus and shear modulus normalized to resting state stiffness were averaged over the three repetitions of the same condition.

Statistics

Data are presented as median (25% quartile, 75% quartile, or interquartile range, IQR) because some distributions did not pass the Shapiro-Wilk test. To examine the influence of the manual definition of the muscle ROI, the elastography clips of six participants were processed twice with two weeks interval; intra-rater reliability was determined using intraclass correlation coefficients (ICC(3,1)) for single and ICC(3,3) for averaged measurements of shear modulus. Absolute reliability was expressed by the mean difference between measurement repetitions, standard deviation (SD) and standard error of measurement (SEM) (Hopkins 2000). Differences of shear modulus and of normalized shear modulus between muscle layers and levels of effort were examined using two-way repeated measures analysis of variance (ANOVA (within subject factors: muscle layer and level of effort)). The consistency of shear modulus measurements was examined by the coefficient of variation (CV) over the three repetitions in each condition. Differences in the consistency of shear modulus were tested using two-way repeated measures ANOVA (within subject factors: muscle layer and level of effort). For all ANOVAs, when Mauchly's test of sphericity was significant, Greenhouse-Geisser correction was applied. Pairwise comparisons with Bonferroni adjustment were used to specify significant differences. Significance was set to $\alpha = 0.05$.

Results

Intra-rater reliability of the measurements of shear modulus was excellent (Table 1). Shear modulus was higher in the deeper muscles, at resting state: multifidus 14.9 kPa (IQR 1.4), semispinalis capitis 9.5 kPa (IQR 2.5), semispinalis cervicis 8.9 kPa (IQR 2.8), splenius capitis 6.5 kPa (IQR 2.5) and trapezius 7.7 kPa (IQR 4.4) (Fig. 3a), with a significant main effect of the muscle layer on muscle shear modulus ($P < 0.001$). Post-hoc tests revealed non-significant differences between adjacent muscle layers and significant differences to more distant muscle layers (Table 2). Shear modulus increased with the head lift (Fig. 3a,b) with a significant main effect of the level of effort on shear modulus ($P < 0.001$). Post-hoc tests revealed a significant difference between the resting state and head lift conditions but not between the different levels of effort of the head lift (Table 2).

Stiffness of Neck Extensor Muscles

Further, there was a significant interaction effect between muscle and level of effort ($P < 0.001$), which indicates that the effect of effort differed between muscles (Fig. 3a,b).

The effect of effort was demonstrated by the shear modulus normalized to the resting state. There was a significant main effect of the muscle layer on normalized shear modulus ($P = 0.031$). Post-hoc tests revealed a significantly higher increase of shear modulus with head lift in semispinalis cervicis compared to multifidus ($P = 0.011$, Table 2). The consistency of shear modulus between repetitions at the same level of effort was on average 23.5% (range 12% - 31%) and did not differ between muscle layers ($P = 0.62$) or levels of effort ($P = 0.16$) (Table 2).

Discussion

Passive and active shear modulus of the neck extensor muscles differed between muscles and with the effort of a head lift. The head lift was performed mainly with active tensioning in the deeper muscles. Higher activity of the deep neck extensors during a head lift has been demonstrated by invasive electromyography measurements (Siegmund et al. 2007) and by fMRI measurements of neck extensor activation (O'Leary et al. 2011; Elliott et al. 2010; Conley et al. 1997). Compared to fine-wire electromyography and fMRI, ultrasound shear wave elastography is distinguished by its clinical applicability. Thus, the current results encourage the use of shear wave elastography on the neck muscles for diagnostic purposes or for the evaluation of therapeutic interventions.

The deepest muscle layer, the cervical multifidus demonstrated the highest stiffness in the resting state and, together with the semispinalis cervicis, also during head lift. High passive multifidus stiffness has been shown in fibre bundle examinations of the excised lumbar multifidus (Ward et al. 2009) and is thought to protect the spinal joints against translatory motions (Panjabi 2003). The cervical multifidus is predominantly composed of low-threshold slow twitch muscle fibres (Boyd-Clark et al. 2001), which produce greater muscle force with contraction (Petit et al. 1990) and are stiffer (Petit et al. 1990; Toursel et al. 2002) than fast twitch fibres. A postural and often tonic, reflex modulated activity, e.g. in head/trunk coordination and head orientation in space (Richmond and

Stiffness of Neck Extensor Muscles

Bakker 1982) is supported by the great content of muscle spindles (Richmond and Bakker 1982; Boyd-Clark et al. 2002) which implies high stretch sensitivity. Due to its short moment arm towards the spinal joints, multifidus may contribute most efficiently to low-level activation and less to higher level efforts (Fig. 2a).

The semispinalis cervicis demonstrated lower stiffness at rest compared to the multifidus muscle, but stronger active stiffening with the head lift. Commensurate, fMRI measurements of isometric neck extension demonstrated the highest T2 shifts in the deepest neck extensor muscles (not distinguishing multifidus and semispinalis cervicis) (O'Leary et al. 2011). Also biomechanical modelling predicted the largest moment-generating capacity for the semispinalis muscles (without distinguishing cervicis and capitis) (Vasavada and Delp 1998; Nolan and Sherk 1988). Current study results encourage the distinctive examination of multifidus and semispinalis cervicis as their mechanical properties and contributions to managing head weight differed.

The active increase in muscle stiffness of the semispinalis capitis was less than in semispinalis cervicis, although the muscle fibres of semispinalis capitis are best aligned with the cervical spine and the muscle's moment arm is, due to the greater distance from the centre of rotation, advantageous compared to deeper muscles. Probably, this muscle was not sufficiently challenged by lifting the head. Considering a head weight of 3.2 – 4.1 kg (Clemens 1972) and a maximal isometric neck extension force of 127 – 278 N \approx 13-28 kg (Valkeinen et al. 2002; Rezasoltani et al. 2010), a full head lift requires 25% or less of the maximal neck extension force.

Splenius capitis demonstrated the lowest stiffness in the resting state. With an increasing effort of the head lift, tension was developed in a non-linear manner. High splenius capitis activity has been documented with upper cervical head extension (O'Leary et al. 2011) and head rotation (Vasavada et al. 2002). Presumably, the low engagement of splenius capitis in a head lift with a neutral cervical spine, documented also by O'Leary et al (2011), reserves capacities for moving the head in extension or rotation during head lift.

Stiffness of Neck Extensor Muscles

The only non-autochthonous neck muscle, the trapezius, demonstrated a special role; stiffness in the resting state was higher than in splenius capitis but increased only marginally during head lift. Higher stiffness in the resting state may relate to the partial weight of the upper limb which requires passive stretch resistance. Little active involvement of the trapezius during head lift may provide the advantage of free muscular control of shoulder and arm motion (Leong et al. 2013). Collectively, the current study results demonstrate that in normal conditions the head's weight is managed predominantly by the active stiffening of the deep neck extensor muscles.

A study limitation is the high variability of the shear modulus measurements that may have obscured statistic differences between levels of effort. A lower reproducibility of shear modulus measurements on deep compared to superficial muscles has been reported (MacDonald et al. 2016). Also in the current study, measurements of the deeper muscles were more challenging which resulted in smaller muscle-specific ROIs at varying locations. The transducer position had to be modified in search for complete elastograms. Stiffness measurements along muscle fibre direction are most reliable (Dorado Cortez et al. 2016) and reflect best active increase with muscle contraction (Gennisson et al. 2010). The transducer manoeuvres induced slight changes of the scanning angle and the alignment relative to the muscle fibres which probably increased measurement variability (Chernak et al. 2013; Gennisson et al. 2010). However, the transducer manoeuvres in the current study were probably not the major source of variation because measurement reliability and consistency were similar for deep and superficial muscles.

To reduce the number of task repetitions, the shear modulus of two muscles was evaluated in a single recording, which required the positioning of the transducer in between the anatomical shortening directions of the muscles. The expected imprecision was accepted because a complete and precise representation of each muscle by a single transducer position appeared unrealistic due to the complex anatomy of the cervical extensors with a three-dimensional variation of fibre angles, within-muscle differing fascicle orientations and individual anatomic variations (Anderson et al. 2005; Borst et al. 2011). The pragmatic approach of a between-muscles averaged longitudinal orientation

Stiffness of Neck Extensor Muscles

may have led to a slight underestimation of the shear modulus (Gennisson et al. 2010) of multifidus, semispinalis cervicis, splenius capitis and trapezius and, together with the variation in transducer orientation, may have increased the variability of the shear modulus measurements. Shear wave measurements require sufficient quality of the ultrasound images. Ultrasound imaging is an operator-dependent skill. In the present study, R.A. who took the images had 2 years experience in ultrasound imaging of muscle activation and shear wave elastography.

The choice of a low intensity task with small differences between the increments was not optimal for detecting differences. Considering that a full head lift is likely less than 25% of the maximal capacity, increments between levels of effort were 5%-7% of maximum, which would require a high precision for distinction. Participants lifted their head slowly while one examiner instructed to lift further or stop and hold. The precision of performance was controlled only visually. However, if imprecision would have been the main source of variation, more consistent measurements would be expected in the resting state and full head lift, but differences in variation between the conditions were small. Thus and with acknowledgement of the discussed methodological influences, some variability must be considered as physiological variation of performance and force sharing (MacDonald et al. 2016; Falla et al. 2014; Falla and Farina 2007).

In conclusion, healthy young individuals managed the head's weight in isometric conditions mainly using the deep layers of the neck extensor muscles, probably to reserve the more superficial muscles to control head and arm movements. Uniquely, shear wave elastography enables muscle-specific and comparative insights into mechanical muscle characteristics and contributions to isometric tasks in real-time. Elastography estimates of selective muscle stiffness may provide new insights into impaired cervical mechanics e.g. by scar tissue, fibrosis or altered patterns of muscle activation, and will enable evaluation of therapeutic interventions (Hug et al. 2013; Hug et al. 2014).

References

- Anderson JS, Hsu AW, Vasavada AN (2005) Morphology, Architecture, and Biomechanics of Human Cervical Multifidus. *Spine* 30 (4):E86-E91
- Bergmark A (1989) Stability of the lumbar spine. *Acta Orthopaedica Scandinavica* (230 (Suppl.)):20-24
- Borst J, Forbes PA, Happee R, Veeger D (2011) Muscle parameters for musculoskeletal modelling of the human neck. *Clinical Biomechanics* 26 (4):343-351.
doi:10.1016/j.clinbiomech.2010.11.019
- Boudreau S, Falla D (2014) Chronic neck pain alters muscle activation patterns to sudden movements. *Exp Brain Res* 232 (6):2011-2020. doi:10.1007/s00221-014-3891-3
- Bouillard K, Nordez A, Hug F (2011) Estimation of Individual Muscle Force Using Elastography. *PLOS ONE* 6 (12):e29261
- Boyd-Clark LC, Briggs CA, Galea MP (2001) Comparative histochemical composition of muscle fibres in a pre- and postvertebral muscle of the cervical spine. *Journal of Anatomy* 199:709-716
- Boyd-Clark LC, Briggs CA, Galea MP (2002) Muscle spindle distribution, morphology, and density in longus colli and multifidus muscles of the cervical spine. *Spine* 27 (7):694-701
- Brandenburg JE, Eby SF, Song P, Zhao H, Brault JS, Chen S, An K-N (2014) Ultrasound Elastography: The New Frontier in Direct Measurement of Muscle Stiffness. *Archives of Physical Medicine and Rehabilitation* 95:2207-2219
- Chernak LA, DeWall RJ, Lee KS, Thelen DG (2013) Length and activation dependent variations in muscle shear wave speed. *Physiological Measurement* 34 (6):713-721
- Clemens HJ (1972) Das Kopfgewicht des Menschen - ein biomechanisches Problem. *Archiv für orthopädische und Unfall-Chirurgie* 73 (3):220-228
- Conley MS, Stone MH, Nimmons M, Dudley GA (1997) Resistance training and human cervical muscle recruitment plasticity. *Journal of Applied Physiology* 83 (6):2105-2111
- Deffieux T, Gennisson JL, Larrat B, Fink M, Tanter M (2012) The variance of quantitative estimates in shear wave imaging: theory and experiments. *IEEE Transactions on Ultrasonics, Ferroelectrics and Frequency Control* 59 (11):2390-2410
- Dorado Cortez C, Hermitte L, Romain A, Mesmann C, Lefort T, Pialat JB (2016) Ultrasound shear wave velocity in skeletal muscle: A reproducibility study. *Diagnostic and Interventional Imaging* 97 (1):71-79. doi:10.1016/j.diii.2015.05.010
- Dubois G, Kheireddine W, Vergari C, Bonneau D, Thoreaux P, Rouch P, Tanter M, Gennisson J-L, Skalli W (2015) Reliable protocol for shear wave elastography of lower limb muscles at rest and during passive stretching. *Ultrasound in Medicine & Biology* 41 (9):2284-2291
- Eby SF, Song P, Chen S, Chen Q, Greenleaf JF, An K-N (2013) Validation of shear wave elastography in skeletal muscle. *Journal of Biomechanics* 46 (14):2381-2387.
doi:10.1016/j.jbiomech.2013.07.033
- Elliott JM, O'Leary SP, Cagnie B, Durbridge G, Danneels L, Jull G (2010) Craniocervical Orientation Affects Muscle Activation When Exercising the Cervical Extensors in Healthy Subjects. *Archives of Physical Medicine and Rehabilitation* 91 (9):1418-1422.
doi:10.1016/j.apmr.2010.05.014
- Falla D, Farina D (2007) Periodic increases in force during sustained contraction reduce fatigue and facilitate spatial redistribution of trapezius muscle activity. *Exp Brain Res* 182:99-107
- Falla D, Gizzi L, Tschapek M, Erlenwein J, Petzke F (2014) Reduced task-induced variations in the distribution of activity across back muscle regions in individuals with low back pain. *Pain* 155 (5):944-953
- Field A (2009) *Discovering statistics using SPSS*. Sage, London
- Gennisson J-L, Deffieux T, Macé E, Montaldo G, Fink M, Tanter M (2010) Viscoelastic and anisotropic mechanical properties of in vivo muscle tissue assessed by supersonic shear imaging. *Ultrasound in Medicine and Biology* 36 (5):789-801

- Gennisson JL, Deffieux T, Fink M, Tanter M (2013) Ultrasound elastography: Principles and techniques. *Diagnostic and Interventional Imaging* 94 (5):487-495. doi:10.1016/j.diii.2013.01.022
- Gizzi L, Muceli S, Petzke F, Falla D (2015) Experimental Muscle Pain Impairs the Synergistic Modular Control of Neck Muscles. *PLOS ONE* September 18. doi:10.1371/journal.pone.0137844
- Herzog W, Powers K, Johnston K, Duvall M (2015) A new paradigm for muscle contraction. *frontiers in Physiology* 6 (174). doi:10.3389/fphys.2015.00174
- Hogg-Johnson S, van der Velde G, Carroll LJ, Holm LW, Cassidy JD, Guzman J, Côté P, Haldeman S, Ammendolia C, Carragee E, Hurwitz E, Nordin M, Peloso P (2009) The Burden and Determinants of Neck Pain in the General Population: Results of the Bone and Joint Decade 2000–2010 Task Force on Neck Pain and Its Associated Disorders. *Journal of Manipulative and Physiological Therapeutics* 32 (2, Supplement):S46-S60. doi:10.1016/j.jmpt.2008.11.010
- Holm LW, Carroll LJ, Cassidy JD, Hogg-Johnson S, Côté P, Guzman J, Peloso P, Nordin M, Hurwitz E, van der Velde G, Carragee E, Haldeman S (2009) The Burden and Determinants of Neck Pain in Whiplash-Associated Disorders After Traffic Collisions: Results of the Bone and Joint Decade 2000–2010 Task Force on Neck Pain and Its Associated Disorders. *Journal of Manipulative and Physiological Therapeutics* 32 (2, Supplement):S61-S69. doi:10.1016/j.jmpt.2008.11.011
- Hopkins WG (2000) Measures of reliability in sports medicine and science. *Sports Medicine* 30 (1):1-15
- Hug F, Hodges PW, Tucker KJ (2013) Effect of pain location on spatial reorganisation of muscle activity. *Journal of Electromyography and Kinesiology* 23 (6):1413-1420
- Hug F, Ouellette A, Vincenzino B, Hodges PW, Tucker K (2014) Deloading tape reduces muscle stress at rest and during contraction. *Medicine & Science in Sports & Exercise* 46 (12):2317-2325
- Hug F, Tucker K, Gennisson JL, Tanter M, Nordez A (2015) Elastography for Muscle Biomechanics: Toward the Estimation of Individual Muscle Force. *Exercise and Sports Sciences Reviews* 43 (3):125-133
- Juul Kristensen B, Clausen B, Ris I, Jensen R, Steffensen R, Chreiteh S, Jørgensen M, Søgaaard K (2013) Increased neck muscle activity and impaired balance among females with whiplash-related chronic neck pain: A cross-sectional study. *Journal of Rehabilitation Medicine* 45 (4):376-384
- Keshner EA, Hain TC, Chen KJ (1999) Predicting control mechanisms for human head stabilization by altering the passive mechanics. *Journal of Vestibular Research* 9 (423-434)
- Koo TK, Guo J-Ya, Cohen JHb, Parker KJ (2013) Relationship between shear elastic modulus and passive muscle force: An ex-vivo study. *Journal of Biomechanics* 46:2053-2059
- Kuo WH, Jian DW, Wang TG, Wang YC (2013) Neck muscle stiffness quantified by sonoelastography is correlated with body mass index and chronic neck pain symptoms. *Ultrasound in Medicine & Biology* 39 (8):1356-1361
- Lacourpaille L, Hug F, Bouillard K, Hogrel JY, Nordez A (2012) Supersonic shear imaging provides a reliable measurement of resting muscle shear modulus. *Physiological measurement* 33:N19-N28
- Lee J-P, Wang C-L, Shau Y-W, Wang S-F (2009) Measurement of cervical multifidus contraction pattern with ultrasound imaging. *Journal of Electromyography and Kinesiology* 19 (3):391-397. doi:10.1016/j.jelekin.2007.11.007
- Leong HT, Ng GY-F, Leung VY-F, Fu SN (2013) Quantitative Estimation of Muscle Shear Elastic Modulus of the Upper Trapezius with Supersonic Shear Imaging during Arm Positioning. *PLOS ONE* 8 (6):e67199. doi:10.1371/journal.pone.0067199
- Lieber R (2010) Skeletal muscle, structure, function, and plasticity. Wolters Kluwer / Lippincott Williams & Wilkins, Philadelphia
- Lieber RL, Ward SR (2013) Cellular Mechanisms of Tissue Fibrosis. 4. Structural and functional consequences of skeletal muscle fibrosis. *American Journal of Physiology Cell Physiology* 305 (3):C241-C252

Stiffness of Neck Extensor Muscles

- Loram ID, Maganaris CN, Lakie M (2007) The passive, human calf muscles in relation to standing: the non-linear decrease from short range to long range stiffness. *The Journal of Physiology* 584 (2):661-675. doi:10.1113/jphysiol.2007.140046
- MacDonald D, Wan A, McPhee M, Tucker K, Hug F (2016) Reliability of Abdominal Muscle Stiffness Measured Using Elastography during Trunk Rehabilitation Exercises. *Ultrasound in Medicine & Biology* 42 (4):1018-1025
- Miyamoto N, Hirata K, Kanehisa H, Yoshitake Y (2015) Validity of Measurement of Shear Modulus by Ultrasound Shear Wave Elastography in Human Pennate Muscle. *PLOS ONE* 10 (4):e0124311
- Nolan JPJ, Sherk HH (1988) Biomechanical evaluation of the extensor musculature of the cervical spine. *Spine* 13 (1):9-11
- Nordez A, Hug F (2010) Muscle shear elastic modulus measured using supersonic shear imaging is highly related to muscle activity level. *Journal of Applied Physiology* 108:1389-1394
- O'Leary S, Cagnie B, Reeve A, Jull G, Elliott JM (2011) Is There Altered Activity of the Extensor Muscles in Chronic Mechanical Neck Pain? A Functional Magnetic Resonance Imaging Study. *Archives of Physical Medicine and Rehabilitation* 92 (6):929-934. doi:10.1016/j.apmr.2010.12.021
- Panjabi MM (2003) Clinical spinal instability and low back pain. *Journal of Electromyography and Kinesiology* 13 (4):371-379
- Peolsson A, Brodin L-Å, Peolsson M (2010) A tissue velocity ultrasound imaging investigation of the dorsal neck muscles during resisted isometric extension. *Manual Therapy* 15 (6):567-573. doi:10.1016/j.math.2010.06.007
- Petit J, Filippi GM, Emonet-Denand F, Hunt CC, Laporte Y (1990) Changes in muscle stiffness produced by motor units of different types in peroneus longus muscle of cat. *Journal of Neurophysiology* 63 (1):190-197
- Rezasoltani A, Ali-Reza A, Khosro KK, Abbass R (2010) Preliminary study of neck muscle size and strength measurements in females with chronic non-specific neck pain and healthy control subjects. *Manual Therapy* 15 (4):400-403
- Rezasoltani A, Nasiri R, Faizei AM, Zaafari G, Mirshahvelayati AS, Bakhshidarabad L (2013) The variation of the strength of neck extensor muscles and semispinalis capitis muscle size with head and neck position. *Journal of Bodywork and Movement Therapies* 17 (2):200-203. doi:10.1016/j.jbmt.2012.07.001
- Richmond FJR, Bakker DA (1982) Anatomical organization and sensory receptor content of soft tissues surrounding upper cervical vertebrae in the cat. *Journal of Neurophysiology* 48 (1):49-61
- Sakanaka TE, Lakie M, Reynolds RF (2016) Sway-dependent changes in standing ankle stiffness caused by muscle thixotropy. *Journal of Physiology* 594 (3):781-793
- Siegmund GP, Blouin J-S, Brault JR, Hedenstierna S, Inglis JT (2007) Electromyography of superficial and deep neck muscles during isometric, voluntary, and reflex contractions. *Journal of Biomechanical Engineering* 129:66-77
- Toursel T, Stevens L, Granzier H, Mounier Y (2002) Passive tension of rat skeletal soleus muscle fibers: effects of unloading conditions. *Journal of Applied Physiology* 92:1465-1472
- Valkeinen H, Ylinen J, Mälikä E, Alen M, Häkkinen K (2002) Maximal force, force/time and activation/coactivation characteristics of the neck muscles in extension and flexion in healthy men and women at different ages. *European Journal of Applied Physiology* 88 (3):247-254. doi:10.1007/s00421-002-0709-y
- Vasavada A, Peterson B, Delp S (2002) Three-dimensional spatial tuning of neck muscle activation in humans. *Exp Brain Res* 147 (4):437-448. doi:10.1007/s00221-002-1275-6
- Vasavada ANL, S., Delp SL (1998) Influence of muscle morphometry and moment arms on the movement-generating capacity of human neck muscles. *Spine* 23 (4):412-422
- Ward SR, Tomiya A, Regev GJ, Thacker BE, Benzl RC, Kim CW, Lieber RL (2009) Passive mechanical properties of the lumbar multifidus muscle support its role as a stabilizer. *Journal of Biomechanics* 42 (10):1384-1389. doi:10.1016/j.jbiomech.2008.09.042

Stiffness of Neck Extensor Muscles

- Yavuz A, Bora A, Deniz Bulut M, Batur A, Milanlioglu A, Göya C, Andic C (2015) Acoustic Radiation Force Impulse (ARFI) elastography quantification of muscle stiffness over a course of gradual isometric contractions: a preliminary study. *Medical Ultrasonography* 17 (1):49-57
- Yoshitake Y, Takai Y, Kanehisa H, Shinohara M (2014) Muscle shear modulus measured with ultrasound shear-wave elastography across a wide range of contraction intensity. *Muscle & Nerve* 50:103-113

Stiffness of Neck Extensor Muscles

Table 1: Intra-tester reliability of shear modulus of the examined five neck extensor muscles in 6 subjects; intraclass correlation coefficients (ICC), confidence intervals (CI) and absolute differences in mean (standard deviation, SD), standard error of measurement, SEM.

Muscle	Single measures		Averaged measures	
	ICC _{3,1} (CI)	mean (SD), SEM	ICC _{3,3} (CI)	mean (SD), SEM
		kPa		kPa
Trapezius	0.974 (0.956-0.984)	-0.3 (0.9), 0.7	0.988 (0.972-0.995)	-0.3 (0.7), 0.5
Splenius capitis	0.982 (0.971-0.988)	0.2 (1.7), 1.2	0.996 (0.991-0.998)	0.2 (1.1), 0.7
Semispinalis capitis	0.985 (0.974-0.991)	0.6 (2.0), 1.4	0.995 (0.989-0.998)	0.6 (1.4), 0.9
Semispinalis cervicis	0.980 (0.968-0.987)	0.6 (3.6), 2.6	0.997 (0.992-0.998)	0.6 (2.0), 1.4
Multifidus	0.970 (0.953-0.981)	0.0 (4.2), 2.9	0.996 (0.991-0.998)	0.0 (1.9), 1.4

Stiffness of Neck Extensor Muscles

Table 2: Results of two-way repeated measures ANOVAs with within-subject factors 'muscle layer' and 'level of effort'. GG indicates the application of Greenhouse-Geisser correction due to a significant Mauchly test of sphericity with $\epsilon < 0.75$ (Field 2009). Abbreviations: CV, coefficient of variation; Mult, multifidus; Rest, resting state; Semcap, semispinalis capitis; Semcerv, semispinalis cervicis; Splen, splenius capitis; Trap, trapezius; 1/3, lift of 1/3 head weight; 2/3, lift of 2/3 head weight.

Differences between:	Main effect muscle layer	Main effect level of effort	Interaction	Significant post-hoc comparisons, P values	
Shear modulus (absolute)	$F(4,36) = 20.222$, P < 0.001	$F(13,27) = 20.940$, P < 0.001	$F(12,108) = 4.990$, P < 0.001	Mult>Semcap Mult>Splen Mult>Trap Semcerv>Splen Semcerv>Trap Semcap>Trap 1/3>Rest 2/3>Rest Full>Rest	P = 0.011 P = 0.005 P < 0.001 P = 0.040 P = 0.005 P = 0.018 P < 0.001 P < 0.001 P = 0.001
Shear modulus (normalized to resting state)	$F(1.52,13.68) = 4.979$, P = 0.031 (GG)	$F(3,18) = 3.881$, P = 0.040	$F(2.07,18.67) = 1.812$, P = 0.190 (GG)	Semcerv>Mult	P = 0.011 no significant post-hoc comparison for level of effort
CV of repeated trials at the same level of effort	$F(1.78,15.98) = 0.449$, P = 0.623 (GG)	$F(1.54,13.90) = 2.120$, P = 0.163 (GG)	$F(12,108) = 0.940$, P = 0.511		

Stiffness of Neck Extensor Muscles

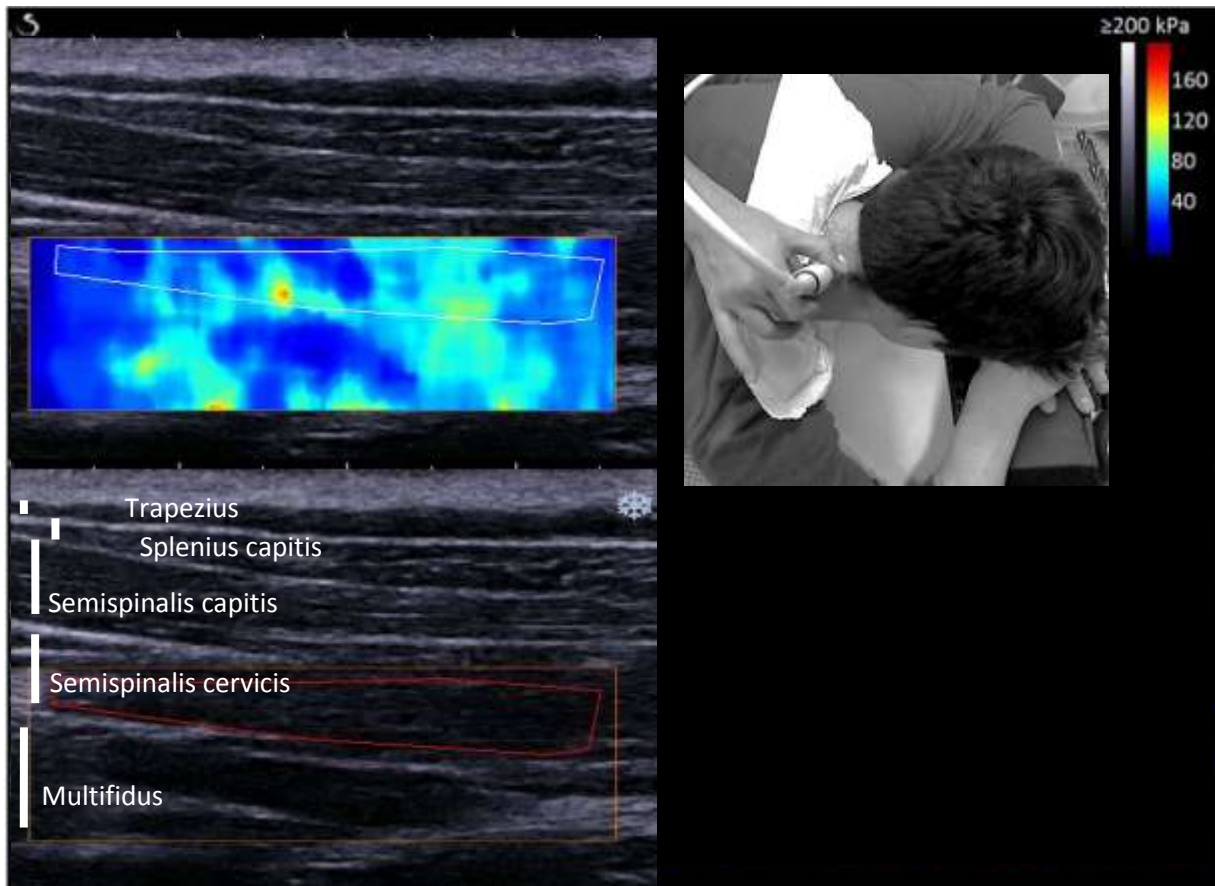
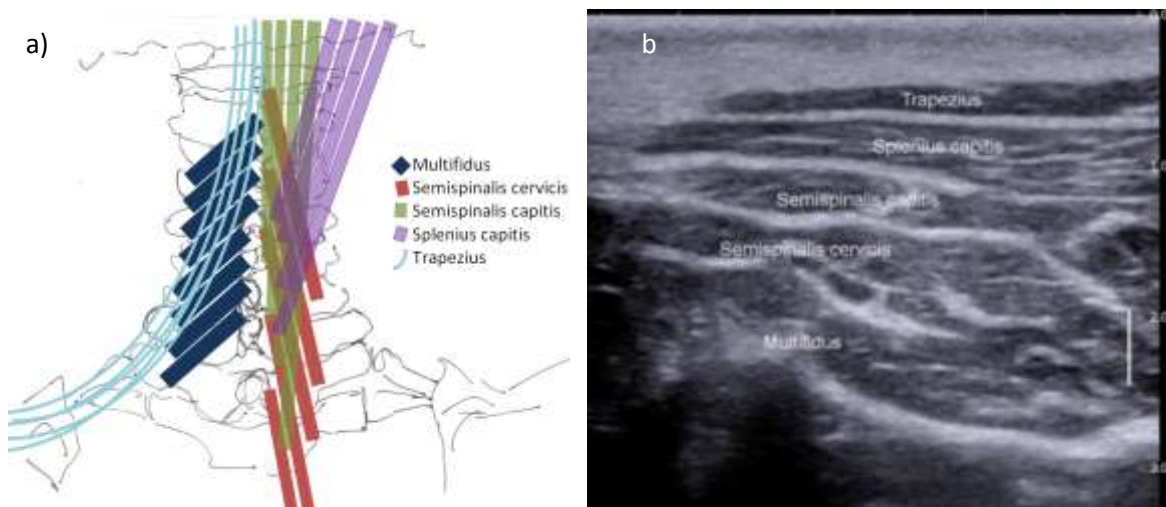
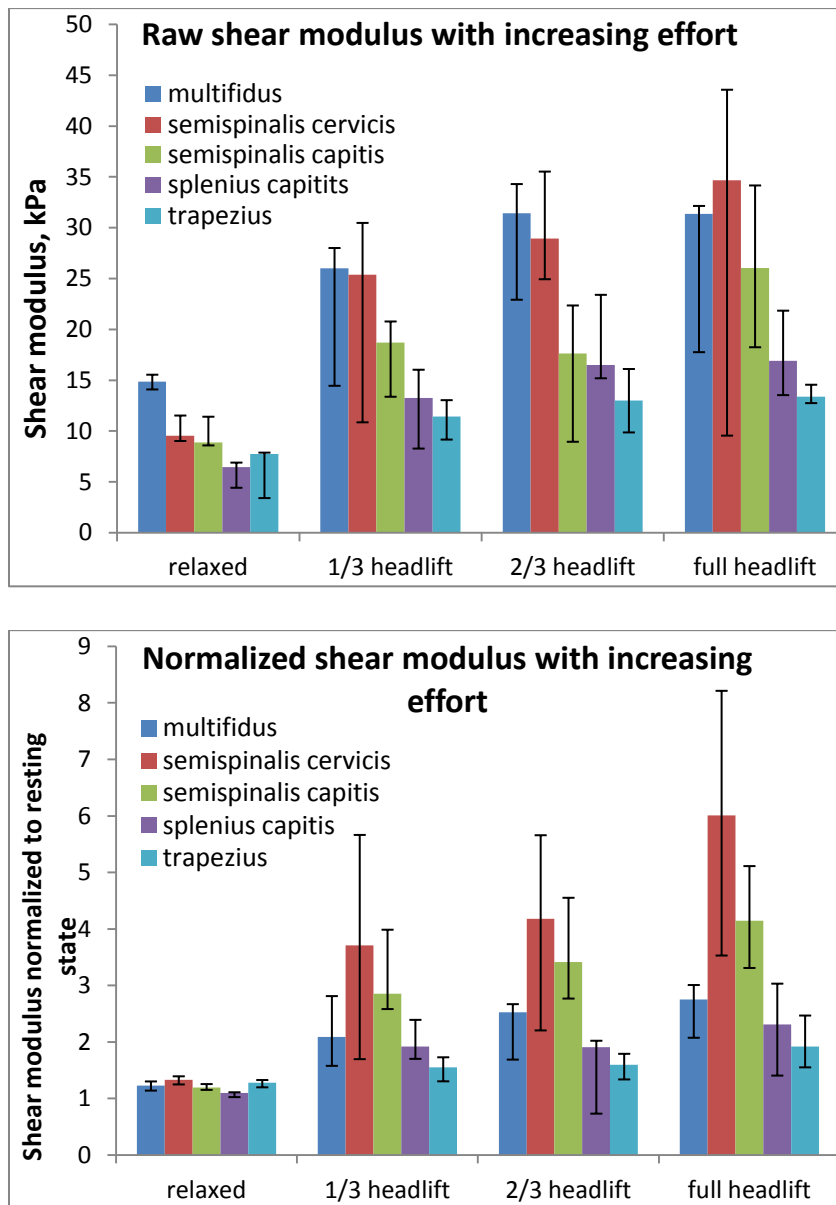


Figure 1: Elastogram of the neck extensor muscles (longitudinal) at the start of a trial of full head lift, each layer of the neck extensor muscles indicated by a white bar at the left edge of the image and labelled; muscle-specific ROI (red shape) inserted for semispinalis cervicis. Note that these data were processed twice, one time for semispinalis cervicis and a second time for multifidus. Subject and transducer position see right top.



Figures 2a, b: Five layers of neck extensor muscles; a) approximate fibre directions (sketched only unilaterally for better distinction); b) B-mode ultrasound cross-sectional view at C4

Stiffness of Neck Extensor Muscles



Figures 3a, b: Shear modulus (median, interquartile range) of the five examined neck extensor muscles during relaxation and head lift; a) shear modulus in kPa, b) shear modulus normalized to the lowest shear modulus in resting state.