



**HAL**  
open science

## Enhancement of color retinal images in poor imaging conditions

G. Russell, J. P Oakley, N. McLoughlin, Vincent Nourrit

► **To cite this version:**

G. Russell, J. P Oakley, N. McLoughlin, Vincent Nourrit. Enhancement of color retinal images in poor imaging conditions. 2012 IEEE International Conference on Imaging Systems and Techniques (IST), Jul 2012, Manchester, United Kingdom. pp.176-178, 10.1109/IST.2012.6295584 . hal-03332155

**HAL Id: hal-03332155**

**<https://hal.science/hal-03332155>**

Submitted on 2 Sep 2021

**HAL** is a multi-disciplinary open access archive for the deposit and dissemination of scientific research documents, whether they are published or not. The documents may come from teaching and research institutions in France or abroad, or from public or private research centers.

L'archive ouverte pluridisciplinaire **HAL**, est destinée au dépôt et à la diffusion de documents scientifiques de niveau recherche, publiés ou non, émanant des établissements d'enseignement et de recherche français ou étrangers, des laboratoires publics ou privés.

# Enhancement of color retinal images in poor imaging conditions

G. Russell,  
Health Intelligence Ltd. Sandbach, UK  
Gregg.russell@health-intelligence.com

J. P. Oakley  
University of Manchester, Faculty of Engineering and  
Physical Sciences, Manchester, UK  
john.oakley@manchester.ac.uk

N. McLoughlin, V. Nourrit  
University of Manchester, Faculty of Life Sciences  
Manchester, UK  
vincent.nourrit@manchester.ac.uk

**Keywords-component: retinal imaging, scattering.**

## I. INTRODUCTION

One of the first accounts of retinal observation in vivo was perhaps Jean Mery's now famous report to the French Royal Academy of Sciences in 1684. The French anatomist described how immersing a cat underwater allowed him to observe the retina in more details [1]. Nowadays a large range of retinal imaging instruments exists (e.g. flood imaging, optical scanning laser ophthalmoscopy, optical coherence tomography, etc. [2]) together with sophisticated techniques to correct for the eye's optical aberrations (e.g. adaptive optics, deconvolution [3]).

Aberrations are however only one of the two main optical phenomena degrading the retinal image's quality. As light propagates to and from the retina, it will be scattered by small inhomogeneities within the ocular media [4]. The amount of scattering in a young non pathological eye is low but increases with age and some pathologies (e.g. cataract). This increased scattering results in a degradation of the retinal image in terms of reduced brightness, poorer contrast, colour degradation and possibly lower spatial resolution.

This phenomenon is similar to the degradation of images caused by atmospheric conditions. Although a large body of work exists on the enhancement of images recorded in poor visibility conditions, a paucity of papers have focused on reducing the degradation of retinal images by intraocular scattering [5].

In this context, our aim was to adapt and assess the potential of an automatic defogging system to retinal imaging.

## II. METHODS

### A. Descattering

Image contrast enhancement can be divided into two main types: model based and non model based. Model based algorithms improve image contrast by reversing the underlying cause of image degradation but requires a large amount of information about the geometry of the scene and the nature of the scattering. Due to the difficulty to develop a realistic yet

tractable model of intraocular scattering, we investigated non-model based algorithms as they do not require information about the cause of degradation.

Perhaps the most important non-model based algorithm is histogram equalization (HE). This algorithm is usually performed on the luminance and saturation of the image but not the hue so as to maintain the original color. However, because intraocular scattering is partly wavelength dependent [6], this method may cause some color degradation.

Oakley and Bu [7] presented a successful non-model based algorithm to restore the chrominance and luminance of a scene while maintaining good color fidelity. In this model, the image (I) recorded by the camera is the sum of the light reflected by the scene (here the retina (R)) as it would be observed in the absence of scattering together with the scattered light, known in the remote sensing literature as "airlight" (A).

$$I = R + A \quad (1)$$

The airlight value will depend on the distribution and the concentration of the different scattering particles (e.g. keratocytes in the cornea, proteins aggregates in the crystalline lens), the distance from the eye to the camera and the angle of illumination. As a result, the airlight value can vary across the image. Another version of this algorithm has recently been reported that can deal with such spatial variation [8]. The degradation model assumed in both [7] and [8] is an additive noise with a possible scaling of the R term due to extinction. In extremely turbid conditions this model breaks down and significant blurring takes place due to small-angle scattering and recovery of a clear image becomes difficult. However in previous work it was found that the additive noise is the most significant image defect in atmospheric imaging. It is therefore reasonable to assume that the same may be the case in retinal imaging but it is obviously important to check this empirically.

### B. Artificial images

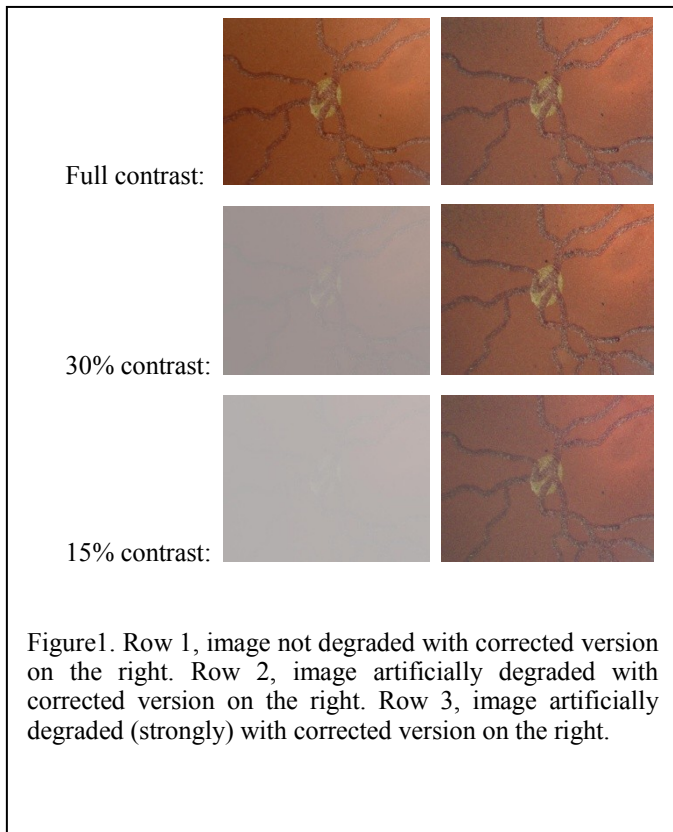
We first assessed the potential of the technique on retinal images artificially degraded. The images were obtained with an artificial eye and a standard fundus camera. After acquisition

an airlight value was added to the images to simulate various level of scattering. This allowed us to assess the optimum value for the adjustable parameters (one that controls the level of spatial variation of the airlight estimate and one that controls the noise compensation) and to quantify the ability of the algorithm to estimate the airlight value.

### C. Real images

The industrial partner, Health Intelligence Ltd, provided us with a series of retinal images obtained in patients with various degrees of ocular opacities and recorded with a similar camera

## III. RESULTS



Results obtained with artificial images are illustrated in figure (1). Row 1 shows an image of an artificial eye, with the enhanced image to the right. Rows 2 and 3 show the same image but with the contrast deliberately reduced to 30% and 15% using Matlab software with the following command lines:

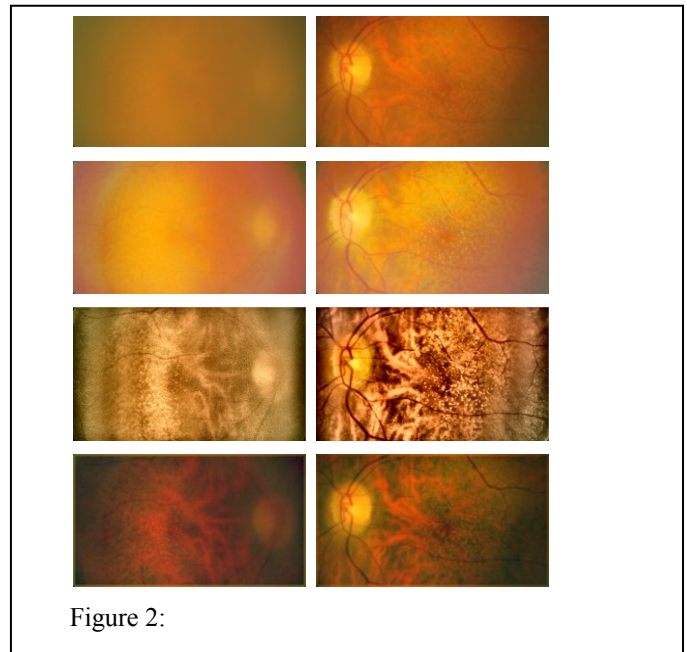
$$\begin{aligned} \text{im2} &= \text{im1} * 0.30 + 0.70 + 0.004 * \text{randn}(\text{size}(\text{im1})); \\ \text{im3} &= \text{im1} * 0.15 + 0.85 + 0.004 * \text{randn}(\text{size}(\text{im1})); \end{aligned}$$

where im2 and im3 are output images, im1 is the input image (scaled to unity with no gamma encoding) and the 'randn' function generates a Normally-distributed random number that represents a realistic noise level.

As can be observed, the "correction" does not significantly degrade the image if no scattering is present (i.e. no airlight).

When the visibility is very poor, e.g. in case of advanced cataract, the recovered images show a grainy effect. This is due to the scaling needed to restore image contrast after subtraction of the airlight [8]. However, in spite of this defect, the recovered images show a good level of consistency when the input contrast falls to low levels such that the retinal vessels become almost completely invisible.

Results obtained with real images are illustrated in figure (2) and these show a similar effect. The first row presents the original images. On the second row, the images are corrected by histogram equalization. This processing was performed



using Photoshop CS5.1 from Adobe Corporation. On the third row, images are improved using a more sophisticated contrast enhancement technique (i.e. Contrast-limited adaptive histogram equalization (CLAHE) [9]). Finally, images corrected using our technique are presented on the bottom row.

Image quality is by nature subjective, particularly for images of low to moderate quality as the ones processed, and although few metrics have been suggested for retinal images, there is not yet an accepted gold standard [10]. In addition, the quality of an image measured with one of these metrics may not correlate well with the suitability of an image for diagnosis purposes. For these reasons, the processed images presented in Figure 2 were assessed subjectively by an expert retinal grader.

As can be observed simple histogram equalization provides little improvement and significantly alters the color balance. Results presented on the last 2 rows appear more beneficial. The color balance in images processed with CLAHE appears however strongly altered and less natural which reduces the possibility to differentiate between various clinical elements such as arteries and veins, or drusens and exudates. Important

artefacts are also present as bands on the right and left sides of the images. If less dramatic, such artefacts could be misinterpreted as pathological feature (e.g. choroidal fold).

#### IV. DISCUSSION

A novel method to improve the quality of retinal images degraded by scattering is presented. The main advantage is the ability to automatically improve the contrast and color fidelity of the image. These improvements were superior to those achieved with locally adaptive histogram equalization.

Such improvements could be highly beneficial in the context of screening for Diabetic Retinopathy (DR). Diabetic patients regularly undergo fundus photography and if the image is considered "inadequate" by retinal graders the patient will usually be referred to additional examination leading to more stress for the patient, possibly a delayed diagnosis, and increased costs for the health care system.

Current methods used in retinal screening to enhance images rely basically on simple brightness and contrast manipulations which can easily lead to loss of information (e.g. blown out highlights) or the creation of spurious clinical information (e.g. colour distortion may lead a pigment to look like a microaneurysm or fine vessels to be confused with a microvascular abnormality). Our method overcome these faults of colour and feature distortion, allowing the colour levels and contrast to be optimised automatically to offer the grader additional information. This should help reducing the rate of ungradable images (current rate for most screening program is higher than the 7% recommended rate by the

Diabetic Eye Screening Program) and associated inappropriate referrals for additional eye examination.

We plan now to test our algorithms on a large database of images to confirm that it will not convey any erroneous clinical information (e.g. to hide an existing lesion or to create a non-existing one) and quantify the improvements achieved.

#### REFERENCES

- [1] P. M. Damel, "A simple and inexpensive method for examining the fundus oculi" in *Physiol.* 1963; 169(Suppl): 1P-9P
- [2] , M.D.; Garvin, M.K.; Sonka, M.; , "Retinal Imaging and Image Analysis," *Biomedical Engineering, IEEE Reviews in* , vol.3, no., pp.169-208, 2010
- [3] V. Nourrit, B. Vohnsen and P. Artal. Blind deconvolution for high-resolution confocal scanning laser ophthalmoscopy. *Journal of Optics* 2005; 10(7): 585-92
- [4] V. Nourrit, JM Kelly. Intra-ocular scatter and visual performances. *Optometry in practice* 2009; 10(3):117-26
- [5] Peli E, Peli T, Restoration of retinal images obtained through cataracts. *IEEE Trans Med Imaging.* 1989;8(4):401-6.
- [6] E. J. McCartney, *Optics of the Atmosphere* (Wiley, Toronto,1976).
- [7] J P Oakley and H Bu, 2007, Correction of simple contrast loss in color images, *IEEE Trans. on Image Processing*, 16 (2), pp 511-522.
- [8] J.P. Oakley and Z. Marceta. An Automatic HD Defogging System. *The Best of IBC and IET.* 2011 September; 3: 1. eScholarID:143707
- [9] [9] Zuiderveld, Karel. "Contrast Limited Adaptive Histogram Equalization." *Graphic Gems IV.* San Diego: Academic Press Professional, 1994. 474-485.
- [10] J. Paulus, J. Meier, R. Bock, J. Hornegger, G. Michelson. "Automated quality assessment of retinal fundus photos". *Int J Comput Assist Radiol Surg.* 2010 Nov;5(6):557-64.