



HAL
open science

3D reappraisal of trepanations at St. Cosme priory between the 12th and the 15th centuries, France

Samuel Bédécarrats, Valentin Micolon, Nadine Travers, Matthieu Gaultier,
Estelle Herrscher, Hélène Coqueugniot

► **To cite this version:**

Samuel Bédécarrats, Valentin Micolon, Nadine Travers, Matthieu Gaultier, Estelle Herrscher, et al..
3D reappraisal of trepanations at St. Cosme priory between the 12th and the 15th centuries, France.
International Journal of Paleopathology, 2021, 34, pp.168-181. 10.1016/j.ijpp.2021.07.003 . hal-
03328279

HAL Id: hal-03328279

<https://hal.science/hal-03328279>

Submitted on 6 Oct 2021

HAL is a multi-disciplinary open access archive for the deposit and dissemination of scientific research documents, whether they are published or not. The documents may come from teaching and research institutions in France or abroad, or from public or private research centers.

L'archive ouverte pluridisciplinaire **HAL**, est destinée au dépôt et à la diffusion de documents scientifiques de niveau recherche, publiés ou non, émanant des établissements d'enseignement et de recherche français ou étrangers, des laboratoires publics ou privés.

3D reappraisal of trepanations at St. Cosme priory between the 12th and the 15th centuries, France.

Bédécarrats, Samuel (UMR CITERES 7324 - LAT; Université de Tours)*

Miclon, Valentin (UMR CITERES 7324 - LAT; Université de Tours)*

Travers, Nadine (CHRU de Tours - Service de neurochirurgie pédiatrique, Hôpital Clocheville)

Gaultier, Matthieu (SADIL; UMR CITERES 7324 - LAT)

Herrscher, Estelle (LAMPEA UMR 7269, Aix-Marseille Université, CNRS, Ministère Culture)

Coqueugniot, Hélène (UMR 5199 PACEA; Université de Bordeaux; École Pratique des Hautes Études - EPHE-PSL).

*These authors contributed equally to this work.

Abstract

Objective

This study aims to place trepanation in a medieval therapeutic context by addressing its medical use in neurological disorders and by testing the existence of particular dietary care for the sick.

Materials

Six cases of trepanation found at the St. Cosme priory (La Riche, France) dated from the 12th-15th centuries.

Methods

Neurological health was explored by geometric morphometrics by comparing the six cases to 68 skulls and 67 endocraniums belonging to individuals from the same period and geographical area. Trepanned diet was investigated by carbon and nitrogen isotopes and compared to 49 individuals from the same site.

Results

The study of shapes suggests a possible pathological state for four subjects. The diet of the trepanned is not different from the rest of the population.

Conclusions

The treatment of neurological disorders emerges as the main therapeutic motivation in the corpus, contrary to the reports from the ancient surgical treatises. A specific diet for the sick is not highlighted.

Significance

Geometric morphometrics is rarely used in paleopathology and the results suggest a potential of this type of analysis in the identification of pathological cases. The results on therapeutic motivations and diet do not fit the descriptions from ancient medical sources.

Limitations

The study of forms did not lead to definitive diagnosis. The isotopic study does not allow us to appreciate all the aspects of the diet.

Suggestions for Further Research

A geometric morphometric study of the skulls and endocraniums of individuals with a known neurological condition would allow a better appreciation of the link between shapes and pathologies.

Keywords

Trepanation ; Middle ages ; 3D imaging ; Geometric morphometrics ; Isotopes

1. Introduction

1.1. Trepanation in the middle ages

Trepanation refers to the use of a small circular saw called trepan. However, its use in medical vocabulary is broader and is metonymically equivalent to the action of perforating a bone (Quevauvilliers et al., 2011). Since the work of (Broca, 1867), this term has been used in archaeology to refer to an anthropic perforation of a bone of the skull vault not resulting from an act of violence or an accident.

Trepanning is the oldest surgical procedure documented by archaeology (Arnott et al., 2003; Verano and Finger, 2009) with cases dating back to the Epipaleolithic (Ferembach et al., 1962) and the Mesolithic (Lillie, 1998). Although prehistoric cases are numerous and broadly studied (Verano, 2016) the aims of trepanning are hard to assess by osteological examination. Taking into account the textual sources, the study of trepanation during historical periods allows us to place it in a broader therapeutic context.

According to ancient and medieval medicine, body functions are governed by four humours. As disorder results from the imbalance of these, therapy is seen as a health regimen (diet, exercise, rest, environmental conditions) that either prevents an excess or a deficiency of humours, or allows a return to a state of equilibrium (Magner, 2005; Siraisi, 1990). Surgery intervenes when such therapy is not sufficient, as summarized in the Hippocratic aphorism 7: 87: "Those diseases which medicines do not cure, iron cures; those which iron cannot cure, fire cures; and those which fire cannot cure, are to be reckoned wholly incurable" (ed. Littré, 1844). Cranial interventions involving the removal of part of a bone are described in ancient and medieval surgical treatises in the chapters addressing cranial trauma (e.g. On injuries of the head Hippocrates, c. 400 BC, On fractures of the head Albucasis, c. 1000, On head wounds Chauliac, 1363; eds. Hippocrate, 1839; Leclerc, 1861; Nicaise, 1890). Trepanning is used to clean broken bone surrounding a fracture.

Other assumptions have been made about the reasons leading to trepanning for this period: the treatment of neurological disorders (Giraud, 2004), psychopathology (Guenée, 2016), or the recovery of bone powder (Giuffra and Fornaciari, 2015). In a medico-historical approach, the treatment of a trauma is the main motivation retained because it is the only one traceable to ancient surgical texts.

Although there is a rich ancient medical literature on the subject of trepanations, french archaeological cases from the medieval period remain sparse.

Archaeological discoveries regularly provide new cases of trepanation (e.g. Díaz-Navarro, 2021). For the medieval period (5th-15th centuries), at least 134 cases of trepanation have been published (Table 1). These are found throughout Europe, with a gap in the documentation for the Islamic world. Out of

the 51 cases recorded in the bibliography and dated between the 12th and 15th century, only five came from french sites.

1.2. Study background

The archaeological excavations carried out at the St. Cosme Priory in the center of France uncovered six cases of cranial bone defects resulting from anthropic interventions dated between the 12th and 15th centuries. Studies performed by digital imaging based on CTscan and μ CTscan acquisitions were carried out on these six cases in order to assess their osseous and endocranial morphology and volumes (Bédécarrats et al., 2021). The results of those studies, summarized below (see 2.4), lead to the hypothesis that, at St Cosme Priory, trepanation was mainly used on patients having neurological disorders. The present study further explores neuropathology through a study of cranial and endocranial morphological variabilities and the place of diet in therapy of trepanation.

1.3. Aims of the current study: increasing paleopathology semiology by geometric morphometrics and approach dietary aspects of medieval therapeutic

Taking into account previous studies of these cases (Bédécarrats et al., 2021), the hypothesis of the use of trepanation to treat neurological disorders at St. Cosme should be considered. As surgery was part of a broader therapeutic approach in the Middle Ages, we propose in this new study to further explore the neurological health of the individuals in order to investigate the motivations for the interventions and to consider the diet of these individuals as a possible indicator of a specific health regimen taking part to a therapeutic approach.

We sought to increase paleopathological semiology by exploring the variability of cranial and endocranial shapes and analysing the place of trepanned individuals in those variabilities by a geometric morphometrics (GM) approach. GM is defined as a set of methods for the acquisition, processing and analysis of shape variables (Slice, 2005). It provides the ability to study shapes as geometric properties of an object independently of their positions, scales and orientations. The birth of modern GM is attributed to Marcus who, in the article (Rohlf and Marcus, 1993), gives it its current definition. Applied to biology, GM accounts for the spatial heterogeneity associated with the anatomy and ontogeny of biological structures (Klingenberg, 2003). In this study, GM has been used to explore the variability in cranial and endocranial morphologies within populations of medieval Touraine. Those variabilities are mainly genetic and environmental dependents (Boas, 1912, 1907; Carson, 2006). They can also account for pathological phenomena as demonstrated by (Mitteroecker et al., 2004) in their analysis of a case of hydrocephalus from the Neolithic period. The reasoning then no longer focuses on variability but on the study of individuals outside of it (Claes et al., 2012). Since those works, other studies have focused on the identification by GM of bone and soft tissues morphologies associated with pathologies (e.g. Bruner and Jacobs, 2013; Milella et al., 2015; Plomp et al., 2015, 2012).

Moreover, if according to ancient and medieval medicine, body functions are governed by four humours, diet plays a prophylactic or even curative role by contributing to their good balance (Audouin-Rouzeau and Sabban, 2007; Laurieux, 2002). This is notably the case in the monastic context, where living conditions were dictated by rules in the form of prescriptions, commandments or prohibitions. While several Eastern rules influenced Western monasticism, a relative unity was achieved with the Benedictine rule written in the 6th century by Benedict of Nursia. This rule dominated Western monastic life throughout the medieval period following the monastic reform implemented from the beginning of the 9th century by Benedict of Aniane and Louis the Pious (Le Goff and Rémond, 1988; Racinet, 2006). Several chapters of the Rule of St. Benedict frame the dietary practices of monastic communities, which respond to biological as well as spiritual imperatives. While

the consumption of quadruped meat was usually forbidden, it was authorised for the sick in chapter 36 of the Benedictine Rule (Saint-Benoît, 2002).

The hypothesis of a possible adapted diet for trepanned individuals, within the framework of this rule, can be examined through isotope analysis. To test this hypothesis an analysis of the stable isotope ratios of carbon and nitrogen in bone collagen was conducted.

2. Material

2.1. Archaeological context

St. Cosme Priory (La Riche, Indre-et-Loire, France) is located 3 Km from the city of Tours in central France. It was founded in the 11th century, and remained in use until its canonical suppression in 1742. Archaeological excavations were carried out mainly between 2009 and 2010 (Dufaÿ et al., 2018). They unearthed 481 individuals in 450 burials located inside and outside the buildings (Fig. 1).

Osteological analysis used observations of bone maturation (Coqueugniot et al., 2010) and auricular surface senescence (Schmitt, 2005) to estimate age at death, and coxal morphology (Brůžek, 2002) and/or metric (Murail et al., 2005) to determine sex. Biological identifications revealed an over-representation of males (82.58 % of the adults whose sex is determined) and an under-representation of immature subjects (4.18 % of the individuals whose age at death is estimated), indicating that the majority of burials belonged to monks. Recruitment by funerary spaces, however, led to the assumption that the southern cemetery received more lay people than the other spaces (Dufaÿ and Gaultier, 2011): the female represent 36.84 % of the adults whose sex is determined and buried in the southern cemetery whereas they represent 5.84 % of the adults unearthed from the northern cemetery. Individuals with cranial lesions attributed to trepanation (Fig. 2) were not placed in a dedicated burial site.

2.2. Description of the cases

2.2.1. Individual 163_1

Individual 163_1 is a teenager who died between 10 and 14 years of age (Coqueugniot et al., 2010) and whose skull has a hole on the left frontal, 10.66 mm above the left orbit, mainly involving the ipsilateral half of the bone. The metopic suture is observable. This suture normally disappears at about one year of age (Vinchon, 2019). Its persistence after this age is an anatomical variation (Cunningham et al., 2016). This persistence allows to deduce the small involvement of the contralateral half of the frontal bone. The opening is oblong with a straight lower edge, a quasi-straight upper edge not parallel to the lower and two rounded lateral edges. Its maximum length is 51.39 mm and its maximum width is 21.39 mm. No evidence of bone reaction is observed, suggesting a peri or post-mortem phenomenon (Kranioti, 2015).

2.2.2. Individual 511_1

Individual 511_1 is identified as an adult male (Brůžek, 2002; Murail et al., 2005). His skull displays two holes: one on the frontal and one on the left parietal. The opening in the posterior lower quarter of the left parietal is oblong with a maximum length of 40.97 mm and a maximum width of 17.16 mm. Its edges are well defined with two parallel sub rectilinear long sides and two short sides rounded. The latter have circular removals with a resituated diameter of approximately 10–15 mm. The edges are sloping and a progressive thinning of the bone is visible on an area of approximately 19.42 cm². The frontal opening lies on the median axis of the bone, 13.67 mm above the nasion. It creates a communication between the frontal sinuses and the exocranium. It is round with a diameter of 13.48

mm. Its edges are vertical and parallel. The diploe is covered by reactive bone at both openings, which is evidence of the long survival of the individual, more than a year after the creation of the perforations (Barbian and Sledzik, 2008; Nerlich et al., 2003).

2.2.3. Individual 556_1

Individual 556_1 is identified as a male (Brůžek, 2002; Murail et al., 2005) adolescent (probability 10–14 years old = 0.34, probability 15–19 years old = 0.66, Coqueugniot et al., 2010). His skull shows two intersecting areas of defect: a fracture line visible in right lateral view and extending from half of the frontal to the right lateral third of the occipital; and a hole located in the right parietal above the pars petrosa. The latter extends slightly over the occipital. The opening is oblong, with a maximum length of 58.92 mm and a maximum width of 38.13 mm. It mainly occupies the inferior-posterior quarter of the left temporal, 6.01 mm from the parietomastoid suture. It continues for about 1 cm on the occipital. The edges are well defined with rounded corners. The edges are mostly sloping and occasionally vertical at the lower edge. Both the fracture and the opening show signs of advanced bone healing, making it difficult to discuss the relative chronology of the two phenomena and suggesting a long survival of more than a year (Barbian and Sledzik, 2008; Nerlich et al., 2003).

2.2.4. Individual 572_3

Individual 572_3 is identified as a man (Brůžek, 2002; Murail et al., 2005) who died between 30 and 59 years of age (Schmitt, 2005). He has a very large hole in the central part of his left parietal. This oblong lesion has a maximum length of 54.09 mm and a maximum width of 46.17 mm. The edges are sloping and sub-perpendicular in some places. Advanced bone healing is observed: the diploe is entirely covered with newly formed bone, indicating that the individual survived for a considerable time (more than a year) following the perforation (Barbian and Sledzik, 2008; Nerlich et al., 2003). His skull shows early craniosynostosis of all but the squamous sutures of his neurocranium. This craniosynostosis defines an oxycephaly, in this case one with pathological consequences (see 2.4) (Renier et al., 2006a).

2.2.5. Individual 902_1

Individual 902_1 is identified as a young male (Brůžek, 2002; Murail et al., 2005) adult between 20 and 39 years of age (Schmitt, 2005). He presents two distinct cranial lesions. The first, involving the two parietals, consists of two perpendicular “rod” removals forming a “T” shape. One of the rods has a right anterolateral / left posterolateral axis and a length of 120.65 mm. The second rod, with an antero-posterior axis, cuts the sagittal suture 51.36 mm from the bregma and 41.31 mm from the opisthocranium. It is 98.12 mm long. The widths of the two removals are almost constant, averaging 9 mm (variation between 8.12 and 10.11 mm, 15 measurements taken). Their edges are vertical and there is no sign of bone healing, suggesting a peri or post-mortem intervention (Kranioti, 2015). The second lesion is located on the right upper lateral quarter of the frontal bone and creates a hole of 19.82 by 14.58 mm. The upper edge is sloping and the lower one is irregular with a tendency to verticality, suggesting weapon related trauma (Symes et al., 2002; Verano, 2016). The absence of bone healing suggests a peri or post-mortem character for this second lesion (Kranioti, 2015).

2.2.6. Individual 942_1

The sex and age at death of Individual 942_1 could not be reliably estimated due to pathologic bone remodelling at the coxal bones. The skull has a hole in the left upper lateral quarter of the frontal bone, consisting of two arcs. This ellipsoidal opening measures 22.3 mm by 9.29 mm. The maximum length of the opening follows the upper-inferior axis of the bone. The sloping edges show a significant bone reaction resulting in a remodelled cortical bone covering the entire diploe and developing into a thin

blade at the inner table. Macroscopic examination thus suggests a long survival of more than a year of the individual after creation of the opening (Barbian and Sledzik, 2008; Nerlich et al., 2003).

2.3. Differential diagnosis

Numerous physiological, pathological, or taphonomic phenomena can cause a cranial lacuna (Kaufman et al., 1997; Pavlovic et al., 2019; Verano, 2016). For the St. Cosme cases, application of the criteria proposed by (Verano, 2016) leads to a preferential diagnosis of surgical intervention for the lacunae observed on 163_1, 511_1, 572_3 and 902_1 (Table 2). For individuals 556_1 and 942_1, cranial trauma is also included in the final differential diagnosis. This etiology does not exclude the possibility of a surgical cleaning that favors the survival of the individuals and could be consistent with the practice known from ancient medical treatises.

2.4. Synthesis of previous studies

The six cases have already been studied using CTscans and μ CTscans acquisitions (Bédécarrats et al., 2021). In this previous study, 3D models of the skulls and endocraniums of these individuals were assessed morphologically. The volume of the endocraniums was compared to the variability of medieval populations from Touraine.

Morphological analysis of the endocranium of 572_3 showed numerous reliefs in the frontal zone, indicating disorders of cerebrospinal fluid flow and implying intracranial hypertension (Desai et al., 2014), a phenomenon associated with a risk of papilledema (Craig et al., 2001; Friedman, 2007) and headaches (Round and Keane, 1988). His frontal area is also atrophied, a feature that may be associated with a frontal syndrome and thus behavioral disorders (Altschuler and Augenstein, 2012; Harlow, 1868; Mesulam, 2000). These two signs, intracranial hypertension and frontal atrophy, are consistent with his multiple synostosis (Renier et al., 2006b).

Volume analyses noted macroendocranial-like values for four of six individuals (163_1, 511_1, 556_1, 942_1): relative to their stature, their endocranial volumes are high in comparison with the populations of reference. This may suggest megalencephalies whose pathogenesis remains undetermined, but which may have been accompanied by neurological disorders (DeMyer, 1986; Pavone et al., 2017; Tan et al., 2018).

Thus, one case presents neurological disorders (572_3) and four cases may have had neurological disorders (163_1, 511_1, 556_1, 942_1). Among the latter four, 556_1 shows a fracture line which suggests a case of trauma treatment. Confirming the existence of neurological disorders is therefore of crucial interest in order to determine whether he has undergone surgery to relieve central nervous system disorders or to surgically manage his cranial trauma.

3. Methods

3.1. Geometric morphometrics approach to cranial and endocranial shape variability

The study of the cranial shapes involved 74 individuals excavated from medieval sites located in the center of France and dated from the same period as the trepanned cases (12th-15th centuries). Thirty three are from St. Cosme, 19 from Rigny (rural parish cemetery; Theureau, 2007), 19 from St. Pierre-le-Puellier (urban parish cemetery; Theureau, 1985) and 8 from Chinon (urban parish cemetery; Lorans, 2006). A case of trepanation found at the St Lazare leprosarium in Tours (Theureau, 1994) is also included in this study. For endocranial shapes, 73 individuals were studied: 32 are from St. Cosme, 19 from Rigny, 13 from St. Pierre-le-Puellier, 8 from Chinon and the case from St. Lazare.

The skulls were scanned on a Siemens Somatom Definition (Cire platform, Inra Centre Val de Loire/CHRU of Tours). A unique protocol conceived for bony tissue was applied for all the acquisitions (140 kVp, 400 mAs, section thickness 0.4 mm). Segmentations (image partitions, Cocquerez and Bolon, 1995) were then carried out on the CTscans acquisitions to select the skulls and the endocranial spaces. The TIVMI software (Dutailly et al., 2009) was used to produce 3D cranial models (meshes) and virtual endocasts from segmentations. This choice was based on the fact that this software integrates the “half maximum height” algorithm (Spoor et al., 1993) which recalculates the segmentation limits in order to produce meshes very close to the reality of the reconstructed objects (Guyomarc’h, 2011). The cranial meshes and virtual endocasts were used as a support for the GM. GM comprises three main processes: data collection, alignment and statistical analysis (Bookstein, 1992, 1992; Marcus, 1996; Marcus et al., 1993; Rohlf and Bookstein, 1990; Zelditch, 2008).

In this study, data are collected by placing digital landmarks on the three-dimensional models to record the shape of the specimens. These landmarks must be homologous from one subject to another: their definitions must be the same from one individual to another, thus ensuring that the shapes obtained are comparable (Bookstein, 1992). It is also possible to use semilandmarks (sliding landmarks distributed according to a given density) whose position is defined by two (in the case of a curve) or more fixed points (in the case of an area).

The use of biologically defined homologous landmarks is optimal in the recording of shapes for a study in GM (Bookstein, 1992). However, skull and endocranial analyses regularly use semilandmarks because there are not enough craniometric and endocranial points to account for the shapes (Gunz and Mitteroecker, 2013). In this study, the cases of interest have bony defects related to human interventions and taphonomy. Thus, the application of semilandmarks gives rise to the problem of missing data: the estimation of the position of numerous landmarks that could not be placed implies a significant risk of modification of the data in GM (Arbour and Brown, 2014; Couette and White, 2010). In order to limit the amount of missing data and the problem of their estimation, only fixed landmarks were used.

GM is systematically subject to intra-observer error (Barbeito-Andrés et al., 2012; Valeri et al., 1998). This error is due to the learning curve, fatigue and daily variations in the positioning of landmarks (Corner et al., 1992; Engelkes et al., 2019; Shearer et al., 2017). A measure of this error was made by calculating the coefficient of variation for the coordinates obtained after five successive poses. Only landmarks with coefficients of variation of less than 5% in their coordinates are included in the study. The landmarks subject to a variation linked to learning or to a fatigue effect were therefore excluded, leading to a final protocol comprising 15 cranial points and 14 endocranial points (Table 3 Fig. 3). A second reduction of intra-observer error was achieved by conducting the final placement of the landmarks in a single session. Daily variability is therefore excluded. The landmarks were placed using the software MorphoDig (Lebrun, 2018). The coordinates obtained were then completed by estimating the missing values with the “thin-plate spine” method (Gunz et al., 2009).

The data obtained remains dependent on the space in which it was collected: each individual presents variations in the coordinates of similar points linked to the position in space. The next step in GM analysis is therefore to reduce all the data to a single space that retains only the shape information by removing the orientation, scale and position of the individuals. The most widespread approach in GM is the Procrustes alignment (Gower, 1975; Kendall, 1989, 1984; Mosier, 1939). This alignment consists of three steps: elimination of position differences by translation, elimination of scale by reducing to “centroid size” and rotation to optimise the overprinting of shapes. After this alignment, a “consensus shape” is created and Procrustean residues (differences from the consensus) are calculated for each individual. The study of Procrustes distances is suitable for characterizing morphological heterogeneity

(Klingenberg, 2003) and, as stated earlier, can also highlight the effect of pathological phenomena on shapes (Bruner and Jacobs, 2013; Claes et al., 2012; Milella et al., 2015; Mitteroecker et al., 2004; Plomp et al., 2015, 2012). Procrustes analysis were used to define cranial and endocranial morphospaces and to assess the influence and significance of pathological phenomena on the cranial and endocranial morphologies of trepanned individuals. The covariance matrix of Procrustean residues is analysed by principal component analysis (PCA, Hotelling, 1933; Pearson, 1901). This multidimensional descriptive method assembles the covariance variables into principal components (PCs) ordered according to their influence in the population.

Retrodeformations (Schlager et al., 2018) of the “consensus” individuals according to the theoretical coordinates of the landmarks at the ends of the PCs were performed in R: the individuals at the centre of the variability were virtually deformed to correspond to the theoretical individuals found at the ends of the axes. These retrodeformations are proposed on the figures in order to visualize the changes in shape along the axes.

All statistical operations and production of figures were carried out using the R software (packages: geomorph, Adams and Otárola-Castillo, 2013; RGL, Adler et al., 2003; Morpho and RVCG, Schlager, 2017). The group variabilities are represented by 95 % confidence ellipses.

3.2. Isotopic approach to possible difference in the diet of trepanned individuals

The analysis of stable isotope ratios of carbon and nitrogen was conducted on 55 individuals from St. Cosme Priory, including the six with trepanning stigmata. Collagen extraction was carried out at the UMR 7269 LAMPEA in Aix-en-Provence following the Longin (1971) protocol modified by Bocherens et al. (1991). Elemental and isotopic measurements of collagen samples were performed on a Europa Scientific 20–20 isotope mass spectrometer coupled with an automated elemental analyser (EA-IRMS) at the Iso-Analytical laboratory (Crewe, Cheshire, UK). Isotopic measurements were calibrated with an internal beef liver standard (IA-R042) and standards provided by the international atomic energy agency (IAEA-CH-6: $\delta^{13}\text{C}_\text{C} = -10.43\text{‰}$; IAEA-N-1, $\delta^{15}\text{N} = 0.40\text{‰}$). The analytical accuracy, calculated on the repeated measurements of archaeological samples and internal laboratory standard, was less than 0.1‰ for the $\delta^{13}\text{C}$ and the $\delta^{15}\text{N}$ values.

Isotopic ratio reliability was checked using classical preservation indicators (Ambrose, 1990; DeNiro, 1985; van Klinken, 1999). Yield of extraction, carbon and nitrogen contents and C/N atomic ratios are within the limits proposed by authors ensuring the good conservation of all samples (Yield > 10 mg.g⁻¹, %C > 30, %N > 11 and 2.9 < C/N < 3.6).

4. Results

4.1. Cranial and endocranial shapes of the trepanned cases

The analysis of the results focused on the location of trepanned individuals within overall cranial and endocranial morphological variability. Therefore, analyses and interpretations were made using PCA on Procrustes residue matrices.

Regarding the cranial morphology, the linear regression crossing Procrustean coordinates and centroid sizes shows a lack of correlation between these two parameters (p-value = 0.128, 10 000 permutation tests). The shape variations observed are therefore not considered allometrics (size-dependent). The totality of the variance of the individuals considered is expressed in 38 PCs. The first two express respectively 18.11 % and 16.02 % of the variance. These were used to define the cranial morphospace (Fig. 4).

Individuals with traces of surgery are dispersed within cranial morphological variability. Subjects 511_1, 556_1 and 942_1 are within the common variability of all groups. Individuals 163_1, 942_1 and the case from St. Lazare are outside the variability of Rigny and subject 572_3 is outside the global variability.

For the endocranial models, an effect of allometry is highlighted by linear regression (adjusted $R^2 = 0.381$, p -value < 0.001 , prediction of 4.17 %). Allometry can be ontogenetic (changes according to developmental stage), evolutionary (evolution between different species) or static (related to biological variability) (Gould, 1966; Gunz, 2012; Klingenberg, 1998; Mitteroecker et al., 2013; Schaefer et al., 2004). As the study conducted involves mature individuals from the same area and time period, the observed allometry is assumed to be mainly static. When constructing a morphospace by PCA, the effect of allometry is found on the first PC and the space studied is a size-shape space (Mitteroecker et al., 2005, 2004). Since we are looking for the location of trepanning individuals in morphospace and not for differences according to static allometry factors (e.g. sex differences), we used the residuals of the linear regression to perform a "size correction" (Klingenberg, 2016, 2011) before constructing the PCA that is used to define the morphospace. The variance is expressed in 35 PCs. The first PC expresses 16.70 % of the variance and the second 13.16 %. These were used to construct the endocranial morphospace (Fig. 5).

The endocranial morphologies of trepanned individuals fall within the overall variability. Similar morphologies can be observed for subjects 511_1, 572_3 and 942_1. The individual 556_1, although being within the normal range of variability of the St. Cosme Priory population, falls outside this if the confidence interval is lowered from 95 % to 90 %.

4.2. Isotopic approach of diet

Trepanned individuals $\delta^{15}\text{N}$ values range between 10.6 and 13.0‰ (median [Q1/Q3] = 12.0 [11.7/12.5] ‰; $n = 6$) and $\delta^{13}\text{C}$ values from 19.8 to 19.3‰ (19.6 [19.8/ 19.4] ‰). Non-trepanned individuals $\delta^{15}\text{N}$ values range from 10.6 to 14.2‰ (12.3 [12.0/12.7] ‰; mean = 12.3 ± 0.8 ‰; $n = 49$) and $\delta^{13}\text{C}$ values from 20.4 to 18.5‰ (19.6 [19.7/19.5] ‰; 19.6 ± 0.3 ‰; $n = 49$). Comparison between trepanned and non-trepanned shows no statistical difference for both isotope ratios (Fig. 6; Mann-Whitney test: p -value($\delta^{15}\text{N}$) = 0.344, $W = 182.5$; p -value($\delta^{13}\text{C}$) = 0.816, $W = 138.0$; Levene test: p -value($\delta^{15}\text{N}$) = 0.892, $F = 0.019$; p -value($\delta^{13}\text{C}$) = 0.963, $F = 0.002$).

5. Discussion

5.1. Place of the trepanned individuals in the morphospaces

The distribution of the six individuals does not suggest a particular condition impacting the cranial and endocranial morphologies, which might have motivated a trepanation: the trepanned cases are not all outliers or gathered in a specific area of the morphospaces. However, there are indications of an association of pathological phenomena and features of morphospaces. Individual 572_3, who presents a synostosis and a trepanation, comes out of the general cranial variability and lies in the positive values of the first two axes of the PCA. The morphologies of the St. Lazare trepanation, the individual 163_1 and another individual from the St. Cosme priory that does not have a trepanation and shows no macroscopic signs of neuropathy are close and falls in the same quarter of the morphospace as the individual 572_3.

In relation to endocranial morphology, individuals 511_1, 572_3 and 942_1 are found in the quarter defined by the negative values of the first two main components. Due to the presence of 572_3, this could suggest the association of a pathological phenomenon and morphology. This individual presents

a cranial morphology impacted by a craniostenosis. Some of the subjects appearing close to 572_3 might have an endocranial morphology potentially indicating a pathological condition. However, the three trepanned individuals (511_1, 572_3, 942_1) are not outliers or clearly gathered in the variability, making the hypothesis of a pathological influence insufficient to explain the result.

The endocranial morphology of subject 556_1 is outside the variability of all comparison populations if a threshold of 90 % is accepted. In order to characterize his morphology, his endocranium was compared to the eight individuals who were the most complete and closest to the consensus form.

The most recurrent difference concerns Brodmann areas 44, 45 and 47 left (lower frontal gyrus, pars orbitalis, opercularis and triangularis, Brodmann, 1909). These areas seem different for the trepanned individual compared to seven of the eight comparison individuals (Fig. 7). The first two areas define Broca's area (Keller et al., 2009). Broca (1865, 1863, 1861a, 1861b) demonstrated an association between lesions of this area and aphasia, leading to the deduction that this cerebral zone played a role in the production of language. However, lesions in this area are not systematically accompanied by aphasia (Ardila et al., 2016). Broca's area seems to have a role in coordinating the transformation of information and not only in initiating language (Flinker et al., 2015).

Population variability exists in the volume of the lower frontal gyrus and its subdivisions. The volumetric study by Kennedy et al. (1998), based on 20 magnetic resonance imaging acquisitions, notes a variation of 1.9 cm³ for the pars triangularis, 2.2 cm³ for the pars opercularis and 2.5 cm³ for the pars orbitalis. Associations of the overgrowth of these pars with schizophrenia (Lieberman et al., 1992) and professional music practice (Sluming et al., 2002) have been proposed. It is thus difficult to link the morphological variation identified for individual 556_1 to human biological variability or to a specific pathology.

The results obtained for individual 556_1 in particular, although difficult to relate to a precise pathological phenomenon, question the main hypothesis on the use of trepanning during the Middle Ages. From antiquity onwards, surgical treatises mention trepanation in chapters related to cranial trauma, presenting it as a method for removing bone debris from a fracture site. Regarding the cases from St. Cosme, morphological and metric characterizations of skulls and endocrania have suggested the possibility of neuropathies for five of the six individuals presenting trepanations. GM revealed that the only case in the corpus with clear evidence of head trauma also presents an endocranial morphology potentially indicative of a pathology.

5.2. Diet of trepanned individuals

If a strong association existed at a regional scale between dietary behaviors and social groups (Miclon, 2020), isotopic data would show differences between the diets of trepanned individuals and those of the other individuals from this site. However, in our study, statistical differences were not found. These results, therefore, do not allow us to confirm an adaptation or change of diet of sick individuals within monastic institutions, at least not to an isotopically visible extent.

6. Conclusion

The examination of six cases of trepanation reveals a discrepancy between the written sources and observed practice. The diet of the patients and the monks is similar to the extent that it can be identified in isotopic analysis. This result therefore does not highlight specificities in the sick's diet. Furthermore, trepanations seem to be carried out on individuals with neurological disorders, whereas medical treatises recommend it to clean fractures. Therapeutic motivations assumed from the ancient medical treatises are therefore not reflected in our paleopathological analysis.

These same treatises are perhaps not intended to present therapeutic approaches (Savage-Smith, 2013), but rather to discuss in a scholastic approach the good practice of surgery. This assumption would explain the discrepancies observed regarding both dietary specificities and therapeutical motivations. It needs to be confirmed by generalizing isotope and imaging analyses of individuals presenting evidence for surgical procedures.

Even though the proposed use of GM to discuss paleoneuropathology is limited in its interpretation, our results, without leading to diagnoses, are very encouraging and allow us to hypothesise an association of pathologies and the observed variability. This observation leads us to propose further exploration of the concept of dysmorphometry in paleopathology, since pathologies associated with morphological deformations can be identified by GM (Bruner and Jacobs, 2013; Claes et al., 2012; Milella et al., 2015; Mitteroecker et al., 2004; Plomp et al., 2015, 2012). Working on modern clinical case studies is necessary to improve our knowledge of pathology impact on GM studies. This future research has to be done in order to establish semiological criteria in virtual anthropology and to assess their paleopathological significance.

Funding

The isotopic analyses were funded by the SADIL (Conseil Départemental d'Indre-et-Loire). The CTscan acquisitions were funded by the UMR 7324 CITERES-LAT. The first two authors were respectively granted a regional grant (Région Centre Val de Loire) and a ministerial grant (Ministère de l'Education Nationale, de l'Enseignement supérieur et de la Recherche).

Acknowledgements

The authors thank Philippe Rosset, Yves Tillet and François Lecompte from the Cire plate form for the CTscan acquisitions along with Steve Brookes and Ian Begley from IsoAnalytical Ltd. for the spectrometric analyses. We are grateful to the special editors and the anonymous reviewers for their insights, which have strengthened this contribution. We also thank Élisabeth Lorans and Alexis Bédécarrats for their proofreading.

Bibliography

Adams, D.C., Otárola-Castillo, E., 2013. geomorph: an R package for the collection and analysis of geometric morphometric shape data. *Methods in Ecology and Evolution* 4, 393–399. <https://doi.org/10.1111/2041-210X.12035>

Adler, D., Nenadic, O., Zucchini, W., 2003. Rgl: A r-library for 3d visualization with opengl, in: Bravermann, A., Hesterberg, T., Minnotte, M., Symanzik, J., Said, Y. (Eds.), *Proceedings of the 35th Symposium. Presented at the Interface: Computing Science and Statistics, Interface Foundation of North America, Salt Lake City, UT, United States of America*, pp. 1–11.

Altschuler, E.L., Augenstein, S., 2012. The earliest description of the frontal lobe syndrome in an Edgar Allan Poe tale. *Brain Injury* 26, 1403–1404. <https://doi.org/10.3109/02699052.2012.676224>

Amato, L., 2014. Letsels, verwondingen en medische behandelingen bij uiteenlopende sociale groepen in de middeleeuwse abdij Ten Duinen in Koksijde. *Novi Monasterii* 14, 43–76.

Ambrose, S.H., 1990. Preparation and characterization of bone and tooth collagen for isotopic analysis. *Journal of Archaeological Science* 17, 431–451. [https://doi.org/10.1016/0305-4403\(90\)90007-R](https://doi.org/10.1016/0305-4403(90)90007-R)

Arbour, J.H., Brown, C.M., 2014. Incomplete specimens in geometric morphometric analyses. *Methods in Ecology and Evolution* 5, 16–26. <https://doi.org/10.1111/2041-210X.12128>

- Ardila, A., Bernal, B., Rosselli, M., 2016. Why Broca's Area Damage Does Not Result in Classical Broca's Aphasia. *Frontiers in Human Neuroscience* 10, 249. <https://doi.org/10.3389/fnhum.2016.00249>
- Arnott, R., Finger, S., Smith, C.U.M. (Eds.), 2003. *Trepanation: discovery, history, theory*. Swets & Zeitlinger, Lisse, Netherlands.
- Audouin-Rouzeau, F., Sabban, F. (Eds.), 2007. *Un aliment sain dans un corps sain : Perspectives historiques*, *Un aliment sain dans un corps sain : Perspectives historiques*, *Tables des hommes*. Presses universitaires François-Rabelais, Tours, France.
- Barbeito-Andrés, J., Anzelmo, M., Ventrice, F., Sardi, M.L., 2012. Measurement error of 3D cranial landmarks of an ontogenetic sample using Computed Tomography. *Journal of Oral Biology and Craniofacial Research* 2, 77–82. <https://doi.org/10.1016/j.jobcr.2012.05.005>
- Barbian, L.T., Sledzik, P.S., 2008. Healing Following Cranial Trauma. *Journal of Forensic Sciences* 53, 263–268. <https://doi.org/10.1111/j.1556-4029.2007.00651.x>
- Barnes, E., Ortner, D.J., 1997. Multifocal eosinophilic granuloma with a possible trepanation in a fourteenth century Greek young skeleton. *International Journal of Osteoarchaeology* 7, 542–547. [https://doi.org/10.1002/\(SICI\)1099-1212\(199709/10\)7:5<542::AID-OA363>3.0.CO;2-5](https://doi.org/10.1002/(SICI)1099-1212(199709/10)7:5<542::AID-OA363>3.0.CO;2-5)
- Bédécarrats, S., Travers, N., Gaultier, M., Miclon, V., Coqueugniot, H., 2021. Expressions ostéoarchéologiques de la pratique chirurgicale en Touraine médiévale : le prieuré Saint-Cosme et la léproserie Saint-Lazare, in: Kacki, S., Réveillat, H., Knüsel, C. (Eds.), *Rencontre Autour Du Corps Malade : Prise En Charge et Traitement Funéraire Des Individus Souffrants à Travers Les Siècles*, *Actes Des Rencontres Du GAAP*.
- Blary, F., Bougault, D., 2004. Etude archéologique et paléopathologique de la maladrerie de Château-Thierry, in: Touati, F.-O. (Ed.), *Archéologie et architecture hospitalières de l'antiquité tardive à l'aube des temps modernes*. La Boutique de l'histoire, Paris, France, pp. 103–133.
- Boas, F., 1912. Changes in the Bodily Form of Descendants of Immigrants. *American Anthropologist, New Series* 14, 530–562. <https://doi.org/10.1525/aa.1912.14.3.02a00080>
- Boas, F., 1907. Heredity in Anthropometric Traits. *American Anthropologist* 9, 453–469. <https://doi.org/10.1525/aa.1907.9.3.02a00010>
- Bocherens, H., Fizet, M., Mariotti, A., Lange-Badre, B., Vandermeersch, B., Borel, J.P., Bellon, G., 1991. Isotopic biogeochemistry (^{13}C , ^{15}N) of fossil vertebrate collagen: application to the study of a past food web including Neandertal man. *Journal of Human Evolution* 20, 481–492. [https://doi.org/10.1016/0047-2484\(91\)90021-M](https://doi.org/10.1016/0047-2484(91)90021-M)
- Boljunčić, J., Hat, J., 2015. Mastoid Trepanation in a Deceased from Medieval Croatia: A Case Report. *Collegium Antropologicum* 39, 209–214.
- Bookstein, F.L., 1992. *Morphometric tools for landmark data: Geometry and biology*. Cambridge University Press, Cambridge, England, United Kingdom. <https://doi.org/10.1017/CBO9780511573064>
- Broca, P., 1867. Trépanation chez les Incas. *Bulletins et Mémoires de la Société d'Anthropologie de Paris* 2, 403–408. <https://doi.org/10.3406/bmsap.1867.4320>
- Broca, P., 1865. Sur le siège de la faculté du langage articulé (15 juin). *Bulletins et Mémoires de la Société d'Anthropologie de Paris* 6, 377–393. <https://doi.org/10.3406/bmsap.1865.9495>

- Broca, P., 1863. Localisation des fonctions cérébrales: Siègne de langage articulé. *Bulletins et Mémoires de la Société d'Anthropologie de Paris* 4, 200–208. <https://doi.org/10.3406/bmsap.1865.9495>
- Broca, P., 1861a. Nouvelle observation d'aphémie produite par une lésion de la moitié postérieure des deuxième et troisième circonvolutions frontales. *Bulletins de la Société Anatomique de Paris* 36, 398–407.
- Broca, P., 1861b. Remarques sur le siège de la faculté du langage articulé, suivies d'une observation d'aphémie (perte de la parole). *Bulletins de la Société Anatomique de Paris* 6, 330–357.
- Brodman, K., 1909. *Vergleichende Lokalisationslehre der Grosshirnrinde in ihren Prinzipien dargestellt auf Grund des Zellenbaues*. Barth, Leipzig, Germany.
- Bruner, E., Jacobs, H.I.L., 2013. Alzheimer's Disease: The Downside of a Highly Evolved Parietal Lobe? *Journal of Alzheimer's Disease* 35, 227–240. <https://doi.org/10.3233/JAD-122299>
- Brůžek, J., 2002. A method for visual determination of sex, using the human hip bone. *American Journal of Physical Anthropology* 117, 157–168. <https://doi.org/10.1002/ajpa.10012>
- Buchet, L., 1983. Médecine et chirurgie pendant les premiers siècles du Moyen-Age. Présentation de quelques vestiges anthropologiques. *Revue archéologique du Centre de la France* 22, 273–281. <https://doi.org/10.3406/racf.1983.2393>
- Buckley, L., Ó Donnabháin, B., 1992. Trephination: early cranial surgery in Ireland. *Archaeology Ireland* 10–12.
- Campillo, D., Safont, S., Malagosa, A., Puchalt, F.J., 1999. Four trepanned skull from 5th and 16th century in Spain. Surgery or ritual? *Cronos* 2, 261–283.
- Capasso, L., Tota, G.D., 1996. Possible Therapy for Headaches in Ancient Times. *International Journal of Osteoarchaeology* 6, 316–319. [https://doi.org/10.1002/\(SICI\)1099-1212\(199606\)6:3<316::AID-OA271>3.0.CO;2-G](https://doi.org/10.1002/(SICI)1099-1212(199606)6:3<316::AID-OA271>3.0.CO;2-G)
- Carson, E.A., 2006. Maximum likelihood estimation of human craniometric heritabilities. *American Journal of Physical Anthropology* 131, 169–180. <https://doi.org/10.1002/ajpa.20424>
- Cave, A.J.E., 1956. Report on the Remains from Snell's Corner, Harndean, Hampshire. *Field Club and Archaeology Society* 19, 148–170.
- Claes, P., Daniels, K., Walters, M., Clement, J., Vandermeulen, D., Suetens, P., 2012. Dymorphometrics: the modelling of morphological abnormalities. *Theoretical Biology and Medical Modelling* 9, 5. <https://doi.org/10.1186/1742-4682-9-5>
- Cocquerez, J.-P., Bolon, P. (Eds.), 1995. *Analyse d'images: filtrage et segmentation, Enseignement de la physique traitement du signal*. Masson, Paris, France.
- Coqueugniot, H., Weaver, T.D., Houët, F., 2010. Brief communication: a probabilistic approach to age estimation from infracranial sequences of maturation. *American Journal of Physical Anthropology* 142, 655–664. <https://doi.org/10.1002/ajpa.21312>
- Corner, B.D., Lele, S.R., Richtsmeier, J.T., 1992. Measuring Precision of Three-Dimensional Landmark Data. *Journal of Quantitative Anthropology* 3, 347–359.

Couette, S., White, J., 2010. 3D geometric morphometrics and missing-data. Can extant taxa give clues for the analysis of fossil primates? *Comptes Rendus Palevol, Imaging & 3D in palaeontology and palaeoanthropology* 9, 423–433. <https://doi.org/10.1016/j.crpv.2010.07.002>

Craig, J.J., Mulholland, D.A., Gibson, J.M., 2001. Idiopathic intracranial hypertension; incidence, presenting features and outcome in Northern Ireland (1991-1995). *The Ulster Medical Journal* 70, 31–35.

Crépeau, N., Chenal, F., Seguin, G., Beauval, C., 2018. Connaissances des pratiques médico-chirurgicales au XIV^e siècle à travers l'exemple d'une sépulture de l'ensemble funéraire de Sainsen-Gohelle (Pas-de-Calais), in: Kacki, S., Réveillat, H., Knüsel, C. (Eds.), *Pré Actes Rencontre Autour Du Corps Malade Prise En Charge et Traitement Funéraire Des Individus Souffrants à Travers Les Siècles*. Presented at the Rencontre du Groupe d'Anthropologie et d'Archéologie Funéraire, Bordeaux, France, p. 55.

Cunningham, C., Scheuer, L., Black, S.M., Liversidge, H., Christie, A., 2016. *Developmental juvenile osteology*, Second edition. ed. Academic Press, Amsterdam, Netherlands.

de Claifontaine, F.F., 1989. La nécropole de la Salle des Fêtes: Corseul (Côtes-du-Nord) au haut Moyen-Age. *Dossiers du Centre Régional d'Archéologie d'Alet* 65–72.

DeMyer, W., 1986. Megalencephaly: Types, clinical syndromes, and management. *Pediatric Neurology* 2, 321–328. [https://doi.org/10.1016/0887-8994\(86\)90072-X](https://doi.org/10.1016/0887-8994(86)90072-X)

DeNiro, M.J., 1985. Postmortem preservation and alteration of in vivo bone collagen isotope ratios in relation to palaeodietary reconstruction. *Nature* 317, 806–809. <https://doi.org/10.1038/317806a0>

Desai, V., Priyadarshini, S.R., Sharma, R., 2014. Copper Beaten Skull! Can It be a Usual Appearance? *International Journal of Clinical Pediatric Dentistry* 7, 45–47. <https://doi.org/10.5005/jp-journals-10005-1233>

Di Salvo, R., Germana, F., 2002. Dettagli antropologici e paleopatologici in un cranio femminile trapanato dalla necropoli araba di Segesta (Calatafimi-Trapani, Sicilia). *Archivio per l'antropologia e la etnologia* 132, 323–339.

Díaz-Navarro, S., 2021. A new case of prehistoric trepanation and scalping in the Iberian Peninsula: The tomb of La Saga (Cáseda, Navarre). *International Journal of Osteoarchaeology* 31, 88–98. <https://doi.org/10.1002/oa.2927>

Dufaÿ, B., Capron, F., Gaultier, M., 2018. *La Riche, Prieuré Saint-Cosme : Tome 1 volume 1 : Étude générale - Les résultats (Rapport de recherche)*. Conseil départemental d'Indre-et-Loire ; Service de l'archéologie du département d'Indre-et-Loire, Chambray-lès-Tours, France.

Dufaÿ, B., Gaultier, M., 2011. Premier bilan des fouilles archéologiques du prieuré de Saint-Cosme à La Riche près de Tours. *Bulletin de la Société archéologique de Touraine* 83–104.

Dutailly, B., Coqueugniot, H., Desbarats, P., Gueorguieva, S., Synave, R., 2009. 3D surface reconstruction using HMM algorithm, in: *Processing*. Presented at the 16th IEEE International Conference on Image Processing, IEEE, Cairo, Egypt, pp. 2505–2508. <https://doi.org/10.1109/ICIP.2009.5413911>

Engelkes, K., Helfsgott, J., Hammel, J.U., Büsse, S., Kleinteich, T., Beerlink, A., Gorb, S.N., Haas, A., 2019. Measurement error in μ CT -based three-dimensional geometric morphometrics introduced by surface

generation and landmark data acquisition. *Journal of Anatomy* joa.12999. <https://doi.org/10.1111/joa.12999>

Fabbri, P.F., Lonoce, N., Masieri, M., Caramella, D., Valentino, M., Vassallo, S., 2012. Partial cranial trephination by means of Hippocrates' trypanon from 5th century BC Himera (Sicily, Italy). *International Journal of Osteoarchaeology* 22, 194–200. <https://doi.org/10.1002/oa.1197>

Facchini, F., Rastelli, E., Ferrero, L., Fulcheri, E., 2003. Cranial trepanation in two skulls of early medieval Italy. *HOMO* 53, 247–254. <https://doi.org/10.1078/0018-442X-00047>

Ferembach, D., Dastugue, J., Poitrat Targowla, M.-J., 1962. La nécropole épipaléolithique de Taforalt, Maroc oriental: étude des squelettes humains. impr. Edita-Casablanca, Rabat, Morocco.

Fernandez, T., 1989. Etude paléo-pathologique de populations armoricaines du Haut Moyen-Age (Thèse de doctorat en Médecine). Université de Bretagne Occidentale, Brest, France.

Flinker, A., Korzeniewska, A., Shestyuk, A.Y., Franaszczuk, P.J., Dronkers, N.F., Knight, R.T., Crone, N.E., 2015. Redefining the role of Broca's area in speech. *Proceedings of the National Academy of Sciences of the United States of America* 112, 2871–2875. <https://doi.org/10.1073/pnas.1414491112>

Franckaert, B., 2014. Santé et pratiques médicales des Bretons insulaires et continentaux du Haut Moyen Âge (V-Xe siècles): revue de la littérature ouverte, analyse croisée des données historiques et archéologiques (Thèse de doctorat en Médecine). Université de Bretagne occidentale, Brest, France.

Friedman, D.I., 2007. Idiopathic intracranial hypertension. *Current Pain and Headache Reports* 11, 62–68. <https://doi.org/10.1007/s11916-007-0024-8>

Giot, P.-R., 1988. Le cimetière de l'île Lavret et sa chronologie. *Dossiers du Centre Régional d'Archéologie d'Alet* 16, 35–55.

Giot, P.-R., 1974. Etude anthropologique des sépultures médiévales d'Alet. *Dossiers du Centre Régional d'Archéologie d'Alet* 2, 6–13.

Giot, P.-R., 1949. Trépanations de la nécropole gauloise de Saint-Urmel en Plomeur. *Bulletins et Mémoires de la Société d'Anthropologie de Paris* 10, 59–69. <https://doi.org/10.3406/bmsap.1949.2849>

Giot, P.-R., Monnier, J.-L., 1977. Le cimetière des anciens Bretons de Saint-Urmel ou Saint-Saturnin en Plomeur (Finistère). *Gallia* 35, 141–171. <https://doi.org/10.3406/galia.1977.1559>

Giraud, C., 2004. La trépanation: étude de cette pratique chirurgicale au Moyen Age. *Paleobios* 13, 41–51.

Giuffra, V., Fornaciari, G., 2017. Trepanation in Italy: A Review. *International Journal of Osteoarchaeology* 27, 745–767. <https://doi.org/10.1002/oa.2591>

Giuffra, V., Fornaciari, G., 2015. Pulverized human skull in pharmacological preparations: Possible evidence from the "martyrs of Otranto" (southern Italy, 1480). *Journal of Ethnopharmacology* 160, 133–139. <https://doi.org/10.1016/j.jep.2014.11.042>

Gould, S.J., 1966. Allometry and size in ontogeny and phylogeny. *Biological Reviews* 41, 587–638. <https://doi.org/10.1111/j.1469-185X.1966.tb01624.x>

Gower, J.C., 1975. Generalized procrustes analysis. *Psychometrika* 40, 33–51. <https://doi.org/10.1007/BF02291478>

Guenée, B., 2016. *La folie de Charles VI : Roi Bien-Aimé*. CNRS, Paris, France.

Guillén, J.I.R., Lizalde, J.I.L., Fernández, L.F., 2016. 41. Una Necrópolis De Inhumación, Con Una Trepanación Frontal, De Cronología Tardoantigua, En El Paraje “Cabezón Grau” En La Localidad De Montoro De Mezquita (Villarluengo, Teruel), in: Lizalde, J., Vicente, J. (Eds.), *I Congreso de Arqueología y Patrimonio Aragónés-CAPA*. GRADISA MEDIA, S. L., Zaragoza, Spain, pp. 415–424.

Gunz, P., 2012. Evolutionary Relationships Among Robust and Gracile Australopiths: An “Evo-devo” Perspective. *Evolutionary Biology* 39, 472–487. <https://doi.org/10.1007/s11692-012-9185-4>

Gunz, P., Mitteroecker, P., 2013. Semilandmarks: a method for quantifying curves and surfaces. *Hystrix, the Italian Journal of Mammalogy* 24, 103–109. <https://doi.org/10.4404/hystrix-24.1-6292>

Gunz, P., Mitteroecker, P., Neubauer, S., Weber, G.W., Bookstein, F.L., 2009. Principles for the virtual reconstruction of hominin crania. *Journal of Human Evolution* 57, 48–62. <https://doi.org/10.1016/j.jhevol.2009.04.004>

Guyomarc’h, P., 2011. *Reconstitution faciale par imagerie 3d : variabilité morphométrique et mise en oeuvre informatique (Thèse de doctorat en Anthropologie Biologique)*. Université Bordeaux 1, Bordeaux, France.

Hanewald, G.T., Perziounus, W.R.K., 1980. Trepaning practice in the Netherlands, in: *Paleopathology Association (Ed.), Papers on Paleopathology*. Presented at the 3rd european meeting, Caen, France, pp. 167–170.

Harlow, J.M., 1868. Recovery from the passage of an iron bar through the head. *Massachusetts Medical Society Publication* 2, 327–346. <https://doi.org/10.1177/0957154X9300401407>

Hippocrate, 1839. *Oeuvres complètes d’Hippocrate: traduction nouvelle avec le texte grec en regard collationné sur les manuscrits et toutes les éditions: accompagnée d’une introduction, de commentaires médicaux, de variantes et de notes philologiques: suivie d’une table générale des matières*. J.-B. Baillière et Fils, Paris, France.

Holck, P., 2008. Two medieval ‘trepanations’ – therapy or swindle? *International Journal of Osteoarchaeology* 18, 188–194. <https://doi.org/10.1002/oa.933>

Hotelling, H., 1933. Analysis of a complex of statistical variables into principal components. *Journal of Educational Psychology* 24, 417–441. <https://doi.org/10.1037/h0071325>

Jones, G.D.B., Webster, P.V., 1968. Mediolanum: Excavations at Whitchurch 1965–6. *Archaeological Journal* 125, 193–254. <https://doi.org/10.1080/00665983.1968.11078340>

Kaufman, M.H., Whitaker, D., McTavish, J., 1997. Differential Diagnosis of Holes in the Calvarium: Application of Modern Clinical Data to Palaeopathology. *Journal of Archaeological Science* 24, 193–218. <https://doi.org/10.1006/jasc.1995.0104>

Keller, S.S., Crow, T., Foundas, A., Amunts, K., Roberts, N., 2009. Broca’s area: Nomenclature, anatomy, typology and asymmetry. *Brain and Language* 109, 29–48. <https://doi.org/10.1016/j.bandl.2008.11.005>

Kendall, D.G., 1989. A Survey of the Statistical Theory of Shape. *Statistical Science* 4, 87–99. <https://doi.org/10.1214/ss/1177012582>

Kendall, D.G., 1984. Shape Manifolds, Procrustean Metrics, and Complex Projective Spaces. *Bulletin of the London Mathematical Society* 16, 81–121. <https://doi.org/10.1112/blms/16.2.81>

- Kissné-Korompai, B., 1973. Nagytálya középkori (13–16. századi) templomának belsejében feltárt embertani anyag elemzése. *Egri Múzeum Évkönyve* 11–12.
- Klingenberg, C.P., 2016. Size, shape, and form: concepts of allometry in geometric morphometrics. *Development Genes and Evolution* 226, 113–137. <https://doi.org/10.1007/s00427-016-0539-2>
- Klingenberg, C.P., 2011. MorphoJ: an integrated software package for geometric morphometrics. *Molecular Ecology Resources* 11, 353–357. <https://doi.org/10.1111/j.1755-0998.2010.02924.x>
- Klingenberg, C.P., 2003. Quantitative Genetics Of Geometric Shape: Heritability And The Pitfalls Of The Univariate Approach. *Evolution* 57, 191–195. <https://doi.org/10.1111/j.0014-3820.2003.tb00230.x>
- Klingenberg, C.P., 1998. Heterochrony and allometry: the analysis of evolutionary change in ontogeny. *Biological Reviews* 73, 79–123. <https://doi.org/10.1111/j.1469-185X.1997.tb00026.x>
- Knocker, G.M., 1958. Early burials and an Anglo-Saxon cemetery at Snell's Corner, near Horndean, Hampshire. Warren, Winchester, England, United Kingdom.
- Kranioti, E., 2015. Forensic investigation of cranial injuries due to blunt force trauma: current best practice. *Research and Reports in Forensic Medical Science* 25. <https://doi.org/10.2147/RRFMS.S70423>
- László, O., 2016. Detailed Analysis of a Trepanation from the Late Avar Period (Turn of the 7th-8th Centuries-811) and Its Significance in the Anthropological Material of the Carpathian Basin: Late Avar Period (turn of the 7th-8th centuries-811) Ancient Surgical Trepanation. *International Journal of Osteoarchaeology* 26, 359–365. <https://doi.org/10.1002/oa.2414>
- Laurieux, B., 2002. *Manger au Moyen Age: pratiques et discours alimentaires en Europe aux XIVe et XVe siècles*. Hachette littératures, 2002, Paris, France.
- Le Goff, J., Rémond, R., 1988. *Histoire de la France religieuse*. Seuil, Paris, France.
- Lebrun, R., 2018. MorphoDig, an open-source 3D freeware dedicated to biology.
- Leclerc, L., 1861. *La Chirurgie d'Albucasis...* J.-B. Baillière, Paris, France.
- Likovský, J., Malyková, D., Brzobohatá, H., Stránská, P., 2010. Causation And Methods Of Skull Trepanation In The Past From The Point Of View Of The Latest Findings From The Czech Territory. *Anthropologie* 48, 19–32.
- Lillie, M.C., 1998. Cranial surgery dates back to Mesolithic. *Nature* 391, 854–854. <https://doi.org/10.1038/36023>
- Lisowski, F.P., 1967. Prehistoric and early historic trepanation, in: Brothwell, D.R., Sandison, A.T. (Eds.), *Diseases in Antiquity*. Charles C Thomas, Springfield, IL, United States of America, pp. 651–672.
- Litré, É., 1844. *Aphorismes d'Hippocrate*. J.-B. Baillière, Paris, France.
- Longin, R., 1971. New Method of Collagen Extraction for Radiocarbon Dating. *Nature* 230, 241–242. <https://doi.org/10.1038/230241a0>
- López, B., Caro, L., Pardiñas, A.F., 2011. Evidence of trepanations in a medieval population (13th–14th century) of northern Spain (Gormaz, Soria). *Anthropological Science* 119, 247–257. <https://doi.org/10.1537/ase.100913>
- Lorans, É. (Ed.), 2006. *Saint-Mexme de Chinon, Ve-XXe siècles*. Ed. du CTHS, Paris, France.

- Lorkiewicz, W., Mietlińska, J., Karkus, J., Żądzińska, E., Jakubowski, J.K., Antoszewski, B., 2018. Over 4,500 years of trepanation in Poland: From the unknown to therapeutic advisability. *International Journal of Osteoarchaeology* 28, 626–635. <https://doi.org/10.1002/oa.2675>
- Magner, L.N., 2005. *A History of Medicine, Second Edition*. Taylor & Francis, Boca Raton, FL, United States of America.
- Malim, T., Hines, J., Duhig, C., 1998. The Anglo-Saxon cemetery at Edix Hill (Barrington A), Cambridgeshire: excavations, 1989-1991 and a summary catalogue of material from 19th century interventions. Council for British Archaeology, York, England, United Kingdom.
- Marcus, L.F., 1996. *Advances in morphometrics*. Springer Science+Business, New York, NY, United States of America.
- Marcus, L.F., Bello, E., García-Valdecasas, A., 1993. Contributions to morphometrics, *Monografias del Museo Nacional de Ciencias Naturales*. Editorial CSIC-CSIC Press, Madrid, Spain.
- Martin, R., 1929. *Anthropometrie*. Springer Berlin Heidelberg, Berlin, Heidelberg, Germany. <https://doi.org/10.1007/978-3-662-31681-8>
- Mays, S., 2006. A possible case of surgical treatment of cranial blunt force injury from medieval England. *International Journal of Osteoarchaeology* 16, 95–103. <https://doi.org/10.1002/oa.806>
- Mesulam, M.-M. (Ed.), 2000. *Principles of behavioral and cognitive neurology*, 2nd ed. Oxford University Press, Oxford, England, United Kingdom.
- Milella, M., Zollikofer, C.P.E., León, M.S.P., 2015. Virtual Reconstruction and Geometric Morphometrics as Tools for Paleopathology: A New Approach to Study Rare Developmental Disorders of the Skeleton. *The Anatomical Record* 298, 335–345. <https://doi.org/10.1002/ar.23020>
- Mitteroecker, P., Gunz, P., Bookstein, F.L., 2005. Heterochrony and geometric morphometrics: a comparison of cranial growth in *Pan paniscus* versus *Pan troglodytes*. *Evolution & Development* 7, 244–258. <https://doi.org/10.1111/j.1525-142X.2005.05027.x>
- Mitteroecker, P., Gunz, P., Teschler-Nicola, M., Weber, G.W., 2004. New morphometric methods in Paleopathology: Shape analysis of a Neolithic Hydrocephalus, in: *Enter the Past: The e-Way into the Four Dimensions of Cultural Heritage*. Presented at the computer applications and quantitative methods in archaeology, Vienna, Austria, pp. 96–98.
- Mitteroecker, P., Gunz, P., Windhager, S., Schaefer, K., 2013. A brief review of shape, form, and allometry in geometric morphometrics, with applications to human facial morphology. *Hystrix, the Italian Journal of Mammalogy* 24. <https://doi.org/10.4404/hystrix-24.1-6369>
- Mosier, C.I., 1939. Determining a simple structure when loadings for certain tests are known. *Psychometrika* 4, 149–162. <https://doi.org/10.1007/BF02288493>
- Murail, P., Brůžek, J., Houët, F., Cunha, E., 2005. DSP: a tool for probabilistic sex diagnosis using worldwide variability in hip-bone measurements. *Bulletins et Mémoires de la Société d'Anthropologie de Paris* 17, 167–176. <https://doi.org/10.4000/bmsap.1157>
- Nerlich, A., Peschel, O., Zink, A., Rösing, F.W., 2003. The pathology of trepanation: Differential diagnosis, healing and dry bone appearance in modern cases. *Trepanation History, Discovery, Theory* 17, 43–51.

Nicaise, É., 1890. *La grande chirurgie de Guy de Chauliac,...* composée en l'an 1363. F. Alcan, Paris, France.

Novak, M., Nad, M., Plese, T., Cavka, M., 2013. Skeletal evidence of trepanning on a 5th century skull from Ludbreg, Croatia. *Acta medico-historica adriatica: AMHA* 11, 197–212.

Nuzzolese, E., Sublimi Saponetti, S., Scattarella, V., Capece, M., Di Nunno, N., 2010. Case Studies of Cranial Trepanation in Apulia (Southern Italy) Through Forensic Imaging, in: AAFS (Ed.), *Putting out Forensic House in Order: Examining, Validation and Expelling Incompetence*. Presented at the American Academy of Forensic Sciences, American Academy of Forensic Sciences, Seattle, WA, United States of America, pp. 278–279.

Parker, S., Roberts, C.A., 1986. A review of British trepanations with reports on two new cases. *Ossa* 12, 141–157.

Parry, T.W., 1940. 46. A Comparison Between Two Roundels Removed by Surgical Holing from Two Prehistoric Skulls, Lately Excavated in the County of Dorset; Together with a Full Description of the Push-Plough Method of Operation That Was Probably Employed. *Man* 40, 33–35. <https://doi.org/10.2307/2792279>

Parry, T.W., 1936. A Case of Primitive Surgical Holing of the Cranium Practised in Great Britain in Mediæval Times, with a Note on the Introduction of Trepanning Instruments. *Proceedings of the Royal Society of Medicine* 29, 898–902. <https://doi.org/10.1177/003591573602900804>

Parry, T.W., 1921. *The Prehistoric Trephined Skulls of Great Britain: Together with a Detailed Description of the Operation Probably Performed in Each Case*. John Bale, Sons & Danielsson, London, England, United Kingdom.

Pasini, A., Manzon, V.S., Gonzalez-Muro, X., Gualdi-Russo, E., 2018. Neurosurgery on a Pregnant Woman with Post Mortem Fetal Extrusion: An Unusual Case from Medieval Italy. *World Neurosurgery* 113, 78–81. <https://doi.org/10.1016/j.wneu.2018.02.044>

Pavlovic, T., Djonic, D., Byard, R.W., 2019. Trepanation in archaic human remains – characteristic features and diagnostic difficulties. *Forensic Science, Medicine and Pathology* 6. <https://doi.org/10.1007/s12024-019-00158-7>

Pavone, P., Praticò, A.D., Rizzo, R., Corsello, G., Ruggieri, M., Parano, E., Falsaperla, R., 2017. A clinical review on megalencephaly. *Medicine* 96. <https://doi.org/10.1097/MD.00000000000006814>

Pearson, K., 1901. LIII. On lines and planes of closest fit to systems of points in space. *The London, Edinburgh, and Dublin Philosophical Magazine and Journal of Science* 2, 559–572. <https://doi.org/10.1080/14786440109462720>

Pereira-Pedro, A.S., Bruner, E., 2018. Landmarking Endocasts, in: Bruner, E., Ogiwara, N., Tanabe, H.C. (Eds.), *Digital Endocasts*. Springer Japan, Tokyo, Japan, pp. 127–142. https://doi.org/10.1007/978-4-431-56582-6_9

Perrot, R., 1982. *Les blessures et leur traitement au Moyen-Age d'après les textes médicaux anciens et les vestiges osseux (grande région Lyonnaise)* (Thèse de doctorat en Biologie Humaine). Université Claude Bernard, Lyon, France.

Piggott, S., 1940. A Trepanned Skull of the Beaker Period from Dorset and the Practice of Trepanning in Prehistoric Europe. *Proceedings of the Prehistoric Society* 6, 112–132. <https://doi.org/10.1017/S0079497X00020430>

Pilet, C., Bagousse, A.-L., Blondiaux, J., Buchet, L., Grévin, G., Pilet-Lemière, J., 1990. Les nécropoles de Giberville (Calvados) fin du Ve siècle-fin du VIIe siècle ap. JC. *Archéologie médiévale* 20, 3–140.

Plomp, K., Roberts, C., Vidarsdottir, U.S., 2015. Does the correlation between schmorl's nodes and vertebral morphology extend into the lumbar spine? *American Journal of Physical Anthropology* 157, 526–534. <https://doi.org/10.1002/ajpa.22730>

Plomp, K., Roberts, C.A., Viðarsdóttir, U.S., 2012. Vertebral morphology influences the development of Schmorl's nodes in the lower thoracic vertebrae. *American Journal of Physical Anthropology* 149, 572–582. <https://doi.org/10.1002/ajpa.22168>

Quevauvilliers, J., Somogyi, A., Fingerhut, A., 2011. *Dictionnaire médical*. Elsevier Masson, Issy-les-Moulineaux, France.

Racinet, S., 2006. Les prescriptions concernant l'alimentation et la boisson dans les règles monastiques médiévales (jusqu'à la règle de saint Benoît), in: Clavel, B. (Ed.), *Production Alimentaire et Lieux de Consommation Dans Les Établissements Religieux Au Moyen Âge et à l'époque Moderne: Presented at the Actes du colloque de Lille, 16, 17, 18 et 19 octobre 2003, Histoire médiévale et Archéologie.*, CAHMER, CREDHIR, CRAVO, Amiens, France, pp. 3–7.

Renier, D., Arnaud, E., Marchac, D., 2006a. Classification des craniosténoses. *Neurochirurgie* 52, 200–227. [https://doi.org/10.1016/S0028-3770\(06\)71216-4](https://doi.org/10.1016/S0028-3770(06)71216-4)

Renier, D., Arnaud, E., Marchac, D., 2006b. Le retentissement fonctionnel des craniosténoses. *Neurochirurgie* 52, 259–263. [https://doi.org/10.1016/S0028-3770\(06\)71220-6](https://doi.org/10.1016/S0028-3770(06)71220-6)

Reverté, J.M., 1980. Paléopathologie dans quelques fouilles en Vieille Castille, in: *Papers on Paleopathology. Presented at the Paleopathology Association, Caen, France*, pp. 141–149.

Roberts, C.A., McKinley, J., 2003. Review of trepanations in British antiquity focusing on funerary context to explain their occurrence, in: Arnott, R., Finger, S., Smith, C.U.M. (Eds.), *Trepanation: History, Discovery, Theory*. Swets & Zeitlinger, Lisse, Netherlands, pp. 55–78.

Rohlf, F.J., Bookstein, F.L. (Eds.), 1990. *Proceedings of the Michigan Morphometrics Workshop, Special publication*. University of Michigan Museum of Zoology, Ann Arbor, MI, United States of America.

Rohlf, F.J., Marcus, L.F., 1993. A revolution morphometrics. *Trends in Ecology & Evolution* 8, 129–132. [https://doi.org/10.1016/0169-5347\(93\)90024-J](https://doi.org/10.1016/0169-5347(93)90024-J)

Round, R., Keane, J.R., 1988. The minor symptoms of increased intracranial pressure: 101 patients with benign intracranial hypertension. *Neurology* 38, 1461–1461. <https://doi.org/10.1212/WNL.38.9.1461>

Saint-Benoît, 2002. *La Règle de Saint Benoît / traduction nouvelle par un moine de Solesmes.*, 2 édition revue. ed. S.A.S La Froidfontaine – éditions de Solesmes, Solesmes, France.

Savage-Smith, E., 2013. Medicine in Medieval Islam, in: Lindberg, D.C., Shank, M.H. (Eds.), *The Cambridge History of Science: Volume 2: Medieval Science, The Cambridge History of Science*. Cambridge University Press, Cambridge, England, United Kingdom, pp. 139–167. <https://doi.org/10.1017/CHO9780511974007.007>

Schaefer, K., Mitteroecker, P., Gunz, P., Bernhard, M., Bookstein, F.L., 2004. Craniofacial sexual dimorphism patterns and allometry among extant hominids. *Annals of Anatomy - Anatomischer Anzeiger* 186, 471–478. [https://doi.org/10.1016/S0940-9602\(04\)80086-4](https://doi.org/10.1016/S0940-9602(04)80086-4)

- Schlager, S., 2017. Chapter 9 - Morpho and Rvcg – Shape Analysis in R: R-Packages for Geometric Morphometrics, Shape Analysis and Surface Manipulations, in: Zheng, G., Li, S., Székely, G. (Eds.), *Statistical Shape and Deformation Analysis*. Academic Press, London, pp. 217–256. <https://doi.org/10.1016/B978-0-12-810493-4.00011-0>
- Schlager, S., Profico, A., Vincenzo, F.D., Manzi, G., 2018. Retrodeformation of fossil specimens based on 3D bilateral semi-landmarks: Implementation in the R package “Morpho.” *PLOS ONE* 13, e0194073. <https://doi.org/10.1371/journal.pone.0194073>
- Schmitt, A., 2005. Une nouvelle méthode pour estimer l’âge au décès des adultes à partir de la surface sacro-pelvienne iliaque. *Bulletins et Mémoires de la Société d’Anthropologie de Paris* 17, 89–101. <https://doi.org/10.4000/bmsap.943>
- Shearer, B.M., Cooke, S.B., Halenar, L.B., Reber, S.L., Plummer, J.E., Delson, E., Tallman, M., 2017. Evaluating causes of error in landmark-based data collection using scanners. *PLOS ONE* 12, e0187452. <https://doi.org/10.1371/journal.pone.0187452>
- Siraisi, N.G., 1990. *Medieval & early Renaissance medicine: an introduction to knowledge and practice*. The Univ. of Chicago Press, Chicago, IL, United States of America.
- Slice, D.E. (Ed.), 2005. *Modern morphometrics in physical anthropology, Developments in primatology*. Kluwer Academic/Plenum Publishers, New York, NY, United States of America.
- Smrčka, V., Kuželka, V., Melková, J., 2003. Meningioma probable reason for trephination. *International Journal of Osteoarchaeology* 13, 325–330. <https://doi.org/10.1002/oa.706>
- Spoor, C.F., Zonneveld, F.W., Macho, G.A., 1993. Linear measurements of cortical bone and dental enamel by computed tomography: Applications and problems. *American Journal of Physical Anthropology* 91, 469–484. <https://doi.org/10.1002/ajpa.1330910405>
- Symes, S., Williams, J., Murray, E., Hoffman, M., Holland, T., Saul, J., Pope, E., 2002. Taphonomic Context of Sharp-Force Trauma in Suspected Cases of Human Mutilation and Dismemberment, in: Haglund, W.D., Sorg, M.H. (Eds.), *Advances in Forensic Taphonomy: Method, Theory, and Archaeological Perspectives*. CRC Press, Boca Raton, Fla., United States of America, pp. 418–450.
- Tan, A.P., Mankad, K., Gonçalves, F.G., Talenti, G., Alexia, E., 2018. Macrocephaly: Solving the Diagnostic Dilemma. *Topics in Magnetic Resonance Imaging* 27, 197–217. <https://doi.org/10.1097/RMR.0000000000000170>
- Theureau, C., 2007. Étude anthropologique d’un cimetière de paroisse rurale : les sépultures (8e-19e s.) de Rigny (Rigny-Ussé, Indre-et-Loire). *Revue archéologique du Centre de la France* 43 p.
- Theureau, C., 1994. Etude anthropologique, ossements humains et lèpre. Fouille de sauvetage de la chapelle Saint-Lazare (Tours, Indre-et-Loire). *Mediarch*, Tours, France.
- Theureau, C., 1985. Anthropologie des squelettes du cimetière paroissial de Saint-Pierre-le-Puellier (XIe-XVIIe siècle). *Recherches sur Tours, Supplément à la Revue Archéologique du Centre de la France* 3, 62. https://doi.org/sracf_0769-8755_1985_mon_0_3
- Valeri, C.J., Cole, T.M., Lele, S., Richtsmeier, J.T., 1998. Capturing data from three-dimensional surfaces using fuzzy landmarks. *American Journal of Physical Anthropology* 107, 113–124. [https://doi.org/10.1002/\(SICI\)1096-8644\(199809\)107:1<113::AID-AJPA9>3.0.CO;2-O](https://doi.org/10.1002/(SICI)1096-8644(199809)107:1<113::AID-AJPA9>3.0.CO;2-O)

- van Klinken, G.J., 1999. Bone Collagen Quality Indicators for Palaeodietary and Radiocarbon Measurements. *Journal of Archaeological Science* 26, 687–695. <https://doi.org/10.1006/jasc.1998.0385>
- Verano, J.W., 2016. Differential diagnosis: Trepanation. *International Journal of Paleopathology* 14, 1–9. <https://doi.org/10.1016/j.ijpp.2016.04.001>
- Verano, J.W., Finger, S., 2009. Chapter 1 Ancient trepanation, in: Aminoff, M.J., Boller, F., Swaab, D.F. (Eds.), *History of Neurology, Handbook of Clinical Neurology*. Elsevier, Amsterdam, Netherlands, pp. 3–14. [https://doi.org/10.1016/S0072-9752\(08\)02101-5](https://doi.org/10.1016/S0072-9752(08)02101-5)
- Vinchon, M., 2019. The metopic suture: Natural history. *Neurochirurgie* 65, 239–245. <https://doi.org/10.1016/j.neuchi.2019.09.006>
- Wacher, J.S., McWhirr, A., 1982. Early Roman occupation at Cirencester. Cirencester Excavation Committee, Corinium Museum, Cirencester, England, United Kingdom.
- Warhurst, A., 1955. The Jutish Cemetery at Lyminge. *Archaeologia Cantiana* 69, 1–40.
- Wells, C., 1974. Probable trephination of five Early Saxon skulls. *Antiquity* 48, 298–302. <https://doi.org/10.1017/S0003598X00058282>
- Wheeler, R.E., 1943. Maiden Castle, Dorset. Reports of the Research Committee of the Society of Antiquaries of London, No. XII). Oxford XII, 344–346.
- Zanello, M., Decofour, M., Corns, R., Pallud, J., Charlier, P., 2015. Report of a successful human trepanation from the Dark Ages of neurosurgery in Europe. *Acta Neurochir* 157, 303–304. <https://doi.org/10.1007/s00701-014-2239-x>
- Zelditch, M.L. (Ed.), 2008. *Geometric morphometrics for biologists: a primer*. Elsevier Academic Press, Amsterdam, Netherlands.

Country	N cases	References
Belgium	7	(Amato, 2014)
Croatia	4	(Boljunčić and Hat, 2015; Novak et al., 2013)
Czech Republic	7	(Likovský et al., 2010; Smrčka et al., 2003)
England	31	(Cave, 1956; Giraud, 2004; Jones and Webster, 1968; Klocker, 1958; Malim et al., 1998; Mays, 2006; Parker and Roberts, 1986; Parry, 1940, 1936, 1921; Piggott, 1940; Roberts and McKinley, 2003; Wachter and McWhirr, 1982; Warhurst, 1955; Wells, 1974; Wheeler, 1943)
France	25	(Blary and Bougault, 2004; Buchet, 1983; Crépeau et al., 2018; de Claifontaine, 1989; Fernandez, 1989; Franckaert, 2014; Giot, 1988, 1974, 1949; Giot and Monnier, 1977; Giraud, 2004; Zanello et al., 2015)
Greece	1	(Barnes and Ortner, 1997)
Hungary	3	(Giraud, 2004; Kissné-Korompai, 1973; László, 2016; Perrot, 1982)
Ireland	6	(Buckley and Ó Donnabháin, 1992; Giraud, 2004; Lisowski, 1967; Pilet et al., 1990; Roberts and McKinley, 2003)
Italy	13	(Capasso and Tota, 1996; Di Salvo and Germana, 2002; Fabbri et al., 2012; Facchini et al., 2003; Giuffra and Fornaciari, 2017; Nuzzolese et al., 2010; Pasini et al., 2018)
Netherlands	9	(Giraud, 2004; Hanewald and Periziounus, 1980)
Norway	2	(Holck, 2008)
Poland	3	(Lorkiewicz et al., 2018)
Scotland	1	(Roberts and McKinley, 2003)
Serbia	3	(Pavlovic et al., 2019)
Spain	19	(Campillo et al., 1999; Giraud, 2004; Guillén et al., 2016; López et al., 2011; Reverté, 1980)

Table 1. Published cases of trepanation found in Europe and dated between the 5th and the 15th centuries.

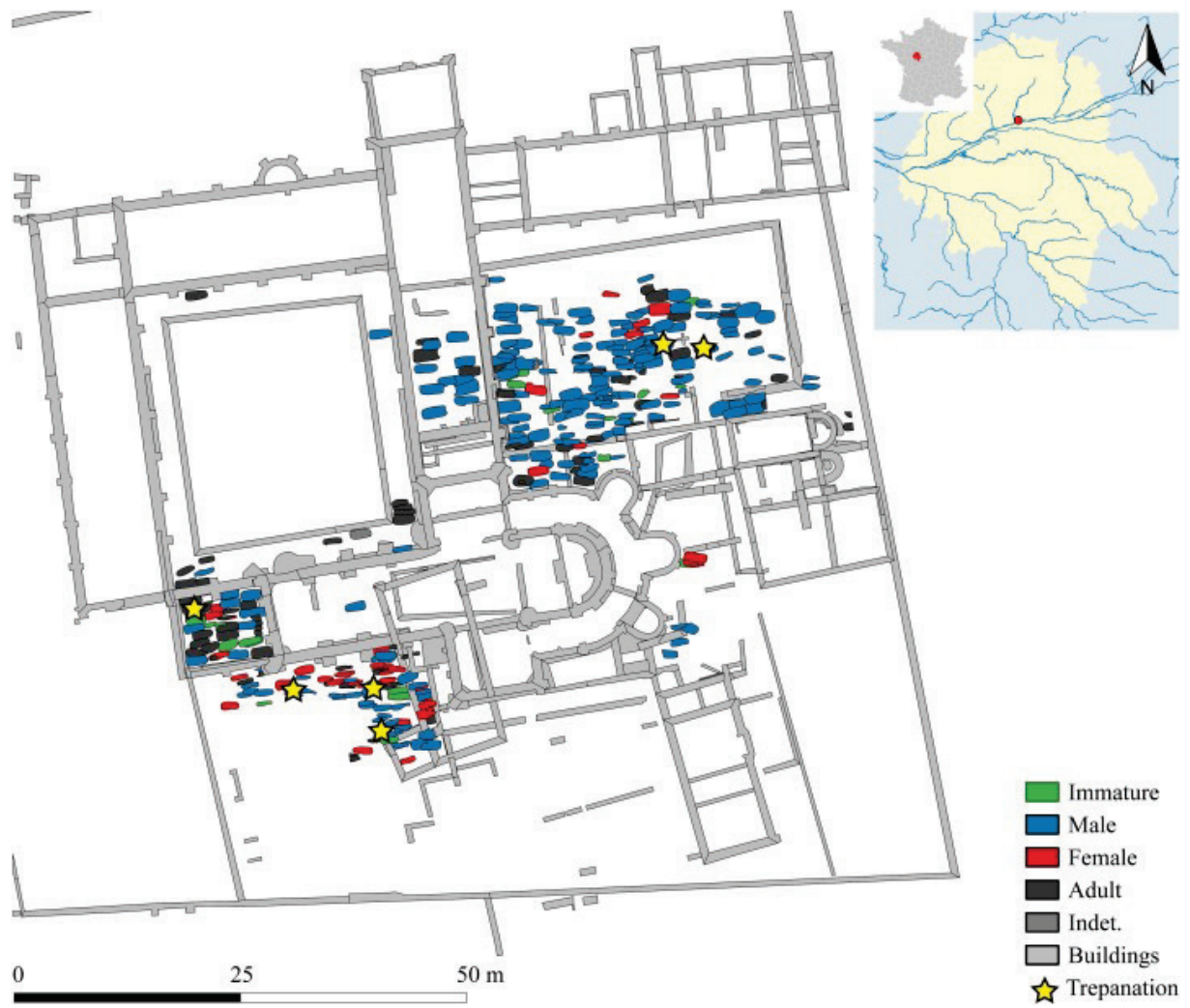


Fig. 1. Inhumations at the St. Cosme Priory and localisation of trepanned cases.

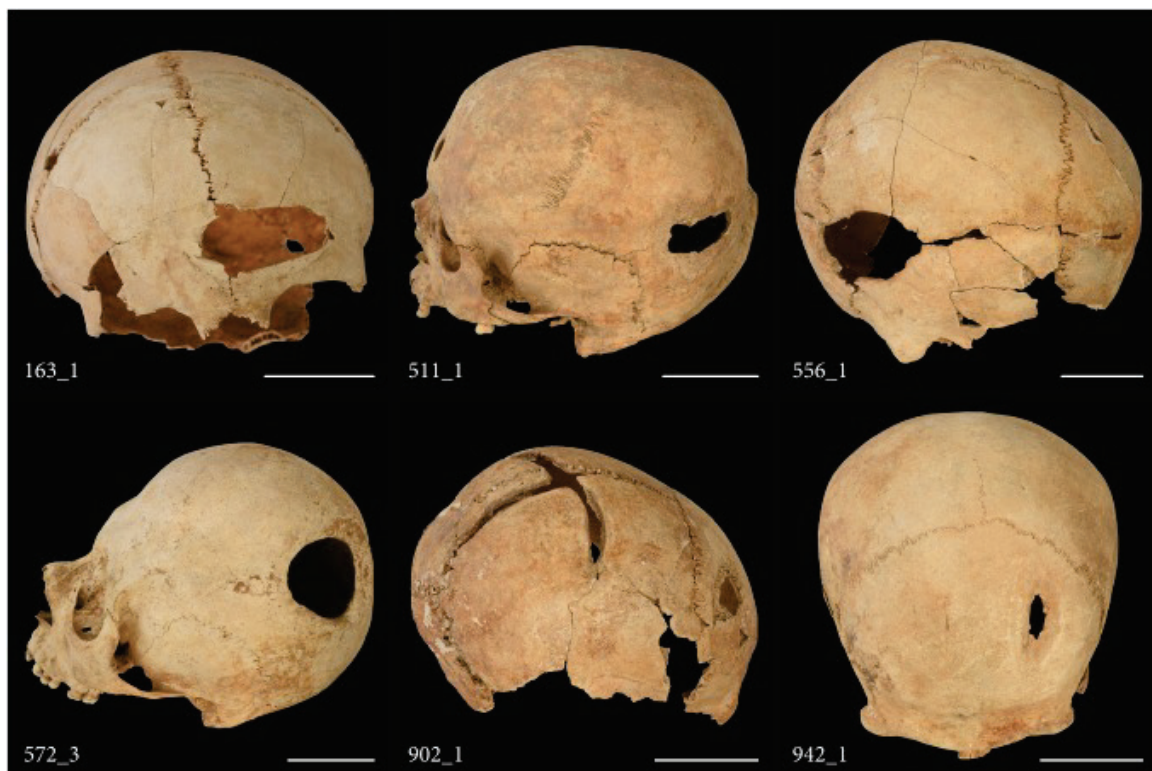

Fig. 2. The six cases of cranial interventions excavated at the St. Cosme Priory. Scale: 5 cm.

Etiology	Pathology	Main characteristic	PSC_163_1	PSC_511_1	PSC_556_1	PSC_572_3	PSC_902_1	PSC_942_1
Defects reflecting normal cranial anatomy	Dysostosis	Juvenile only	-1	-1	-1	-1	-1	-1
		Non-union at the sutures	-1	-1	-1	-1	-1	-1
Failure of normal ossification	Meningocele	Located on the sagittal suture or coronal/sagittal junction	-1	-1	-1	-1	-1	-1
		Cyst dermoid /epidermal	-1	-1	-1	-1	-1	-1
Biparietal thinning	Parietal fenestrae	Bilateral and oval	-1	-1	-1	-1	-1	-1
		Gradual thinning of parietal bones, loss of diploe bone, biparietal	-1	-1	-1	-1	-1	-1
Infection	Osteomyelitis	Active: margins porous and ragged. Healed: remodelling. Can co-occur with other phenomenon	-1	0	0	0	-1	0
		Inflammation of the outer table	-1	-1	-1	-1	-1	-1
Neoplasm	Depressed	Primarily lytic	-1	-1	-1	-1	-1	-1
		Non-healed or non-extensive healing: markings where bone fragments were lost. Healed: difficult to tell if intervention was done to treat the fracture	-1	0	1	0	-1	-1
Trauma	Penetrating	Non-healed: shape and size can be matched to particular weapons. Healed: more difficult to distinguish from a small trepanation, rare.	-1	-1	-1	-1	-1	-1
		Edged weapons	-1	-1	-1	-1	Frontal lesion 1	1
Supraionion lesions	Edged weapons	On theinion	-1	-1	-1	-1	-1	-1
		No bone reaction, different coloration of broken edges. Gnawing: specific marks	-1	-1	-1	-1	-1	-1
Surgical intervention	Final diagnosis	Non-healed: marks. Healed: diameter at the upper table superior or equal diameter at the lower table, difficult to tell if intervention was done to treat a fracture	1	1	1	1	Biparietal lesion 1	1
		Highly consistent	Healed osteomyelitis, healed depressed fracture	Healed osteomyelitis, healed depressed fracture	Healed osteomyelitis, healed depressed fracture	Healed osteomyelitis, healed depressed fracture	Healed osteomyelitis, healed depressed fracture	Healed osteomyelitis, healed depressed fracture

Table 2. Differential diagnosis of the cranial defects according to the criteria by (Verano, 2016). -1 not consistent with; 0 consistent with; 1 highly consistent with; (a) the two diagnosis are not mutually exclusive.

Cranial landmarks

N°	Name	Description
1	Nasion	midline point where the two nasal bones and the frontal intersect
2	Glabella	most anterior midline point on the frontal bone, usually above the frontonasal suture
3	Ectocranial bregma	point where the coronal and sagittal sutures intersect
4	Frontomalare (right)	most anterior point of the frontozygomatic suture
5	Frontomalare (left)	most anterior point of the frontozygomatic suture
6	Stephanion (right)	point where the coronal suture crosses the temporal line region where the frontal, temporal, parietal, and sphenoid meet on the side of the vault
7	Pterion (right)	
8	Porion (right)	uppermost point on the margin of the external acoustic meatus
9	Asterion (right)	point where the lambdoid, parietomastoid, and occipitomastoid sutures meet
10	Stephanion (left)	point where the coronal suture crosses the temporal line region where the frontal, temporal, parietal, and sphenoid meet on the side of the vault
11	pterion (left)	
12	Porion (left)	uppermost point on the margin of the external acoustic meatus
13	Asterion (left)	point where the lambdoid, parietomastoid, and occipitomastoid sutures meet
14	Lambda	ectocranial midline point where the sagittal and lambdoid sutures intersect
15	Opisthion	midline point at the posterior margin of the foramen magnum

Endocranial landmarks

N°	Name	Description
1	Internal glabella	most anterior midline point on the frontal area
2	Central sulcus	intersection of the central sulcus with inter-hemispheric fissure
3	Frontal pole (right)	anteriormost point following maximum length
4	Frontal pole (left)	anteriormost point following maximum length
5	Broca's cap (right)	maximum prefrontal width, namely, the posterior bulging area of the third frontal gyrus, corresponding to the Broca's cap in humans
6	Temporal pole (right)	tip point of the temporal pole
7	Cerebellar pole (right)	lowermost point of the cerebellum
8	Lateral sulcus (right)	posterior limit of the lateral sulcus maximum prefrontal width, namely, the posterior bulging area of the third frontal gyrus, corresponding to the Broca's cap in humans
9	Broca's cap (left)	
10	Temporal pole (left)	tip point of the temporal pole
11	Cerebellar pole (left)	lowermost point of the cerebellum
12	Lateral sulcus (left)	posterior limit of the lateral sulcus
13	Perpendicular sulcus Internal occipital	Parioeto-occipital boundary, central point
14	protuberance	inter-hemispheric and cerebro-cerebellar separation, central point

Table 3. Landmarks selected for the study. Descriptions are adapted from (Martin, 1929) for the cranial landmarks and from (Pereira-Pedro and Bruner, 2018) for the endocranial landmarks.

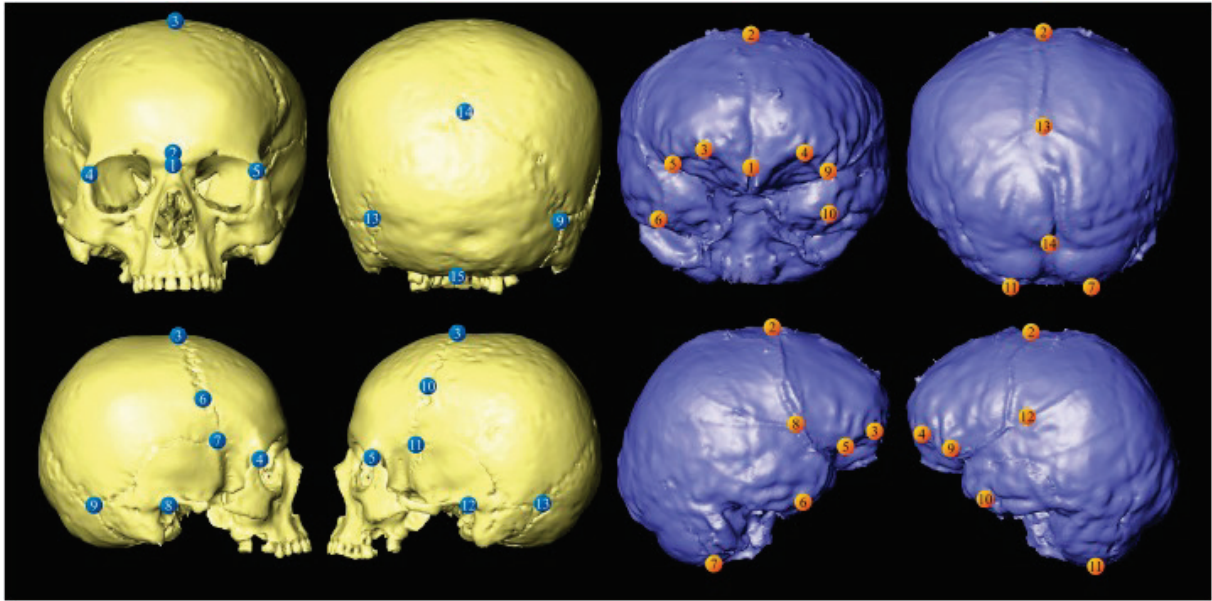


Fig. 3. Localisation of the landmarks on cranial models and virtual endocasts.

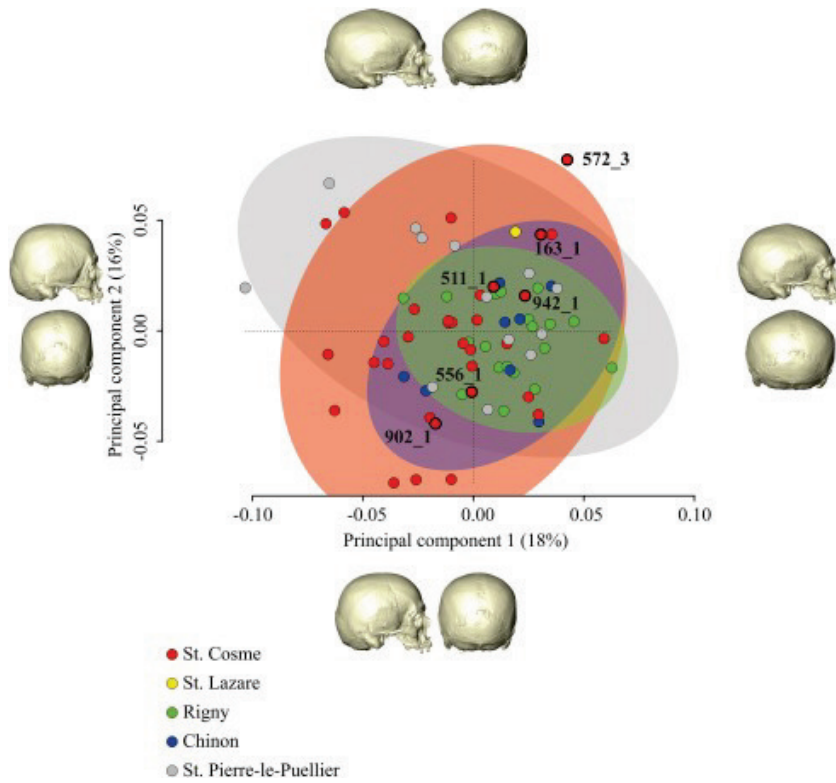


Fig. 4. PCA of the cranial shapes. Retrodeformations of shapes at the extremities of the principal components are represented. Population variability are represented using 95 % ellipsoidal confidence interval.

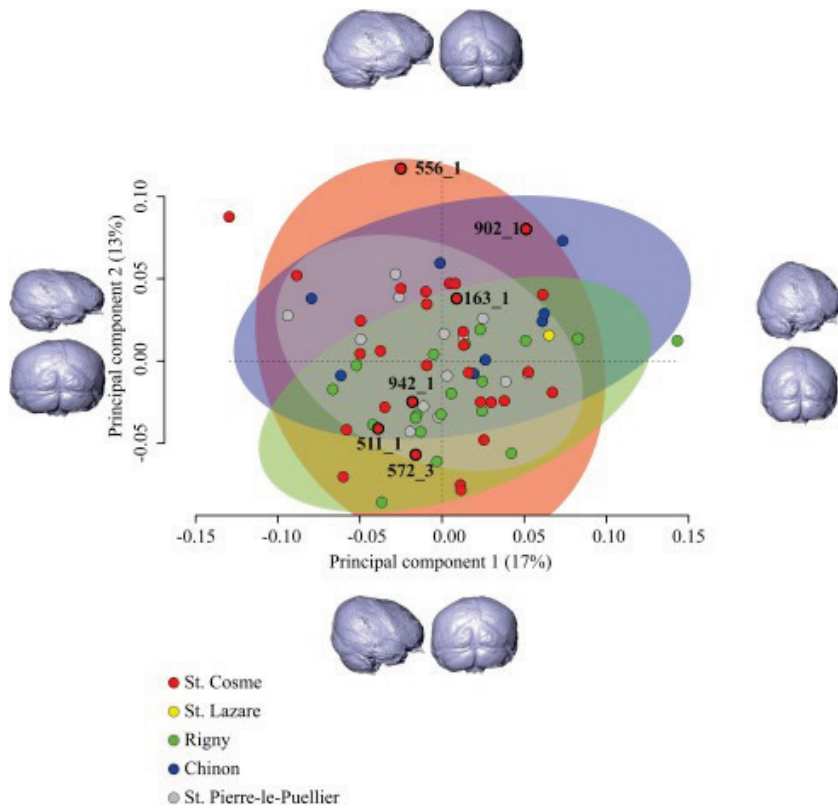


Fig. 5. PCA of the endocranial shapes. Retrodeformations of shapes at the extremities of the principal components are represented. Population variability are represented using 95 % ellipsoidal confidence interval.

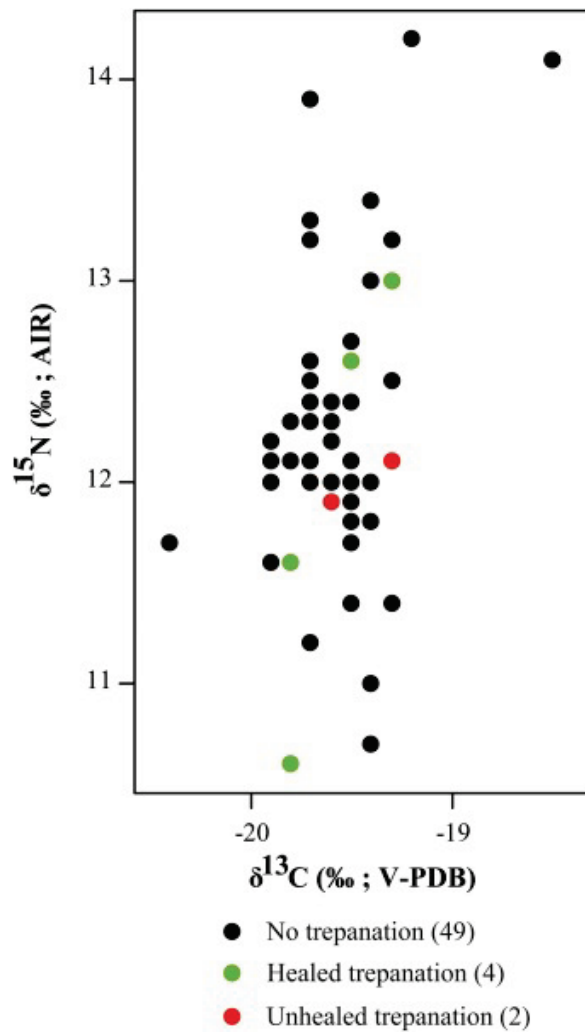


Fig. 6. Isotope ratios ($\delta^{15}\text{N}$ and $\delta^{13}\text{C}$) of trepanned and non-trepanned individuals of St. Cosme Priory.

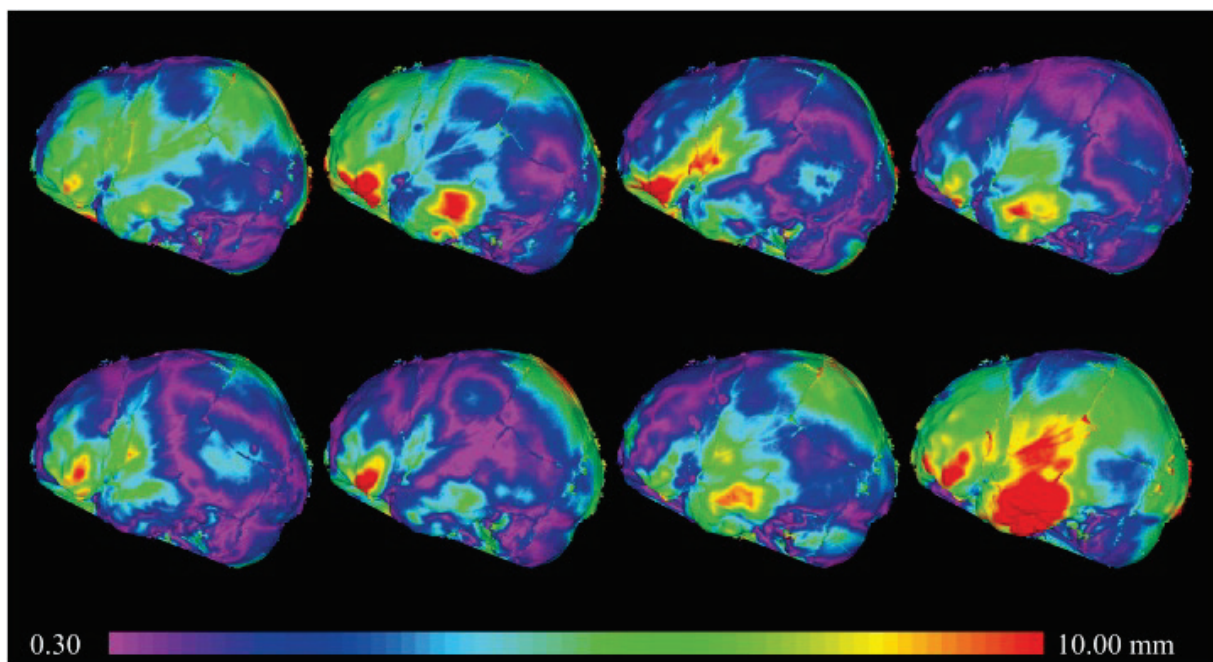


Fig. 7. Heatmap of the differences in endocranial shape of 556_1 and eight reference subjects. Only left side is represented and the differences are projected on 556_1.