



HAL
open science

The Brief Case: *Mycoplasma hominis* Extragenital Abscess

Sarah Stabler, Emmanuel Faure, Claire Duployez, Frédéric Wallet, Rodrigue Dessein, Rémi Le Guern

► **To cite this version:**

Sarah Stabler, Emmanuel Faure, Claire Duployez, Frédéric Wallet, Rodrigue Dessein, et al.. The Brief Case: *Mycoplasma hominis* Extragenital Abscess. *Journal of Clinical Microbiology*, 2021, 59 (4), pp.e02343-20. 10.1128/JCM.02343-20 . hal-03311395

HAL Id: hal-03311395

<https://hal.science/hal-03311395>

Submitted on 31 Jul 2021

HAL is a multi-disciplinary open access archive for the deposit and dissemination of scientific research documents, whether they are published or not. The documents may come from teaching and research institutions in France or abroad, or from public or private research centers.

L'archive ouverte pluridisciplinaire **HAL**, est destinée au dépôt et à la diffusion de documents scientifiques de niveau recherche, publiés ou non, émanant des établissements d'enseignement et de recherche français ou étrangers, des laboratoires publics ou privés.

1 **TITLE:** The Brief Case: *Mycoplasma hominis* Extragenital Abscess

2

3 **Author names and affiliations:** Sarah Stabler^{1,2}, Emmanuel Faure^{1,2}, Claire
4 Duployez^{1,3}, Frédéric Wallet^{1,3}, Rodrigue Dessein^{1,3}, Rémi Le Guern^{1,3}

5

6 ¹ Univ. Lille, CNRS, Inserm, CHU Lille, Institut Pasteur Lille, U1019 - UMR 9017 - CIIL -
7 Center for Infection and Immunity of Lille, F-59000 Lille, France.

8 ² Service de Maladies Infectieuses, CHU Lille, F-59000 Lille, France.

9 ³ Laboratoire de Bactériologie, CHU Lille, F-59000 Lille, France.

10

11 **Corresponding author:** Rémi Le Guern. Laboratoire de Bactériologie, Centre de
12 Biologie Pathologie Génétique. Boulevard du Professeur Jules Leclercq. 59037 Lille
13 France.

14 Email address: remi.leguern@chru-lille.fr

15 **Keywords:** Bacteriological Techniques; *Mycoplasma* infections; Extragenital infection

16 **CASE**

17 A 55-year-old woman with an unexplored 1-month history of rectal bleeding presented
18 to the emergency department with abdominal pain, chills, and fever. The patient
19 received rituximab, a monoclonal antibody targeting the CD20 antigen expressed on B
20 cells, for rheumatoid arthritis. An abdominal computed tomography (CT) scan
21 highlighted a right peri-rectal collection and focal sigmoiditis with few diverticula (Fig. 1).
22 Owing to sepsis, the patient received piperacillin-tazobactam in association with
23 gentamicin and underwent an early laparoscopy to drain the collection a few hours after
24 initiation of antimicrobial therapy. Gram staining of the peri-rectal collection revealed
25 numerous polymorphonuclear leukocytes with no visible microorganisms. Surgical
26 samples and blood cultures remained sterile even after five days of incubation. The
27 patient presented no improvement in her clinical condition. Persistent fever and
28 recurring chills along with high levels of inflammatory blood markers resulted in a
29 treatment change to vancomycin, cefepime, and metronidazole. A CT scan on day 10
30 showed a stable rectal abscess. On day 14, antibiotics were switched for meropenem,
31 amikacin, and fluconazole due to the persistent fever. Other sets of blood cultures
32 remained negative. The fever persisted with no explanation other than the rectal
33 abscess.

34 On day 20, the patient underwent exploratory laparotomy and a low Hartmann's
35 resection of the rectum. The pathological examination of the resected specimen led to a
36 diagnosis of perforated rectal endometriosis. Gram staining of the peri-rectal collection
37 again showed numerous polymorphonuclear leukocytes and no visible microorganisms.
38 However, four days of incubation on blood agar at 35°C under 5% CO₂ resulted in the

39 formation of pinpoint-sized colonies resembling water droplets (Fig. 2A). These colonies
40 could not be identified by matrix-assisted laser desorption/ionization-time of flight mass
41 spectrometry (MALDI-TOF MS) (“no peaks found”). A Gram-stain performed on the
42 colonies showed no bacteria. These results led us to suspect *Mycoplasma hominis*, and
43 the colonies were transferred to differential agar medium (A7) for further analysis.

44 *M. hominis* identification was confirmed after 48 hours of incubation on A7 agar. In
45 addition, after a total of six days of incubation on blood agar, MALDI-TOF MS (Bruker
46 Daltonics, Wissembourg, France) identified the larger colonies as *M. hominis* with a
47 score of 1.97 (database MBT IVD, Library 9.0).

48 The commercial MYCOFAST Revolution colorimetric assay (ELITechGroup, Puteaux,
49 France) was used to determine antibiotic susceptibility, using the Clinical Laboratory
50 Standards Institute (CLSI) breakpoints (1). The isolate was susceptible to both
51 tetracycline ($\text{MIC} \leq 1 \text{ mg/L}$) and clindamycin ($\text{MIC} \leq 0.25 \text{ mg/L}$), but resistant to
52 erythromycin/azithromycin ($\text{MIC} > 16 \text{ mg/L}$), levofloxacin ($\text{MIC} > 4 \text{ mg/L}$), and
53 moxifloxacin ($\text{MIC} > 2 \text{ mg/L}$) (Fig. 2B). The patient was treated with doxycycline for three
54 weeks with a favorable outcome.

55 DISCUSSION

56 *Mycoplasma* belongs to the class *Mollicutes*, which is characterized by the absence of a
57 cell wall. *M. hominis* is a commensal bacterium colonizing the urogenital tract and is a
58 causative agent for urogenital infections, such as pelvic inflammatory disease or
59 chorioamnionitis. Although extragenital infections are less frequent, *M. hominis* has
60 been reported to cause mediastinitis (2), abscesses, and bacteremia, particularly in
61 postoperative patients and immunocompromised patients (3, 4).

62 Immunosuppression is the main risk factor for developing *M. hominis* extragenital
63 infections (3). Approximately 50% of patients with *M. hominis* extragenital infections had
64 an impaired cell-mediated immune system or hypogammaglobulinemia (3). In our case,
65 the patient had received rituximab, which decreases B cell number for more than six
66 months after administration and may also decrease immunoglobulin levels. Solid organ
67 transplant recipients are particularly at risk of developing extragenital *M. hominis*
68 infections (4). *M. hominis* has also been identified in postoperative infections (1).
69 Hyperammonemia syndrome, an encephalopathy due to high plasma ammonium levels,
70 has also been linked to *Mycoplasma* and *Ureaplasma* following lung, kidney, or
71 hematopoietic stem cell transplantation (5). Notably, ammonium is produced from
72 arginine by one of the major energy-producing pathways of *M. hominis*. Overall, *M.*
73 *hominis* infection should be evoked in immunocompromised patients with extragenital
74 abscesses, particularly when numerous leukocytes are present with no visible
75 microorganisms.

76 The diagnosis of invasive *M. hominis* infections is challenging. As *M. hominis* lacks a
77 cell wall, it cannot be detected by Gram staining. DNA fluorochrome staining (acridine
78 orange or Hoechst 33258) may be used to detect *Mycoplasma* in body fluids, but these
79 stains are not specific. Without clinical suspicion of *M. hominis* infection, specific tests
80 for *Mycoplasma* detection are not routinely performed. Our case shows the
81 serendipitous diagnosis of *M. hominis* through the observation of pinpoint-sized
82 colonies, which can grow on blood and chocolate agar after two to seven days of
83 incubation (2). The small size of these colonies (0.2 mm in diameter) renders them
84 difficult to detect without careful inspection under reflected light. This knowledge could
85 prove useful to clinical microbiologists. In our case, no bacterial growth was detected
86 from the first surgical samples. Even if *M. hominis* can grow on blood or chocolate agar,
87 this is not always reliable. *M. hominis* translucent colonies may have been overlooked
88 before discarding the agar media because they can be easily mistaken for water
89 droplets. Prolonged incubation is necessary to allow *M. hominis* colonies to develop.

90 *M. hominis* should be suspected when Gram staining fails to detect microorganisms
91 from pinpoint-sized colonies, warranting subculture onto mycoplasma media. If
92 mycoplasma media is unavailable locally, another alternative workflow would be to
93 perform an acridine orange stain on the colonies to prove the presence of
94 microorganisms and send the isolate to a reference laboratory for identification by
95 MALDI-TOF MS or 16S rRNA sequencing. There are several types of mycoplasma
96 media, including SP4 agar supplemented with arginine, Hayflick agar, and A7 agar, with
97 penicillin G generally added for selectivity. Agar plates should be incubated under 5–
98 10% CO₂ or under anaerobic conditions at 35°C for a minimum of five days. A

99 stereomicroscope can aid in the visualization of the colonies, identifiable by their typical
100 “fried egg” appearance. The biochemical profile helps to differentiate *M. hominis* from
101 *Ureaplasma* spp.: *M. hominis* utilizes arginine (alkaline shift from orange to deep-red,
102 Fig. 2B), contrary to *Ureaplasma* spp. which utilizes urea. Other *Mycoplasma* species
103 are also able to utilize arginine, but *M. hominis* is the only human pathogenic species of
104 *Mycoplasma* able to grow on blood or chocolate agar.

105 For a definite identification at the species level, MALDI-TOF MS can be used. *M.*
106 *hominis* is present in both Bruker MALDI Biotyper and Vitek MS databases. In total, the
107 Bruker MBT 8326 IVD database contains 12 species of *Mycoplasma*, and the Vitek MS
108 V3.2 database contains 14 species of *Mycoplasma*. However, the main issue is the low
109 biomass of the *Mycoplasma* colonies, especially after incubation on blood or chocolate
110 agar instead of specific mycoplasma media. In our case, MALDI-TOF MS identification
111 failed after four days of incubation on blood agar but was successful after six days of
112 incubation on blood agar or two days on A7 agar, with a score of 1.97. Pereyre *et al.*
113 suggested that accurate species-level identification was achievable for *Mycoplasma*
114 with a score ≥ 1.70 for Bruker MALDI-TOF MS, instead of the classical threshold of
115 ≥ 2.00 (6).

116 Molecular methods provide an alternative for diagnosing extragenital *M. hominis*
117 infections, not only for identifying suspect colonies but also directly from clinical
118 samples. Several in-house real-time PCR assays have been developed for *M. hominis*
119 detection, targeting either 16S rRNA, *gap*, or *yidC* genes. However, minor sequence
120 variations were reported in 16 rRNA or *gap* genes, which may lower clinical sensitivity
121 (7). Real-time PCR targeting the *yidC* gene was estimated to have a limit of detection of

122 seven copies/ μL , making it more sensitive than culturing urogenital samples (7). Direct
123 16S rRNA sequencing from clinical samples has been successfully used to diagnose
124 extragenital *M. hominis* infections (2). Extending this to next-generation sequencing or
125 shotgun metagenomic sequencing is promising for diagnosing pathogens in abscesses.

126 *M. hominis* is naturally resistant to all antibiotics targeting cell wall synthesis (β -lactams,
127 glycopeptides, fosfomycin), erythromycin/azithromycin, sulfamides, and rifampicin.
128 Without a definitive diagnosis, it is unlikely that patients suffering from *M. hominis*
129 extragenital infections will receive effective antimicrobial therapy. For example, patients
130 with intra-abdominal abscesses or mediastinitis typically receive a broad-spectrum β -
131 lactam, associated with an antibiotic covering Gram-positive bacteria (glycopeptide or
132 oxazolidinone). These antibiotics are not active on *M. hominis*. Inadequate antimicrobial
133 therapy can lead to poor outcomes, including complications and iterative readmissions
134 with prolonged hospital stays (4). *M. hominis* is potentially susceptible to tetracyclines,
135 clindamycin, and fluoroquinolones (levofloxacin or moxifloxacin). However, acquired
136 resistance has been reported. High-level resistance to tetracyclines is carried by the
137 *tet(M)* gene, and isolates resistant to fluoroquinolones harbor mutations in the *gyrA*,
138 *parC*, or *parE* genes (8). In France, the resistance rate was 15% for tetracyclines, 3%
139 for levofloxacin, and 2% for moxifloxacin (8). Therefore, antimicrobial susceptibility
140 testing must be performed to select adequate antimicrobial therapy.

141 The disk diffusion method is not recommended for testing antimicrobial susceptibility as
142 there is no correlation between inhibition diameter and MIC. The Clinical Laboratory
143 Standards Institute (CLSI) describes the reference methods for antimicrobial
144 susceptibility as agar dilution and broth microdilution (9). Agar gradient diffusion (E-test)

145 represents a potentially comparable method (10) but is not endorsed by the CLSI (9).
146 Commercial antimicrobial susceptibility assays using *M. hominis* have also been
147 reported to perform similarly to the reference methods (8). These commercial assays
148 provide a simple method to screen several concentrations of antimicrobials in a
149 microwell plate format.

150 Extragenital infections due to *M. hominis* are rare but not exceptional, particularly in
151 immunocompromised patients, and are likely underdiagnosed. Clinical microbiologists
152 should be aware of the appearance of *M. hominis* colonies on blood agar after
153 prolonged incubation to ensure the appropriate testing for *M. hominis* in the case of
154 culture-negative abscesses, particularly in immunocompromised individuals.

155 **SELF-ASSESSMENT QUESTIONS**

156 1. Which of the following condition is associated with *Mycoplasma hominis*
157 extragenital infections?

- 158 a. Neutropenia
- 159 b. Hypogammaglobulinemia
- 160 c. Obesity
- 161 d. Diabetes

162 2. Which of the following statements concerning *Mycoplasma hominis* identification
163 is correct?

- 164 a. *M. hominis* is unable to grow on blood or chocolate agar under 5% CO₂.
- 165 b. *M. hominis* is undetectable by Gram staining.
- 166 c. *M. hominis* is absent from MALDI-TOF MS databases.
- 167 d. *M. hominis* produce large colonies (> 1 mm) on mycoplasma media.

168 3. *Mycoplasma hominis* is naturally resistant to which class of antibiotics?

- 169 a. Tetracyclines
- 170 b. β -lactams
- 171 c. Lincosamides
- 172 d. Fluoroquinolones

173

174 **Conflict of interest:** None.

175 **Funding:** CHU Lille.

176 **Words:**

177 Case: 426 words

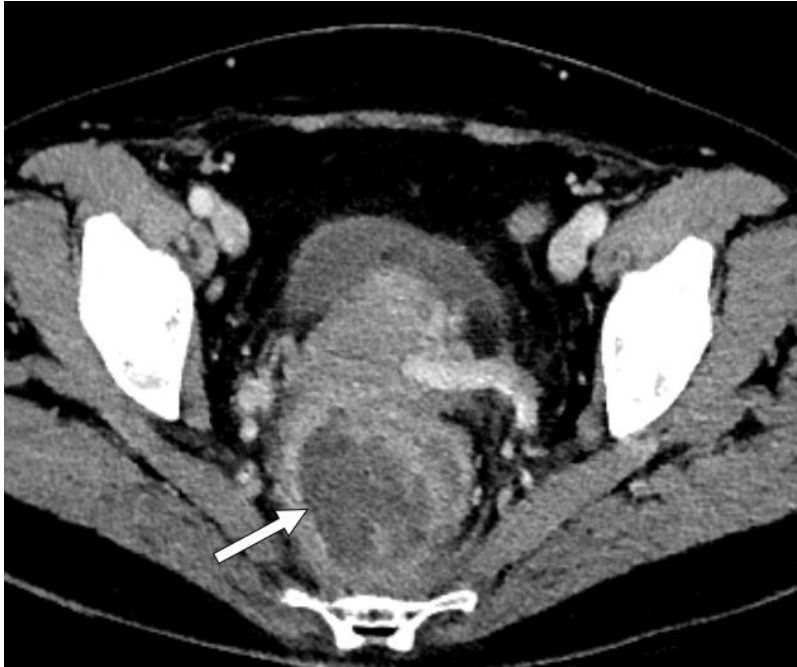178 Discussion: 1158 words

179

180 **Figure Legends**

181 **Figure 1.** Contrast-enhanced abdominopelvic CT scan. White arrow: peri-rectal
182 abscess.

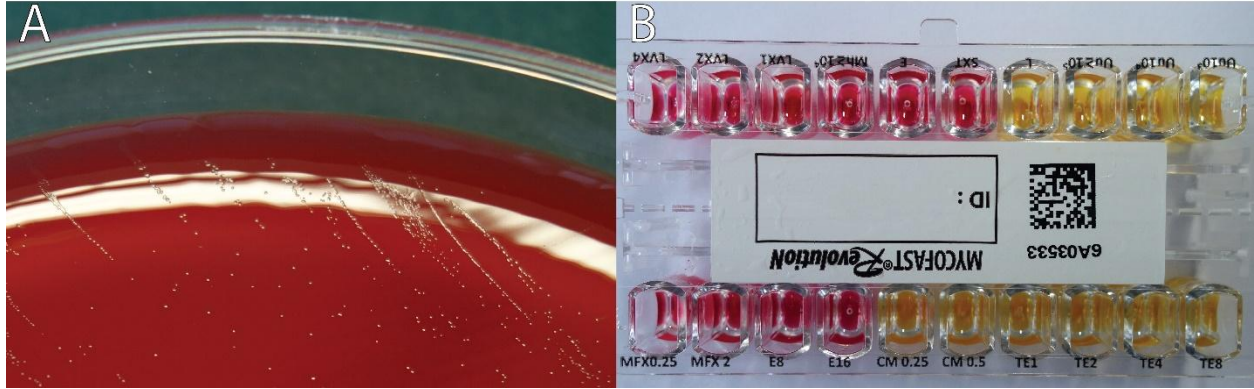
183 **Figure 2.** Microbial analysis images. (A) Pinpoint-sized colonies, later identified as *M.*
184 *hominis*, on blood agar following four days of incubation under 5% CO₂ at 35°C. (B)
185 Colorimetric antibiotic susceptibility results. MFX: moxifloxacin, E: erythromycin, CM:
186 clindamycin, TE: tetracycline, LVX: levofloxacin.



187

188 **Figure 1.** Contrast-enhanced abdominopelvic CT scan. White arrow: peri-rectal
189 abscess.

190



191

192 **Figure 2.** Microbial analysis images. (A) Pinpoint-sized colonies, later identified as *M.*
193 *hominis*, on blood agar following four days of incubation under 5% CO₂ at 35°C. (B)
194 Colorimetric antibiotic susceptibility results. MFX: moxifloxacin, E: erythromycin, CM:
195 clindamycin, TE: tetracycline, LVX: levofloxacin.

196

197 **BILIOGRAPHY**

198

- 199 1. Waites KB, Duffy LB, Bebear CM, Matlow A, Talkington DF, Kenny GE, Totten
200 PA, Bade DJ, Zheng X, Davidson MK, Shortridge VD, Watts JL, Brown SD. 2012.
201 Standardized methods and quality control limits for agar and broth microdilution
202 susceptibility testing of *Mycoplasma pneumoniae*, *Mycoplasma hominis*, and
203 *Ureaplasma urealyticum*. *J Clin Microbiol* 50:3542-7.
- 204 2. Le Guern R, Loiez C, Loobuyck V, Rouse N, Courcol R, Wallet F. 2015. A new
205 case of *Mycoplasma hominis* mediastinitis and sternal osteitis after cardiac
206 surgery. *Int J Infect Dis* 31:53-5.
- 207 3. Meyer RD, Clough W. 1993. Extragenital *Mycoplasma hominis* infections in
208 adults: emphasis on immunosuppression. *Clin Infect Dis* 17 Suppl 1:S243-9.
- 209 4. Adams M, Bouzigard R, Al-Obaidi M, Zangeneh TT. 2020. Perinephric abscess
210 in a renal transplant recipient due to *Mycoplasma hominis*: Case report and
211 review of the literature. *Transpl Infect Dis* doi:10.1111/tid.13308:e13308.
- 212 5. Wylam ME, Kennedy CC, Hernandez NM, Peters SG, Maleszewski JJ, Cassivi
213 SD, Scott JP. 2013. Fatal hyperammonaemia caused by *Mycoplasma hominis*.
214 *Lancet* 382:1956.
- 215 6. Pereyre S, Tardy F, Renaudin H, Cauvin E, Del Pra Netto Machado L, Tricot A,
216 Benoit F, Treilles M, Bebear C. 2013. Identification and subtyping of clinically
217 relevant human and ruminant mycoplasmas by use of matrix-assisted laser
218 desorption ionization-time of flight mass spectrometry. *J Clin Microbiol* 51:3314-
219 23.

- 220 7. Ferandon C, Peuchant O, Janis C, Benard A, Renaudin H, Pereyre S, Bebear C.
221 2011. Development of a real-time PCR targeting the yidC gene for the detection
222 of Mycoplasma hominis and comparison with quantitative culture. Clin Microbiol
223 Infect 17:155-9.
- 224 8. Meygret A, Le Roy C, Renaudin H, Bebear C, Pereyre S. 2018. Tetracycline and
225 fluoroquinolone resistance in clinical Ureaplasma spp. and Mycoplasma hominis
226 isolates in France between 2010 and 2015. J Antimicrob Chemother 73:2696-
227 2703.
- 228 9. Clinical and Laboratory Standards Institute. 2011. Methods for Antimicrobial
229 Susceptibility Testing for Human Mycoplasmas; Approved Guideline M43-A.
230 Clinical and Laboratory Standards Institute, Wayne (PA).
- 231 10. Waites KB, Canupp KC, Kenny GE. 1999. In vitro susceptibilities of Mycoplasma
232 hominis to six fluoroquinolones as determined by E test. Antimicrob Agents
233 Chemother 43:2571-3.

234