



Bacteremia Due to *Kosakonia cowanii* in a Preterm Neonate

Claire Duployez, Marie-Eve Edun-Renard, Eric Kipnis, Rodrigue Dessein,
Rémi Le Guern

► To cite this version:

Claire Duployez, Marie-Eve Edun-Renard, Eric Kipnis, Rodrigue Dessein, Rémi Le Guern. Bacteremia Due to *Kosakonia cowanii* in a Preterm Neonate. *Journal of Pediatric Infectious Diseases*, 2021, 16 (04), pp.183-186. 10.1055/s-0040-1721448 . hal-03309806

HAL Id: hal-03309806

<https://hal.science/hal-03309806>

Submitted on 30 Jul 2021

HAL is a multi-disciplinary open access archive for the deposit and dissemination of scientific research documents, whether they are published or not. The documents may come from teaching and research institutions in France or abroad, or from public or private research centers.

L'archive ouverte pluridisciplinaire **HAL**, est destinée au dépôt et à la diffusion de documents scientifiques de niveau recherche, publiés ou non, émanant des établissements d'enseignement et de recherche français ou étrangers, des laboratoires publics ou privés.

Copyright

TITLE: Bacteremia due to *Kosakonia cowanii* in a preterm neonate.

AUTHORS: Claire Duployez^{1,2}, Marie-Eve Edun-Renard³, Eric Kipnis^{2,4}, Rodrigue Dessein^{1,2}, Rémi Le Guern^{1,2}

AUTHORS AFFILIATIONS:

¹ Laboratoire de Bactériologie, CHU Lille, F-59000 Lille, France.

² Univ. Lille, CNRS, Inserm, CHU Lille, Institut Pasteur de Lille, U1019 - UMR 9017 - CIIL - Center for Infection and Immunity of Lille, F-59000 Lille, France.

³ Unité des Soins Intensifs, Service de Néonatalogie, CHU Lille, F-59000 Lille, France.

⁴ Pôle d'Anesthésie-Réanimation, CHU Lille, F-59000 Lille, France.

CORRESPONDING AUTHOR: Dr Claire DUPLOYEZ

claire.duployez@chru-lille.fr

Laboratoire de Bactériologie-Institut de Microbiologie

Centre de Biologie Pathologie

F-59037-Lille Cedex, France

Telephone number: +33-320.445.480

Fax number: +33-320.444.895

ABSTRACT

Objective: Low-weight birth infants admitted to neonatal intensive care units are at high risk of hospital-acquired infections by opportunistic pathogens. The gut microbiota of preterm neonates lacks commensal bacteria providing a barrier against pathogens. We report a case of bacteremia due to *Kosakonia cowanii* in a preterm neonate.

Case report: Caesarian-section delivered a female baby of 680g at 28 weeks of gestation due to intrauterine growth retardation and fetal rhythm abnormalities. On day 27, two blood cultures grew Gram-negative bacilli in a context of functional ileus. No reliable identification could be obtained using MALDI-TOF mass spectrometry, biochemical reactions with the VITEK 2 GN ID card, or 16S rDNA sequencing. *Kosakonia cowanii* was finally identified by *gyrB* sequencing. The source of infection may have been either the central venous catheter or translocation from the gut microbiota. Evolution was favorable after 14 days of cefepime (combined with amikacin for five days) and central venous catheter removal.

Conclusion: *Kosakonia cowanii* is a member of the *Enterobacteriaceae* family that was recently reclassified from the *Enterobacter* genus. Human infections due to *K. cowanii* are scarce and have mainly been associated with traumatic inoculation from plants or transient gut colonization. *K. cowanii* may be an underestimated opportunistic pathogen in susceptible populations such as preterm neonates.

KEY-WORDS: Bacteriological Techniques; *Kosakonia cowanii*; Prematurity

Introduction

Healthcare-associated infections frequently occur in neonatal intensive care units, with a peak incidence reported between the 10th and 22nd day of life¹. Incidence of late-onset sepsis is inversely correlated to birth weight: 36.3% of neonates with a gestational age under 28 weeks had at least one episode of sepsis compared to 29.6% for moderately preterm, 17.5% for late preterm, and 16.5% for full term infants¹. Risk factors include the immature innate immune system of preterm neonates, prolonged hospitalization, use of invasive medical procedures, and failure of early enteral feeding with breast milk^{1,2}. Moreover, the gut microbiota of preterm neonates lacks commensal bacteria providing resistance against pathogens³. Thus, the risk of infection due to translocation from the intestinal tract may increase. Indeed, Stewart et al. found that the causative agent of late-onset sepsis in preterm neonates was within the dominant genus of the gut microbiome⁴. *Enterobacter* species are the most abundant bacteria present in preterm neonates' gut, especially after antimicrobial therapy⁵. *Kosakonia cowanii* is a member of the *Enterobacteriaceae* family that was recently reclassified from the *Enterobacter* genus⁶. *K. cowanii* is frequently encountered as a plant pathogen but rarely described in human infections. We present a case of bacteremia due to *K. cowanii* in a preterm neonate.

Case report

Caesarian-section delivered a female baby of 680g at 28 weeks of gestation due to intrauterine growth retardation and fetal rhythm abnormalities. A central venous catheter was inserted, and enteral nutrition with pasteurized breast milk was initiated on day 1 of life. On day 10, the neonate presented bacterial sepsis due to *Staphylococcus epidermidis* : he had fever at 38°C, frequent apneas with bradycardia and desaturation. Continuous Positive Airway Pressure

(CPAP) and transfusion of one unit of packed red blood cells were required. The evolution was favorable after ten days of antimicrobial therapy with vancomycin.

On day 27, the baby presented abdominal distension with residual feeds attributed to a functional ileus, since she had no rectal bleeding nor vomiting. Hemodynamic and respiratory functions deteriorated again, requiring endotracheal intubation from day 28 to day 31, transfusion of five units of packed red blood cells and daily platelet transfusion from day 27 to day 34. Enteral feeding was temporarily stopped.

Blood cultures from day 27 yielded Gram-negative bacilli after 16 hours of incubation. No reliable identification was assessed by MALDI-TOF spectrometry mass (Bruker Daltonics, Wissembourg, France); the best score was 1.54 for *K. cowanii*. Biochemical reactions using VITEK 2 GN ID card (BioMérieux, Marcy l'Etoile, France) identified the strain as *Pantoea* spp., with a probability of 97%. However, the strain fermented sorbitol and did not use malonate; those two characteristics distinguish *K. cowanii* from *Pantoea agglomerans*.

Sequencing of 16S rDNA was performed using universal primers 91E (TCAAAKGAATTGACGGGGGC-3) and 13BS (CCCGGGAACGTATTTCAC) on the 3500 Dx Genetic Analyzer (Life Technologies, Cergy-Pontoise, France)⁷. Definitive identification could not be obtained from the 16S partial sequence, because 99% identity out of 431 base pairs was found for *K. cowanii*, *Salmonella enterica*, and *Atlantibacter hermannii*. Thus, *gyrB* sequencing was performed using the primers UP1 (GAAGTCATCATGACCGTTCTGCAYGCNGGNGGNAARTTYGA) and 181r (CAGGAAACAGCTATGACCARRTGNGTNCCNCC) for amplification, followed by UP1-seq (GAAGTCATCATGACCGTTCTGCA) and 181r-seq (CAGGAAACAGCTATGACC) for sequencing⁸. *gyrB* sequencing identified the isolate as *K. cowanii*, showing 99% identity out of 521 base pairs with *K. cowanii* type strain JCM 10956 (Genbank accession number

JX425012.1). A phylogenetic tree based on *gyrB* sequences (Figure 1) was constructed in MEGA X⁹, using the minimum evolution method.

In vitro antimicrobial susceptibility was determined by Mueller-Hinton agar disc diffusion using the critical zone diameters recommended by the CASFM –EUCAST (version 2020) and using an automated method (VITEK 2, BioMérieux, Marcy l'Etoile, France). Interestingly, this strain did not produce an AmpC β -lactamase as expected from a former *Enterobacter* species, but a penicillinase. The strain was resistant to amoxicillin (MIC \geq 32 mg/L), ticarcillin (MIC \geq 128 mg/L), and piperacillin (MIC = 64 mg/L); all the other beta-lactams were active, including amoxicillin-clavulanate (MIC \leq 2 mg/L) and cephalosporins (MIC \leq 1 mg/L for cefotaxime, ceftriaxone, and cefepime).

After 14 days of cefepime, initiated on day 27 (combined with amikacin for five days) and central venous catheter removal, evolution was favorable. Antimicrobial therapy and laboratory values are represented as a timeline in Figure 2. Blood cultures remained sterile after catheter change; *K. cowanii* also grew from the central venous catheter (10^3 CFU / mL), indicating it could be the infection source. The neonate was discharged from the hospital after three months of life, weighing 2615g for 48 cms.

Discussion

Until 2013, the *Kosakonia* genus was part of the genus *Enterobacter*. Many species from the *Kosakonia* genus (*K. radicincitans*, *K. sacchari*, *K. oryzae*, *K. cowanii*, *K. arachidis*) have been isolated from plants, and only a few human infections have been described¹⁰. *K. cowanii* was first described from a patient sample but is mostly isolated from environmental samples, including soil and trees. *K. cowanii* may promote plant growth and be identified as an endophyte in trees with symptoms of blight⁶. Human infections due to *K. cowanii* are scarce. They have been associated with traumatic inoculation from plants. In a

case, rhabdomyolysis due to bacteremia was observed after rose thorn prick¹¹. More recently, Berinson *et al.* reported a case of acute cholecystitis in an immunocompromised patient without penetrating trauma¹², suggesting the origin of the infection may be food contamination. The authors suggested that transient colonization of the gut by *K. cowanii* may have caused acute cholecystitis in an immunocompromised patient.

Low-weight birth infants admitted in neonatal intensive care units are at high risk of hospital-acquired infections by opportunistic pathogens². No case of *K. cowanii* opportunistic infections in low-weight birth infants had been reported in the literature yet. Our case report highlights that *K. cowanii* may be a relevant cause of infections in the population of preterm neonates. Preterm neonates are vulnerable to infections caused by opportunistic foodborne pathogens since their local natural barrier is immature, and secretory immunoglobulins A are lacking during the first days of life. *K. cowanii* was previously isolated from powdered infant milk formula¹³. However, food contamination may not be the origin of infection in our case since the neonate was fed with pasteurized breast milk. In our patient, the source of infection may have been bacterial translocation from the gut microbiota. Indeed, previous studies showed that the pathogen identified in blood culture for late-onset sepsis in preterm infants was usually abundant in the gut microbiome⁴. Additional risk factors of bacterial sepsis in this population include a central venous catheter, parenteral nutrition, and steroids¹⁴. Another hypothesis for the infection source may have been the central venous catheter, as suggested by the positive bacteriological culture of the catheter.

Other environmental species, mostly former members of the *Enterobacter* group, were described as pathogens for neonates. The typical example is *Cronobacter sakazakii*, which has been isolated from environmental sources, milk, and infant formula, causing severe infections, especially bacteremia in preterm neonates^{6,15}. Powdered infant formula has been reported as the most commonly identified transmission vehicle of this bacterium¹⁵.

142 Berinson et al. suggested that *K. cowanii* might be an underestimated pathogen in
143 children¹². Indeed, in a retrospective study about pediatric infections due to
144 *Pantoea agglomerans*, seven patients out of 53 (13%) had a history of penetrating trauma
145 with a stick, plant thorn, or glass shard¹⁶. As shown in our case report, *K. cowanii* may be
146 falsely identified as *P. agglomerans* using biochemical reactions. It may be one of the reasons
147 for the few human infections described in the literature. The development of new
148 bacteriological techniques such as MALDI-TOF mass spectrometry and molecular biology
149 may improve our ability to identify this bacterium. *K. cowanii* is probably an underestimated
150 opportunistic pathogen in susceptible populations such as preterm neonates.

151
152 **Acknowledgments:** We thank Laure Marceau for technical help with DNA sequencing.

REFERENCES

1. Dong Y, Speer CP. Late-onset neonatal sepsis: recent developments. Arch Dis Child Fetal Neonatal Ed. 2015 May;100(3):F257-63.
2. Sharma AA, Jen R, Butler A, et al. The developing human preterm neonatal immune system: a case for more research in this area. Clin Immunol 2012;145(1):61-8.
3. Drell T, Lutsar I, Stsepetova J, et al. The development of gut microbiota in critically ill extremely low birth weight infants assessed with 16S rRNA gene based sequencing. Gut Microbes 2014;5(3):304-12.
4. Stewart CJ, Embleton ND, Marrs ECL, et al. Longitudinal development of the gut microbiome and metabolome in preterm neonates with late onset sepsis and healthy controls. Microbiome. 2017 Jul 12;5(1):75.
5. Greenwood C, Morrow AL, Lagomarcino AJ, et al. Early empiric antibiotic use in preterm infants is associated with lower bacterial diversity and higher relative abundance of Enterobacter. J Pediatr 2014;165(1):23-9.
6. Brady C, Cleenwerck I, Venter S, et al. Taxonomic evaluation of the genus Enterobacter based on multilocus sequence analysis (MLSA): proposal to reclassify *E. nimipressuralis* and *E. amnigenus* into *Lelliottia* gen. nov. as *Lelliottia nimipressuralis* comb. nov. and *Lelliottia amnigena* comb. nov., respectively, *E. gergoviae* and *E. pyrinus* into *Pluralibacter* gen. nov. as *Pluralibacter gergoviae* comb. nov. and *Pluralibacter pyrinus* comb. nov., respectively, *E. cowanii*, *E. radicincitans*, *E. oryzae* and *E. arachidis* into *Kosakonia* gen. nov. as *Kosakonia cowanii* comb. nov., *Kosakonia radicincitans* comb. nov., *Kosakonia oryzae* comb. nov. and *Kosakonia arachidis* comb. nov., respectively, and *E. turicensis*, *E. helveticus* and *E. pulveris* into *Cronobacter* as *Cronobacter zurichensis* nom. nov., *Cronobacter helveticus* comb. nov.

177 and *Cronobacter pulveris* comb. nov., respectively, and emended description of the genera
178 *Enterobacter* and *Cronobacter*. *Syst Appl Microbiol* 2013;36(5):309-19.

179 7. Le Guern R, Loïez C, Armand S, et al. Infective endocarditis: does a new 16S rDNA set of
180 primers improve the microbiological diagnosis? *Infect Dis (Lond)*. 2015;47(12):896-901.

181 8. Delmas J, Breysse F, Devulder G, et al. Rapid identification of Enterobacteriaceae by
182 sequencing DNA gyrase subunit B encoding gene. *Diagn Microbiol Infect Dis*. 2006
183 Aug;55(4):263-8.

184 9. Kumar S., Stecher G., Li M., et al. MEGA X: Molecular Evolutionary Genetics Analysis
185 across computing platforms. *Molecular Biology and Evolution* 2018;35:1547-1549.

186 10. Mertschnigg T, Patz S, Becker M, et al. First Report of *Kosakonia radicincitans*
187 Bacteraemia from Europe (Austria) - Identification and Whole-Genome Sequencing of Strain
188 DSM 107547. *Sci Rep*. 2020 Feb 6;10(1):1948.

189 11. Washio K, Yamamoto G, Ikemachi M, et al. Rhabdomyolysis due to bacteremia from
190 *Enterobacter cowanii* caused by a rose thorn prick. *J Dermatol* 2018;45(11):e313-e4.

191 12. Berinson B, Bellon E, Christner M, et al. Identification of *Kosakonia cowanii* as a rare
192 cause of acute cholecystitis: case report and review of the literature. *BMC Infect Dis*
193 2020;20(1):366.

194 13. Mardaneh J, Soltan-Dallal MM. Isolation and Identification of *E. cowanii* from Powdered
195 Infant Formula in NICU and Determination of Antimicrobial Susceptibility of Isolates. *Iran J*
196 *Pediatr* 2014;24(3):261-6.

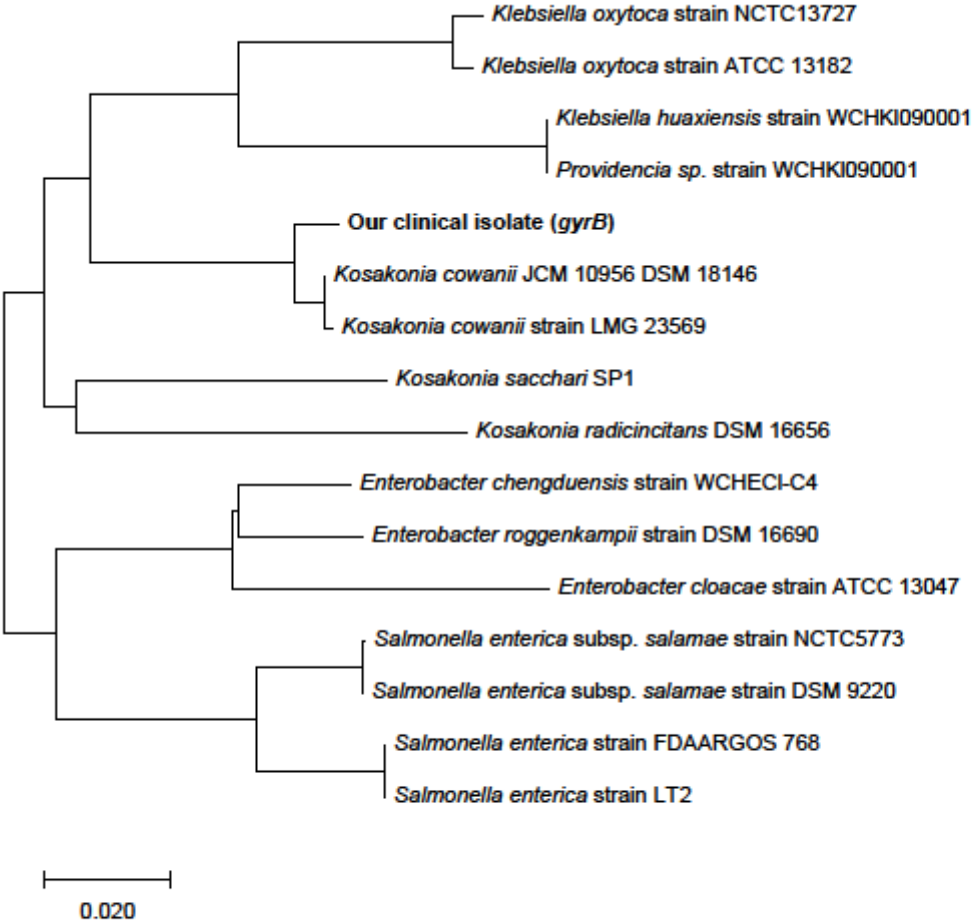
197 14. Manzoni P, De Luca D, Stronati M, et al. Prevention of nosocomial infections in neonatal
198 intensive care units. *Am J Perinatol* 2013;30(2):81-8.

199 15. Stryko J, Cope JR, Martin H, T et al. Food Safety and Invasive Cronobacter Infections
200 during Early Infancy, 1961-2018. Emerg Infect Dis 2020;26(5).

201 16. Cruz AT, Cazacu AC, Allen CH. Pantoea agglomerans, a plant pathogen causing human
202 disease. J Clin Microbiol 2007;45(6):1989-92.

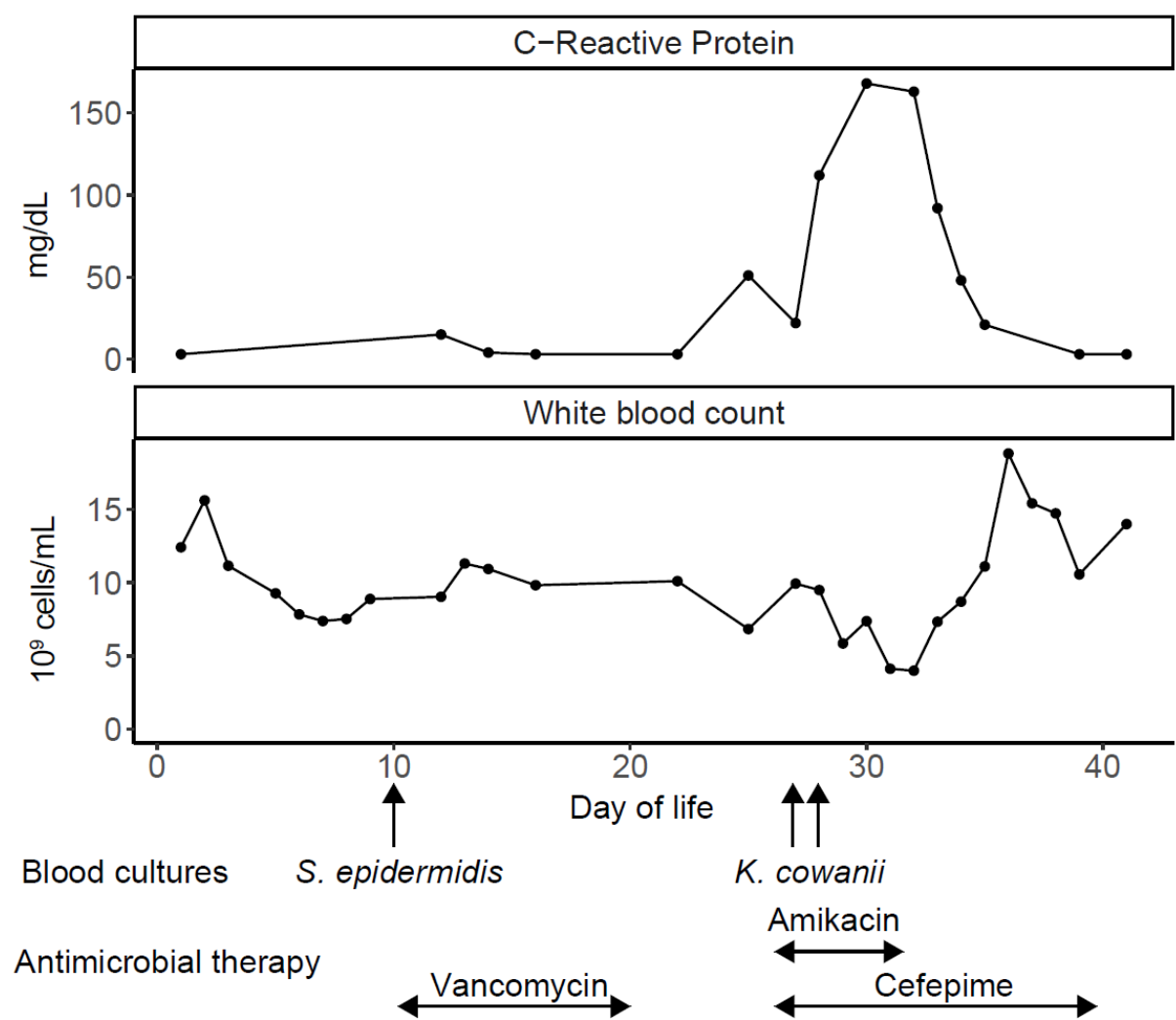
203

204 **Figure 1.** Phylogenetic tree based on *gyrB* sequences.



205
206

207 **Figure 2.** Timeline visualization of laboratory data and antimicrobial therapy.



208