



**HAL**  
open science

## Case report of a very late dual coronary stent thrombosis in a patient with coronavirus disease 2019

Marie Hauguel-Moreau, Simon Lannou, Léa Bergez, Nicolas Mansencal

### ► To cite this version:

Marie Hauguel-Moreau, Simon Lannou, Léa Bergez, Nicolas Mansencal. Case report of a very late dual coronary stent thrombosis in a patient with coronavirus disease 2019. *European Heart Journal. Case Reports*, 2021, 5 (6), pp.ytab114. 10.1093/ehjcr/ytab114 . hal-03287328

**HAL Id: hal-03287328**

**<https://hal.science/hal-03287328v1>**

Submitted on 1 Jun 2022

**HAL** is a multi-disciplinary open access archive for the deposit and dissemination of scientific research documents, whether they are published or not. The documents may come from teaching and research institutions in France or abroad, or from public or private research centers.

L'archive ouverte pluridisciplinaire **HAL**, est destinée au dépôt et à la diffusion de documents scientifiques de niveau recherche, publiés ou non, émanant des établissements d'enseignement et de recherche français ou étrangers, des laboratoires publics ou privés.



Distributed under a Creative Commons Attribution - NonCommercial 4.0 International License

# Case report of a very late dual coronary stent thrombosis in a patient with coronavirus disease 2019

Marie Hauguel-Moreau <sup>1,2\*</sup>, Simon Lannou<sup>1,2</sup>, Léa Bergez <sup>1</sup>, and Nicolas Mansencal <sup>1,2</sup>

<sup>1</sup>Department of Cardiology, Ambroise Paré Hospital, Assistance Publique-Hôpitaux de Paris (AP-HP), Centre de référence des cardiomyopathies et des troubles du rythme cardiaque héréditaires ou rares, Université de Versailles-Saint Quentin (UVSQ), 9 avenue Charles de Gaulle, 92100 Boulogne, France; and <sup>2</sup>INSERM U-1018, CESP, Épidémiologie clinique, Université de Versailles-Saint Quentin (UVSQ), 16 avenue Paul Vaillant Couturier, 94800 Villejuif, France

Received 23 November 2020; first decision 8 December 2020; accepted 10 March 2021

## Background

Coronavirus disease 2019 (COVID-19) is associated with hypercoagulability and a high rate of thrombosis. Few cases of coronary stent thrombosis associated with COVID-19 have been reported.

## Case summary

In this report, we describe the case of a 65-year-old man with a history of coronary artery disease (CAD) who was admitted following an out-of-hospital cardiac arrest related to an ST-segment elevation myocardial infarction revealing a very late dual coronary stent thrombosis of the left anterior descending and posterior descending arteries. Ten days prior to admission, he was diagnosed with COVID-19 pneumonia and treated with dexamethasone, which led to rapid clinical improvement. After resuscitation, coronary angiography revealed an acute thrombotic occlusion in the two previous drug-eluting stents (implanted in 2010 and 2018), with a high thrombus burden. He was successfully treated by percutaneous coronary intervention. The patient did not present any further complications during his hospital stay and was transferred to a cardiac rehabilitation centre.

## Discussion

Dual stent thrombosis is an exceptional event highlighting the high procoagulant state promoted by coronavirus 19. This case suggests that strengthening of antithrombotic therapy in CAD patients presenting with COVID-19 should be discussed.

## Keywords

COVID-19 • Stent thrombosis • ST-segment elevation myocardial infarction • Case report

## Learning points

- Coronavirus disease 2019 (COVID-19) is associated with hypercoagulability and high rate of arterial and venous thrombosis.
- We report an exceptional case of dual stent thrombosis in a COVID 19-affected patient, highlighting the high procoagulant state promoted by the virus.
- Clinicians should strengthen the antithrombotic therapy in coronary patients when affected by COVID-19.

\* Corresponding author. Tel: +33 (0)149095624, Fax: +33 (0)149095344, Email: [marie.hauguel@aphp.fr](mailto:marie.hauguel@aphp.fr)

Handling Editor: Grigoris Karamasis

Peer-reviewers: Konstantinos Stathogiannis; Dimitrios A Vrachatis; John Kanakakis and Derek Phan

Compliance Editor: Max Sayers

Supplementary Material Editor: Ross Thomson

© The Author(s) 2021. Published by Oxford University Press on behalf of the European Society of Cardiology.

This is an Open Access article distributed under the terms of the Creative Commons Attribution Non-Commercial License (<http://creativecommons.org/licenses/by-nc/4.0/>), which permits non-commercial re-use, distribution, and reproduction in any medium, provided the original work is properly cited. For commercial re-use, please contact [journals.permissions@oup.com](mailto:journals.permissions@oup.com)

## Introduction

By the end of January 2021, there were nearly 100 million reported cases of coronavirus disease 2019 (COVID-19) worldwide, including more than 2 million deaths.<sup>1</sup> Coronavirus disease 2019 is associated with hypercoagulability and a high rate of thrombosis.<sup>2,3</sup> Few cases of coronary stent thrombosis associated with COVID-19 have been reported.<sup>4-6</sup> We describe a patient with SARS-CoV-2 pneumonia developing late dual stent thrombosis complicated by an out-of-hospital cardiac arrest (OHCA).

## Timeline

| Time                               | Event  |
|------------------------------------|--|
| 7 September                        | Diagnostic of COVID-19 and first admission.  |
| 14 September to admission + 7 days | The patient is discharged.   |
| 15 September, 18:30                | Cardiac symptoms: violent chest pain.  |
| 15 September, 20:32                | Diagnostic of ST-segment elevation myocardial infarction with an anterior and inferior ST-segment elevation on electrocardiogram.  |
| 15 September 20:42                 | First out-of-hospital cardiac arrest (OHCA) on ventricular fibrillation.   |
| 15 September, 21:23                | Second OHCA/ventricular fibrillation (VF).   |
| 15 September, 21:27                | Third OHCA/VF.   |
| 15 September, 21:32                | A coronary angiogram shows a dual stent thrombosis in mid-left anterior descending and mid-posterior descending artery. The patient is successfully treated by percutaneous coronary intervention. |
| 24 September to admission +9 days  | The patient is transferred to a cardiac rehabilitation centre.   |

## Case presentation

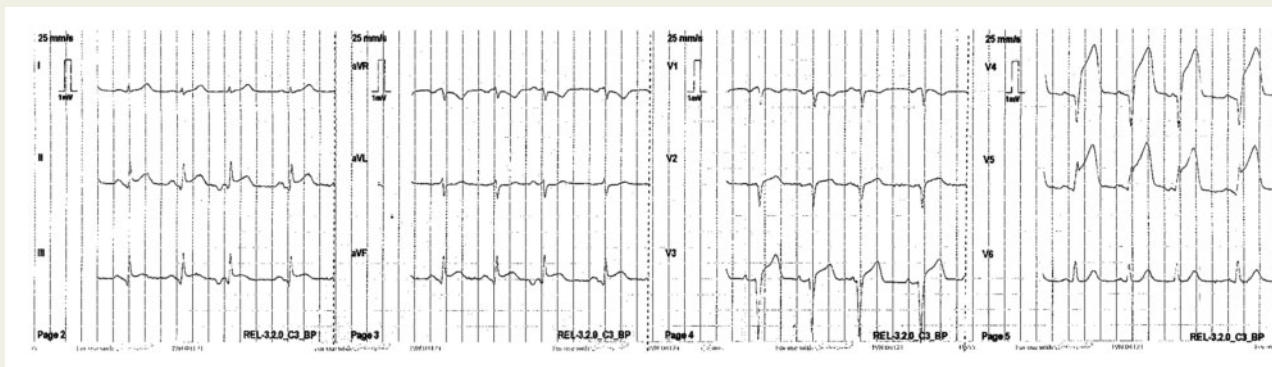
A 65-year-old man with hypertension, psoriatic arthritis treated by etanercept and methotrexate, and coronary artery disease (CAD) was admitted to our catheterization laboratory following an OHCA. Examination revealed an ST-segment elevation myocardial infarction (STEMI). Ten years before, the patient presented with STEMI and two drug-eluting stents (DES) were implanted in the posterior descending artery (PDA). Two years prior to the present admission, a DES was implanted in the mid-left anterior descending (LAD) for *de novo* angina. Left ventricular ejection fraction (LVEF) was normal. The patient was compliant with his treatment including aspirin, etanercept, methotrexate, enalapril, hydrochlorothiazide, ezetimib, atorvastatin, and verapamil.

Ten days prior to admission, he was admitted to our hospital for dyspnoea and fever, with a diagnosis of COVID-19 interstitial

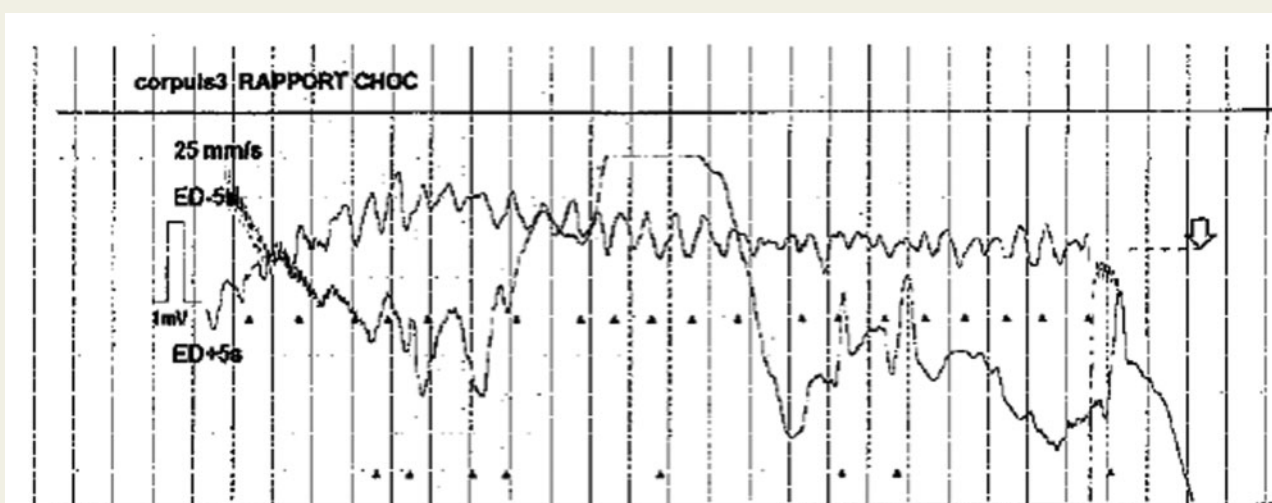
pneumonia and a positive SARS-CoV-2 reverse transcriptase-polymerase chain reaction. Laboratory tests indicated an increase in inflammatory markers: increased levels of fibrinogen [4.9 g/L ( $N < 3.5$  g/L)], C-reactive protein [74 mg/L ( $N < 6$  mg/L)], lactate dehydrogenase [410 U/L ( $N < 246$  U/L)], and D-dimer [1874 ng/mL ( $N < 650$  ng/mL)]. Treatment with dexamethasone, oxygen supplementation, and enoxaparin 4000 IU bid led to fast clinical improvement. One day before the OHCA, he was discharged without any change in cardiovascular treatment. He had fully recovered from COVID-19, the D-dimer level was normal for his age [630 ng/mL ( $N < 650$  ng/mL)], whereas fibrinogen was still high [3.9 g/L ( $N < 3.5$  g/L)] at discharge.

Three hours prior to admission, the patient felt sudden chest pain. He had no signs of shock, shortness of breath, or fever. His physical examination findings were normal. The emergency transport service performed an electrocardiogram (ECG) (Figure 1), which indicated anterior and inferior ST-segment elevation with Q waves in the anterior and inferior leads. Immediately after the ECG, cardiac arrest due to ventricular fibrillation (VF) was noted and was terminated by external electric defibrillation (Figure 2). Two recurrences of VF were observed and immediately reduced by two external electric defibrillations, and the patient was transferred to the catheterization laboratory. Coronary angiography revealed an acute thrombotic occlusion in the LAD DES and an acute thrombotic occlusion in the PDA DES (Figure 3A and C). Coronary flow was rapidly restored by percutaneous coronary intervention (PCI) resulting in two DES implanted in mid-LAD and PDA with a resolution of chest pain and ST-segment elevation (Figure 3B and D, and Videos 1 and 2). No thrombus aspiration was performed according to current ESC guidelines<sup>3</sup> since the vessel was open after guide wire insertion. The patient did not experience VF recurrence after angioplasty. Echocardiography showed large anterior apical and inferior akinesia with a reduced LVEF of 25%. Laboratory tests indicated a decrease in previous inflammatory markers: fibrinogen (3.8 g/L), C-reactive protein (2 mg/L), and D-dimer (630 ng/mL). An increase in platelet count was observed between the first hospitalization for COVID-19 and the admission for OHCA, with a peak  $>400.10^9/L$  (precise count was impossible because of platelet aggregates). Von Willebrand factor activity was very high ( $>480\%$ ), as was von Willebrand factor antigen (361%).

Intravenous antiplatelet therapy was initiated during PCI with canagrelor, replaced by ticagrelor after PCI, whereas aspirin was continued without interruption. During hospitalization, anticoagulant therapy was initiated, initially with unfractionated heparin, then with enoxaparin, and finally with apixaban because of atrial fibrillation onset. Ticagrelor was switched to clopidogrel according to ESC guidelines,<sup>7</sup> since it is not recommended as part of triple antithrombotic therapy with aspirin and oral anticoagulation (class III), and clopidogrel is the P2Y<sub>12</sub> inhibitor of choice. At the time of PCI, adjunctive tirofiban was discussed because of a large thrombus (Class IIa in STEMI ESC guidelines<sup>7</sup>), but finally avoided because of rib fractures during cardiopulmonary resuscitation. At discharge, the antithrombotic regimen was aspirin 75 mg, clopidogrel 75 mg, and apixaban 5 mg bid for 1 month since the patient had equal bleeding (HAS-BLED score = 3) and ischaemic risks (CHA<sub>2</sub>DS<sub>2</sub>-VASc = 3). At 1 month, 24-h ECG monitoring found no recurrence of atrial



**Figure 1** Initial electrocardiogram.



**Figure 2** Electrocardiogram with the first episode of ventricular fibrillation.

fibrillation. Apixaban was stopped. Dual antiplatelet therapy (DAPT) should be continued in the long term according to ESC guidelines.<sup>7</sup>

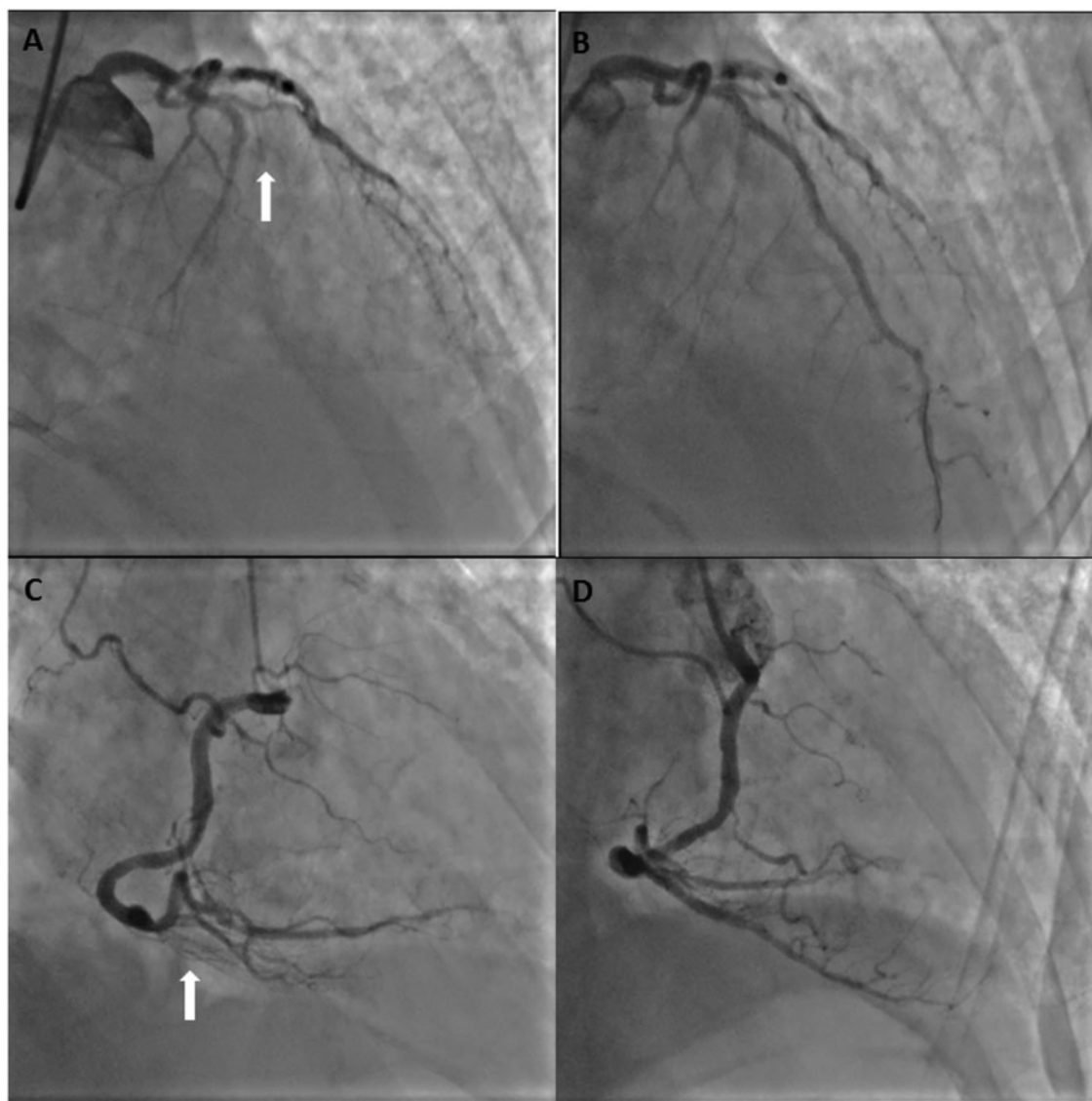
A temporary wearable defibrillator LifeVest (Zoll®, Pittsburgh, PA, USA) was proposed to the patient at discharge for 6 weeks rather than an implantable cardioverter-defibrillator since he had no recurrent VF after revascularization (ESC guidelines, class IIb). Six weeks later, since LVEF was still low (<35%) despite optimal medical therapy, internal cardioverter defibrillator implantation was recommended to the patient (ESC guidelines, class I<sup>7</sup>). The patient did not present any further complications during his hospital stay and was transferred to a cardiac rehabilitation centre. Written informed consent was obtained from the patient.

## Discussion

A sustained prothrombotic state with high prevalence of both venous<sup>2</sup> and arterial thrombotic events<sup>3</sup> has been described during COVID-19. Cytokine storm occurs 5–10 days after the onset of

symptoms, resulting in endothelial injury, activation of the coagulation cascade, and platelet activation. The presence of a coronary stent should be considered as a local stasis factor, which would complete the Virchow triad. Indeed, several cases of stent thrombosis have been reported during the COVID-19 pandemic.<sup>4–6</sup> Even though late stent thrombosis is rare (0.5–1% and 0.2–2% per year),<sup>8</sup> an increased incidence of stent thrombosis was observed in a high-volume centre in Spain.<sup>4</sup> To our knowledge, no dual stent thrombosis during COVID-19 has been reported and dual stent thrombosis is a very rare event. In our monocentre stent thrombosis registry (January 2000 to December 2019), 122 patients presented with stent thrombosis: only one presented with dual stent thrombosis (unpublished data).

In the present case, an increase in inflammatory markers was found initially, at the time of COVID-19 hospitalization. Before the first hospitalization discharge, i.e. 3 days prior to OHCA and myocardial infarction, a decrease in inflammatory markers was observed, whereas platelet count increased greatly with formation of platelet aggregates. At the time of OHCA, no marked inflammatory syndrome was

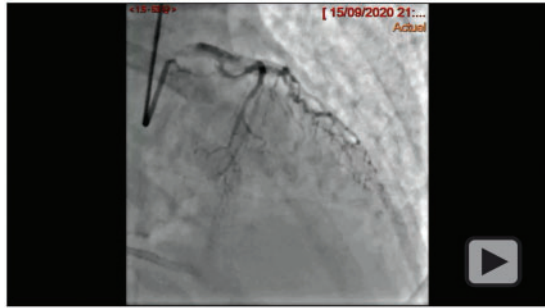


**Figure 3** Coronary angiography. (A) Stent thrombosis of mid-left anterior descending artery. (B) Left anterior descending artery after percutaneous coronary intervention. (C) Stent thrombosis of posterior descending artery. (D) Post-descending artery after percutaneous coronary intervention. White arrows show the sites of stent thrombosis.

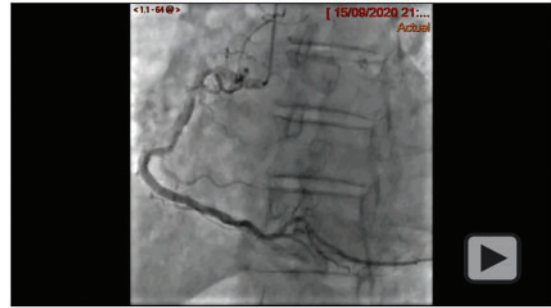found, but von Willebrand factor activity and antigen were increased. Interestingly, even though STEMI may be associated with infections,<sup>9,10</sup> it is not always associated with severe biological sepsis.<sup>11</sup> Data concerning the time required for normalization of the coagulation cascade in COVID-treated patients is not currently available.<sup>12</sup> However, different societies<sup>13</sup> recommend serial monitoring of platelet count, prothrombin time, activated partial thromboplastin time, D-dimer and fibrinogen in hospitalized COVID-19 patients to guide further anticoagulant strategies. The addition of extended antithrombotic treatment at discharge in patients with COVID-19 and previous coronary disease is not currently recommended. Data on the optimal duration and method of anticoagulation for COVID-19 patients post-discharge are currently not available. However, numerous randomized studies are ongoing (e.g. NCT04508439, NCT04372589). Our

case emphasizes the high procoagulant state related to COVID-19 and thus raises the issue of an extended (post-discharge) antithrombotic treatment, which could reduce the risk of ischaemic events, at the cost of increase in bleeding events. Pending specific data on COVID-19, it is reasonable to employ individualized risk stratification for both thrombotic and haemorrhagic risks.

Before OHCA, the patient was on single antiplatelet therapy since it was 2 years after his last PCI for *de novo* angina. According to ESC guidelines on DAPT interruption,<sup>14</sup> in patients with stable CAD who have tolerated DAPT without a bleeding complication and who are at low bleeding but high thrombotic risk, continuation of DAPT with clopidogrel for >6 months and <30 months may be considered.<sup>4</sup> Since the patient had a low bleeding risk (PRECISE-DAPT score = 16) and a high thrombotic risk (age > 65 years, prior spontaneous



**Video 1** Angiogram and percutaneous coronary intervention of the left anterior descending artery.



**Video 2** Angiogram and percutaneous coronary intervention of the posterior descending artery.

acute myocardial infarction and multivessel CAD), DAPT could have been extended up to 30 months (class IIb). However, in the setting of COVID-19, no data on the optimal antiplatelet therapy for COVID-19 patients with previous CAD are currently available.

Other factors such as delayed stent endothelialization with uncovered struts, late stent malapposition, or underexpansion, or neoatherosclerosis plaque rupture may be implicated in stent thrombosis. Here, no intravascular optical coherence tomography was performed, but it seems unlikely that concomitant thrombosis of two stents was due to the stents, but rather to a profoundly prothrombotic state with a significant thrombus burden triggered by COVID-19. We believe that COVID-19 triggered very late dual-stent thrombosis in this patient rather than local stent-related factors, even in the absence of clear evidence. A direct connection between COVID-19 and stent thrombosis cannot be made without being questioned, but there is now bedside evidence for a unique hypercoagulable state in COVID-19 leading to both arterial and venous thrombosis.

## Conclusion

This case emphasizes the high thrombotic risk in COVID-19 patients and suggests that strengthening of antithrombotic therapy in CAD patients presenting with COVID-19 should be discussed.

## Lead author biography



Dr Marie Hauguel-Moreau is an interventional cardiologist and the director of the catheterization laboratory at Ambroise Paré University Hospital (Université Versailles-Saint Quentin) in Boulogne, France. She is researcher at the INSERM U-1018 research unit on cardiovascular epidemiology and member of the ACTION study group, an academic research organization based in Paris, France. Her

research themes cover coronary artery disease, thrombosis, cardiovascular prevention. Dr Hauguel-Moreau received her medical degree from Sorbonne University, Paris VI, and underwent fellowship training at the Pitié-Salpêtrière Hospital, Paris.

## Supplementary material

**Supplementary material** is available at *European Heart Journal - Case Reports* online.

**Slide sets:** A fully edited slide set detailing this case and suitable for local presentation is available online as **Supplementary data**.

**Consent:** The authors confirm that written consent for submission and publication of this case report including images and associated text has been obtained from the patient in line with COPE guidance.

**Conflict of interest:** None declared.

**Funding:** None declared.

## References

1. World Health Organization—COVID-19 situation reports; <https://www.who.int/emergencies/diseases/novel-coronavirus-2019/situation-reports> (5 February 2021).
2. Hauguel-Moreau M, Hajjam ME, De Baynast Q, Vieillard-Baron A, Lot A-S, Chinet T et al. Occurrence of pulmonary embolism related to COVID-19. *J Thromb Thrombolysis* 2020;**6**:1–7.
3. Lodigiani C, Lapichino G, Carenzo L, Cecconi M, Ferrazzi P, Sebastian T, Humanitas COVID-19 Task Force et al. Venous and arterial thromboembolic complications in COVID-19 patients admitted to an academic hospital in Milan, Italy. *Thromb Res* 2020;**191**:9–14.
4. Prieto-Lobato A, Ramos-Martínez R, Vallejo-Calcerrada N, Corbi-Pascual M, Córdoba-Soriano JG. A case series of stent thrombosis during the COVID-19 pandemic. *JACC Case Rep* 2020;**2**:1291–1296.
5. Antuña P, Rivero F, Del Val D, Cuesta J, Alfonso F. Late coronary stent thrombosis in a patient with coronavirus disease 2019. *JAMA Cardiol* 2020;**5**:1195–1198.
6. Hinterseer M, Zens M, Wimmer RJ, Delladio S, Lederle S, Kupatt C et al. Acute myocardial infarction due to coronary stent thrombosis in a symptomatic COVID-19 patient. *Clin Res Cardiol* 2020;**110**:302–306.
7. Ibanez B, James S, Agewall S, Antunes MJ, Bucciarelli-Ducci C, Bueno H et al. 2017 ESC Guidelines for the management of acute myocardial infarction in patients presenting with ST-segment elevation: the Task Force for the management of acute myocardial infarction in patients presenting with ST-segment

- elevation of the European Society of Cardiology (ESC). *European Heart Journal* 2018;**39**:119–177.
8. Gori T, Polimeni A, Indolfi C, Räber L, Adriaenssens T, Münzel T. Predictors of stent thrombosis and their implications for clinical practice. *Nat Rev Cardiol* 2019; **16**:243–256.
  9. Smeeth L, Thomas SL, Hall AJ, Hubbard R, Farrington P, Vallance P. Risk of myocardial infarction and stroke after acute infection or vaccination. *N Engl J Med* 2009;**351**:2611–2618.
  10. Musher DM, Abers MS, Corrales-Medina VF. Acute infection and myocardial infarction. *N Engl J Med* 2019;**380**:171–176.
  11. Corrales-Medina VF, Madjid M, Musher DM. Role of acute infection in triggering acute coronary syndromes. *Lancet Infect Dis* 2010;**10**:83–92.
  12. Abou-Ismaïl MY, Diamond A, Kapoor S, Arafah Y, Nayak L. The hypercoagulable state in COVID-19: incidence, pathophysiology, and management. *Thromb Res* 2020;**194**:101–115.
  13. Thachil J, Tang N, Gando S, Falanga A, Cattaneo M, Levi M et al. ISTH interim guidance on recognition and management of coagulopathy in COVID-19. *J Thromb Haemost* 2020;**18**:1023–1026.
  14. Valgimigli M, Bueno H, Byrne RA, Collet J-P, Costa F, Jeppsson A et al. 2017 ESC focused update on dual antiplatelet therapy in coronary artery disease developed in collaboration with EACTS: the Task Force for dual antiplatelet therapy in coronary artery disease of the European Society of Cardiology (ESC) and of the European Association for Cardio-Thoracic Surgery (EACTS). *Eur Heart J* 2018; **39**:213–260.