



HAL
open science

Mast cell activation syndrome: High frequency of skin manifestations and anaphylactic shock

Eline A. Casassa, Claire Mailhol, Emilie Tournier, Camille Laurent, Yannick Degboe, Marine Eischen, Natalia Kirsten, Jacques Moreau, Solène M. Evrard, Véronique Mansat-de Mas, et al.

► To cite this version:

Eline A. Casassa, Claire Mailhol, Emilie Tournier, Camille Laurent, Yannick Degboe, et al.. Mast cell activation syndrome: High frequency of skin manifestations and anaphylactic shock. *Allergology International*, 2018, 68 (1), pp.119-121. 10.1016/j.alit.2018.07.003 . hal-03284412


HAL Id: hal-03284412

<https://hal.science/hal-03284412>

Submitted on 19 Jul 2021

HAL is a multi-disciplinary open access archive for the deposit and dissemination of scientific research documents, whether they are published or not. The documents may come from teaching and research institutions in France or abroad, or from public or private research centers.

L'archive ouverte pluridisciplinaire **HAL**, est destinée au dépôt et à la diffusion de documents scientifiques de niveau recherche, publiés ou non, émanant des établissements d'enseignement et de recherche français ou étrangers, des laboratoires publics ou privés.



Letter to the Editor

Mast cell activation syndrome: High frequency of skin manifestations and anaphylactic shock

Dear Editor,

Mast cell activation syndrome (MCAS), is associated with mast cell activation-related symptoms involving two or more organs.^{1,2} The disease in patients with MCAS does not fulfill the diagnostic criteria for systemic (SM) or cutaneous mastocytosis.³ There is limited information about the clinical and biological characteristics of MCAS in clinical practice.^{1,2,4} The performance of the proposed diagnostic criteria for MCAS has not been prospectively assessed.^{1,2,4}

Bone marrow tryptase has been shown to be a sensitive diagnostic tool for SM even in patients with normal serum tryptase (ST).⁵

The primary objective of this study was to describe the clinical and paraclinical characteristics of a cohort of patients with primary MCAS. The secondary objective was to describe the usability of the two available sets of diagnostic criteria for MCAS.

We included all consecutive adult patients with a diagnosis of primary MCAS evaluated between April 2011 and May 2015.

The diagnostic of MCAS was established using the diagnostic criteria defined by Valent *et al.* and/or those defined by Molderings *et al.*^{1,2} The presence/absence of a monoclonal mast cell carrying the D816V *KIT* mutation and/or expression of CD25 in bone marrow determined the classification of patients as monoclonal MCAS (MMCAS)/idiopathic MCAS (IMCAS) respectively.¹

The following data were collected: demographic, presented mast cell activation-related symptoms, classification of MCAS, history of anaphylactic shock and bone fracture, general osteoporosis risk factors, and time between first clinical symptoms and MCAS diagnosis. Laboratory values included level of mast cell mediators in blood (tryptase, histamine, serotonin, chromogranin, and heparin), level of bone marrow tryptase, presence of mast cells by immunohistochemical analysis with anti-CD117 antibodies (polyclonal rabbit; Dako Glostrup, Denmark) on bone marrow smear/biopsy and, skin biopsy, molecular, immunophenotypic analysis of bone marrow mast cells and, bone densitometry (Lunar Prodigy, GE Healthcare®, UK).

Software Prism, Version 5.01 (Graphpad, Irvine, CA, USA) was used for statistical analysis.

The diagnosis of MCAS was established in 23 patients: eight (35%) male and 15 (65%) female with a median age of 47 years (IQR: 40–64) at diagnosis time. The median time from first symptoms to diagnosis was 48 months (IQR: 12–168).

Valent *et al.* diagnostic criteria could be fully assessed in nine (39%) patients due to missing information/assessment regarding biological criteria. Molderings *et al.* diagnostic criteria could be fully assessed in 18 (78%) patients. Data are shown in Table 1.

Two (9%) patients had MMCAS defined by the presence of D816V *KIT* mutation and expression of CD25 by bone marrow mast cells, and three (13%) had MMCAS defined only by presence of the expression of CD25.¹ Eighteen (78%) patients had IMCAS and one of these patients was subsequently diagnosed with myelodysplasia.¹

Twenty-two patients (96%) had skin manifestations: 10 (43%) angioedema, 12 (52%) chronic urticaria, 15 (65%) pruritus and 15 (65%) flushing (Fig. 1).

Eleven patients (48%) had a history of idiopathic anaphylactic shock: nine experienced only idiopathic anaphylactic shock and two had an idiopathic and allergic anaphylactic shock. Nineteen patients (83%) presented with gastrointestinal symptoms (diarrhea, vomiting, and/or abdominal pain) and three (13%) with pollakiuria. One patient (4.3%) had a history of seven bone fractures in the absence of osteoporosis risk factor. Data regarding symptoms are summarized in Table 1.

No patient had increased mast cells in bone marrow biopsy as defined by Molderings *et al.* In nine patients (39%) normal mast cells were identified in bone marrow biopsy/smear and for seven patients (30%) the number of mast cells identified in skin was >20/field (x 40).

The median basal serum and bone marrow tryptase level were 5.3 µg/L (IQR: 3.4–7.6) and 7.57 µg/L (IQR: 4.02–10.75) respectively. The median basal serum chromogranin, serotonin and histamine level were 65 µg/L (IQR: 48.5–106) (normal: 27–94), 71 µg/L (IQR: 40.5–148) (normal: 50–300) and 4.3 nmol/L (IQR: 2.4–5.05) (normal < 10) respectively. The median basal plasma heparin level was 0 anti Xa UI/ml (IQR: 0–0.06) (normal < 0.037).

Bone densitometry was abnormal for two patients (8%): one patient (4%) had osteoporosis (hip T score –4.8) and one (4%) had osteopenia (hip T score of –2). The patient with osteoporosis also presented bone fractures. Serum heparin level was increased in this patient, during a crisis of mast cell activation-related symptoms according to the formula defined by Valent *et al.*¹

We show here that the delay in MCAS diagnosis is important (4 years). Skin manifestations (96%) and gastrointestinal symptoms (83%) are very common and non-specific.⁴ The frequency of idiopathic anaphylactic shock (48%) seems more important than those of SM (20%).⁶

The median basal serum and bone marrow tryptase levels are within normal limits even in patients experiencing serious mast

Table 1
Diagnostic criteria, MCAS classification, skin and systemic mast cell activation-related symptoms presented by our patients.

Patient	Age at first symptom	Gender	Valent <i>et al.</i> diagnostic criteria	Molderings <i>et al.</i> diagnostic criteria	Skin involvement (N = 21)	Anaphylactic shock (N = 11)	Others vascular symptoms (N = 8)	Gastrointestinal symptoms (N = 19)	Urinary tract symptoms (N = 3)	Respiratory symptoms (N = 2)	Response to symptomatic treatment (N = 23)
#1	45	Women	UK	Yes (IIa + IVb [chromogranine [†]])	Yes (SU, A, F, P)	Yes	Yes	Yes	No	No	Yes
#2 [‡]	27	Women	UK	Yes (IIa + IIb)	Yes (SU, F, P)	No	No	Yes	No	No	Yes
#3	19	Women	Yes (chromogranine)	No (IIa)	Yes (SU, A, F)	No	No	Yes	No	No	Yes
#4	58	Men	Yes (heparine)	No (IIa)	Yes (SU, P)	Yes	No	Yes	No	No	Yes
#5	30	Women	UK	Yes (IIa + IVb [chromogranine])	Yes (SU, A, F)	Yes	Yes	Yes	No	No	Yes
#6	69	Women	UK	Yes (IIa + IVb [tryptase])	Yes (P)	No	No	Yes	No	No	Yes
#7 [†]	60	Women	UK	Yes (IIa + IIb + IIIb)	Yes (SU, F, P)	No	No	Yes	Yes	No	Yes
#8	51	Men	Yes (tryptase + chromogranine)	Yes (IIa + IVb [chromogranine])	Yes (A, F)	Yes	No	Yes	No	No	Yes
#9	6	Men	Yes (histamine)	No (IIa)	Yes (A, F, P)	Yes	No	Yes	Yes	No	Yes
#10	52	Men	Yes (chromogranine)	No (IIa)	Yes (SU, A)	No	No	Yes	No	No	Yes
#11	17	Men	UK	Yes (IIa + IVb [tryptase])	Yes (A, F, P)	Yes	No	Yes	No	No	Yes
#12	27	Women	UK	Yes (IIa + IVb [chromogranine [†]])	Yes (SU, F, P)	Yes	Yes	Yes	No	No	Yes
#13	40	Men	UK	Yes (IIa + IVb [chromogranine tryptase])	Yes (F, P)	No	Yes	Yes	No	No	Yes
#14	53	Women	UK	Yes (IIa + IVb [chromogranine])	Yes (F, P)	No	Yes	No	No	No	Yes
#15	49	Men	Yes (serotonin + chromogranine)	Yes (IIa + IVb [chromogranine [†]])	Yes (P)	No	Yes	Yes	No	No	Yes
#16	50	Women	Yes (Serotonin)	No (IIa)	Yes (SU, A, P)	Yes	No	Yes	No	No	Yes
#17 [†]	46	Women	UK	Yes (IIa + IIb)	Yes (SU, F, P)	No	No	No	No	Yes	Yes
#18	60	Men	Yes (chromogranine)	Yes (IIa + Ib)	Yes (SU, A, P)	No	Yes	No	No	No	Yes
#19	46	Women	UK	Yes (IIa + IVb [heparine])	Yes (F)	Yes	No	Yes	No	No	Yes
#20	17	Women	UK	Yes (IIa + IVb [chromogranine])	Yes (SU, A, P)	Yes	Yes	Yes	Yes	Yes	Yes
#21 [†]	45	Women	UK	Yes (IIa + Ib + IIb + IIIb)	Yes (F, P)	No	No	Yes	No	No	Yes
#22	35	Women	Yes (serotonin)	Yes (IIa + IVb [heparine])	Yes (F)	No	No	Yes	No	No	Yes
#23 [†]	53	Women	UK	Yes (IIa + IIb)	No	Yes	No	No	No	No	Yes

Diagnostic Criteria of MCAS:

Yes: diagnostic criteria fullfield; No: diagnostic criteria examined and not fullfield; UK: unknown: could not be assessed.

Valent *et al.* diagnostic criteria:

Yes: presence of all the following criteria: (I). Typical symptoms of several recurrent and/or chronic systemic mast cell activation symptoms; (II). involvement of mast cells, documented by an increase of mast cell marker(s) in the blood during a crisis or within 4 h following a symptomatic period, according to the formula: basic level of mast cell marker + 20% + 2 µg/L (tryptase, serotonin, histamine, chromogranine, heparine); (III). a major response of typical clinical symptoms to antimediator-type pharmacological agents; (IV). absence of SM or cutaneous mastocytosis; and absence of other diagnoses that could explain the symptoms.

Molderings *et al.* diagnostic criteria:

Yes: presence of 2 major criteria or the second major criterion and at least one minor criterion, and absence of SM or cutaneous mastocytosis, of other diagnoses that could explain the symptoms. The major criteria are: (IA) the presence of multifocal or disseminated infiltrates of mast cells in bone marrow biopsies or in sections of other extra cutaneous organ(s), and (IIA) unique constellation of clinical complains as a result of a pathologically increased mast cell activity (mast cell mediator release symptom). The minor criteria are (Ib) presence of mast cell in bone marrow (bone marrow smears or bone marrow histology) or other extracutaneous organs show an abnormal morphology (>25%); (IIb) presence of mast cells in bone marrow expressing CD2 and/or CD25; (IIIb) detection of genetic changes in mast cells from blood, bone marrow or extra cutaneous organs for which an impact on the state of activity of affected mast cells in terms of increased activity has been proven; (IVb) evidence of a pathologically increase of mast cell mediators by dosage of tryptase in blood, heparin in blood, chromogranin A in blood, other mast cell specific mediators in blood and/or N-methylhistamine in urine. We performed only mediator in blood: tryptase, heparin, chromogranin A and serotonin.

Skin involvement:

SU, superficial urticaria; A, angioedema; F, Flushing; P, pruritus.

[†] Monoclonal mast cell activation syndrome.

[‡] Increased basal serum chromogranin level in patients under proton pompe inhibitor treatment.

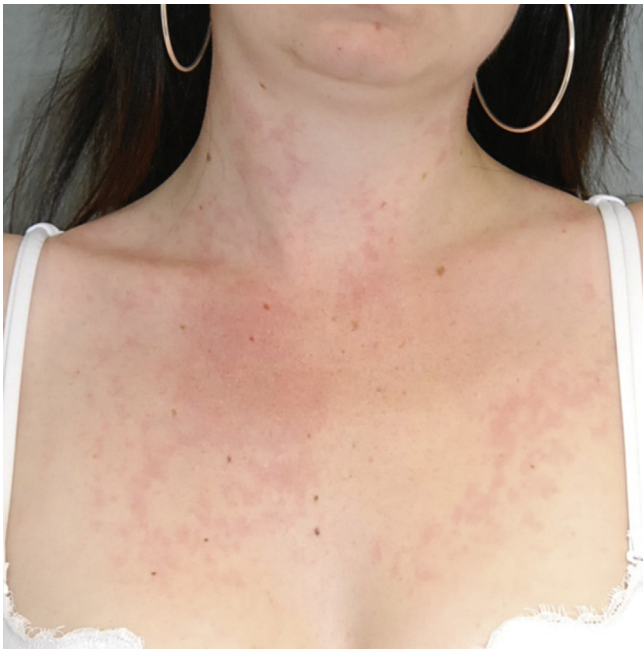

Fig. 1. Flushing in a patient with IMCAS.

cell activation-related symptoms showing the limited utility of these parameters to establish MCAS diagnosis.^{4,5}

Bone involvement seems to be present (8%) in primary MCAS patient. Currently, the biological rationale for bone involvement in MCAS is unknown. Presumably, heparin and histamine released by mast cells may promote osteoporosis leading to bone fracture.^{7,8}

The five (22%) patients with MMCAS, having one or two minor criteria of SM could be classified as pre-SM according to Pardanani.⁹

Analysis of the usability of the available diagnostic criteria for MCAS shows that both diagnostic criteria have good sensitivity. However, some laboratory investigations proposed as criteria are not easily performed in practice. For example, the measurement of N-methylhistamine in urine could not be assessed in all centers. Increase in chromogranin A is difficult to interpret in patients taking proton pump inhibitors (3/23 patients).¹⁰ For patients experiencing anaphylactic shock, stopping treatment to assess mast cell markers during a crisis is difficult.⁴ The current diagnostic criteria for MCAS should be harmonized and prospectively validated to adequately identify patients with MCAS.

In conclusion MCAS is characterized by a high frequency of skin manifestations. MCAS diagnosis is delayed by a mean of four years. There is a need to harmonize MCAS diagnostic criteria to promote earlier disease detection.

Conflict of interest

The authors have no conflict of interest to declare.

Elaine A. Casassa^a, Claire Mailhol^b, Emilie Tournier^c, Camille Laurent^c, Yannick Degboe^d, Marine Eischen^d, Natalia Kirsten^a, Jacques Moreau^e, Solène M. Evrard^c, Véronique Mansat-De Mas^f, Laurence Lamant^c, Patrice Dubreuil^g, Pol André Apoil^h, Olivier Hermineⁱ, Carle Paul^a, Cristinai Bulai Livideanu^{a,*}

^a Mastocytosis National Reference Center (CEREMAST), Department of Dermatology, Toulouse University Hospital, Paul Sabatier University, Toulouse, France

^b Mastocytosis National Reference Center (CEREMAST), Department of Pneumo-Allergology, Toulouse University Hospital, Paul Sabatier University, Toulouse, France

^c Mastocytosis National Reference Center (CEREMAST), Department of Pathology, Institut Universitaire du Cancer, Oncopole, University of Toulouse III Paul Sabatier, Toulouse, France

^d Mastocytosis National Reference Center (CEREMAST), Department of Rheumatology, Toulouse University Hospital, Paul Sabatier University, Toulouse, France

^e Mastocytosis National Reference Center (CEREMAST), Department of Gastro-Enterology, Toulouse University Hospital, Paul Sabatier University, Toulouse, France

^f Mastocytosis National Reference Center (CEREMAST), Department of Haematology, Toulouse University Hospital, Paul Sabatier University, Toulouse, France

^g CRCM [Signaling, Hematopoiesis and Mechanism of Oncogenesis], Inserm, U1068, Institut Paoli-Calmettes, Université Aix-Marseille, UM105, CNRS, UMR7258, Marseille, France

^h Mastocytosis National Reference Center (CEREMAST), Department of Immunology, Toulouse University Hospital, Paul Sabatier University, Toulouse, France

ⁱ Department of Hematology, Mastocytosis National Reference Center (CEREMAST), Necker Hospital, Paris-APH, Paris, France

* Corresponding author.

E-mail address: livideanu.c@chu-toulouse.fr (C. Bulai Livideanu).

References

- Valent P, Akin C, Arock M, Brockow K, Butterfield JH, Carter MC, et al. Definitions, criteria and global classification of mast cell disorders with special reference to mast cell activation syndromes: a consensus proposal. *Int Arch Allergy Immunol* 2012;**157**:215–25.
- Molderings GJ, Brettner S, Homann J, Afrin LB. Mast cell activation disease: a concise practical guide for diagnostic workup and therapeutic options. *J Hematol Oncol* 2011;**4**:10.
- Gülen T, Hägglund H, Sander B, Dahlén B, Nilsson G. The presence of mast cell clonality in patients with unexplained anaphylaxis. *Clin Exp Allergy J Br Soc Allergy Clin Immunol* 2014;**44**:1179–87.
- Afrin LB, Self S, Menk J, Lazarchick J. Characterization of mast cell activation syndrome. *Am J Med Sci* 2017;**353**:207–15.
- Bulai Livideanu C, Apoil PA, Lepage B, Eischen M, Laurent C, Laharrague P, et al. Bone marrow tryptase as a possible diagnostic criterion for adult systemic mastocytosis. *Clin Exp Allergy* 2016;**46**:133–41.
- Wimazal F, Geissler P, Shnawa P, Sperr WR, Valent P. Severe life-threatening or disabling anaphylaxis in patients with systemic mastocytosis: a single-center experience. *Int Arch Allergy Immunol* 2012;**157**:399–405.
- Biosse-Duplan M, Barouk B, Dy M, de Vernejoul M-C, Saffar J-L. Histamine promotes osteoclastogenesis through the differential expression of histamine receptors on osteoclasts and osteoblasts. *Am J Pathol* 2009;**174**:1426–34.
- Vysniauskaite M, Hertfelder H-J, Oldenburg J, Dreßen P, Brettner S, Homann J, et al. Determination of plasma heparin level improves identification of systemic mast cell activation disease. *PLoS One* 2015;**10**:e0124912.
- Pardanani A. Systemic mastocytosis in adults: 2017 update on diagnosis, risk stratification and management. *Am J Hematol* 2016;**91**:1146–59.
- Mosli HH, Dennis A, Kocha W, Asher LJ, Van Uum SHM. Effect of short-term proton pump inhibitor treatment and its discontinuation on chromogranin A in healthy subjects. *J Clin Endocrinol Metab* 2012;**97**:1731–5.

Received 19 June 2018

Received in revised form 4 July 2018

Accepted 15 July 2018

Available online 7 August 2018