



Theranostic AGuIX nanoparticles as radiosensitizer: A phase I, dose-escalation study in patients with multiple brain metastases (NANO-RAD trial)

Camille Verry, Sandrine Dufort, Julie Villa, Marylaure Gavard, Carole Iriart, Sylvie Grand, Julie Charles, Benoit Chovelon, Jean-Luc Cracowski, Jean-Louis Quesada, et al.

► To cite this version:

Camille Verry, Sandrine Dufort, Julie Villa, Marylaure Gavard, Carole Iriart, et al.. Theranostic AGuIX nanoparticles as radiosensitizer: A phase I, dose-escalation study in patients with multiple brain metastases (NANO-RAD trial). *Radiotherapy & Oncology*, 2021, 160, pp.159-165. 10.1016/j.radonc.2021.04.021 . hal-03283692

HAL Id: hal-03283692

<https://hal.science/hal-03283692>

Submitted on 6 Sep 2021

HAL is a multi-disciplinary open access archive for the deposit and dissemination of scientific research documents, whether they are published or not. The documents may come from teaching and research institutions in France or abroad, or from public or private research centers.

L'archive ouverte pluridisciplinaire **HAL**, est destinée au dépôt et à la diffusion de documents scientifiques de niveau recherche, publiés ou non, émanant des établissements d'enseignement et de recherche français ou étrangers, des laboratoires publics ou privés.



Original Article

Theranostic AGuIX nanoparticles as radiosensitizer: A phase I, dose-escalation study in patients with multiple brain metastases (NANO-RAD trial)



Camille Verry^{a,b,*}, Sandrine Dufort^c, Julie Villa^a, Marylaure Gavard^d, Carole Iriart^a, Sylvie Grand^e, Julie Charles^f, Benoit Chovelon^g, Jean-Luc Cracowski^h, Jean-Louis Quesada^h, Christophe Mendoza^h, Lucie Sanceyⁱ, Audrey Lehmann^j, Florence Jover^a, Jean-Yves Giraud^a, François Luxⁱ, Yannick Crémillieux^{c,k}, Stephen McMahon^l, Petrus J. Pauwels^m, Daniel Cagneyⁿ, Ross Berbecoⁿ, Ayal Aizerⁿ, Eric Deutsch^o, Markus Loeffler^c, Géraldine Le Duc^c, Olivier Tillementⁱ, Jacques Balosso^a

^a Radiotherapy Department, Grenoble Alps University Hospital; ^b INSERM UA7, University of Grenoble Alps, Synchrotron Radiation for Biomedical Research (ESRF), Grenoble; ^c NH TherAguix SA, Meylan; ^d Clinical Research Vigilance; ^e Neuroradiology Department; ^f Dermatology Department; ^g Unit of Hormonal and Nutritional Biochemistry, Institute of Biology and Pathology; ^h Clinical Investigation Center, Grenoble Alps University Hospital, Grenoble; ⁱ Institute Light and Matter, UMR5306, Lyon1 University-CNRS, Lyon University, Villeurbanne; ^j Pharmacy Department, Grenoble Alps University Hospital, Grenoble; ^k Institut des Sciences Moléculaires, UMR5255, Université de Bordeaux, France; ^l Center for Cancer Research and Cell Biology, Queen's University Belfast, United Kingdom; ^m Dap-Santé Consulting, Dolomieu, France; ⁿ Department of Radiation Oncology, Brigham and Women's Hospital, Dana-Farber Cancer Institute and Harvard Medical School, Boston, USA; ^o Radiation Oncology Department, INSERM1030 Molecular Radiotherapy and Therapeutic Innovations, Paris-Saclay University, Gustave Roussy, Villejuif, France

ARTICLE INFO

Article history:

Received 9 February 2021
Received in revised form 9 April 2021
Accepted 28 April 2021
Available online 5 May 2021

Keywords:

Nanoparticles
Radiosensitization
Brain metastases
AGuIX
Theranostic

ABSTRACT

Background and purpose: Brain metastasis impacts greatly on patients' quality of life and survival. The phase I NANO-RAD trial assessed the safety and maximum tolerated dose of systemic administration of a novel gadolinium-based nanoparticle, AGuIX, in combination with whole brain radiotherapy in patients with multiple brain metastases not suitable for stereotactic radiotherapy.

Materials and methods: Patients with measurable brain metastases received escalating doses of AGuIX nanoparticles (15, 30, 50, 75, or 100 mg/kg intravenously) on the day of initiation of WBRT (30 Gy in 10 fractions) in 5 cohorts of 3 patients each. Toxicity was assessed using NCI Common Terminology Criteria for Adverse Events v4.03.

Results: Fifteen patients with 354 metastases were included. No dose-limiting toxic effects were observed up to AGuIX 100 mg/kg. Plasma elimination half-life of AGuIX was similar for all groups (mean 1.3 h; range 0.8–3 h). Efficient targeting of metastases (T₁ MRI enhancement, tumor selectivity) and persistence of AGuIX contrast enhancement were observed in metastases from patients with primary melanoma, lung, breast, and colon cancers. The concentration of AGuIX in metastases after administration was proportional to the injected dose. Thirteen of 14 evaluable patients had a clinical benefit, with either stabilization or reduction of tumor volume. MRI analysis showed significant correlation between contrast enhancement and tumor response, thus supporting a radiosensitizing effect.

Conclusion: Combining AGuIX with radiotherapy for patients with brain metastases is safe and feasible. AGuIX specifically targets brain metastases and is retained within tumors for up to 1 week; ongoing phase II studies will more definitively assess efficacy.

© 2021 The Author(s). Published by Elsevier B.V. Radiotherapy and Oncology 160 (2021) 159–165 This is an open access article under the CC BY-NC-ND license (<http://creativecommons.org/licenses/by-nc-nd/4.0/>).

External radiotherapy is one of the main treatment in neuro oncology due to difficulty of surgery and uncertain distribution of systemic therapy. Despite advances in cancer treatments, however, no curative approaches exist for patients with multiple brain metastases. The use of radiation sensitizers would therefore be of

great interest specifically in increasing the effects of RT in tumors while sparing surrounding healthy tissues as RT dose-escalation can significantly improve local tumor control and survival [1,2]. Radiosensitization is an effective means of increasing local tumor control and limiting RT toxicity [3]. An ideal radiosensitizer is an agent (eg, molecule, drug, nanoparticle) that preferentially sensitizes tumor cells to RT, increasing the therapeutic window in

* Corresponding author at: Radiotherapy Department, Grenoble Alps University Hospital, BP217, F38043 Grenoble Cedex 9, France.

E-mail address: cverry@chu-grenoble.fr (C. Verry).

which radiation doses are effective enough to eradicate the tumor while preserving normal tissue.

Development of novel nanoparticles is a promising area that offers opportunities for improved diagnosis and treatment of cancer. Among the nanoparticles known to be radiosensitizers, those with high-Z elements (eg, gadolinium, hafnium, gold, and silver) can interact with X-rays through various mechanisms, including the production of photoelectric Compton and Auger electrons, which in turn produces further secondary electrons. Localized energy deposits in the vicinity of high-Z atoms result in enhanced killing effects of X-rays on cells [4–7]. Consequently, the differential effects of radiation on healthy tissue and tumors are improved, provided that the nanoparticles concentrate primarily in tumors.

AGuIX (Activation and Guidance of Irradiation by X-ray) is a 5 nm nanoparticle based on a polysiloxane network surrounded by gadolinium chelates [8]. AGuIX is a theranostic agent that functions as a magnetic resonance imaging (MRI) contrast and a radiosensitizer. Each nanoparticle has on its surface an average of 10 dodecane tetraacetic acid ligands capable of chelating core gadolinium ions. AGuIX can penetrate tumors after systemic administration due to the enhanced permeability and retention effect of altered blood vessels within the tumor stroma and lack of effective lymphatic drainage within tumor tissues [9]. Preclinical studies in various tumor models, including brain tumors, showed that low concentrations of AGuIX were non-toxic radiosensitizers with a significant therapeutic effect [10–13].

Brain metastasis is a common event in the clinical course of many cancers that has a dramatic effect on life expectancy. For patients ineligible for a stereotactic approach, whole brain RT (WBRT) is an effective treatment option [14], although radiation doses are limited by the sensitivity of healthy brain tissue. Consequently, this approach is generally associated with a median overall survival (OS) of ≤ 6 months [15,16]. New approaches are therefore needed to improve outcomes in these patients and the clinical use of radiosensitizers is of great interest.

Thus, a phase III clinical trial has demonstrated that the use of motexafin gadolinium in combination with prompt WBRT prolongs time to neurologic progression in non-small-cell-lung cancer patients with brain metastases but without impact on the overall survival [17]. Motexafin gadolinium sensitizes cells through oxidative stress caused by redox cycling, leading to an enhanced radiation response, and seems to be less significantly modulated by the high atomic number of gadolinium and the associated physical dose enhancement.

The first-in-human phase I NANO-RAD study of AGuIX nanoparticles was undertaken in patients with multiple brain metastases from melanoma, lung, breast, or colon cancer. This patient cohort was chosen not only to investigate contrast enhancement in multiple brain metastases in different types of primary cancers, but also to assess the evolution of a large number of metastases in a limited number of patients. Patients received WBRT of 30 Gy in 10 daily sessions over 2 weeks; AGuIX was administered intravenously 4 h before the first WBRT session. The study aimed to investigate the safety and pharmacokinetics of this regimen. As gadolinium (Gd) is a positive T_1 contrast agent, an MRI protocol was established to evaluate drug distribution in brain metastases and surrounding healthy tissues. Intracranial progression-free survival (PFS) and OS were also assessed.

Materials and methods

Study design and patient selection

This prospective phase Ib dose-escalation clinical trial evaluated the tolerability of intravenous administration of radiosensitizing AGuIX nanoparticles plus WBRT for patients with multiple brain

metastases (ClinicalTrials.gov identifier: NCT02820454). This investigator-initiated trial was sponsored by the Grenoble Alps University Hospital (France) and performed in its Radiotherapy department. Approval was obtained from the French National Agency for Safety of Medicines and Health Products (EudraCT 2015-004259-30) in May 2016. Detailed trial information has been published previously [18]. Patients with multiple brain metastases not eligible for surgery or stereotactic radiation were recruited. Patients were aged ≥ 18 years, with secondary brain metastases from pathologically confirmed solid tumors, no prior brain irradiation, normal liver function, and no renal failure (clearance > 60 mL/min/1.73 m²). The main exclusion criteria were leptomeningeal carcinomatosis; life-threatening extracranial disease; previous brain irradiation (other than stereotactic irradiation); contraindication, sensitivity, or allergy to Gd; and inability to undergo or tolerate MRI. All patients provided written informed consent as legally required.

Procedures

At inclusion (Day 0), patients underwent baseline MRI with a bolus injection of gadoterate meglumine (Dotarem®; 0.2 mL/kg [0.1 mmol/kg] body weight). On Day 1, patients received a single intravenous injection of AGuIX nanoparticles (15, 30, 50, 75, or 100 mg/kg body weight), followed by MRI (2 h after injection) and their first RT session (4 h after injection). The longitudinal relaxivity r_1 at 3 T is equal to 8.9 mM⁻¹s⁻¹ per Gd³⁺ ion, resulting in a total r_1 of 89 mM⁻¹s⁻¹ per AGuIX nanoparticle. Further MRI sessions were performed on Day 8 (without gadoterate meglumine), Day 28 (with gadoterate meglumine), at 3 months, and every 3 months thereafter (with gadoterate meglumine) up to 12 months (Appendix Fig A1). Plasma and urinary Gd concentrations were analyzed using a validated inductively coupled plasma-mass spectrometry method (X Serie II, Thermo Electron, Bremen, Germany). The study was performed in accordance with the Helsinki Declaration (modified in Fortaleza in 2013), Good Clinical Practice (International Conference on Harmonisation E6), and local regulations.

MRI protocol

A 3T Achieva MR scanner (Philips Healthcare, Netherlands) was used, with a 32-channel Philips head coil. All patients underwent an identical imaging protocol, including 3-dimensional T_1 -weighted gradient echo sequence, 3-dimensional fast low-angle shot (FLASH) sequence with multiple flip angles, susceptibility-weighted imaging sequence, fluid-attenuated inversion recovery sequence, and diffusion-weighted imaging sequence. The total acquisition time was 30–40 min.

Image processing and quantification

MRI analyses were performed using in-house software (MP³; <https://github.com/nifm-gin/MP3>) developed by the GIN Laboratory (Grenoble, France) and running under Matlab® (MathWorks, Natick, MA, USA). Image analyses included counting and measuring of all individual metastases, and quantification of contrast enhancement, relaxation times, and nanoparticle concentrations. MRI enhancement was defined as the ratio of the MRI signal amplitude post-contrast agent administration to pre-contrast agent administration; signal amplitudes were measured in the 3-dimensional T_1 -weighted image dataset. T_1 relaxation times were derived from 3-dimensional FLASH images obtained at 4 different flip angles. The concentration of nanoparticles in brain metastases was derived from variations of T_1 relaxation times pre- and post-nanoparticle administration and their known relaxivity. Three-

dimensional images were generated using BrainVISA/Anatomist software (<http://brainvisa.info>) developed at NeuroSpin (Saclay, France). Intracranial PFS was defined according to RECIST (version 1.1) [19].

Outcomes

The primary outcome was determination of the maximum tolerated dose (MTD) of AGuIX combined with WBRT by determining the incidence of dose-limiting toxicities (DLTs) graded using Common Terminology Criteria for Adverse Events (version 4.03). DLT was defined as any grade 3 event persisting 15 days or any grade 4 AGuIX-related event.

Secondary outcomes were pharmacokinetics of AGuIX obtained by measuring Gd content in blood and urinary samples; distribution of AGuIX in metastases and surrounding brain tissue studied by MRI; intracranial PFS assessed by MRI at 1, 3, 6, 9, and 12 months; and OS assessed from initiation of treatment (Day 1).

Statistical analysis

Analyses were performed using SAS software (version 9.4; SAS Institute Inc., Cary, NC) for baseline descriptions, and primary and secondary endpoints. Pharmacokinetics and MRI evaluation of AGuIX distribution in brain metastases were performed using WinNonLin Professional (version 6.4.0.768; Pharsight, Mountain View, CA) and Prism (version 5.01; GraphPad software, San Diego, CA), respectively. Unless specified, significance was fixed at $P < 0.05$. Data are presented as mean value \pm standard deviation (SD). A final statistical analysis plan was finalized on June 5, 2019, before database freeze. Safety (adverse events [AEs] and serious AEs [SAEs]) was evaluated using Medical Dictionary for Regulatory Activities coding (version 22.0) and evaluating severity, intensity, imputability, and outcome. Survival analyses were performed using the Kaplan-Meier method.

Results

Between July 4th, 2016 and February 22nd, 2018, 15 patients with primary non-small cell lung cancer (NSCLC; $n = 6$), melanoma ($n = 6$), breast ($n = 2$), and colon tumors ($n = 1$) were included; all had brain metastases (range 4–50). Patient characteristics are summarized in Table 1.

No DLTs occurred according to the Data Safety Monitoring Board; consequently, the MTD was not determined. AEs are summarized in Tables 2 and 3. All patients receiving AGuIX 15, 30, and 50 mg/kg, and 2 of 3 patients receiving AGuIX 75 and 100 mg/kg experienced 29 SAEs. Most were related to brain metastases, primary tumor progression, or other systemic treatment. Four SAEs were considered possibly related to AGuIX: these were delayed effects of radiation, possibly enhanced by the experimental drug.

Ten patients died during study follow-up, including all patients receiving AGuIX 15 and 30 mg/kg, 2 receiving 50 mg/kg, and 1 each in the 75 and 100 mg/kg cohorts. Nine deaths were considered unrelated to experimental treatment. Preferred terms used for deaths were: disease progression ($n = 3$), neoplasm progression ($n = 1$), sepsis ($n = 1$), cardiac death ($n = 1$; patient died prematurely at Day 9 due to heart attack; patient had cardiovascular comorbidities and obesity), malignant neoplasm progression ($n = 2$), intracranial pressure increased ($n = 1$), and general physical health deterioration ($n = 1$) in a patient whose death may have been related to disease progression and the experimental treatment (radiation-induced leukoencephalopathy).

Seventy-one non-serious AEs occurred; 54 were considered unrelated to the experimental drug by the investigator, 10 were

Table 1

Demographic and Clinical Characteristics of Patients With Multiple Brain Metastases Included in the NANO-RAD Trial.

Characteristic n (%)	All patients (n = 15)
Sex	
Male	10 (66.7)
Female	5 (33.3)
Median age (range), years	61 (37–79)
ECOG performance status	
0/1	9 (60.0)
2	5 (33.3)
3	1 (6.7)
Recursive partitioning analysis class	
I	1 (6.7)
II	6 (40.0)
III	8 (53.3)
Number of brain metastases	
<4	0
4–10	4 (26.7)
>10	11 (73.3)
Primary tumor type	
Lung cancer	6 (40.0)
Melanoma	6 (40.0)
Breast cancer	2 (13.3)
Colon cancer	1 (6.7)
Previous treatment for brain metastases	
Surgery	3 (20.0)
Stereotactic radiotherapy	1 (6.7)
Previous chemotherapy lines	
None	1 (6.7)
1–2	13 (86.7)
3–4	1 (6.7)
Corticoid treatment at inclusion	
No	4 (26.7)
Yes	11 (73.3)
Neurologic status at inclusion	
Asymptomatic	10 (66.7)
Symptomatic	5 (33.3)

considered unlikely related to AGuIX, and 7 were probably related to AGuIX. Nervous system disorders were the most common non-serious AEs (25 events in 9 patients).

No AEs were reported at injection sites and no systemic or allergic reactions after AGuIX injection were observed. No grade ≥ 2 kidney or liver function toxicity occurred.

AGuIX maximum plasma concentration and area under the plasma concentration versus time curve increased linearly with AGuIX dose (15–100 mg/kg). Plasma elimination half-life (elimination rate constant) of AGuIX was similar for all doses (mean 1.3 h; range 0.8–3 h). The distribution phase was fast ($T_{1/2}$ ranges: α 0.21–1.41 h, β 2.4–70 h). Mean AGuIX clearance and volume of distribution at steady state were approximately 0.12 (range 0.76–0.16) L/h/kg and 0.42 (range 0.23–1.19) L/kg, respectively (Appendix Fig. A2, Appendix Table A1).

Urinary AGuIX elimination was fitted to a non-compartmental model. Peak excretion rate increased more than linearly with dose ($\times 2$, $\times 4$, $\times 8$, and $\times 9$ for 30, 50, 75, and 100 mg/kg groups, respectively, v 15 mg/kg group). The maximum excretion rate occurred during 0–4 h except for 2 patients in the 50 mg/kg group (4–8 h). Mean urinary excretion of AGuIX was 54% during the first 24 h (range 18–83%; Appendix Table A2).

All measurable brain metastases showed AGuIX enhancement on MRI, regardless of primary tumor, patient, and AGuIX dose. The mean MRI signal enhancement in metastases correlated linearly with injected AGuIX dose. Fig. 1 shows tumor signal enhancements in 2 patients with NSCLC following administration of AGuIX 15 and 100 mg/kg. For the 3 patients receiving AGuIX 100 mg/kg, mean \pm SD AGuIX concentrations in metastases were 57.5 ± 14.3 , 20.3 ± 6.8 , and 29.5 ± 12.5 mg/L. Persistence of MRI signal enhancement was systematically observed in metastases in all patients at

Table 2

Acute Adverse Events in Patients With Multiple Brain Metastases Included in the NANO-RAD Trial.

Adverse Event, n (%)	Grades 1/2	Grade 3	Grade 4
<i>In-field radiation (intracranial) adverse events</i>			
Headache	6 (40.0)	0 (0.0)	0 (0.0)
Nausea	5 (33.3)	0 (0.0)	0 (0.0)
Intracranial pressure increased	3 (20.0)	1 (6.7)	0 (0.0)
Paresthesia	3 (20.0)	0 (0.0)	0 (0.0)
Confusional state	3 (20.0)	0 (0.0)	0 (0.0)
Vomiting	2 (13.3)	0 (0.0)	0 (0.0)
Aphasia	1 (6.7)	0 (0.0)	0 (0.0)
Cognitive disorder	1 (6.7)	0 (0.0)	0 (0.0)
Dysmetria	1 (6.7)	0 (0.0)	0 (0.0)
Epilepsy	1 (6.7)	0 (0.0)	0 (0.0)
Hemiplegia	1 (6.7)	0 (0.0)	0 (0.0)
Memory impairment	1 (6.7)	0 (0.0)	0 (0.0)
Parosmia	1 (6.7)	0 (0.0)	0 (0.0)
Partial seizures	0 (0.0)	1 (6.7)	0 (0.0)
Psychomotor skills impaired	1 (6.7)	0 (0.0)	0 (0.0)
Reading disorder	1 (6.7)	0 (0.0)	0 (0.0)
Blindness	0 (0.0)	1 (6.7)	0 (0.0)
Gait disturbance	1 (6.7)	0 (0.0)	0 (0.0)
<i>Out-field radiation (extracranial) adverse events</i>			
Asthenia	4 (26.7)	0 (0.0)	0 (0.0)
Dermatitis	3 (20.0)	0 (0.0)	0 (0.0)
Disease progression	2 (13.3)	1 (6.7)	0 (0.0)
Thrombocytopenia	2 (13.3)	0 (0.0)	0 (0.0)
Pulmonary embolism	1 (6.7)	1 (6.7)	0 (0.0)
Constipation	2 (13.3)	0 (0.0)	0 (0.0)
Anemia	1 (6.7)	0 (0.0)	0 (0.0)
Supraventricular extrasystoles	1 (6.7)	0 (0.0)	0 (0.0)
Hypoacusis	1 (6.7)	0 (0.0)	0 (0.0)
Vertigo	1 (6.7)	0 (0.0)	0 (0.0)
Hypothyroidism	1 (6.7)	0 (0.0)	0 (0.0)
Esophagitis	0 (0.0)	1 (6.7)	0 (0.0)
Malaise	1 (6.7)	0 (0.0)	0 (0.0)
Pain	1 (6.7)	0 (0.0)	0 (0.0)
Pyrexia	1 (6.7)	0 (0.0)	0 (0.0)
Sepsis	0 (0.0)	0 (0.0)	1 (6.7)
Hypoglycemia	1 (6.7)	0 (0.0)	0 (0.0)
Musculoskeletal pain	1 (6.7)	0 (0.0)	0 (0.0)
Malignant neoplasm progression	1 (6.7)	0 (0.0)	0 (0.0)
Alopecia	1 (6.7)	0 (0.0)	0 (0.0)
Livedo reticularis	1 (6.7)	0 (0.0)	0 (0.0)

Table 3Late Adverse Events (Occurring ≥ 3 Months After Treatment) in Patients With Multiple Brain Metastases Included in the NANO-RAD Trial.

Adverse Event, n (%)	Grades 1/2	Grade 3	Grade 4
<i>In-field radiation (intracranial) adverse events</i>			
Nausea	2 (13.3)	0	0
Confusional state	1 (6.7)	2 (13.6)	0
Cerebellar syndrome	1 (6.7)	0	0
Leukoencephalopathy	0	1 (6.7)	0
Headache	1 (6.7)	0	0
Balance disorder	1 (6.7)	0	0
Disturbance in attention	1 (6.7)	0	0
Vomiting	1 (6.7)	0	0
<i>Out-field radiation (extracranial) adverse events</i>			
Aphthous ulcer	1 (6.7)	0	0
Diarrhea	1 (6.7)	0	0
Asthenia	1 (6.7)	0	0
Disease progression	0	1 (6.7)	0
Sinusitis	1 (6.7)	0	0
Device-related infection	1 (6.7)	0	0
Musculoskeletal pain	1 (6.7)	0	0
Malignant neoplasm progression	1 (6.7)	0	0
Malignant pleural effusion	0	1 (6.7)	0
Dry skin	1 (6.7)	0	0

Day 8 after AGuIX administration. No MRI signal enhancement or T_1 variation was observed in healthy brain regions 2 h after AGuIX administration.

Details of the contrast agent characteristics of AGuIX in this phase I trial have been previously published [20].

Analysis of changes in metastases indicated stable disease or partial response in 13 of 14 evaluable patients (Fig. 2A). The overall median intracranial PFS was 5.5 months (Fig. 2B); median OS was 5.5 months. Fig. 2C compares observed survival time with expected survival according to Diagnosis-Specific Graded Prognostic Assessment score [21]. Five patients, namely Patients 8 (dose 50 mg/kg), 11, and 12 (75 mg/kg), and 13 and 15 (100 mg/kg) were alive at study end, 12 months after AGuIX-WBRT treatment.

Correlation of metastatic response with AGuIX uptake and estimated magnitude of radiosensitization is shown in Fig. 3 (methodology described in Appendix). Measurement of tumor volumes and values of AGuIX enhancement at Days 0 and 28 was performed for 255 metastases, representing 12 of 15 patients. One patient died before Day 28, 1 had macroscopic bleeding into brain metastases without accurate values of AGuIX, and Day 28 contrast agent injection was not performed for 1 patient. A clear trend in metastasis reduction was seen with AGuIX uptake, correlating well with hypothesized model predictions, although there was significant intra-patient heterogeneity ($R^2 = 0.4$; $P < 1 \times 10^{-5}$). Despite this heterogeneity, there is clear evidence of AGuIX-dependent reductions in metastasis growth. These results suggest that AGuIX uptake leading to 1% T_1 enhancement would cause a 1.9% reduction in metastasis volume when combined with irradiation. As no matched control data were available, this cannot be converted into a dose-enhancement value, but strongly supports the observation that AGuIX likely sensitizes metastases to radiation in a dose-response manner.

Discussion

The NANO-RAD trial has established the feasibility and safety of systemic administration of AGuIX nanoparticles at doses of ≤ 100 mg/kg when combined with WBRT. To our knowledge, this is the first report on intravenous use of nanoparticles as radiosensitizing agents. We observed good tolerance of a single intravenous AGuIX infusion in all 15 patients, without any signs of acute toxicity. Considering the plasma half-life of AGuIX of 0.8–3 h, and urinary excretion of at least half of the injected dose during the first 24 h, repeated weekly administration will likely be possible in future trials.

As expected, given the advanced disease stage of our patients, numerous SAEs were observed during follow-up; most appeared unrelated to AGuIX. A possible link was assumed between treatment and the delayed neurocognitive toxicity observed in 3 patients, as this is a known WBRT complication. Nevertheless, it is difficult to link causality of these events with administration of AGuIX, given its fast clearance from healthy tissue and high prevalence of neurocognitive disorders associated with brain RT alone [22].

MRI results demonstrated the theranostic characteristics of AGuIX nanoparticles. Monitoring distribution and washout with quantification of accumulation in each of the 255 metastases by MRI enabled modeling of AGuIX radiosensitization. Significant radiosensitization requires the presence of nanoparticles with multiple high-Z atoms, unlike Gd-based molecular agents such as gadoterate meglumine [23]. Indeed, it has been suggested that clustering of Gd atoms on nanoparticles leads to formation of an Auger shower inducing a strong increase in dose deposit in the nanoparticle vicinity [5]. No MRI enhancement was observed in healthy brain tissues 2 h after AGuIX administration, even at the highest dose. This favors the best possible differential effect by radiosensitization and is consistent with rapid clearance of AGuIX nanoparticles.

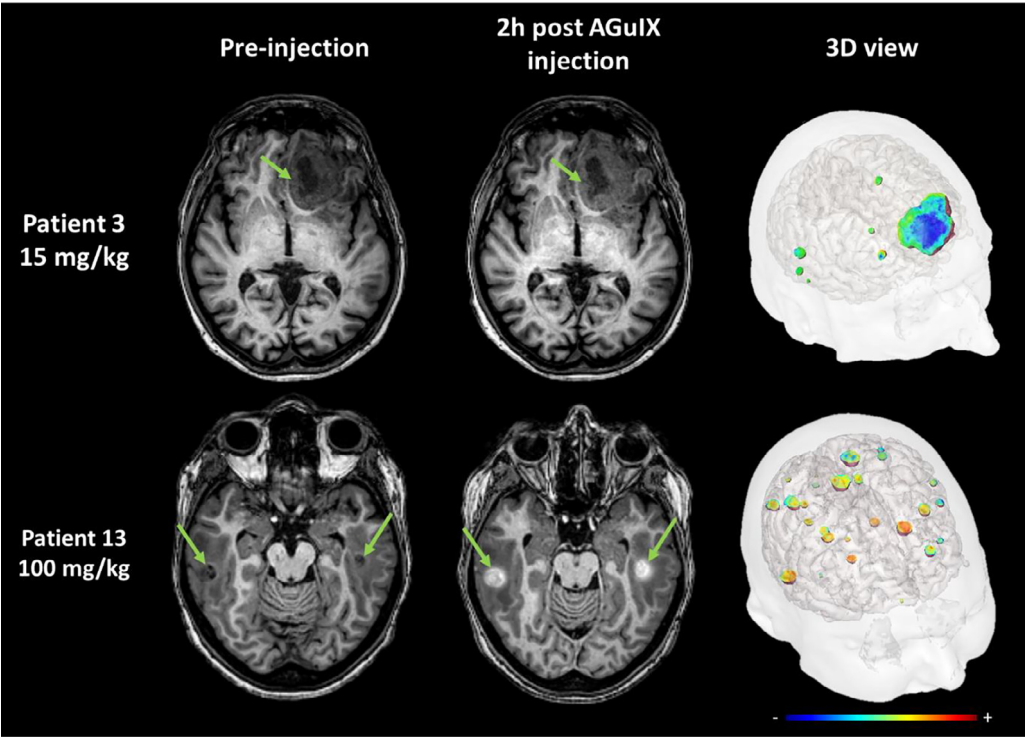


Fig. 1. AGuIX contrast-enhanced MRI at 2 h in brain metastases of 2 patients with lung cancer following intravenous AGuIX administration at 15 and 100 mg/kg respectively. AGuIX, Activation and Guidance of Irradiation by X-Ray; MRI, magnetic resonance imaging. T₁-weighted MRI images were obtained without injection of contrast agent before and at 2 h after a single AGuIX intravenous administration at the indicated concentration. Green arrows are pointing highlighted metastases. The 3-D visualization of entire brain with specific contrast enhancement into metastases was obtained from T₁-weighted MRI mapping.

This study has limitations by design. The MTD for AGuIX was not reached because of lack of toxicity. Assuming comparability with the number of Gd³⁺ ions injected by contrast agents, the target dose for theranostic AGuIX was set at 100 mg/kg, the highest dose planned in NANO-RAD. We stopped dose escalation at 100 mg/kg because of the quality of AGuIX enhancement in brain metastases and the possibility of late toxicity. As a phase I dose-

escalation trial, the number of patients was limited at each dose level, including the final one. Although no control arm was included to directly demonstrate the dose-enhancement effect of AGuIX, informative modeling was possible due to follow-up of each relevant metastasis. This showed that AGuIX nanoparticles were present in brain metastases from melanoma, lung, breast, and colon cancers, regardless of the injected dose. WBRT is no longer standard of care for patients with multiple brain metastases because of possible neurocognitive toxicity and the development of stereotactic RT. Although stereotactic RT can be used to treat increasing numbers of brain metastases [24], this is not always feasible in daily clinical practice. Moreover, recent publications suggest that late neurocognitive toxicities can be reduced by preserving the hippocampus or by using memantine [25,26].

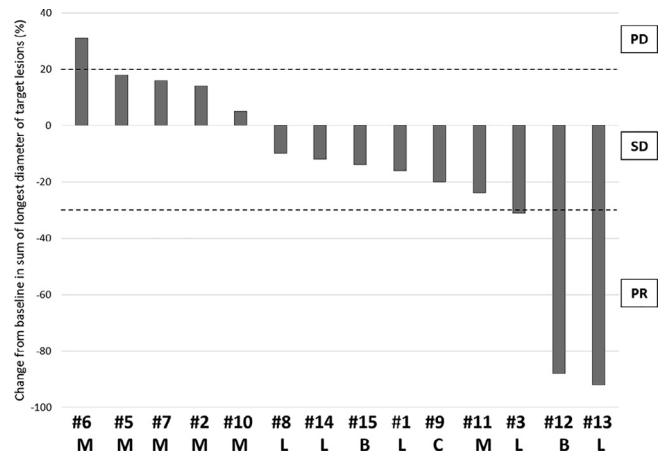


Fig. 2. (A) Best response rate from baseline in target lesions (RECIST version 1.1) and (B) intracranial progression-free survival, and (C) overall survival of multiple patients with brain metastases treated with a combination of WBRT and different dose levels of intravenous AGuIX. Gray bars: expected median survival time according to the Diagnosis-Specific Graded Prognostic Assessment score [21]; blue bars: survival time of deceased patients; green bars: survival time of patients still alive at the end of the study (at 12 months after initiation of WBRT). AGuIX, Activation and Guidance of Irradiation by X-Ray; B, Breast cancer; C, Colon cancer; L, Lung cancer; M, Melanoma; PD, progressive disease; PR, partial response; SD, stable disease; WBRT, whole brain radiotherapy.

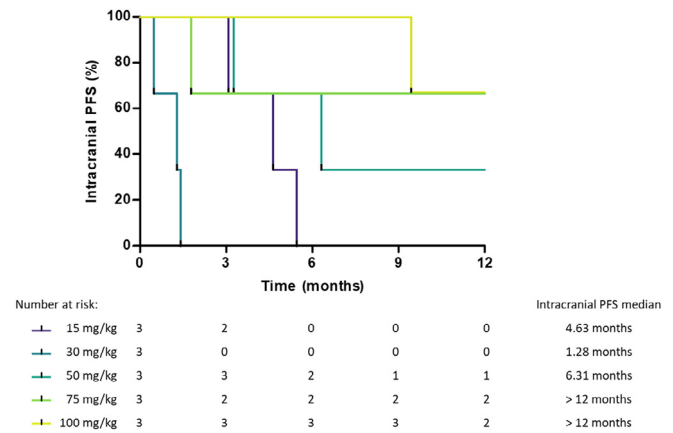


Fig. 2 (continued)

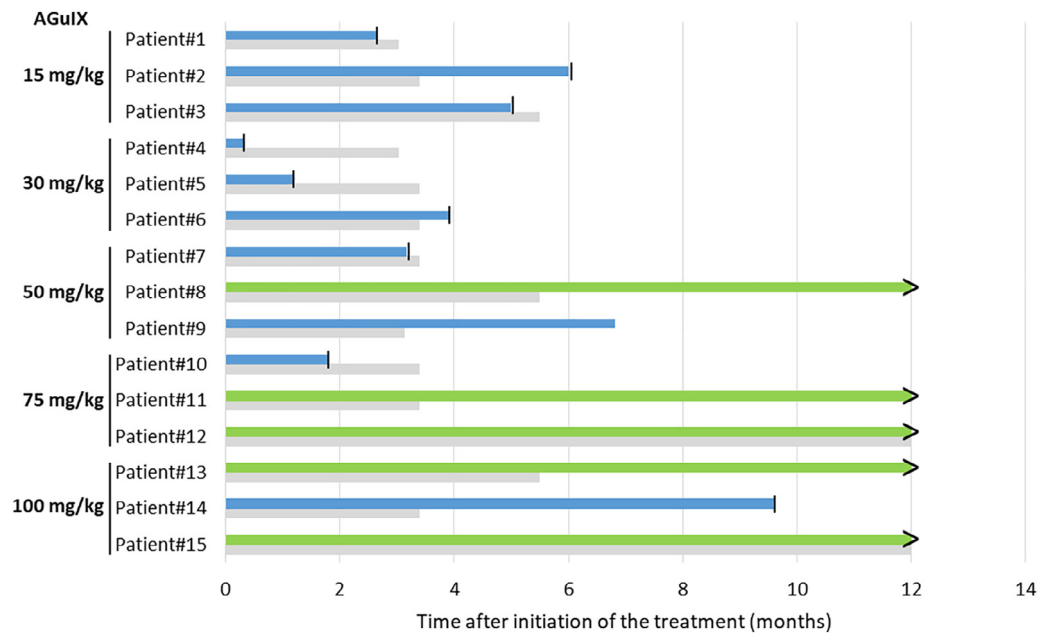


Fig. 2 (continued)

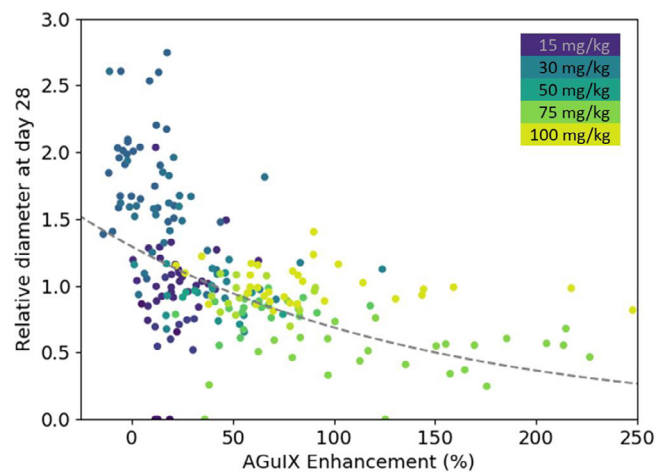


Fig. 3. Correlation between change in size of brain metastases and AGuIX signal variation. Correlation of measured metastasis sizes for patients with brain metastases and treated with whole brain radiotherapy and different AGuIX doses. Points colored according to patient number and administrated dose with darker colors corresponding to lower AGuIX doses. Metastasis diameter at 28 days normalized to diameter at Day 0 (V_{28}/V_0) as a function of AGuIX enhancement (points) compared with predicted trend (dashed line), showing good agreement and dependence of metastasis evolution on AGuIX uptake. AGuIX, Activation and Guidance of Irradiation by X-Ray.

Our patients had advanced disease, as indicated by the median of 28 brain metastases (range 4->50) and recursive partitioning analysis class III in 53%, with an estimated OS prognosis of 2 months [15]. In similar patients, the QUARTZ trial of best supportive care versus WBRT reported median OS times of 8.5 and 9.2 weeks, respectively [27]. Although our main objective was not to demonstrate efficacy and that these patients may have received different systemic treatments post WBRT, we observed controlled intracranial disease in 5 of 15 patients, all of whom were alive 12 months after treatment. Interestingly, individual analysis of metastases showed a significant correlation between AGuIX uptake in the tumor and therapeutic response.

The expected benefits of radiosensitizers are to increase the effectiveness of RT, thereby improving tumor response, or to obtain an equivalent response with reduced radiation dose. In the case of AGuIX, MRI visualization may facilitate personalized and adaptive RT. Based on local uptake of Gd-based radiosensitizers, this could be particularly relevant to the emerging magnetic resonance linear accelerator technology, combining MRI and a linear accelerator in one instrument [28]. Another key property of AGuIX nanoparticles is their prolonged retention in brain metastases. At the highest dose of 100 mg/kg, all brain metastases > 1 cm in size were contrast-enhanced ≤ 8 days after nanoparticle administration [20]. To our knowledge, this is the first report of such enduring MRI enhancement in tumors after administration of Gd-based contrast agents. Use of this radiosensitizer under optimal conditions, with elimination of nanoparticles in healthy tissues and retention in tumors, has a wide therapeutic window with potential for optimal fractionated RT in many clinical situations.

In conclusion, the results of the first-in-human NANO-RAD study demonstrate good tolerability of intravenous injection of AGuIX nanoparticles at doses of ≤ 100 mg/kg with WBRT in patients with multiple brain metastases. These first clinical findings with AGuIX — pharmacokinetics, passive targeting, concentration in metastases, and radiosensitizing effects — are consistent with observations from preclinical studies. Based on these results, phase II clinical trials in the same indication (NANORAD 2, NCT03818386) and with stereotactic RT (NANOSTEREO, NCT04094077) will continue.

Author contributions

CV contributed to the study concept, study design, study oversight, patient recruitment, data collection, data interpretation, and writing of the manuscript.

JV, CI, JC, SG, JB contributed to patient recruitment, study design, data interpretation, and critically reviewed manuscript.

SD, GLD, FL, OT, YC, LS contributed to the study concept, study design, data interpretation, and critically reviewed manuscript.

MG contributed to the study design, study oversight, data collection, data interpretation, and reviewed manuscript.

J-LQ, J-LC contributed to the study design, data collection, data interpretation, and reviewed manuscript.

FJ, CM contributed to patient recruitment, study oversight, and data collection.

AL contributed to the study oversight and reviewed manuscript.

ED, SMcM, J-YG, BC, RB, AA, DC, PJP, ML contributed to data interpretation, and critically reviewed manuscript.

All authors approved the final version of the paper.

Data sharing

Any request should be directed to the corresponding author.

Conflicts of interest

FL and OT disclose patent No. WO2011/135101. GLD and OT disclose patent No. WO2009/053644. These patents protect the AGuIX nanoparticles described in this publication. SD, GLD, YC, FL, and OT are employees of NH TherAguix (Meylan, France), which is developing the AGuIX nanoparticles. SD, GLD, FL, and OT own shares in this company. PJP is a consultant for NH TherAguix. The other authors declare no competing interests.

Acknowledgments

We thank all the patients and their families for participation in this trial. We also thank NH TherAguix for providing AGuIX nanoparticles. CV acknowledges all site personnel for their contributions, nurses, radiographers, medical secretaries, members of Clinical Investigation Center and Clinical Research Department of Grenoble Alps University Hospital. The MRI study was performed on the IRMaGe platform member of France Life Imaging network (grant ANR-11-INBS-0006). The clinical trial was funded by the Centre Hospitalier Universitaire (CHU) of Grenoble and the company NH TherAguix (Meylan, France).

Appendix A. Supplementary data

Supplementary data to this article can be found online at <https://doi.org/10.1016/j.radonc.2021.04.021>.

References

- [1] Bleeher NM, Stenning SP. A Medical Research Council trial of two radiotherapy doses in the treatment of grades 3 and 4 astrocytoma. The Medical Research Council Brain Tumour Working Party. *Br J Cancer* 1991;64:769–74.
- [2] Zschack S, Wust P, Graf R, et al. Locally dose-escalated radiotherapy may improve intracranial local control and overall survival among patients with glioblastoma. *Radiat Oncol* 2018;13:251.
- [3] Liauw SL, Connell PP, Weichselbaum RR. New paradigms and future challenges in radiation oncology: an update of biological targets and technology. *Sci Transl Med* 2013;5: 173sr2.
- [4] Liu Y, Zhang P, Li F, et al. Metal-based NanoEnhancers for future radiotherapy: radiosensitizing and synergistic effects on tumor cells. *Theranostics* 2018;8:1824–49.
- [5] McMahon SJ, Hyland WB, Muir MF, et al. Biological consequences of nanoscale energy deposition near irradiated heavy atom nanoparticles. *Sci Rep* 2011;1:18.
- [6] Retif P, Pinel S, Toussaint M, et al. Nanoparticles for radiation therapy enhancement: the key parameters. *Theranostics* 2015;5:1030–44.
- [7] Kwatra D, Venugopal A, Anant S. Nanoparticles in radiation therapy: a summary of various approaches to enhance radiosensitization in cancer. *Transl Cancer Res* 2013;2:330–42.
- [8] Lux F, Mignot A, Mowat P, et al. Ultrasmall rigid particles as multimodal probes for medical applications. *Angew Chem Int Ed Engl* 2011;50:12299–303.
- [9] Bort G, Lux F, Dufort S, et al. EPR-mediated tumor targeting using ultrasmall-hybrid nanoparticles: From animal to human with theranostic AGuIX nanoparticles. *Theranostics* 2020;10:1319–31.
- [10] Detappe A, Kunjachan S, Sancey L, et al. Advanced multimodal nanoparticles delay tumor progression with clinical radiation therapy. *J Control Release* 2016;238:103–13.
- [11] Kotb S, Detappe A, Lux F, et al. Gadolinium-based nanoparticles and radiation therapy for multiple brain melanoma metastases: proof of concept before phase I trial. *Theranostics* 2016;6:418–27.
- [12] Le Duc G, Miladi I, Alric C, et al. Toward an image-guided microbeam radiation therapy using gadolinium-based nanoparticles. *ACS Nano* 2011;5:9566–74.
- [13] Verry C, Dufort S, Barbier EL, et al. MRI-guided clinical 6-MV radiosensitization of glioma using a unique gadolinium-based nanoparticles injection. *Nanomedicine (Lond)* 2016;11:2405–17.
- [14] Lin X, DeAngelis LM. Treatment of brain metastases. *J Clin Oncol* 2015;33:3475–84.
- [15] Gaspar L, Scott C, Rotman M, et al. Recursive partitioning analysis (RPA) of prognostic factors in three Radiation Therapy Oncology Group (RTOG) brain metastases trials. *Int J Radiat Oncol Biol Phys* 1997;37:745–51.
- [16] Rastogi K, Bhaskar S, Gupta S, et al. Palliation of brain metastases: analysis of prognostic factors affecting overall survival. *Indian J Palliat Care* 2018;24:308–12.
- [17] Mehta MP, Shapiro WR, Phan SC, Gervais R, Carrie C, Chabot P, et al. Motexafin gadolinium combined with prompt whole brain radiotherapy prolongs time to neurologic progression in non-small-cell lung cancer patients with brain metastases: results of a phase III trial. *Int J Radiat Oncol Biol Phys* 2009;15:1069–76.
- [18] Verry C, Sancey L, Dufort S, et al. Treatment of multiple brain metastases using gadolinium nanoparticles and radiotherapy: NANO-RAD, a phase I study protocol. *BMJ Open* 2019;9:e023591.
- [19] Eisenhauer EA, Therasse P, Bogaerts J, et al. New response evaluation criteria in solid tumours: revised RECIST guideline (version 1.1). *Eur J Cancer* 2009;45:228–47.
- [20] Verry C, Dufort S, Lemasson B, et al. Targeting brain metastases with ultrasmall theranostic nanoparticles, a first-in-human trial from an MRI perspective. *Sci Adv* 2020;6:eaay5279.
- [21] Sperduto PW, Kased N, Roberge D, et al. The effect of tumor subtype on survival and the graded prognostic assessment (GPA) for patients with breast cancer and brain metastases. *J Clin Oncol* 2011;29:238.
- [22] Klein M, Heimans JJ, Aaronson NK, et al. Effect of radiotherapy and other treatment-related factors on mid-term to long-term cognitive sequelae in low-grade gliomas: a comparative study. *Lancet* 2002;360:1361–8.
- [23] Le Duc G, Roux S, Paruta-Tuarez A, et al. Advantages of gadolinium based ultrasmall nanoparticles vs molecular gadolinium chelates for radiotherapy guided by MRI for glioma treatment. *Cancer Nanotechnol* 2014;5:4.
- [24] Niranjana A, Monaco E, Flickinger J, et al. Guidelines for multiple brain metastases radiosurgery. *Prog Neurol Surg* 2019;34:100–9.
- [25] Brown PD, Gondi V, Pugh S, et al. Hippocampal avoidance during whole-brain radiotherapy plus memantine for patients with brain metastases: Phase III Trial NRG Oncology CC001. *J Clin Oncol* 2020;38:1019–29.
- [26] Gondi V, Pugh SL, Tome WA, et al. Preservation of memory with conformal avoidance of the hippocampal neural stem-cell compartment during whole-brain radiotherapy for brain metastases (RTOG 0933): a phase II multi-institutional trial. *J Clin Oncol* 2014;32:3810–6.
- [27] Mulvenna P, Nankivell M, Barton R, et al. Dexamethasone and supportive care with or without whole brain radiotherapy in treating patients with non-small cell lung cancer with brain metastases unsuitable for resection or stereotactic radiotherapy (QUARTZ): results from a phase 3, non-inferiority, randomised trial. *Lancet* 2016;388:2004–14.
- [28] Wen N, Kim J, Doerner A, et al. Evaluation of a magnetic resonance guided linear accelerator for stereotactic radiosurgery treatment. *Radiother Oncol* 2018;127:460–6.