



HAL
open science

Prefrontal seizure classification based on stereo-EEG quantification and automatic clustering

Stéphanie Machado, Francesca Bonini, Aileen Mcgonigal, Rinki Singh, Romain Carron, Didier Scavarda, Stanislas Lagarde, Agnes Trébuchon, Bernard Giusiano, Fabrice Bartolomei

► **To cite this version:**

Stéphanie Machado, Francesca Bonini, Aileen Mcgonigal, Rinki Singh, Romain Carron, et al.. Prefrontal seizure classification based on stereo-EEG quantification and automatic clustering. *Epilepsy & Behavior*, 2020, 112, pp.107436. 10.1016/j.yebeh.2020.107436 . hal-03273628

HAL Id: hal-03273628

<https://hal.science/hal-03273628v1>

Submitted on 7 Sep 2022

HAL is a multi-disciplinary open access archive for the deposit and dissemination of scientific research documents, whether they are published or not. The documents may come from teaching and research institutions in France or abroad, or from public or private research centers.

L'archive ouverte pluridisciplinaire **HAL**, est destinée au dépôt et à la diffusion de documents scientifiques de niveau recherche, publiés ou non, émanant des établissements d'enseignement et de recherche français ou étrangers, des laboratoires publics ou privés.



Distributed under a Creative Commons Attribution - NonCommercial 4.0 International License

Prefrontal seizure classification based on stereo-EEG quantification and automatic clustering

Stéphanie Machado², Francesca Bonini ^{1,2}, Aileen McGonigal^{1,2}, Rinki Singh⁵, Romain Carron ^{1,4}, Didier Scavarda ^{1,3}, Stanislas Lagarde^{1,2}, Agnes Trébuchon^{1,2}, Bernard Giusiano^{1,2}, Fabrice Bartolomei^{1,2}

1. Aix Marseille Univ, INSERM, INS, Inst Neurosci Syst, Marseille, France
2. APHM, Timone hospital, Epileptology department, Marseille, France
3. APHM, Timone Hospital, Paediatric Neurosurgery Department, Marseille, 13005, France
4. APHM, Timone Hospital, Functional and Sterotactical Neurosurgery Department, Marseille, 13005, France
5. King's College Hospital ,Department of Clinical Neurophysiology, London

Corresponding author :

Prof Fabrice Bartolomei, MD, PhD

Epileptology Department, CHU Timone, 264 Rue Saint-Pierre, 13005, Marseille, France

Tel: +33491385833 Fax: +33491385826 Email: fabrice.bartolomei@ap-hm.fr

Abstract

Purpose: Frontal seizures are organized according to anatomo-functional subdivisions of the frontal lobe. Prefrontal seizures have been the subject of few detailed studies to date. The objective of this study was to identify subcategories of prefrontal seizures based on seizure onset quantification and to look for semiological differences.

Methods: Consecutive patients who underwent stereo-electroencephalography (SEEG) for drug-resistant prefrontal epilepsy between 2000 and 2018 were included. The different prefrontal regions investigated in our patients were: dorsolateral prefrontal cortex (DLPFC), ventrolateral prefrontal cortex (VLPFC), dorsomedial prefrontal cortex (DMPFC), ventromedial prefrontal cortex (VMPFC) and orbitofrontal cortex (OFC). The seizure onset zone was determined from one or two seizures in each patient, using the epileptogenicity index (EI) method. The presence or absence of 16 clinical ictal manifestations were analyzed. Classification of prefrontal networks was performed using the k-means automatic classification method.

Results: A total of 51 seizures from 31 patients were analyzed. The optimal clustering was 4 subgroups of prefrontal seizures: a "pure DLPF" group, a "pure VMPF" group, a "pure OFC" group and a "global prefrontal" group. The first 3 groups showed a mean EI considered epileptogenic (> 0.4) only in one predominant structure, while the fourth group showed a high mean EI in almost all prefrontal structures. The median number of epileptogenic structures per seizure (prefrontal or extra-frontal) was 5 for the "global prefrontal" group and 2 for the other groups. We found that the most common signs were altered consciousness, automatisms/stereotypies, integrated gestural motor behavior and hyperkinetic motor

behaviour. We found no significant difference in the distribution of ictal signs between the different groups.

Conclusion: Our study showed that although most prefrontal seizures manifest as a network of several anatomically distinct structures, we were able to determine a sublobar organization of prefrontal seizure onset with four groups.

Key words: focal epilepsy, epilepsy surgery, Frontal lobe, SEEG

Abbreviations: SEEG: stereoelectroencephalography, MRI: magnetic resonance imaging, SOZ: seizure onset zone, EI: epileptogenicity index, FLE: frontal lobe epilepsy, EZ: epileptogenic zone, DLPFC: dorsolateral prefrontal cortex VLPFC: ventrolateral prefrontal cortex, DMPFC: dorsomedial prefrontal cortex , VMPFC: ventromedial prefrontal cortex, OFC: orbitofrontal cortex

1.Introduction

Frontal lobe seizures represent the second most frequent group of epilepsies in surgical series [1, 2]. However, they do not represent a homogeneous group of anatomically well-defined entities[3-5]. Seizures arising from the motor and premotor cortices have been earlier and better delineated compared to prefrontal seizures, both in terms of clinical expression and cortical substrate, since the beginning of the 19th century up until recent years[6-8]. Conversely, descriptions and investigations of prefrontal lobe seizures were elaborated later, particularly after the introduction of intracranial investigations [9-14]. Nonetheless it is commonly accepted that prefrontal seizures are more difficult to characterize in terms of organization of the epileptogenic networks within the prefrontal cortices [4, 5, 15, 16] and such a difficulty to define distinct electroclinical patterns is related to intrinsic characteristics of the lobe.

Indeed the prefrontal cortex represents a large part of total cortical volume in humans (about 30%) [17]and is subdivided into different cytoarchitectural and functional subregions[18], with complex and multidirectional patterns of connections, both intrinsic and extra-lobar[19]. The exact boundaries of the different prefrontal areas are not easy to delineate and this subject is still matter of debate. However a rostro-caudal organization together with a orbito-medial and lateral gradient of functional organization have been evidenced, and dorsolateral, dorsomedial, ventrolateral, ventromedial, and orbital prefrontal cortex are common functional divisions[18, 20].

The prefrontal cortex with all its subdivisions is involved in various higher cognitive processes and more generally in the control of behavior, either motor or not, including: executive functions[21], visual working memory[22], regulation of emotion[23],

social cognition[24] or decision making[25] . It is also a critical part of the fronto-parietal system essential for consciousness processing [26].

The large and partially buried volume of the prefrontal cortex, its complex multidirectional, intra and inter-lobar connectivity, and the different functions in which it is involved, can explain the complexity of the clinical expression of prefrontal seizures[5]. Indeed, the variability in terms of clinical expression from one patient to another, makes classification challenging.

In a previous study, electroclinical patterns in the whole frontal lobe and its subregions were identified, in which an aspect of the methodology involved evaluation of “the early spread network” rather than the seizure onset zone only, encompassing motor, premotor and prefrontal areas [5]. This study showed a rostrocaudal semiological gradient within the frontal lobes. However, a precise sublobar organization of prefrontal seizures using quantified analysis of electrical activity at seizure onset has not been clearly established and a comprehensive analysis of prefrontal epileptogenic zone networks is lacking.

The goal of this study was to determine whether subcategories of prefrontal seizures as determined by stereoelectroencephalography (SEEG) could be identified, in a consecutive series of patients, using a quantification of the epileptogenic zone (EZ) by the estimation of the “epileptogenicity index” (EI)[27]. A second objective was to describe the clinical features of each subcategory.

2. Material and methods

2.1. Patient selection and SEEG recording

Patients undergoing presurgical evaluation for drug resistant epilepsy were selected from a series of 400 patients in whom intracerebral recordings had been performed between 2000 and

2018 (Timone Hospital, Marseille, France). Selection was based on the results of SEEG recordings showing a clear definition of the seizure onset zone within the prefrontal cortex (Table 1).

Prior to selection for SEEG, all patients underwent non-invasive assessment including detailed clinical history and neurologic examination, neuropsychological testing, magnetic resonance imaging (MRI) and long-term surface video-electroencephalography (video-EEG) recording.

SEEG exploration was carried out during long-term video-EEG monitoring in order to record several of the patient's habitual seizures, following complete or partial withdrawal of antiepileptic drugs. SEEG exploration was performed using intracerebral multiple contacts electrodes (Dixi Medical (France) or Alcis (France); 10–15 contacts, length: 2mm, diameter: 0.8mm, 1.5mm apart) placed intracranially according to Talairach stereotactic method¹⁷. Anatomic positioning of electrodes was established in each patient based upon available non-invasive data and hypotheses of localization of the EZ (Fig1). Post-operative computerized scan (CT) was performed in order to verify the absence of bleeding and the positioning of each recording contact. We co-registered pre-implantation MRI and post-implantation CT[28]. We analyzed bipolar channels within selected brain regions (adjacent contacts within grey matter). For each selected region we retain the bipolar signals with maximal epileptogenicity value (see below). The mean number of electrodes was 11 (range 6-14). Patients had spatial sampling of the prefrontal structures that varied slightly between patients, according to hypotheses of localization of the EZ. The Brodmann areas (BA) usually defined as prefrontal in humans are BA8 to 14 and BA44 to 47[20], corresponding roughly to the granular part of the prefrontal cortex (except the anterior cingulate gyrus which has agranular and dysgranular parts). Because of their extensive pre-frontal connectivity and integrated functions, the pre-supplementary motor area (pre-SMA)[29, 30] and Brodmann Area 8 are

grouped with the prefrontal structures. According to visualization of electrode position on magnetic resonance imaging (MRI), the different prefrontal areas explored in our patients were therefore grouped into the five anatomo-functional divisions mentioned above (Supplementary Figure 1): dorsolateral prefrontal cortex (DLPFC, including dorsolateral areas with lateral BA 8, lateral BA 9, BA46, and frontal pole BA 10); ventrolateral prefrontal cortex (VLPFC, including ventrolateral and frontal operculum areas with BA 44, BA45, BA 47); dorsomedial prefrontal cortex (DMPFC, including pre-SMA, medial BA8 and medial BA9); ventromedial prefrontal cortex (VMPFC, corresponding to the anterior cingulate gyrus); and orbitofrontal cortex (BA11 with orbitofrontal gyrus and rectus gyrus). In many cases, non-prefrontal structures were also sampled: lateral premotor cortex (lateral BA6); medial premotor cortex (including supplementary motor area (SMA) and posterior part of BA24 in the anterior cingulate gyrus, corresponding to monkey cingulate motor areas) [8, 31]; medial temporal lobe (amygdala, hippocampus), lateral temporal lobe (temporal pole or, if not available, middle temporal gyrus); insular cortex. The anatomical definition and the boundaries of the pre-SMA and SMA were chosen according to previous studies[8, 32]. The pre-SMA was defined as the region located above the cingulate sulcus, anterior to the vertical line passing through the anterior commissure (VAC), extending anteriorly to the VAC up to 17% of the total anteroposterior length of the brain. The SMA corresponded to the area between the VAC and the vertical line passing through the posterior commissure (VPC) and superior to the cingulate sulcus. We defined the anterior cingulate gyrus as the region lying on the banks of the cingulate sulcus and inferior to the SMA region. Within the anterior cingulate gyrus, we distinguished a caudal subdivision corresponding to the cingulate motor areas in BA24, and a rostral subdivision belonging to the prefrontal cortex mainly including BA32.

Signals were recorded on a 128 channel system (Natus/Deltamed™) sampled at 256, 512 or 1024 Hz and recorded on a hard disk (16 bits/sample) using no digital filter. A high-pass filter

(cut-off frequency equal to 0.16 Hz at -3 dB) was used to remove very slow variations that sometimes contaminate the baseline.

2.2.SEEG signal analysis: computation of the epileptogenicity index (EI)

The EI is a normalized quantity, ranging from 0 to 1, computed from SEEG recorded signals with the aim of objectively quantifying and defining a neuronal networks underlying seizures generation[27]. In this method each recorded signal is analyzed in the transition period from interictal to ictal activity and two parameters are evaluated : (i) the capacity of a given structure to generate rapid discharges (β 12–24 Hz and γ 24–90 Hz), considered a typical electrophysiological pattern of the EZ in focal epilepsies, replacing background activity (θ 3.4–7.4 Hz and α 7.4–12.4Hz) and (ii) the delay of appearance of this discharge, which is the latency of involvement of a given explored brain area with respect to the first structure involved by the ictal discharge. The EI allows quantitative estimation of the combination of these two phenomena as it provides a quantitative measure that increases with the increase of high-frequency components and short delay of involvement. The EI can therefore be used as a classification measure to rank the different explored regions.

We used a semiautomatic approach using AnyWave software[33]: the graphical interface allows the user to easily inspect and validate the automatically detected change points indicating the accurate onset of rapid discharges, which can be corrected for each channel by the user in case of false detections. Once detected change points for each recording channel were validated by the user, EI was computed for each channel providing the epileptogenicity of each corresponding structure.

For all selected patient, EI was calculated from bipolar signals recorded from all sampled structures, in prefrontal and extra-prefrontal areas. EI values were calculated on two spontaneous seizures, recorded from each patient; if only one seizure was recorded in one patient, the EI was calculated only for the single seizure.

2.3. Analysis of semiological features

Video-SEEG data were analyzed using the criteria detailed below. For each patient, all spontaneous seizures were examined and the presence or absence of 16 ictal signs were noticed : aura, versive signs, tonic/dystonic signs, vocalization (including grunt), staring/behavioural arrest, speech production (including verbal automatism), facial contraction (including “chapeau de gendarme” or rictus), automatism/stereotypies either proximal or distal (including manipulation and utilization), negative emotional/affective expression, positive emotional/affective expression, hyperkinetic motor behavior, integrated gestural motor behavior, non-integrated gestural motor behavior, impairment of consciousness, clonic signs and generalized tonic-clonic seizure (GTCS). These 16 ictal signs corresponded to a simplification of the semiological features already detailed in a previous article [5]. As a reminder (for detail see supplementary information), stereotypies, defined as excessive production of one type of motor act necessarily resulting in repetition[34], hyperkinetic motor behavior is considered as an excessive amount of movement (hyperactivity) and/or excessive amplitude, speed, and acceleration. The terms integrated and non-integrated gestural motor behavior were chosen to convey the notion of whether or not the sequence of movements appeared to follow a recognizable and somewhat “naturalistic” pattern.

2.4. Clustering classification and statistical analysis

A first attempt to classify prefrontal networks was performed using an automatic classification. Maximal EI values obtained on each of the ten structures detailed above (DLPFC, VLPFC, DMPFC, VMPFC, OFC, lateral premotor cortex, medial premotor cortex, mesial temporal lobe, lateral temporal lobe and insular cortex) were determined for each patient. These ten values were first used to classify the networks using a k-means classification method. The k-means[35] is one of the simplest and most commonly used algorithms to partition a multidimensional dataset into k clusters. It is an iterative algorithm that aims to minimize the total within-cluster variance (i.e., the sum of the squares of the distances between each data point and its cluster center). A major drawback of the k-means algorithm is that the quality of the final partition strongly depends on the initial (typically, randomly selected) cluster centers. In practice, this effect can be reduced by running the algorithm multiple times with different sets of initial cluster centers and by returning the best partition found (i.e., the one with the minimum within-cluster inertia). In addition, in the k-means algorithm, the number k of clusters must be fixed a priori. Therefore, we complemented the algorithm by a procedure aimed at determining an optimal value for k. This procedure consists in running the k-means algorithm for an increasing number of clusters (from 2 to 15). For each partition, we computed the so-called R-square criterion (defined as the ratio of the inter-cluster inertia to the total inertia) as a function of the number k of clusters.

Since not all brain structures described above were sampled for each patient (as the sampling was guided by the hypothesis about EZ localization) some EI values were missing for one or more structures depending on patients. Here, in order to solve this statistical problem and coherently with SEEG exploration procedure, we considered that a non-sampled structure was

not a potential EZ and thus it was assigned the EI value of zero. Missing data for each brain structure are detailed in supplementary Figure 2.

Fisher's test was used to determine if any significant difference of semiological symptoms was present between the groups. A p-value <0.05 was considered to be significant.

3.Results

3.1.General characteristics

Thirty-three patients (18 males and 13 females) were selected on the basis of prominent involvement of prefrontal cortex at seizure onset. Two patients were excluded (one because the electrophysiological pattern was too slow to allow calculation of EI; the other because seizures were too brief to be computed using EI, being characterized by very short-lasting spasms). Thus 31 consecutive patients were finally included in our study and we analyzed a total of 51 seizures (1 or 2 seizures per patient, 11 patients having only one spontaneous prefrontal seizure during SEEG). General characteristics of the 31 selected patients are shown in Table 1.

The mean age at onset was 12.1 ± 8.5 (range 0.3 – 33) years, with a mean age at SEEG recording at 28.6 ± 11.2 (range 6 – 47) years, which corresponds to a mean epilepsy duration of 16.5 ± 9 (range 1 – 43.5) years. Sixteen patients had left-sided epilepsy, 14 patients right-sided epilepsy and 1 patient bilateral epilepsy. The most common etiology was focal cortical dysplasia, found in 11 patients (35.5%). Negative MRI was observed in 8 patients. Twenty one patients have been operated on. The average follow-up was 14 years (range 1-20 years). 14 (66.6%); patients were seizure-free (Engel I); 2 (0.9 %) had only rare seizures (Engel II) and 4 (23%) had little or no improvement after surgery (Engel III or IV).

3.2. Classification of prefrontal networks/prefrontal seizure subtypes

EI values were computed for the different brain structures recorded in each patient's seizure.

All patients had maximal EI values in the prefrontal cortex (one or more areas). A structure with an $EI \geq 0.4$ was considered as a highly epileptogenic structure [36].

To classify the involved regions, for each seizure, we took the maximal EI values obtained from each recorded brain structure. According to the k-means classification, clustering into four groups was considered "optimal" according to the R-square criterion (defined as the ratio of the inter-cluster inertia to the total inertia). Indeed, as depicted in the curve provided in figure 2A, it can be verified that 50% of the total variance is obtained for four groups. The R-square reaches only 54% when the number of clusters goes to 5. This result indicates that partition with $k = 5$ groups is not so different in terms of interclass and intraclass variance, when compared to the one obtained for $k = 4$ groups. This suggests that classification of prefrontal seizure onset could be defined by four main subtypes in our series.

The first group included 11 seizures with maximal values in dorsolateral prefrontal regions (DLPFC): the mean EI in that group for DLPFC was 1. No other brain structure reached a mean EI of 0.4. This group can be considered as "pure DLPF". The second group included 13 seizures with maximal values in VMPFC (anterior cingulate region): the mean EI for VMPFC in that group was 1. No other brain structures reached a mean EI at 0.4. This group can be considered as "pure VMPF". The third group included 16 seizures with high values (mean $EI \geq 0.4$) in orbitofrontal cortex (OFC): the mean EI for OFC in that group was 0.97. No other brain structures reached a mean EI at 0.4. This group can be considered as "pure OFC".

The fourth group included 11 seizures with high values (mean $EI \geq 0.4$) in 4 different prefrontal structures: VLPFC (mean EI at 0.77), DLPFC (mean EI at 0.75), DMPFC (mean EI

at 0.45) and VMPFC (mean EI at 0.41). This group can be considered as “global prefrontal” including both mesial and lateral, as well as dorsal and ventral prefrontal cortices.

The details of the EI means for each brain structures of each group are detailed in Table 2 and represented in Fig.2B and 3A . The medians are represented in Figure 2C.

As cluster analysis was performed on seizures and not on patients, it is interesting to observe that 5 patients presented 2 seizures classified in 2 different groups : one patient had one seizure of the pure VMPF group and one of the pure OFC group; one patient had one seizure of the pure VMPF group and one of the global prefrontal group; one patient had one seizure of the pure DLPF group and one of the global prefrontal group, one patient had one seizure of the pure DLPF group and one of the pure OFC group, and a last patient had one seizure of the pure DLPF group and one of the pure VMPF group.

3.3.Number of epileptogenic regions and extra-prefrontal involvement

The median number of regions with high EI (≥ 0.4) per seizure was 2 for the pure DLPF group, 2 for the pure VMPF group, 2 for the pure OFC group, and 5 for the global prefrontal group. Only 10 seizures disclosed only one epileptogenic structure ($EI \geq 0.4$). Five of these were part of the pure DLPF group, two of these were part of the pure VMPF group and three of these were part of the pure OFC group.

The SOZ as quantified by EI could also involve extra-prefrontal structures (medial or lateral premotor cortex, mesial or lateral temporal cortex, or insular cortex). The median number of extra-prefrontal epileptogenic structures per seizure was 0 for the pure DLPF group, 1 for the pure VMPF group, 0 for the pure OFC group, and 1 for the global prefrontal group. Interestingly, most of the extra-prefrontal epileptogenic structures in the global prefrontal group were premotor cortices (lateral or medial) (Fig 3B).

3.4. Relationship with clinical semiology

The presence or the absence of the 16 ictal signs as detailed above was noted for each seizure.

The prevalence of each ictal sign for our patients is detailed in Table 3.

As shown in this table, the most common sign was the impairment of consciousness, occurring in 82% of the seizures. Secondly, automatism/stereotypies (including manipulation and utilization), occurred in 71% of seizures, followed by hyperkinetic motor behavior and integrated gestural motor behavior, both occurring in 41% of seizures. These signs did not appear to be discriminating since they can occur in the different subgroups.

In contrast, positive emotional/affective expression, were observed only in the pure VMPF group (15%). Speech production (including verbal automatism) occurred only in patients of pure VMPF and pure OFC groups (respectively 23% and 25% of the patients of the group). Clonic signs occurred only in patients of pure DLPF and pure VMPF groups (respectively 9% and 8% of the patients of the group). Secondary generalizations occurred only in patients of pure VMPF or global prefrontal groups (respectively 8% and 9% of the patients of the group). Auras were reported in 12 seizures from six patients. It consisted in emotional negative feelings (anxiety, fear) or/and autonomic symptoms (tachycardia, chest oppression) in 5 and positive feeling (pleasant excitement) in one.

Taken as a whole, semiological analysis of each subgroups of prefrontal seizures suggested a trend for some ictal signs, but did not show any significant difference for the distribution of single ictal signs between the different groups (p-value = 0.52).

4. Discussion

The main aim of this study was to estimate the involvement of the different sampled regions within prefrontal cortex in the generation of ictal discharge, in order to establish if a sublobar

organization of prefrontal seizures could be demonstrated. By using the EI method we quantified 51 prefrontal seizures recorded by SEEG, to assess the degree of epileptogenicity of each subregion of the prefrontal cortex. We decided to subdivide the prefrontal cortex into different subregions according to an anatomo-functional parcellation established in previous literature [18]. Using a clustering method (k-means) we found four main classes of prefrontal seizures following these recognized prefrontal subdivisions : a group of “pure DLPF”, a group of “pure VMPF”, a group of “pure OFC” and a “global prefrontal” group. By definition, the 3 first groups showed a mean EI considered epileptogenic (> 0.4) only in one predominant subregion, while the fourth group showed high mean EI in several prefrontal subregions.

It is interesting to note that we did not identify a “pure VLPF” group or “pure DMPF” group. These regions appeared to disclose high epileptogenicity when other structures were also involved (particularly DLPFC and VMPFC). This result was constant whatever the k number of clusters chose: indeed, a bigger k number would have slightly increased the R-square without producing “pure VLPF or DMPF” groups, but rather generating clusters incongruous with anatomo-functional prefrontal subdivisions. Due to the limited number of seizures studied here, we cannot rule out the fact that these rare subtypes are not represented in our sample. With a median number of epileptogenic structures per seizure of 5 for the “global prefrontal” group and of 2 for the other groups, we showed that most prefrontal seizures manifest as a network of several anatomically distinct structures. Structures involved can be prefrontal or even extra-frontal (medial or lateral premotor cortex, mesial or lateral temporal cortex, or insular cortex). This last finding is not surprising given the abundant intra- and interlobar connections of the prefrontal cortex [19, 37], and is in line with few previous studies reporting the possible involvement of motor or extra-frontal cortex in prefrontal seizures[38, 39] . We also observed that 5 patients (16%) could present crises belonging to different clusters.

With regard to clinical semiology, we found that the most common sign was the impairment of consciousness. The frequent occurrence of loss of consciousness in frontal seizures has been reported and related to the role of prefrontal associative cortex – and particularly of its interactions with parietal cortex - in the processing of consciousness, [40].

Secondly, in agreement with previous studies on frontal lobe seizures [15, 41], other common clinical features were automatisms/stereotypies, followed by hyperkinetic motor behavior and integrated gestural motor behavior.

Nonetheless we found no significant difference for the distribution of the ictal signs between the different anatomical groups, that is, no sign was significantly associated with a particular sublobar localization of the EZ. This finding can be differently explained, firstly by the relatively small dataset; as such, it might be possible that differences may emerge with a larger number of patients. Secondly, it is known that most objective signs of a seizure are due to propagation networks and not to the seizure onset zone itself [42], which has been quantified in this work. However it is interesting to note that the presence of an emotional aura, vocalization or emotional signs were more frequent in orbito-frontal and ventromedial clusters (2 and 3). Indeed these regions are part of the limbic system, particularly of the so-called “orbital and medial prefrontal network”, and are highly connected with the temporal lobe and the hypothalamus[43]. Likewise, emotional behaviors suggesting defensive or attacking reactions have been well described in ventromedial/orbitofrontal seizures and temporal-frontal seizures[44-46].

This study confirms that, although hyperkinetic movements, gestural motor behavior, stereotypies, vocalisation and pronounced emotional signs are characteristic features of prefrontal seizures, precise sublobar anatomical localization is difficult to determine using seizure onset quantification and the link between classically defined EZ and clinical expression of seizures has not yet been fully elucidated. The extensive and widespread

connections within the different areas of the frontal lobe, together with extra-frontal cortico-cortical projections, can partially explain such variability in the semiological expression of prefrontal seizures. Furthermore, cortico-subcortical projections, particularly to the basal ganglia, may represent possible distinct networks or even a final pathway for the production of semiology in these seizures, namely for complex motor manifestations and the alteration of consciousness [47].

In conclusion, this study shows that prefrontal seizures can be organized into four anatomical subgroups, according to a functional subdivision of the prefrontal cortex: dorsolateral, orbito-frontal, ventro-medial, and global prefrontal. The absence of a clear link between EZ and semiological signs, claims to consider the involvement of all these different regions in the planning of SEEG implantation in cases of suspected prefrontal seizures. However, despite the rich anatomy, especially connectivity, of these anatomical regions, many prefrontal seizures have a relatively focal epileptogenic zone that can lead to effective surgical resections.

5. References

- [1] Jeha LE, Najm I, Bingaman W, Dinner D, Widdess-Walsh P, Lüders H. Surgical outcome and prognostic factors of frontal lobe epilepsy surgery. *Brain* 2007;130: 574-84.
- [2] Bonini F, McGonigal A, Scavarda D, Carron R, Regis J, Dufour H, Peragut JC, Laguitton V, Villeneuve N, Chauvel P, Giusiano B, Trebuchon A, Bartolomei F. Predictive Factors of Surgical Outcome in Frontal Lobe Epilepsy Explored with Stereoelectroencephalography. *Neurosurgery* 2017.
- [3] Bancaud J, Talairach J. Clinical semiology of frontal lobe seizures. *Adv Neurol* 1992;57: 3-58.
- [4] Bartolomei F, Chauvel P. Frontal Lobe and Rolandic seizures. In: Oxbury J, Polkey C, Duchowny M, editors. *Intractable Focal Epilepsy*. Oxford: Saunders WB; 2000, p. 55-62.
- [5] Bonini F, McGonigal A, Trebuchon A, Gavaret M, Bartolomei F, Giusiano B, Chauvel P. Frontal lobe seizures: from clinical semiology to localization. *Epilepsia* 2014;55: 264-77.
- [6] Ajmone-Marsan C, Goldhammer L. Clinical Ictal Patterns and Electrographic Data in Cases of Partial Seizures of Frontal-Central-Parietal Origin. . In: New York: Academic Press; 1973. doi:10.1016/b978-0-12-128650-7.50017-2.
- [7] Lim SH, Dinner DS, Pillay PK, Luders H, Morris HH, Klem G, Wyllie E, Awad IA. Functional anatomy of the human supplementary sensorimotor area: results of extraoperative electrical stimulation. *Electroencephalogr Clin Neurophysiol* 1994;91: 179-93.

- [8] Bonini F, McGonigal A, Wendling F, Regis J, Scavarda D, Carron R, Chauvel P, Bartolomei F. Epileptogenic networks in seizures arising from motor systems. *Epilepsy Res* 2013;106: 92-102.
- [9] Ludwig B, Marsan CA, Van Buren J. Cerebral seizures of probable orbitofrontal origin. *Epilepsia* 1975;16: 141-58.
- [10] Rasmussen T. Characteristics of a pure culture of frontal lobe epilepsy. *Epilepsia* 1983;24: 482-93.
- [11] Geier S, Bancaud J, Talairach J, Bonis A, Szikla G, Enjelvin M. The seizures of frontal lobe epilepsy. A study of clinical manifestations. *Neurology* 1977;27: 951-8.
- [12] Jobst B, Siegel aM, Thadani V, Roberts D, Rhodes H, Williamson P. Intractable seizures of frontal lobe origin: clinical characteristics, localizing signs, and results of surgery. *Epilepsia* 2000;41: 1139-1152.
- [13] So N. Mesial frontal epilepsy. *Epilepsia* 1998;39: S49-S61.
- [14] Munari C, Bancaud J. Electroclinical symptomatology of partial seizures of orbital frontal origin. *Adv Neurol* 1992;57: 257-65.
- [15] Chauvel P, Kliemann F, Vignal JP, Chodkiewicz JP, Talairach J, Bancaud J. The clinical signs and symptoms of frontal lobe seizures. Phenomenology and classification. *Adv Neurol* 1995;66: 115-25; discussion 125-6.
- [16] Lee RW, Worrell GA. Dorsolateral frontal lobe epilepsy. *J Clin Neurophysiol* 2012;29: 379-84.
- [17] Carlen M. What constitutes the prefrontal cortex? *Science* 2017;358: 478-482.
- [18] Petrides M, Tomaiuolo F, Yeterian EH, Pandya DN. The prefrontal cortex: comparative architectonic organization in the human and the macaque monkey brains. *Cortex* 2012;48: 46-57.
- [19] Barbas H. General cortical and special prefrontal connections: principles from structure to function. *Annu Rev Neurosci* 2015;38: 269-89.
- [20] Fuster J. *The Prefrontal Cortex*: Academic Press; 2015.
- [21] Yuan P, Raz N. Prefrontal cortex and executive functions in healthy adults: a meta-analysis of structural neuroimaging studies. *Neurosci Biobehav Rev* 2014;42: 180-92.
- [22] Mottaghy FM, Gangitano M, Sparing R, Krause BJ, Pascual-Leone A. Segregation of areas related to visual working memory in the prefrontal cortex revealed by rTMS. *Cereb Cortex* 2002;12: 369-75.
- [23] Dixon ML, Thiruchselvam R, Todd R, Christoff K. Emotion and the prefrontal cortex: An integrative review. *Psychol Bull* 2017;143: 1033-1081.
- [24] Eickhoff SB, Laird AR, Fox PT, Bzdok D, Hensel L. Functional Segregation of the Human Dorsomedial Prefrontal Cortex. *Cereb Cortex* 2016;26: 304-21.
- [25] Bechara A, Damasio H, Tranel D, Anderson SW. Dissociation Of working memory from decision making within the human prefrontal cortex. *J Neurosci* 1998;18: 428-37.
- [26] Dehaene S, Changeux JP. Experimental and theoretical approaches to conscious processing. *Neuron* 2011;70: 200-27.
- [27] Bartolomei F, Chauvel P, Wendling F. Epileptogenicity of brain structures in human temporal lobe epilepsy: a quantified study from intracerebral EEG. *Brain* 2008;131: 1818-30.
- [28] Medina Villalon S, Paz R, Roehri N, Lagarde S, Pizzo F, Colombet B, Bartolomei F, Carron R, Benar CG. EpiTools, A software suite for presurgical brain mapping in epilepsy: Intracerebral EEG. *J Neurosci Methods* 2018;303: 7-15.
- [29] Wang Y, Isoda M, Matsuzaka Y, Shima K, Tanji J. Prefrontal cortical cells projecting to the supplementary eye field and presupplementary motor area in the monkey. *Neurosci Res* 2005;53: 1-7.
- [30] Nachev P, Wydell H, O'Neill K, Husain M, Kennard C. The role of the pre-supplementary motor area in the control of action. *Neuroimage* 2007;36 Suppl 2: T155-63.
- [31] Picard N, Strick PL. Motor areas of the medial wall: a review of their location and functional activation. *Cereb Cortex* 1996;6: 342-53.
- [32] Chassagnon S, Minotti L, Kremer S, Hoffmann D, Kahane P. Somatosensory, motor, and reaching/grasping responses to direct electrical stimulation of the human cingulate motor areas. *J Neurosurg* 2008;109: 593-604.

- [33] Colombet B, Woodman M, Badier JM, Benar CG. AnyWave: a cross-platform and modular software for visualizing and processing electrophysiological signals. *J Neurosci Methods* 2015;242: 118-26.
- [34] Ridley RM. The psychology of perseverative and stereotyped behaviour. *Prog Neurobiol* 1994;44: 221-31.
- [35] MacQueen J. Some methods for classification and analysis of multivariate observations. In: Le Cam L, Neyman J, editors. Berkeley: University of California Press; 1967, p. 666.
- [36] Aubert S, Wendling F, Regis J, McGonigal A, Figarella-Branger D, Peragut JC, Girard N, Chauvel P, Bartolomei F. Local and remote epileptogenicity in focal cortical dysplasias and neurodevelopmental tumours. *Brain* 2009;132: 3072-86.
- [37] Ghaziri J, Tucholka A, Girard G, Houde JC, Boucher O, Gilbert G, Descoteaux M, Lippe S, Rainville P, Nguyen DK. The Corticocortical Structural Connectivity of the Human Insula. *Cereb Cortex* 2017;27: 1216-1228.
- [38] Gibbs SA, Proserpio P, Francione S, Mai R, Cardinale F, Sartori I, Castana L, Plazzi G, Tinuper P, Cossu M, Russo GL, Tassi L, Nobili L. Clinical features of sleep-related hypermotor epilepsy in relation to the seizure-onset zone: A review of 135 surgically treated cases. *Epilepsia* 2019;60: 707-717.
- [39] Fayerstein J, McGonigal A, Pizzo F, Bonini F, Lagarde S, Scavarda D, Scholly J, Lambert I, Giusiano B, Bartolomei F. Quantitative analysis of hyperkinetic seizures and correlation with seizure onset zone. *Epilepsia* 2020;in press.
- [40] Bonini F, Lambert I, Wendling F, McGonigal A, Bartolomei F. Altered synchrony and loss of consciousness during frontal lobe seizures. *Clin Neurophysiol* 2016;127: 1170-5.
- [41] McGonigal A, Chauvel P. Prefrontal seizures manifesting as motor stereotypies. *Mov Disord* 2014;29: 1181-5.
- [42] Bartolomei F, Lagarde S, Wendling F, McGonigal A, Jirsa V, Guye M, Benar C. Defining epileptogenic networks: Contribution of SEEG and signal analysis. *Epilepsia* 2017;58: 1131-1147.
- [43] Barbas H, Garcia-Cabezas M. Prefrontal cortex integration of emotion and cognition. In: Watanabe E, editor. *The prefrontal cortex as an executive, emotional and social brain*. Japan: Springer; 2017, p. 51-76.
- [44] Biraben A, Taussig D, Thomas P, Even C, Vignal JP, Scarabin JM, Chauvel P. Fear as the main feature of epileptic seizures. *J Neurol Neurosurg Psychiatry* 2001;70: 186-91.
- [45] Tassinari CA, Tassi L, Calandra-Buonaura G, Stanzani-Maserati M, Fini N, Pizza F, Sartori I, Michelucci R, Lo Russo G, Meletti S. Biting behavior, aggression, and seizures. *Epilepsia* 2005;46: 654-63.
- [46] Bartolomei F, Trebuchon A, Gavaret M, Regis J, Wendling F, Chauvel P. Acute alteration of emotional behaviour in epileptic seizures is related to transient desynchrony in emotion-regulation networks. *Clin Neurophysiol* 2005;116: 2473-9.
- [47] Guedj E, McGonigal A, Vaugier L, Mundler O, Bartolomei F. Metabolic brain PET pattern underlying hyperkinetic seizures. *Epilepsy Res* 2012;101: 237-45.

Legends of Tables and Figures

Figure 1: A. Example of SEEG recordings of a patient with orbitofrontal cortex seizures. Each trace represents the bipolar recording between two contacts of an electrode. The electrodes are shown in section C. B. Normalized Epileptogenicity index (EI) values. EI ranks brain structures according to the “tonicity” of the fast discharge (energy ratio of high frequency content over low frequency, red bars) and the delay of involvement at seizure onset. Its normalized values range from 0 to 1 (blue bars), with 1 corresponding to the most epileptogenic region. To compute the EI, we used the plugin designed for the open-source AnyWave software (available at: [http:// meg.univ-amu.fr](http://meg.univ-amu.fr)). Max EI value was observed in left orbitofrontal cortex (OR'1-2; OR'2-3; R'4-5; R'5-6) C. 3D representation of the SEEG

exploration; the balloons indicate the EI detections. Balloon colour (from yellow to red) and dimension correspond to the EI value e . MRI (T1 sequence) - CT data fusion:

Figure2: A: Total variance of data explained by the clustering depending on the number of clusters. B: Means of EI-max for each structure by cluster. C: Boxplots of EI-max for each structure by cluster (the thick red line is the median, the left and right edges of the box, when it exists, correspond to the first and the third quartile). Abbreviations: DLPFC: dorsolateral prefrontal cortex VLPFC: ventrolateral prefrontal cortex; DMPCF: dorsomedial prefrontal cortex; VMPFC: ventral medial prefrontal cortex; OFC: orbitofrontal cortex; LPM: lateral premotor cortex; MPM: medial premotor cortex; MT: mesial temporal; LT: lateral temporal; INS: insular cortex

Figure 3 . A. Individual profiles of epileptogenicity for each seizure (means of EI, same color legend as figure 2B). B. Proportion (in %) of seizures disclosing $EI > 0.4$ in extraprefrontal structures (Insula, LPM lateral premotor, MPM mesial premotor, MT mesial temporal, LT lateral temporal) for the four groups (cluster 1 DLPFC, Cluster 2 VMPFC, cluster 3 OFC; cluster 4 Prefrontal global).

Table 1: Clinical characteristics of the 31 patients with prefrontal lobe epilepsies. Abbreviations: FCD: focal cortical dysplasia. DLPFC: dorsolateral prefrontal cortex VLPFC: ventrolateral prefrontal cortex; DMPCF: dorsomedial prefrontal cortex; VMPFC: ventral medial prefrontal cortex;

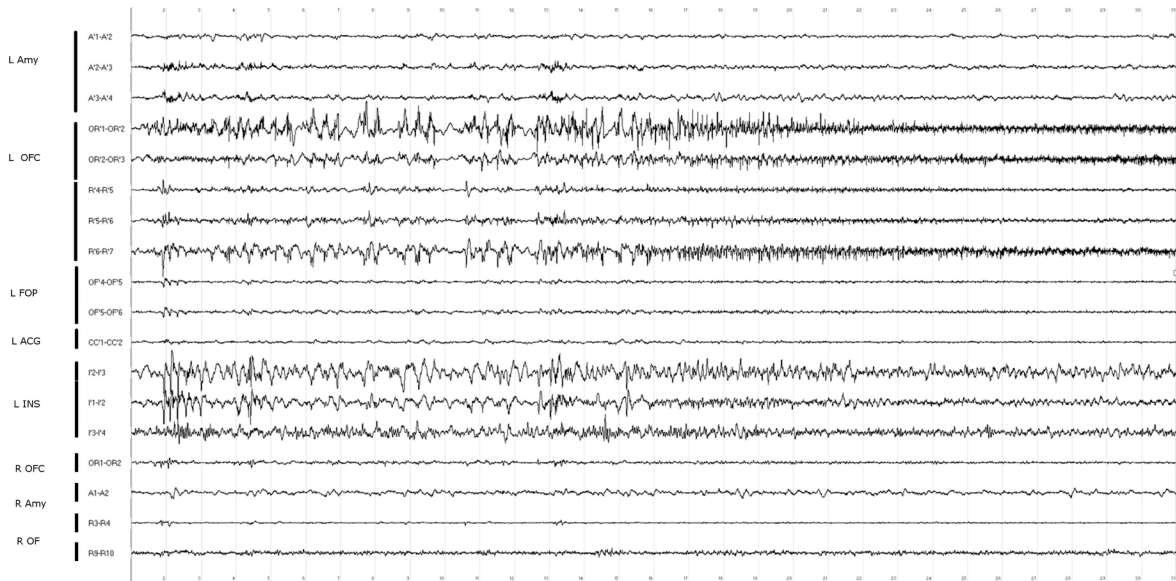
Table 2: Means of the maximal values of epileptogenicity index (EI-max) in each prefrontal subregions for the 4 clusters (respectively 11, 13, 16, 11 seizures)

Table 3: Prevalence of ictal signs in each cluster. Abbreviations: DLPFC: dorsolateral prefrontal cortex VMPFC: ventral medial prefrontal cortex;GTCS: generalized tonic clonic seizures

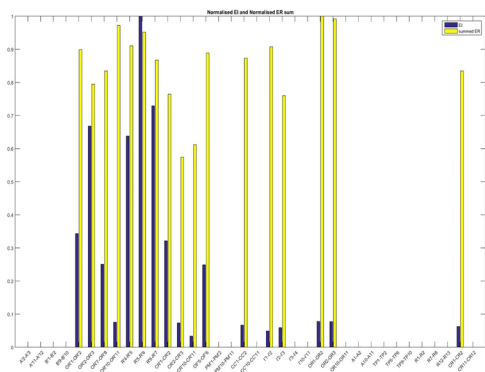
Declaration of competing interest

The authors have no conflict of interest to declare.

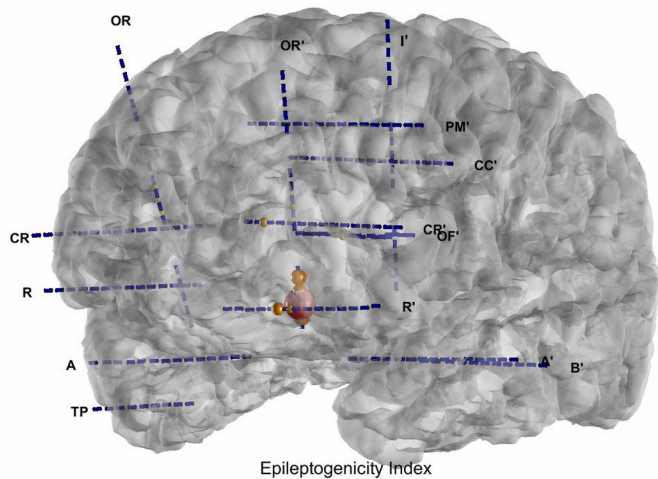
A

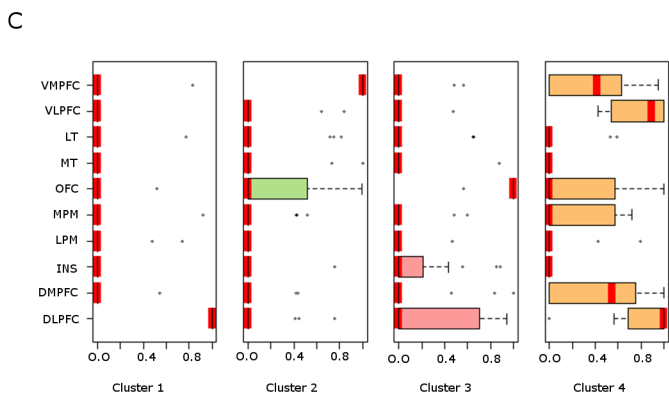
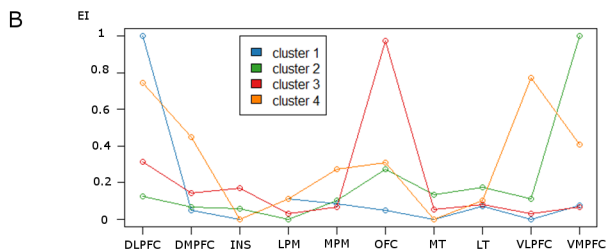
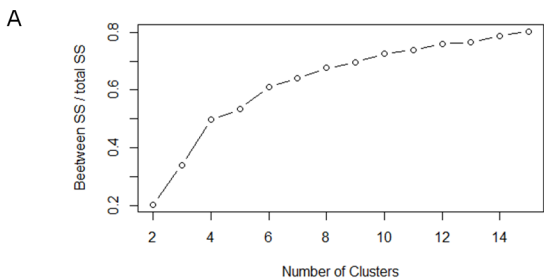


B

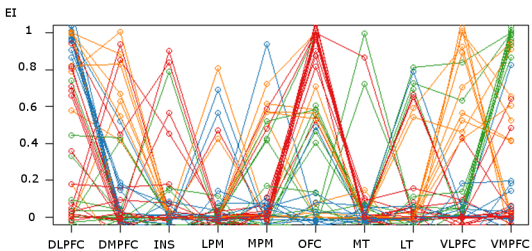


C





A



B

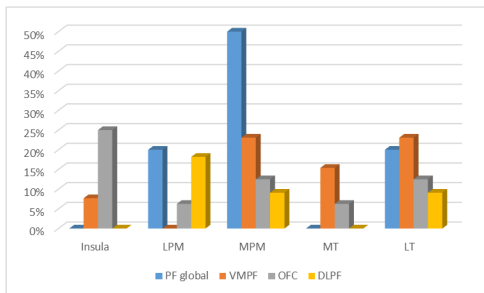


Table 1

Patient	Gender	Age at onset (y)	Age at SEEG recording (y)	Epilepsy duration (y)	Epilepsy side	Etiology/MRI	Surgical outcome (Engel's class)
P1	M	19	35	16	R	FCD	I
P2	F	17	41	24	R	Ethmoidal fistula	No
P3	F	18	32	14	R	Cryptogenic	II
P4	M	2	6	4	R	Abnormal gyration F1/F2	No
P5	F	5	24	19	L	Cryptogenic	II
P6	F	4	29	25	L	FCD	I
P7	F	12	34	22	L	FCD (but MRI negative)	I
P8	F	8	22	14	R	Ischemic lesions post herpetic encephalitis	IV
P9	M	6	30	24	R	FCD (but MRI negative)	I
P10	M	21	27	6	L	Cryptogenic	No
P11	M	10	26	16	L	Cryptogenic	No
P12	F	21	41	20	L	Post abscess sequel	IV
P13	M	20	44	24	R	Heterotopic lesion	No
P14	M	1	6	5	R	FCD	IV
P15	M	24	37	13	L	Ischemic sequel	No
P16	M	16	22	6	L	Arteriovenous malformation sequel	I
P17	M	3	46	44	R	FCD	I
P18	M	15	30	15	B	Cryptogenic	IV
P19	M	33	47	14	R	Oligodendroglioma sequel	No
P20	F	1	29	28	L	FCD	I
P21	F	16	27	11	L	FCD	I
P22	F	6	22	16	L	Developmental venous anomaly	No
P23	F	24	42	18	L	Post traumatic sequel	No
P24	M	2	8	6	R	FCD (but MRI negative)	I
P25	F	18	27	9	L	Post traumatic sequel	I
P26	M	17	29	12	R	Arteriovenous malformation sequel	I
P27	M	16	33	17	R	FCD (but MRI negative)	I
P28	M	12	30	18	L	Post traumatic sequel	I
P29	M	0	34	34	R	Cavernoma	IV
P30	M	6	7	1	L	FCD	I
P31	F	3	19	16	L	Cryptogenic	No

Table 2

Cluster	DLPFC	DMPFC	insula	lateral premotor	medial premotor	orbito frontal	MT	LT	VLPFC	VMPFC
1	1,00	0,05	0,00	0,11	0,08	0,05	0,00	0,07	0,00	0,08
2	0,12	0,07	0,06	0,00	0,10	0,27	0,13	0,17	0,11	1,00
3	0,32	0,14	0,17	0,03	0,07	0,97	0,06	0,08	0,03	0,07
4	0,75	0,45	0,00	0,11	0,27	0,31	0,00	0,10	0,77	0,41

Table 3

Ictal signs	Prevalence of ictal signs (number of seizures)				
	pure DLPF (11)	pure VMPF (13)	pure orbitofrontal (16)	global prefrontal (11)	all group (51)
aura	18% (2)	38% (5)	25% (4)	9% (1)	24% (12)
versive signs	0% (0)	31% (4)	25% (4)	27% (3)	22% (11)
tonic/dystonic signs	55% (6)	38% (5)	31% (5)	27% (3)	37% (19)
vocalization	55% (6)	23% (3)	38% (6)	45% (5)	39% (20)
staring/behavioural arrest	18% (2)	38% (5)	25% (4)	36% (4)	29% (15)
speech production/verbal automatism	0% (0)	23% (3)	25% (4)	0% (0)	14% (7)
chapeau/rictus/facial contraction	55% (6)	15% (2)	25% (4)	36% (4)	31% (16)
manipulation/utilization/stereotypies/automatism	82% (9)	62% (8)	69% (11)	73% (8)	71% (36)
negative emotional/affective expression	27% (3)	46% (6)	6% (1)	0% (0)	20% (10)
positive emotional/affective expression	0% (0)	15% (2)	0% (0)	0% (0)	4% (2)
hyperkinetic motor behaviour	55% (6)	38% (5)	44% (7)	27% (3)	41% (21)
integrated gestural motor behaviour	36% (4)	54% (7)	31% (5)	45% (5)	41% (21)
non-integrated gestural motor behaviour	45% (5)	0% (0)	31% (5)	18% (2)	24% (12)
impairment of consciousness	91% (10)	69% (9)	94% (15)	73% (8)	82% (42)
GTCS	0% (0)	8% (1)	0% (0)	9% (1)	4% (2)
clonic	9% (1)	8% (1)	0% (0)	0% (0)	4% (2)