



HAL
open science

Terahertz refractive index-based morphological dilation for breast carcinoma delineation

Quentin Cassar, Samuel Caravera, Gaëtan Macgrogan, Thomas Bücher,
Philipp Hillger, Ullrich Pfeiffer, Thomas Zimmer, Jean-Paul Guillet, Patrick
Mounaix

► **To cite this version:**

Quentin Cassar, Samuel Caravera, Gaëtan Macgrogan, Thomas Bücher, Philipp Hillger, et al.. Terahertz refractive index-based morphological dilation for breast carcinoma delineation. *Scientific Reports*, 2021, 11 (1), 10.1038/s41598-021-85853-8 . hal-03273518

HAL Id: hal-03273518

<https://hal.science/hal-03273518>

Submitted on 25 Nov 2021

HAL is a multi-disciplinary open access archive for the deposit and dissemination of scientific research documents, whether they are published or not. The documents may come from teaching and research institutions in France or abroad, or from public or private research centers.

L'archive ouverte pluridisciplinaire **HAL**, est destinée au dépôt et à la diffusion de documents scientifiques de niveau recherche, publiés ou non, émanant des établissements d'enseignement et de recherche français ou étrangers, des laboratoires publics ou privés.

Terahertz Refractive Index-based Morphological Dilation for Breast Carcinoma Delineation

Quentin Cassar¹, Samuel Caravera³, Gaëtan MacGrogan³, Thomas Bücher², Philipp Hillger², Ullrich Pfeiffer², Thomas Zimmer¹, Jean-Paul Guillet¹, and Patrick Mounaix^{1,*}

¹Integration: from Material to Systems Laboratory, University of Bordeaux, Talence, 33405, France

²Institute for High-Frequency and Communication Technology, University of Wuppertal, Wuppertal, 42119, Germany

³Bergonié Institute, Department of Pathology, Bordeaux, 33076, France

*patrick.mounaix@u-bordeaux.fr

ABSTRACT

This paper reports investigations led on the combination of the refractive index and morphological dilation to enhance performances towards breast tumour margin delineation during conserving surgeries. The refractive index map of invasive ductal and lobular carcinomas were constructed from an inverse electromagnetic problem. Morphological dilation combined with refractive index thresholding was conducted to classify the tissue regions as malignant or benign. A histology routine was conducted to evaluate the performances of various dilation geometries associated with different thresholds. It was found that the combination of a wide structuring element and high refractive index was improving the correctness of tissue classification in comparison to other configurations or without dilation. The method reports a sensitivity of around 80% and a specificity of 82% for the best case. These results indicate that combining the fundamental optical properties of tissues denoted by their refractive index with morphological dilation may open routes to define supporting procedures during breast-conserving surgeries.

1 Introduction

1 Terahertz imaging and spectroscopy have rapidly spread to different application areas thanks to the continued development of
2 efficient emitters and detectors between 0.1 and 7-THz¹. The biomedical field is one domain of study that could benefit from
3 terahertz wave properties^{2,3}. Radiations at terahertz frequencies have been shown to be non-ionizing and non-hazardous for
4 biological tissues at the power commonly employed to inspect the super-cellular level⁴. Besides, terahertz radiations are notably
5 sensitive to the presence of polar molecules such as the most abundant component of the body: water⁵. Hence, different medical
6 topics have been assessed with terahertz imaging and spectroscopy to look for alternative and complementary methods to the
7 existing ones. These investigations cover a broad range of possible surgical and clinical applications⁶⁻⁸. Among them, cancer
8 diagnosis remains the most widely investigated topic throughout the literature, covering blood^{9,10}, brain¹¹⁻¹³, colorectal^{14,15},
9 gastric^{16,17}, liver⁶, lung¹⁸, oral¹⁹, skin^{20,21} and breast cancer²²⁻²⁶.

10 Investigations, conducted on breast cancer, mainly aim to develop supporting procedures for breast-conservative surgeries
11 through breast tumour margin delineation. The success of breast-conserving surgeries is dictated by the accuracy of delineating
12 the concentric margins of excised breast volumes. Although there is no clear description of what ideal margins are, it is
13 recommended that no cancer cells remain adjacent to any inked edge/surface of the specimen²⁷. Conserving surgeries are
14 usually followed by postoperative radiation management to eradicate microscopic remains of disease²⁸. Margin cleanliness is
15 assessed via biopsy examinations during which excised volumes are subsequently fixed into formalin solution, embedded into
16 paraffin, sliced in micrometric sections and immersed into different alcohol and biological stain baths. Usually, hematoxylin
17 and eosin stains are used. The reason for that is that hematoxylin stains cell nuclei blue and eosin stains both the cytoplasm and
18 the extracellular matrix pink. The stain draws the global layout of a tissue structure so that a pathologist judges the cleanliness
19 of the margin²⁹. Overall, two extreme cases of margin delineation can be observed: (i). positive margins - malignant cells
20 are located at the edge of the excised volume; (ii). negative margins - an absence of tumor cells at the edge or the distance of
21 abnormal cells from the edge is at least more than 1-mm. Following histopathologic inspection, up to 20% of excised breast
22 samples are reported to exhibit positive margins³⁰. Reasons behind tumor edge delineation failure are often presence of *in situ*
23 carcinoma at close proximity to the surgical margin, discontinuous tumor spread from the original surgery site, or inappropriate
24 presurgical tumor localization and inappropriate excision during surgery³¹. A positive margin inevitably leads to a second
25 surgery to favor low recurrence risk and to attain more widely clear surgical margins. In return, a second surgery concomitantly
26 increases the morbidity rate.

27 So far, different research teams worldwide have reported the ability of terahertz imaging and spectroscopy to discriminate

28 between healthy and malignant breast tissues. These studies were primarily conducted on formalin-fixed and paraffin-embedded
29 breast tissues³²⁻³⁴. Such investigations opened the route for clinical studies on freshly excised breast volumes^{18,22,24}. The
30 capabilities of terahertz radiation demarcation between normal and abnormal tissue regions were originally attributed to
31 free-water content. Indeed, free-water molecules have been proven to present a specific permittivity step around 900-GHz⁵.
32 Moreover cancer tissues are known to exhibit a greater free-water content than normal tissues³⁵. However, further studies have
33 suggested that the origin of contrast could not be solely attributed to water. That is because specific dielectric features exhibited
34 by breast tissues, in the low terahertz frequency band, were not observed in water dielectric profile³⁶. Hence, it has been
35 suggested that, specific functional groups play a potential role²². Globally, the refractive index of breast cancer tissues has been
36 shown to be higher than the one observed for normal tissues over the terahertz band. On the contrary, the related absorption
37 coefficient was reported as unsatisfactory parameter for demarcation^{36,37}. Additionally, the contrast level between healthy and
38 malignant tissues depends on cancer cell density. In fact, while the resolution of any light-based imager remains dictated by
39 the diffraction limit, two objects separated by a distance less than the wavelength cannot be distinguished. For instance, the
40 spatial resolution of a far-field imaging system operating at 1-THz will be limited to 0.3-mm. Hence, the respective response to
41 the external terahertz radiation stimuli of two biological entities, separated by a distance smaller than 0.3-mm, will have to be
42 averaged. Considering the typical diameter of the eukaryotic cell is at the order of tens of microns, it can be concluded that,
43 such a terahertz imager cannot manage to resolve entities at the cellular level. **It has, however, been demonstrated that the use
44 of computational imaging system operating in a total internal reflection geometry could resolve features with a sub-wavelength
45 lateral resolution.**³⁸ While it can be expected that high densities of cancer cells will lead to a well-defined demarcation, the
46 dielectric response of isolated abnormal groups may be blurred by the healthy surrounding and ultimately leading to recognition
47 analysis failure. Although the diffraction limit of resolution may complicate recognition in areas sparsely populated by cancer
48 cells³⁹, it also raises delicate questions on the exact frontier between two well localized normal and abnormal regions. Indeed,
49 rather than depicting a sharp contrast between areas, the obtained cliché may inevitably exhibit a smooth gradient from one to
50 another area which is a result of class-overlapping. That is particularly limiting when it comes to providing a pixel-by-pixel
51 diagnosis based on the information collected.

52 The present work proposes a new approach for the clinical classification of breast tissue pixels that overcomes the limitations
53 aforementioned. The method is based on the extraction of the terahertz refractive index map of freshly excised samples followed
54 by morphological dilation. A high value of the refractive index has been reported as a reliable measure of the presence of cancer
55 within a tissue^{22,24}. Morphological dilation is a part of set-theory⁴⁰ and is commonly employed to images having characteristics
56 of ambiguity and vagueness⁴¹. It consists of expanding a given shape contained in the input image. In biology, morphological
57 processing was notably employed for counting blood cells during blood smear test⁴², to isolate female gametocyte⁴³ or for skin
58 cancer segmentation⁴⁴.

59 Operating dilation from regions exhibiting a higher refractive index should allow bypassing class-overlapping limitations.
60 Such a process is referred to as terahertz refractive index-based morphological dilation and operates as follows: (i). the refractive
61 index map of a freshly excised breast tissue is extracted through a specific objective function minimization; (ii). a refractive
62 index threshold is defined such that pixels exhibiting a refractive index higher than the threshold are classified as malignant
63 while others are classified as benign; (iii). morphological dilation is used to spread the malignant zones to the neighborhood.

64 To conduct these investigations, different freshly excised breast tissues have been scanned in reflection geometry by means
65 of a terahertz spectrometer. The refractive index maps have been extracted. Different refractive index thresholds and dilation
66 shapes have been tested. The related pixel classifications have been compared to those provided by a pathologist. Finally, the
67 sensitivity and specificity of each combination of threshold - dilation shape have been derived.

68 The paper is organized as follows: Section 2 describes the experimental framework to acquire raw terahertz images
69 of the freshly excised breast tissues. Section 3 describes the mathematical background to extract the refractive index map.
70 Section 4 defines the morphological dilation and the respective dilation shapes employed in the study. Section 5 describes the
71 registration of obtained images with respect to the pathological cliché. Section 6 details the evaluation of compliance between
72 the classifications provided respectively by the pathologist and the reported strategy. Section 7 presents the results for different
73 samples. Finally, Section 8 presents the conclusions.

74 2 Experimental Framework

75 *The experimental protocol was assessed and approved by the ethics committee of the Bergonié Institute. Human tissue analysis
76 have been conducted in view of the fundamental ethical principles as stipulated in the Helsinki declaration and its later
77 revisions. Written informed consent from each patient undergoing breast surgery was collected, stipulating their agreement
78 regarding the use of their tissues for research purposes.*

79 2.1 Breast Tissue Samples

80 Following surgery, breast excisions were cut into slices of a few millimeters and kept into physiological serum before
81 measurement to ensure the moisture content and delay the necrosis. A maximum of one hour elapsed between the end of
82 surgery and the terahertz acquisition starting time. Once measurement was complete, excised tissue samples were placed
83 in formalin-buffered solution. This process enabled the further histology routine to compare the diagnoses provided by the
84 reported method and the pathologist. **Biological samples analyzed using the method about to be reported were obtained from**
85 **three different patients. One sample was excised from each of these patients.**

86 2.2 Measurement Setup

87 Time-domain terahertz pulsed images were acquired with a TPS3000 spectrometer (TeraView Ltd, Cambridge, UK) operating in
88 reflection geometry. In such systems, terahertz pulses are generated from the activation of a GaAs photoswitch. A photoswitch
89 consists of a discontinuous metallic antenna patterned onto a photoconductive layer. Ultra-fast near-infrared pulses with an
90 energy greater than the semiconductor band gap are focused onto the gap between the two electrodes forming the photoswitch.
91 The incident pump laser thus propagates within the photoconductive layer and generates electron-hole pairs due to absorption.
92 Those photocarriers are then accelerated within the electric field of the biased antenna. The acceleration of these charges
93 produces a transient current that drives the metallic antenna and is eventually emitted as a broadband terahertz pulse. The
94 bandwidth directly depends on the lifetime of the carriers before recombination. The carrier lifetime in the GaAs crystal is in
95 the subpicosecond scale, hence enabling pulses with a bandwidth ranging from 200-GHz to 2-THz.

96 The schematic of the experimental set-up is given in Figure 1. The route of the terahertz pulses is governed by two planar
97 mirrors and a knife-edge right-angle prism mirror (KERAPM). The terahertz pulses are focused on the tissue sample supported
98 by a 2-mm thick non-birefractive C-cut sapphire substrate (see Supplementary Information, Supplementary Fig. 1.) via a
99 polytetrafluoroethylene (PTFE) lens. The maximum incident angle of the terahertz pulses is 10° . Both the reflections at the
100 air-sapphire and sapphire-tissue interfaces are then focused onto a photoconductive antenna detector. The detector is sourced
101 from the same ultra-fast near-infrared pulses used for terahertz wave generation with a beam splitter. The pulses are, however,
102 delayed in time with a mechanical delay line. The periodic variation of the delay line length allows a time gated detection of
103 terahertz pulses reflected by the object. In order to reduce the natural absorption of terahertz pulses by water vapor molecules,
104 the terahertz route is confined within nitrogen chamber.

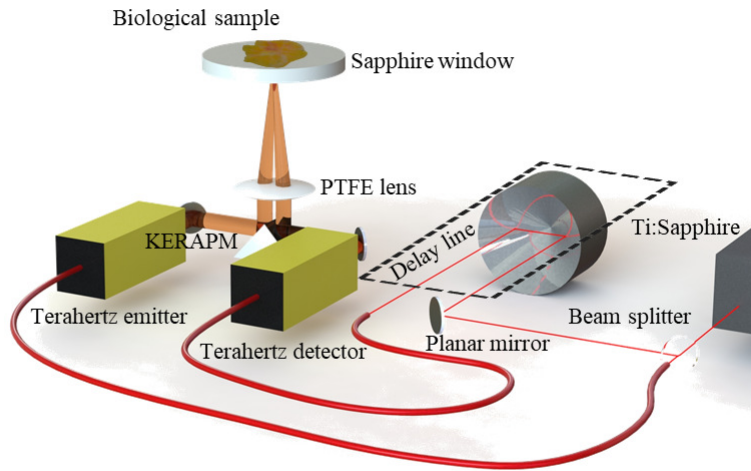


Figure 1. Schematic of the acquisition system.

105 3 Refractive Index Map

106 To extract the refractive index from a raw frequency image, a reference electric field has to be recorded. The reference electric
107 field $E^r(\omega)$ refers to the electric field generated by the acquisition system. The reference measurement records the electric field
108 of the reflection from a metal plate that is located where the sapphire substrate sample holder is aimed to be positioned for
109 tissue imaging. From the reference electric field $E^r(\omega)$, the experimental transfer function $T^s(\omega)$, which is a measure of the
110 disturbance experienced by the incident field as a result of the interaction with the sample, can be calculated:

$$T^s(\omega) = \frac{E^s(\omega)}{E^r(\omega)}, \quad (1)$$

111 with $E^s(\omega)$ the sample frequency-dependent electric field. The shape of transfer function $T^s(\omega)$ is a function of the
 112 refractive index $n(\omega)$ and the extinction coefficient $\kappa(\omega)$ of the sample under inspection. $E^s(\omega)$ depends on the Fresnel's
 113 coefficients in transmission $T(\omega)$ and in reflection $R(\omega)$, and on propagation coefficients $P(\omega, d)$:

$$E^s(\omega) \propto T_{air-sapphire}(\omega) \times R_{sapphire-tissue}(\omega) \times T_{sapphire-air}(\omega) \times P_{sapphire}^2(\omega, d), \quad (2)$$

114 with d being the thickness of the sapphire substrate. The Fresnel's coefficients $T(\omega)$ and $R(\omega)$, as well as propagation
 115 terms $P(\omega, d)$ relate to the refractive index $n(\omega)$ and the extinction coefficient $\kappa(\omega)$ through:

$$T_{a-b}(\omega) = \frac{2\hat{n}_a}{\hat{n}_a + \hat{n}_b}, \quad (3a)$$

$$R_{a-b}(\omega) = \frac{\hat{n}_a - \hat{n}_b}{\hat{n}_a + \hat{n}_b}, \quad (3b)$$

$$P_a(\omega, d) = e^{-j\frac{\omega d}{c}\hat{n}_a}, \quad (3c)$$

116 where a and b are the indices of the respective medium, \hat{n} is the complex refractive index defined as $\hat{n} = n(\omega) - j\kappa(\omega)$ and
 117 c is the light velocity in vacuum. Although the extinction coefficient $\kappa(\omega)$ is involved in the calculation of the transfer function
 118 $T^s(\omega)$, no significant differences have been reported in the literature between normal and abnormal tissue extinction^{22,36}.
 119 Hence, solely the refractive index is further considered as a possible intrinsic parameter for demarcation.
 120

121 3.1 Map Extraction

122 The extraction of the complex refractive index $\hat{n}(\omega)$ at each pixel from the experimental transfer function $T^s(\omega)$ can be
 123 performed by solving an inverse electromagnetic problem. Inverse electromagnetic problems usually minimize a specific convex
 124 objective function. This function denotes the discrepancies between the experimental waveform $E^s(\omega)$ and the waveforms
 125 $E_x^c(\omega)$ successively computed from a set of candidate parameters, where the x -index refers to the x^{th} -candidate tested. The
 126 candidate waveforms $E_x^c(\omega)$ are computed as stipulated in⁴⁵. The corresponding transfer functions $T_x^c(\omega)$ are calculated in the
 127 same way as described by (1). The measures of discrepancies $\delta M_x(\omega)$ between the experimental transfer function $T^s(\omega)$ and
 128 the computed transfer functions $T_x^c(\omega)$ are defined as:

$$\delta M_x(\omega) = \ln\left(\frac{|T^s(\omega)|}{|T_x^c(\omega)|}\right). \quad (4)$$

129 The natural logarithmic ratio is favored here instead of standard difference as it is more penalizing. Finally, the objective
 130 function $\chi(\omega)$ to be minimized is defined as:

$$\chi(\omega) = \delta M(\omega) \times \delta M(\omega). \quad (5)$$

131 The minimization of the transfer function is subject to the following set of candidate parameters:

$$\min_{n(\omega), \kappa(\omega)} \chi(\omega), \text{ subject to } \begin{cases} n \in [1.5; 3], \text{ with } \Delta n = 1.10^{-2}, \\ \kappa \in [0; 1], \text{ with } \Delta \kappa = 1.10^{-3}. \end{cases} \quad (6)$$

132 It was stated before that the sample is maintained by the sapphire substrate. Instead of extracting the properties of the
 133 sapphire substrate for each pixel, the properties were extracted upstream, in absence of a sample, and following the same
 134 minimization process. The sapphire properties are provided in Supplementary Information, see Supplementary Fig. 2. Finally,
 135 applying the above process to each electric field stored in each pixel of the sample image allows to construct the refractive
 136 index map.

137 Once the refractive index map is obtained, it is converted to a binary map that shows areas that are considered malignant or
 138 benign. To do so, a threshold among the refractive index vector has to be set. Depending on the defined value for the threshold,
 139 one may progressively increase or decrease the extent of areas classified as malignant, since pixels with a refractive index
 140 higher than the threshold are classified as cancerous. A schematic of the process is given in Figure 2.

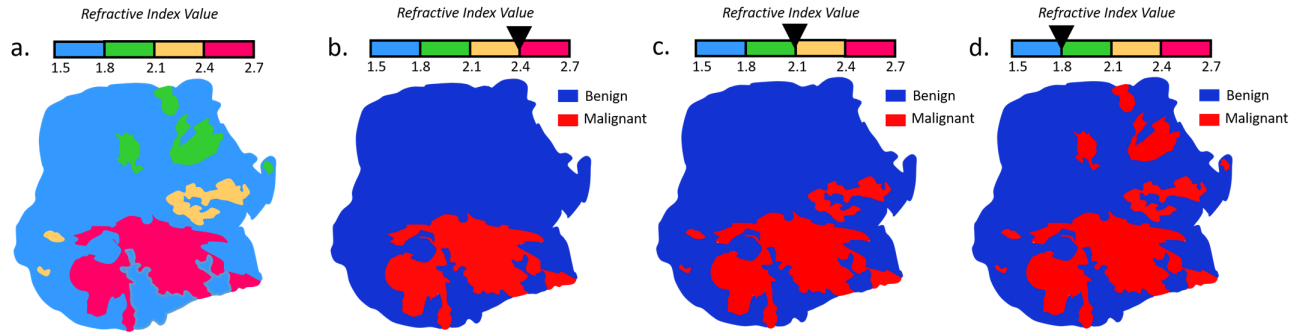


Figure 2. Thresholding principle applied to the refractive index map. a: Schematic refractive index map; b: Binary refractive index map with a threshold set at 2.4; c: Binary refractive index map with a threshold set at 2.1; d: Binary refractive index map with a threshold set at 1.8;

3.2 Operating Frequency

Although the refractive index is often referred to as optical constant, its profile varies as a function of the frequency. Previous studies have reported the terahertz frequency dependent refractive index values of abnormal and normal breast tissues³⁷. Overall, the global difference between these values was shown to be the highest between 300-GHz and 700-GHz, roughly. Hence, rather than investigating the entire band, the classification was operated at 550-GHz, as a good trade-off between signal-to-noise ratio (SNR) and higher frequency spatial resolution⁴⁶. However, naively classifying pixels via the refractive index exhibited at 550-GHz may hardly be relevant. In particular, the refractive index extracted at the edges of malignant regions with low density may present values close to the ones of healthy tissues. Therefore, morphological dilation is introduced to overcome this limitation.

4 Morphological Dilation

Prior to dilation, the refractive index map is converted to a binary image as it was described in the previous section. The dilation can therefore be referred to as binary dilation. The dilation consists of a shift-invariant addition, denoted “ \oplus ”, within the meaning of Minkowski⁴⁷. Mathematically, let’s define P as an ensemble that contains the pixels (x,y) of the tissue imaged. The binary dilation $\partial_{\Lambda}(P)$ of P by a shape $\Lambda \in \mathbb{Z}^2$ - also referred to as a structuring element, is given by:

$$\partial_{\Lambda}(P) = P \oplus \Lambda = \{x + \lambda, y + \lambda | \lambda \in \Lambda\}, \quad (7)$$

where $\lambda \in \Lambda$ produces the translation from P to $\partial_{\Lambda}(P)$. Supposing the matrix P and the structuring element Λ as represented in Figure 3, the matrix $\partial_{\Lambda}(P)$ is obtained by superimposing the center of Λ aligned with each pixel in P that has a value of 1.

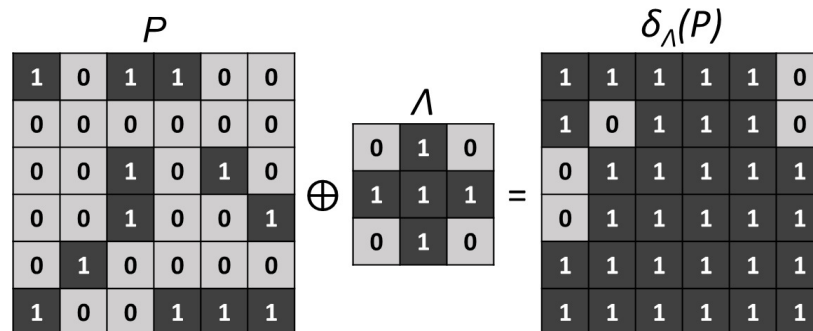


Figure 3. Morphological dilation operated with a cross structuring element Λ on the matrix P .

In the present work, three different structuring elements have been considered to dilate the binary refractive index map. They are referred to as Λ^1 , Λ^2 and Λ^3 classifiers. Their spatial properties are exposed in Figure 4. **These specific geometries allow the classifiers to act in the close vicinity of a starting pixel and with the same impact in all directions.**

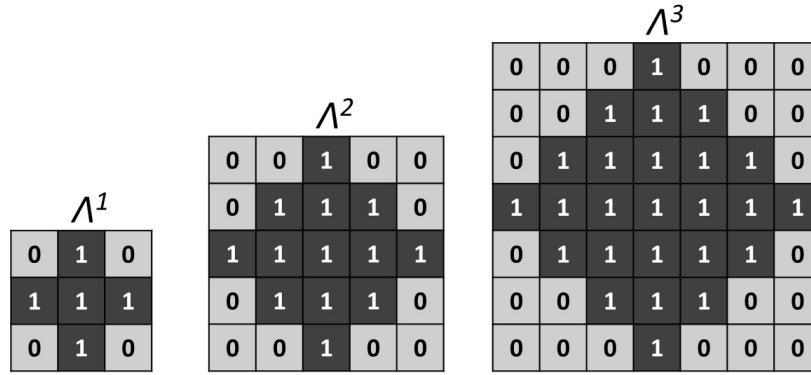


Figure 4. Geometry of the three different classifiers Λ^1 , Λ^2 , Λ^3 .

160 Therefore, depending on the classifier considered, a pixel may be attributed to the malignant group if at least one of the
 161 component λ of the structuring element Λ^n – where $n \in \mathbb{N}^*$ – reports a pixel whose refractive index is higher than the defined
 162 refractive index threshold. Alternatively, the structuring elements can be seen as the area of influence of a cancerous pixel.
 163 Consequently pixels with a refractive index lower than the threshold but situated in such an area of influence, are turned into
 164 malignant pixels. It is however important to note that the process is constrained to a unique dilation and therefore, newly
 165 classified malignant pixels cannot, in turn, exercise a zone of influence.

166 In order to carry out the dilation and the registration steps that follow, it is essential to preserve the morphology of the
 167 imaged sample. To do this, the dilation procedure must be carried out with respect to the initial contour of the sample generated
 168 from a standard contouring algorithm, thus preventing the appearance of cancerous pixels outside the original surface of the
 169 sample. A schematic of the dilation process operated on a binary refractive index map is given in Figure 5.

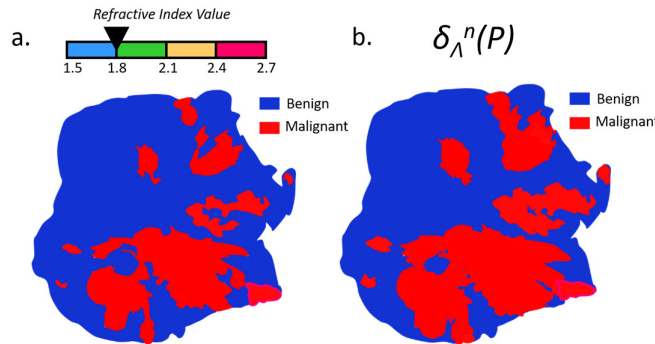


Figure 5. Schematic of a morphological dilation applied to a binary refractive index map over a tissue sample. a: Binary refractive index map with a threshold set at 1.8; b: Morphological dilation applied to the binary refractive index map with an arbitrary classifier Λ^n .

170 5 Image Registration

171 The classification images provided by the reported method and the ones given by the pathologist do not share the same
 172 coordinate system. Image registration is the process of migrating different images into one common coordinate system⁴⁸.
 173 Therefore, image registration is necessary to enable the comparison between the data sets. Effectively, the spatial resolution
 174 of the optical microscope used to acquire pathology clichés is far greater than the one of the employed terahertz imager.
 175 Additionally, the orientation of the tissue sample in the terahertz image and in the clinical image are expected to be different, as
 176 they are not acquired with the same angle. A simple pixel-by-pixel comparison is therefore not possible as it stands. Prior to
 177 comparison, images have to be resized and reorientated. The registration process is feature-based and solely involves image
 178 contours to avoid unintentional human bias. The different steps that are followed to register the images with respect to each
 179 other are hereafter described.

180 **5.1 Contouring**

181 Contour lines, also called isolines, can be calculated by interpolating the value of the scalar field found at each point of each
182 pixel. An infinite number of isolines can however be delineated. The choice of the contour to define the spatial extent of the
183 sample in the image remains therefore subjective. For each sample, the isoline that suited the visualized tissue area best was
184 determined by carefully comparing the terahertz image and the different contour levels.

185 **5.2 Resizing**

186 As the resolution of the images is different, it is necessary to resize the histology pictures. To do so, a bicubic interpolation is
187 operated onto pathology images. Contrary to the previous interpolation, where it is based on the four nearest pixels, bicubic
188 interpolation takes into account a neighborhood of sixteen pixels. Therefore, bicubic interpolation provides a smoother histology
189 slide than simple bilinear interpolation.

190 **5.3 Reorientation**

191 First, the contour of the terahertz image is manually and progressively twisted to bring it closer to the twist angle of the pathology
192 contour. Once the orientations approximately match, the pathology contour is iteratively rotated to establish the correlation
193 between the two contour matrices at each step. Basically, it consists in determining the Pearson's correlation coefficients⁴⁹. The
194 rotation angle providing the highest positive correlation is selected and the terahertz image is correspondingly rotated. The flow
195 chart of these three pre-treatments, namely contouring, resizing and reorientation for image registration is provided in Figure 6.

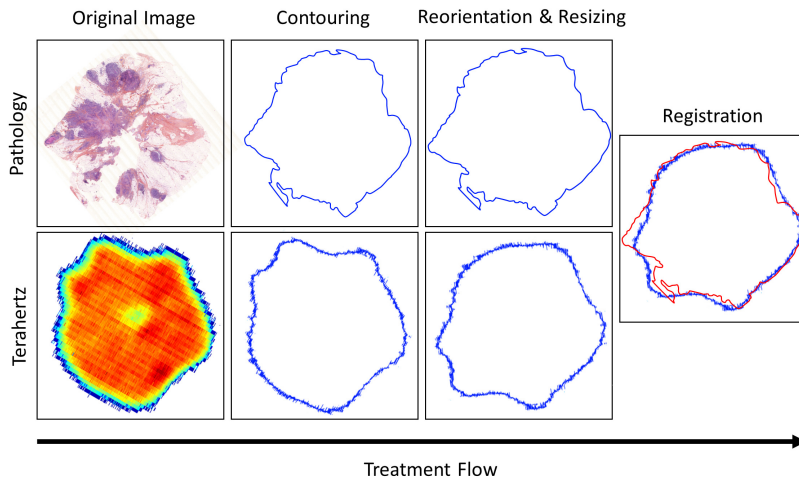


Figure 6. Flow chart of the registration procedure for predicted diagnosis evaluation.

196 **5.4 Image Discrepancies Issues**

197 Although one can resize and reorientate the two images with respect to each other, the pathology cliché and the terahertz
198 image may not perfectly depict the same information. First, while terahertz imaging is performed directly on freshly excised
199 tissues, the pathology diagnosis is established after the histology routine. Moreover, to obtain the pathology image, the excised
200 tissue is first fixed in neutral buffered formalin, then dehydrated in subsequent alcohol baths with increasing concentrations,
201 then cleared in a solvent before being infiltrated and finally embedded in paraffin wax. At this stage, the processed tissue is
202 encased in a paraffin block that can be sliced in sections of a few microns thickness to be deposited on glass slides. These
203 tissue sections are deparaffinized, rehydrated and subsequently stained with hematoxylin and eosin dyes. Finally, they are
204 dehydrated in alcohol and cleared in a solvent before being mounted with a coverslip. The embedding, the sectioning and the
205 desiccation alter the global structure of the tissues. These alterations are collectively referred as artefacts⁵⁰. Artefacts include
206 loss of tissue area and details, folds and wrinkles or cracks and holes. These alterations may result in misinterpretation as they
207 are modifying the morphological structure of tissues. Alternatively, these artefacts may drastically limit the evaluation of the
208 terahertz classification compliance (see Supplementary Information Supplementary Fig. 3, for an example based on one of the
209 tissue reported by the present work). However, histological slides remain the only available reference picture that allows one
210 to examine the performances of classifier under-test. Overall, there are two ways to deal with such issues: (i). correcting the
211 histology slides at risk of adding artificial information; (ii). comparing directly the terahertz image with the raw pathology
212 image at risk of underestimating the efficiency of the method. The first way would require to morph the pathology image
213 to correspond to the terahertz picture. Some procedures to do so were reported in the literature⁵¹. However, these methods

214 are cumbersome and the evaluation of the histological cliché reconstruction is often complicated since no perfect reference
215 pathology image exists. As terahertz imaging remains a new technology for breast carcinoma delineation, the second approach
216 was favored - at risk of underestimating the efficiency of the classifiers.

217 6 Diagnosis Compliance

218 Following the histology routine, pathology images are colored in different shades of blue and pink. The pathologist draws the
219 contour of malignant areas based on his/her expertise. From the interpretation of the pathologist, the images were binarized and
220 each pixel was classified either as benign or as malignant⁵².

221 Once both diagnosis images exhibit binary information, have the same size and orientation, the compliance between them
222 can be evaluated. In case of discrepancies, the pathologist classification prevails over terahertz delineation. The present section
223 describes how the ability of classifiers was evaluated with respect to the pathologist one.

224 6.1 Performance of the Classification Test

225 As each diagnosis presents a binary information, four different cases can be distinguished:

- 226 i. True negative: both methods classify a pixel as benign;
- 227 ii. True positive: both methods classify a pixel as malignant;
- 228 iii. False positive: the terahertz method stands for a malignant pixel while histology stipulates a benign pixel;
- 229 iv. False negative: the terahertz method stands for a benign pixel while histology stipulates a malignant pixel;

230 Hence, for each refractive index threshold associated with a specific classifier, one can fill the corresponding confusion
231 matrices that highlight the classification procedure performances. In such error matrices, the rows represent the instances in the
232 terahertz class, here the predicted class, while columns represent the actual diagnosis provided by histology examination⁵³.

233 From these matrices, the effectiveness of the classification method is assessed by creating the receiver operatic characteristic
234 (ROC) curve⁵⁴ for each classifier. The ROC curve represents the ability of the classifier to provide the correct diagnosis as
235 the refractive index threshold varies. The ROC curve is obtained by plotting the true positive rate (TPR) as a function of the
236 false positive rate (FPR). The TPR is defined as the number of true positives divided by all pixels classified by the pathologist
237 as positives: true positives and false negatives. The FPR is defined as the number of false negatives divided by all pixels
238 classified by the pathologist as negatives: false positives and true negatives. It can also be thought as a plot of the sensitivity
239 - that is equivalent to the TPR defined in equation (8), against the probability of false-alarm - that can be calculated as (1 -
240 specificity) and defined in equation (9)⁵⁵. These measures of performances are favored as they are not sensitive to changes in
241 data distributions, compared to accuracy and to error rate. Hence, both metrics can be used with imbalanced data⁵⁶.

$$\text{True Positive Rate} = \text{Sensitivity} = \frac{\text{True Positives}}{\text{True Positives} + \text{False Negatives}}, \quad (8)$$

$$\text{False Positive Rate} = 1 - \text{Specificity} = \frac{\text{False Positives}}{\text{False Positives} + \text{True Negatives}}. \quad (9)$$

242 To complement these measures, the area under each ROC curve (AUC) is calculated as it relies on the performance of score
243 classifiers for all possible classification thresholds⁵⁷.

244 Finally, the best discrimination thresholds are selected as the ones that provide the highest sensitivity while preserving the
245 healthy tissue area from false diagnosis, *i.e.* specificity. It is noted that the aforementioned classification procedure is studied for
246 the specific case of breast conserving surgery. Hence, it is essential to preserve the healthy area while removing the malignant
247 zones. Ultimately, the best classifiers are selected as the ones that provide the highest measure of $TPR - FPR$, since higher
248 values of this function indicates more accurate results.

249 7 Results

250 In this section, the classifiers are employed to evaluate their effectiveness on three freshly excised breast tissues. Two of these
251 samples were diagnosed as invasive ductal carcinoma (IDC) and one was identified as an invasive lobular carcinoma (ILC).
252 These samples are referred to as test sample TS#1, TS#2 and TS#3.




Figure 7. Sample TS#1. (i). Pathology image and correlated view of the respective zones a, b, c and d; (ii). Pathology mask; (iii). Raw terahertz image at 550-GHz; (iv). Refractive index map at 550-GHz.

7.1 TS#1

TS#1 is an invasive ductal carcinoma. The pathology image with some enlightened pathology areas, the pathology mask, the raw terahertz image obtained at 550-GHz and the correlated refractive index map are presented in Figure 7.

It can be observed that the raw terahertz image as well as the refractive index map exhibits specific features that correspond to the pathology image. Regions depicted in Figure 7.a. and Figure 7.b. correspond to fibrous tissues that are included in an adipose matrix. Such regions are therefore expected to globally give rise to a lower refractive index than the one classified as malignant as depicted in Figure 7.c. and Figure 7.d. Although such a refractive index seems overall lower than the refractive index of the tumour, it remains relatively close to it. Therefore, classifying only on the basis of the refractive index would certainly prove to be inefficient. The sensitivity and the specificity of each structuring element classifier for varying refractive index threshold were calculated for TS#1. The corresponding ROC curves and $TPR - FPR$ functions are given in Figure 8.

Each Λ^n -dependent ROC curve is located to the left of the $TPR = FPR$ line in Figure 8, proving that the fraction of true positives is greater than the proportion of false positives. It is clear that the use of the refractive index alone as a classifier (Λ^0) is shown to be less efficient than associating the refractive index with a classifier. Such a statement is not surprising as the classification does not consider the neighborhood. While on ROC graphics, depicted in Figure 8, it does not seem that obvious which classifier among Λ^1 , Λ^2 and Λ^3 performs well, the $TPR - FPR$ visualization indicates that the structuring element Λ^3 in association with a high refractive index threshold by about 2.6 is the most efficient rule of classification. The association provides a classification with a sensitivity by around 80% and a specificity of 82%. What is more, the wider the structuring element, the higher the refractive index has to be set for good performances. Effectively, starting with a high refractive index makes it possible to identify, in a first instance, tissue areas densely populated with cancer cells, while a broad structuring element makes it possible to efficiently spread the identification over a wide zone.

The corresponding AUC for each ROC curve, the $TPR - FPR$ value, the sensitivity and the specificity for the first two best refractive index thresholds are given in Table 1 (see Supplementary Information, Supplementary Table 1. for the complete list of performances). While Λ^1 and Λ^2 are less efficient than Λ^3 for both sensitivity and specificity, the Λ^0 classifier provides a slightly greater sensitivity for a threshold of 2.1, by about 83%. However, the gain of 4% in sensitivity with respect to Λ^3 costs concomitantly 20% in method specificity. Reasonably, this gain is not worth it, considering such a drastic decrease in classification specificity. Alternatively, if one wants to increase the sensitivity while maintaining specificity at a reasonable level, second best thresholds may offer a promising substitute. On using the second best threshold provided by Λ^3 of 2.5, an increase of 7% in sensitivity conjointly leads to a decrease by about 12% in specificity. By doing so, one reaches a sensitivity of 86%.

The superimposition of the classification images from the reported method and the clinical one, corresponding to the performances listed in Table 1 are given in Figure 9.

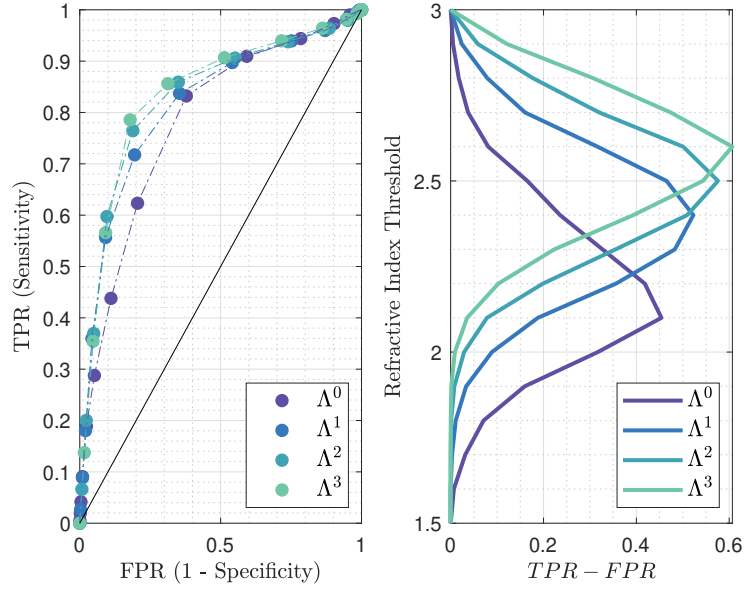


Figure 8. Left: receiver operating characteristic for the different classification methods, at 550-GHz applied to TS#1. The black line stands for $TPR = FPR$. Right: Refractive index threshold as a function of the $TPR - FPR$ measure for the different classifiers.

Table 1. Statistical measure of the performance of the classifiers and AUC. The sensitivity and specificity obtained for the best performing classifier - refractive index threshold association is given in bold.

Classifier	Λ^0		Λ^1		Λ^2		Λ^3	
AUC	0.7804		0.8149		0.8285		0.8360	
RI-Threshold	2.1	2.2	2.4	2.3	2.5	2.4	2.6	2.5
TPR - FPR	0.4540	0.4181	0.5227	0.4829	0.5759	0.5093	0.6068	0.5433
Sensitivity-%	83	62	72	84	76	86	79	86
Specificity-%	62	79	81	65	81	65	82	69

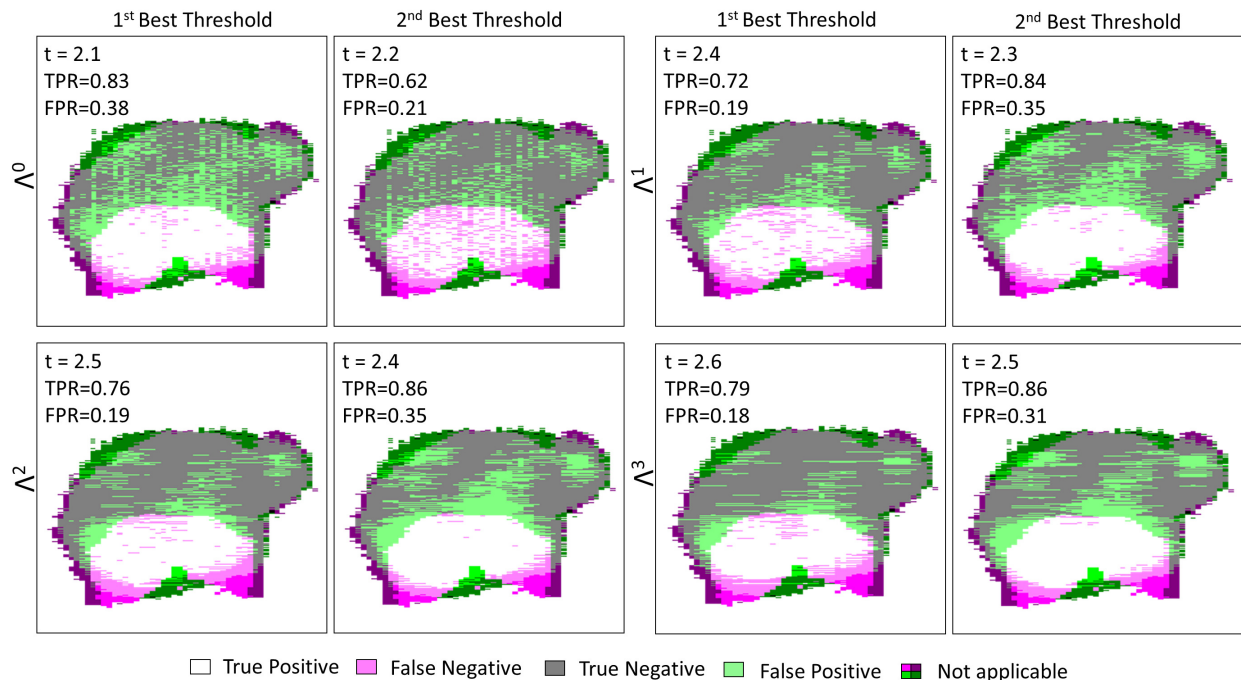


Figure 9. TS#1 tissue sample classification maps at 550-GHz for Λ^0 , Λ^1 , Λ^2 , Λ^3 and their respective first two best thresholds. “Not applicable” refers to regions where the binary pathology classification and the binary terahertz classification image do not match spatially. The values listed in each box are respectively standing for the refractive index threshold, the true positive rate and the false positive rate.

284 **7.2 TS#2**

285 TS#2 sample is an invasive ductal carcinoma from which a 67 years old woman was suffering. The initial tumor site was
 286 found to be roughly 100 mm². On Figure 10, the pathology image with some enlightened pathology areas, the pathology
 287 mask, the terahertz image at 550-GHz, and the refractive index map are shown. The pathology image as well as the pathology
 288 mask exhibit the presence of a hole, where no tissue is found. The lack of tissue in the middle of the section is not natural
 289 and enlightens the issues, that have been previously reported towards pathology images. Hence, this specific region is not
 290 considered for performance evaluation.

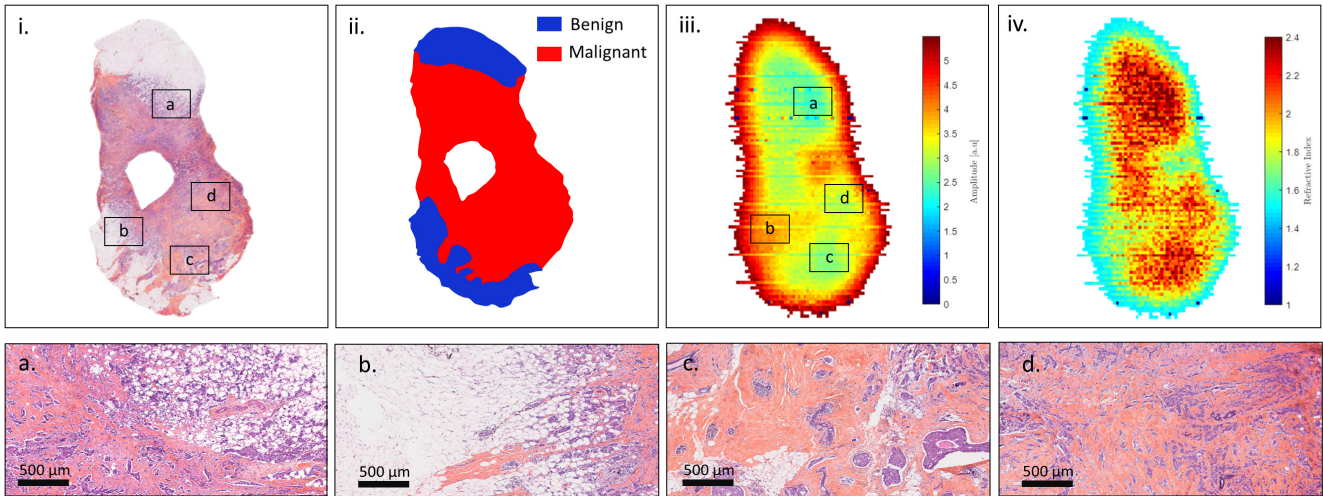


Figure 10. Sample TS#2. (i). Pathology image and correlated view of the respective zones a, b, c and d; (ii). Pathology mask; (iii). Raw terahertz image at 550-GHz; (iv). Refractive index map at 550-GHz.

291 The ROC curves as well as the $TPR - FPR$ function for different classifiers with various thresholds are given in Figure 11.
 292 Similarly to the foregoing, all ROC curves are located to the left of the $TPR = FPR$ line, hence proving that the fraction of true
 293 positives remains greater than that of false positives.

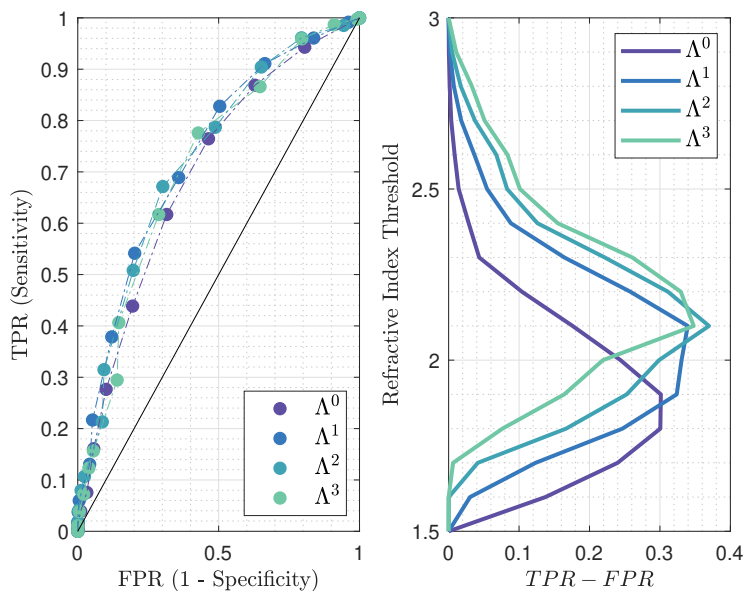


Figure 11. Left: receiver operating characteristic for the different classification methods, at 550-GHz applied to TS#2. The black line stands for $TPR = FPR$. Right: Refractive index threshold as a function of the $TPR - FPR$ measure for the different classifiers.

294 The most effective classifiers towards conserving classification are Λ^2 and Λ^3 , both for a threshold set at 2.1. While the
 295 combination of such a threshold with Λ^2 provides a sensitivity of 67% and a specificity of 70%, the same threshold operating
 296 with Λ^3 gives rise to a sensitivity by about 78% and a specificity of 57%. Hence, tuning the structuring element geometry
 297 would offer an interesting trade-off between specificity and sensitivity. The respective performances of each classifier applied
 298 to TS#2 are listed in Table 2 (see Supplementary Information, Supplementary Table 1. for the complete list of performances).

Table 2. Statistical measure of the performance of the classifiers and AUC. The sensitivity and specificity obtained for the best performing classifier - refractive index threshold association is given in bold.

Classifier	Λ^0		Λ^1		Λ^2		Λ^3	
AUC	0.6976		0.7307		0.7264		0.7127	
RI-Threshold	1.9	1.8	2.1	2.0	2.1	2.2	2.1	2.2
TPR - FPR	0.3013	0.3006	0.3395	0.3307	0.3697	0.3113	0.3480	0.3295
Sensitivity-%	62	76	54	69	67	51	78	62
Specificity-%	68	54	80	64	70	80	57	71

299 The classification maps involving each classifier and their respective best performing thresholds are exposed in Figure 12.
 300 These images show the improvement in classification with the use of morphological dilatation. Moreover, they highlight the
 301 difficulties of good prediction at the outer margins. Low performance at the outer margins may come from the non-conformity
 302 of the information in these areas between the terahertz image and the histology picture. The most convincing hypothesis for
 303 this non-conformity is the tissue deformation imposed by the histological routine.

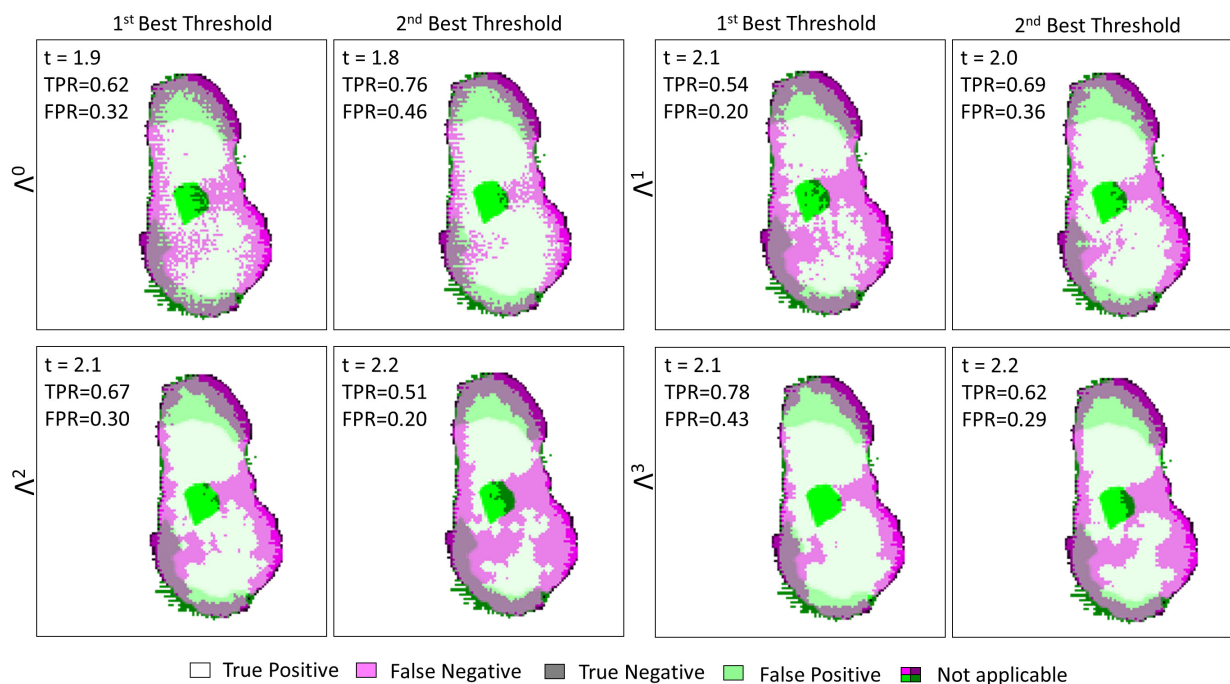


Figure 12. TS#2 tissue sample classification maps at 550-GHz for Λ^0 , Λ^1 , Λ^2 , Λ^3 and their respective first two best thresholds. “Not applicable” refers to regions where the binary pathology classification and the binary terahertz classification image do not match spatially. The values listed in each box are respectively standing for the refractive index threshold, the true positive rate and the false positive rate.

304 7.3 TS#3

305 In contrast to the two previous samples, the TS3 sample was taken from an 83 years old patient with an invasive lobular
 306 carcinoma. On Figure 13, the pathology image with some enlightened pathology areas, the pathology mask, the terahertz image
 307 at 550-GHz, and the refractive index map are shown.

308 The ROC curves plotted in Figure 14 indicate a lower efficiency towards classification than the efficiencies for TS#1 and
 309 TS#2. The cause may be found in the distribution of cancer cells within the malignant zone, in comparison to previously tested

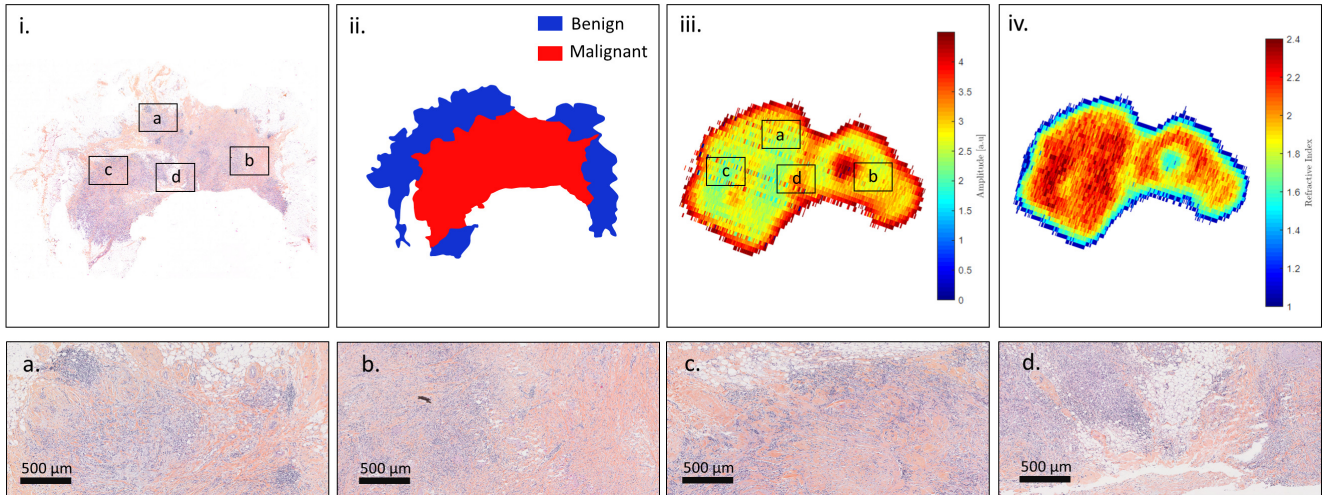


Figure 13. Sample TS#3. (i). Pathology image and correlated view of the respective zones a, b, c and d; (ii). Pathology mask; (iii). Raw terahertz image at 550-GHz; (iv). Refractive index map at 550-GHz.

310 samples. While for other cases the malignant zone was densely populated, cancer cells are found in small quantity and in
 311 an inhomogeneous manner over TS#3. Additionally, the histology routine may have alter the tissue morphology as stated in
 312 section 5.4 *Image Discrepancies Issues*.

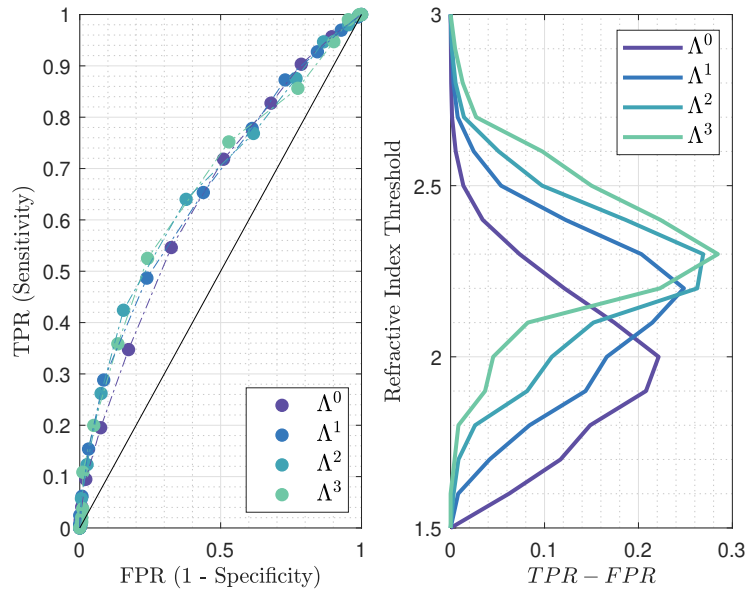


Figure 14. Left: receiver operating characteristic for the different classification methods, at 550-GHz applied to TS#3. The black line stands for $TPR = FPR$. Right: Refractive index threshold as a function of the $TPR - FPR$ measure for the different classifiers.

313 The AUC values and the performances for each classifier are given in Table 3 (see Supplementary Information, Supplementary
 314 Table 1. for the complete list of performances). Despite the lower efficiency the most accurate classifying strategy remains
 315 Λ^3 when associated with a refractive index threshold of 2.3. The $TPR - FPR$ measure is by around 0.28 with a sensitivity
 316 of 53% and a specificity of 76%. As already indicated these performances are below the ones reached for other study cases.
 317 Λ^2 classifier offers a greater specificity of 85% but simultaneously concedes 11% upon sensitivity, thus falling below the
 318 critical threshold of half the number of malignant pixels correctly classified. The weak density of cancer cells within a lobular
 319 carcinoma slice may lead one to opt for Λ^0 classifier operating in association with a low refractive index threshold to maximize

320 the sensitivity, despite a concomitant loss in specificity.

Table 3. Statistical measure of the performance of the classifiers and AUC. The sensitivity and specificity obtained for the best performing classifier - refractive index threshold association is given in bold.

Classifier	Λ^0		Λ^1		Λ^2		Λ^3	
AUC	0.6478		0.6631		0.6695		0.6693	
RI-Threshold	2.0	1.9	2.2	2.1	2.3	2.2	2.3	2.4
TPR - FPR	0.2215	0.2080	0.2484	0.2148	0.2690	0.2626	0.2845	0.2234
Sensitivity-%	55	72	49	65	42	64	53	36
Specificity-%	68	49	76	56	84	62	76	86

321 The corresponding classification images for TS#3 for each classifier and the correlated best refractive index threshold are
 322 demonstrated in Figure 15. The global classification clearly suffers from the spatial discrepancies between the fresh state
 323 tissue and the histological state. Even though such differences are expected to be the main roots behind classification accuracy
 324 weakness, the histological type of TS#3 may also trigger difficulties. It can be assumed that the classification strategy may
 325 provide better performances when applied on ductal carcinoma cases than on lobular ones. However, it is noted that the number
 326 of samples investigated does not allow to assert such a hypothesis.

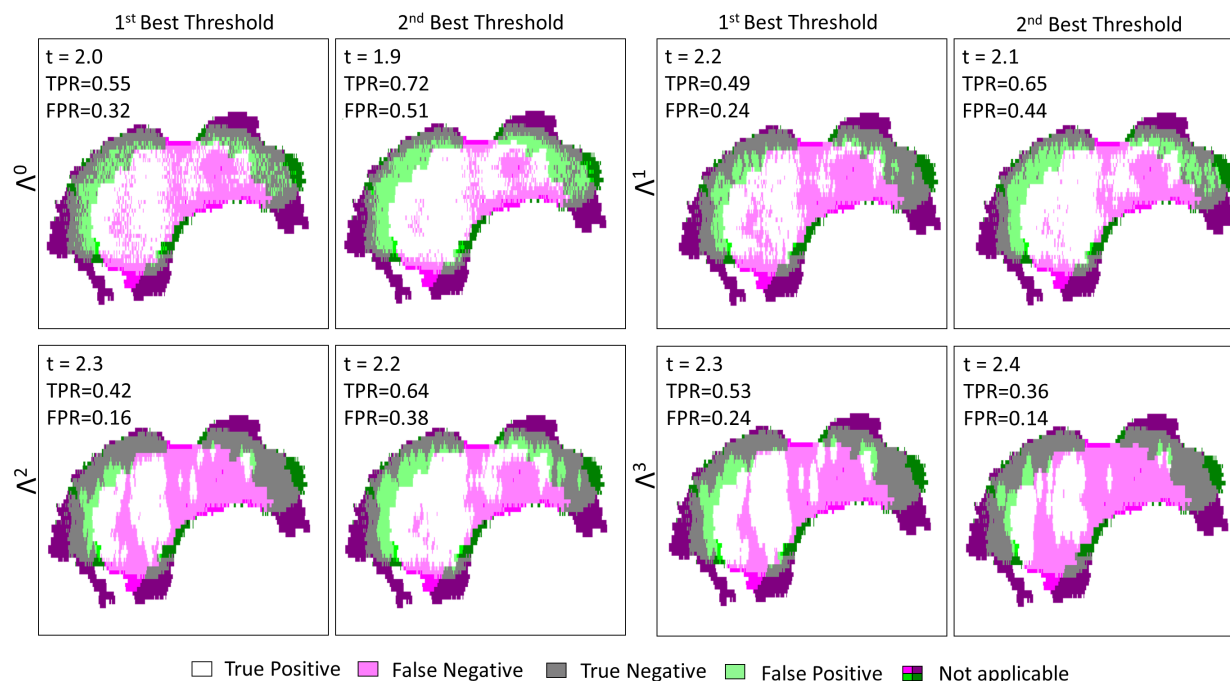


Figure 15. TS#3 tissue sample classification maps at 550-GHz for Λ^0 , Λ^1 , Λ^2 , Λ^3 and their respective first two best thresholds. “Not applicable” refers to regions where the binary pathology classification and the binary terahertz classification image do not match spatially. The values listed in each box are respectively standing for the refractive index threshold, the true positive rate and the false positive rate.

327 8 Conclusions

328 In this paper, a new approach to support breast carcinoma margin delineation during surgeries with terahertz radiations was
 329 proposed. The method relies on the acquisition of the excised samples by means of a terahertz time-domain imager followed by
 330 a segmentation based on the extracted refractive index map at 550-GHz and its morphological dilation. Morphological dilation
 331 was introduced to overcome the weakness of the refractive index alone as a classifier in tissue regions sparsely populated with
 332 cancer cells. Dilation was used to construct a zone of influence of pixels. Hence, tissue areas close to regions identified as
 333 malignant were successfully classified as cancerous despite a refractive index suggesting benign zones.

334 The performances of the classifications were assessed for three different samples. Overall, the association of a high
335 refractive index threshold with a wide dilation has shown to be the most appropriate combination to maintain both method
336 sensitivity and specificity at decent levels for invasive ductal carcinoma. The best performances of the methods have been
337 reported to stand by about 80% in sensitivity and 82% in specificity. On the contrary, the same methodology applied onto an
338 invasive lobular carcinoma showed lower performances. Various hypothesis were drawn to determine the roots for classification
339 failure. While lobular carcinoma are globally less populated by cancer cells than the ductal histology type, pathology image
340 alterations may also have contribute by rendering the diagnosis evaluation tedious.

341 The recognition performances of malignant areas could be improved. Indeed, the terahertz classification has localized
342 false negatives surrounded by true positives. Therefore, implementing an additional and simple processing that classifies as
343 malignant, benign-predicted pixels that are encircled by cancerous ones would enhance the classification accuracy.

344 Although investigations on higher rank classifier, *i.e.* for Λ^n with $n > 3$, have not been conducted, a more efficient structuring
345 element could be found. Nevertheless, a high rank for a structuring element is accompanied by an equally high refractive
346 index threshold. Thus, a reasonable assumption would be that the refractive index suitable for the use of these higher-ranked
347 classifiers lies beyond the optical properties of biological tissues.

348 This preliminary investigation towards terahertz refractive index-based morphological dilation may open the routes to
349 refine strategies to improve the accuracy with which breast tumour margins are delineated. However, the field still stands in
350 its early stages and suffers challenges due to pathology reference image alterations that complicate classification correctness
351 assessment. **Additionally, performance comparison with other classification algorithms are yet to be investigated and will be**
352 **needed to pursue with the proposed methodology.** Finally, and in authors's opinion, the applicability of terahertz waves for
353 breast carcinoma margin demarcation still requires further studies to evaluate its feasibility in the clinical environment.

354 9 Methods

355 Numerical procedures were conducted with in-house software, written with the MatLab development framework. The software
356 follows mathematical procedures described in this paper and our preceding works.

357 Acknowledgements

358 The authors acknowledge the German Research Foundation for funding this work as a part of the Priority Program ESSENCE
359 (SPP 1857). The authors gratefully acknowledge partial financial support for this work from the French Nouvelle-Aquitaine
360 Region. The authors would like to acknowledge Jean-Baptiste Perraud and Dominika Warmowska for fruitful discussions.

361 Author contributions statement

362 Q.C. conceived and conducted the research; S.C. prepared the freshly excised breast samples; G.MG. analyzed the pathology
363 images, provided the histological classification and assured the clinical background of the study; Q.C. wrote the manuscript
364 with input from G.MG., T.B., P.H., U.P., T.Z., J-P.G. and P.M.; P.M. supervised the study. All authors reviewed the manuscript.

365 Additional information

366 **Competing interests:** the authors declare no conflict of interests.

367 References

- 368 1. Dhillon, S. *et al.* The 2017 terahertz science and technology roadmap. *J. Phys. D: Appl. Phys.* **50**, 043001 (2017).
- 369 2. Pickwell, E. & Wallace, V. Biomedical applications of terahertz technology. *J. Phys. D: Appl. Phys.* **39**, R301 (2006).
- 370 3. Romanenko, S., Begley, R., Harvey, A. R., Hool, L. & Wallace, V. P. The interaction between electromagnetic fields at
371 megahertz, gigahertz and terahertz frequencies with cells, tissues and organisms: risks and potential. *J. The Royal Soc.*
372 *Interface* **14**, 20170585 (2017).
- 373 4. Il'ina, I. V., Sitnikov, D. S. & Agranat, M. B. State-of-the-art of studies of the effect of terahertz radiation on living
374 biological systems. *High Temp.* **56**, 789–810 (2018).
- 375 5. Møller, U., Cooke, D. G., Tanaka, K. & Jepsen, P. U. Terahertz reflection spectroscopy of debye relaxation in polar liquids.
376 *JOSA B* **26**, A113–A125 (2009).
- 377 6. Sy, S. *et al.* Terahertz spectroscopy of liver cirrhosis: investigating the origin of contrast. *Phys. Medicine & Biol.* **55**, 7587
378 (2010).

- 379 7. Arbab, M. H. *et al.* Terahertz spectroscopy for the assessment of burn injuries in vivo. *J. biomedical optics* **18**, 077004
380 (2013).
- 381 8. Taylor, Z. D. *et al.* Thz medical imaging: in vivo hydration sensing. *IEEE transactions on terahertz science technology* **1**,
382 201–219 (2011).
- 383 9. Jeong, K. *et al.* Characterization of blood using terahertz waves. *J. biomedical optics* **18**, 107008 (2013).
- 384 10. Reid, C. B., Reese, G., Gibson, A. P. & Wallace, V. P. Terahertz time-domain spectroscopy of human blood. *IEEE journal*
385 *biomedical health informatics* **17**, 774–778 (2013).
- 386 11. Oh, S. J. *et al.* Study of freshly excised brain tissues using terahertz imaging. *Biomed. optics express* **5**, 2837–2842 (2014).
- 387 12. Meng, K. *et al.* Terahertz pulsed spectroscopy of paraffin-embedded brain glioma. *J. biomedical optics* **19**, 077001 (2014).
- 388 13. Yamaguchi, S. *et al.* Brain tumor imaging of rat fresh tissue using terahertz spectroscopy. *Sci. reports* **6**, 30124 (2016).
- 389 14. Reid, C. B. *et al.* Terahertz pulsed imaging of freshly excised human colonic tissues. *Phys. Medicine & Biol.* **56**, 4333
390 (2011).
- 391 15. Eadie, L. H., Reid, C. B., Fitzgerald, A. J. & Wallace, V. P. Optimizing multi-dimensional terahertz imaging analysis for
392 colon cancer diagnosis. *Expert. Syst. with Appl.* **40**, 2043–2050 (2013).
- 393 16. Hou, D. *et al.* Terahertz spectroscopic investigation of human gastric normal and tumor tissues. *Phys. Medicine & Biol.* **59**,
394 5423 (2014).
- 395 17. Ji, Y. B. *et al.* Feasibility of terahertz reflectometry for discrimination of human early gastric cancers. *Biomed. optics*
396 *express* **6**, 1398–1406 (2015).
- 397 18. Brun, M.-A. *et al.* Terahertz imaging applied to cancer diagnosis. *Phys. Medicine & Biol.* **55**, 4615 (2010).
- 398 19. Sim, Y. C., Park, J. Y., Ahn, K.-M., Park, C. & Son, J.-H. Terahertz imaging of excised oral cancer at frozen temperature.
399 *Biomed. optics express* **4**, 1413–1421 (2013).
- 400 20. Woodward, R. M. *et al.* Terahertz pulse imaging in reflection geometry of human skin cancer and skin tissue. *Phys.*
401 *Medicine & Biol.* **47**, 3853 (2002).
- 402 21. Woodward, R., Wallace, V., Arnone, D., Linfield, E. & Pepper, M. Terahertz pulsed imaging of skin cancer in the time and
403 frequency domain. *J. Biol. Phys.* **29**, 257–259 (2003).
- 404 22. Ashworth, P. C. *et al.* Terahertz pulsed spectroscopy of freshly excised human breast cancer. *Opt. express* **17**, 12444–12454
405 (2009).
- 406 23. Chavez, T., Bowman, T., Wu, J., Bailey, K. & El-Shenawee, M. Assessment of terahertz imaging for excised breast cancer
407 tumors with image morphing. *J. Infrared, Millimeter, Terahertz Waves* **39**, 1283–1302 (2018).
- 408 24. Cassar, Q. *et al.* Pilot study of freshly excised breast tissue response in the 300–600 ghz range. *Biomed. optics express* **9**,
409 2930–2942 (2018).
- 410 25. Chavez, T., Vohra, N., Wu, J., Bailey, K. & El-Shenawee, M. Breast cancer detection with low-dimensional ordered
411 orthogonal projection in terahertz imaging. *IEEE Transactions on Terahertz Sci. Technol.* **10**, 176–189 (2019).
- 412 26. Okada, K. *et al.* Terahertz near-field microscopy of ductal carcinoma in situ (dcis) of the breast. *J. Physics: Photonics* **2**,
413 044008 (2020).
- 414 27. Buchholz, T. A. *et al.* Margins for breast-conserving surgery with whole-breast irradiation in stage i and ii invasive breast
415 cancer: American society of clinical oncology endorsement of the society of surgical oncology/american society for
416 radiation oncology consensus guideline. *J. clinical oncology* **32**, 1502–1506 (2014).
- 417 28. Fajdic, J., Djurovic, D., Gotovac, N. & Hrgovic, Z. Criteria and procedures for breast conserving surgery. *Acta Informatica*
418 *Medica* **21**, 16 (2013).
- 419 29. Alturkistani, H. A., Tashkandi, F. M. & Mohammedsaleh, Z. M. Histological stains: a literature review and case study.
420 *Glob. journal health science* **8**, 72 (2016).
- 421 30. Jacobs, L. Positive margins: the challenge continues for breast surgeons. *Annals surgical oncology* **15**, 1271–1272 (2008).
- 422 31. Landercasper, J., Whitacre, E., Degnim, A. C. & Al-Hamadani, M. Reasons for re-excision after lumpectomy for breast
423 cancer: insight from the american society of breast surgeons mastery sm database. *Annals surgical oncology* **21**, 3185–3191
424 (2014).
- 425 32. Hassan, A. M., Hufnagle, D. C., El-Shenawee, M. & Pacey, G. E. Terahertz imaging for margin assessment of breast
426 cancer tumors. In *2012 IEEE/MTT-S International Microwave Symposium Digest*, 1–3 (IEEE, 2012).

- 427 **33.** Bowman, T. C., El-Shenawee, M. & Campbell, L. K. Terahertz imaging of excised breast tumor tissue on paraffin sections.
428 *IEEE Transactions on Antennas Propag.* **63**, 2088–2097 (2015).
- 429 **34.** Cerica, D., Nguyen, D., Hernandez, Y., Verly, J. G. & Boutaayamou, M. Terahertz pulsed imaging of paraffin-embedded
430 human breast cancer tissue. In *2019 44th International Conference on Infrared, Millimeter, and Terahertz Waves (IRMMW-*
431 *THz)*, 1–2 (IEEE, 2019).
- 432 **35.** McIntyre, G. Cell hydration as the primary factor in carcinogenesis: a unifying concept. *Med. hypotheses* **66**, 518–526
433 (2006).
- 434 **36.** Cassar, Q. *Terahertz Radiations for Breast Tumour Recognition*. Ph.D. thesis, Université de Bordeaux (2020).
- 435 **37.** Fitzgerald, A. J. *et al.* Terahertz pulsed imaging of human breast tumors. *Radiology* **239**, 533–540 (2006).
- 436 **38.** Barr, L. E. *et al.* Super-resolution imaging for sub-ir frequencies based on total internal reflection. *Optica* **8**, 88–94 (2021).
- 437 **39.** Hillger, P. *et al.* A 128-pixel system-on-a-chip for real-time super-resolution terahertz near-field imaging. *IEEE J.*
438 *Solid-State Circuits* **53**, 3599–3612 (2018).
- 439 **40.** Jech, T. *Set theory* (Springer Science & Business Media, 2013).
- 440 **41.** Meyer, F. & Beucher, S. Morphological segmentation. *J. visual communication image representation* **1**, 21–46 (1990).
- 441 **42.** Tulsani, H., Saxena, S. & Yadav, N. Segmentation using morphological watershed transformation for counting blood cells.
442 *IJCAIT* **2**, 28–36 (2013).
- 443 **43.** Caponetti, L., Castellano, G., Basile, M. T. & Corsini, V. Fuzzy mathematical morphology for biological image segmenta-
444 tion. *Appl. intelligence* **41**, 117–127 (2014).
- 445 **44.** Lee, H. & Chen, Y.-P. P. Skin cancer extraction with optimum fuzzy thresholding technique. *Appl. intelligence* **40**, 415–426
446 (2014).
- 447 **45.** Cassar, Q. *et al.* Iterative tree algorithm to evaluate terahertz signal contribution of specific optical paths within multilayered
448 materials. *IEEE Transactions on Terahertz Sci. Technol.* **9**, 684–694 (2019).
- 449 **46.** Pfeiffer, U. R. *et al.* Ex vivo breast tumor identification: Advances toward a silicon-based terahertz near-field imaging
450 sensor. *IEEE Microw. Mag.* **20**, 32–46 (2019).
- 451 **47.** Najman, L. & Talbot, H. *Mathematical morphology: from theory to applications* (John Wiley & Sons, 2013).
- 452 **48.** Goshtasby, A. A. *2-D and 3-D image registration: for medical, remote sensing, and industrial applications* (John Wiley &
453 Sons, 2005).
- 454 **49.** Kaur, A., Kaur, L. & Gupta, S. Image recognition using coefficient of correlation and structural similarity index in
455 uncontrolled environment. *Int. J. Comput. Appl.* **59** (2012).
- 456 **50.** Aresta, G. *et al.* Bach: Grand challenge on breast cancer histology images. *Med. image analysis* **56**, 122–139 (2019).
- 457 **51.** Pichat, J., Iglesias, J. E., Yousry, T., Ourselin, S. & Modat, M. A survey of methods for 3d histology reconstruction. *Med.*
458 *image analysis* **46**, 73–105 (2018).
- 459 **52.** Peter, B. S. *et al.* Development and testing of a single frequency terahertz imaging system for breast cancer detection.
460 *IEEE Transactions on Terahertz Sci. Technol.* **3**, 374–386 (2013).
- 461 **53.** Powers, D. M. Evaluation: from precision, recall and f-measure to roc, informedness, markedness and correlation. *arXiv*
462 *preprint arXiv:2010.16061* (2020).
- 463 **54.** Rizk, Y., Hajj, N., Mitri, N. & Awad, M. Deep belief networks and cortical algorithms: A comparative study for supervised
464 classification. *Appl. Comput. Informatics* **15**, 81–93 (2019).
- 465 **55.** Tharwat, A. Classification assessment methods. *Appl. Comput. Informatics* (2020).
- 466 **56.** García, V., Mollineda, R. A. & Sanchez, J. S. Theoretical analysis of a performance measure for imbalanced data. In *2010*
467 *20th International Conference on Pattern Recognition*, 617–620 (IEEE, 2010).
- 468 **57.** Fawcett, T. An introduction to roc analysis. *Pattern recognition letters* **27**, 861–874 (2006).