



HAL
open science

Complications of dexamethasone prescribed for *Streptococcus pneumoniae* meningitis associated with cerebral vasculitis involving large- to medium-sized vessels

A Corchia, A Gouvion, S Deguelte-Lardiere, V Vernet Garnier, P Raclot, Y
N'guyen

► To cite this version:

A Corchia, A Gouvion, S Deguelte-Lardiere, V Vernet Garnier, P Raclot, et al.. Complications of dexamethasone prescribed for *Streptococcus pneumoniae* meningitis associated with cerebral vasculitis involving large- to medium-sized vessels. *Revue Neurologique*, 2017, 174, pp.267 - 268. 10.1016/j.neurol.2017.06.024 . hal-03267293

HAL Id: hal-03267293

<https://hal.science/hal-03267293>

Submitted on 24 Jun 2021

HAL is a multi-disciplinary open access archive for the deposit and dissemination of scientific research documents, whether they are published or not. The documents may come from teaching and research institutions in France or abroad, or from public or private research centers.

L'archive ouverte pluridisciplinaire **HAL**, est destinée au dépôt et à la diffusion de documents scientifiques de niveau recherche, publiés ou non, émanant des établissements d'enseignement et de recherche français ou étrangers, des laboratoires publics ou privés.

**Complications of dexamethasone prescribed for
Streptococcus pneumoniae meningitis associated with
cerebral vasculitis involving large- to medium-sized
vessels**

A Corchia, A Gouvion, S Deguelte-Lardiere, V Vernet Garnier, P Raclot, Y
N'guyen

► **To cite this version:**

A Corchia, A Gouvion, S Deguelte-Lardiere, V Vernet Garnier, P Raclot, et al.. Complications of dexamethasone prescribed for Streptococcus pneumoniae meningitis associated with cerebral vasculitis involving large- to medium-sized vessels. *Revue Neurologique*, Elsevier Masson, 2017, 174, pp.267 - 268. 10.1016/j.neurol.2017.06.024 . hal-03267293

HAL Id: hal-03267293

<https://hal.archives-ouvertes.fr/hal-03267293>

Submitted on 24 Jun 2021

HAL is a multi-disciplinary open access archive for the deposit and dissemination of scientific research documents, whether they are published or not. The documents may come from teaching and research institutions in France or abroad, or from public or private research centers.

L'archive ouverte pluridisciplinaire **HAL**, est destinée au dépôt et à la diffusion de documents scientifiques de niveau recherche, publiés ou non, émanant des établissements d'enseignement et de recherche français ou étrangers, des laboratoires publics ou privés.

1
2
3
4
5
6
7
8

Letter to the editor

Complications of dexamethasone prescribed for *Streptococcus pneumoniae* meningitis associated with cerebral vasculitis involving large- to medium-sized vessels

9 A 57-year-old asplenic woman, suffering from Crohn's disease
10 and experiencing fever for 7 days, was treated at another
11 hospital with mesalazine (mesalamine) and ofloxacin based
12 on the hypothesis of a Crohn's disease flare-up. Headache,
13 neck stiffness and confusion arose in the last 2 days prior to
14 her referral to our hospital (day 1) and before a brain computed
15 tomography (CT) scan, showing a bilateral frontal ischemic
16 lesion (with no mass effect), was performed. Lumbar puncture
17 showed purulent cerebrospinal fluid (CSF) with purple
18 diplococci after Gram staining. Ofloxacin was withdrawn,
19 and a combined treatment associating cefotaxime 300 mg/kg/
20 day and dexamethasone 10 mg four times a day was started
21 within 2 h of admission. The minimum inhibitory concentra-
22 tion (MIC) for the *Streptococcus pneumoniae* strain isolated from
23 both CSF and blood cultures drawn on admission was
24 0.064 mg/L. Antibiotic treatment was switched from cefota-
25 xime to intravenous amoxicillin.

26 Thoracic CT confirmed that the portal of entry of the *S.*
27 *pneumoniae* bacteremia was left lower lobe pneumonia.
28 Austrian syndrome was ruled out, as bone scintigraphy
29 evidenced left hip arthritis. Levofloxacin and co-trimoxazole
30 were prescribed for 1 supplementary month after the end of
31 the intravenous antibiotics. While the patient was no longer
32 confused, cerebral magnetic resonance imaging (MRI), per-
33 formed on day 3, revealed cerebral vasculitis (CV) involving
34 medium and large vessels, such as the anterior and middle
35 cerebral arteries (A1, M1/A2 and M2 segments; Fig. 1). As early
36 discontinuation of dexamethasone (after 4 days) is recom-
37 mended in cases of *S. pneumoniae* meningitis (SPM) because it
38 can lead to a rebound effect and multiple cerebral infarctions
39 [1], dexamethasone was left unchanged for 3 weeks before
40 being tapered (Fig. 1). Also, because of the large-vessel
41 involvement, it was preferable to administer high-dose
42 steroids, ~~which are~~ recommended for giant cell arteritis,
43 rather than to introduce cyclophosphamide, which is recom-
44 mended for primary CV where the involvement of large
45 vessels is not consistent [2].

Our patient became bedridden because of bilateral qua-
driceps atrophy, and she experienced acute pancreatitis due to
cytomegalovirus (CMV) reactivation. Despite ganciclovir
treatment, septic shock due to nosocomial peritonitis, related
to the duodenal necrosis associated with CMV pancreatitis,
arose on day 56. Surgical treatment consisted of a duodenum-
excluding gastrojejunal anastomosis and an Oddi papillary
surgical drainage procedure.

In the intensive care unit, dexamethasone was switched for
hydrocortisone before steroid withdrawal after 93 days (Fig. 1).
The outcome was favourable and the patient was discharged
home from hospital after 6 months of rehabilitation. Her Mini-
Mental State Examination and Rankin Scale scores were 29/30
and 2, respectively, 1-year later.

The case described here ~~is of~~ CV involving large- to
medium-sized vessels that appeared after 2 days' evolution
of SPM. Large-to-medium vessels are usually involved in
bacterial-meningitis-associated CV and accounts for 0.5% of
patients referred for strokes [3], whereas CV has been reported
in 12 out of 87 cases of SPM [4]. In such cases, there are no
recommendations concerning steroid treatment or adjunctive
immunosuppressive therapy [3].

In our patient, the quadriceps atrophy that led to her
bedridden state was due to dexamethasone: fluorinated
glucocorticoids (including dexamethasone) are associated
with a higher risk of muscle atrophy than non-fluorinated
glucocorticoids (such as prednisone) [5]. This suggests that an
immediate switch to a non-fluorinated corticosteroid or
corticosteroid tapering should be discussed together with
follow-up cerebral MRI, as an early switch to prednisone after
3 days of rapidly tapered dexamethasone has been associated
with the development of chronic CV [6].

Thus, while gathering data to better define the optimal
regime for steroids in CV associated with SPM, it ~~is apparently~~
important to immediately search for CV in cases of ischemic
lesions ~~as revealed~~ on brain CT scans which, ~~in our case here,~~
were systematically performed.

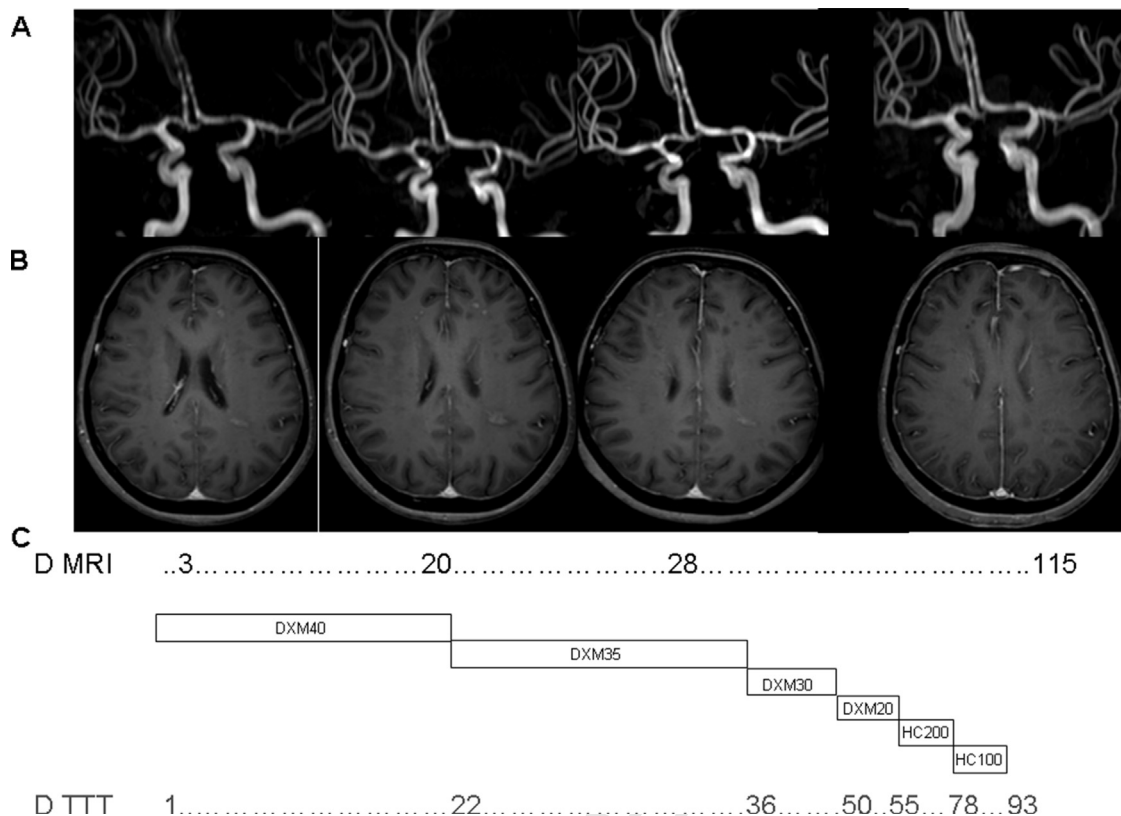


Fig. 1 – Cerebral magnetic resonance imaging (MRI) initially performed in our patient: (A) successive time-of-flight magnetic resonance angiography (TOF MRA) of the anterior and middle cerebral arteries reveals stenosis and dilatation of these arteries, giving a ‘string of pearls’ appearance; (B) successive T1-weighted post-gadolinium axial MRI sequences show blood–brain barrier ruptures in the anterior and middle cerebral artery territories; and (C) time scale in days (D) indicates when the MRI scans were performed and when the steroid treatment (TTT) was tapered (schematically depicted), with day 1 being the time of admission to our hospital. DXM: dexamethasone (daily dosage in mg); HC: hydrocortisone (daily dosage in mg).

Disclosure of interest

The authors declare that they have no competing interest.

Acknowledgements

Daniele Fiquemont, Bernard Pignon, Sonia Baumard, Ahmed El Bekri.

REFERENCES

- [1] Lefebvre N, Carre AC, Delabranche X, Guiot P, Mootien Y. Implication of dexamethasone adjunctive therapy after the onset of cerebral vasculitis in *Streptococcus pneumoniae* meningitis. *Med Mal Infect* 2007;37:118–20.
- [2] Salvarani C, Brown Jr RD, Christianson T, Miller DV, Giannini C, Huston 3rd J, et al. An update of the Mayo Clinic cohort of patients with adult primary central nervous system vasculitis: description of 163 patients. *Medicine (Baltimore)* 2015;94:e738.

- [3] Katchanov J, Siebert E, Klingebiel R, Endres M. Infectious vasculopathy of intracranial large- and medium-sized vessels in neurological intensive care unit: a clinico-radiological study. *Neurocrit Care* 2010;12:369–74.
- [4] Kastenbauer S, Pfister HW. Pneumococcal meningitis in adults: spectrum of complications and prognostic factors in a series of 87 cases. *Brain* 2003;126:1015–25.
- [5] Pereira RM, Freire de Carvalho J. Glucocorticoid-induced myopathy. *Joint Bone Spine* 2011;78:41–4.
- [6] Czartoski T, Hallam D, Lacy JM, Chun MR, Becker K. Postinfectious vasculopathy with evolution to moyamoya syndrome. *J Neurol Neurosurg Psychiatry* 2005;76:256–9.

A. Corchia^a

A. Gouvion^b

S. Deguelte-Lardiere^c

V. Vernet Garnier^d

P. Raclot^e

Y. N'Guyen^{f,*}

^aService de Néphrologie, Hôpital Maison Blanche, CHU Reims, 51092 Reims Cedex, France

^bService de Radiologie, Hôpital Maison Blanche, CHU Reims, 51092 Reims Cedex, France

^cService de Chirurgie générale et digestive, Hôpital Robert Debré, CHU Reims, Rue du Général Koenig, 51100 Reims, France

123 ^dLaboratoire de Bactériologie, Hôpital Robert Debré, CHU Reims, Rue
124 du Général Koenig, 51100 Reims, France
125 ^eUnité de Réanimation Polyvalente, Hôpital Robert Debré, CHU
126 Reims, Rue du Général Koenig, 51100 Reims, France
127 ^fLaboratoire de Virologie, EA 4684, UFR médecine Reims, 51 Avenue
128 Cognacq Jay, 51100 Reims, France

129 *Corresponding author at: EA 4684, UFR médecine Reims, 51
130 Avenue Cognacq Jay, 51100 Reims, France.
131 E-mail address: yohan.nguyen@wanadoo.fr (Y. N'Guyen)

Received 25 April 2017 132
Received in revised form 17 May 2017 133
Accepted 15 June 2017 134
Available online xxx 135

<https://doi.org/10.1016/j.neurol.2017.06.024> 137

0035-3787/© 2017 Elsevier Masson SAS. All rights reserved. 138

139

140

UNCORRECTED PROOF