



HAL
open science

**Amoxicillin-tolerant *Pasteurella multocida* strain
isolated from chronic dermohypodermatitis after
suboptimal exposure to amoxicillin is not associated
with reduced growth rate**

A Limelette, D Giusti, D Anuset, C Beaupuis, H Jacquier, C de Champs, F
Bani-Sadr, T Guillard, Y N'guyen

► **To cite this version:**

A Limelette, D Giusti, D Anuset, C Beaupuis, H Jacquier, et al.. Amoxicillin-tolerant *Pasteurella multocida* strain isolated from chronic dermohypodermatitis after suboptimal exposure to amoxicillin is not associated with reduced growth rate. *Journal of Medical Microbiology*, 2018, 67, pp.579 - 584. 10.1099/jmm.0.000692 . hal-03267048

HAL Id: hal-03267048

<https://hal.science/hal-03267048v1>

Submitted on 22 Jun 2021

HAL is a multi-disciplinary open access archive for the deposit and dissemination of scientific research documents, whether they are published or not. The documents may come from teaching and research institutions in France or abroad, or from public or private research centers.

L'archive ouverte pluridisciplinaire **HAL**, est destinée au dépôt et à la diffusion de documents scientifiques de niveau recherche, publiés ou non, émanant des établissements d'enseignement et de recherche français ou étrangers, des laboratoires publics ou privés.

Amoxicillin-tolerant *Pasteurella multocida* strain isolated from chronic dermohypodermatitis after suboptimal exposure to amoxicillin is not associated with reduced growth rate

A. Limelette,^{1,2†} D. Giusti,^{3†} D. Anuset,⁴ C. Beaupuis,⁵ H. Jacquier,^{6,7} C. De Champs,^{1,2} F. Bani-sadr,⁵ T. Guillard^{1,2†} and Y. N'Guyen^{5,*†}

Abstract

Pasteurella multocida is rarely observed in human chronic infections. A *Pasteurella multocida* strain was isolated from a skin biopsy of chronic dermohypodermatitis in a 21-year-old woman without an immunocompromised state. As this strain was viable one month after a cat scratch despite treatment by amoxicillin-clavulanic acid, we compared this strain's growth rate, amoxicillin Minimal Inhibitory and Bactericidal Concentrations (MIC and MBC), resistance to serum and ability to activate neutrophil granulocytes with those of control strains isolated during acute infections in humans without previous antibiotics exposure. This particular strain was not more resistant to serum and did not induce a lower phagocytic activity than control strains. It did not grow more slowly than control strains even after suboptimal exposure to amoxicillin. This particular strain was tolerant to amoxicillin but tolerance did not appear sufficient alone for the induction of a chronic infection in a host without an immunocompromised state.

Pasteurella multocida, 'killer of many species' [1], is a small Gram-negative coccobacillus, commensal of the oral flora of many animals, that causes fowl cholera in birds and haemorrhagic septicaemia in cattle [2]. In human species, after pet's bites or scratches, *P. multocida* is responsible for acute infections such as dermohypodermatitis, tenosynovitis, septic arthritis or osteomyelitis [3]. Such infections can be life threatening (e.g. bacteraemia, meningitis and peritonitis) in immunocompromised hosts [4, 5]. Conversely, *P. multocida* have been less frequently observed in chronic infections, mainly in pulmonary abscesses mistaken as neoplastic nodules [6–8].

Interestingly, *P. multocida* relapsing wound infection has been previously reported, despite treatment by trimethoprim-sulfamethoxazole, in an immunocompetent patient whose leg wound had been licked by his dog [9]. Insufficient compliance with treatment had been ruled out, but this case report did not allow determining if (i) the patient was

contaminated again by his dog after the end of treatment, (ii) *P. multocida* strain was tolerant to trimethoprim-sulfamethoxazole, (iii) the exposure to antibiotics was suboptimal with skin concentrations below Minimal Inhibitory Concentration (MIC), leading to reduced bacterial growth rate as described previously [10, 11].

A similar case occurred in our centre when a 21-year-old woman was referred for dermohypodermatitis evolving over one month. She did not report any significant past medical history except obesity (body mass index 45 kg m⁻²) and deafness. She had her left leg scratched by her mother's cat one month ago and experienced pain around the scratch in the following night. Her general practitioner had evidenced an inflammatory lesion the next morning and amoxicillin-clavulanic acid, 1 gram tid (i.e. 25 mg/kg/day) had been prescribed for ten days. Despite such treatment, evolution was not favourable, with persistent nodular dermohypodermatitis whereas she had not been licked, bitten or scratched again by

Received 16 October 2017; Accepted 23 January 2018

Author affiliations: ¹Laboratoire de Bactériologie, Hôpital Robert Debré, Avenue Général Koenig, 51100 Reims, France; ²EA4687, UFR Médecine, Université de Reims Champagne-Ardenne, 51100 Reims, France; ³Laboratoire d'Immunologie, Hôpital Robert Debré, Avenue Général Koenig, 51100 Reims, France; ⁴Service de Dermatologie, Hôpital Robert Debré, Avenue Général Koenig, 51100 Reims, France; ⁵Service de Médecine Interne, Maladies Infectieuses et Immunologie Clinique, Hôpital Robert Debré, Avenue Général Koenig, 51100 Reims, France; ⁶Service de bactériologie, AP-HP, Hôpitaux Universitaires Saint Louis-Lariboisière-Fernand Widal, Paris, France; ⁷IAME, UMR 1137, Inserm, Université Paris Diderot, Sorbonne Paris Cité, Paris, France.

*Correspondence: Y. N'Guyen, yohan.nguyen@wanadoo.fr

Keywords: *Pasteurella multocida*; human; tolerant; amoxicillin; growth rate.

Abbreviations: DHR 123, DiHydroRhodamine 123; HCG, Human chorionic gonadotropin; HIV, Human immunodeficiency virus; MALDI-TOF, Matrix Assisted Laser Desorption Ionisation time-of-flight; MBC, Minimal Bactericidal Concentration; MGR, Maximum Growth Rate; MIC, Minimal Inhibitory Concentration; tid, ter in die (three times a day).

†These authors contributed equally to this work.

her mother's cat. Clinical examination on admission revealed a three-centimeter-wide nodular dermohypodermatitis in the anterior and external part of the left leg, with serohematic discharge (Fig. 1a). The patient was afebrile and the rest of the physical examination unremarkable. A leg computerised tomography scan did not show any subcutaneous abscess, tenosynovitis or osteitis (Fig. 1b). C-reactive protein rate was 15.5 mg l^{-1} ($N < 10 \text{ mg l}^{-1}$) and other tests, including white blood cell count, liver enzymes and serum creatinine were all within normal range. Serum beta-HCG was negative. The presence of an immunocompromised state was ruled out by negative HIV status, normal immunoglobulin classes and subclasses plasma concentration, normal peripheral blood lymphocytes immunophenotyping and by normal granulocytes oxidative burst assays (see methodology below) (Fig. 1c). Two scalpel biopsies of the chronic dermohypodermatitis lesion were performed. The first was formalin-fixed for classical histopathological analysis that evidenced intense dermohypodermatitis

with fibrinoid necrosis of vascular walls and thrombosis (Fig. 1d). Bacterial culture for the second (fresh tissue for microbiological purposes) grew with *P. multocida*, referred hereafter as chronic dermohypodermatitis strain. No other pathogen was evidenced in culture (bacteria, fungi or mycobacteria). Cat scratch disease serology was also negative and a treatment by levofloxacin was prescribed immediately after skin biopsy.

As this *P. multocida* strain was still viable one month after a cat scratch and despite treatment by amoxicillin-clavulanic acid, we tried to analyse using routine methods. The phenotype of this particular strain was compared to control strains from our laboratory collection that had been sampled from peripheral tissues ($n=4$) or blood culture ($n=1$) in five human patients during the last four years and kept in agar tubes. Clinical data of these patients was retrospectively assessed by an external reviewer (CB) (Table 1).

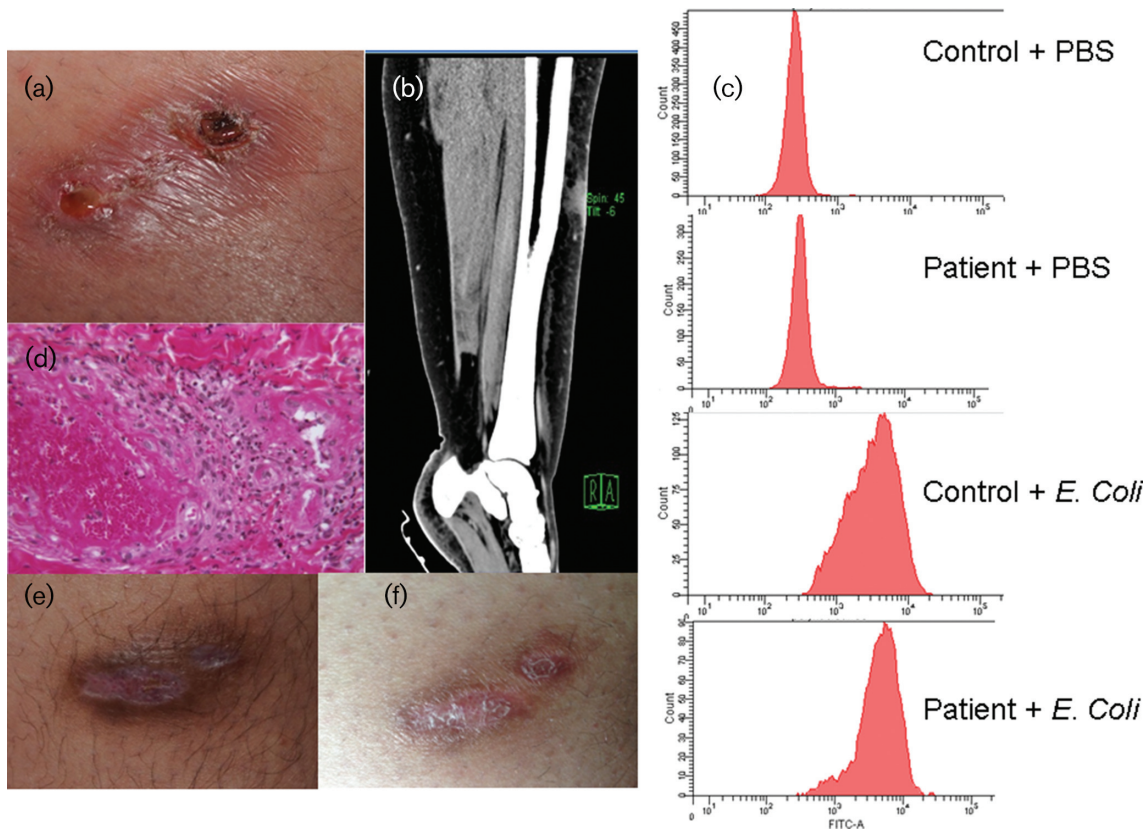


Fig. 1. (a) Nodular inflammatory lesion of the left leg at admission, one month after cat scratch, with serohematic discharge at the lower left extremity of the lesion. Biopsy was performed at upper right extremity of the lesion. (b) Computerized tomography scanner with injection evidencing inflammatory oedema of soft tissues in the antero-external part of the leg, without tenosynovitis or osteitis. (c) Flow cytometric investigation of oxidative burst of patient's neutrophil granulocytes and control neutrophil granulocytes after challenge by phosphate-buffered saline (PBS) and *E. coli* strain using FagoFlowEx kit (ExBio diagnostics). The two upper pictures depicted the absence of fluorescence after stimulation of control and patient granulocytes by PBS respectively whereas the two lower pictures depicted the fluorescence due to rhodamine 123 after stimulation of control and patient granulocytes by *E. coli* strain. (d) Histopathological analysis (hematoxylin and eosin staining, $\times 200$) evidencing inflammatory dermal infiltrate of polynuclear cells with fibrinoid necrosis of vascular walls and thrombosis. (e) Reepithelialised lesion after a course of levofloxacin therapy during 6 weeks. (f) Healed lesion 3 months after the end of levofloxacin therapy.

Table 1. Clinical data of patients from whom chronic dermohypodermatitis strain and control strains were isolated

No	Age (years)	Significant comorbidity	Injury	Prior antibiotics exposure	Clinical presentation*	Antibiotics regimen	Surgery	Outcome
1	21	Deafness, obesity	Cat scratch	Yes	Chronic dermohypodermatitis (leg)	AMC then LVX	No	Favourable
2	37	AHT†	Cat scratch	No	Flexor tenosynovitis (hand II)	AMC	Yes	Favourable
3	73	AHT†, DM‡, LLAD§, obesity, dyslipidemia, CRF	Cat bite	No	Metacarpophalangeal joint arthritis (III)	AMX	Yes	Favourable
4	55	LLAD§, obesity, bipolar disorder	Cat bite	No	Palmar face abscess (III)	AMX	Yes	Favourable
5	32	-	Cat scratch	No	Acute dermohypodermatitis hand (II)	AMC	Yes	Favourable
6	80	AHT†, dyslipidemia, CRF	Unknown	No	Bacteraemia, shoulder arthritis	AMX and OFX	Yes	Favourable

Data of patient from whom chronic dermohypodermatitis strain was isolated are marked in bold.

II designed index finger, III middle finger. LVX, Levofloxacin; AMX, Amoxicillin; AMC, Amoxicillin-clavulanic acid; OFX, Ofloxacin.

*Lesion localization is noted between parentheses.

†Arterial hypertension.

‡Diabetes mellitus.

§Lower limb peripheral arterial disease.

||Chronic renal failure.

All strains were plated on blood agar. Identification of *P. multocida* was confirmed by MALDI-TOF mass spectrometry (Microflex BRUKER), according to the manufacturer's instructions. Strain's capsular serogroups have been determined using multiplex capsular PCR typing system [12]. Strains were observed using transmission electron microscopy after strain preparation described elsewhere [13]. *P. multocida* strains' antimicrobial susceptibility was further examined using the disk diffusion method performed with an inoculum of 10^6 c.f.u. ml⁻¹ on MH-F agar plates (Mueller-Hinton agar with 5% horse blood and 20 mg l⁻¹ β-NAD) as previously described [14]. The presence of beta-lactamase was detected by nitrocefin test (Céfinase, Biomérieux), according to the manufacturer's instructions. Minimal Inhibitory and Bactericidal Concentrations (MIC and MBC) for amoxicillin and levofloxacin were determined using dilution method on liquid medium for all strains and chronic dermohypodermatitis strain only three times and once respectively. Growth rates were assessed in real time by measuring the optical density by spectrometry. Briefly, each strain was previously incubated at 37 °C for 18 h in a nutrient broth (Brain Heart Infusion, BHI). Absorbance of each liquid medium was measured and adjusted to obtain the same starting inoculum for all strains. Growth curves were performed at 37 °C in 96-well microliter plates containing 200 µl of those media, using a Tecan infinite 96-wells plate reader. Each strain was assessed in triplicate and experiments were also performed in triplicate. Maximum Growth Rate (MGR) was determined as the maximum value of the derivative of the logOD₆₀₀ using R software. All strains were challenged for serum killing as previously described [15]. Each strain was

incubated in pooled human serum from non-immunised healthy donors in order to determine the serum bactericidal activity against these isolates. The phagocytic activity of neutrophil granulocytes against chronic dermohypodermatitis strain and control strains was measured twice using Fago-FlowEx kit (ExBio diagnostics). This test is based on the measurement of respiratory burst of neutrophil granulocytes after stimulation with *P. multocida* (10^6 cells/reaction) in human heparinised whole blood at 37 °C. During the process of bacteria ingestion, neutrophils activate the Nicotinamide Adenine Dinucleotide PHosphate (NADPH) oxidase, producing reactive oxidative intermediates (respiratory burst). Resulting hypochlorite ions, inside neutrophils, strongly oxidise DiHydroRhodamine 123 (DHR 123) into its fluorescent derivative rhodamine 123 which is detected by a flow cytometer at λ=527 nm after excitation at λ=503 nm. We used lyophilised *Escherichia coli* strains and phosphate-buffered saline (PBS) as positive and negative control respectively. Human heparinised whole blood samples were provided by the patient suffering of dermohypodermatitis and by a healthy donor (DG) (control neutrophil granulocytes). Quantitative variables were compared using Student *t*-test or Mann Whitney U test. A *P* value <0.05 was considered as significant. Statistical analyses were performed using Statview 5.0 Software (SAS institute).

All *Pasteurella* spp strains (chronic dermohypodermatitis strain and controls) belonged to capsular serogroup A except strain isolated in patient 3 that belonged to serogroup F (not shown). No significant differences were evidenced between chronic dermohypodermatitis strain and control strains capsules using transmission electron

microscopy (e.g. thin condensed capsules were evidenced in chronic dermohypodermatitis strain and control strain isolated from patient number 2, whereas a thick capsule was evidenced in control strain isolated from patient number 5) (Fig. 2a). No beta-lactamase was detected by nitrocefin test; mean amoxicillin MICs were 0.14 mg l^{-1} and between 0.09 and 0.33 mg l^{-1} for chronic dermohypodermatitis strain and control strains respectively ($P=0.55$) (Fig. 2b). Amoxicillin MICs of strain isolated in patient 3 were statistically higher than those of dermohypodermatitis strain and control strains isolated in patients 4 and 6 ($P=0.04$), whereas other inter-strain comparisons of MICs gave non significant results (not shown). Growth rates of all *Pasteurella* strains are depicted in Fig. 2(c). Calculated MGRs were 0.000414 and 0.000372 for chronic dermohypodermatitis strain and control strains respectively ($P=0.012$). Growth rate of chronic dermohypodermatitis strain was statistically higher than all control strains ($P=0.04$) except those isolated from patient 3 and 6. Calculated MGRs of these latter were not statistically different (not shown) but both were higher than those of

other control strains ($P=0.04$). No strain was killed by serum except the strain isolated from patient number 6 (not shown). The phagocytic activity of neutrophil granulocytes against chronic dermohypodermatitis strain and control strains is depicted in Fig. 2(d). Median fluorescent intensity of chronic dermohypodermatitis strain was not statistically inferior to those of control strains ($P=0.13$). Interstrain comparison gave non significant results (not shown).

No clear different phenotype was evidenced using routine methods between chronic dermohypodermatitis strain and control strains. We then tested whether chronic dermohypodermatitis strain was tolerant to amoxicillin. Mean amoxicillin MBC was 4.6 mg l^{-1} for chronic dermohypodermatitis strain (Fig. 2b) and this strain was considered as tolerant to amoxicillin because of a ratio $\text{MBC}/\text{MIC} > 32$. All other control strains did not meet criteria for amoxicillin tolerance (Fig. 2b). Amoxicillin MBC of chronic dermohypodermatitis strain was not statistically superior to those of all other control strains ($P=0.13$). Amoxicillin MBCs of

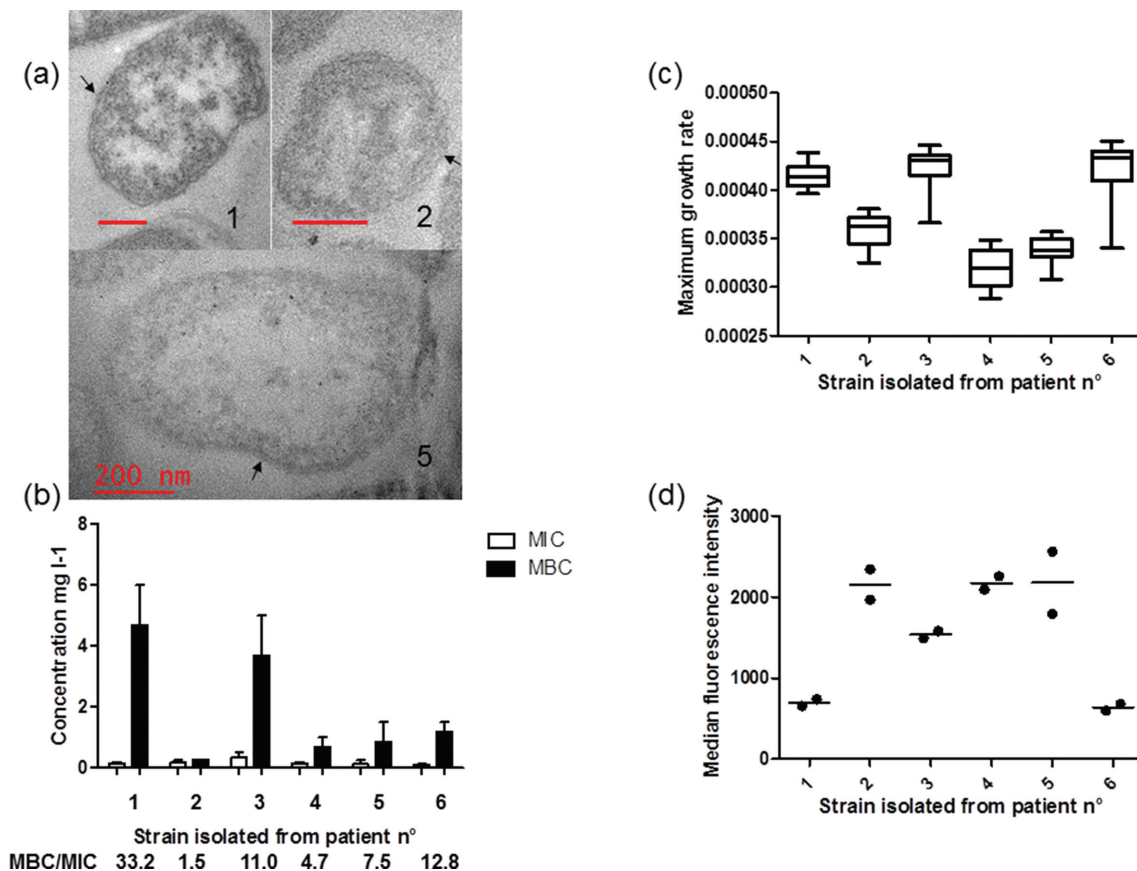


Fig. 2. (a) Transmission electron micrographs of *Pasteurella multocida* strains. Number of the patient in whom strain had been isolated is written in black, red bar 200 nm. Capsules are depicted by black arrows. (b) Mean minimal inhibitory and bactericidal concentrations (MIC and MBC) for amoxicillin of chronic dermohypodermatitis strain and control strains, vertical bars depicting range. (c) Growth rates of chronic dermohypodermatitis strain and control strains. (d) Flow cytometric investigation of oxidative burst of control neutrophil granulocytes after challenge by chronic dermohypodermatitis strain and control strains using FagoFlowEx kit (ExBio diagnostics).

dermohypodermatitis strain and control strain isolated in patient 3 were statistically higher than those of all other control strains ($P=0.04$) but there was no statistical difference between MBCs of these two strains (not shown). Amoxicillin MBCs of strain isolated in patients 5 and 6 were also higher than those of control strain isolated in patient 2 ($P=0.04$). Levofloxacin MIC and MBC of chronic dermohypodermatitis strain were 0.06 and 0.12 mg l⁻¹ respectively and outcome was finally favourable after six weeks of levofloxacin 500 mg bid (Fig. 1e, f).

Herein, we report the first case of chronic dermohypodermatitis due to *P. multocida* one month after cat scratch in a 21-year-old woman without immunodeficiency and despite suboptimal treatment by amoxicillin 25 mg/kg/day. As this infection seemed unusual, we tried to examine using routine investigations the strain that was isolated from a skin biopsy performed one month later, wherein the patient had not been licked, bitten or scratched again by her mother's cat. First, even if the parental strain from the cat was unavailable, we presumed that this strain exhibited virulence similar to those of other *Pasteurella* strains, because the incubation between scratch and dermohypodermatitis was very short as expected in previous data from the literature [16, 17]. Secondly, no bacterial clearance was observed after treatment by amoxicillin and in the absence of an immunocompromised state that could have had an impact on bacterial clearance. As amoxicillin remains the drug of choice against *Pasteurella* strains [18], the absence of bacterial clearance of this strain exhibiting amoxicillin MIC equal to 0.14 mg l⁻¹ raised the hypothesis of amoxicillin underdosing in this obese patient and/or the eventuality that this strain was tolerant to amoxicillin (see below). In both cases, we presumed that innate and acquired immunity should have led to bacterial clearance. Indeed, persistence of a viable *P. multocida* strain for months in a normally sterile site has only been reported once in the lung of a Japanese patient without an immunocompromised state or pulmonary chronic disease [6], but never fully documented in patients with skin infections [9]. As skin and wound infections are the most common form of *Pasteurella* infections [3], we thus hypothesised that suboptimal exposure to amoxicillin here (i.e. 25 mg/kg/day) may have led to an alteration of *Pasteurella* strain phenotype and therefore to the chronicity of the dermohypodermatitis. Indeed, suboptimal exposure to amoxicillin (1/4 MIC) has previously been associated with proteomic modifications and a reduced growth rate [11], and with capsule or cell morphological changes [10]. We compared this chronic dermohypodermatitis strain to control strains previously isolated during acute infections in human patients without previous antibiotic exposure (Table 1). Chronic dermohypodermatitis strain did not grow more slowly (Fig. 2c), and did not resist serum more than control strains. Moreover, the phagocytic activity induced by this particular strain was not lower than those induced by all control strains (Fig. 2d). We haven't been able to test whether this chronic dermohypodermatitis strain was able to survive longer in phagocytes or macrophages than control strains, but, taking together these data, no phenotype differences were evidenced between strains that

were almost all belonging to the same capsular serotype A. Within limits of visualisation of bacterial capsule using transmission electron microscopy with conventional embeddings [19], we did not evidence major differences between this chronic dermohypodermatitis strain and control strains suggesting that the capsule did not play a role in this persistent skin infection here.

In this particular strain we only evidenced amoxicillin tolerance with a ratio MBC/MIC > 32. Such a phenotype was presumed to be uncommon for *Pasteurella* strains that have been reported to have very close MIC and MBC for amoxicillin [18]. Interestingly, even if they did not meet criteria for tolerance, control strains isolated in patients 3 and 6, both with mean MBC/mean MIC ratio higher than 10 also had maximum growth rates and fluorescent intensities during oxidative burst assays quite similar to those of chronic dermohypodermatitis strain, which was the sole amoxicillin tolerant strain. The biological support of tolerance is now considered to be persister cells [20], that we have not been able to evidence here using routine investigations. Indeed, persister cells are slowly growing or non-growing cells whose formation is favoured under growth-limiting conditions but their implication in the chronicity of *Pasteurella* infections has never been demonstrated [21]. The favourable outcome here after treatment by levofloxacin underlines that tolerance usually involves only one class of antibiotics among *Pasteurella* strains, as described for other bacteria [20]. More studies are required to better understand the cellular mechanisms of tolerance and of the absence of spontaneous clearance of strains isolated from clinical samples. This strain remains available for further genomic sequencing or proteomic analyses.

In conclusion, we isolated for the first time a *P. multocida* strain in a skin biopsy performed in a chronic dermohypodermatitis despite suboptimal amoxicillin concentrations in a patient without an immunocompromised state. Using routine investigations, this particular strain was not different from control strains isolated during acute infections in humans, within limits that isolated strain had not reverted to a wild-type phenotype *ex vivo* after amoxicillin exposure. It did not resist serum more and did not induce a lower phagocytic activity than control strains. Unexpectedly, it did not grow more slowly than control strains even after suboptimal exposure to amoxicillin. This particular strain was tolerant to amoxicillin but tolerance did not appear sufficient alone for the induction of a chronic infection in a host without an immunocompromised state. Outcome was favourable after a treatment by levofloxacin and more studies are required to better understand the cellular mechanisms of tolerance or absence of spontaneous clearance of *Pasteurella* strains.

Funding information

This work was supported by 'Société rémoise de pathologie interne et infectieuse'.

Acknowledgements

We are indebted to Dr Anne Durlach, Anne Laure Lebreuil, Pierre Vermeulen, Marylin Simon, Laurence Wortham, Pierre Vermeulen, Dr

Jean Michel for their precious help during the preparation of manuscript.

Conflicts of interest

The authors declare that there are no conflicts of interest.

Ethical statement

Written consent was obtained from the patient for publication of images and neither patient nor controls raised any objection against the use of clinical samples for scientific purpose, in agreement with current French Legislation.

References

1. Guion TL, Sculco TP. *Pasteurella multocida* infection in total knee arthroplasty. Case report and literature review. *J Arthroplasty* 1992;7:157–160.
2. Harper M, Boyce JD, Adler B. *Pasteurella multocida* pathogenesis: 125 years after Pasteur. *FEMS Microbiol Lett* 2006;265:1–10.
3. Weber DJ, Wolfson JS, Swartz MN, Hooper DC. *Pasteurella multocida* infections. Report of 34 cases and review of the literature. *Medicine* 1984;63:133–154.
4. Grillon A, Guillard T, Brasme L, Limelette A, Novella JL et al. Lethal meningitis due to *Pasteurella multocida*. *Med Mal Infect* 2012;42:374–375.
5. Hey P, Gow P, Torresi J, Testro A. Cirrhosis, cellulitis and cats: a 'purrfect' combination for life-threatening spontaneous bacterial peritonitis from *Pasteurella multocida*. *BMJ Case Rep* 2012;2012:bcr2012007397.
6. Umemori Y, Hiraki A, Murakami T, Aoe K, Matsuda E et al. Chronic lung abscess with *Pasteurella multocida* infection. *Intern Med* 2005;44:754–756.
7. Steyer BJ, Sobonya RE. *Pasteurella multocida* lung abscess. A case report and review of the literature. *Arch Intern Med* 1984;144:1081–1082.
8. Machiels P, Haxhe JP, Trigaux JP, Delos M, Shovevaerdt JC et al. Chronic lung abscess due to *Pasteurella multocida*. *Thorax* 1995;50:1017–1018.
9. Cook PP. Persistent postoperative wound infection with *Pasteurella multocida*: case report and literature review. *Infection* 1995;23:252.
10. Jacques M, Lebrun A, Foiry B, Dargis M, Malouin F. Effects of antibiotics on the growth and morphology of *Pasteurella multocida*. *J Gen Microbiol* 1991;137:2663–2668.
11. Nanduri B, Lawrence ML, Boyle CR, Ramkumar M, Burgess SC. Effects of subminimum inhibitory concentrations of antibiotics on the *Pasteurella multocida* proteome. *J Proteome Res* 2006;5:572–580.
12. Townsend KM, Boyce JD, Chung JY, Frost AJ, Adler B. Genetic organization of *Pasteurella multocida* cap Loci and development of a multiplex capsular PCR typing system. *J Clin Microbiol* 2001;39:924–929.
13. Chung JY, Wilkie I, Boyce JD, Townsend KM, Frost AJ et al. Role of capsule in the pathogenesis of fowl cholera caused by *Pasteurella multocida* serogroup A. *Infect Immun* 2001;69:2487–2492.
14. Société Française de Microbiologie. Comité de l'antibiogramme de la Société Française de Microbiologie. Recommendations 2017. www.sfm-microbiologie.org/UserFiles/files/casfm/CASFMV1_0_MARS_2017.pdf (Available at 13/04/2017).
15. Skurnik D, Roux D, Cattoir V, Danilchanka O, Lu X et al. Enhanced *in vivo* fitness of carbapenem-resistant oprD mutants of *Pseudomonas aeruginosa* revealed through high-throughput sequencing. *Proc Natl Acad Sci USA* 2013;110:20747–20752.
16. Arons MS, Fernando L, Polayes IM. *Pasteurella multocida*—the major cause of hand infections following domestic animal bites. *J Hand Surg Am* 1982;7:47–52.
17. Corchia A, Limelette A, Hubault B, Robbins A, Quinquenel A et al. Rapidly evolving conjunctivitis due to *Pasteurella multocida*, occurring after direct inoculation with animal droplets in an immunocompromised host. *BMC Ophthalmol* 2015;15:21.
18. Stevens DL, Higbee JW, Oberhofer TR, Everett ED. Antibiotic susceptibilities of human isolates of *Pasteurella multocida*. *Antimicrob Agents Chemother* 1979;16:322–324.
19. Stukalov O, Korenevsky A, Beveridge TJ, Dutcher JR. Use of atomic force microscopy and transmission electron microscopy for correlative studies of bacterial capsules. *Appl Environ Microbiol* 2008;74:5457–5465.
20. Hemsley CM, Luo JX, Andrae CA, Butler CS, Soyer OS et al. Bacterial drug tolerance under clinical conditions is governed by anaerobic adaptation but not anaerobic respiration. *Antimicrob Agents Chemother* 2014;58:5775–5783.
21. Fauvart M, de Groot VN, Michiels J. Role of persister cells in chronic infections: clinical relevance and perspectives on anti-persister therapies. *J Med Microbiol* 2011;60:699–709.

Five reasons to publish your next article with a Microbiology Society journal

1. The Microbiology Society is a not-for-profit organization.
2. We offer fast and rigorous peer review – average time to first decision is 4–6 weeks.
3. Our journals have a global readership with subscriptions held in research institutions around the world.
4. 80% of our authors rate our submission process as 'excellent' or 'very good'.
5. Your article will be published on an interactive journal platform with advanced metrics.

Find out more and submit your article at microbiologyresearch.org.