



HAL
open science

Osteoformation potential of an allogenic partially demineralized bone matrix in critical-size defects in the rat calvarium

Ahmad Moustapha Diallo, Ahmad Moustapha Diallo, Solène Rota, Michel Boissière, Raphaël Bardonnnet, Emmanuel Pauthe, Hervé Petite, Henri M Benoist, Morad Bensidhoum, Fani Anagnostou

► To cite this version:

Ahmad Moustapha Diallo, Ahmad Moustapha Diallo, Solène Rota, Michel Boissière, Raphaël Bardonnnet, et al.. Osteoformation potential of an allogenic partially demineralized bone matrix in critical-size defects in the rat calvarium. *Materials Science and Engineering: C*, 2021, 127, pp.112207. 10.1016/j.msec.2021.112207 . hal-03264528

HAL Id: hal-03264528

<https://hal.science/hal-03264528>

Submitted on 13 Jun 2023

HAL is a multi-disciplinary open access archive for the deposit and dissemination of scientific research documents, whether they are published or not. The documents may come from teaching and research institutions in France or abroad, or from public or private research centers.

L'archive ouverte pluridisciplinaire **HAL**, est destinée au dépôt et à la diffusion de documents scientifiques de niveau recherche, publiés ou non, émanant des établissements d'enseignement et de recherche français ou étrangers, des laboratoires publics ou privés.



Distributed under a Creative Commons Attribution - NonCommercial 4.0 International License

1 **Osteoformation potential of an allogenic partially demineralized bone matrix in critical-**
2 **size defects in the rat calvarium**

3

4 **Running Title:** Injectable allograft promotes calvarial-defects bone regeneration

5

6 **Ahmad Moustapha Diallo^{a,b}, Solène Rota^{c,d}, Michel Boissière^c, Raphaël Bardonnet^d,**
7 **Emmanuel Pauthe^c, Hervé Petite^a, Henri M. Benoist^b, Morad Bensidhoum^a, Fani**
8 **Anagnostou^{a,e*}**

9

10 a. CNRS UMR 7052 - INSERM U1271, Laboratory of Osteoarticular Biology,
11 Bioengineering and Bioimaging, University of Paris, 10 Avenue de Verdun, 75010
12 Paris, France.

13 b. Service of Periodontology, Institute of Odontology and Stomatology (IOS); Faculty of
14 Medicine, Pharmacy and Odonto-Stomatology; University Cheikh Anta Diop (UCAD)
15 BP 5005 Dakar-Fann, Sénégal.

16 c. ERRMECe, Research Team on Extracellular Matrix-Cellular Relationships (EA1391),
17 Biomaterials for Health Research Group, Institute of Materials I-MAT (FD4122), CY
18 Tech, CY University Cergy Paris, International House of Research (MIR), rue
19 Descartes, 95001 Neuville sur Oise cedex, France.

20 d. Biobank, 3 rue Georges Charpak 77127 Lieusaint, France,

21 e. Service of Odontology, Hôpital Pitié-Salpêtrière APHP, U.F.R. of Odontology
22 University of Paris, 47-83 Boulevard de l'Hôpital, 75013 Paris, France

23

24 *** Corresponding author: fani.anagnostou@univ-paris-diderot.fr; Tel.: +33-(0)1-57-27-**
25 **85-70**

26 **ABSTRACT**

27 Allogenic demineralized bone matrix has been developed as a reliable alternative to the
28 autologous bone graft. In the present study, we assessed the osteoformation potential of a
29 partially demineralized bone matrix (PDBM) in a paste form obtained without an added carrier.
30 This formulation included the preparation of cancellous bone from femoral heads after
31 decellularisation, delipidation, demineralization in HCl and autoclaving at 121°C. Structural
32 and biochemical characteristics of PDBM were determined using FTIR (Fourier transform
33 infrared spectroscopy), hydroxyproline, DNA content assays, and optical ellipsometry. The
34 osteoformation potential was evaluated in 8-, 6-, and 4-mm-diameter rat-calvarial bone defects
35 by *in vivo* micro-CT analysis, performed immediately after surgery on days 0, 15, 30, 45, and
36 60. Moreover, histological and histomorphometric analyses were done on day 60. PDBM was
37 compared to cancellous bone powder (BP) before its partial demineralization. The expression
38 levels of selected inflammation-, angiogenesis-, and bone-related genes were also investigated
39 by RT-PCR, 3, 7, and 14 days after surgery. Compared to the control group, the PDBM group
40 exhibited a significant increase ($p < 0.05$) in radiopacity in 8-mm- and 6-mm-diameter defects
41 at all time points tested. On day 60, the amount of newly-formed bone was greater (16 and 1.6
42 folds; $p < 0.001$; respectively) compared to that in control defects. No bone formation was
43 observed in defects filled with BP regardless of the size. In 8-mm-diameter defect, PDBM
44 was effective enough to induce the upregulation of genes pertinent to inflammation (i.e.,
45 TNF α , IL-6, and IL-8), angiogenesis (i.e., VEGF, VWF), and osteogenesis (ALP, RUNX2,
46 BGLAP, SP7) by day 3 after surgery. This study showed that the tested PDBM deeply
47 influences the early critical events involved in bone regeneration and exhibits efficient
48 osteoformation capacity, making it an attractive graft option for treating defects in periodontal
49 and maxillofacial areas.

50 **Keywords:** critical-size bone defect; bone regeneration; calvarial defect; demineralized bone
51 matrix; bone allograft

52 1. INTRODUCTION

53 Restoration of defects arising from periodontal disease, infections, trauma, and tumor exeresis
54 remains a major challenge in craniofacial surgery. In such clinical cases, autograft is the
55 “gold-standard” treatment, however the morbidity and the limited availability of bone tissue
56 constrain their use. Allografts have been developed as alternatives to autografts [1]. Collected
57 from human donors, machined allografts are customized to precise dimensions and are
58 available in variable forms, including highly processed decellularized bone derivatives such as
59 mineralized and demineralized bone matrix (DBM), demineralized freeze-dried bone allograft
60 (DFDBA), and freeze-driedbone allograft (FDBA) [2,3].

61 Decellularised bone derivatives processed from human bone are widely used as bone
62 substitutes. Allogenic bone substitutes obtained after removing the cells, debris, and
63 extracellular matrix proteins retain their porous structure and osteoconductivity, but not
64 osteogenicity and osteoinductivity [4]. Moreover, in bone powder/ particles (BP) formed,
65 these “fully” mineralised substitutes are not easily handled as they are dispersed by irrigation
66 and blood flow during surgery. On the other hand, DBM contains small amounts of calcium-
67 based solids, inorganic phosphates, some traces of cell debris, and proteinaceous components
68 issued from the bone extracellular matrix (i.e., collagen, non-collagenous proteins, and growth
69 factors including BMPs) [5,6], giving it a bone-forming potential. Allogenic DBM exhibits
70 minimal risk of immunogenic reactions [7] and its efficiency is well documented by several
71 preclinical [8-10-9] and clinical studies [11-13]. However, DBM has varying bone-forming
72 efficiencies [14] depending on its harvesting and processing conditions, sterilization methods
73 and storage [15,5,7], carrier use and preparation form [16,14]. DBM is available in powder,
74 particle, sheet, and putty/ paste forms. The latter form is easy to handle and therefore is the

75 most commonly used. However, conversion of DBM powder to paste by mixing it with a
76 viscous carrier such as hyaluronic acid, carboxymethyl cellulose, poloxamer, calcium sulfate,
77 and so on [17,5,3] has been reported to have several adverse effects, as well as compromising
78 DBM bone-forming efficiency [14]. Therefore, there is an increasing demand for DBM
79 products in paste form, entirely developed from natural bone.

80 Allogenic bone efficiency also varies depending on the extent of demineralization
81 [18,19]. Specifically DBM products to deliver “good” biological performance they have
82 insufficient mechanical stability and, altered ultra-micro-structural properties [19] while the
83 “fully” mineralized bone matrix lacks appropriate osteogenic potential and degradability.
84 Considering these, a partially DBM may be a promising strategy for promoting bone
85 regeneration. Taking these needs into consideration, an allogenic PDBM has been developed
86 (BioBank[®]). It is composed of human bone particles which preserve a part of the mineral in
87 the core after demineralization and are included in collagen-rich gelatin, formed by the organic
88 bone phase without added carriers. It is obtained from a cancellous bone of femoral head after
89 decellularisation, delipidation, demineralization in HCl and autoclaving at 121°C. It should be
90 noticed that in the paste form, it may be directly injected at the implantation site without prior
91 hydration.

92 The objective of the present study was to evaluate the osteoformation potential of the new
93 PDBM in rat calvarial defects. It was compared with that of BP before its partial
94 demineralization which was used as a non-demineralized and non-cohesive bone allogenic
95 reference. It is worth noting that rat is a relevant preclinical model to evaluate bone graft
96 substitutes for the repair of craniomaxillofacial defects [20]. Regarding the controversy
97 surrounding the rationale on the use of critical- or subcritical-size defects [21,22], the
98 biological performance of PDBM was evaluated in calvarial size defects. Moreover, the

99 present study sought to determine whether or not and how the PDBM impacts the early bone
100 healing process in the calvarial defects.

101

102 **2. MATERIALS AND METHODS**

103 **2.1. Partially Demineralized Bone Matrix paste**

104 PDBM and all the other formulations used in the present study were produced and provided by
105 BioBank[®]. These bone substitutes were derived from discarded femoral heads obtained from
106 healthy living donors, selected according to the clinical and serological criteria. Briefly,
107 collected femoral heads first underwent a supercritical CO₂ patented process (EP3134138B1;
108 BioBank[®]) that leads to the production of delipidated and viro-inactivated, clinically approved
109 and commercially authorized, bone allografts.

110 Materials called BP were directly obtained from fractures of cancellous bone issued from the
111 supercrit-treated femoral head after smashing into granules and/or powder particles (0.3 to 1
112 mm in diameter). BP was used as a non-demineralized and non-cohesive bone allograft
113 reference.

114 PDBM referred to the material obtained from BP after a specific two-step treatment. This
115 PDBM -the innovative material of interest in this study- was obtained following a process
116 recently patented (EP3134138B1; BIOBank[®]).

117 The first step consisted of a partial demineralization of the BP following a liquid HCl
118 treatment (4.5 mmol/g) at room temperature during 90 min. Then, the bone-treated acidic
119 solution was dried under hot air flux in order to generate a partially demineralized bone
120 powder (PDBP). The second step consisted of the hydration of the PDBP (bone/water,
121 45/55, w/w) and immediate autoclaving (121°C, 30 min) in certified ISO 13485 conditions

122 (BIO-STERIL, Saint Germain-Nuelles, 69210 France). The autoclaving step of the PDBM
123 mixed with water ensured both the sterilization and the transformation of the outer
124 demineralized organic phase to gelatin. This high temperature and under-pressure treatment
125 led consequently to a spontaneous organization of the matter to a stable and conformable paste
126 form and assured its sterilization. This new bone material (i.e., PDBM) was then packaged
127 under sterile conditions in a specially designed syringe for direct injection to the implantation
128 site. The main advantages of this formulation process are: i) the preparation method that leads,
129 in one single step, to a sterile material formulated in an interesting paste form, and ii) the
130 clinical potential for the surgeons to use this material directly in clinic without a need for prior
131 (re)hydratation and/or reformulation.

132 BP, PDBP, and PDBM characteristics were analyzed, compared to each other, and compared
133 to that of totally calcinated BP (BP after heat treatment at 600°C for 8 h) and totally
134 demineralized BP (BP after HCl treatment at 4.5 mmol HCl/g of bone for 3 h), respectively.

135 Gelatin was provided from Sigma Aldrich (gelatin from porcine skin type A, CAS: 900-70-8).

136 **2.2. Physical and biochemical characterization of the PDBM**

137 **2.2.1. Microscopy:**

138 The surfaces of materials were assessed before implantation using digital microscopy
139 (KAYENCE[®] / VHX-2000F) and environmental scanning electron microscopy (eSEM)
140 (Philips eSEM FEG/XL-30). ESEM examinations were carried out at 15 kV and in a humid
141 atmosphere (approximately from 3 to 5 Torr).

142 **2.2.2. Fourier transform infrared (FTIR) spectroscopy:**

143 FTIR spectra were obtained using a Brüker-Tensor spectrometer, which is piloted by OPUS
144 software equipped with an MCT (mercury cadmium) detector. The acquisitions were made in

145 absorbance mode on a scale of 500 to 4000 cm^{-1} with a resolution of 2 cm^{-1} . Potassium
146 bromide (KBr) pellets were obtained under vacuum using 1 mg of the samples to test and 200
147 mg of IR grade KBr (0.5%) samples.

148 **2.2.3. Determination of collagen content by hydroxyproline assay:**

149 Collagen content was obtained using a hydroxyproline assay. Lyophilized samples
150 (Msamples) were incubated in 0.1 M acetic acid at 37°C for 48 h, and hydrolyzed by 6 N
151 hydrochloric acid (VWR Chemicals) overnight at 106°C to release hydroxyproline residues.
152 After drying under vacuum, the solid residue was soaked in 1 mL of demineralized water
153 (Vsamples). A different diluted (diluted with a different Factor F) solution of hydroxyproline
154 was oxidized by chloramine T, and was stopped by 3.15 M perchloric acid (Sigma-Aldrich)
155 after 20 min. The addition of dimethylamino-4-benzaldehyde (DMBA) generates a complex
156 which is detected by spectrophotometry. This reaction was carried out at 60°C for 20 min, and
157 was stopped by immersing the tubes in cool water (4°C). The optical density of the aliquots
158 was read using a spectrophotometer at a wavelength of 557 nm and compared with a standard
159 range of trans-4-hydroxy-L-proline (Sigma Aldrich) to determine the concentration of
160 hydroxyproline (Chyp). The following equation determines the collagen concentration of the
161 solutions (Ccoll): $C_{\text{coll}} = \text{Chyp} * 7.7 * V_{\text{sample}} * F / M_{\text{sample}}$. Where factor 7.7 represents the
162 converted percentage of hydroxyproline per collagen molecule (13%); F corresponds to
163 dilution factor.

164 **2.2.4. Polarimetry: Optical rotation:**

165 Data were collected using a P-1010 Jasco polarimeter, fitted with a 435 nm filter (this is the
166 usual reference for collagen) and a 1 cm cylinder thermostat (tank-stat). Temperature control
167 was achieved by a Julabo FS18 bath. The optical path was also controlled by Spectra Manager
168 software. Measurements were taken at 27°C. The lyophilized PDBM was solubilized at 20

169 mg/mL (1.5 mg/mL in collagen according to hydroxyproline assay) with 18 mM acetic acid
170 maintained at 27°C for 2 h before the measurement. The device allows the direct measurement
171 of the angle of optical rotation α_λ expressed in degrees. The amount of helix (X) is derived
172 from the specific optical rotation. And X is derived from [23]:

$$173 \quad X = [\alpha]_\lambda^{\text{Helix}} - [\alpha]_\lambda^{\text{Coil}} / ([\alpha]_\lambda^{\text{Collagen}} - [\alpha]_\lambda^{\text{Coil}})$$

174 where λ is the wavelength ($\lambda = 435$ nm); $[\alpha]_\lambda = \alpha_\lambda/lc$ is the specific optical rotation of the
175 protein in solution; c is the concentration (g/cm^3); l is the optical path (0.1 dm); $[\alpha]_\lambda^{\text{collagen}}$ is
176 the specific optical rotation of native soluble collagen ($X = 1$), which contains only triple
177 helices; and $[\alpha]_\lambda^{\text{Collagen coil}}$ is the specific optical rotation of the coils ($\chi = 0$) ($[\alpha]_{436\text{nm}}^{\text{Collagen}} = -$
178 $800 \text{ deg. cm}^3 \cdot \text{g}^{-1} \cdot \text{dm}^{-1}$ at 27 °C, $[\alpha]_{436\text{nm}}^{\text{Collagen coil}} = -274 \text{ deg. cm}^3 \cdot \text{g}^{-1} \cdot \text{dm}^{-1}$ at pH = 7.4 and 40
179 °C).

180 **2.2.5. Quantification of DNA content:**

181 DNA isolation was done by classical phenol-chloroform from three different types of samples:
182 (i) frozen human femur head (HFH) samples which were crushed, milled, weighed, and
183 lyophilized (n=3), (ii) PDBM which was weighed and lyophilized (n=3), and (iii) bone powder
184 (BP) which was only weighed (n=3). All samples were lysed using proteinase K at 56°C
185 overnight within lysis buffer containing 0.25 M NaCl, 1% SDS, 50 mM Tris, and 5 mM
186 EDTA [24]. The concentration of each extracted DNA sample was determined using the
187 Quant-iT™ PicoGreen dsDNA assay kit (Invitrogen) following the manufacturer's
188 instructions and assessed fluorometrically. Samples of known DNA concentration (in the
189 range 0 to 1 ng / μL) were used to generate the standard curve. When needed, extracted DNA
190 was diluted to ensure that the respective absorbance was within the standard curve range. The
191 DNA quantity was normalized to the initial dry weight of the samples.

192 **2.3. Experimental design and animal model**

193 **2.3.1. Animals:**

194 Sixty male, Wistar rats (12 weeks old, 320 to 410 g with mean body weight of 365 g),
195 provided by Janvier Lab, France, were used in this study. The animals were housed at room
196 temperature (20–22°C) and humidity (55%), and were exposed to a 12-hour light/dark cycle
197 (to maintain a normal day/night biological rhythm). They were fed on an *ad libitum* basis with
198 standard laboratory food, and were handled according to the European Guidelines for Care and
199 Use of Laboratory Animals (Directive 2010/63/EU, the European Convention ETS 123, and
200 ARRIVE guidelines). The present animal study was approved by the Ethics Committee
201 2015072718426555 1'2 (APAFIS#1333).

202 **2.3.2. Experimental design:**

203 To do the radiological and histological evaluations, thirty-six animals randomly distributed
204 (n=6 per group) underwent calvarial defect procedures. In Group I, 8-mm defects on each
205 calvarium were left empty; in Group II, 4- and 6-mm calvarium defects were left empty; in
206 Group III, 8-mm calvarium defects were filled with PDBM paste; in Group IV 8-mm
207 calvarium defects were filled with BP; in Group V, 4- and 6-mm calvarium defects were filled
208 with PDBM bone paste; and in Group VI, 4- and 6-mm calvarium defects were filled with BP.
209 Other thirty-six animals randomly distributed (n=6 per group; a total of 12 per time period,
210 i.e., 3, 7, and 14 days after surgery) were assessed in terms of the expression of target genes.

211 **2.3.3. Animal surgery**

212 **2.3.3.1. Anesthesia:**

213 Before the surgery, each rat was first anesthetized by the inhalation of 2% isoflurane and
214 oxygen and then subcutaneously injected with a mixture of Ketamine (IMALGENE®: 40-80
215 mg/kg weight) and Medetomidine (DOMITOR®: 0.5-1 mg/kg animal weight). As pre-emptive

216 analgesia, each animal received an intraperitoneal injection of buprenorphine (0.05 mg/kg
217 animal weight).

218

219 **2.3.3.2. Surgical procedure:**

220 In preparation for surgery, each rat was transferred onto a heating pad, maintained at 37°C on
221 the operating field. Each calvarium was shaved and disinfected using Betadine[®]. Then, an L-
222 shaped incision was made; the skin and the periosteum consisting two successive layers were
223 elevated and the parietal and frontal calvarium bones were exposed. Afterward, circular
224 bicortical defects were made using trephines (under constant irrigation with physiological
225 saline) and taking care to avoid perforation of the dura mater. The 8-mm-diameter defect was
226 centered on the intersection of the sagittal and coronal sutures. The two 4-mm diameter defects
227 were placed on each parietal bone, whilst the 6-mm defect was located on the frontal bone.
228 Thereafter, each defect site was rinsed with sterile saline and was either left empty or filled
229 with 100 mg of PDBM paste using a specifically designed syringe and applying light pressure
230 or with BP rehydrated with 0.9 NaCl (0.6mL/cc) for 10 min. Finally, the periosteum and skin
231 of the animals were closed with absorbable sutures.

232 **2.3.3.3. Post-surgical animal care:**

233 After surgery, all animals were given the following subcutaneous injections: (i)
234 Buprenorphine, to relieve the pain during the post-operative period; (ii) 5% Baytril[®], as
235 prophylactic antibacterial treatment; and (iii) Antisedan[®] (5 mg/mL), to accelerate awakening.
236 Rats were kept onto the heating pad until awakening. During the postoperative 24 hours, each
237 rat was kept in a separate cage under observation by the animal care personnel. The animals
238 were sacrificed at the determined time points using an overdose of pentobarbital
239 (DOLETHAL[®]). The calvarial bone was then excised, defleshed, and prepared for analysis.

240 **2.4. In vivo micro-CT analysis**

241 For each animal, a longitudinal analysis of the radiopacity of the calvarial defects, either left
242 empty or filled with PDBM paste, or BP was performed immediately after surgery on days 0,
243 15, 30, 45, and 60 using a high-resolution, non-invasive, in vivo micro-scanner (micro-CT,
244 Skyscan 1176, Brucker, Aartselaar, Belgium). To do this analysis, the rats were anesthetized
245 using inhaled isoflurane. Images were acquired at the following settings: 50 kV voltage, 476
246 mA current, exposure time of 40 ms, and a rotation step of 0.7° through a 0.5-mm-thick
247 aluminum filter. The image acquisition time per rat was 6 min. Each three-dimensional (3D)
248 image was reconstructed using a 35-micron average voxel size and using the manufacturer's
249 reconstruction software (NRecon Skyscan 1176, Brucker, Aartselaar, Belgium). 3D
250 visualization was performed with CTVox software (Skyscan 1176, Brucker, Aartselaar,
251 Belgium). Quantitative analysis of the radiopacity volume was also done by DataViewer and
252 CTAn software packages (Skyscan 1176, Brucker, Aartselaar, Belgium). For each rat and each
253 defect of interest in the present study, a cylindrical region of interest (ROI) was fixed at day 0
254 of the study, corresponding to the diameter of each defect, specifically 4, 6, and 8 mm with a
255 height of 5 mm, and subsequently used as a reference for respective data obtained on days 0,
256 15, 30, 45, and 60. post-surgery. These ROI dimensions were chosen to take into account all
257 newly formed bone tissues in all cases and time points tested during the healing process. The
258 gray levels corresponding to bone tissue and the PDBM paste and BP were similar;
259 consequently, for the defects that had been left empty, the measured radiopacity presented
260 only the newly formed bone tissue/volume (BV). In the case of defects filled with the PDBM
261 paste, the measured radiopacity presented the sum of both the radiopacity of the biomaterial
262 and that of the newly formed bone tissue.

263 **2.5. Histology and Histomorphometry**

264 The excised calvarial specimens were prepared for non-demineralized histological analysis.
265 Each bone specimen was fixed in 10% neutral-buffered formalin, rinsed with water,

266 dehydrated using a series of increasing concentrations of ethanol solutions, cleared with
267 xylene, and then embedded in methyl methacrylate. After polymerization, the calvarial bone
268 blocks were oriented to radiography to obtain cross-sections cut parallel to the sagittal plane.
269 Each such section was ground down to a thickness of 300 μm using the exact grinding system
270 (Exakt Apparatebau GmbH Norderstedt, Germany), and polished down to 100 μm . Each
271 section was stained with Stevenel's blue and Van Gienson's picro fuschin before visualization
272 using standard light microscopy.

273 Images of histological sections were obtained using a light microscope (Olympus Bx 4500)
274 connected to a digital camera (Nikon Coolpix 4500) equipped with a video and image analysis
275 system (NIS Elements BR 2.3, Nikon France S.A.S., France). The images that corresponded to
276 the three successive cross-sections of each defect center were analyzed. To overcome the
277 problem arising from the similarity of bone and material pixels on the digitized and calibrated
278 images, the newly formed bone area and residual particles were delineated manually. The total
279 area of newly formed bone was calculated by adding the areas measured and reported in mm^2 .

280 **2.6. Gene expression analyses**

281 Three, 7, and 14 days after surgery, the rats were sacrificed and the calvarial specimens were
282 harvested. The mRNA expression of selected genes was determined quantitatively using RT-
283 PCR as previously described [25]. The tissue inside the 8-mm-diameter defects was retrieved,
284 homogenized, and total RNA was extracted using the TRIzol[®] Reagent according to the
285 manufacturer's protocol (Invitrogen, France). A NanoDrop spectrophotometer (NanoDrop
286 1000, Labtech, Palaiseau, France) was used to determine the RNA concentration and purity.
287 After RNA isolation, 500 ng of total RNA was reverse-transcribed into cDNA using the
288 superscript II transcriptase kit (Invitrogen), in which random hexamers were used as primers.
289 Correspondingly, for each time-point of interest, 20 μL of RNA from each sample in the
290 empty calvarium defect group was pooled and reverse transcribed into cDNA to serve as a

291 reference control. Each RT-PCR analysis was performed in triplicate using 12.5 ng cDNA
292 (RNA equivalent) on the CFX 96 Real-time system (BIORAD Laboratories).

293 Amplification of the cDNA, using TaqMan[®] gene expression assays of genes encoding for
294 TNF α (Tumor necrosis factor), IL-1 β
295
296 GF (Vascular endothelial growth factor), ANG (Angiogenin), CDH5 (Cadherin 5), PECAM1
297 (Platelet endothelial cell adhesion molecule), VWF (Von Willebrand factor), ALP (Alkaline
298 phosphatase), RUNX2 (Runt-related transcription factor 2), COL1A1 (alpha-1 type I collagen),
299 BGLAP (Bone gamma-carboxyglutamate protein), SP7 (Sp7 transcription factor), MMP13
300 (Matrix metalloproteinase 13), OPG
301
302
303 (n cysteine), and TaqMan Universal PCR
304 Master Mix (Applied Biosystems Inc.) was performed by an iCycler thermocycling apparatus
305 (MyiQ[™] Single-Color Real-Time PCR; Bio-Rad Laboratories). All reagents were supplied
306 from Applied Biosystems Inc.: 18s (Hs 99999901_s1), TNF α (Rn 01525859_g1), IL-1 β (Rn
307 00580432_m1), IL-6 (Rn 01410330_m1), IL-8 [cxcl1] (Rn 005578225_m1), VEGF
308 (Rn00582935_m1), ANG (Rn 02349499_g1), CDH5 (Rn 01536708_m1), PECAM1 (Rn
309 01467262_m1), VWF (Rn 01492158_m1), ALP (Rn 00689814_m1), RUNX2 (Rn
310 01512298_m1), COL1A1 (Rn 01463848_m1), BGLAP (Rn 01455285_g1), SP7 (Rn
311 01761789_m1), MMP13 (Rn 01448194_m1), OPG (Rn 00563499_m1), RANKL (Rn
312 00589289_m1), and SPARC (Rn 00561955_m1). For gene expression measurements, 18s
313 RNA endogenous control (house-keeping gene with a constant expression level) was used as
314 an internal control. Additionally, relative gene expression was calculated using the $\Delta\Delta C_t$

315 method by normalizing the Ct value of each gene at each time-point to the Ct value of the
316 corresponding pooled sample.

317 **2.7. Statistical analyses**

318 Numerical values of the volume of regenerated bone within the defects, as well as the RT-PCR
319 results of interest in the present study are reported as mean value \pm standard deviation (SD).
320 Statistical analysis was performed using the Student's unpaired t-test. Furthermore, differences
321 with P -value < 0.05 were considered statistically significant.

322 **3. RESULTS**

323 **3.1. PDBM characterization**

324 In digital microscopy, the partially demineralized bone matrix (PDBM) paste and the bone
325 powder (BP) showed different forms (Figure 1A and 1D). In scanning electron microscope
326 (eSEM), the PDBM showed an amorphous structure devoid of collagen fibers (Figure 1B-C)
327 while BP exhibited small particles consisting collagen bundles with different orientations
328 (Figure 1E and 1F). The efficiency of the decellularization was evaluated by the quantification
329 of residual DNA in human femoral heads (HFH), BP, and PDBM. DNA level was
330 significantly ($p < 0.05$) reduced in PDBM (2.22 ± 0.33 ng /mg) and in BP (0.55 ± 0.03 ng/mg)
331 compared to the pertinent results obtained from HFH (296.9 ± 74.33 ng/mg) (Figure 1G). The
332 DNA level was considerably ($p < 0.05$) lower than the 50 ng/mg threshold [26] in both PDBM
333 and BP.

334 PDBM paste was further analyzed with Fourier transform infrared (FTIR) and compared with
335 that of the BP, fully calcinated or totally demineralized. The absorption bands located at 1655
336 and 1565 cm^{-1} corresponded to the amide I and amide II, respectively. The peak around 1450
337 cm^{-1} was attributed to the carbonate. While the peak at 1000 and the double peaks at 657 and
338 577 cm^{-1} were attributed to the phosphate contents ν_1 and ν_4 , respectively (Figure 1H). As
339 expected, in the calcinated BP, amide I and amide II bands were totally eliminated. In the

340 completely demineralized form of the BP, the two organic bands were the unique compounds
341 preserved. In contrast with both bands in the BP, as in the PDBM paste, the two organic and
342 the four inorganic components were present. However, it is worth to note that in the PDBM
343 paste, the bands present in the spectrum were similar though the intensity was different. The
344 proportion of amide peaks to inorganic compounds was more attenuated in the PDBM paste
345 compared to the BP. This result confirms the loss of part of the inorganic phase and
346 subsequently the increase of the relative contribution of the organic phase in the PDBM paste
347 in comparison with the BP.

348 The organic phase of PDBM was analyzed by hydroxyproline content, and collagen type I was
349 further characterized by optical ellipsometry. The quantity of “collagenic phase” extractible
350 from the BP and the PDBP (the partially demineralized form of BP) was 0.005 mg/mg product
351 and 0.009 mg/mg product, respectively. In the PDBM paste, the relative quantity of accessible
352 collagenic phase was still weak (0.073 mg/mg product) though significantly higher (Figure
353 1I). It was compatible to compare these experimentally observed values with the collagen
354 amount expected from theoretical calculations; 0.3 mg/mg, 0.23 mg/mg, and 0.46 mg/mg for
355 BP, PDBP, and the PDBM paste, respectively. Interestingly, the percentage of accessible
356 collagenic fraction on BP and PDBP was less than 2% ($0.005/0.3 = 1.66\%$; $0.009/0.46 =$
357 1.96% for BP and PDBP, respectively), whereas this amount reached more than 30% in the
358 PDBM paste ($0.073/0.23 = 31.7\%$). This result demonstrated that the organic phase accessible
359 from the PDBM matrix was 15 times higher than that in the powder form of the material. In
360 conclusion, the biochemical analysis suggested that the thermic process increased the
361 “accessibility” of the organic phase. The organic phase extracted from PDBM was
362 characterized in polarimetry via measuring the optical rotation. The values of the optical
363 rotation measured by polarimetry at 435 nm compared to native collagen in the same
364 conditions allowed to estimate the amount of helix alpha in the biochemical structure of

365 PDBM paste (Table 1). The quantity found (only 13%) suggested that the organic phase of
366 PDBM was mainly constituted by collagen fragments like gelatin. Moreover, ellipsometry
367 measurements in various temperature conditions showed that the rotary power of PDBM
368 (reflecting the presence of helix alpha within collagen) was similar to that observed in gelatin,
369 suggesting that the organic phase of PDBM was mainly constituted by collagen fragments.

370 **3.2. Clinical observation**

371 All animals regained their ambulatory capabilities within 2-3 hours after surgery. All surgical
372 wounds healed uneventfully. Moreover, there were no changes in the animal body weight,
373 behavior, and in the overall animal health during the 8-weeks post-surgery period.

374 **3.3. Bone repair kinetics**

375 To study the bone healing as a function of the size of calvarial defect, critical 8-mm-diameter
376 and subcritical, specifically, 6-, 4-mm-diameter defects on the same rat in a multi-defect
377 calvarial model was used. *In vivo* micro-CT scans of the defects either filled or not filled with
378 BP or PDBM paste was immediately made after surgery at day 0 (D0) and during the 2nd, 4th,
379 6th, and 8th weeks post-surgery. In the empty 8-mm-diameter defects, only small areas of
380 radiopacity were observed mainly along the borders during the entire healing period (Figure
381 2A1). In the BP-filled defects, radiopacity area decreased from D0 to D15 (Figure 2A2), while
382 in the PDBM-filled defects, radiopacity areas were present as early as the 2nd week after
383 surgery (Figure 2A3). In the PDBM-filled defects, compared to D0, the radiopacity volume
384 (evidence for the residual implanted material and the new formed bone volume) was
385 significantly ($p < 0.05$) increased by 2 folds at the 2nd week and reached a plateau at the 4th
386 week post-surgery (Figure 2B). Compared to the empty defects and the BP-filled defects, the
387 radiopacity in the PDBM paste-filled defects was significantly ($p < 0.05$) increased, for
388 exemple by 3.5 folds ($16.64 \pm 6.9 \text{ mm}^3$ and $22.2 \pm 6.4 \text{ mm}^3$ vs. $4.87 \pm 3.72 \text{ mm}^3$, and $6.27 \pm$
389 5.09 mm^3 for the PDBM paste-filled and empty defects, respectively, at the 4th and 8th weeks

390 post-surgery) (Figure 2B). These results provided evidence that PDBM notably promoted new
391 bone formation.

392 The radiopacity areas increased along with the healing time in 6-mm-diameter defects left
393 empty and in PDBM paste-filled defects; while in the BP-filled defects, the radiopacity
394 decreased from D0 to D15 (Figure 3A). New bone formation, especially in the frontal area of
395 the empty defects, was present at the 2nd post-surgery week, which improved thereafter and
396 attained a plateau at the 4th week (Figure 3A1). The animal group which had received the
397 PDBM paste exhibited significant improvement ($p < 0.05$) in every defect at all time-points
398 tested ($6.23 \text{ mm}^3 \pm 1.17$ vs $22.15 \text{ mm}^3 \pm 3.45$ at D0 and D60, respectively; Figure 3B). At
399 D60, compared to the empty- and BP-filled defects, the defects filled with PDBM paste
400 exhibited a significant increase ($p < 0.05$) in radiopacity volume (almost 3-folds; Figure 3B). In
401 vivo micro-CT scans, monitoring the subcritical-size defects, revealed that the 6-mm- and 4-
402 mm-diameter empty calvarial defects exhibited a different time course of the bone healing
403 process (Figure 3A). In the case of 4-mm diameter defects, the radiopacity volume also
404 increased over the time course of healing process in both animal groups tested (Figure 3A).
405 Two 4-mm-diameter calvarial defects were created bilaterally in both animal groups tested
406 (specifically the controls and those filled with BP or PDBM paste). Comparison of the results
407 from the two empty defects located in the same rat revealed differences related to the incision
408 location and the flap: in defects away from the flap incision, increased bone formation was
409 systematically observed over the time period of the present study in all defects in contrast to
410 the defects close to the lateral flap incision (Figure 3A). The radiopacity volume increased in
411 the empty defects of the rats in the control group over time and was similar to that observed
412 for the defects filled with BP or PDBM paste in the treated rat group (Figure 3C).

413 **3.4. New bone formation**

414 After 8 weeks of implantation, in the empty and BP-filled 8-mm-diameter defects, newly
415 formed bone was observed mainly at the edge of the defects (Figure 4A and 4B). On the
416 contrary, new bone formation in the defects filled with the PDBM paste was localized both at
417 the edges and in the center of the defects around remnants of PDBM paste (identified as
418 varying-size particles of bone with cell-free lacunas) (Figure 4C and 4D). Quantitative
419 analysis confirmed radiological findings in that a considerable amount of bone was formed. In
420 other words, bone area was significantly increased ($p < 0.05$) specifically by 16.34 times and
421 2.16 times, compared to that observed in the defects that had remained empty or filled with BP
422 (specifically, $1.02 \pm 0.32 \text{ mm}^2$ vs $0.06 \pm 0.05 \text{ mm}^2$ and $0.47 \pm 0.5 \text{ mm}^2$ respectively) (Figure
423 4E). In the case of the 6mm-diameter-PDBM-filled defects, a newlyformed bone was observed
424 throughout the filled defects. The newly formed bone was either surrounding or bridging the
425 particles from the edge to the central area of the defect, while it was mainly located at the
426 periphery of the empty and the BP-filled defects (Figure 5A, 5B and 5C). Lacuna containing
427 osteocytelike and some lining cells, as well as blood vessels and bone marrow were observed
428 in the newly formed bone (Figure 5D). The area of the newly formed bone was significantly
429 ($p < 0.05$) greater (by about 1.6 times and 2.58 times) in the defects filled with the PDBM paste
430 than those in the defects left empty or filled with BP (specifically, $1.96 \pm 0.81 \text{ mm}^2$ vs $1.24 \pm$
431 0.75 mm^2 and $0.76 \pm 0.52 \text{ mm}^2$ respectively) (Figure 5E). In the case of the 4-mm-diameter
432 defects, the new bone formed in the empty defects (located away from the flap incision) had
433 almost filled entirely these defects (Figure 6A, 6B and. 6C). Quantitative analysis showed that
434 the amount of newly formed bone was similar in the empty, BP and PDBM-paste-filled
435 defects (Figure 6D). None of the defects exhibited inflammation or foreign body reaction.

436 **3.5. Expression of selected inflammation-, angiogenesis- and bone-related genes**

437 To determine whether and how PDBM affects the early stages of intramembranous bone
438 regeneration, the expression of selected genes in 8-mm-diameter-PDBM-filled defects was

439 compared to those expressed in empty same-diameter ones at 3, 7, and 14 days after
440 implantation.

441 **Gene expression of inflammatory markers:** The time course of TNF α , IL-1 β , IL-6, and IL-8
442 mRNA expression in both empty- and PDBM-filled defects increased from D3 to D7 exhibited
443 a peak at D7 and decreased thereafter (for up to 14 days) (Figure 7A, B). Compared to the
444 respective results obtained from the empty defects, the PDBM-filled ones exhibited significant
445 upregulated expression (by 2.5 and 6.8 folds; $p=0.003$ and $p=0.01$, respectively) of the TNF α
446 gene at D3 and D7 (Figure 7A). IL-6 and IL-8 genes were also upregulated (by 4.7 and 4
447 folds; $p= 0.046$ and 0.036 , respectively) only at D3 post-surgery (Figure 7B). On the contrary,
448 IL-6 expression was significantly down-regulated at D7 ($p= 0.02$; Figure 7B). Non-significant
449 difference was observed in the expression level of IL-1 β gene in both groups tested; that is, the
450 expression was similar at all time-points checked (Figure 7A).

451 **Gene expression of angiogenesis markers:** Expression of angiogenesis markers showed a
452 similar temporal trend to that of inflammatory markers in both empty and PDBM-filled defects
453 (Figure 7C, D). Expression of VEGF, ANG, CDH5, PECAM1, and VWF genes exhibited a
454 peak level at D7 post-surgery. Moreover, the expression of all aforementioned genes was
455 increased from D3 to D7 and decreased thereafter. Compared to the empty defects, the
456 expression levels of VEGF and VWF in the PDBM-filled defects were significantly increased
457 at D3 ($p=0.019$ and $p=0.014$, respectively; Figure 7D). Expression of the ANG gene increased
458 at D7 ($p=0.036$), while that of CDH5 was downregulated at D14 ($p= 0.007$; Figure7C).
459 Moreover, the expression levels of all angiogenesis markers selected for the empty and
460 PDBM-filled defects were similar for all other time-points tested.

461 **Expression of genes pertinent to bone formation and remodeling:** RUNX2, MMP13,
462 RANKL, and SPARC genes were upregulated in the empty defects, from D3 to D7 post-
463 surgery (Figure 8B, C). The presence of PDBM affected these outcomes. Compared to the

464 results obtained from the empty defects, expression of the ALP, BGLAP, SP7, and RUNX2
465 genes in the PDBM-filled defects was significantly higher at D3 (p= 0.004, 0.02, 0.015, and
466 0.008, respectively; Figure 8A and B). From D3 to D7, only the expression of ALP, BGLAP,
467 SP7, RUNX2, COL1A1, and RANKL genes was decreased (Figure 8A, B, and C); while the
468 expression of other genes tested was similar during those days. From D7 to D14, only the
469 expression of RANKL gene was significantly increased (p= 0.001; Figure 8C). The presence
470 of PDBM in the defects differently affected the expression of aforementioned genes over time.
471 Specifically, the expression of the genes ALP (D3), RUNX2 (D3), BGLAP (D3), SP7 (D3),
472 and RANKL (D14) was significantly up-regulated (p= 0.004, 0.02, 0.015, and 0.016,
473 respectively) by the presence of PDBM in the calvarium defects tested. In contrast, the
474 expression of ALP (D7 and D14), BGLAP (D14), SP7 (D14), COL1A1(D7), OPG (D7), and
475 SPARC (D7) was significantly down-regulated (p= 0.04, 0.03, 0.012, 0.016, 0.013, 0.011 and
476 0.001, respectively; Figure 8A, B, and C).

477 **4. DISCUSSION**

478 Allogenic demineralized bone matrix (DBM) is regarded as a viable alternative option for
479 autografts ([5,3]. Its use is increasing and different formulations are constantly
480 emerging;however, at the present time, conditions under which DBM exhibits optimal
481 osteoforming activity remain elusive. The present study investigated for the first to our
482 knowledge the *in vivo* response of a new formulation of allogenic partially DBM (PDBM). It
483 was prepared from cancellous bone of femoral heads after decellularisation, delipidation, and
484 demineralization in HCl, as well as autoclaving at 121°C. It consisted of partially demineralized
485 bone particles (PDBP), in a collagen-rich gelatin, formed by the organic bone phase without
486 added carriers. The biological performance of PDBM paste was studied in healing the bone
487 defect in the rat calvarium model, in critical- and subcritical-size calvarial defects, in
488 comparison to that of the BP before its partial demineralization, which was used as a non-

489 demineralized and non-cohesive bone allograft reference. Results obtained showed that the
490 new PDBM paste had an enhanced clinical use (ready-to-use, easy-to-handle, moldable, and
491 cohesive), influenced the early critical events involved in bone regeneration, and exhibited
492 efficient bone forming capacity in critical-size calvarial defects.

493
494 In contrast to BP, PDBM paste promoted bone healing in 6- and 8- mm-diameter calvarial
495 bone defects, both considered critical-sized [21,22]. As expected, the extent of new bone
496 formation was decreased by increasing the size of the defect. However, PDBM paste presence
497 showed to be crucial for the repair of the 8-mm defects, as the amount of newly formed bone
498 in defects filled with PDBM was increased by about 16.5 folds compared to that of defects left
499 empty at 8 weeks post-implantation. Bone healing was accelerated in 6-mm defects left empty,
500 and after PDBM addition the new bone formation augmented only 1.6 folds. While, in the 4-
501 mm defects, the closure was observed regardless of the PDBM presence, showing that the use
502 of PDBM was not clinically effective in regenerating small defects. It is interesting to note that
503 no new bone formation in contact to or around the BP was observed regardless of the size of
504 the bone defect. Moreover, in the critical-size PDBM-filled defects, the bone formation was
505 enhanced as the radiopacity volume was significantly increased ($p < 0.05$) already at the 2nd
506 week post-surgery, suggesting that PDBM may be also clinically effective in shortening the
507 time required for bone healing after surgery. Some studies have investigated the potential of
508 allogenic DBM in the same animal model and reported contradictory results. For instance, in
509 the 8-mm-diameter defects, DBM showed significant bone-forming capacity [18,8,10] while
510 others showed limited capability [27-29]. Direct comparison between the results of this study
511 and the aforementioned published reports is thus not possible due to differences in the DBM
512 formulations, as well as the outcome measures.

513 The bone-forming potential of PDBM paste may be attributed to several factors including
514 enhanced clinical use. It displays improved surgical handling properties, adaptation to the
515 uneven walls of the bone defects and cohesive between the particles properties without
516 drawbacks of added carriers. Paste form was obtained entirely from bone and showed a
517 significant bone-forming advantage over human BP. Carriers (e.g., hyaluronic acid,
518 carboxymethylcellulose, glycerol, calcium sulfate, gelatin, etc.) used to turn DBM powder to
519 paste or putty forms [30,3] have been reported to compromise DBM clinical performance by
520 decreasing the amount of the active DBM components [16,14] and/or by adverse effects such
521 as inflammation [31,32].

522 In histology, the PDBM paste showed typical osteoconductive phenomena, including newly-
523 formed bone at the defect edges and around the PDBM remnants (Figure 5C), probably due to
524 both the partially demineralized bone particles and the collagen-rich gelatin.. DBM
525 osteoconductivity has been reported as the primary mechanism for supporting the DBM-
526 associated bone formation [5,10], and gelatin derived from the collagen hydrolysis has been
527 shown to be highly biocompatible and biodegradable [33] and plays a role in promoting cell
528 adhesion. Moreover, PDBM has been displayed better applicability than un-demineralized or
529 full DBM [19], and in contrast to full DBM, PDBM particles could act in a more bone-like
530 manner, providing immediate structural support to unstable osseous defects.

531 Bone forming capacity of DBM is also attributed to its osteoinductivity [5,34]. In the present
532 study, the bone formation in the center of the PDBM-filled critical-sized defects could suggest
533 a slight osteoinductive potential though further confirmatory evaluation with heterotopic
534 implantation is required. Moreover, in the PDBM-filled defects, the expression of RUNX2,
535 ALP, SP7, and BGLAP genes was upregulated 3 days after surgery. These genes are closely
536 related to osteogenesis [35,36] and their upregulated expression under the effect of PDBM in
537 the bone defect could signify the recruitment and/or enhanced differentiation of

538 osteoprogenitor cells. However, osteoinduction implication in the cellular behavior is unlikely
539 as PDBM paste was obtained with autoclaving the PDBP, a process that denaturates growth
540 factors, including BMPs, which are released during demineralization and therefore abolishes
541 their “osteoinduction” properties.

542 Indeed, autoclaving is a key and puzzling point for the mechanisms underlying the
543 osteoformation capacity of the PDBM paste observed in the present study. Autoclaved
544 autografts or allografts have been used to reconstruct bone with interesting results [37,38]
545 while it has been reported that in addition to the denaturation of bone organic matrix,
546 autoclaving also alters its mechanical and structural properties [39,40]. Consequently, in the
547 present study autoclaving the PDBP, in addition to transforming the outer demineralized
548 organic phase in a collagen-rich gelatin probably modifies the structural and biomechanical
549 properties of the mineral part preserved in the core, thereby influencing the cell behavior in a
550 multifacet manner. For instance, it has been reported that pepsin-digested and solubilized
551 DBM hydrogel allows osteoprogenitors proliferation [41] and denaturated collagen promotes
552 fibroblast survival [42] while partially demineralized displays better osteoprogenitor adhesion
553 and proliferation than those completely demineralized [19]. It is logical therefore to consider
554 that in the osteoformation capacity of the PDBM is involved an overall effect of the material,
555 paste structure, mechanical properties, and constitutive molecules. Further comparison of the
556 potential of PDBM paste with those of the PDBP before autoclaving and fully DBP *in vivo*
557 and the comparison of the osteoprogenitor behavior towards such substitutes is necessary to
558 decipher mechanisms involved in the osteoconduction/ osteoinduction process.

559 Besides the osteogenesis -related genes, another main finding of the present study that pointed
560 out the PDBM influence in the early critical events involved in bone regeneration was that
561 PDBM differently modulated the expression of genes pertinent to inflammation and
562 angiogenesis at days 3 and 7 post-surgery. Proinflammatory cytokines such as TNF α , IL-1, IL-

563 6, and IL-8, which mainly contribute to the initiation of the healing process by recruiting
564 macrophages and osteoprogenitor cells from their local niches [43-45], were highly expressed
565 in empty-left defects, reflecting inflammation during the early wound healing [46]. In the
566 PDBM-filled defects, the overall increase of the aforementioned gene expression levels clearly
567 indicated that the PDBM promoted immuno-inflammatory mechanisms at least at gene level
568 and might be involved in the early recruitment of mesenchymal stem cells and osteoprogenitor
569 cells. Moreover, we observed that the angiogenesis-related genes exhibited a temporal trend
570 similar to that of inflammation, that is, a trend towards higher expression at D7 and a
571 reduction at D14, which corresponds with the gradual process of maturation from the
572 granulation tissue to woven bone formation taking place between days 7 and 14 [46]. PDBM
573 significantly upregulated the expression level of VEGF and VWF at D3 and that of ANG at
574 D7. Above all, VEGF is a signaling protein that is induced during the inflammation phase
575 within the surrounding bone cells or recruited inflammatory cells [47,48], initiates
576 macrophage-related angiogenic responses [49], and is a crucial factor in angiogenesis-
577 osteogenesis coupling during intramembranous ossification-mediated bone healing [50].
578 The present study showed for the first time the PDBM-associated modifications of the
579 transcriptional profile pertinent to bone repair ; however, it suffers some limitations. Firstly,
580 the gene expression profile has to be associated with histology and immunohistochemistry to
581 further understand the PDBM impact on the early healing. Secondly, the harvested tissue
582 comprised various cell types, making difficult to localize the source of the gene expression
583 within the defects. Lastly, the identification of genes in later time points should also be
584 analyzed.

585 **5. CONCLUSION**

586 Results of the present study indicated the characterization and the biological performance of a
587 new PDBM paste. PDBM consists of PDBP in a collagen-rich gelatin, formed by the organic

588 bone phase without added carriers. This formulation included the preparation of the cancellous
589 bone from femoral head after decellularisation, delipidation, and demineralization in HCl, as
590 well as autoclaving at 121°C, a process that ensures both the sterilization and transformation
591 of the outer organic phase of the PDBP to gelatin. It exhibits many advantages for the
592 clinicians, that is providing a ready-to-use, easy-to-handle, moldable, and cohesive paste,
593 which can be packed into bone defects and resists against irrigation and bleeding during
594 surgery. Implanted in critical-size calvarial defects, it also exhibits a bone-forming capacity in
595 contrast to BP which before demineralization failed to show any new bone formation capacity
596 in both critical- and subcritical-size calvarial defects. The comparison of the transcriptional
597 profile of genes in 8-mm-diameter-PDBM-filled defects to that of genes in empty defects
598 showed that PDBM deeply influences the early critical events involved in bone regeneration.
599 The PDBM efficient bone formation capacity makes it an attractive graft option for treating
600 the defects in periodontal and maxillofacial areas.

601

602

603 **Acknowledgments**

604 We gratefully acknowledge the help of Prof. Rena Bizios for critically review of the paper. We
605 also thank Nathanael Larochette and Hanane El-Hafci for their technical support.

606 **Formatting of funding sources**

607 This study was supported by Campus France, and “Fondation des Gueules Cassées” [N° 53,
608 2018].

609 **Author contributions:** AMD : design, data research, analysis, and interpretation and
610 manuscript writing; MB and HP : data research, analysis and interpretation and critically read
611 the manuscript; SR, BM and EP: data research, analysis, and interpretation regarding material

612 characterization; RB: provided bone substitutes used; HMB: critically read the manuscript;
613 FA: conception, design, data analysis and interpretation and manuscript writing/ editing.

614 **Conflict of interest:**

615 AMD, HP, HMB, FA declare that they have no conflicts of interest

616 SR work at c and d

617

618

619

620 **REFERENCES**

- 621 [1] V. Campana, G. Milano, E. Pagano, M. Barba, C. Cicione, G. Salonna, W. Lattanzi, G.
622 Logroscino, Bone substitutes in orthopaedic surgery: from basic science to clinical
623 practice, *Journal of Materials Science: Materials in Medicine* 25 (2014) 2445-61. doi:
624 10.1007/s10856-014-5240-2.
- 625 [2] W. Wang, K.W.K. Yeung, Bone grafts and biomaterials substitutes for bone defect
626 repair: A review, *Bioactive Materials* 2 (2017) 224-247. doi:
627 10.1016/j.bioactmat.2017.05.007.
- 628 [3] H. Zhang, L. Yang, X.G. Yang, F. Wang, J.T. Feng, K.C. Hua, Q. Li, Y.C. Hu,
629 Demineralized Bone Matrix Carriers and their Clinical Applications: An Overview,
630 *Orthopaedic Surgery* 11 (2019) 725-737. doi: 10.1111/os.12509.
- 631 [4] P. Baldwin, L.J Deborah, D.A Auston, M.S. Hassan, R.S. Yoon, K.J. Kenneth.
632 Autograft, Allograft, and Bone Graft Substitutes: Clinical Evidence and Indications for
633 Use in the Setting of Orthopaedic Trauma Surgery, *Journal of Orthopaedic Trauma* 4
634 (2019) 203-213. doi: 10.1097/BOT.0000000000001420.

- 635 [5] E. Gruskin, B.A. Doll, F.W. Futrell, J.P. Schmitz, J.O. Hollinger, Demineralized bone
636 matrix in bone repair: history and use, *Advanced Drug Delivery Reviews* 64 (2012)
637 1063-77. doi: 10.1016/j.addr.2012.06.008.
- 638 [6] M.G. Gonzaga, B.G. Dos Santos Kotake, F.A.T. de Figueiredo, S. Feldman, E.
639 Ervolino, M.C.G. Dos Santos, J.P.M. Issa, Effectiveness of rhBMP-2 association to
640 autogenous, allogeneic, and heterologous bone grafts, *Microscopy Research and*
641 *Technique* 82 (2019) 689-695. doi: 10.1002/jemt.23215.
- 642 [7] N. Bhamb, L.E.A. Kanim, S. Drapeau, S. Mohan, E. Vasquez, D. Shimko, W.
643 McKAY, H.W. Bae, Comparative Efficacy of Commonly Available Human Bone
644 Graft Substitutes as Tested for Posterolateral Fusion in an Athymic Rat Model,
645 *International Journal of Spine Surgery* 13 (2019) 437-458. doi: 10.14444/6059.
- 646 [8] N. Mokbel, C. Bou Serhal, G. Matni, N. Naaman, Healing patterns of critical size bony
647 defects in rat following bone graft, *Journal of Oral and Maxillofacial Surgery*, 12
648 (2008) 73-8. doi: 10.1007/s10006-008-0107-7.
- 649 [9] C.I.A. Van Houdt, DA. Cardoso, B.A.J.A. van Oirschot, D.J.O. Ulrich, J.A. Jansen,
650 S.C.G. Leeuwenburgh, J.J.J.P. van den Beucken, Porous titanium scaffolds with
651 injectable hyaluronic acid-DBM gel for bone substitution in a rat critical-sized
652 calvarial defect model, *Journal of Tissue Engineering and Regenerative Medicine* 11
653 (2017) 2537-2548. doi: 10.1002/term.2151.
- 654 [10] A. Sindel, Ö. Dereci, H.S. Toru, S. Tozoğlu, Histomorphometric Comparison of Bone
655 Regeneration in Critical-Sized Bone Defects Using Demineralized Bone Matrix,
656 Platelet-Rich Fibrin, and Hyaluronic Acid as Bone Substitutes, *The Journal of*
657 *craniofacial surgery* 28 (2017) 1865-1868. doi: 10.1097/SCS.0000000000003588.
- 658 [11] C.A. Serrano Méndez, N.P. Lang, M. Caneva, G. Ramírez Lemus, G. Mora Solano, D.
659 Botticelli, Comparison of allografts and xenografts used for alveolar ridge

660 preservation. A clinical and histomorphometric RCT in humans, *Clinical Implant*
661 *Dentistry and Related Research* 19 (2017) 608-615. doi: 10.1111/cid.12490.

662 [12] Ö. Solakoglu, W. Götz, G. Heydecke, H. Schwarzenbach, Histological and
663 immunohistochemical comparison of two different allogeneic bone grafting materials
664 for alveolar ridge reconstruction: A prospective randomized trial in humans, *Clinical*
665 *Implant Dentistry and Related Research* 21 (2019) 1002-1016. doi: 10.1111/cid.12824.

666 [13] A. Patel, H. Greenwell, M. Hill, B. Shumway, A. Radmall, Ridge Augmentation
667 Comparing an Allograft Plus Autogenous Bone Chips to an Osteoinductive
668 Demineralized Bone Matrix: A Clinical and Histologic Study in Humans, *Implant*
669 *Dentistry* 28 (2019) 613-620. doi: 10.1097/ID.0000000000000925.

670 [14] N. Russell, W.R. Walsh, V. Lovric, P. Kim, J.H. Chen, M.J. Larson, F. Vizesi, In-vivo
671 Performance of Seven Commercially Available Demineralized Bone Matrix Fiber and
672 Putty Products in a Rat Posterolateral Fusion Model, *Frontiers in Surgery* (2020) 7:10.
673 doi: 10.3389/fsurg.2020.00010.

674 [15] S.D. Ferreira, W.S. Dernell, B.E. Powers, R.A. Schochet, C.A. Kuntz, S.J. Withrow,
675 R.M. Wilkins, Effect of gas-plasma sterilization on the osteoinductive capacity of
676 demineralized bone matrix, *Clinical Orthopaedics and Related Research* 388 (2001)
677 233-9. doi: 10.1097/00003086-200107000-00032.

678 [16] K.J. Lee, J.G. Roper, J.C. Wang, Demineralized bone matrix and spinal arthrodesis,
679 *The Spine Journal: official journal of the North American Spine Society* 5 (2005)
680 217S-223S. doi: 10.1016/j.spinee.2005.02.006.

681 [17] S.T. Moore, J.M. Katz, R.M. Zhukauskas, R.M. Hernandez, C.S. Lewis, P.R.
682 Supronowicz, E. Gill, S.M. Grover, N.S. Long, R.R. Cobb, Osteoconductivity and
683 osteoinductivity of Puros (R) DBM putty, *Journal of Biomaterials Applications* 26
684 (2011) 151-71. doi: 10.1177/0885328210366061.

- 685 [18] J.W. Turonis, J.C. 3rd. McPherson, M.F. Cuenin, S.D. Hokett, M.E. Peacock, M.
686 Sharawy, The effect of residual calcium in decalcified freeze-dried bone allograft in a
687 critical-sized defect in the *Rattus norvegicus* calvarium, *The Journal of oral*
688 *implantology* 32 (2006) 55-62. doi: 10.1563/780.1.
- 689 [19] S. Liu, Y. Wang, J. Wang, P. Qiu, S. Wang, Y. Shi, M. Li, P. Chen, X. Lin, X. Fang, A
690 cancellous bone matrix system with specific mineralisation degrees for mesenchymal
691 stem cell differentiation and bone regeneration, *Biomaterials Science* 6 (2019) 2452-
692 2467. doi: 10.1039/c8bm01657g.
- 693 [20] P.P. Spicer, J.D. Kretlow, S. Young, J.A. Jansen, F.K. Kasper, A.G. Mikos, Evaluation
694 of bone regeneration using the rat critical size calvarial defect, *Nature Protocols* 7
695 (2012) 1918-29. doi: 10.1038/nprot.2012.113.
- 696 [21] A. Vajgel, N. Mardas, B.C. Farias, A. Petrie, R. Cimões, N. Donos, A systematic
697 review on the critical size defect model, *Clinical Oral Implants Research* 25 (2014)
698 879-93. doi: 10.1111/clr.12194.
- 699 [22] P.S. Gomes, M.H. Fernandes, Rodent models in bone-related research: the relevance of
700 calvarial defects in the assessment of bone regeneration strategies, *Laboratory Animals*
701 45 (2011) 14-24. doi: 10.1258/la.2010.010085.
- 702 [23] S. Giraudier, D. Hellio, M. Djabourov, V. Larreta-Garde, Influence of weak and
703 covalent bonds on formation and hydrolysis of gelatin networks, *Biomacromolecules*,
704 5 (2004) 1662-6. doi: 10.1021/bm049670d.
- 705 [24] M. Bensidhoum, A. Chapel, S. Francois, C. Demarquay, C. Mazurier, L. Fouillard, S.
706 Bouchet, J.M. Bertho, P. Gourmelon, J. Aigueperse, P. Charbord, N.C. Gorin, D.
707 Thierry, M. Lopez, Homing of in vitro expanded Stro-1- or Stro-1+ human
708 mesenchymal stem cells into the NOD/SCID mouse and their role in supporting human
709 CD34 cell engraftment, *Blood* 103 (2004) 3313-9. doi: 10.1182/blood-2003-04-1121.

- 710 [25] K. Vandamme, X. Holy, M. Bensidhoum, M. Deschepper, D. Logeart-Avramoglou, I.
711 Naert, J. Duyck, H. Petite, Impaired osteoblastogenesis potential of progenitor cells in
712 skeletal unloading is associated with alterations in angiogenic and energy metabolism
713 profile, *Bio-medical Materials and Engineering* 22 (2012) 219-26. doi: 10.3233/BME-
714 2012-0711.
- 715 [26] P.M. Crapo, T.W. Gilbert, S.F. Badylak, An overview of tissue and whole organ
716 decellularization processes, *Biomaterials* 32 (2011) 3233-43. doi:
717 10.1016/j.biomaterials.2011.01.057.
- 718 [27] B.W. Stancoven, J. Lee, D.R. Dixon, J.C. 3rd. McPherson, F.C. Bisch, U.M. Wikesjö,
719 C. Susin, Effect of bone morphogenetic protein-2, demineralized bone matrix and
720 systemic parathyroid hormone (1-34) on local bone formation in a rat calvaria critical-
721 size defect model, *Journal of Periodontal Research* 48 (2013) 243-51. doi:
722 10.1111/jre.12001.
- 723 [28] H.P. Kim, Y.H. Ji, S.C. Rhee, E.S. Dhong, S.H. Park, E.S. Yoon, Enhancement of
724 bone regeneration using osteogenic-induced adipose-derived stem cells combined with
725 demineralized bone matrix in a rat critically-sized calvarial defect model, *Current Stem*
726 *Cell Research & Therapy* 7 (2012) 165-72. doi: 10.2174/157488812799859847.
- 727 [29] G. Intini, S. Andreana, R.J. Buhite, L.A. Bobek, A comparative analysis of bone
728 formation induced by human demineralized freeze-dried bone and enamel matrix
729 derivative in rat calvaria critical-size bone defects, *Journal of Periodontology* 79
730 (2008) 1217-24. doi: 10.1902/jop.2008.070435.
- 731 [30] J.A. Shehadi, S.M. Elzein, Review of commercially available demineralized bone
732 matrix products for spinal fusions: A selection paradigm, *Surgical Neurology*
733 *International* 8 (2017) 203. doi: 10.4103/sni.sni_155_17.

- 734 [31] M.P. Bostrom, X. Yang, M. Kennan, H. Sandhu, E. Dicarolo, J.M. Lane, An unexpected
735 outcome during testing of commercially available demineralized bone graft materials:
736 how safe are the nonallograft components? *Spine (Phila Pa 1976)* 26 (2001) 1425-8.
737 doi: 10.1097/00007632-200107010-00007.
- 738 [32] D.C. Markel, S.T. Guthrie, B. Wu, Z. Song, P.H. Wooley, Characterization of the
739 inflammatory response to four commercial bone graft substitutes using a murine
740 biocompatibility model, *Journal of Inflammation Research* 5 (2012) 13-8. doi:
741 10.2147/JIR.S21411.
- 742 [33] M. Santoro, A.M. Tataru, A.G. Mikos, Gelatin carriers for drug and cell delivery in
743 tissue engineering, *Journal of Controlled Release* 190 (2014) 210-8. doi:
744 10.1016/j.jconrel.2014.04.014.
- 745 [34] T. Al Kayal, D. Panetta, B. Canciani, P. Losi, M. Tripodi, S. Burchielli, P. Ottoni, P.A.
746 Salvadori, G. Soldani, Evaluation of the effect of a gamma irradiated DBM-pluronic
747 F127 composite on bone regeneration in Wistar rat, *PLOS One* 10 (2015) e0125110.
748 doi: 10.1371/journal.pone.0125110.
- 749 [35] L. Wang, Z.Y. Li, Y.P. Wang, Z.H. Wu, B. Yu, Dynamic Expression Profiles of
750 Marker Genes in Osteogenic Differentiation of Human Bone Marrow-derived
751 Mesenchymal Stem Cells, *Chinese Medical Sciences Journal* 30 (2015) 108-13. doi:
752 10.1016/s1001-9294(15)30021-3.
- 753 [36] J. Freitas, S.G. Santos, R.M. Gonçalves, J.H. Teixeira, M.A. Barbosa, M.I. Almeida,
754 Genetically Engineered-MSC Therapies for Non-unions, Delayed Unions and Critical-
755 size Bone Defects, *International Journal of Molecular Sciences* 20 (2019) 3430. doi:
756 10.3390/ijms20143430.

- 757 [37] T. Inokuchi, H. Ninomiya, R. Hironaka, S. Yoshida, M. Araki, K. Sano, Studies on
758 heat treatment for immediate reimplantation of resected bone, *Journal of Cranio-*
759 *Maxillo-Facial Surgery* 19 (1991) 31–39. doi: 10.1016/s1010-5182(05)80269-0.
- 760 [38] S. Menon, K. Banu, R. Veena, V. Srihari, M.E. Sham, M. Vinay, The Recycling of
761 Autoclaved Autografts in Mandibular Reconstruction: Case Report and Review of
762 Literature, *Journal of Maxillofacial and Oral Surgery* 14 (2015) 308-312. doi:
763 10.1007/s12663-013-0508-5.
- 764 [39] K.K. Hallfeldt, H. Stütze, M. Puhmann, S. Kessler, L. Schweiberer, Sterilization of
765 partially demineralized bone matrix: the effects of different sterilization techniques on
766 osteogenetic properties, *The Journal of Surgical Research* 5 (1995) 614-620. doi:
767 10.1006/jsre.1995.1213.
- 768 [40] G.F. Draenert, M. Delius, The mechanically stable steam sterilization of bone grafts,
769 *Biomaterials* 8 (2007) 1531-8. doi:10.1016/j.biomaterials.2006.11.029.
- 770 [41] M.J. Sawkins, W. Bowen, P. Dhadda, H. Markides, L.E. Sidney, A.J. Taylor, F.R.
771 Rose, S.F. Badylak, K.M. Shakesheff, L.J. White, Hydrogels derived from
772 demineralized and decellularized bone extracellular matrix, *Acta Biomaterialia* 8
773 (2013) 7865–7873. doi: 10.1016/j.actbio.2013.04.029
- 774 [42] Y. Su, M. Li, X. Wang, Z. Wang, L. Yi, Denatured Collagen Could Increase the
775 Autophagy Level and Inhibit Apoptosis of Fibroblasts to Help Cell Survival and
776 Influence Wound Healing, *the International Journal of Lower Extremity Wounds* 10
777 (2020). doi: 10.1177/1534734620925942.
- 778 [43] D. Medhat, C.I. Rodríguez, A. Infante, Immunomodulatory Effects of MSCs in Bone
779 Healing, *International Journal of Molecular Sciences* 20 (2019) 5467. doi:
780 10.3390/ijms20215467.

- 781 [44] A. Dorronsoro, I. Ferrin, J.M. Salcedo, E. Jakobsson, J. Fernández-Rueda, V. Lang, P.
782 Sepulveda, K. Fechter, D. Pennington, C. Trigueros, Human mesenchymal stromal
783 cells modulate T-cell responses through TNF- α -mediated activation of NF- κ B,
784 European Journal of Immunology 44 (2014) 480-8. doi: 10.1002/eji.201343668.
- 785 [45] L.C. Gerstenfeld, T.J. Cho, T. Kon, T. Aizawa, J. Cruceta, B.D. Graves, T.A. Einhorn,
786 Impaired intramembranous bone formation during bone repair in the absence of tumor
787 necrosis factor-alpha signaling, Cells Tissues Organs 169 (2001) 285-94. doi:
788 10.1159/000047893.
- 789 [46] S. Ivanovski, S. Hamlet, M. Retzepi, I. Wall, N. Donos, Transcriptional profiling of
790 "guided bone regeneration" in a critical-size calvarial defect, Clinical Oral Implants
791 Research 22 (2011) 382-389. doi: 10.1111/j.1600-0501.2010.02104.x.
- 792 [47] W. Zhang, C. Zhu, Y. Wu, D. Ye, S. Wang, D. Zou, X. Zhang, D.L. Kaplan, X. Jiang,
793 VEGF and BMP-2 promote bone regeneration by facilitating bone marrow stem cell
794 homing and differentiation, European Cells & Materials 27 (2014) 1-11, discussion
795 11-2. doi: 10.22203/ecm.v027a01.
- 796 [48] Y.B. Shaik-Dasthagirisahab, G. Varvara, G. Murmura, A. Saggini, G. Potalivo, A.
797 Caraffa, P. Antinolfi, S. Tete, D. Tripodi, F. Conti, E. Cianchetti, E. Toniato, M.
798 Rosati, P. Conti, L. Speranza, A. Pantalone, R. Saggini, T.C. Theoharides, F. Pandolfi,
799 Vascular endothelial growth factor (VEGF), mast cells and inflammation, International
800 Journal of Immunopathology and Pharmacology 26 (2013) 327-35. doi:
801 10.1177/039463201302600206.
- 802 [49] E. Dohle, I. Bischoff, T. Böse, A. Marsano, A. Banfi, R.E. Unger, C.J. Kirkpatrick,
803 Macrophage-mediated angiogenic activation of outgrowth endothelial cells in co
804 culture with primary osteoblasts, European Cells & Materials 27 (2014) 149-64,
805 discussion 164-5. doi: 10.22203/ecm.v027a12.

806 [50] K. Hu, B.R. Olsen, The roles of vascular endothelial growth factor in bone repair and
807 regeneration, *Bone* 91 (2016) 30-8. doi: 10.1016/j.bone.2016.06.013.
808

809 **TABLE**

810 **Table 1:** Specific optical rotation value of collagenic fraction extracted from PDBM compared
811 to previous values obtained from collagen coil and collagen helix

812

	Collagen coil at 40°C (2mg/mL)	Collagen Helix at 27°C (2mg/mL)	PDBM at 27°C (1.5mg/mL of collagen- like)
Specific optical rotation Deg.cm³.g⁻¹.dm⁻¹	-274° +/- 1°	-800° +/- 4°	-340° +/- 2°

813

814

815

816 **FIGURE LEGENDS**

817 **Figure 1: Material characterization**

818 Representative light micrographs of the morphology of the PDBM (A) and the BP (D).
819 Representative environmental scanning electron microscopy (eSEM) of the morphology of the
820 PDBM (B-C) and the BP (E-F). Amount of residual DNA (G) in HFH, BP, and PDBM;
821 significant differences are indicated by* ($p < 0.05$) (compared to HFH) and # ($p < 0.05$)
822 (compared to PDBM). Fourier transform infrared spectrometry (FTIR) (H): absorption spectra
823 of the mineral and the organic phases of BP and PDBM used in the present study. (I)
824 Quantified “collagenic phase” extractible from BP, PDBP, and PDBM.

825
826 **Figure 2. Micro-CT images of the bone healing process within 8-mm-diameter rat**
827 **calvarium defects during the 8 weeks post-surgery.** The calvarium defects tested were
828 either left empty or filled with BP or PDBM paste and were scanned using micro-CT
829 immediately (D0) and 15, 30, 45, and 60 days post-surgery. (A) Representative 2D images
830 illustrating a significant increase (evidenced as radiopacity) in the PDBM paste-filled defects
831 (A3) compared to the BP-filled defects (A2) and the defects left empty (A1). (B) Significant
832 ($p < 0.01$) greater radiopacity volume was present in the PDBM-filled defects compared to the
833 respective results obtained from the BP-filled defects and the defects left empty. Numerical
834 data are shown as means \pm SD of 6 samples per animal group. Significant differences are
835 indicated by * $p < 0.05$, and ** $p < 0.01$.

836
837 **Figure 3. Micro-CT follow-up of bone healing within the 4-mm- and 6-mm-diameter rat**
838 **calvarium defects during the 8 weeks post-surgery.** The calvarium defects were either left
839 empty or filled with BP or PDBM paste and were scanned immediately (D0) and 15, 30, 45,
840 and 60 days post-surgery. (A) Representative 2D images illustrating new bone formation in

841 both the 6-mm- and 4-mm-diameter defects left empty (A1) or filled with BP (A2) or PDBM
842 paste (A3). (B) Radiopacity volume (evidenced as radiopacity) was significantly ($p < 0.01$)
843 greater in the 6-mm PDBM paste-filled defects compared to pertinent results obtained from
844 the BP-filled defects and the defects left empty. (C) Radiopacity volume was similar in the 4-
845 mm-diameter defects that were left empty or filled with the BP and the PDBM paste.
846 Numerical data are shown as means \pm SD of 6 samples per animal group. Significant
847 differences are indicated by * $p < 0.05$, and ** $p < 0.01$.

848
849 **Figure 4. Histology and histomorphometric analyses of new bone formation in the 8-mm-**
850 **diameter rat calvarium defects at the 8th week post-surgery.** (A) and (B) New bone
851 formation (*) in the defects left empty and the BP-filled defects was located at the periphery of
852 the defect. (C) In the PDBM- filled defects, it was present between and around the PDBM
853 particles (p) and in the center of the defect. (D) Magnified light micrograph of the framed
854 section in Figure 4C illustrates new bone formation (*) in contact with PDBM particles (p),
855 osteoblasts (white arrow), and osteocyte lacunas (blue arrow). (E) The area of the new bone
856 formation in the defects filled with the PDBM paste was significantly higher ($p < 0.001$) than
857 those obtained from the BP-filled defects and the defects left empty. **Stains:** Stevenel's blue
858 and Van Gieson picro fuschin were used for the visualization of cell nuclei and bone tissue,
859 respectively. Significant difference ($p < 0.01$) is indicated by **.

860
861 **Figure 5. Histology and histomorphometric analyses of new bone formation in 6-mm-**
862 **diameter rat calvarium defects at the 8th week post-surgery.** (A) and (B) New bone
863 formation (*) in the 6-mm-diameter defects left empty or filled with the BP was located at the
864 edge and inside the defects. (C) Bone formation (*) in the defects filled with the PDBM paste
865 was present between and around the PDBM paste particles (p) and in the center of the defects.

866 (D) Magnified light micrograph of the framed section in Figure 5C illustrates histology details
867 such as woven bone in contact with the residual PDBM particles. Osteocyte-like and some
868 lining cells, as well as blood vessels were observed in the bone marrow spaces. * = newly-
869 formed bone; P = PDBM paste; MO = bone marrow; Dotted line = edge of the defect; Arrow
870 points to an osteocyte lacuna; Ob = osteoblast.(E) Quantitative analysis showed significantly a
871 wider area of new bone formation in the defects filled with PDBM compared to those that had
872 been left empty or filled with the BP. Significant difference ($p < 0.05$) is indicated by *.

873
874 **Figure 6. Histology and histomorphometric analyses of new bone formation in 4-mm-**
875 **diameter rat calvarium defects at the 8th week post-surgery.** An important new bone
876 formation (*) was observed in the 4-mm-diameter defects which had been left empty (A) or
877 filled with BP (B). In the defects filled with PDBM paste (C), bone formation (*) was
878 observed between and around the PDBM particles (p) and in the center of the defect. (D) The
879 new bone formation was similar in the empty defects and in the BP- or PDBM paste-filled
880 defects.

881
882 **Figure 7. Time course of selected inflammation- and angiogenesis-related genes'**
883 **expression levels in the 8-mm-diameter bone defects on days 3, 7, and 14 post-surgery.**
884 The defects had been left empty (white columns) or filled with PDBM (black columns). The
885 basis of comparison for the observed significant differences ($p < 0.05$) are the following lower
886 case letters: a = significant difference from pertinent results obtained for empty defect group; b
887 = significant difference compared to the results obtained from PDBM group; c = significant
888 difference compared to the results obtained for the same gene in the same group on D3; d =
889 significant difference compared to the results obtained for the same gene in the same group on
890 D14. $TNF\alpha$ = Tumor necrosis factor; $IL-1\beta$ = Interleukin 1 β ; IL-6 = Interleukin 6; IL-8 =

891 Interleukin 8; VEGF = Vascular endothelial growth factor; ANG = Angiogenin; CDH5 =
892 Cadherin 5; PECAM1 = Platelet endothelial cell adhesion molecule; VWF= Von Willebrand
893 factor.

894 **Figure 8: Time course of expression of selected genes related to bone formation and**
895 **remodeling in the 8-mm-diameter bone defects on days 3, 7, and 14 post-surgery.** The
896 defects had been either left empty (white columns) or filled with PDBM (black columns).
897 Statistically significant differences ($p < 0.05$) are indicated by the following lower case letters:
898 a = significant difference from pertinent results obtained for empty defect group; b =
899 significant difference compared to the results obtained from PDBM group; c = significant
900 difference compared to the results obtained for the same gene in the same group on D3; d =
901 significant difference compared to the results obtained for the same gene in the same group on
902 D14. ALP = Alkaline phosphatase; RUNX2 = Runt-related transcription factor 2; COL1A1 =
903 alpha-1 type I Collagen; BGLAP (Osteocalcin) = Bone gamma-carboxyglutamate protein; SP7
904 = Transcription factor Sp7 or Osterix (Osx); MMP13 = Matrix metalloproteinase 13; OPG =
905 Osteoprotegerin; RANKL = Receptor activator of nuclear factor kappa-B ligand; SPARC
906 (Osteonectin) = Secreted protein acidic and rich in cysteine.

907

Table 1: specific optical rotation value of collagenic fraction extracted from PDBM compared to previously values observed from collagen coil and collagen helix

	Collagen coil at 40°C (2mg/ml)	Collagen Helix at 27°C (2mg/ml)	PDBM at 27°C (1,5mg/ml of collagen-like)
Specific optical rotation Deg.cm³.g⁻¹.dm⁻¹	-274° +/- 1°	-800° +/- 4°	-340° +/- 2°

Figure 1. Material characterization

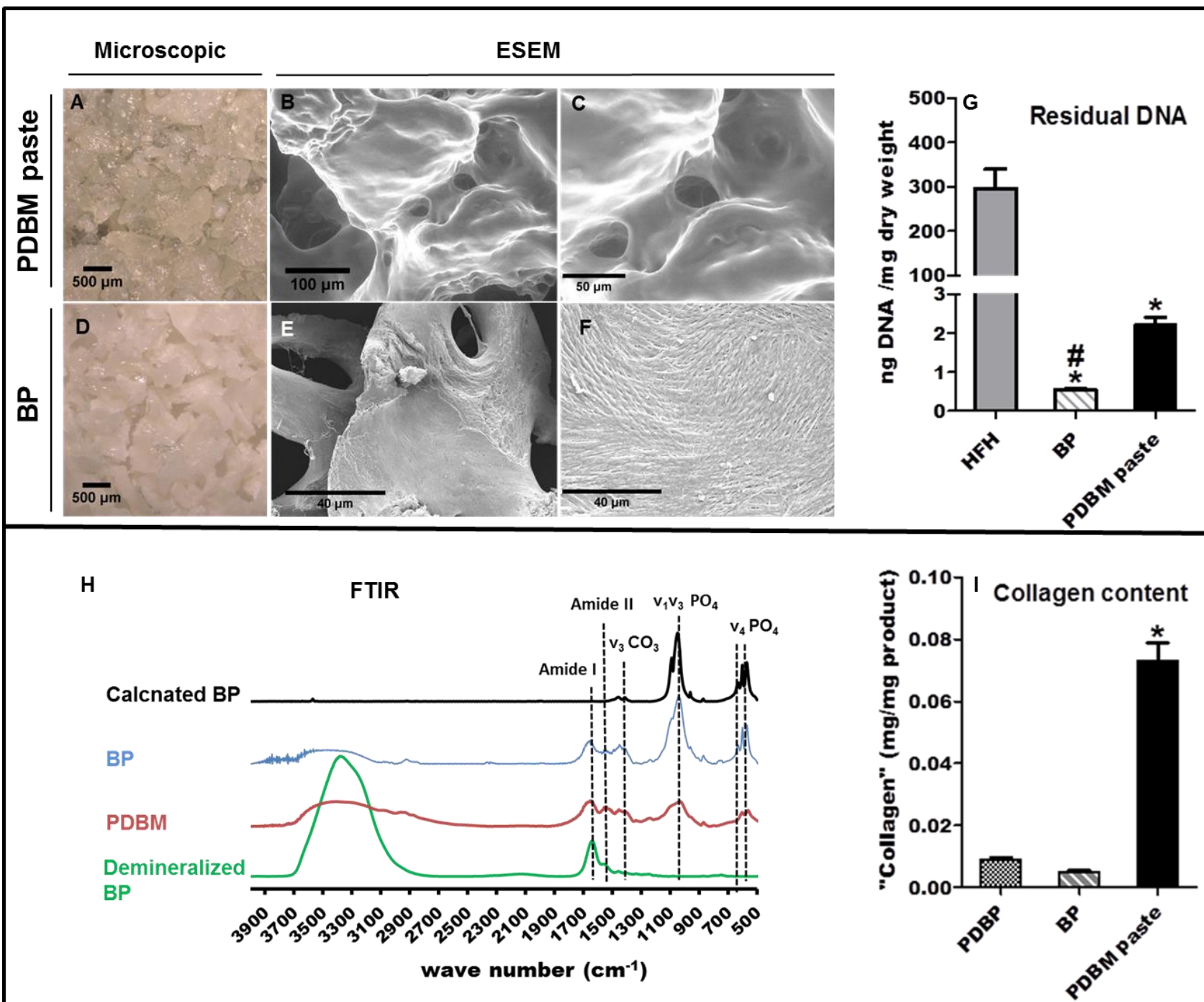


Figure 2. Micro-CT images of the bone repair process within 8-mm-diameter rat calvarium defects during 8 weeks post-surgery.

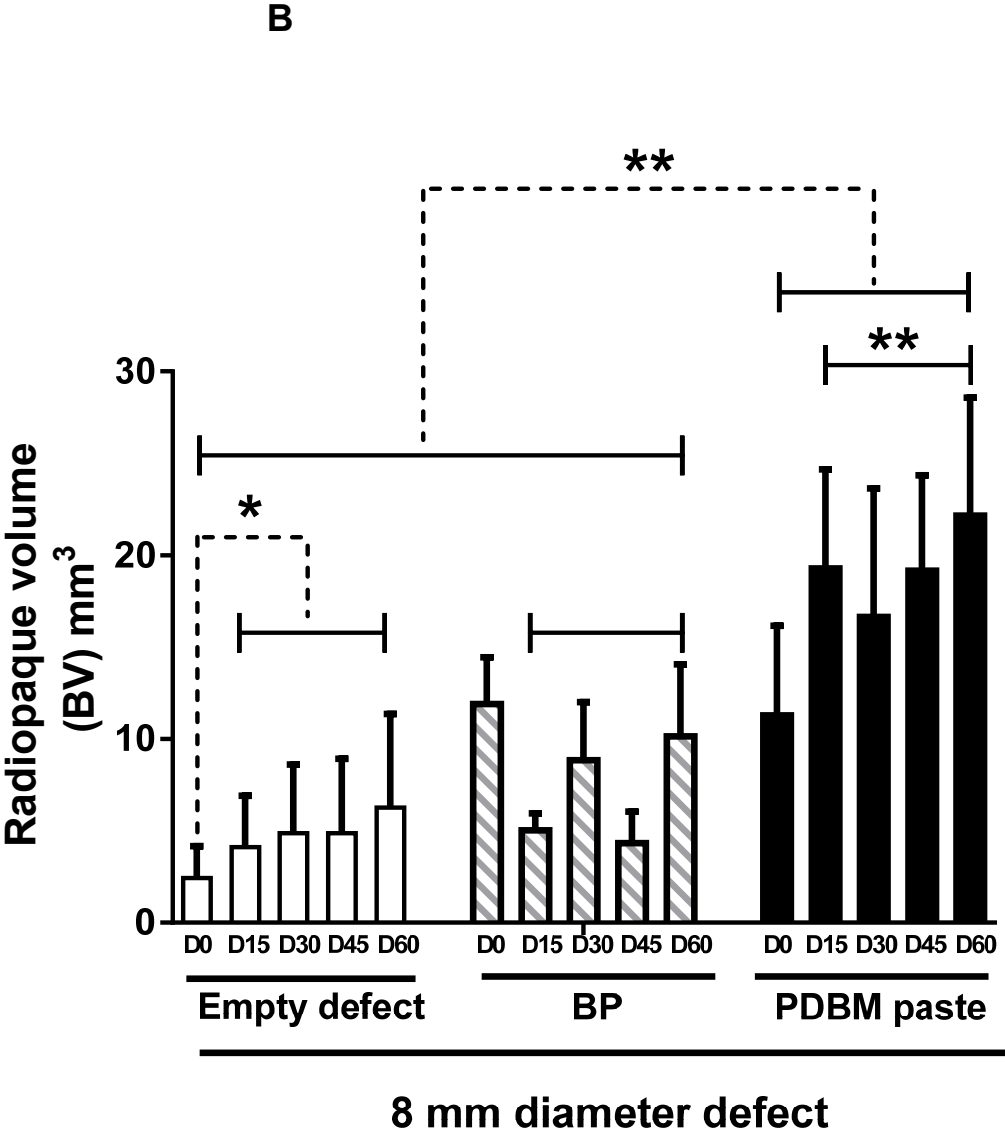
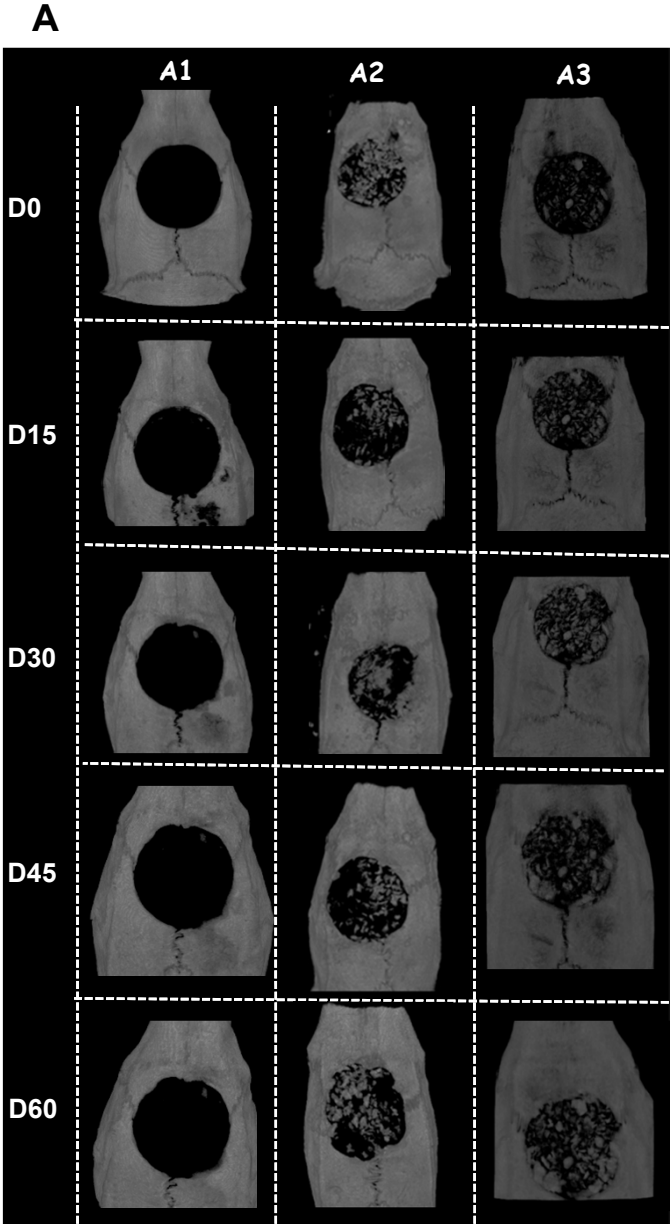


Figure 3. Micro-CT follow-up of bone repair within the 4-mm- and 6-mm-diameter rat calvarium defects during 8 weeks post surgery.

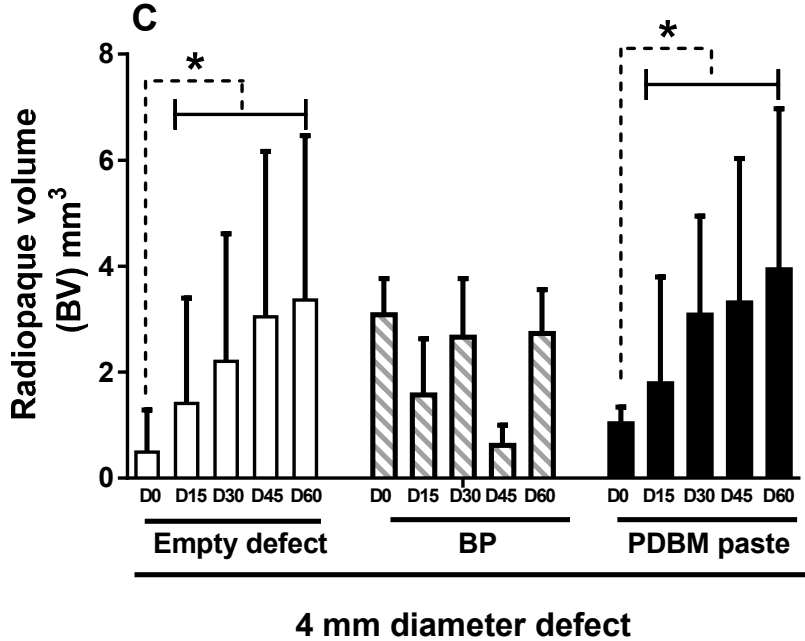
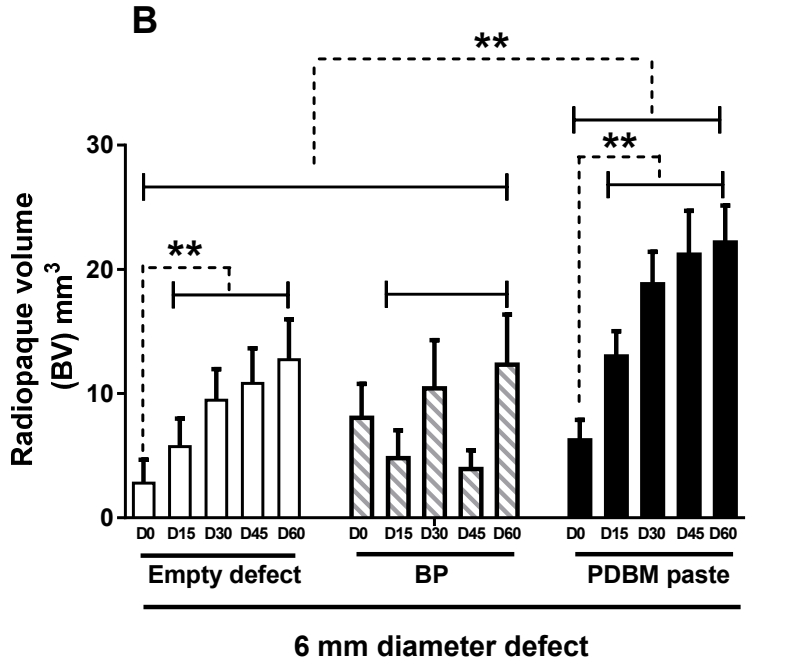
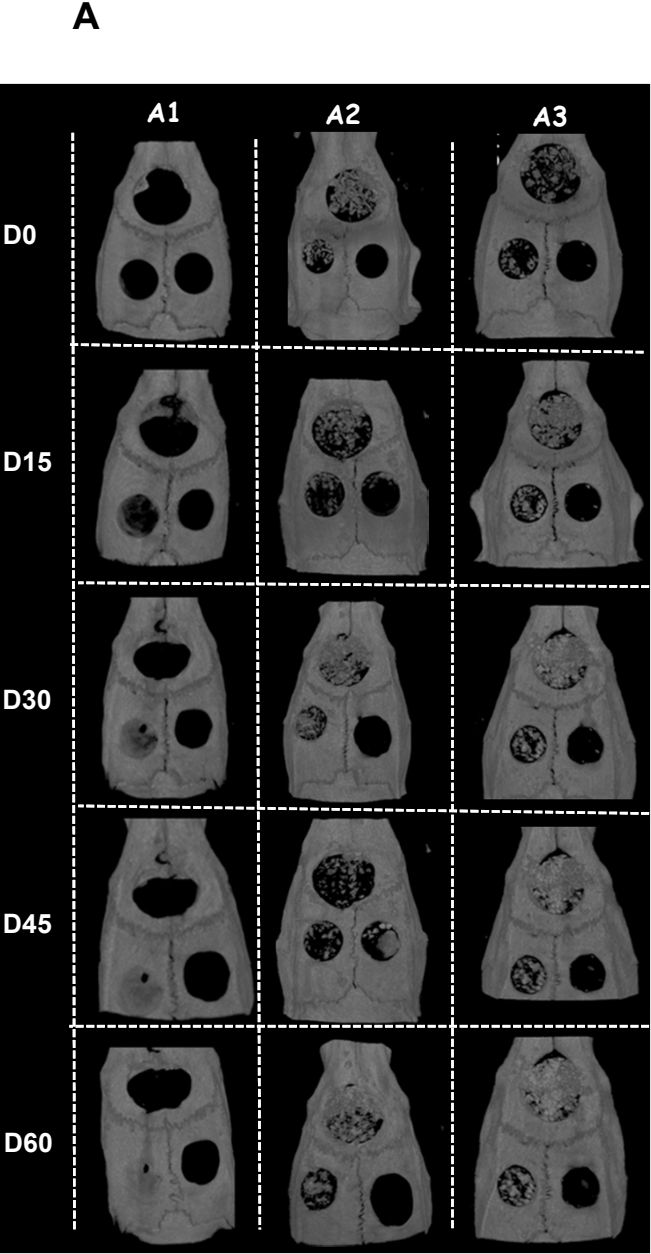


Figure 4. Histology and histomorphometrical analysis of new-bone formation in the 8-mm-diameter rat calvarium defects at the 8th weeks post-surgery.

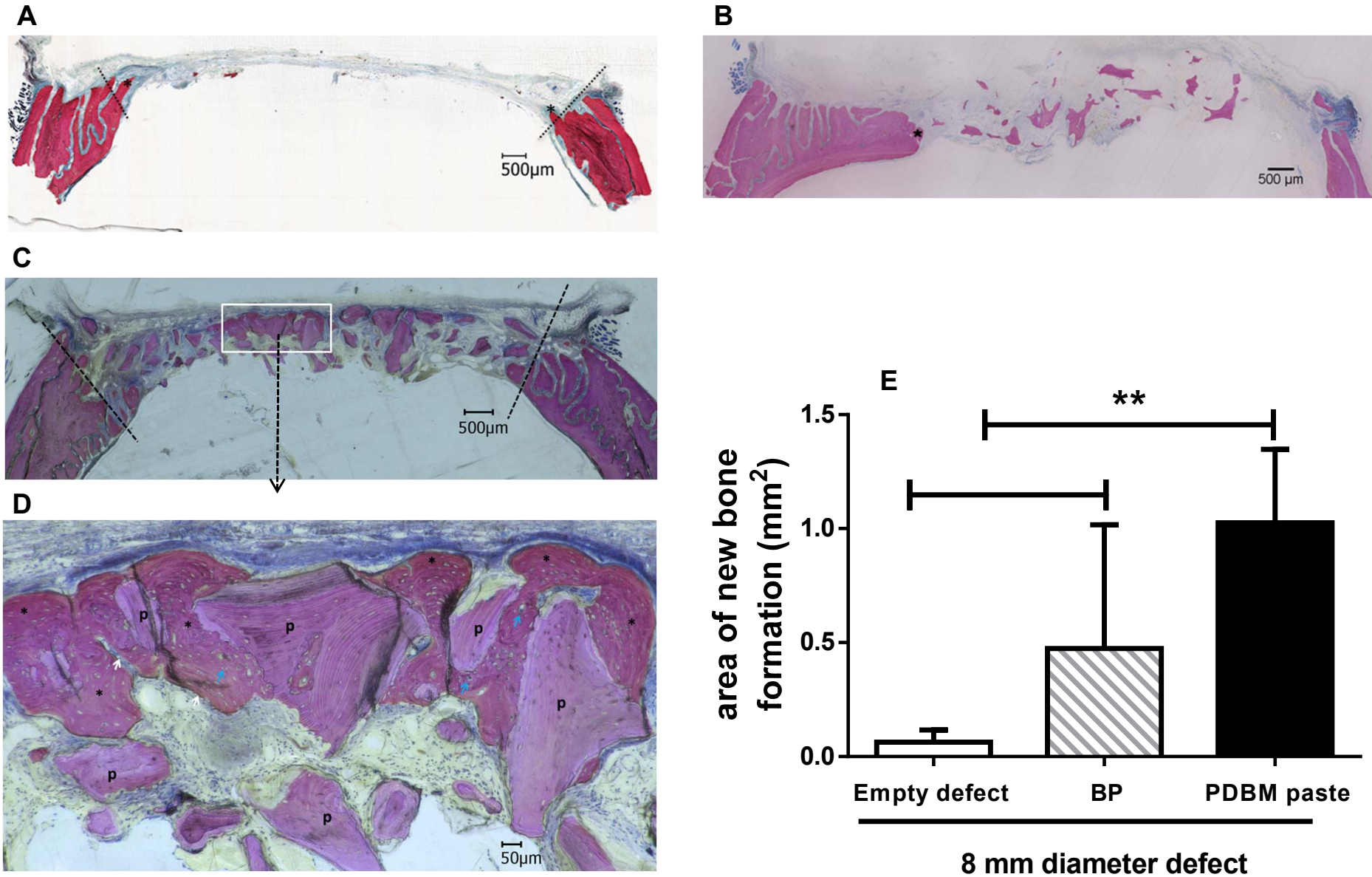


Figure 5. Histology and histomorphometrical analyses of new-bone formation in 6-mm-diameter rat calvarium defects at the 8th week post-surgery.

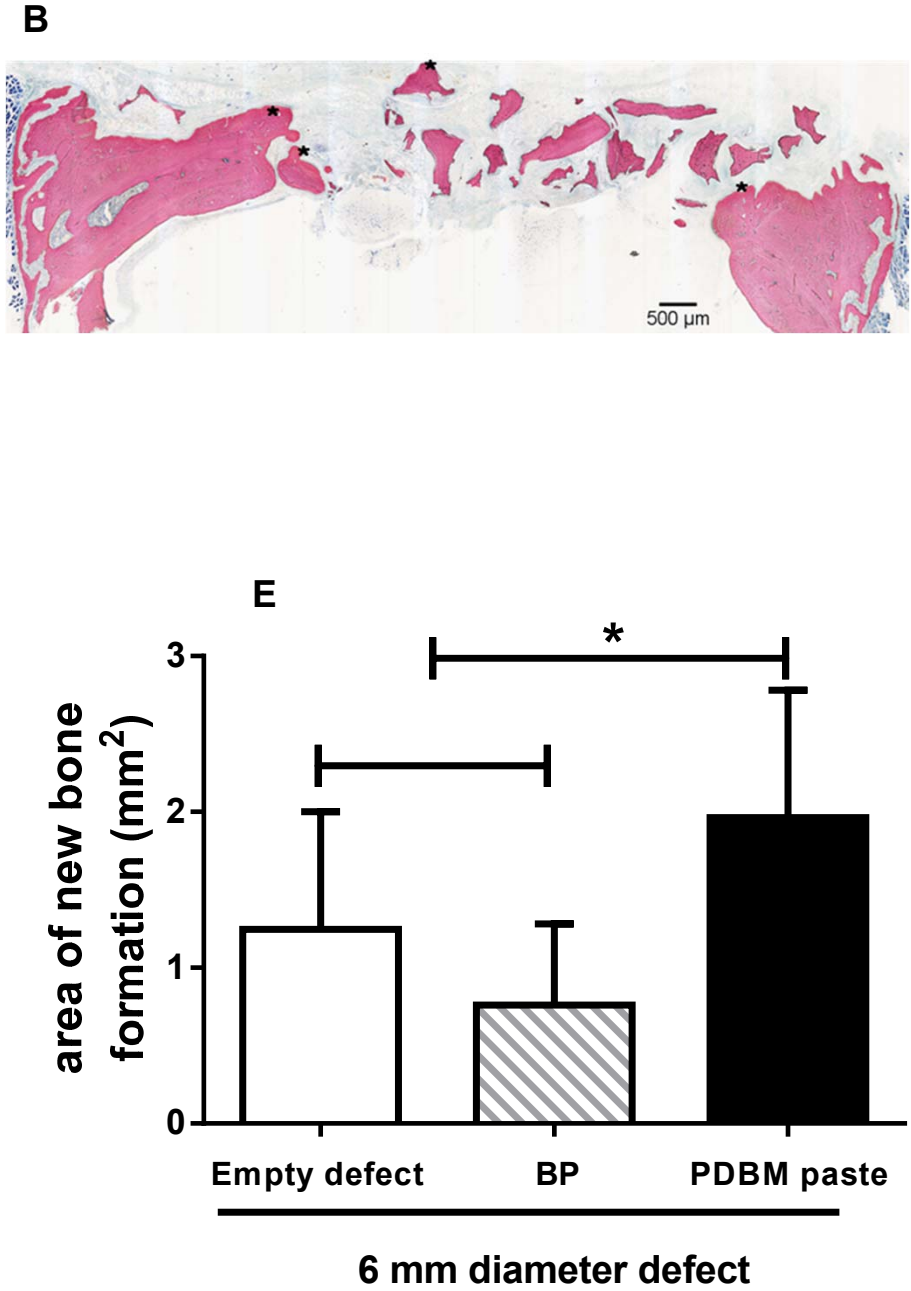
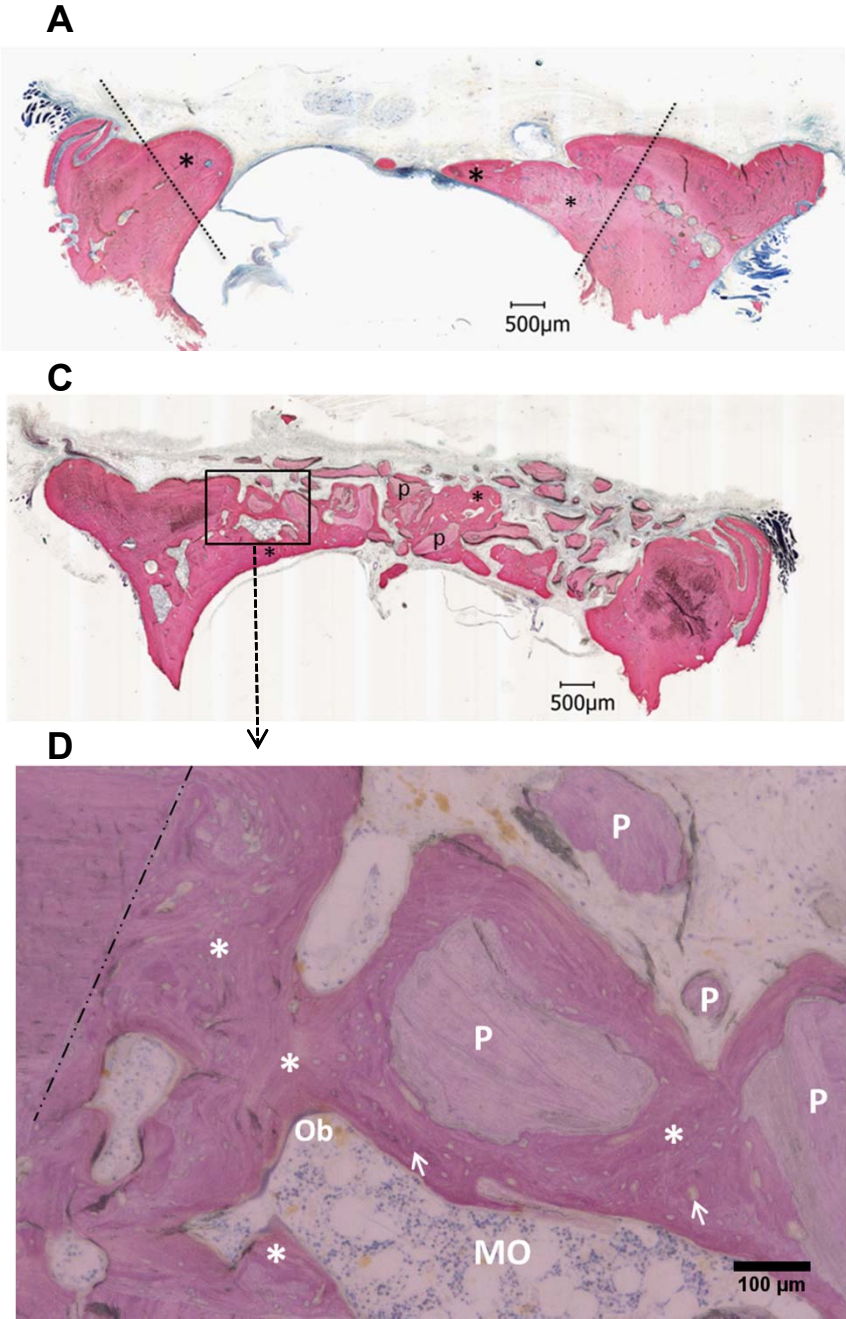


Figure 6. Histology and histomorphometrical analyses of new bone formation in 4-mm-diameter rat calvarium defects at the 8th week post-surgery.

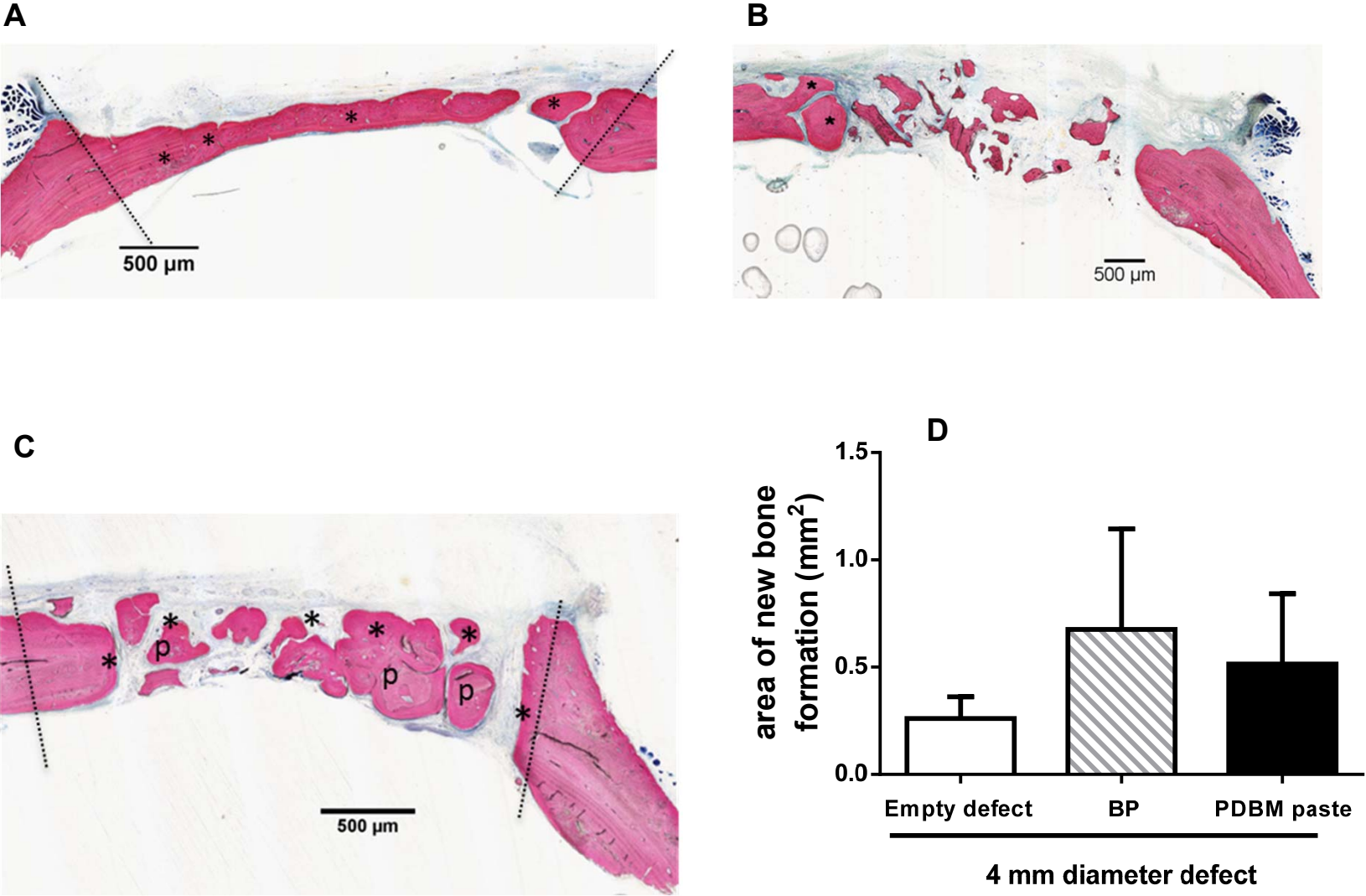


Figure 7: Gene expression analysis of pro-inflammatory and angiogenesis markers in the 8-mm diameter bone defects after 3, 7 and 14 days of healing.

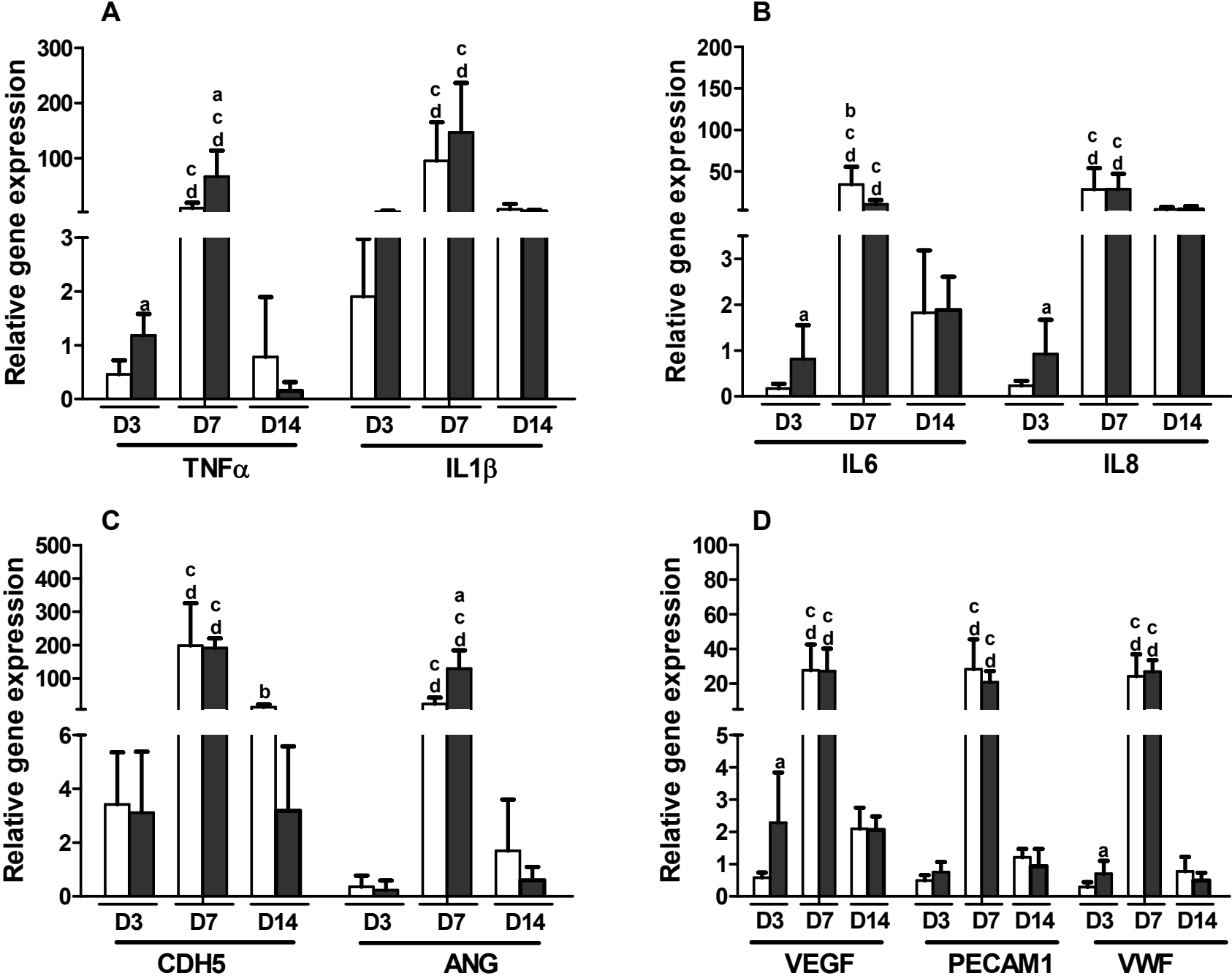


Figure 8: Gene expression analysis of bone formation and bone resorption markers, in the 8-mm diameter bone defects after 3, 7 and 14 days of healing.

