



**HAL**  
open science

## Therapeutic implications of improved molecular diagnostics for rare CNS-embryonal tumor entities: results of an international, retrospective study

Katja von Hoff, Christine Haberler, Felix Schmitt-Hoffner, Elizabeth Schepke, Teresa de Rojas, Sandra Jacobs, Michal Zapotocky, David Sumerauer, Marta Perek-Polnik, Christelle Dufour, et al.

### ► To cite this version:

Katja von Hoff, Christine Haberler, Felix Schmitt-Hoffner, Elizabeth Schepke, Teresa de Rojas, et al.. Therapeutic implications of improved molecular diagnostics for rare CNS-embryonal tumor entities: results of an international, retrospective study. *Neuro-Oncology*, 2021, 23 (9), pp.1597-1611. 10.1093/neuonc/noab136 . hal-03253034

**HAL Id: hal-03253034**

**<https://hal.science/hal-03253034v1>**

Submitted on 3 Jul 2024

**HAL** is a multi-disciplinary open access archive for the deposit and dissemination of scientific research documents, whether they are published or not. The documents may come from teaching and research institutions in France or abroad, or from public or private research centers.

L'archive ouverte pluridisciplinaire **HAL**, est destinée au dépôt et à la diffusion de documents scientifiques de niveau recherche, publiés ou non, émanant des établissements d'enseignement et de recherche français ou étrangers, des laboratoires publics ou privés.

## Therapeutic implications of improved molecular diagnostics for rare CNS-embryonal tumor entities: results of an international, retrospective study

Katja von Hoff<sup>1</sup>, Christine Haberler<sup>2</sup>, Felix Schmitt-Hoffner<sup>3-5</sup>, Elizabeth Schepke<sup>6</sup>, Teresa de Rojas<sup>7</sup>, Sandra Jacobs<sup>8</sup>, Michal Zapotocky<sup>9</sup>, David Sumerauer<sup>9</sup>, Marta Perek-Polnik<sup>10</sup>, Christelle Dufour<sup>11,12</sup>, Dannis van Vuurden<sup>13</sup>, Irene Slavic<sup>14</sup>, Johannes Gojo<sup>14</sup>, Jessica C. Pickles<sup>15,16</sup>, Nicolas U. Gerber<sup>17</sup>, Maura Massimino<sup>18</sup>, Maria Joao Gil-da-Costa<sup>19</sup>, Miklos Garami<sup>20</sup>, Ella Kumirova<sup>21</sup>, Astrid Sehested<sup>22</sup>, David Scheie<sup>23</sup>, Ofelia Cruz<sup>24</sup>, Lucas Moreno<sup>25</sup>, Jaeho Cho<sup>26</sup>, Bernward Zeller<sup>27</sup>, Niels Bovenschen<sup>28</sup>, Michael Grotzer<sup>17</sup>, Daniel Alderete<sup>29</sup>, Matija Snuderl<sup>30</sup>, Olga Zheludkova<sup>31</sup>, Andrey Golanov<sup>32</sup>, Konstantin Okonechnikov<sup>3,4</sup>, Martin Mynarek<sup>33</sup>, B. Ole Juhnke<sup>33</sup>, Stefan Rutkowski<sup>33</sup>, Ulrich Schüller<sup>33,34,35</sup>, Barry Pizer<sup>36</sup>, Barbara v. Zezschwitz<sup>1</sup>, Robert Kwiecien<sup>37</sup>, Maximilian Wechsung<sup>38</sup>, Frank Konietschke<sup>38</sup>, Eugene I. Hwang<sup>39</sup>, Dominik Sturm<sup>3,40,41</sup>, Stefan M. Pfister<sup>3,4,41</sup>, Andreas von Deimling<sup>42,43</sup>, Elisabeth J. Rushing<sup>44</sup>, Marina Ryzhova<sup>45</sup>, Peter Hauser<sup>20</sup>, Maria Łastowska<sup>46</sup>, Pieter Wesseling<sup>13,47</sup>, Felice Giangaspero<sup>48,49</sup>, Cynthia Hawkins<sup>50</sup>, Dominique Figarella-Branger<sup>51</sup>, Charles Eberhart<sup>52</sup>, Peter Burger<sup>52</sup>, Marco Gessi<sup>53</sup>, Andrey Korshunov<sup>42,43</sup>, Tom S. Jacques<sup>16</sup>, David Capper<sup>54, 55</sup>, Torsten Pietsch<sup>56</sup>, Marcel Kool<sup>3,4,13</sup>

<sup>1</sup> Department of Pediatric Oncology and Hematology, Charité University Medicine, Berlin, Germany (KVH, BVZ)

<sup>2</sup> Division of Neuropathology and Neurochemistry, Department of Neurology, Medical University of Vienna, Austria (CH)

<sup>3</sup> Hopp Children's Cancer Center (KiTZ), Heidelberg, Germany (FSH, KO, DS, SMP, MK)

<sup>4</sup> Division of Pediatric Neurooncology, German Cancer Research Center (DKFZ) and German Cancer Consortium (DKTK), Heidelberg, Germany (FSH, KO, SMP, MK)

<sup>5</sup> Faculty of Biosciences, Heidelberg University, Heidelberg, Germany (FSH)

<sup>6</sup> The Queen Silvia Children's Hospital, Sahlgrenska University Hospital, Gothenburg, Sweden (ES)

<sup>7</sup> Pediatric OncoGenomics Unit, Children's University Hospital Niño Jesús, Madrid, Spain (TDR)

<sup>8</sup> Department of Pediatrics, KU Leuven and University Hospitals Leuven, Leuven, Belgium (SJ)

<sup>9</sup> Second Faculty of Medicine, Charles University and University Hospital Motol, Prague, Czech Republic (MZ, DS)

<sup>10</sup> Department of Oncology, The Children's Memorial Health Institute, University of Warsaw, Warsaw, Poland (MPP)

<sup>11</sup> Gustave Roussy Cancer Center, Department of Pediatric and Adolescent Oncology, Villejuif, France (CD)

- <sup>12</sup> Paris-Saclay University, INSERM, Molecular predictors and New targets in Oncology, Villejuif, France (CD)
- <sup>13</sup> Princess Máxima Center for Pediatric Oncology, Utrecht, the Netherlands (DVV, MK, PW)
- <sup>14</sup> Department of Pediatrics and Adolescent Medicine and Comprehensive Center for Pediatrics, Medical University of Vienna, Vienna, Austria (IS, JG)
- <sup>15</sup> Developmental Biology and Cancer Research & Teaching Department, UCL Great Ormond Street Institute of Child Health, London, UK (JCP)
- <sup>16</sup> Department of Histopathology, Great Ormond Street Hospital for Children NHS Foundation Trust, London, UK (JCP, TSJ)
- <sup>17</sup> Department of Oncology, University Children's Hospital, Zurich, Switzerland (NUG, MG)
- <sup>18</sup> Pediatric Unit, Fondazione IRCCS Istituto Nazionale die Tumori, Milan, Italy (MM)
- <sup>19</sup> Pediatric Oncology Department, University Hospital S.João, Porto, Portugal (MJGC)
- <sup>20</sup> 2nd Department of Pediatrics, Semmelweis University, Budapest, Hungary (MG, PH)
- <sup>21</sup> Department of Neuro-Oncology, Dmitry Rogachev National Medical Research Center for Pediatric Hematology, Oncology and Immunology, Moscow, Russia (EK)
- <sup>22</sup> Department of Pediatrics and Adolescent Medicine, Rigshospitalet, Copenhagen, Denmark (AS)
- <sup>23</sup> Department of Pathology, Rigshospitalet, Copenhagen University Hospital, Frederik Vs vej 11, 2100 Copenhagen, Denmark (DS)
- <sup>24</sup> Pediatric Oncology Department. Hospital Sant Joan de Deu. Barcelona, Spain (OC)
- <sup>25</sup> Paediatric Haematology & Oncology Division, Hospital Universitari Vall d'Hebron, Barcelona, Spain (LM)
- <sup>26</sup> Dept. of Radiation Oncology, Yonsei Cancer Center, Yonsei University College of Medicine, Seoul, South Korea (JC)
- <sup>27</sup> Division of Pediatric and Adolescent Medicine, Oslo University Hospital, Oslo, Norway (BZ)
- <sup>28</sup> Department of Pathology, University Medical Centre Utrecht, Utrecht, The Netherlands (NB)
- <sup>29</sup> Service of Hematology/Oncology, Hospital JP Garrahan, Buenos Aires, Argentina (DA)
- <sup>30</sup> Department of Pathology, NYU Langone Health and School of Medicine, New York, NY, USA (MS)
- <sup>31</sup> Department of Neurooncology, Russian Scientific Center of Radiology, Moscow, Russia (OZ)
- <sup>32</sup> Department of Neuroradiology, Burdenko Neurosurgical Institute, Moscow, Russia (AG)
- <sup>33</sup> Department of Pediatric Hematology and Oncology, University Medical Center Hamburg-Eppendorf, Hamburg (MM, BOJ, SR, US)
- <sup>34</sup> Institute of Neuropathology, University Medical Center Hamburg-Eppendorf, Hamburg, Germany (US)
- <sup>35</sup> Research Institute Children's Cancer Center Hamburg, Hamburg, Germany (US)
- <sup>36</sup> Institute of Translational Research, University of Liverpool, UK (BP)
- <sup>37</sup> Institute of Biostatistics and Clinical Research, University of Muenster, Muenster, Germany (RK)

- <sup>38</sup> Institute of Biometry and Clinical Epidemiology, Charité University Medicine and Berlin Institute of Health, Berlin, Germany (MW, FK)
- <sup>39</sup> Department of Pediatric Hematology-Oncology, Center for Cancer and Immunology Research and Neuroscience Research, Children's National Medical Center, Washington DC, USA (EIH)
- <sup>40</sup> Pediatric Glioma Research, German Cancer Research Center (DKFZ) and German Cancer Consortium (DKTK), Heidelberg, Germany (DS)
- <sup>41</sup> Department of Pediatric Oncology, Hematology & Immunology, Heidelberg University Hospital, Heidelberg, Germany (DS, SMP)
- <sup>42</sup> Department of Neuropathology, Heidelberg University Hospital, Heidelberg, Germany (AVD, AK)
- <sup>43</sup> Clinical Cooperation Unit Neuropathology, German Cancer Research Center (DKFZ), Heidelberg, Germany (AVD, AK)
- <sup>44</sup> Institute of Neuropathology, University Medical Center Zurich, Zurich, Switzerland (ER)
- <sup>45</sup> Department of Neuropathology, Burdenko Neurosurgical Institute, Moscow, Russia (MR)
- <sup>46</sup> Department of Pathomorphology, Children's Memorial Health Institute, Warsaw, Poland (ML)
- <sup>47</sup> Amsterdam University Medical Center / VUmc, Amsterdam, The Netherlands (PW)
- <sup>48</sup> Department of Radiological, Oncological and Anatomopathological Sciences, Sapienza University of Rome, Rome, Italy (FG)
- <sup>49</sup> IRCCS Neuromed, Pozzilli (IS), Italy (FG)
- <sup>50</sup> Division of Pathology, The Hospital for Sick Children, Toronto, Canada (CH)
- <sup>51</sup> Aix-Marseille Univ, APHM, CNRS, INP, Inst Neurophysiopathol, CHU Timone, Service d'Anatomie Pathologique et de Neuropathologie, Marseille, France (DFB)
- <sup>52</sup> Department of Pathology, Johns Hopkins University, Baltimore, MD, USA (CE, PB)
- <sup>53</sup> Neuropathology Unit, Division of Pathology, Fondazione Policlinico Universitario "A.Gemelli" IRCCS, Università Cattolica S.Cuore, Rome, Italy (MG)
- <sup>54</sup> Department of Neuropathology, Charité University Medicine, and Berlin Institute of Health, Berlin, Germany (DC)
- <sup>55</sup> German Cancer Consortium (DKTK), partner site Berlin, German Cancer Research Center (DKFZ), Heidelberg, Germany (DC)
- <sup>56</sup> Department of Neuropathology, DGNN Brain Tumor Reference Center, University of Bonn, DZNE German Center for Neurodegenerative Diseases, Bonn, Germany (TP)

**Corresponding author:** Katja von Hoff  
Charité Universitätsmedizin  
Augustenburger Platz 1  
13353 Berlin, Germany

Telephone: +49-30-450-566132

E-mail: [katja.von-hoff@charite.de](mailto:katja.von-hoff@charite.de)

**Funding:**

The work has been funded by the German Childhood Cancer Foundation (Deutsche Kinderkrebsstiftung) and KINDerLEBEN e.V. Berlin.

**Conflict of Interest:**

There is no conflict of interest declared by any of the authors.

Accepted Manuscript

**Authorship:**

Study concept: KvH, CH, BP, EIH, CD, SR, SMP, DC, TP, MK

Study coordination and manuscript writing: KvH, CH, TP, MK

Figures: KvH, FSH, MW, MK

DNA methylation profiling, classification and interpretation: MK, FSH, KO, AvD, DC

Neuropathology panel review: CH, FG, CH, DFB, CE, PB, MG, AK, TSJ, TP

Provision of samples, clinical data and clinical interpretation: ES, TdR, SJ, MZ, DS, MPP,

CD, DvV, IS, JG, JCP, NUG, MM, MJGC, MG, EK, AS, DS, OC, LM, JC, BZ, NB, MG,

DA, MS, OZ, AG, MM, BOJ, SR, US, PB, BvZ, EIH, EJR, MR, PH, ML, PW

Curation of data: KvH, MK

Statistical analyses: KvH, FK, MW, RK

All authors contributed and reviewed the final manuscript.

**Cited unpublished paper:**

BO Juhnke et. al. Treatment of Embryonal Tumours with Multi-layered Rosettes (ETMR) with carboplatin/etoposide Induction and High-dose Chemotherapy within the Prospective P-HIT/HIT2000 Trial; *Neuro-Oncology*; accepted for publication

## ABSTRACT

**BACKGROUND:** Only few data are available on treatment-associated behavior of distinct rare CNS-embryonal tumor entities previously treated as “CNS-primitive neuroectodermal tumors” (CNS-PNET). Respective data on specific entities, including CNS neuroblastoma, FOXR2 activated (CNS NB-FOXR2), and embryonal tumor with multi-layered rosettes (ETMR) are needed for development of differentiated treatment strategies.

**METHODS:** Within this retrospective, international study, tumor samples of clinically well-annotated patients with the original diagnosis of CNS-PNET were analyzed using DNA methylation arrays (n=307). Additional cases (n=66) with DNA methylation pattern of CNS NB-FOXR2 were included irrespective of initial histological diagnosis. Pooled clinical data (n=292) were descriptively analyzed.

**RESULTS:** DNA methylation profiling of “CNS-PNET” classified 58(19%) cases as ETMR, 57(19%) as HGG, 36(12%) as CNS NB-FOXR2, and 89(29%) cases were classified into 18 other entities. Sixty-seven (22%) cases did not show DNA methylation patterns similar to established CNS tumor reference classes. Best treatment results were achieved for CNS NB-FOXR2 patients (5-year PFS: 63%±7%, OS: 85%±5%, n=63), with 35/42 progression-free survivors after upfront craniospinal irradiation (CSI) and chemotherapy. The worst outcome was seen for ETMR and HGG patients with 5-year PFS of 18%±6% and 22%±7%, and 5-year OS of 24%±6% and 25%±7%, respectively.

**CONCLUSION:** The historically reported poor outcome of CNS-PNET patients becomes highly variable when tumors are molecularly classified based on DNA methylation profiling.

Patients with CNS NB-*FOXR2* responded well to current treatments and a standard-risk-CSI based regimen may be prospectively evaluated. The poor outcome of ETMR across applied treatment strategies substantiates the necessity for evaluation of novel treatments.

**KEYWORDS:** CNS embryonal tumor, ETMR, CNS NB-*FOXR2*, DNA methylation profiling, CNS-PNET

Accepted Manuscript



## KEY POINTS:

- Molecular diagnostic differentiation of rare CNS embryonal tumors is clinically relevant.
- Observed favorable outcome for CNS NB-*FOXR2* is likely based on the use of CSI.
- Frequent progressions of ETMR occurred irrespective of treatment strategy.

## IMPORTANCE OF THE STUDY

This retrospective study is a comprehensive analysis on the clinical behavior and treatment associated outcome of patients with rare CNS embryonal tumors. Central diagnostic re-evaluation was performed and structured clinical data were pooled and analysed with regard to the result of the DNA methylation-based classification. Our data show that beside high-grade gliomas also ETMR largely drive the poor outcome of historic “CNS-PNET” cohorts. In contrast to ETMR, patients with CNS NB-*FOXR2* had a much better 5-year overall survival of 85%. Our data suggest that the use of craniospinal irradiation is most likely an important premise for the favorable survival in patients with CNS NB-*FOXR2*. Patients with ETMR presented at younger age and the majority of patients developed treatment refractory progressions irrespective of treatment modality. The data confirm the importance of molecular diagnostic differentiation of rare CNS embryonal tumors and substantiate the necessity for development of entity-specific prospective clinical trials.

## INTRODUCTION

Classification of rare embryonal tumors of the central nervous system (CNS) has been a long-standing challenge that has undergone modifications over the last years. The term CNS primitive neuroectodermal tumor (CNS-PNET), removed from the WHO classification of CNS tumors within the 2016 revision, was based on diagnostic criteria of limited specificity, and inaccurate diagnoses of other entities as “CNS-PNET” were frequent.<sup>1,2</sup> In a previous CNS-PNET cohort, re-evaluated by DNA methylation analysis, many tumors could be epigenetically annotated to specific entities.<sup>3</sup> Known entities comprised embryonal tumors with multilayered rosettes (ETMR), high-grade gliomas (HGG) and multiple other diagnoses. Additionally, four new entities were delineated based on specific DNA methylation profiles and genetic alterations.<sup>3</sup> One of these new entities showed morphological similarity with CNS-neuroblastoma and harbored chromosomal rearrangements leading to an increased expression of the forkhead box R2 (*FOXR2*) gene, based on which it was termed CNS-neuroblastoma, *FOXR2* activated (CNS NB-*FOXR2*).<sup>3</sup> Nearly all CNS NB-*FOXR2* samples in this series were historically diagnosed as CNS-PNET, while the other newly defined entities were histologically more diverse and were also resolved from other diagnoses.<sup>3</sup> Beside CNS NB-*FOXR2*, only ETMR uniquely presented as CNS-embryonal tumors on morphological evaluation in this and other series.<sup>3-6</sup>

The term ETMR has been introduced as a unifying diagnosis for tumors with diverse histological designations such as ependymoblastoma, embryonal tumor with abundant neuropil and true rosettes (ETANTR), and medulloepithelioma.<sup>1,7,8</sup> The characteristic molecular hallmark of this entity, amplification of the microRNA cluster on chromosome 19 (*C19MC*), is present in ~90% of the ETMR cases, while tumors lacking the *C19MC*

amplification frequently harbour bi-allelic *DICER1* mutations, of which the first hit is generally present in the germline of the patients.<sup>8-12</sup>

Historically, patients with a diagnosis of CNS-PNET have mostly been treated similar to high-risk medulloblastoma patients with the few prospective clinical trials often including pineoblastoma patients.<sup>13-18</sup> Reported outcome rates were poor for both, for young children treated with chemotherapy-based regimens, and for older children who underwent combined intensified radiotherapy and chemotherapy. However, after identification of the molecular heterogeneity of the histologically diagnosed CNS-PNET cohorts, previously published data on treatment and outcome of patients with CNS-PNET have to be interpreted with caution. Indeed, retrospective molecular evaluation of tumors from a cohort of patients prospectively treated as CNS-PNET patients identified a high fraction of HGG with poor prognosis, while survival rates for patients with molecularly confirmed CNS-embryonal tumors were superior compared to historic series, despite the heterogeneity within this group.<sup>18</sup>

Clinical data published in the literature on patients with retrospective molecularly characterized rare CNS-embryonal tumors are scarce.<sup>3</sup> Therefore, we analyzed tumor samples of clinically well-annotated patients with a historic histopathological diagnosis of CNS-PNET to evaluate the clinical behavior within molecularly well-defined groups, with a special focus on the CNS-embryonal tumor entities CNS NB-*FOXR2* and ETMR.

## METHODS

### **Study design and participants**

Twenty national groups or single institutions participated in this retrospective study and provided original tumor material and link-anonymized or anonymized clinical data of patients diagnosed previously with CNS-PNET and treated within a prospective trial or on an institutional basis. The study has been evaluated and approved by the ethics board of the coordinating institution and by local ethics boards of participating groups where required according to initial consent and trial approval.

Eligibility for evaluation within the retrospective study was based on initial local or national central histopathological diagnosis of CNS-PNET (for cases diagnosed after implementation of the 2007 WHO classification of CNS tumors), or diagnosis of supratentorial PNET (for cases with earlier diagnoses).<sup>19</sup> At the time of study initiation, availability of sufficient archival FFPE material for diagnostic re-evaluation was required for inclusion. By amendment, the eligibility criteria were later adapted to include clinical information on patients based on the availability of a DNA methylation profile classified as one of the newly described, molecularly defined entities<sup>3</sup>, of which only data from patients with CNS NB-*FOXR2* are included in the amended cohort of this manuscript.

### **Histological and molecular re-evaluation**

Histological and molecular evaluation of tumor samples included an independent neuropathological review by a panel of expert neuropathologists and a DNA methylation based classification using a random forest class prediction algorithm (version 11b4; [www.molecularneuropathology.org](http://www.molecularneuropathology.org)) as described previously.<sup>20</sup> In addition, DNA methylation data were clustered with reference samples using t-distributed stochastic neighbor embedding

(tSNE) dimensionality reduction in order to verify the results of the methylation classifier. Diagnoses were assigned based on a calibrated score of  $>0.9$ , or a lower score and clustering within the respective cohort. Copy number profiles were created from the DNA methylation data using the conumee package (v.1.3.0). Results of the neuropathological panel review will be reported separately.

### **Cohort description and clinical data**

Overall, 307 CNS-PNET samples were submitted. Date of diagnosis ranged from 1988 to 2017. For 197/307 (64%) samples, both DNA methylation profile and corresponding results of the neuropathological panel review were available. For 109 (36%) samples only DNA methylation data were generated. Of the patients included after amendment, 66 patients with DNA methylation profile of CNS NB-*FOXR2* were identified. Tumor material had been analyzed and results partly published before for 74/307 samples of the re-evaluation cohort,<sup>3,12,21</sup> and 46/66 samples of the amended cohort.<sup>3,18</sup> These include samples of 22 of 35 ETMR patients, and 15 of 20 CNS NB-*FOXR2* patients clinically described in recent series.<sup>22</sup> (and Juhnke et al., *Neuro-Oncology*, accepted for publication)

Structured clinical information was submitted for 292 patients (Figure 1A), of whom 204 were treated within or according to trials that recruited CNS-PNET patients.<sup>14-16,18,23-35</sup> Information on staging was acquired according to the Chang-classification.<sup>36</sup> Information on response to treatment was based on the institutional or group-specific response criteria. Data were linked to acquired results of the diagnostic re-evaluation and pooled for analyses. Detailed plausibility control and descriptive analysis of treatment was performed for patients with molecularly confirmed CNS-embryonal tumor entities ETMR and CNS NB-*FOXR2*.

### **Statistical Analysis**

Data analysis focused on entity-specific description of presentation, treatment, pattern of relapse, progression-free (PFS), and overall survival (OS). Descriptive analyses were performed by Kaplan-Meier estimates and log-rank tests for PFS and OS rates ( $\pm$  standard errors). All *p*-values were considered as explorative and no significance level was fixed. Analyses were performed with SPSS software (IBM), version 22.

## RESULTS

### Molecular evaluation of CNS-PNET cohort

DNA methylation-based classification of the 307 “CNS-PNET”s confirmed a molecular profile matching CNS-embryonal tumors of interest for 94 (31%) patients: 58 (19%) patients with ETMR and 36 (12%) patients with CNS NB-*FOXR2* (Figure 1B). The DNA methylation class for these two entities was in accordance with parallel and blinded histopathological re-evaluation for all samples with FFPE sections (ETMR, n=38; CNS NB-*FOXR2*, n=29). Based on the DNA methylation pattern, another 57 (19%) tumors were classified as HGG, including distinct subtypes such as “glioblastoma, H3.3 G34 mutant” (GBM-G34, n=10)<sup>37</sup>, “infantile hemispheric glioma” (IHG, n=7)<sup>38</sup>, “diffuse midline glioma H3K27M mutant” (DMG-K27, n=6), “glioblastoma, IDH wildtype, subclass midline” (GBM-MID, n=6)<sup>39</sup>, “glioblastoma, subclass MYCN” (GBM-MYCN, n=5)<sup>40</sup>, and other not further specified HGGs (HGG-NOS, n=19) (Figure 1D). Blinded neuropathological review confirmed the diagnosis of HGG in 30/39 (77%) evaluated samples. The remaining CNS-PNET samples (n=156) were either classified as other known entities (n=89; 29%), including ependymoma with *RELA* fusion (n=23; 7%), ATRT (n=13; 4%), pineoblastoma (n=10; 3%), medulloblastoma (n=9; 3%), CNS HGNET-*BCOR* (n=6; 2%)<sup>3</sup>, CNS *CIC*-rearranged sarcoma (n=6; 2%)<sup>3</sup>, CNS HGNET-*MNI* (n=4; 1%)<sup>3</sup>, diffuse glioneuronal tumour with oligodendroglioma-like features and nuclear clusters (DGONC, n=4; 1%)<sup>41</sup>, CNS sarcoma with *DICER1* mutation (n=2; 0.6%)<sup>42</sup>,

or were not classifiable (n=67; 22%) by DNA methylation-based analyses at the time of evaluation (Figure 1B, and supplementary figure S1). Overall t-SNE analysis and visualisation of the DNA methylation profiles of all 307 samples showed that ETMRs and CNS NB-*FOXR2* cases formed two distinct clusters. All other samples formed one large cluster with smaller clusters therein representing distinct entities mentioned above. Only some separation between HGGs and other tumors was observed within this cluster (Figure 1C). The distribution of entities identified by DNA methylation profiling were in line with previous reports on CNS-PNET.<sup>3</sup> Based on these findings, we grouped the CNS-PNET cohort into five categories for subsequent analyses: CNS NB-*FOXR2*, ETMR, HGG, other, and unclassified (Figure 1B,C).

### **CNS NB-*FOXR2***

In total, DNA methylation profiles were available for 102 CNS NB-*FOXR2* tumors. The calibrated score based on the brain tumor classifier version 11b4 was > 0.9 for 94 samples. Clustering within the cohort was confirmed for the remaining eight samples, while no major differences were observed in comparison to the samples with high scores. The samples which could be re-evaluated neuropathologically (n=29) showed histological features with predominant neuroblastic/neurocytic differentiation corresponding to the WHO diagnosis “CNS neuroblastoma” but also very undifferentiated neuroepithelial phenotypes. DNA copy number profiles derived from DNA methylation data showed gain of chromosome 1q in nearly all samples (94%). Other chromosomal gains or losses frequently ( $\geq 20\%$ ) observed in these tumors included gain of 3q (21%), 8p (21%), 8q (28%), and 17q (49%) as well as loss of 3p (34%), 6q (24%), 10q (25%), and 16q (56%) (Figure 2A), and are in line with previous findings in this tumor group.<sup>3</sup>

Median age at diagnosis was 5.0 years (range 1.0 to 20.0 years) and sex ratio was nearly balanced with 56/102 females (55%) (Figure 2B, 2C). Tumor location was supratentorial in all 87 cases with available information (Figure 2D). Clinical data were available for 63 patients (Figure 1A). For 10/63 (16%) patients, macroscopic CNS metastases detected on MR-imaging were reported at diagnosis (Table 1).

Forty-four patients underwent postoperative chemotherapy (CT), and 19 patients started treatment with irradiation (CSI 18, local RT 1) (Figure 2E). For patients who received postoperative chemotherapy, objective response was documented in 13/18 (72%) patients with evaluable disease. High-dose chemotherapy was applied to 22 patients (after induction chemotherapy, n=19; after irradiation, n=3), with objective response documented in 4/6 patients with evaluable disease (Figure 2E).

Upfront radiotherapy (RT) was administered to 51 patients (CSI and boost for 42, and local irradiation for nine patients). Of those 51 patients, 19 received RT postoperatively, while the other 32 received RT after CT. Median CSI dose was 35 Gy (range: 23.4 – 41.0 Gy; dose  $\leq$  24 Gy: n=12; dose  $>$  24 Gy: n=27; dose unknown: n=3). Median boost dose was 55.0 Gy (range: 49.6 – 72.0 Gy). Objective response to treatment with CSI and boost was documented for 7/8 (88%) patients with evaluable disease.

Relapse, progression, or death of unknown reason was observed in 22/63 (35%) patients, with 11 radiotherapy-naïve at time of relapse and six of whom had received high-dose chemotherapy before relapse/progression (Figure 2E). For patients who had received upfront irradiation, relapse/progression or death occurred in 7/42 after CSI (2/12 with dose  $\leq$  24 Gy; 5/27 with dose  $>$  24 Gy, Fisher exact test, p=1.0) and in 4/9 after local radiotherapy. Location



of relapse was local for 7/11 radiotherapy-naïve patients, whereas after local irradiation 4/4 distant events occurred (Fisher exact test,  $p=0.08$ ) (Table 2). Late relapses were observed (7/22 events occurred later than two years after diagnosis) with the latest relapse documented 5.9 years after diagnosis. Overall, 10/63 (16%) patients died within the observation time. Thus, the data show an overall high rate of survival after combined craniospinal irradiation and chemotherapy treatment, with however prolonged period of risk for development of relapse and disease associated death.

### **ETMR**

Fifty-eight tumors were classified as ETMR according to methylation profiling (54 with calibrated scores  $> 0.9$  based on classifier version 11b4). The samples that could be re-evaluated neuropathologically showed histological features of an immature small cell tumor with multi-layered (ependymoblastic) rosettes or medulloepithelioma-like trabecular structures, varying amounts of synaptophysin positive neuropil and characteristic LIN28A expression. Copy number profiles derived from the methylation data identified the characteristic *C19MC* amplification in 55/58 (95%) of cases and gain of chromosome 2 in 47/58 (81%) (Figure 3A,B). The four samples with calibrated scores of the DNA methylation profile  $< 0.9$  clustered at the edges of the ETMR cohort, with three of them being C19MC-negative as described within a previous large series of ETMR patients.<sup>12</sup>

Median age at diagnosis was 2.5 years (range 0.8 to 7.6 years) and sex ratio was nearly balanced with 33/58 females (57%) (Figure 3B,C). Most tumors ( $n=48$ , 83%) were located supratentorially, with a potential sampling bias towards supratentorial lesions, as only tumors with an initial diagnosis of CNS-PNET or stPNET were collected. Still, in 9 (16%) patients an infratentorial ( $n=6$ ) or extended infra-/supratentorial ( $n=3$ ) location was documented

(location unknown, n=1). Detailed clinical data were available for 52/58 patients (Figure 1A). Initial metastatic presentation was reported in 13 (25%) patients (Table 1).

Of the 49 patients who received postoperative treatment, treatment was started with chemotherapy for most patients (n=45; 92%) (Figure 3E). Objective response was documented in 7/24 (29%) patients with evaluable disease, whereas 22/45 (49%) showed treatment-refractory relapse or progression, and another three patients progressed after initial response or stable disease. Seventeen patients underwent high-dose chemotherapy with autologous stem cell rescue after conventional chemotherapy, with objective response documented in 2/6 (33%) patients with evaluable disease. Immediate and delayed relapse/progression to high-dose chemotherapy was documented in 9/16 (56%) patients. Upfront irradiation was applied either as CSI (n=10) or local irradiation (n=4) in combination with chemotherapy  $\pm$  high-dose chemotherapy treatment. Median CSI dose was 24 Gy (range: 23.4–35.2 Gy), median local boost dose was 55.0 Gy (range: 54.0 – 59.7 Gy).

Relapse or progression occurred in 40/49 (82%) treated patients, with 38/40 (95%) progressing/relapsing while on treatment. Relapse or progression occurred in 34 radiotherapy-naïve patients. After irradiation, relapse/progression occurred in 5/10 patients after CSI, and in 1/4 patients after local irradiation and high-dose chemotherapy (Table 2). All six patients who relapsed after radiotherapy died. Of 34 patients who relapsed before irradiation, 22 patients received radiotherapy as salvage treatment and four were alive at last follow-up (Table 2). There was no first event documented later than 1.4 years after diagnosis. Overall, 36/49 (73%) patients died within the observation time, with the latest death documented 2.4 years after diagnosis. Of 13 survivors at last follow-up, 10 patients were alive longer than 2.5 years after diagnosis. Of the latter patients, all had supratentorially

located tumors, 6/10 were females, 9/10 were not metastasized, GTR was achieved for 7/10 by first or second resection, and all were irradiated within primary (n=8), or salvage (n=2) treatment. The data show the highly aggressive and treatment-refractory behaviour of most ETMR, while prolonged survival has been observed for a subset of ETMR patients. There were no molecular features detected that were associated to a favourable outcome based on the here performed analyses.

Accepted Manuscript

## Survival analyses

In the CNS-PNET re-evaluation cohort, the overall 5-year PFS and OS were  $40\% \pm 3\%$  and  $51\% \pm 3\%$ , respectively (Figure 4A,B). Survival markedly differed for the patients with different molecularly informed diagnoses. Best survival rates were observed for CNS NB-*FOXR2* patients (5-year PFS and OS:  $69\% \pm 9\%$ ;  $86\% \pm 7\%$ ) (Figure 4C,D). Similar survival rates were observed for the extended cohort of CNS NB-*FOXR2* patients (5-year PFS and OS:  $57\% \pm 10\%$ ;  $85\% \pm 5\%$ ). Combining both CNS NB-*FOXR2* cohorts, 5-year PFS and OS were  $63\% \pm 7\%$  and  $85\% \pm 5\%$ , respectively. No statistically relevant differences in survival according to initial staging were observed in this cohort (Table 2, Figure 4E,F). The worst survival rates within the CNS-PNET re-evaluation cohort were observed for ETMR patients (5-year PFS and OS:  $18\% \pm 6\%$ ;  $24\% \pm 6\%$ ) and HGG patients (5-year PFS and OS:  $22\% \pm 7\%$ ;  $25\% \pm 7\%$ ) (Figure 4C,D). Presentation with metastases, but not postoperative residual tumor had a negative impact on outcome for patients with ETMR, with 5-year PFS and OS of  $25\% \pm 10\%$ , and  $34\% \pm 11\%$  for 20 non-metastatic patients with complete resection, compared to  $8\% \pm 7\%$  for both, PFS (log-rank  $p=0.08$ ) and OS (log-rank  $p=0.007$ ) for 13 patients with metastases at presentation (Table 2, Figure 4G,H).

Five-year PFS and OS for the pooled group of patients with tumors classified as other known entities were  $44\% \pm 6\%$  and  $58\% \pm 6\%$ , respectively. The mixed cohort of patients with tumors unclassifiable by DNA methylation at the time of analysis showed 5-year PFS and OS of  $54\% \pm 7\%$  and  $69\% \pm 7\%$ , respectively (Figure 4C,D).

## DISCUSSION

The heterogeneity of the historical cohorts of tumors diagnosed as “CNS-PNET” as well as the emergence of molecularly defined entities has led to diagnostic and therapeutic uncertainty.<sup>1-3,18</sup> Historically, patients with CNS-PNET were treated with age-dependent intensive multimodal treatment strategies resulting in high rates of toxicity and poor survival rates.<sup>13-18,24,43-45</sup> Survival rates of the current CNS-PNET re-evaluation cohort are comparable to previously published series. Crucially, our cohort confirms that only a minor proportion of patients included in historical CNS-PNET cohorts can be considered as having CNS embryonal tumors according to current diagnostic methods and criteria.<sup>2,3,18</sup> In the present re-evaluation cohort, 19% of tumors were classified as ETMR and 12% were classified as CNS NB-*FOXR2*. Reliable diagnosis of these tumors is clinically relevant, as they demonstrate a particular clinical behavior. In contrast to ETMR, patients with CNS NB-*FOXR2* present at an older age, have exclusively supratentorial tumors, and show higher response as well as superior survival rates. In the ACNS0332 trial, which included patients older than three years of age with CNS-PNET, patients with supratentorial embryonal tumors and pineoblastomas had a favorable outcome after excluding other entities, mainly HGG. However, the majority of the patients in the favorable prognostic group in this series were diagnosed with pineoblastoma. A separate analysis of patients with CNS NB-*FOXR2* was not possible due to the limited number of cases.<sup>18</sup> Further data on CNS-neuroblastoma are rare. Since the initial description of the respective histopathological diagnosis, only very few cases have been published. In the early series, the reported survival was poor, while the few additional reports, some lacking molecular annotation, indicate a superior survival.<sup>21,22,46-48</sup>

While the favourable survival for patients with CNS NB-*FOXR2* is clearly confirmed in our series, our data show a higher rate of recurrences in non-irradiated and locally irradiated

patients. Despite the small numbers and data quality limitations of retrospective analysis, the observation of distant metastases after local irradiation may indicate a treatment induced shift of recurrences to distant sites, as it has been shown in medulloblastoma patients.<sup>49,50</sup> The applied CSI doses in our series were variable. Since only 7/42 patients relapsed or died after CSI, the impact of radiation dose on treatment benefit cannot be assessed. While these findings need prospective confirmation, a “medulloblastoma”-like treatment with combination of (medulloblastoma) standard dose CSI and maintenance chemotherapy may be a reasonable treatment choice for older children with localized disease. The benefit of local irradiation for younger children is controversial, with salvage-CSI at the time of relapse as a therapeutic alternative. Given the rarity of the disease, an international registry with prospective clinical data collection may provide a reliable interim source of information until a cooperative, prospective clinical trial can be launched. The observation of frequent late relapses points to the necessity of long-term follow-up.

In agreement with previous publications, survival rates for ETMR were very poor despite intensive multimodal treatment.<sup>7,8,51</sup> Response to chemotherapy was documented for a subset of patients of our cohort, but most patients showed early treatment-refractory progressions on initial treatment with chemotherapy as well as after initial postoperative radiotherapy. Frequent early progression and poor overall survival despite intensive multimodal treatment indicate that innovative treatment approaches are required to improve the outcome of this devastating disease. Therefore, the goal is prospective evaluation of rationally designed targeted therapies that are based on potential effective drug combinations, identified by molecular sequencing and preclinical analyses.<sup>12,52-55</sup> (and Juhnke et al., *Neuro-Oncology*, accepted for publication)

The role of upfront radiotherapy for treatment of ETMR cannot be determined based on this retrospective series. However, in agreement with further series, most survivors were irradiated.<sup>56</sup> The majority of these patients have received CSI, but survivors were also documented within the small group of children, who received local irradiation in combination with dose-intense chemotherapy. This may indicate that similar to ATRT addition of upfront local irradiation may be a reasonable treatment for this entity which mainly presents at a very young age.<sup>57</sup> According to other publications that describe long-term survival for ETMR patients, 10/50 treated patients in our series were survivors with prolonged follow-up.<sup>58,59</sup> (and Juhnke et al., *Neuro-Oncology*, accepted for publication) In our series, this was however rather influenced by the absence of early progression and not associated with a specific treatment.

Within the heterogeneous group of HGG and other entities, detected in this and previous CNS-PNET re-evaluation series, there are several rare entities with idiosyncratic driving mutations or pathways.<sup>37-40,60</sup> Collaborative efforts will be needed to assess the clinical behaviour and response to conventional or targeted treatment of these entities. Furthermore, there are still tumors which cannot be reliably classified according to the current DNA methylation-based class prediction algorithm (version 11b4).<sup>20</sup> This cohort likely represents a mix of rare and heterogeneous neuroepithelial and mesenchymal tumors. Survival of the respective patients was moderate and superior to previously reported CNS-PNET series, which is likely explained by exclusion of poor-prognostic HGG of this cohort. Further improvement of diagnostic classification is required for appropriate assignment of treatment strategy.

The evidence of our data is limited by the retrospective design of the study, the long period of initial patient diagnosis and the variability in applied treatment. However, due to the novelty of the diagnostic delineation of these entities, there are no prospective data within this scope available.

Our data proof the relevance of molecular diagnostic differentiation and development of entity-specific, prospective data for CNS NB-*FOXR2* and ETMR. Our data may serve as baseline data required for the set-up of respective trials.

**Acknowledgement:**

The authors thank all clinicians and involved data manager for contribution of data, as well as all pathologists who have sent the cases for central review and molecular analysis.

Accepted Manuscript



## References

1. Louis DN, Ohgaki H, Wiestler O, et al. *WHO classification of tumours of the central nervous system*. revised 4th Edition ed. Lyon: International agency for research on cancer; 2016.
2. Schwalbe EC, Hayden JT, Rogers HA, et al. Histologically defined central nervous system primitive neuro-ectodermal tumours (CNS-PNETs) display heterogeneous DNA methylation profiles and show relationships to other paediatric brain tumour types. *Acta neuropathologica*. 2013; 126(6):943-946.
3. Sturm D, Orr BA, Toprak UH, et al. New Brain Tumor Entities Emerge from Molecular Classification of CNS-PNETs. *Cell*. 2016; 164(5):1060-1072.
4. Ferris SP, Velazquez Vega J, Aboian M, et al. High-grade neuroepithelial tumor with BCOR exon 15 internal tandem duplication—a comprehensive clinical, radiographic, pathologic, and genomic analysis. *Brain pathology*. 2020; 30(1):46-62.
5. Tauziede-Espariat A, Pages M, Roux A, et al. Pediatric methylation class HGNET-MN1: unresolved issues with terminology and grading. *Acta neuropathologica communications*. 2019; 7(1):176.
6. Łastowska M, Trubicka J, Sobocińska A, et al. Molecular identification of CNS NB-FOXR2, CNS EFT-CIC, CNS HGNET-MN1 and CNS HGNET-BCOR pediatric brain tumors using tumor-specific signature genes. *Acta neuropathologica communications*. 2020; 8(1):105.
7. Korshunov A, Sturm D, Ryzhova M, et al. Embryonal tumor with abundant neuropil and true rosettes (ETANTR), ependymoblastoma, and medulloepithelioma share molecular similarity and comprise a single clinicopathological entity. *Acta neuropathologica*. 2014; 128(2):279-289.

8. Spence T, Sin-Chan P, Picard D, et al. CNS-PNETs with C19MC amplification and/or LIN28 expression comprise a distinct histogenetic diagnostic and therapeutic entity. *Acta neuropathologica*. 2014; 128(2):291-303.
9. Pfister S, Remke M, Castoldi M, et al. Novel genomic amplification targeting the microRNA cluster at 19q13.42 in a pediatric embryonal tumor with abundant neuropil and true rosettes. *Acta neuropathologica*. 2009; 117(4):457-464.
10. Li M, Lee KF, Lu Y, et al. Frequent amplification of a chr19q13.41 microRNA polycistron in aggressive primitive neuroectodermal brain tumors. *Cancer cell*. 2009; 16(6):533-546.
11. Uro-Coste E, Masliah-Planchon J, Siegfried A, et al. ETMR-like infantile cerebellar embryonal tumors in the extended morphologic spectrum of DICER1-related tumors. *Acta neuropathologica*. 2019; 137(1):175-177.
12. Lambo S, Grobner SN, Rausch T, et al. The molecular landscape of ETMR at diagnosis and relapse. *Nature*. 2019; 576(7786):274-280.
13. Pizer BL, Weston CL, Robinson KJ, et al. Analysis of patients with supratentorial primitive neuro-ectodermal tumours entered into the SIOP/UKCCSG PNET 3 study. *European journal of cancer*. 2006; 42(8):1120-1128.
14. Massimino M, Gandola L, Spreafico F, et al. Supratentorial primitive neuroectodermal tumors (S-PNET) in children: A prospective experience with adjuvant intensive chemotherapy and hyperfractionated accelerated radiotherapy. *International journal of radiation oncology, biology, physics*. 2006; 64(4):1031-1037.
15. Friedrich C, von Bueren AO, von Hoff K, et al. Treatment of young children with CNS-primitive neuroectodermal tumors/pineoblastomas in the prospective multicenter trial HIT 2000 using different chemotherapy regimens and radiotherapy. *Neuro-oncology*. 2013; 15(2):224-234.

16. Gerber NU, von Hoff K, Resch A, et al. Treatment of children with central nervous system primitive neuroectodermal tumors/pinealoblastomas in the prospective multicentric trial HIT 2000 using hyperfractionated radiation therapy followed by maintenance chemotherapy. *International journal of radiation oncology, biology, physics*. 2014; 89(4):863-871.
17. Jakacki RI, Burger PC, Kocak M, et al. Outcome and prognostic factors for children with supratentorial primitive neuroectodermal tumors treated with carboplatin during radiotherapy: a report from the Children's Oncology Group. *Pediatr Blood Cancer*. 2015; 62(5):776-783.
18. Hwang EI, Kool M, Burger PC, et al. Extensive Molecular and Clinical Heterogeneity in Patients With Histologically Diagnosed CNS-PNET Treated as a Single Entity: A Report From the Children's Oncology Group Randomized ACNS0332 Trial. *Journal of clinical oncology*. 2018; 36(34):3388-3395.
19. Louis DN, Ohgaki H, Wiestler O, Cavenee WK, eds. *WHO Classification of tumours of the central nervous system*. Lyon: IARC; 2007.
20. Capper D, Jones DTW, Sill M, et al. DNA methylation-based classification of central nervous system tumours. *Nature*. 2018; 555(7697):469-474.
21. Holsten T, Lubieniecki F, Spohn M, et al. Detailed Clinical and Histopathological Description of 8 Cases of Molecularly Defined CNS Neuroblastomas. *J Neuropathol Exp Neurol*. 2021; 80(1):52-59.
22. Korshunov A, Okonechnikov K, Schmitt-Hoffner F, et al. Molecular analysis of pediatric CNS-PNET revealed nosologic heterogeneity and potent diagnostic markers for CNS neuroblastoma with FOXR2-activation. *Acta neuropathologica communications*. 2021; 9(1):20.

23. Aridgides PD, Kang G, Mazewski C, Merchant TE. Outcomes after Radiation Therapy for Very Young Children with High-Risk Medulloblastoma or Supratentorial Primitive Neuroectodermal Tumor Treated on COG ACNS0334. *International journal of radiation oncology, biology, physics*. 2019; 105(1):S109.
24. Dufour C, Kieffer V, Varlet P, et al. Tandem high-dose chemotherapy and autologous stem cell rescue in children with newly diagnosed high-risk medulloblastoma or supratentorial primitive neuro-ectodermic tumors. *Pediatr Blood Cancer*. 2014; 61(8):1398-1402.
25. Fangusaro J, Finlay J, Sposto R, et al. Intensive chemotherapy followed by consolidative myeloablative chemotherapy with autologous hematopoietic cell rescue (AuHCR) in young children with newly diagnosed supratentorial primitive neuroectodermal tumors (sPNETs): report of the Head Start I and II experience. *Pediatr Blood Cancer*. 2008; 50(2):312-318.
26. Gajjar A, Chintagumpala M, Ashley D, et al. Risk-adapted craniospinal radiotherapy followed by high-dose chemotherapy and stem-cell rescue in children with newly diagnosed medulloblastoma (St Jude Medulloblastoma-96): long-term results from a prospective, multicentre trial. *Lancet Oncol*. 2006; 7(10):813-820.
27. Geyer JR, Sposto R, Jennings M, et al. Multiagent chemotherapy and deferred radiotherapy in infants with malignant brain tumors: a report from the Children's Cancer Group. *Journal of clinical oncology*. 2005; 23(30):7621-7631.
28. Grundy RG, Wilne SH, Robinson KJ, et al. Primary postoperative chemotherapy without radiotherapy for treatment of brain tumours other than ependymoma in children under 3 years: results of the first UKCCSG/SIOP CNS 9204 trial. *European journal of cancer*. 2010; 46(1):120-133.

29. Lannering B, Rutkowski S, Doz F, et al. Hyperfractionated versus conventional radiotherapy followed by chemotherapy in standard-risk medulloblastoma: results from the randomized multicenter HIT-SIOP PNET 4 trial. *Journal of clinical oncology*. 2012; 30(26):3187-3193.
30. Massimino M, Gandola L, Biassoni V, et al. Evolving of therapeutic strategies for CNS-PNET. *Pediatr Blood Cancer*. 2013; 60(12):2031-2035.
31. Packer RJ, Goldwein J, Nicholson HS, et al. Treatment of children with medulloblastomas with reduced-dose craniospinal radiation therapy and adjuvant chemotherapy: A Children's Cancer Group Study. *Journal of clinical oncology*. 1999; 17(7):2127-2136.
32. Perek D, Perek-Polnik M, Drogosiewicz M, Dembowska-Baginska B, Barszcz S. [Treatment results of patients over 3 years of age with medulloblastoma]. *Med Wieku Rozwoj*. 2003; 7(2):201-210.
33. Szentés A, Eros N, Kekecs Z, et al. Cognitive deficits and psychopathological symptoms among children with medulloblastoma. *Eur J Cancer Care*.. 2018; 27(6):e12912.
34. von Hoff K, Hinkes B, Gerber NU, et al. Long-term outcome and clinical prognostic factors in children with medulloblastoma treated in the prospective randomised multicentre trial HIT'91. *European journal of cancer*. 2009; 45(7):1209-1217.
35. Timmermann B, Kortmann RD, Kuhl J, et al. Role of radiotherapy in supratentorial primitive neuroectodermal tumor in young children: results of the German HIT-SKK87 and HIT-SKK92 trials. *Journal of clinical oncology*. 2006; 24(10):1554-1560.
36. Chang CH, Housepian EM, Herbert C, Jr. An operative staging system and a megavoltage radiotherapeutic technic for cerebellar medulloblastomas. *Radiology*. 1969; 93(6):1351-1359.

37. Korshunov A, Capper D, Reuss D, et al. Histologically distinct neuroepithelial tumors with histone 3 G34 mutation are molecularly similar and comprise a single nosologic entity. *Acta neuropathologica*. 2016; 131(1):137-146.
38. Clarke M, Mackay A, Ismer B, et al. Infant High-Grade Gliomas Comprise Multiple Subgroups Characterized by Novel Targetable Gene Fusions and Favorable Outcomes. *Cancer Discov*. 2020; 10(7):942-963.
39. Reuss DE, Kratz A, Sahm F, et al. Adult IDH wild type astrocytomas biologically and clinically resolve into other tumor entities. *Acta neuropathologica*. 2015; 130(3):407-417.
40. Korshunov A, Schrimpf D, Ryzhova M, et al. H3-/IDH-wild type pediatric glioblastoma is comprised of molecularly and prognostically distinct subtypes with associated oncogenic drivers. *Acta neuropathologica*. 2017; 134(3):507-516.
41. Deng MY, Sill M, Sturm D, et al. Diffuse glioneuronal tumour with oligodendroglioma-like features and nuclear clusters (DGONC) - a molecularly defined glioneuronal CNS tumour class displaying recurrent monosomy 14. *Neuropathol Appl Neurobiol*. 2020; 46(5):422-430.
42. Koelsche C, Mynarek M, Schrimpf D, et al. Primary intracranial spindle cell sarcoma with rhabdomyosarcoma-like features share a highly distinct methylation profile and DICER1 mutations. *Acta neuropathologica*. 2018; 136(2):327-337.
43. Stensvold E, Krossnes BK, Lundar T, et al. Outcome for children treated for medulloblastoma and supratentorial primitive neuroectodermal tumor (CNS-PNET) - a retrospective analysis spanning 40 years of treatment. *Acta oncologica*. 2017; 56(5):698-705.

44. Choi SH, Kim SH, Shim KW, et al. Treatment Outcome and Prognostic Molecular Markers of Supratentorial Primitive Neuroectodermal Tumors. *PLoS One*. 2016; 11(4):e0153443.
45. de Rojas T, Bautista F, Flores M, et al. Management and outcome of children and adolescents with non-medulloblastoma CNS embryonal tumors in Spain: room for improvement in standards of care. *Journal of neuro-oncology*. 2018; 137(1):205-213.
46. Horten BC, Rubinstein LJ. Primary cerebral neuroblastoma. A clinicopathological study of 35 cases. *Brain*. 1976; 99(4):735-756.
47. Bennett JP, Jr., Rubinstein LJ. The biological behavior of primary cerebral neuroblastoma: a reappraisal of the clinical course in a series of 70 cases. *Ann Neurol*. 1984; 16(1):21-27.
48. Bianchi F, Tamburrini G, Gessi M, Frassanito P, Massimi L, Caldarelli M. Central nervous system (CNS) neuroblastoma. A case-based update. *Child's nervous system*. 2018; 34(5):817-823.
49. Ashley DM, Merchant TE, Strother D, et al. Induction chemotherapy and conformal radiation therapy for very young children with nonmetastatic medulloblastoma: Children's Oncology Group study P9934. *Journal of clinical oncology*. 2012; 30(26):3181-3186.
50. Mynarek M, von Hoff K, Pietsch T, et al. Nonmetastatic Medulloblastoma of Early Childhood: Results From the Prospective Clinical Trial HIT-2000 and An Extended Validation Cohort. *Journal of clinical oncology*. 2020; 38(18):2028-2040.
51. Horwitz M, Dufour C, Leblond P, et al. Embryonal tumors with multilayered rosettes in children: the SFCE experience. *Child's nervous system*. 2016; 32(2):299-305.

52. Sin-Chan P, Mumal I, Suwal T, et al. A C19MC-LIN28A-MYCN Oncogenic Circuit Driven by Hijacked Super-enhancers Is a Distinct Therapeutic Vulnerability in ETMRs: A Lethal Brain Tumor. *Cancer cell*. 2019; 36(1):51-67 e57.
53. Schmidt C, Schubert NA, Brabetz S, et al. Preclinical drug screen reveals topotecan, actinomycin D, and volasertib as potential new therapeutic candidates for ETMR brain tumor patients. *Neuro-oncology*. 2017; 19(12):1607-1617.
54. Neumann JE, Wefers AK, Lambo S, et al. A mouse model for embryonal tumors with multilayered rosettes uncovers the therapeutic potential of Sonic-hedgehog inhibitors. *Nature medicine*. 2017; 23(10):1191-1202.
55. Kleinman CL, Gerges N, Papillon-Cavanagh S, et al. Fusion of TTYH1 with the C19MC microRNA cluster drives expression of a brain-specific DNMT3B isoform in the embryonal brain tumor ETMR. *Nat Genet*. 2014; 46(1):39-44.
56. Jaramillo S, Grosshans DR, Philip N, et al. Radiation for ETMR: Literature review and case series of patients treated with proton therapy. *Clin Transl Radiat Oncol*. 2019; 15:31-37.
57. Chi SN, Zimmerman MA, Yao X, et al. Intensive multimodality treatment for children with newly diagnosed CNS atypical teratoid rhabdoid tumor. *Journal of clinical oncology*. 2009; 27(3):385-389.
58. Mozes P, Hauser P, Hortobagyi T, et al. Evaluation of the good tumor response of embryonal tumor with abundant neuropil and true rosettes (ETANTR). *Journal of neuro-oncology*. 2016; 126(1):99-105.
59. Hanson D, Hoffman LM, Nagabushan S, et al. A modified IRS-III chemotherapy regimen leads to prolonged survival in children with embryonal tumor with multilayer rosettes. *Neurooncol Adv*. 2020; 2(1):vdaa120.



60. Mackay A, Burford A, Carvalho D, et al. Integrated Molecular Meta-Analysis of 1,000 Pediatric High-Grade and Diffuse Intrinsic Pontine Glioma. *Cancer cell*. 2017; 32(4):520-537.e525.

Accepted Manuscript

## Figure Legends

**Figure 1:** Cohort description. A. Patients were included either based on a historical diagnosis of CNS-PNET (CNS-PNET re-evaluation cohort) or on the results of DNA methylation profiles according to CNS NB-*FOXR2* (extended cohort). B. Pie chart of entities diagnosed by DNA methylation profiling within the CNS-PNET re-evaluation cohort. C. T-SNE analysis of DNA methylation profiles from all included. D. Further subspecification of DNA methylation profiles of HGG and other diagnoses.

**Figure 2:** CNS NB-*FOXR2*: Molecular characteristics, clinical information, and treatment. A. Overview of copy number profiles of CNS NB-*FOXR2*. Bars indicating gain, balanced or loss add up to 100% for each chromosome arm. B. The pie chart depicts the nearly balanced sex ratio. C. The bar chart shows the age distribution of age at first diagnosis (information available for 89/102 patients). D. Tumor location is specified for 87 patients with CNS NB-*FOXR2*, with each dot corresponding to one single tumor, or multiple tumors with the respective number of cases given. E. Overview of applied treatment and documented response for patients with CNS NB-*FOXR2*. Overall, 41 of 63 patients remained event-free (EF). Of 22 patients with event, 12 patients were alive at last follow-up with evidence of disease (AWD<sub>2</sub>), or in second complete remission (CR<sub>2</sub>). Further abbreviations: CT, chemotherapy; HDCT, high-dose chemotherapy; CSI, craniospinal irradiation; RT, radiotherapy; Tx, treatment; M0, localized disease, M0R0, with complete resection, M0R+, with incomplete resection, and M0Rx, with unknown resection status; M+, metastatic disease; na, not annotated; CCR, continuous complete response; CR, complete response; PR, partial response; SD, stable disease; PD, relapse or progression; ED, evaluable disease and documented response to treatment; OR, objective response; DOD, death of disease; DUR, death of unknown reason; \*given numbers refer to patients with ED;

**Figure 3:** ETMR: Molecular characteristics, clinical information, and treatment. A. Overview of copy number profiles of ETMR. Bars indicating gain, balanced or loss add up to 100% for each chromosome arm. B. Pie charts depict that 55/58 ETMR carry the characteristic *CI9MC* amplification. The sex ratio was nearly balanced. C. The bar chart shows the age distribution of age at first diagnosis (information available for 55/58 patients). D. Tumor location is specified with each dot corresponding to one single tumor, or multiple tumors with the respective number of cases given. E. Overview of applied treatment and documented response for patients with ETMR. Overall, 9 of 52 patients remained event-free (EF). Of 43 patients with event, 3 died postoperatively, 38 progressed / relapsed while on treatment, and 2 relapsed after end of treatment. § number of PD as first documented response differs from overall number of PD after the respective treatment element due to initial CCR, OR, or SD and later PD before onset of next treatment element; Further explanations and abbreviations: see Figure 2.

**Figure 4:** Kaplan Meier plots of survival. PFS (A) and OS (B) for the re-evaluation cohort. Respective PFS (C) and OS (D) for this same cohort with patients grouped according to result of DNA methylation profiles: CNS NB-*FOXR2*, ETMR, HGG, other, and unclassified. Survival according to postoperative staging for the pooled cohort of patients with CNS NB-*FOXR2*: PFS (E) and OS (F) (n=1 patient with missing information on initial staging is not regarded for this analysis), and for patients with ETMR: PFS (G) and OS (H). Patients without postoperative treatment were excluded from survival analyses.

**Table 1.** Clinical characteristics of patients with CNS NB-*FOXR2* and ETMR and available clinical data.

	<b>CNS NB-<i>FOXR2</i> (n=63)</b>		<b>ETMR (n=52)</b>	
	No.	(%)	No.	(%)
<b>Age at diagnosis</b>				
< 3 years	11	(17%)	34	(66%)
≥ 3 years	52	(83%)	18	(34%)
<b>Sex</b>				
Female	36	(57%)	29	(56%)
Male	27	(43%)	23	(44%)
<b>Location of primary tumor</b>				
Supratentorial	62	(98%)	44	(84%)
Infratentorial			5	(10%)
Supra- and infratentorial			3	(6%)
Not known	1	(2%)		
<b>Staging at diagnosis</b>				
Localized * with complete resection (M0R0)	23	(37%)	20	(38%)
Localized * with incomplete resection (M0R+)	27	(41%)	17	(33%)
Second surgery within primary treatment	6/27		9/17	
GTR at second surgery	5/6		1/9	
Localized * resection status unknown (M0Rx)	2	(3%)	1	(2%)
Microscopic spread to CSF only (M1)	0		3	(6%)
Intracranial / spinal leptomeningeal metastases (M2/3)	10	(16%)	10	(19%)
Not known	1	(3%)	1	(2%)

<b>Treatment</b>				
Within or according to a CNS-ET trial	53	(84%)	43	(83%)
Individual treatment	9	(14%)	6	(11%)
Treatment based on protocol for other entity **	1	(2%)	0	
No antitumor treatment (early death after surgery)	0		3	(6%)

\*Information on CSF staging is missing for n=6 ETMR patients with localized disease. \*\*n=1 patient with CNS NB-*FOXR2* was treated according to an ependymoma protocol. Abbreviations: CNS-ET, CNS embryonal tumor; CSF, cerebrospinal fluid, GTR, gross total resection; M0, localized disease, no metastases; M1, microscopic metastases to cerebrospinal fluid (CSF); M2/3 intracranial or spinal leptomeningeal metastases visible on MRI, according to Chang-classification.<sup>36</sup>

Accepted Manuscript

**Table 2:** Outcome according to treatment for patients with ETMR or CNS NB-*FOXR2*.

	CNS NB- <i>FOXR2</i> (n=63)			ETMR (n=49)		
<b>Observed events</b>						
Relapse / progression *	22 (35%)			40 (82%)		
Death	10 (16%)			36 (73%)		
<b>Timing of first event</b>						
On treatment	6 (27%)			38 (95%)		
After treatment	16 (73%)			2 (5%)		
<b>Outcome according to treatment with HDCT</b>						
HDCT applied before first event or last status	No HDCT (n=41)		HDCT (n=22)	No HDCT (n=32)		HDCT (n=17)
No. of patients with event	13 (32%)		9 (41%)	29 (91%)		11 (65%)
<b>Outcome according to treatment with radiotherapy (RT)</b>						
RT applied before first event or last status	No RT (n=12)	CSI (n=42)	Local RT (n=9)	No RT (n=35)	CSI (n=10)	Local RT (n=4)
No. of patients with event	11 (92%)	7 (17%)	4 (44%)	34 (97%)	5 (50%)	1 (25%)
Local relapse / progression	7	3	-	27	2	1
Distant or combined relapse / progression	4	1	4	5	3	-

Relapse / progression NOS			-		2
Death to unknown reason*			3		
<b>Outcome after first event according to previous radiotherapy</b>					
Occurrence of first event		Before irradiation	After irradiation	Before irradiation	After irradiation
		(n=11)	(n=11)	(n=34)	(n=6)
Death		3 (27%)	7 (64%)	30 (88%)	6 (100%)
Alive		8 (73%)	4 (36%)	4 (12%)	0
<b>PFS</b>					
Median PFS in years (95% CI)		8.4 (1.1-34.1)		0.6 (0.5-0.7)	
5-year PFS (SE)		63% ( $\pm 8\%$ )		18% ( $\pm 6\%$ )	
<b>PFS according to staging</b>					
M0R0, 5-year PFS (SE)		55% ( $\pm 11\%$ )		25% ( $\pm 10\%$ )	
M0R+, 5-year PFS (SE, log-rank p <sup>§</sup> )		77% ( $\pm 8\%$ , 0.57)		19% ( $\pm 10\%$ , 0.65)	
M+, 5-year PFS (SE, log-rank p <sup>§</sup> )		48% ( $\pm 16\%$ , 0.54)		8% ( $\pm 7\%$ , 0.08)	
<b>OS</b>					
Median OS in years (95% CI)		17.6 (15.5-19.7)		1.2 (0.7-1.6)	
5-year OS (SE)		85% ( $\pm 5\%$ )		24% ( $\pm 6\%$ )	
<b>OS according to staging</b>					
M0R0, 5-year OS (SE)		85% ( $\pm 8\%$ )		34% ( $\pm 11\%$ )	
M0R+/Rx, 5-year OS (SE, log-rank p <sup>§</sup> )		90% ( $\pm 7\%$ , 0.59)		23% ( $\pm 12\%$ , 0.60)	
M+, 5-year OS (SE, log-rank p <sup>§</sup> )		70% ( $\pm 15\%$ , 0.11)		8% ( $\pm 7\%$ , 0.007)	

<b>Duration of follow-up of surviving patients</b>		
median follow-up in years (range)	5.7 (0.3-19.5)	3.9 (1.0-18.5)

Patients without treatment are excluded (ETMR, n=3). Abbreviations: CI, confidence interval; CSI, craniospinal irradiation; HDCT, high-dose chemotherapy; M0, localized disease, M0R0, with complete resection, M0R+, with incomplete resection, and M0Rx, with unknown resection status; M+, metastatic disease; OS, overall survival; PD, PFS, progression-free survival; RT, radiotherapy; SE, standard error. \* Three patients with CNS NB-*FOXR2* and death to unknown reason are included in these counts. § Given values for log-rank p refer to comparison to M0R0.

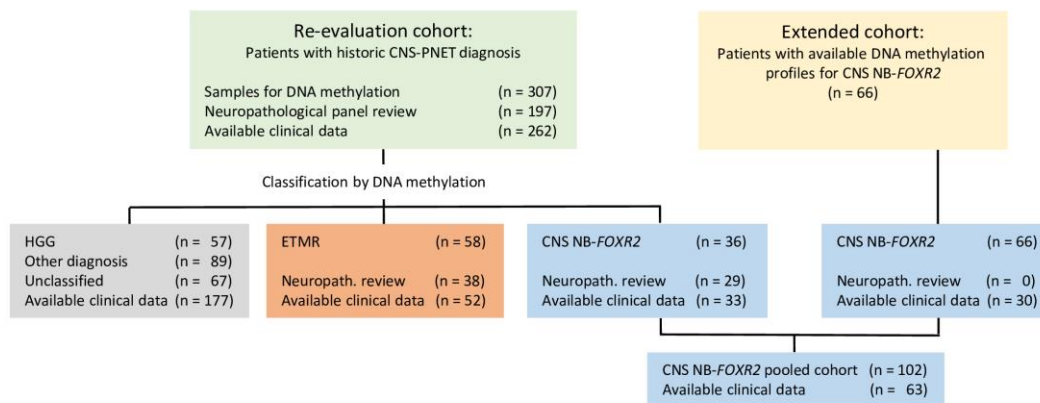
Accepted Manuscript



**FIG 1**

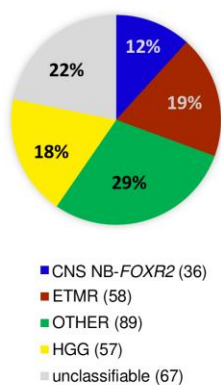
**A**

Cohort description



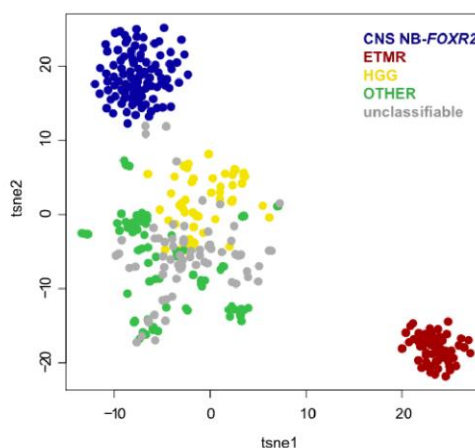
**B**

Re-evaluation cohort (n=307)



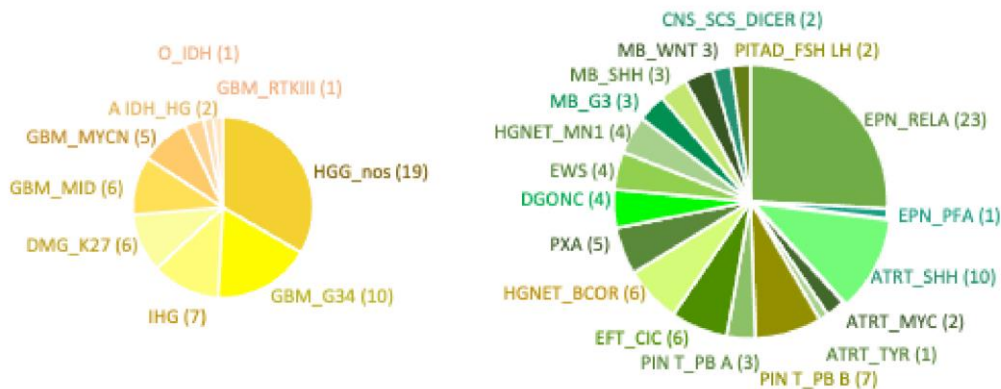
**C**

T-sne plot of DNA methylation profiles (all, n=373)

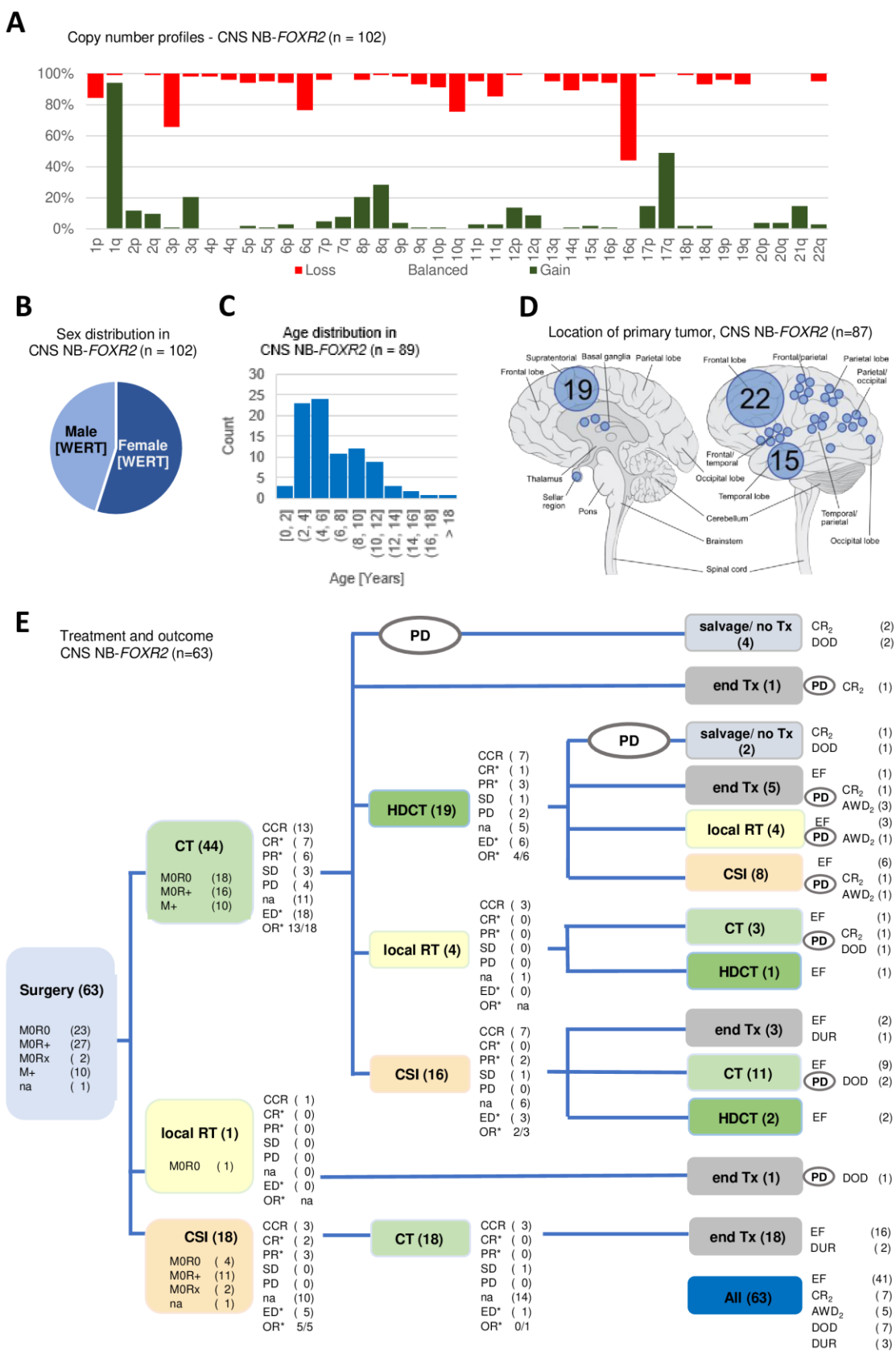


**D**

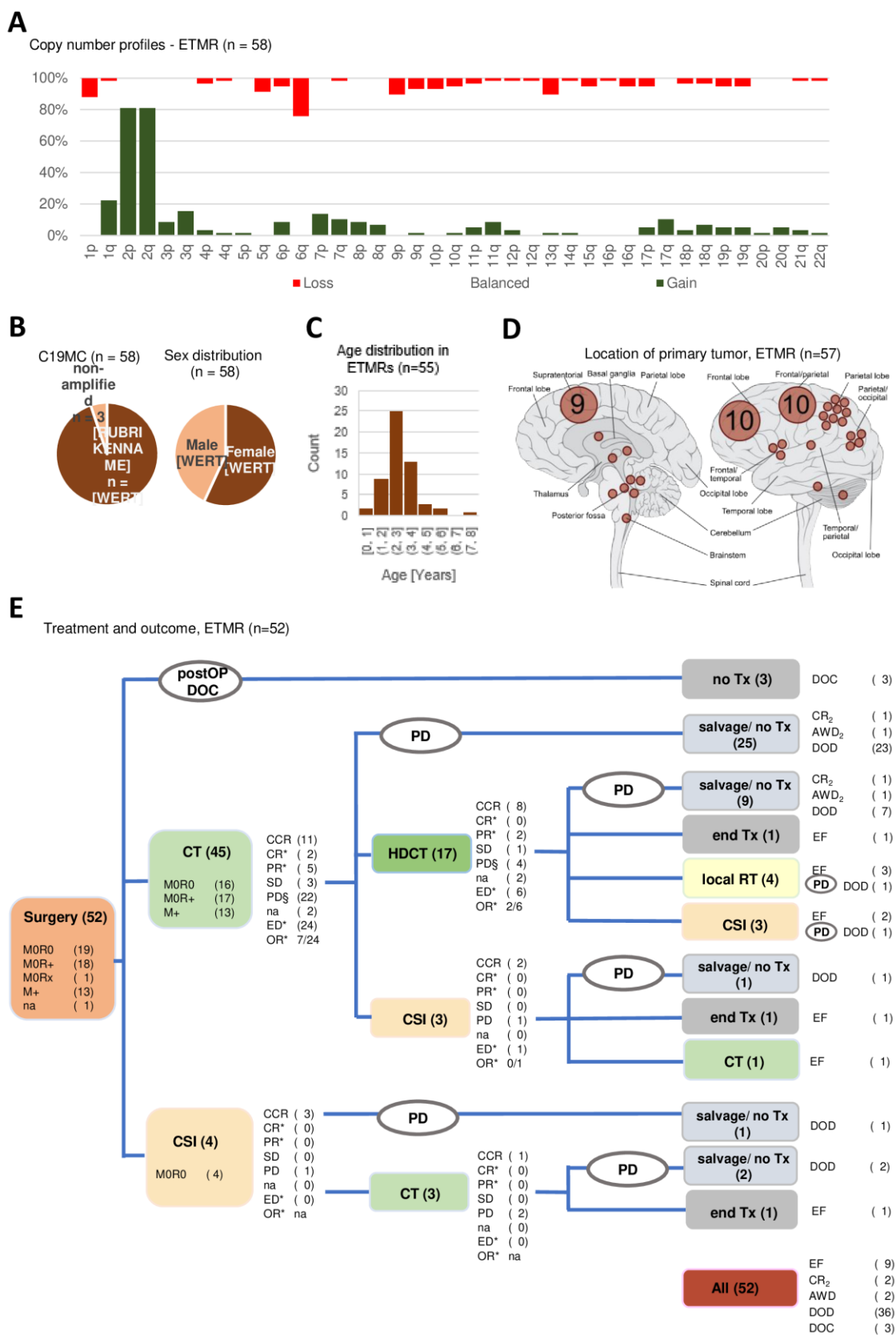
Subspecification of HGG (n=57) and OTHER tumors (n=89)



**FIG 2**



**FIG 3**



**FIG 4**

