



**HAL**  
open science

## Meningiomas in patients with long-term exposition to progestins: Characteristics and outcome

T. Graillon, S. Boissonneau, R. Appay, M. Boucekine, H. Peyrière, M. Meyer, K. Farah, F. Albarel, I. Morange, F. Castinetti, et al.

### ► To cite this version:

T. Graillon, S. Boissonneau, R. Appay, M. Boucekine, H. Peyrière, et al.. Meningiomas in patients with long-term exposition to progestins: Characteristics and outcome. *Neurochirurgie*, 2021, 10.1016/j.neuchi.2021.04.018 . hal-03253024

**HAL Id: hal-03253024**

**<https://hal.science/hal-03253024>**

Submitted on 5 Jan 2024

**HAL** is a multi-disciplinary open access archive for the deposit and dissemination of scientific research documents, whether they are published or not. The documents may come from teaching and research institutions in France or abroad, or from public or private research centers.

L'archive ouverte pluridisciplinaire **HAL**, est destinée au dépôt et à la diffusion de documents scientifiques de niveau recherche, publiés ou non, émanant des établissements d'enseignement et de recherche français ou étrangers, des laboratoires publics ou privés.



Distributed under a Creative Commons Attribution - NonCommercial 4.0 International License

## Original Article

### **Meningiomas in patients with long-term exposition to progestins: Characteristics and outcome**

### **Méningiomes associés à une exposition prolongée aux progestatifs: Caractéristiques et pronostic**

Thomas Graillon<sup>1</sup>, Sébastien Boissonneau<sup>2</sup>, Romain Appay<sup>3</sup>, Mohamed Boucekine<sup>4</sup>, Hadrien Peyrière<sup>5</sup>, Mikael Meyer<sup>5</sup>, Kaissar Farah<sup>5</sup>, Frédérique Albarel<sup>6</sup>, Isabelle Morange<sup>6</sup>, Frédéric Castinetti<sup>6</sup>, Thierry Brue<sup>6</sup>, Stéphane Fuentes<sup>5</sup>, Dominique Figarella-Branger<sup>3</sup>, Thomas Cuny<sup>6</sup>, Henry Dufour<sup>1</sup>

<sup>1</sup>Aix Marseille Univ, APHM, INSERM, MMG, Department of Neursurgery, CHU Timone, Marseille, France

<sup>2</sup>Aix-Marseille Univ, APHM, CNRS, INP, Inst Neurophysiopathol, CHU Timone, Service de Neuro-chirurgie, Marseille, France

<sup>3</sup>Aix-Marseille Univ, APHM, CNRS, INP, Inst Neurophysiopathol, CHU Timone, Service d'Anatomie Pathologique et de Neuropathologie, Marseille, France

<sup>4</sup>Aix-Marseille Univ, School of medicine - La Timone Medical Campus, EA 3279 CERESS - Health Service Research and Quality of Life Center, |27 bd Jean Moulin cedex 05, F-13385, Marseille, France

<sup>5</sup>Aix Marseille Univ, APHM, Department of Neurosurgery, Hospital La Timone, Marseille, France

<sup>6</sup>Aix Marseille Univ, APHM, INSERM, MMG, Department of Endocrinology, Hospital La Conception, Marseille, France

Corresponding authors: Thomas Graillon

Thomas.Graillon@ap-hm.fr / tom.graillon@free.fr

Phone: 0033491385545

Address: Neurosurgery department, La Timone Hospital, 264 rue Saint-Pierre, 13005 Marseille, France

Word count: 3255 w

Abstract: 250 w

44 references

3 Figures and 3 tables

**Highlights:**

Progestins are commonly prescribed in the general female population for various indications. Therefore, the occurrence of progestin associated meningiomas became a public health concern.

Recently, the French “Agence Française de Sécurité du Médicaments et des produits de Santé” (ANSM) conducted a national public health survey concluding to a strong correlation between some progestins intake and meningiomas occurrence.

The mechanism of the relationship between progestin and meningioma tumorigenesis remains unclear, but these meningiomas present specific patterns.

In this study, we described specific characteristics of these progestin associated meningiomas and also the clinical and volumetric outcome after progestin discontinuation depending on the type of progestin and the location of the tumor.

## **Abstract**

### **Objective**

The aim of this study was to describe progestin-associated meningiomas' characteristics, outcome and management.

### **Material and Methods**

We included 53 patients operated on and/or followed in the department for meningioma with progestin intake longer than one year and with recent drug discontinuation.

### **Results**

Cyproterone acetate (CPA), nomegestrol acetate (NomA), and chlormadinone acetate (ChIA) were involved in most cases. Mean duration of progestin drugs intake was 17.5 years.

Tumors were multiple in 66% of cases and were located in the anterior and the medial skull base in 71% of cases. Transitional subtype represented 16/25 tumors; 19 meningiomas were WHO grade I and 6 were grade II. The rate of transitional subtype and skull base location was significantly higher compared to matched operated meningioma general population. No difference was observed given WHO classification. But Ki67 proliferation index tends to be lower and 5/6 of the WHO grade II meningiomas were classified as WHO grade II because of brain invasion. Strong progesterone receptors expression was observed in most cases. After progestin discontinuation, a spontaneous visual recovery was observed in 6/10 patients. Under CPA (n=24) and ChIA/NomA (n=11), tumor volume decreased in 71% and 18% of patients, was stabilized in 25% and 64% of patients, and increased in 4% and 18% of patients, respectively. Volume outcome was related to meningioma location.

### **Conclusions**

Outcome at progestins discontinuation is favorable but different comparing CPA versus ChIA-NomA and comparing tumor location. Long-term follow-up is required. In most cases, simple observation is recommended and surgery should be avoided.

## **Résumé**

### **Objectif**

L'objectif de cette étude était de décrire les caractéristiques et le pronostic des méningiomes associés aux progestatifs, ainsi que leur prise en charge.

### **Matériel et méthodes**

Nous avons inclus 53 patients opérés et / ou suivis dans le service pour méningiome avec une prise de progestatif supérieure à un an et avec un arrêt récent du traitement.

### **Résultats**

L'acétate de cyprotérone (CPA), l'acétate de nomégestrol (NomA) et l'acétate de chlormadinone (ChIA) étaient impliqués dans la plupart des cas. La durée moyenne de la prise de progestatifs était de 17,5 ans. Les tumeurs étaient multiples dans 66% des cas et localisées à la base antérieure et médiale du crâne dans 71% des cas. Le sous-type transitionnel représentait 16/25 tumeurs; 19 méningiomes étaient de grade I de l'OMS et 6 de grade II. Les taux de sous-type transitionnel et de localisation de la base du crâne étaient significativement plus élevés que dans la population générale de méningiomes opérés appariés. Aucune différence n'a été observée quant au grade OMS. Mais l'indice de prolifération Ki67 tendait à être plus bas et 5/6 des méningiomes de grade II de l'OMS ont été classés au grade II en raison d'une invasion cérébrale. Une forte expression des récepteurs de la progestérone a été observée dans la plupart des cas. Après l'arrêt du traitement par progestatif, une récupération visuelle spontanée a été observée chez 6/10

patients. Sous CPA (n = 24) et ChIA / NomA (n = 11), le volume tumoral a diminué chez 71% et 18% des patients, s'est stabilisé chez 25% et 64% des patients et a augmenté chez 4% et 18% des patients, respectivement. L'évolution volumétrique était variable en fonction de la localisation tumorale.

### **Conclusions**

Le résultat à l'arrêt des progestatifs est favorable mais différent en comparant CPA versus ChIA-NomA et de la localisation tumorale. Un suivi à long terme est nécessaire. Dans la plupart des cas, une surveillance est recommandée et la chirurgie peut être évitée.

Running title: Progestin-associated meningiomas

Key words: meningioma, progestin, progesterone receptor, cyproterone acetate, chlormadinone acetate, nomegestrol acetate

Mots-Clés: méningiome; progestatif; récepteur à la progesterone; acétate de cyprotérone; acétate de chlormadinone ; acétate de nomegestrol

This research did not receive any specific grant from funding agencies in the public, commercial, or not-for-profit sectors.

Conflict of Interest: none

Ethics approval: The study was approved by the "College de Neurochirurgie IRB #1" n°

IRB00011687: 2020/12.

## **Introduction**

For many years, progestin drugs have been suspected to cause meningioma arising and proliferation. Either different studies were performed or clinical cases reported with discordant conclusions<sup>1-9</sup>. The French national agency Agence Nationale de Sécurité du Médicament et des Produits de Santé (ANSM) recently conducted an epidemiological study concluding that an increase in the risk of meningioma in patients treated by cyproterone acetate (CPA) can occur, especially if they were treated for a long duration and/or with high doses<sup>10</sup>. These conclusions led French endocrinologists to better inform their patients and to reconsider indication of progestin treatment, particularly for CPA. The aim of this study was to describe a clinical series of progestin-associated meningiomas (characteristics and outcome) and then to highlight short- and long-term management.

## **Material and Methods**

### ***Patients***

This is a monocenter study including patients operated and/or followed in the department of neurosurgery for meningioma with progestin intake  $\geq 1$  year and with recent drug discontinuation. For nonoperated patients, a follow-up  $\geq 1$  year after progestin drugs discontinuation was requested. Drugs intake duration, type of progestin and posology were collected. Clinical symptoms and particularly visual examination were also collected. An informed consent was obtained from each patient after full explanation of the purpose and nature of all procedures used. The study was approved by the "College de Neurochirurgie" IRB#1" n° IRB00011687: 2020/12.

### ***Neuropathology***

Patients operated on for meningioma with a progestin intake  $\geq 1$  year were included for neuropathological analyses. Hematoxylin and eosin staining was performed for pathological examination and grading according to the WHO 2016 classification of tumors of the central nervous system. Immunohistochemical staining for estrogen receptor (ER, clone SP1, Roche), progesterone receptor (PR, clone 1/E2, Roche), and Ki67 (clone Mib1, Dako) were performed on 3.5  $\mu\text{m}$  thick, formalin-fixed, paraffin-embedded tissue sections. For ER and PR, the immunostained sections were scored for both the intensity and the percentage of immunoreactive cells within the tumor. The proliferative index was evaluated using Ki67 antibody and scored as percentage by counting the immunostained nuclei of 400 cells in the most positive area.

### ***MR Imaging***

Meningioma volumetric analysis was performed on initial magnetic resonance imaging (MRI) as on different MRI during the follow-up using 3D T1-weighted with gadolinium enhancement with millimetric sequences and Iplannet software, Brain Lab. Tumor volume was classified as decrease, stable, or increase after drugs discontinuation for each patient. Volume decrease and increase were defined by a  $\pm 10\%$  modification from the baseline volume, respectively.

### ***Visual assessment***

Patients with supra or parasellar meningiomas underwent a visual acuity and a visual field assessment at diagnosis then 3 months later then every year.

### ***Biostatistical Analysis***

Within this population, a matched sample was identified, consisting of 19 cases matched each one with 2 controls (38 controls). Cases and controls were matched for sex (exact



match), and age (within 3 years). Controls were extracted from the neurosurgery department operated meningiomas database and were untitled "general meningioma population". Control tumors were operated during the same period; cases with progestin intake were excluded. Patients were matched using the %match SAS macro<sup>11</sup> which implements the optimal matching algorithm. Conditional logistic regression was used to estimate the odds ratio (OR) with 95% confidence interval for an association between the "progestin associated meningiomas" and risk factors (WHO grade, subtype, Ki67 and skull base location). A two-sided p-value <0.05 was considered to indicate statistical significance. All statistical analyses were conducted using SAS 9.4 software and StataCorp. 2019. *Stata Statistical Software: Release 16*. College Station, TX: StataCorp LLC. Volume data were compared using nonparametric t-test. For per tumor statistical analyses, results are based on two-sided tests with significance level ,05.

## **Results**

### ***Patient Characteristics***

Fifty-three patients (including 51 women, one Turner syndrome and one male-to-female transgender) with diagnosis of meningioma recently discontinued the progestin treatment after an intake exceeding 1 year (Figure 1.A). These 53 patients were retrospectively or prospectively collected in our database. Thirty-seven patients were retained for the follow-up observational study requiring a follow-up  $\geq 1$  year after drugs intake discontinuation and available MRIs during this observational period. Twenty patients were retained for the neuropathological analysis. Among these 20 patients, 4 patients had multiple meningiomas ( $\geq 2$  tumors) and were operated for  $\geq 1$  meningiomas and subsequently followed for  $\geq 1$

other nonoperated meningiomas. The mean age of our cohort was  $55 \pm 20$  years old. Different types of progestin drugs were involved (Figure 1.B). CPA was used in 70% of our patients. Each patient was exposed to high doses of CPA ( $\geq 60g$ ) in this cohort. Nomegestrol acetate (NomA) and chlormadinone acetate (ChIA) were involved in 17% and 5.5 % of cases, respectively, at high doses (dose of 5mg for NomA and 10mg for ChIA, with a treatment duration  $\geq 8$  years). The remaining 7.5% included progesterone and various types of progestin drugs as promegestone or dydrogesterone. Indications of progestin administration are reported in Table 1. The mean duration of progestin administration was 17.5 years (6-37 years).

Among the 53 patients, a total of 20 patients were operated on in our department: 19 for tumor removal (with 25 analyzed tumors) and one patient for ventriculoperitoneal shunt implantation. Surgical indications were severe initial visual loss or lack of visual improvement at 3 months after progestin discontinuation in 12 cases, intracranial hypertension in 6 cases, benign intracranial hypertension and superior sagittal sinus stenosis with ventriculoperitoneal shunt in one case, and severe frontal syndrome in one case. One patient with anterior clinoid meningioma was treated by radiotherapy for the growth of a postoperative residue (Patient 4).

Tumors were multiple ( $\geq 2$ ) in 66% of cases and were located either in the anterior or in the medial skull base in 71% of cases but could also be located in the convexity or in the parasagittal area (Figure 2). Biostatistical analyses on operated patients using 1/2 pairing with age and sex highlighted a significant higher rate of skull base meningiomas in the progestin meningiomas population compared to general matched population (OR=3.98 ; IC95%[1.32-12.03],  $p=0.014$ ).

## ***Neuropathology***

Neuropathological analysis included 25 tumors from 19 patients (Table 2). Nineteen meningiomas were WHO grade I and six were WHO grade II because of brain invasion in 5/6 cases. Using biostatistical 1/2 pairing analyses based on age and sex, no difference was observed considering WHO grades comparing progesterin-associated meningioma population and matched population (OR=1 [0.3-3.45] p=0.99). Median Ki67 proliferation index was 3% (1-15%). On pairing analyses, Ki67 tends to be lower in the progesterin-associated meningiomas population OR=0.83 [0.68-1.01] p=0.067. Transitional subtype represented 16/25 tumors, fibrous 5/25, and meningothelial 4/25. In 4 patients with multiple analyzed meningiomas, transitional subtype was observed in 9/10 cases. On pairing analyses, we observed a significant higher ratio of transitional/meningothelial subtype in the progesterin-associated meningiomas population compared to general matched population: OR=8.7 [1.21-50.4] p=0.015. Both progesterone (PR) and estrogen (ER) receptors expression was analyzed in the 25 tumor specimen with a strong expression of PR as compared to ER (Table 2). No correlation was found between tumor location (skull base or non-skull base) and PR expression: PR expression was mostly strong even in non-skull base progesterin associated meningiomas. In 5 cases, PR expression and/or intensity were lower: 4 among in these 5 cases were fibrous subtypes. Describing these 5 cases, patient 8 harbored a Turner syndrome with long-term progesterone replacement (progesterone and dydrogesterone) at physiological doses. In patients 4 and 16, meningiomas were still growing despite progesterin

discontinuation. In patient 14, the patient was treated by dydrogesterone. Patient 12 underwent pancerebral radiotherapy in the childhood and then a long-term treatment by CPA. Receptors expression pattern highlights low expression of progesterone receptors. Subtype was fibrous atypical with proliferation index at 15%. This patient harbored a second meningioma which was followed up and presented long-term volume decrease after CPA discontinuation.

### ***Outcome after Drugs Discontinuation***

The mean follow-up of the 37 patients with analyzable tumors was 3 years (1 to 10 years). Among the 19 patients with tumor removal, only one patient presented a persistent growth of the postoperative residue. No case of recurrence after gross total removal was observed. Considering the 37 patients with different progestins, a decrease, a stabilization, and an increase in tumor volume were observed in respectively 54% (20/37), 38% (14/37), and 8% (3/37) of patients. Among 10 patients with preoperative moderate visual trouble, a spontaneous visual recovery was observed in 6 cases while the absence of recovery in the remaining cases prompted surgery. No obvious difference regarding MR features or initial visual impairment was observed comparing patients with or without visual recovery after drugs discontinuation. We also did not observed any obvious difference comparing PR expression from tumors operated immediately after progestin discontinuation versus tumors operated 3 months after progestin discontinuation. We analyzed the global tumor volume (GTV) in different subgroups of patients at the last follow-up. In the group of patients treated with CPA (n=24), GTV decreased, remained stable, and increased in respectively 71%, 25%, and 4% of patients. In the ChIA/NomA group (n=11), GTV decreased, remained stable, and increased in respectively 18%, 64%, and 18% of patients. One patient

was considered as stable after progesterone discontinuation and another one presented a decrease in volume after promegestone discontinuation (68% of the initial volume at 2 years). Regarding tumors separately, volume decrease after progestin discontinuation was significantly higher with CPA compared to ChIA and NomA at 3, 6, 12, and 36 months (Figure 3). Interestingly, all the 4 patients with symptomatic meningioma under ChIA or NomA (2 cases of trigeminal neuralgia and 2 cases of visual disturbance) were clinically improved after drug discontinuation despite tumor volume stabilization and absence of edema on the MRI. Then, we analyzed the volume outcome after drug discontinuation depending on progestin and tumor location in 72 meningiomas (Table 3). Volume outcome of anterior skull base meningiomas tends to be better for meningiomas associated with CPA versus ChIA-NomA. No obvious difference was observed for volume outcome of medial skull base tumors comparing CPA and ChIA-NomA intake. In contrast, in non-skull base location, volume outcome was better after CPA discontinuation than after ChIA-NomA discontinuation. Considering only meningiomas after CPA discontinuation, volume outcome tends to be better for anterior skull base location and non-skull base location versus medial skull base location without reaching significance. In contrast, considering only meningiomas after ChIA-NomA discontinuation, no obvious difference depending on the location was observed for tumor volume outcome.

## **Discussion**

The prevalence of meningioma associated with progestin intake remains difficult to assess and is likely related to country and endocrinologists habits in progestins prescription.

Progestins are used worldwide for multiple indications. Today CPA, ChIA, and NomA are not

available for prescription in the US, whereas progestins are prescribed at high doses in France and Europe for progesterone and antiandrogen effect, for instance. Dydrogesterone and promegestone are also not available in the US. Medroxyprogesterone acetate is in contrast currently used in North America<sup>12</sup>. Megestrol acetate is also used in the US with oncological indications and similar cases of meningioma shrinkage have been reported after withdrawal of the drug<sup>13-15</sup>. For transgender male to female, worldwide prescription of high dose of progestin is common. The French agency ANSM recently analyzed in France the prevalence of meningiomas in patients operated on or treated by radiation therapy for meningioma with CPA intake and observed a 7-fold higher risk to develop a meningioma in women treated with high doses of CPA (>25mg/day) for more than 6 months and a 20-fold higher risk after 5 years of treatment (cumulated dose >60g) versus a treatment with low doses of CPA (<3g)<sup>10</sup>. Moreover, this risk is probably underestimated given the non-diagnosed cases. The same analysis is ongoing for ChIA and NomA. Similarities between CPA and ChIA-NomA associated meningiomas outcome are reported showing strong volume decrease after drugs discontinuation<sup>16-18</sup>, although we observed a significantly higher rate of volume decrease after CPA discontinuation versus ChIA and NomA discontinuation in the present study. Epidemiological study on CPA prescription led the ANSM to recommend a MRI before the initiation of the progestin therapy and an annual MRI follow-up in women after 5 years of CPA therapy. Transgender male to female patients treated with progestin are also at risk, and MRI follow-up should be considered<sup>3,19-22</sup>. Fertility therapies were also suspected to promote meningioma growth<sup>23,24</sup>. Reports of meningiomas in patients treated by progestins for prostate cancer remain rare probably related to short- and mid-term treatment<sup>1,25</sup>. In contrast, diagnoses and growth of meningiomas under LHRH agonists were

reported<sup>25-29</sup>. Meningiomas were reported to express LHRH receptors<sup>28,30,31</sup>. Relationship between meningioma and adrenal hyperplasia was also suspected<sup>32,33</sup>.

Progestin-induced meningiomas present typical features with a significantly higher rate of transitional subtype, skull base location and long-term progestin intake<sup>34,35</sup>. They are mostly multiple<sup>36</sup> and seem less aggressive than the matched meningioma population: Ki67 proliferation index tends to be lower than matched meningioma population despite the lack of significant difference of WHO grade II/WHO grade I ratio<sup>37</sup>. But this should be attenuated by the fact that 5/6 WHO grade II meningiomas were classified as WHO grade II because of brain invasion, whereas other features were in accordance with WHO grade I criteria. In contrast, WHO grade and Ki 67 were similar comparing skull base versus non-skull base operated meningiomas in the general population<sup>38</sup>.

Mechanisms underlying the development of meningioma remain unclear, more particularly the progesterone and progestin role<sup>39</sup>. Peyre *et al.* observed a higher rate of *PI3K* mutation in progestin-associated meningiomas as observed in cases of hormonal-related tumors in breast cancer or ovarian and endometrial cancer<sup>35</sup>. The specific role of CPA, ChIA, and Noma in meningioma tumorigenesis could also be suspected suggesting the term of progestin-induced meningiomas. Several arguments from this study and from the literature data, as the higher prevalence of meningioma in treated patients, the necessity of long-term duration of drugs intake at high doses, the reported dose-effect, the occurrence in male to female transgender patient in Europe, the frequent skull base location, the rarity of spinal location, the frequent multiple locations, the predominance of transitional subtype, the specific mutational landscape with *PI3K* mutation high rate and *NF2* mutation low rate, and the redundant profile of high progesterone receptor expression and low estrogen receptor expression support the hypothesis of progestin involvement in meningioma tumorigenesis

<sup>6,19-22,34,35</sup>. CPA, ChIA, and NomA were suspected by their both antiandrogenic and antiestrogenic effects to decrease the negative feedback on GnRH and LHRH hypothalamic secretion and to increase plasmatic level of GnRH and LHRH <sup>40</sup>. Meningiomas were demonstrated to express GnRH and LHRH receptors <sup>18,40</sup>. GnRH and LHRH agonists were also demonstrated to stimulate meningioma growth <sup>25-29</sup>. Patient 12 was particularly interesting given that the removed meningioma presented many features of radiation-induced meningioma (fibrous atypical WHO grade II meningioma with high proliferation index and lower progesterone receptor expression). The patient underwent a childhood radiation therapy. But a second location which was nonoperated on dramatically shrank after CPA discontinuation suggesting a double tumorigenesis mechanism in this patient.

A more simple mechanism of hyperstimulation or vascular turgescence on a preexisting meningioma could also be involved as observed on meningiomas during pregnancy <sup>41-44</sup>. This mechanism could be observed with progesterone and various progestin drugs with a shorter period of progestin exposure. Tumor volume decrease or stabilization in a growing meningioma and/or an objective clinical improvement, particularly visual, after drugs discontinuation, strongly suggests the relationship between the tumor and the progestin intake leading to proposing the definition of progestin-stimulated meningiomas.

In our cohort, we observed different volume outcome after drug discontinuation depending on the type of progestin (CPA vs. ChIA and NomA) and the location (anterior and medial skull base and non-skull base). For ChIA- and NomA-related meningiomas, we observed in most cases, tumor volume stabilization whatever the tumor location. Tumor volume decrease was less frequent than after CPA discontinuation <sup>34</sup>. This suggests the hypothesis that meningioma driver genomic mechanisms could vary depending on the progestin. In contrast,



in our cohort, despite limited data, progesterone and dydrogesterone do not seem to be strongly involved in progestin-induced meningiomas: two neuropathological cases highlight fibrous subtype and different receptor expression pattern (patients 8 and 14).

Based on the results of the present study and multiple reported cases, the medical management requires firstly, to discontinue the progestin drug. In non-symptomatic meningiomas, a simple observation should therefore be set up <sup>1-3,5,16,18</sup>. In symptomatic meningiomas, the symptoms severity should be tightly assessed. Malaize *et al.* highlighted French neurosurgeons change in the management of such tumors with an increase in conservative management over time <sup>45</sup>. In the present series, spontaneous normalization of visual examination after progestin discontinuation was observed in 6/10 cases of parasellar or suprasellar meningiomas. Given this spontaneous favorable visual outcome after progestin discontinuation in most cases, the presence of a moderate visual disturbance with mainly visual field impairment should lead to set up a simple observation with visual reassessment 3 months later. In contrast, the presence of severe visual acuity loss should lead to propose surgery with a rapid issue, but a conservative strategy could also be discussed given the poor postoperative visual outcome in case of severe preoperative visual loss <sup>46-49</sup>. Intracranial hypertension symptoms related to voluminous tumor should also lead to rapid tumor removal despite the lack of literature evidence. In most other situations, a surgery should be delayed and a tight observation set up. Based on the present series, we do recommend a long-term follow-up. In our series, the longest follow-up was approximately 10 years after progestin discontinuation without tumor regrowth, but we also observed rare cases with low and persistent tumor growth even after drugs discontinuation (8% in our series with different progestins). Therefore, despite a favorable outcome after progestin discontinuation, long-term outcome remains uncertain requiring long-term surveillance.

Cases of meningioma aggressive transformation many years after progestin discontinuation are not clearly reported today but could not be excluded. One of the remaining questions is the involvement in meningioma tumorigenesis of low doses of progestin as applied in contraceptive pills. In the present study, no case of meningioma associated with contraceptive pills is reported. We suggest that complete progestin discontinuation would be preferable in patients bearing a meningioma, and microprogestative pills should be probably avoided or assessed with a thigh surveillance<sup>50</sup>.

### **Study limitations**

Despite the large number of patients compared to literature data, the present study remains monocentric with limited number of cases, particularly patients treated with ChIA and NomA. Conclusions about different patient outcome after drug discontinuation comparing CPA and ChIA-NomA require to be confirmed in larger series. Moreover, a longer period of volumetric assessment after drug discontinuation will provide stronger conclusions.

### **Conclusion**

Progestin-associated meningiomas are mostly multiple, with high progesterone receptor expression and present a significantly higher rate of transitional subtype and skull base location compared to general matched meningioma population. No difference was observed with general matched population given WHO classification. But Ki67 proliferation index

tends to be lower and most of the WHO grade II meningiomas were classified as WHO grade II because of brain invasion. Outcome was favorable at progestin discontinuation but with different patterns depending on the location and the progestin: mostly decrease in volume for CPA, mostly volume stabilization for ChIA-NomA. Progestin drugs intake impacts meningioma therapeutic management and should therefore be investigated in each woman harboring a meningioma as in male to female transgender. In case of meningioma diagnosis, progestin drug discontinuation is required. Severe visual disturbance or the lack of improvement after progestin discontinuation and intracranial hypertension required surgery in a short delay. In contrast, in remaining cases, simple observation is required. Long-term follow-up is required.

## References

1. Shimizu J, Matsumoto M, Yamazaki E, Yasue M. Spontaneous regression of an asymptomatic meningioma associated with discontinuation of progesterone agonist administration. *Neurol Med Chir (Tokyo)*. 2008;48(5):227-230.
2. Bernat AL, Bonnin S, Labidi M, et al. Regression of Giant Olfactory Groove Meningioma and Complete Visual Acuity Recovery after Discontinuation of Cyproterone Acetate. *J Ophthalmic Vis Res*. 2018;13(3):355-358.
3. Cebula H, Pham TQ, Boyer P, Froelich S. Regression of meningiomas after discontinuation of cyproterone acetate in a transsexual patient. *Acta Neurochir (Wien)*. 2010;152(11):1955-1956.
4. Jhawar BS, Fuchs CS, Colditz GA, Stampfer MJ. Sex steroid hormone exposures and risk for meningioma. *J Neurosurg*. 2003;99(5):848-853.
5. Goncalves AM, Page P, Domigo V, Meder JF, Oppenheim C. Abrupt regression of a meningioma after discontinuation of cyproterone treatment. *AJNR Am J Neuroradiol*. 2010;31(8):1504-1505.
6. Gil M, Oliva B, Timoner J, Macia MA, Bryant V, de Abajo FJ. Risk of meningioma among users of high doses of cyproterone acetate as compared with the general population: evidence from a population-based cohort study. *Br J Clin Pharmacol*. 2011;72(6):965-968.
7. Claus EB, Calvo Coressi L, Bondy ML, Wrensch M, Wiemels JL, Schildkraut JM. Exogenous hormone use, reproductive factors, and risk of intracranial meningioma in females. *J Neurosurg*. 2013;118(3):649-656.

8. Cea-Soriano L, Blenk T, Wallander MA, Rodriguez LA. Hormonal therapies and meningioma: is there a link? *Cancer Epidemiol.* 2012;36(2):198-205.
9. Botella C, Coll G, Lemaire JJ, Irthum B. [Intra cranial meningiomas and long term use of cyproterone acetate with a conventional dose in women. A report of two cases of tumor decrease after treatment withdrawal]. *Neurochirurgie.* 2015;61(5):339-342.
10. Champeaux-Depond C, Weller J, Froelich S, Sartor A. Cyproterone acetate and meningioma: a nationwide-wide population based study. *J Neurooncol.* 2021;151(2):331-338.
11. Bergstrahl EJ KJ. Computerized matching of controls *Rochester, MN: Department of Health Science Research, Mayo Clinic; Technical Report Series No 56* 1995.
12. Hensiek AE, Kellerman AJ, Hill JT. Spontaneous regression of a solitary cerebral metastases in renal carcinoma followed by meningioma development under medroxyprogesterone acetate therapy. *Br J Neurosurg.* 2000;14(4):354-356.
13. Gruber T, Dare AO, Balos LL, Lele S, Fenstermaker RA. Multiple meningiomas arising during long-term therapy with the progesterone agonist megestrol acetate. Case report. *J Neurosurg.* 2004;100(2):328-331.
14. Gruber TJ, Fabiano AJ, Deeb G, Lele SB, Fenstermaker RA. Intracranial meningiomas in patients with uterine sarcoma treated with long-term megestrol acetate therapy. *World Neurosurg.* 2011;76(5):477 e416-420.
15. Vadivelu S, Sharer L, Schulder M. Regression of multiple intracranial meningiomas after cessation of long-term progesterone agonist therapy. *J Neurosurg.* 2010;112(5):920-924.
16. Champagne PO, Passeri T, Froelich S. Combined hormonal influence of cyproterone acetate and nomegestrol acetate on meningioma: a case report. *Acta Neurochir (Wien).* 2019;161(3):589-592.
17. Raudrant D, Rabe T. Progestogens with antiandrogenic properties. *Drugs.* 2003;63(5):463-492.
18. Passeri T, Champagne PO, Bernat AL, et al. Spontaneous regression of meningiomas after interruption of nomegestrol acetate: a series of three patients. *Acta Neurochir (Wien).* 2019;161(4):761-765.
19. Ter Wengel PV, Martin E, Gooren L, Den Heijer M, Peerdeman SM. Meningiomas in three male-to-female transgender subjects using oestrogens/progestogens and review of the literature. *Andrologia.* 2016;48(10):1130-1137.
20. Mancini I, Rotilio A, Coati I, Seracchioli R, Martelli V, Meriggiola MC. Presentation of a meningioma in a transwoman after nine years of cyproterone acetate and estradiol intake: case report and literature review. *Gynecol Endocrinol.* 2018;34(6):456-459.
21. Raj R, Korja M, Koroknay-Pal P, Niemela M. Multiple meningiomas in two male-to-female transsexual patients with hormone replacement therapy: A report of two cases and a brief literature review. *Surg Neurol Int.* 2018;9:109.
22. Gazzeri R, Galarza M, Gazzeri G. Growth of a meningioma in a transsexual patient after estrogen-progestin therapy. *N Engl J Med.* 2007;357(23):2411-2412.
23. Shahin MN, Magill ST, Dalle Ore CL, et al. Fertility treatment is associated with multiple meningiomas and younger age at diagnosis. *J Neurooncol.* 2019;143(1):137-144.
24. Frassanito P, De Bonis P, Mattogno PP, Novello M, Anile C. Hormonal therapy for fertility and huge meningioma: a purely random association? *Acta Neurol Belg.* 2012;112(3):299-301.

25. Nicosia L, Bucpapaj R, Barresi V, et al. Resected atypical meningioma relapsed to anaplastic meningioma during luteinizing hormone-releasing hormone agonist therapy. *Neurochirurgie*. 2020.
26. Lee KL, Terris MK. Luteinizing hormone-releasing hormone agonists and meningioma: a treatment dilemma. *Urology*. 2003;62(2):351.
27. Anda T, Honda M, Ishihara T, Kamei T. Progression of intracranial meningioma during luteinizing hormone-releasing hormone agonist treatment for prostate cancer: case report. *Neurol Med Chir (Tokyo)*. 2014;54(4):327-330.
28. Li Q, Coulson H, Klaassen Z, et al. Emerging association between androgen deprivation therapy and male meningioma: significant expression of luteinizing hormone-releasing hormone receptor in male meningioma. *Prostate Cancer Prostatic Dis*. 2013;16(4):387-390.
29. Tsutsui T, Miyashita K, Sabit H, et al. Acute Progression of Recurrent Meningioma during Luteinizing Hormone-Releasing Hormone Agonist Treatment for Prostate Cancer. *World Neurosurg*. 2016;91:670 e671-676.
30. Hirota Y, Tachibana O, Uchiyama N, et al. Gonadotropin-releasing hormone (GnRH) and its receptor in human meningiomas. *Clin Neurol Neurosurg*. 2009;111(2):127-133.
31. Durmaz R, Deliorman S, Isiksoy S, Uyar R, Tel E. Luteinizing hormone releasing hormone increases proliferation of meningioma cells in vitro. *Arch Physiol Biochem*. 1999;107(4):286-291.
32. Heijboer AC, Netelenbos JC, Blankenstein MA. Meningioma in untreated congenital adrenal hyperplasia: a relationship? *J Neurooncol*. 2009;92(2):223-225.
33. O'Shea T, Crowley RK, Farrell M, et al. Growth of a progesterone receptor-positive meningioma in a female patient with congenital adrenal hyperplasia. *Endocrinol Diabetes Metab Case Rep*. 2016;2016.
34. Bernat AL, Oyama K, Hamdi S, et al. Growth stabilization and regression of meningiomas after discontinuation of cyproterone acetate: a case series of 12 patients. *Acta Neurochir (Wien)*. 2015;157(10):1741-1746.
35. Peyre M, Gaillard S, de Marcellus C, et al. Progestin-associated shift of meningioma mutational landscape. *Ann Oncol*. 2018;29(3):681-686.
36. Terrier LM, Francois P. [Multiple meningiomas]. *Neurochirurgie*. 2016;62(3):128-135.
37. Roux A, Tauziède-Espariat A, Zanella M, et al. Symptomatic progestin-associated atypical grade II meningioma. A first case report. *Neurochirurgie*. 2020;66(3):174-178.
38. Kuroi Y, Matsumoto K, Shibuya M, Kasuya H. Progesterone Receptor Is Responsible for Benign Biology of Skull Base Meningioma. *World Neurosurg*. 2018;118:e918-e924.
39. Koper JW, Lamberts SW. Meningiomas, epidermal growth factor and progesterone. *Hum Reprod*. 1994;9 Suppl 1:190-194.
40. Marques P, Skorupskaite K, George JT, Anderson RA. Physiology of GnRH and Gonadotropin Secretion. 2000.
41. Kerschbaumer J, Freyschlag CF, Stockhammer G, et al. Hormone-dependent shrinkage of a sphenoid wing meningioma after pregnancy: case report. *J Neurosurg*. 2016;124(1):137-140.
42. Goldberg M, Rappaport ZH. Neurosurgical, obstetric and endocrine aspects of meningioma during pregnancy. *Isr J Med Sci*. 1987;23(7):825-828.
43. Reyes-Myrna C, Torres-Hernandez CM, Herrera-Ortiz A, Figueroa-Angel V. [Intracranial meningioma in pregnancy. Case report and literature review]. *Ginecol Obstet Mex*. 2016;84(1):46-52.

44. Gurcay AG, Bozkurt I, Senturk S, et al. Diagnosis, Treatment, and Management Strategy of Meningioma during Pregnancy. *Asian J Neurosurg.* 2018;13(1):86-89.
45. Malaize H, Samoyeau T, Zanello M, et al. Evolution of the neurosurgical management of progestin-associated meningiomas: a 23-year single-center experience. *J Neurooncol.* 2021.
46. Galal A, Faisal A, Al-Werdany M, El Shehaby A, Lotfy T, Moharram H. Determinants of postoperative visual recovery in suprasellar meningiomas. *Acta Neurochir (Wien).* 2010;152(1):69-77.
47. Wang CW, Li YY, Zhu SG, et al. Surgical management and evaluation of prognostic factors influencing postoperative visual outcome of suprasellar meningiomas. *World Neurosurg.* 2011;75(2):294-302.
48. Rosenstein J, Symon L. Surgical management of suprasellar meningioma. Part 2: Prognosis for visual function following craniotomy. *J Neurosurg.* 1984;61(4):642-648.
49. Giammattei L, Starnoni D, Levivier M, Messerer M, Daniel RT. Surgery for Clinoidal Meningiomas: Case Series and Meta-Analysis of Outcomes and Complications. *World Neurosurg.* 2019;129:e700-e717.
50. Claus EB, Black PM, Bondy ML, et al. Exogenous hormone use and meningioma risk: what do we tell our patients? *Cancer.* 2007;110(3):471-476.

## Figure Legends

Fig. 1: A: Study flow chart

\*Patients with multiple progestin-associated meningiomas: some meningiomas have been operated on and others were observed.

B: Distribution of progestin involved in the present series.

Cyproterone acetate (CPA), nomegestrol acetate (NomA), and chlormadinone acetate (ChIA).

Fig. 2: Location of progestin-associated meningiomas.

Fig. 3: Volume outcome at 3 months, 6 months, 1 year, and 2-3 years after progestin discontinuation. Results are expressed in % of initial volume.

\*\*  $p \leq 0.01$ ; \*\*\*  $p \leq 0.001$ .

CPA: cyproterone acetate, NomA: nomegestrol acetate, and ChIA: chlormadinone acetate.

**Table legends:**

Table 1: Indications of progestin drugs prescription in the present French series.

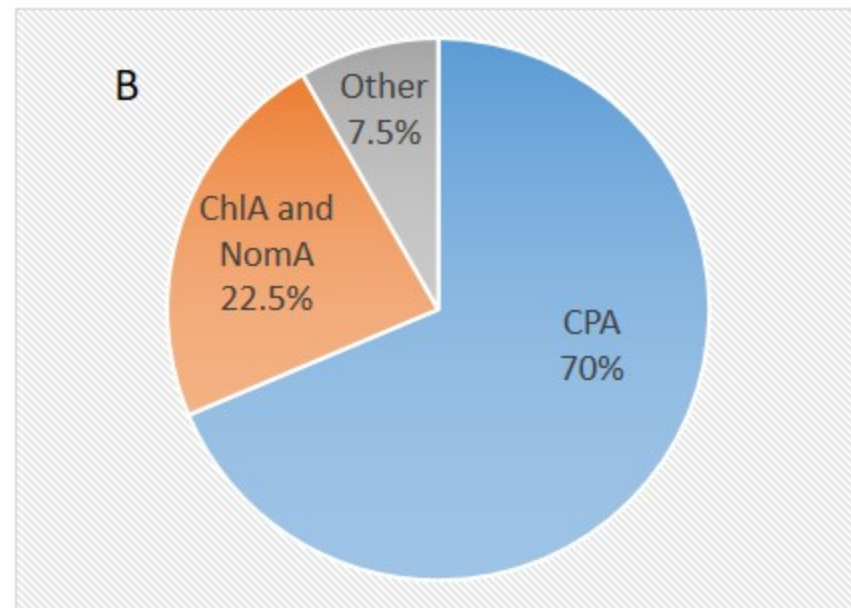
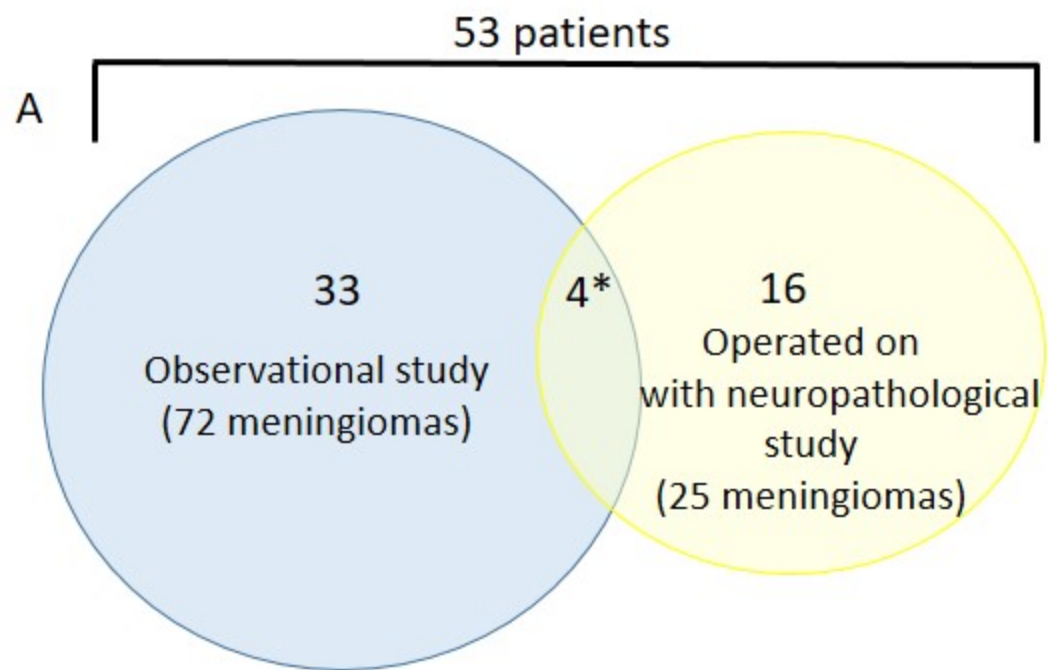
Table 2: Neuropathological features, tumor location: skull base (Sk Base) or non skull base (Non Sk Base), and quality of resection (Simpson grade).

Cyproterone of acetate: CPA; Nomegestrol Acetate: NomA; Dydrogest: Dydrogesterone;

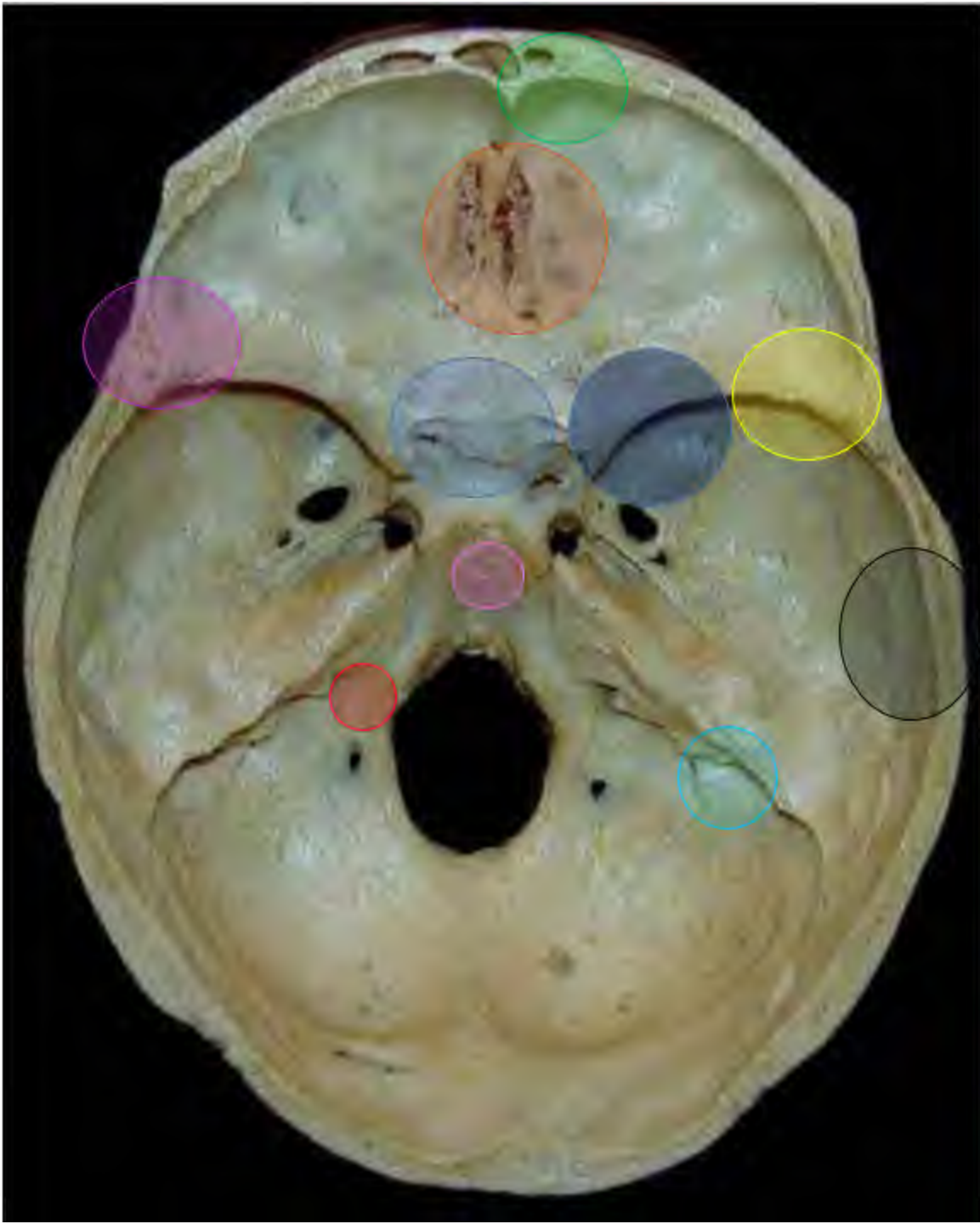Prog: Progesterone.

Table 3: Volume assessment per tumor per location after progestin discontinuation.

CPA: cyproterone acetate, NomA: nomegestrol acetate, and ChIA: chlormadinone acetate.







# Tumor Location

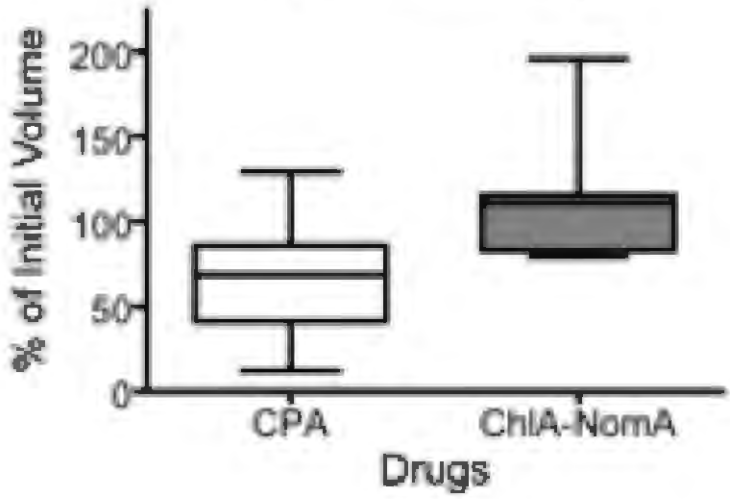
Cavernous Sinus Anterior Clinoid Sphenoid small wing	15%
Temporobasal Pterional	13%
Sphenorbital	9%
Planum, Tuberculum, Diaphragm sellae	14%
Anterior Skull base	20%
Convexity	16%
Parasagittal	6%
Tentorium	4%
Petroclival	2%
Ponto-cerebellar angle	1%

Ant-Med  
Sk Base  
71%

Delay after progestin discontinuation

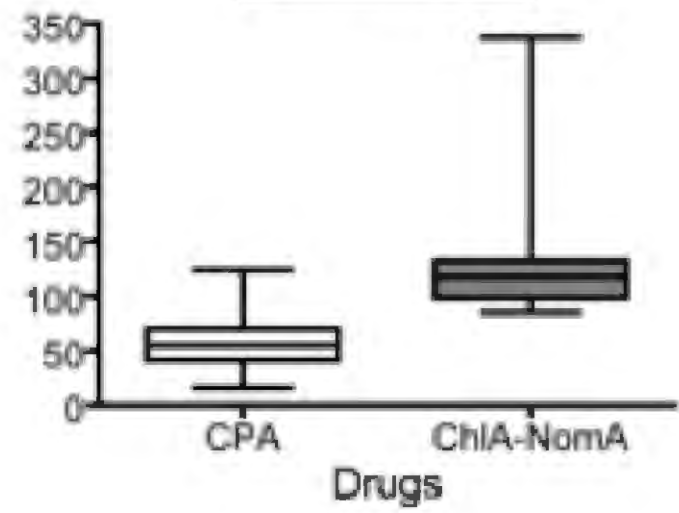
6 months

\*\*\*



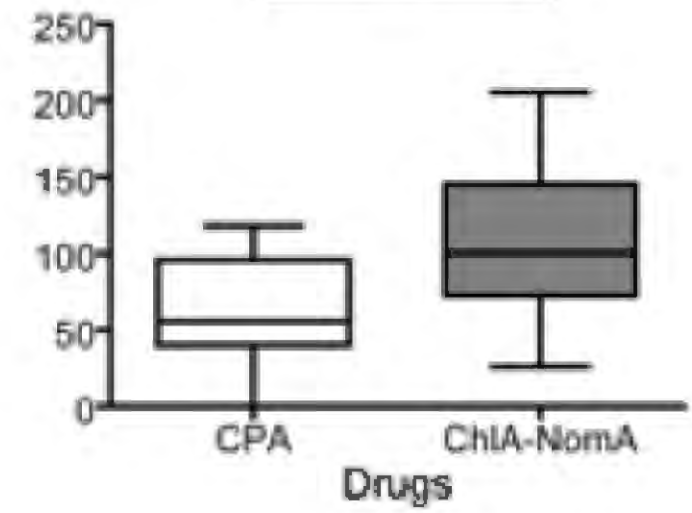
1 year

\*\*\*



2-3 years

\*\*



<b>Progestin indications of prescription</b>	<b>%</b>
Hyperpilosity	21%
Endometriosis	19%
Menopause and hormonal replacement	14%
Uterin fibroma	7%
Contraception	7%
Mammary mastosis and cyst	7%
Acne	5%
Alopecia	5%
Dysmenorrhea	5%
Ovarian cyst	5%
Transgender	3%

Patients	Progestin	Location	WHO Grade	Sub-type	Ki67 max	Necrosis	Cerebral invasion	Mitosis /1,6mm <sup>2</sup>	Total PR (% of positive cells)	PR intensity	Total ER (% of positive cell)	Tumor singularities	Simpson grade
1	CPA	Sk B	I	Transitional	8%	0	0	2	95	95	0		2
2	CPA	Sk B	II	Transitional	4%	0	1	1	100	100	0		2
3		Sk B	I	Transitional	5%	0	0	2	100	100	0		2
4	CPA	Sk B	I	Transitional	3%	0	0	1	70	10	0	Residue regrowth	4
5	CPA	Sk B	I	Transitional	3%	0	0	1	100	100	0		2
		Non Sk B	I	Transitional	3%	0	0	1	100	100	0		1
		Non Sk B	I	Transitional	3%	0	0	1	100	100	0		1
		Sk B	I	Transitional	5%	0	0	1	100	100	0		2
6	CPA	Sk B	I	Transitional	1%	0	0	1	100	100	0		2
		Non Sk B	I	Transitional	2%	0	0	1	100	100	0		1
7	CPA	Sk B	II	Transitional	2%	0	1	2	100	100	0		2
		Non Sk B	II	Transitional	2%	0	1	1	100	100	0		1
8	Prog and Dydrogest	Non Sk B	I	Fibrous	3%	0	0	1	60	40	0	Turner syndrome	2
9	CPA	Sk B	I	Transitional	5%	0	0	1	100	100	10		2
10	CPA	Sk B	II	Meningothelial	5%	0	1	1	100	100	0		2
11	CPA	Sk B	I	Meningothelial	1%	0	0	1	100	100	0		3
12	CPA	Non Sk B	II	Atypical	15%	0	0	2	30	30	0	Radiation therapy in childhood	1
13	NomA	Sk B	I	Meningothelial	5%	0	0	3	100	100	0		4
14	Dydrogest	Non Sk B	I	Fibrous	3%	0	0	1	1	1	0		2
15	CPA	Sk B	I	Transitional	3%	0	0	1	100	100	1		2
16	CPA	Non Sk B	I	Fibrous	10%	1	0	1	10	10	0	One growing lesion in multiple meningiomas	2
17	CPA	Sk B	I	Meningothelial	3%	0	0	1	100	100	0		2
18	CPA	Sk B	II	Transitional	2%	0	1	1	100	100	0		2
19	CPA	Non Sk B	I	Fibrous	1%	0	0	1	90	100	0		2
		Sk B	I	Transitional	2%	0	0	1	100	100	0		2

Volume Assessment	CPA		ChIA-NomA		p
	%	n	%	n	
<b><i>Anterior Skull Base</i></b>					
Decrease	70	7	43	3	0.28
Stabilization	30	3	28.5	2	0.94
Increase	0	0	28.5	2	0.0813
<b><i>Medial Skull Base</i></b>					
Decrease	54	13	50	4	0.8468
Stabilization	33.5	8	25	2	0.6588
Increase	12.5	3	25	2	0.4065
<b><i>Skull Base (Anterior and Medial Skull Base)</i></b>					
Decrease	59	20	47	7	0.4409
Stabilization	32	11	26.5	4	0.7024
Increase	9	3	26.5	4	0.111
<b><i>Other (Convexity, Parasagittal, Posterior fossa...)</i></b>					
Decrease	77.5	14	20	1	<b>0.0197</b>
Stabilization	16.5	3	60	3	0.0735
Increase	5.5	1	20	1	0.3485
<b><i>Total</i></b>					
Decrease	65.5	34	40	8	0.0509
Stabilization	27	14	35	7	0.5068
Increase	7.5	4	25	5	<b>0.0448</b>

Table 3: Volume assessment per tumor per location after progestin discontinuation.

CPA: cyproterone acetate, NomA: nomegestrol acetate, and ChIA: chlormadinone acetate.