



HAL
open science

Ultrasound-assisted treatment of an inoperable pancreatic cancer

Georg Dimcevski, Spiros Kotopoulos, Dag Hoem, Michiel Postema, Bjørn Tore Gjertsen, Tormod Bjånes, Martin Biermann, Emmet Mc Cormack, Halfdan Sørbye, Anders Molven, et al.

► **To cite this version:**

Georg Dimcevski, Spiros Kotopoulos, Dag Hoem, Michiel Postema, Bjørn Tore Gjertsen, et al.. Ultrasound-assisted treatment of an inoperable pancreatic cancer. MedViz Conference 2013, MedViz; Haukeland University Hospital; University of Bergen; Christian Michelsen Research, Jan 2013, Bergen, Norway. pp.49-52. hal-03245676

HAL Id: hal-03245676

<https://hal.science/hal-03245676>

Submitted on 1 Jun 2021

HAL is a multi-disciplinary open access archive for the deposit and dissemination of scientific research documents, whether they are published or not. The documents may come from teaching and research institutions in France or abroad, or from public or private research centers.

L'archive ouverte pluridisciplinaire **HAL**, est destinée au dépôt et à la diffusion de documents scientifiques de niveau recherche, publiés ou non, émanant des établissements d'enseignement et de recherche français ou étrangers, des laboratoires publics ou privés.

MedViz Conference 2013

Ultrasound-assisted treatment of on inoperable pancreatic cancer

Georg Dimcevski^{1,2,3}, Spiros Kotopoulos^{2,3,5}, Dag Hoem^{3,4}, Michiel Postema⁵, Bjørn Tore Gjertsen^{3,11}, Tormod Bjånes¹⁰, Martin Biermann^{6,7}, Emmet McCormack³, Halfdan Sørbye⁸, Anders Molven⁹, Odd Helge Gilja^{2,3}.

¹Department of Medicine, Haukeland University Hospital, Bergen, ²National Centre for Ultrasound in Gastroenterology, Department of Medicine, Haukeland University Hospital, Bergen, ³Institute of Medicine, University of Bergen, Bergen, ⁴Department of Surgery, Haukeland University Hospital, Bergen, ⁵Department of Physics and Technology, University of Bergen, Bergen, ⁶NM/PET-senter, Department of Radiology, Haukeland University Hospital, Bergen, ⁷Department of Surgical Sciences, University of Bergen, Bergen, ⁸Department of Oncology, Haukeland University Hospital, Bergen, ⁹Section of Pathology, The Gade Institute, University of Bergen, ¹⁰Section of Clinical Pharmacology, Laboratory of Clinical Biochemistry, Haukeland University Hospital, Bergen, ¹¹Clinical Trial Unit for Adults, Department for Research and Development, Haukeland University Hospital

Despite the wide array of treatment options, cancer still is a frequent debilitating disease, with increasing incidence and prevalence worldwide. This is especially true for pancreatic cancer which is the cause of death of 600-650 patients in Norway annually. Adenocarcinoma of the pancreas remains one of the most lethal human cancers. Incidence and mortality rate have been stable for the last four decades. At the time tumours are detected, forty percent of the pancreatic cancers are locally advanced tumours, whereas another forty percent are disseminated tumours. These are considered inoperable. The odds are against curing pancreatic cancer, since surgery is unfeasible due to encasement of large blood vessels and/or the presence of metastases. Chemotherapy produces objective responses but is not curative in this setting, mainly because its use is severely hampered by toxic effects in vital organs and it could be the strong desmoplastic reaction induced in this disease, prohibiting efficient delivery of chemicals to the cancer cells. As a result, the viability is very low. The mortality of the inoperable patients is 50% within 3 months and 90% within 12 months.

The nucleoside pyrimidine analogue gemcitabine is the most effective single agent in the treatment and palliation of inoperable cancer. Gemcitabine is a highly effective anti-tumour drug, but its toxic effects limit the maximum dose that can be administered. Thus, its use in high-dose chemotherapy protocols is precluded. Gemcitabine has been reported to improve clinical symptoms and extend the viability by almost 1 month.

It is necessary to develop new therapeutic tools based on novel methods. We investigate ultrasound triggered image-guided microbubble-based therapy for increasing therapeutic drug uptake in tumours.

Ultrasonic imaging is a safe, cheap and reliable diagnostic technique. In clinical ultrasound, blood cells cannot be differentiated from surrounding tissue, due to the low acoustic impedance difference between blood cells and their surroundings. Thus, contrast agents have been added to the blood pool and helps to differentiate between blood and other tissue types. Ultrasound contrast agents consist of low-solubility gas microbubbles encapsulated by a stabilising shell. With mean diameters below 6 microns, these microbubbles are small enough to pass through the lung capillaries. It has been proven by numerous groups, that the cellular uptake of drugs and genes is increased, when the region of interest is under ultrasound sonication, and even more so when ultrasounds contrast agent is present. The increased drug uptake has been attributed to the formation of transient porosities in the cell membrane, which

MedViz Conference 2013

facilitate trans-membrane transport of drugs into the cell. The transient permeabilisation (opening of holes) and resealing of a cell membrane is called sonoporation.

Ultrasound has been used for experimental delivery of therapeutic agents, including genetic material, protein and chemotherapeutic agents mixed with or even encapsulated in microbubbles. Exposure of these microbubbles to ultrasonography yields targeted delivery of therapeutics to specific anatomical locations or tumours. Our research group has demonstrated that lipid-shelled microbubbles can be forced to enter cells at low, diagnostic acoustic settings [Delalande 2011]. Combining ultrasound contrast agents with therapeutic substances may lead to a simple, straightforward and economic method to instantly increase drug uptake during ultrasonic imaging, using conventional echo machines.

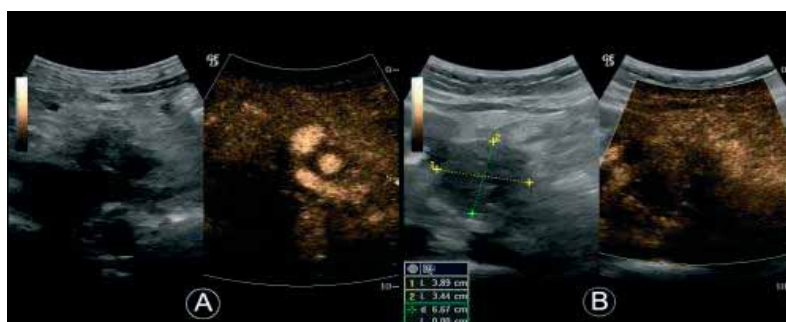

Fig. 1. Images captured in one of the first patients undergoing ultrasound sonoporation in combination with gemcitabine. The early arterial filling to the right of the main tumor can be seen in panel A (arrow). Panel B shows the dimensions of the primary hypoechoic tumor using the customized sonoporation treatment settings.

This human study is an open, single-centre, evaluation study for a new combined treatment of patients with inoperable adenocarcinoma of the pancreas. In the study, we combine gemcitabine with an existing US contrast agent (SonoVue). By simultaneous infusion, i.e. mixing of gemcitabine and contrast bubbles, ultrasound-triggered and image-guided drug delivery can be facilitated and thereby increase local drug effect.

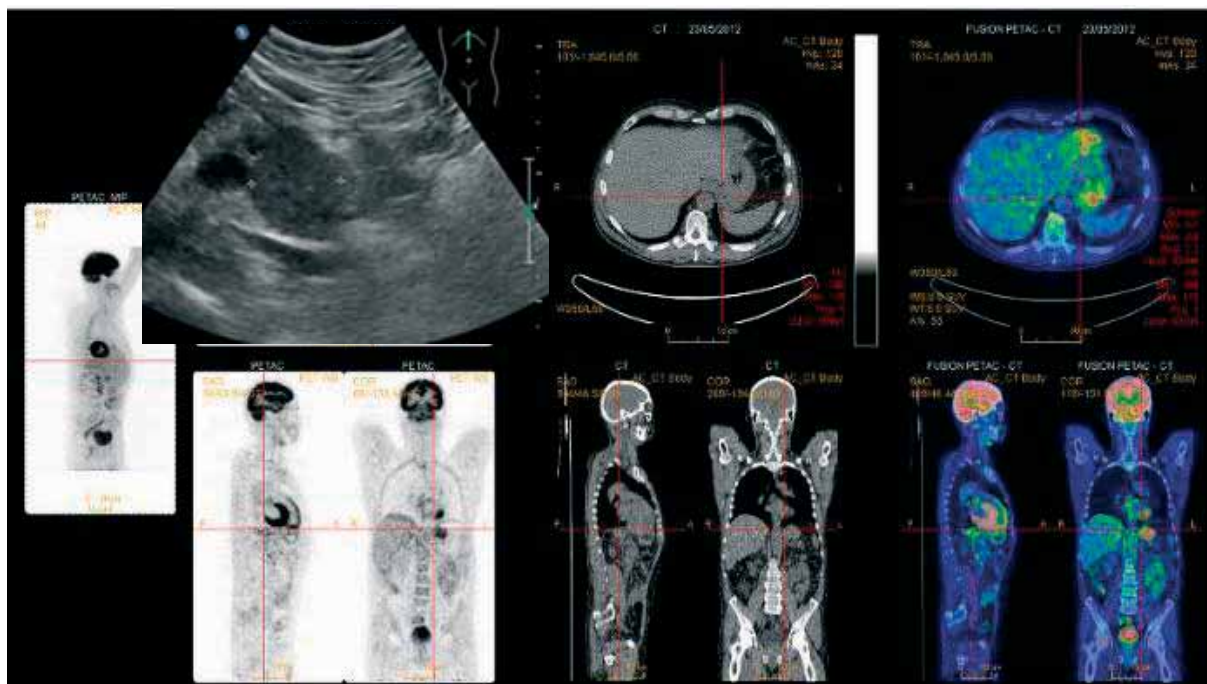


Fig 2. Multimodal imaging with ultrasound and PET-CT of pancreatic cancer in one of the patients. The ultrasound image and CT/PET scans shows the targeted tumour. To monitor our treatment, in addition to the ultrasound imaging following the gemcitabine cycles, abdominal CT will be performed every 8th week and CT/PET at study inclusion to chart possible metastasis.

MedViz Conference 2013

Patients with inoperable pancreatic cancer, who have volunteered to participate and fulfill the inclusion criteria, will be included. Patients will receive standardized treatment with the recommended dose of gemcitabine of 1000 mg/m² given as a 30 minutes intravenous infusion. At the peak gemcitabine concentration, i.e. immediately after the infusion, 4.8 ml SonoVue will be added in small bolus doses, during the sonoporation time (30 minutes). Seven cycles once a week, followed by a week's stay will be given unless unacceptable toxicity is encountered. Subsequent cycles should consist of infusions once weekly for 3 consecutive weeks out of every 4 weeks. All treatment period visits will be conducted on an outpatient basis. The treatment visits will each require the patient to remain in the clinic for approximately 3 hours. The duration of the stay in the clinic can be changed according to the individual patient's requirements.

Aims of this study are to evaluate and compare the toxic effects and safety of gemcitabine in combination with US contrast agent under sonication with gemcitabine alone. Historical data from 50 patients, collected between 2008 and 2012 at Haukeland University Hospital will be used as control group.

To date, five patients have been included. The five included patients have all received more than 11 treatments each. In total, 78 combined treatments have been conducted. No unexpected toxicity or adverse effects are registered to date.

We also recorded tumor sizes and number of conducted gemcitabine cycles. Gemcitabine treatment was conducted by an oncologist and patients were discontinued from the study according to the standard treatment protocol at our oncological department. Our five patients had 23, 16, 18, 10, 11, median 15.6 cycles. Comparing the number of treatment cycles in our patients with historical data from 83 patients who had a median of 8.4 treatment cycles, our data look promising.

Five more patients are planned to be treated by June 2013. By completing 10 patients, the primary outcome can be evaluated, and complete data including safety and patient's tolerance data can be presented.

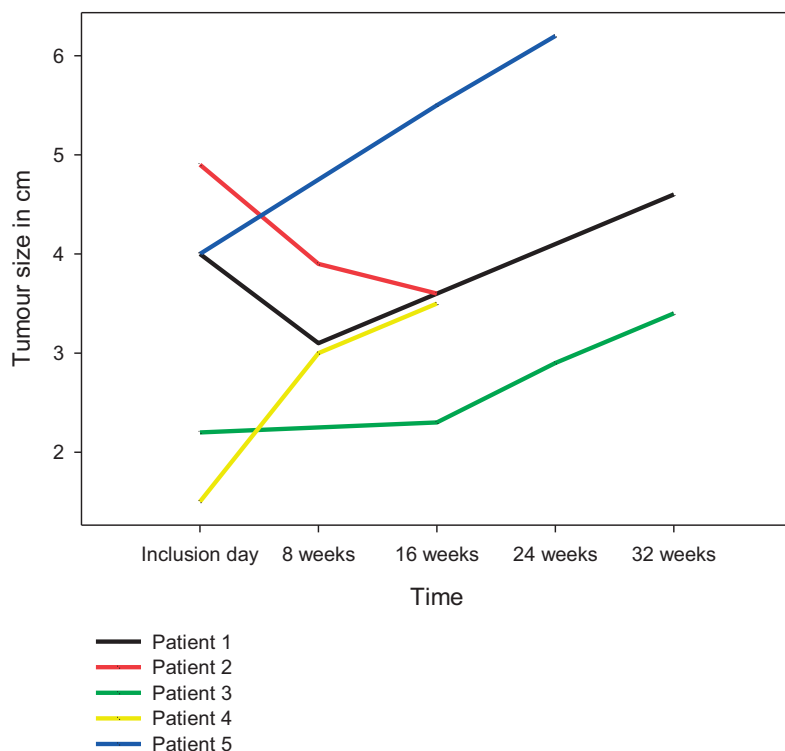


Fig. 3. CT obtained variation in tumour sizes from the inclusion day to the discontinuation due to disease progression*.

Patient nr 2 (red line) was evaluated** by the oncologist to be a god partial responder, withdrawn from the study and offered radiation therapy.

*Deterioration in the clinical state below 3 in ECOG performance status and tumour growth.

**Response Evaluation Criteria in Solid Tumors. (RECIST)

The future. Having confirmed that our combined treatment is safe, we will enroll 50 patients with inoperable pancreatic cancer (Phase II study). Our focus will then be on proving the hypothesized mechanism of action by quantifying tumor size and relate it to the survival over time. The phase I and II studies are approved by the Regional Ethics Committee. The Phase I study is also approved by the Norwegian Medicines Agency.

Progress beyond the state-of-the-art. Instead of just simultaneous administration, the ideal chemotherapeutic should be incorporated in a protective encapsulation. Developing such an agent is our long term-objective. In a forthcoming study, we intend to add on microbubbles loaded with drug (Paclitaxel) as a third therapeutic arm to our existing model.

Reference List

- Dimcevski et al (2012). Clinical sonoporation setup for the treatment of human pancreatic cancer, submitted.
- Delalande et al (2011). Sonoporation at a low mechanical index. *Bub Sci Eng Tech* 3:3.
- Postema & Gilja (2007). Ultrasound-directed drug delivery. *Curr Pharm Biotechnol* 8: 355-. • Postema M, Gilja (2011). Contrast-enhanced and targeted ultrasound. *World J Gastroenterol.* 17:28-.
- Neoptolemos JP et al. (2004). A randomized trial of chemoradiotherapy and chemotherapy after resection of pancreatic cancer. *N Engl J Med* 2004 Mar 18;350(12).

MedViz Conference 2013

Notes:

MedViz Conference 2013

Notes: