



Signal changes in enhanced T1-weighted images related to gadolinium retention: A three-time-point imaging study

François Lersy, Anne-Lise Diepenbroek, Julien Lamy, Thibault Willaume, Guillaume Bierry, François Cotton, Stéphane Kremer

► To cite this version:

François Lersy, Anne-Lise Diepenbroek, Julien Lamy, Thibault Willaume, Guillaume Bierry, et al.. Signal changes in enhanced T1-weighted images related to gadolinium retention: A three-time-point imaging study. Journal de Neuroradiologie / Journal of Neuroradiology, 2020, 10.1016/j.neurad.2020.06.002 . hal-03235724

HAL Id: hal-03235724

<https://hal.science/hal-03235724>

Submitted on 22 Mar 2023

HAL is a multi-disciplinary open access archive for the deposit and dissemination of scientific research documents, whether they are published or not. The documents may come from teaching and research institutions in France or abroad, or from public or private research centers.

L'archive ouverte pluridisciplinaire **HAL**, est destinée au dépôt et à la diffusion de documents scientifiques de niveau recherche, publiés ou non, émanant des établissements d'enseignement et de recherche français ou étrangers, des laboratoires publics ou privés.



Distributed under a Creative Commons Attribution - NonCommercial 4.0 International License

Signal changes in enhanced T1-weighted images related to gadolinium retention: a three-time-point imaging study

François LERSY*(1) (corresponding author) *francois.lersy@hotmail.fr*

Anne-Lise DIEPENBROEK*(2) *annelise.diepenbroek@gmail.com*

Julien LAMY(3) *lamy@unistra.fr*

Thibault WILLAUME(1) *thibault.willaume@chru-strasbourg.fr*

Guillaume BIERRY(1) *guillaume.bierry@chru-strasbourg.fr*

François COTTON**(4) *francois.cotton@chu-lyon.fr*

Stéphane KREMER**(1) *stephane.kremer@chru-strasbourg.fr*

(1) Service de Radiologie, Hôpitaux Universitaires de Strasbourg, Hôpital de Hautepierre, 1 Avenue Molière, 67200 Strasbourg Cedex, France

(2) Faculté de médecine de Strasbourg, Université de Strasbourg, 67000 Strasbourg, France

(3) ICube, Université de Strasbourg-CNRS, ICube - Institut de physique biologique, 4 rue Kirschleger 67000 Strasbourg

(4) Service de Radiologie, Centre Hospitalier Lyon Sud, Hospices Civils de Lyon, 69310 Pierre Bénite, France

* Both authors contributed equally to this work

** Both authors contributed equally to this work

Signal changes in enhanced T1-weighted images related to gadolinium retention: a three-time-point imaging study

Abstract

Background and Purpose

Concern has grown about the finding of gadolinium deposits in the brain after administering gadolinium-based contrast agents (GBCAs). The mechanism is unclear, and related questions remain unanswered, including the stability over time. Therefore, we conducted a three-time-point study to explore T1-weighted (W) signal changes in the dentate nucleus (DN) and globus pallidus (GP), after the first, fifth, and tenth injections of either a macrocyclic agent (gadoterate meglumine) or a linear agent (gadobenate dimeglumine).

Materials and Methods

For this retrospective, multicenter, longitudinal study, two groups of 18 (gadoterate meglumine) and 19 (gadobenate dimeglumine) patients were identified. The evolution of the signal over time was analyzed using DN/pons (DN/P) and GP/thalamus (GP/T) ratios.

Results

DN/P and GP/T ratios tended to increase after the fifth administration of gadobenate dimeglumine, following by a downward trend. A trend in a decrease in DN/P and GP/T ratios were found after the fifth and tenth administrations of gadoterate meglumine.

Conclusion

After exposure to gadobenate dimeglumine, the signal intensity (SI) tended to increase after the fifth injection owing to gadolinium accumulation, however, a SI increase was not found after the tenth administration supporting the hypothesis of a slow elimination of the previously retained gadolinium (wash-out effect) from the brain or of a change in form (by dechelation), causing the signal to fade.

No increasing SI was found in the DN and GP after exclusive exposure to gadoterate meglumine, thus confirming its stability. We found, instead, a trend for a significative gadolinium elimination over time.

Keywords

MRI

Gadolinium

Retention

Linear

Macrocyclic

INTRODUCTION

Contrast-enhanced magnetic resonance imaging (MRI) plays a major role in the diagnosis and follow-up of patients with a variety of neurological diseases and is routinely used in neuroimaging

through the administration of gadolinium-based contrast agents (GBCAs) [1-3]. Over the past 7 years [4], concern has grown worldwide after the finding of gadolinium deposits in the brain.

In 2013, Kanda et al. [4] were the first to report the existence of intracranial gadolinium retention,

based on the findings of high signal intensities on T1-weighted (W) images in two brain structures,

the dentate nucleus (DN) and the globus pallidus (GP). They used the dentate nucleus-to-pons (DN/P) and the globus pallidus-to-thalamus (GP/T) signal intensity (SI) ratios in patients receiving repeated doses of linear GBCAs (gadopentetate dimeglumine, Magnevist®, Bayer; gadodiamide, Omniscan®, GE). Since then, multiple retrospective studies [5,6] have confirmed these findings after five injections or more of gadopentetate dimeglumine, gadodiamide, or gadobenate dimeglumine (Multihance®, Bracco). Some studies have exclusively assessed exposure to macrocyclic GBCAs (gadoteridol, Prohance®, Bracco; gadoterate meglumine, Dotarem®, Guerbet; gadobutrol, Gadovist®, Bayer) and did not find any increased SI [5,7,8]. Correlation between the SI increase and gadolinium deposition in the neural tissue was further confirmed by histopathological correlation studies in postmortem tissue samples [9,10]. This retention depends on the type of gadolinium chelate used. Macrocyclic GBCAs are deposited in tiny amounts without inducing an appreciable increase in the T1 signal. This discrepancy can mostly be attributed to the higher thermodynamic and kinetic stabilities of the macrocyclic GBCAs, which are therefore less prone to releasing dissociated Gd³⁺ in tissues [11,12]. However, the mechanism of gadolinium deposition in brain tissues remains unclear, and several related questions are left unanswered, including the form and the stability over time of this accumulation

and the potential clearance of gadolinium from the brain ("wash-out" effect). Only a single clinical

study to date [13] has investigated the evolution of signal changes over time in patients receiving

injections of GBCAs during follow-up examinations. The latter showed a DN/P SI ratio increase after administering gadopentetate dimeglumine, not found after subsequent applications of macrocyclic agents in the same patients.

Therefore, we conducted a three-time-point retrospective, multicenter, longitudinal study to explore T1 signal changes over time in the DN and GP using automatic segmentation. In order to

investigate the signal variations, we compared SI ratios at the baseline, fifth, and tenth MRI examinations after injection of two classes of gadolinium chelates (either a macrocyclic agent, gadoterate meglumine, or a linear agent, gadobenate dimeglumine).

MATERIALS AND METHODS

The local ethics committee approved the design and the execution of this multicenter, retrospective, longitudinal study. The requirement to obtain written informed consent was waived

because this was a retrospective study. The study was registered with ClinicalTrials.gov, NCT number: NCT02992847.

Study design and population

Two study groups were identified, comprising 18 patients (Department of Medical Imaging, Strasbourg University Medical Center) and 19 patients (Department of Medical Imaging, Lyon University Medical Center).

To compose these groups, we searched for subjects fulfilling the inclusion criteria in our electronic database of MRI examinations conducted between February 2008 and December 2016.

Inclusion criteria were: (a) history of at least ten injections of either gadoterate meglumine (Group

1, Strasbourg) or gadobenate dimeglumine (Group 2, Lyon); (b) all consecutive MRI examinations

were performed in the same center.

After examining the medical records, we chose to exclude patients who had (a) undergone contrast agent administration outside our institutions or had undergone MRI with other

GBCAs.

To avoid possible confounding factors, we excluded (b) patients with diseases that may result

in T1 shortening in the deep gray matter (Wilson disease, Rendu–Osler–Weber disease,

manganese toxicity, hemodialysis, total parenteral nutrition, and neurofibromatosis). Other

exclusion criteria included (c) unsatisfactory images due to MRI artifacts or brain lesions involving

the GP, the ND, the thalamus, or the pons, (d) renal insufficiency defined as an estimated

glomerular filtration rate (eGFR) lower than 60 mL/min per 1.73 m² in a blood sample with respect

to the date of the MRI examination, and (e) history of liver disease (increased liver values were

defined as increased serum levels of the liver transaminases or GGT).

Age, sex, diagnosis, renal function, liver values, total dosage of GBCAs, and time intervals

between first and middle and first and last MRI examinations were gathered for all patients

included in the study.

For the first center, Strasbourg, we extracted data for 48 patients who underwent a minimum of

ten MRI examinations and for whom every instance of contrast agent administration exclusively

involved gadoterate meglumine. Of these 48 patients, 18 were included, 30 patients were

excluded owing to excessive distortion in regions of interest (ROIs) or because the fifth MRI

examination was missing. This group consisted of 11 males and seven females (mean age: 38.3 ±

17.3 years). The cumulated mean injected volume of GBCAs was 159 ± 37 mL, and the mean interval between the first and fifth administration was 1 ± 0.6 years, amounting to 2.4 ± 1.5 years

between the first and tenth injection. A total of 17 patients presented with an eGFR of more than

90 mL/min per 1.73m^2 ; one patient had an eGFR of <90 , but >60 , and no increased liver values

were found.

For the second center, Lyon, we extracted data for 21 patients who underwent a minimum of ten

MRI examinations using gadobenate dimeglumine administration. A total of 19 patients were finally included; one was excluded because of renal dysfunction and one because of excessive distortion in the ROIs.

This group consisted of 12 males and seven females (mean age: 51.7 ± 11.7 years). The cumulated mean injected volume was 145 ± 12 mL, and the mean interval between the first and fifth administration was 1.9 ± 0.7 years, amounting to 3.9 ± 1.2 years between the first and

tenth injection. Of these patients, 19 presented with an eGFR of more than 90 mL/min per 1.73m^2 , and no increased liver values were found.

For both groups, most of the patients underwent successive brain MRI for the follow-up of primary brain tumors (Group 1, $n=15$; Group 2, $n=17$); the other diagnoses included screening for

metastases (Group 1, n=3; Group 2, n=2). Ten patients from each group received tumor-selective brain radiation therapy.

The demographic and clinical characteristics of the study patients are shown in Table 1.

In order to assess signal variation, we decided to collect and analyze data at three-time points: MRI1, baseline, before any injection of GBCAs; MRI2, after five injections of GBCAs; and MRI3, after ten injections of GBCAs. We chose to realize the first analysis after five injections since changes in signal are generally observed at this point [13].

MRI and GBCAs administration

All patients underwent brain imaging performed on one of the MR instruments dedicated to neuroradiologic imaging using either a 1.5-T or 3-T MRI system (Magnetom Avanto 1.5T, Siemens, Aera 1.5T Siemens, Signa 3T GE, Achieva 3T Philips, Ingenia 3T, or 1.5T Philips).

The MRI protocol for the patients varied according to the center and the clinical indications, but

all protocols included enhanced three-dimensional (3D) gradient-echo T1-W images, and GBCAs

were injected in the MRI room. Unenhanced 3D T1 sequences were not available, as they were not part of the MRI protocols used for the patients in this study. Therefore, SI was measured on

3D-enhanced T1 sequences acquired after intravenous injection of a standardized dose of 15 or

20 mL GBCAs per contrast-enhanced MRI study. This approach was used in previous studies

that yielded consistent results [14,15], and it is suitable for long-term longitudinal analysis.

MRI data analysis and MR image segmentation

Quantitative analysis was performed using DN/P and GP/T ratios [4]. We applied an automatic segmentation method as an alternative to manual ROIs delineation as it is more reproducible and

gives more consistent results across all examinations. This technique allowed for the analysis of

the entire structure, instead of measurements on subjectively selected two-dimensional (2D)

slices through each ROIs. The different brain structures were defined with the SPL atlas (based on

data of a healthy 42-year-old male volunteer) [16]. The left and right structures were considered as

a single region for the statistical analyses. The T1-W images of all subjects were registered to the

SPL template using the diffeomorphic registration method of the advanced normalization tools

(ANTs) [17]. The resulting geometric transform was then applied to the ROIs to transport them to

the subject-specific space. A final check of the transform quality using 3D Slicer software [18,19]

was made by consensus of two radiologists (a resident with 4.5 years of experience and a senior

specialist with 7.5 years of experience), who were trained and supervised by a neuroradiology

expert (with more than 20 years of experience). An example of segmentation of DN/P and GP/T

using 3D Slicer is shown in Online Supplement Figures 1 and 2. The mean intensity of each structure at each time point was used to define the DN/P and GP/T ratios. As shown on Figure 1, the ratio not only varies along time but also with the contrast agent (different levels and different profiles on each row), and with the ROIs (different levels on each column, the profiles are however similar).

Statistical analysis

All following analyses were done with R (version 3.4; R Foundation for Statistical Computing). The

evolution of the signal intensity ratios was investigated using a single mixed-effects linear model

with a random intercept for the subject, and with fixed effects for the contrast agent, the time point, the ROI, as well as their second- and third-level interactions (*lmer* function from the *lme4*

package, using the formula $ratio \sim agent * timepoint * roi + (1/subject)$). An ANOVA was computed

on the model to evaluate the effect of each predictor (*anova.lmerMod* of the *lmerTest* package). For each contrast agent and for each ROI, the SI ratio difference between the first and

respectively the fifth and the tenth time point was computed, along with the 95% confidence

interval (CI) and the p-value with the null hypothesis being that the difference is equal to 0. The p-

values were adjusted for multiple comparisons by Dunnett's procedure, using the *emmeans* package.

RESULTS

The registration and subsequent segmentation were performed correctly for all subjects.

The model assumptions were validated from a Q-Q plot of the model residuals versus a normal

distribution. The model ANOVA indicated that the signal intensity varies differently along time across the contrast agents (interaction of the agent and time point predictors, $p=0.025$), that the

mean level for each ROI is different (ROI predictor, $p<0.001$), and that the signal varies similarly along time across the ROIs (interaction of the ROI and time point predictors, $p=0.858$). Table 2 shows the effect of all model variables.

The DN/P SI ratios tended to increase after the fifth administration of gadobenate dimeglumine

(95% CI [-0.002, 0.078], $p=0.064$). After the tenth administration, the SI ratio was still slightly higher than the first time point (95% CI [-0.018, 0.062], $p=0.379$). Similar variations were found in

the GP/T SI ratios, albeit with smaller differences: the difference between the fifth and the

first administration had a 95% CI of [-0.020, 0.060] ($p=0.427$), and the difference between the tenth and the first administration had a 95% CI of [-0.033, 0.048] ($p=0.866$).

For the gadoterate meglumine group, the values of the DN/P SI ratios were decreased after the

fifth administration (95% CI [-0.082, 0.000], $p=0.053$), and were still slightly lower than the first time point after the tenth administration (95% CI [-0.064, 0.018], $p=0.359$). As in the gadobenate

dimeglumine group, the variations in the GP/T SI ratios were much smaller although following the

same pattern: the difference between the fifth and the first administration had a 95% CI of [-0.066, 0.016] ($p=0.302$), and the difference between the tenth and the first administration had a 95% CI of [-0.069, 0.014] ($p=0.246$).

These results are summarized in Table 3a for the gadobenate dimeglumine group and Table 3b for the gadoterate meglumine group.

DISCUSSION

This multicenter, retrospective study shows that exposure to gadobenate dimeglumine, a linear GBCA, tends to increase the DN/P and GP/T SI ratios after the fifth administration of the agent. These findings are in line with previous studies, which have reported the deposition of

linear agents in the brain, seen as high signal intensities on T1-W images [4-6]. Increased

SI in the DN and GP after multiple exposures to a linear GBCAs seems to reflect a residual or progressive accumulation of GBCAs in those structures, as confirmed in animal studies [20,21]

and human brain autopsies [10]. Nevertheless, our study failed in highlighting a significant increase, and several reasons can explain this result. First, the limited number of patients (n=19)

can alone explain the lack of significance. Second, the use of injected sequences for signal

measurements must be considered as a potential bias. Third, the follow-up was performed with

different machines and field strength and, therefore, with changes in the parameters of the

sequences. Lastly, changes in the signal secondary to tumoral evolution or related to treatments

(e.g., brain radiation therapy) can also be discussed.

After the tenth administration, the SI ratio was lower than after the fifth administration.

These results suggest that, after a period of accumulation, retained gadolinium may slowly wash

out of the brain or slowly change form (possibly dechelating), causing the signal to fade.

To our knowledge, only a few studies to date [13,20-22] have investigated whether gadolinium accumulation in brain tissue was permanent or could be cleared. The wash-out hypothesis is consistent with the findings of prospective animal studies [20-22], notably by Smith et al. [20], who used inductively coupled plasma mass spectroscopy to measure the amount of gadolinium

deposition and its potential clearance from the brain in healthy rats. Small amounts of gadolinium

were present in brain tissue after repeated administration of gadodiamide (a linear GBCA), which

then partially cleared over the 20 weeks of follow-up (diminished by approximately 50%).

Even if a wash-out does occur, the dechelation hypothesis probably plays a role both in accumulation and in the elimination of gadolinium from the brain. The dechelation of free gadolinium from its ligand is a process mainly defined by kinetic and thermodynamic stabilities. It

can be influenced by the presence of competitors, such as endogenous metals ions (Fe^{3+} , Cu^{2+} ,

or Zn^{2+}). These agents compete with the gadolinium chelate, bound to the ligand, leading to gadolinium dissociation and deposition in the body [23-27], which then causes a signal increase.

The SI decrease could be explained by a transition of formerly chelated gadolinium or gadolinium

bound to macromolecules with high relaxivity to gadolinium-binding molecules with negligible

relaxivity, causing the T1 signal to fade.

Regarding macrocyclic GBCAs, no increase in signal was found in both DN/P and GP/T after repeated administration, confirming the higher thermodynamic stability of this type of GBCAs, which is less prone to gadolinium accumulation. This is in line with previous studies, notably those

of Kanda et al. [5] and Rabruch et al. [7], who stated that gadolinium deposition in the brain depends mainly on the molecular structure of the GBCAs. However, current animal and human autopsy studies provided evidence of both linear and macrocyclic retention, suggesting that all GBCAs are associated with gadolinium accumulation, even if no appreciable mean increase in SI

was seen on MRI examination when using macrocyclic agents. This could be explained by the minimal amount of macrocyclic retention compared with the linear agents, and it also reflects that

MRI has a relatively limited sensitivity to detect gadolinium deposition in brain tissue.

We found, instead, a trend in a decrease in SI in the DN and GP after the fifth and tenth administrations of gadoterate meglumine.

Such a signal decrease has been reported by few studies only [28-30]. Reasons for this phenomenon can be put forward, such as the hypothesis of precipitation of the GBCAs or an increased signal in the pons and thalami. Before exploring these theories, we considered the possible influence of the MR field strength, since examinations were acquired either at 1.5 T or 3 T. Even if the signal differed slightly between 1.5 T and 3 T, the use of ratios limits this effect

without having an impact on the appearance of an increased signal [31]. One of the theories put

forward was the precipitation of the macrocyclic complex. Indeed, as seen previously,

macrocyclic agents are retained in brain structures, even in small amounts, and are subsequently

eliminated over time. It is established that macrocyclic agents are more stable, less prone to

dechelation, and mostly accumulate in a soluble intact form [32]. However, if this complex

precipitates over time as a phosphate or carbonate complex, which does not induce an

increase in the signal, or if dechelation occurs, which leads to the creation of complexes bound to

macromolecules with negligible relaxivity, this will cause the signal to fade. Regarding the

increase in the signal within the pons or thalamus, this effect was not found in our study. Indeed,

no isolated increase in the value of these denominators, which could have resulted in a decrease

in the DN/P and GP/T ratios, was found.

Our study has several limitations, as previously mentioned, including the small number of subjects

and the fact that retrospective studies may contain observer bias. However, in this multicentric

study, all subjects were exclusively exposed to a single contrast agent. This prerequisite and the

fact that each patient had an equal number of administrations with a high mean volume injected,

increased the power of our study, and allowed us to compare the GBCAs directly. Furthermore, we used data compiled since 2008 from two centers; hence not all examinations were conducted

at the same field strength (1.5 T or 3 T), and no pre-contrast 3D T1 unenhanced images were acquired. The use of 3D T1 contrast-enhanced images for SI analysis and the inhomogeneous field strength thereby may have led to variations in the interpretation of our results. However, our

results are in line with previous studies using unenhanced T1-W imaging. Thereby, as Ramalho [33] underlines in analyzing the study of Tanaka et al. [15], no significant differences were found

throughout the comparison of the SI ratio of the DN/P on both unenhanced T1-W and post-gadolinium T1-W sequences, suggesting that the effect of gadolinium accumulation in the brain

could be analyzed on enhanced T1-W images. This approach can be very useful for long-term analysis, as seen in a previous study [14].

Our study failed in highlighting significant differences that could probably have been highlighted if

the delay between the different MRIs had been longer.

Despite the limitations discussed here, the strength of our study lies in the use of 3D T1 imaging

with an automatic segmentation technique, allowing us to analyze the signal of each whole-brain

structure, right and left, in a more reliable and reproducible way as compared with the use of

subjective unilateral ROI placement on 2D slices.

CONCLUSION

Our three-time-point, longitudinal, retrospective, multicenter study using automatic segmentation

found no measurable SI increase in the DN and GP on T1-W MR images of patients exposed exclusively to gadoterate meglumine, thus confirming the stability of macrocyclic agents, which are less prone to being retained in the brain. Instead, we found, a trend in a decrease in SI, which

confirms the assumption for a significative gadolinium elimination over time.

After exposure to a linear GBCAs (gadobenate dimeglumine), the SI tended to increase after the

fifth injection owing to gadolinium accumulation. After the tenth administration, the SI ratio was

lower than after the fifth administration supporting the hypothesis of a slow elimination of the previously retained gadolinium (wash-out effect) from the brain or of a change in form (by dechelation), causing the signal to fade.

Acknowledgements

This research did not receive any specific grant from funding agencies in the public, commercial,

or not-for-profit sectors.

Formatting of funding sources

This research did not receive any specific grant from funding agencies in the public, commercial,

or not-for-profit sectors.

Abbreviations:

2D: two-dimensional

3D: three-dimensional

ANTs: advanced normalization tools

CI: confidence interval

DN: dentate nucleus

eGFR: estimated Glomerular Filtration Rate

GBCAs: gadolinium-based contrast agents

GP: globus pallidus

MRI: Magnetic resonance imaging

P: pons

ROIs: regions of interest

SI: signal intensity

T: thalamus

W: weighted

Figure legends:

Figure 1: Signal variation between timepoints

References:

1. Kanal E, Maravilla K, Rowley HA. Gadolinium Contrast Agents for CNS Imaging: Current Concepts and Clinical Evidence. Am J Neuroradiol. 2014 Dec;35(12):2215–26.
2. Chazot A, Barrat JA, Gaha M, Jomaah R, Ognard J, Ben Salem D. Brain MRIs make up the bulk of the gadolinium footprint in medical imaging. J Neuroradiol. 2020;47(4):259-265. doi:10.1016/j.neurad.2020.03.004
3. Brisset JC, Kremer S, Hannoun S, et al. New OFSEP recommendations for MRI assessment of multiple sclerosis patients: Special consideration for gadolinium deposition and frequent acquisitions. J Neuroradiol. 2020;47(4):250-258. doi:10.1016/j.neurad.2020.01.083
4. Kanda T, Ishii K, Kawaguchi H, Kitajima K, Takenaka D. High signal intensity in the dentate nucleus and globus pallidus on unenhanced T1-weighted MR images: relationship with

increasing cumulative dose of a gadolinium-based contrast material. *Radiology*. 2014;270(3):834-841. doi:10.1148/radiol.13131669

5. Kanda T, Osawa M, Oba H, et al. High Signal Intensity in Dentate Nucleus on Unenhanced T1-weighted MR Images: Association with Linear versus Macrocyclic Gadolinium Chelate Administration. *Radiology*. 2015;275(3):803-809. doi:10.1148/radiol.14140364
6. Ramalho J, Castillo M, AlObaidy M, et al. High Signal Intensity in Globus Pallidus and Dentate Nucleus on Unenhanced T1-weighted MR Images: Evaluation of Two Linear Gadolinium-based Contrast Agents. *Radiology*. 2015;276(3):836-844. doi:10.1148/radiol.2015150872
7. Radbruch A, Weberling LD, Kieslich PJ, et al. Gadolinium retention in the dentate nucleus and globus pallidus is dependent on the class of contrast agent. *Radiology*. 2015;275(3):783-791. doi:10.1148/radiol.2015150337
8. Radbruch A, Haase R, Kieslich PJ, et al. No Signal Intensity Increase in the Dentate Nucleus on Unenhanced T1-weighted MR Images after More than 20 Serial Injections of Macrocyclic Gadolinium-based Contrast Agents. *Radiology*. 2017;282(3):699-707. doi:10.1148/radiol.2016162241
9. Murata N, Gonzalez-Cuyar LF, Murata K, et al. Macrocyclic and Other Non-Group 1 Gadolinium Contrast Agents Deposit Low Levels of Gadolinium in Brain and Bone Tissue: Preliminary Results From 9 Patients With Normal Renal Function. *Invest Radiol*. 2016;51(7):447-453. doi:10.1097/RLI.0000000000000252
10. Kanda T, Fukusato T, Matsuda M, et al. Gadolinium-based Contrast Agent Accumulates in the Brain Even in Subjects without Severe Renal Dysfunction: Evaluation of Autopsy Brain Specimens with Inductively Coupled Plasma Mass Spectroscopy. *Radiology*. 2015;276(1):228-232. doi:10.1148/radiol.2015142690
11. Morcos SK. Extracellular gadolinium contrast agents: differences in stability. *Eur J Radiol*. 2008;66(2):175-179. doi:10.1016/j.ejrad.2008.01.025
12. Idée JM, Port M, Robic C, Medina C, Sabatou M, Corot C. Role of thermodynamic and kinetic parameters in gadolinium chelate stability. *J Magn Reson Imaging*. 2009;30(6):1249-1258. doi:10.1002/jmri.21967
13. Radbruch A, Weberling LD, Kieslich PJ, et al. Intraindividual Analysis of Signal Intensity Changes in the Dentate Nucleus After Consecutive Serial Applications of Linear and Macrocyclic Gadolinium-Based Contrast Agents. *Invest Radiol*. 2016;51(11):683-690. doi:10.1097/RLI.0000000000000308
14. Jaulent P, Hannoun S, Koccevar G, et al. Weekly enhanced T1-weighted MRI with Gadobutrol injections in MS patients: Is there a signal intensity increase in the dentate nucleus and the globus pallidus?. *Eur J Radiol*. 2018;105:204-208. doi:10.1016/j.ejrad.2018.06.011
15. Tanaka M, Nakahara K, Kinoshita M. Increased Signal Intensity in the Dentate Nucleus of Patients with Multiple Sclerosis in Comparison with Neuromyelitis Optica Spectrum Disorder

after Multiple Doses of Gadolinium Contrast. *Eur Neurol*. 2016;75(3-4):195- 198.
doi:10.1159/000445431

16. Halle M. Multi-modality MRI-based Atlas of the Brain. SPL 2016 Aug.
17. Avants BB, Epstein CL, Grossman M, Gee JC. Symmetric diffeomorphic image registration with cross-correlation: evaluating automated labeling of elderly and neurodegenerative brain. *Med Image Anal*. 2008;12(1):26-41. doi:10.1016/j.media.2007.06.004
18. 3D Slicer <https://www.slicer.org/>.
19. Fedorov A, Beichel R, Kalpathy-Cramer J, et al. 3D Slicer as an image computing platform for the Quantitative Imaging Network. *Magn Reson Imaging*. 2012;30(9):1323- 1341. doi:10.1016/j.mri.2012.05.001
20. Smith AP, Marino M, Roberts J, et al. Clearance of Gadolinium from the Brain with No Pathologic Effect after Repeated Administration of Gadodiamide in Healthy Rats: An Analytical and Histologic Study. *Radiology*. 2017;282(3):743- 751. doi:10.1148/radiol.2016160905
21. Kartamihardja AA, Nakajima T, Kameo S, Koyama H, Tsushima Y. Distribution and clearance of retained gadolinium in the brain: differences between linear and macrocyclic gadolinium based contrast agents in a mouse model. *Br J Radiol*. 2016;89(1066):20160509. doi:10.1259/bjr.20160509
22. Jost G, Frenzel T, Boyken J, Lohrke J, Nischwitz V, Pietsch H. Long-term Excretion of Gadolinium-based Contrast Agents: Linear versus Macrocyclic Agents in an Experimental Rat Model. *Radiology*. 2019;290(2):340- 348. doi:10.1148/radiol.2018180135
23. Hao D, Ai T, Goerner F, Hu X, Runge VM, Tweedle M. MRI contrast agents: basic chemistry and safety. *J Magn Reson Imaging*. 2012;36(5):1060- 1071. doi:10.1002/jmri.23725
24. Valdés Hernández Mdel C, Maconick LC, Tan EM, Wardlaw JM. Identification of mineral deposits in the brain on radiological images: a systematic review. *Eur Radiol*. 2012;22(11):2371- 2381. doi:10.1007/s00330-012-2494-2
25. Tweedle MF, Hagan JJ, Kumar K, Mantha S, Chang CA. Reaction of gadolinium chelates with endogenously available ions. *Magn Reson Imaging*. 1991;9(3):409- 415. doi:10.1016/0730-725x(91)90429-p
26. Cacheris WP, Quay SC, Rocklage SM. The relationship between thermodynamics and the toxicity of gadolinium complexes. *Magn Reson Imaging*. 1990;8(4):467- 481. doi:10.1016/0730-725x(90)90055-7
27. Abraham JL, Thakral C, Skov L, Rossen K, Marckmann P. Dermal inorganic gadolinium concentrations: evidence for in vivo transmetallation and long-term persistence in nephrogenic systemic fibrosis. *Br J Dermatol*. 2008;158(2):273- 280. doi:10.1111/j.1365-2133.2007.08335.x

28. Cao Y, Huang DQ, Shih G, Prince MR. Signal Change in the Dentate Nucleus on T1-Weighted MR Images After Multiple Administrations of Gadopentetate Dimeglumine Versus Gadobutrol. *AJR Am J Roentgenol*. 2016;206(2):414-419. doi:10.2214/AJR.15.15327
29. Schlemm L, Chien C, Bellmann-Strobl J, et al. Gadopentetate but not gadobutrol accumulates in the dentate nucleus of multiple sclerosis patients. *Mult Scler*. 2017;23(7):963-972. doi:10.1177/1352458516670738
30. Kelemen P, Alaoui J, Sieron D, Chan A, Kamm CP, Heldner MR, et al. T1-weighted Grey Matter Signal Intensity Alterations After Multiple Administrations of Gadobutrol in Patients with Multiple Sclerosis, Referenced to White Matter. *Scientific Reports* [Internet]. déc 2018 [cité 28 juill 2019];8(1). Disponible sur: <http://www.nature.com/articles/s41598-018-35186-w>
31. Adin ME, Kleinberg L, Vaidya D, Zan E, Mirbagheri S, Yousem DM. Hyperintense Dentate Nuclei on T1-Weighted MRI: Relation to Repeat Gadolinium Administration. *AJNR Am J Neuroradiol*. 2015;36(10):1859-1865. doi:10.3174/ajnr.A4378
32. Frenzel T, Apte C, Jost G, Schöckel L, Lohrke J, Pietsch H. Quantification and Assessment of the Chemical Form of Residual Gadolinium in the Brain After Repeated Administration of Gadolinium-Based Contrast Agents: Comparative Study in Rats. *Invest Radiol*. 2017;52(7):396-404. doi:10.1097/RLI.0000000000000352
33. Ramalho J, Ramalho M. Gadolinium Deposition and Chronic Toxicity. *Magn Reson Imaging Clin N Am*. 2017;25(4):765-778. doi:10.1016/j.mric.2017.06.007

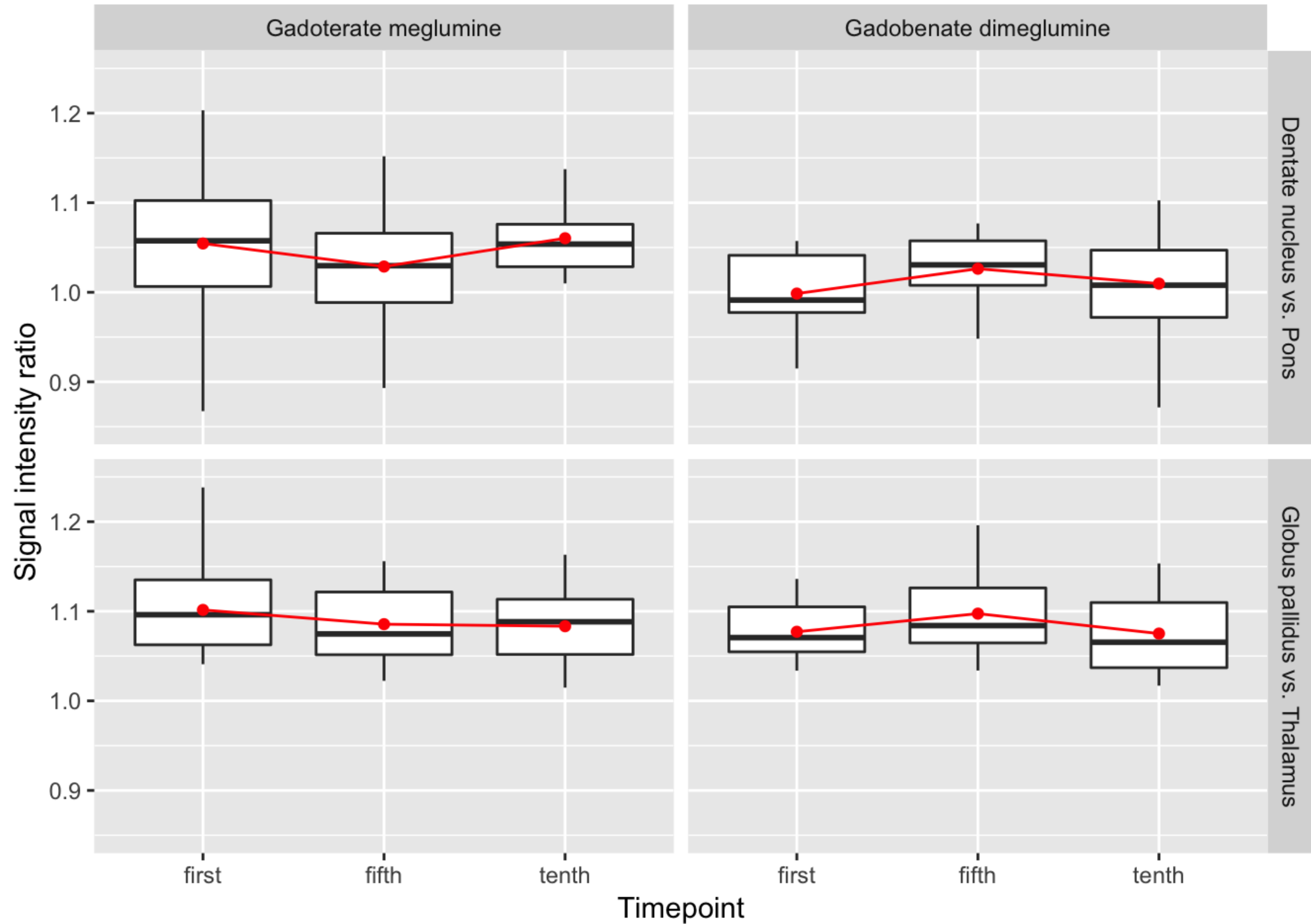


Table 1 : Demographic and Clinical Characteristics of Patients in the Study Sample

	Group 1: Gadoterate meglumine	Group 2: Gadobenate dimeglumine
Number	n=18	n=19
Age (years)*	38.3 ± 17.3	51.7 ± 11.7
Patient sex: - Male(n) - Female (n)	11 7	12 7
Cumulated mean injected volume (mL)* after fifth administration	79 ± 20	72 ± 7
Cumulated mean injected volume (mL)* after tenth administration	159 ± 37	145 ± 12
Mean interval between the first and fifth GBCA administration (years)*	1 ± 0.6	1.9 ± 0.7
Mean interval between the first and tenth GBCA administration (years)*	2.4 ± 1.5	3.9 ± 1.2
Primary indication for brain MRI: - Primary brain tumor - Brain metastasis	15 3	17 2
History of brain radiation therapy: - Whole brain - Tumor selective	0 10	0 10
eGFR: - >90 mL/min per 1.73 m2 - 60–90 mL/min per 1.73 m2	17 1	19 0
Abnormal liver function	0	0

* Data are mean ± standard deviations; eGFR= estimated glomerular filtration rate.

Table 2: Effect of model variables

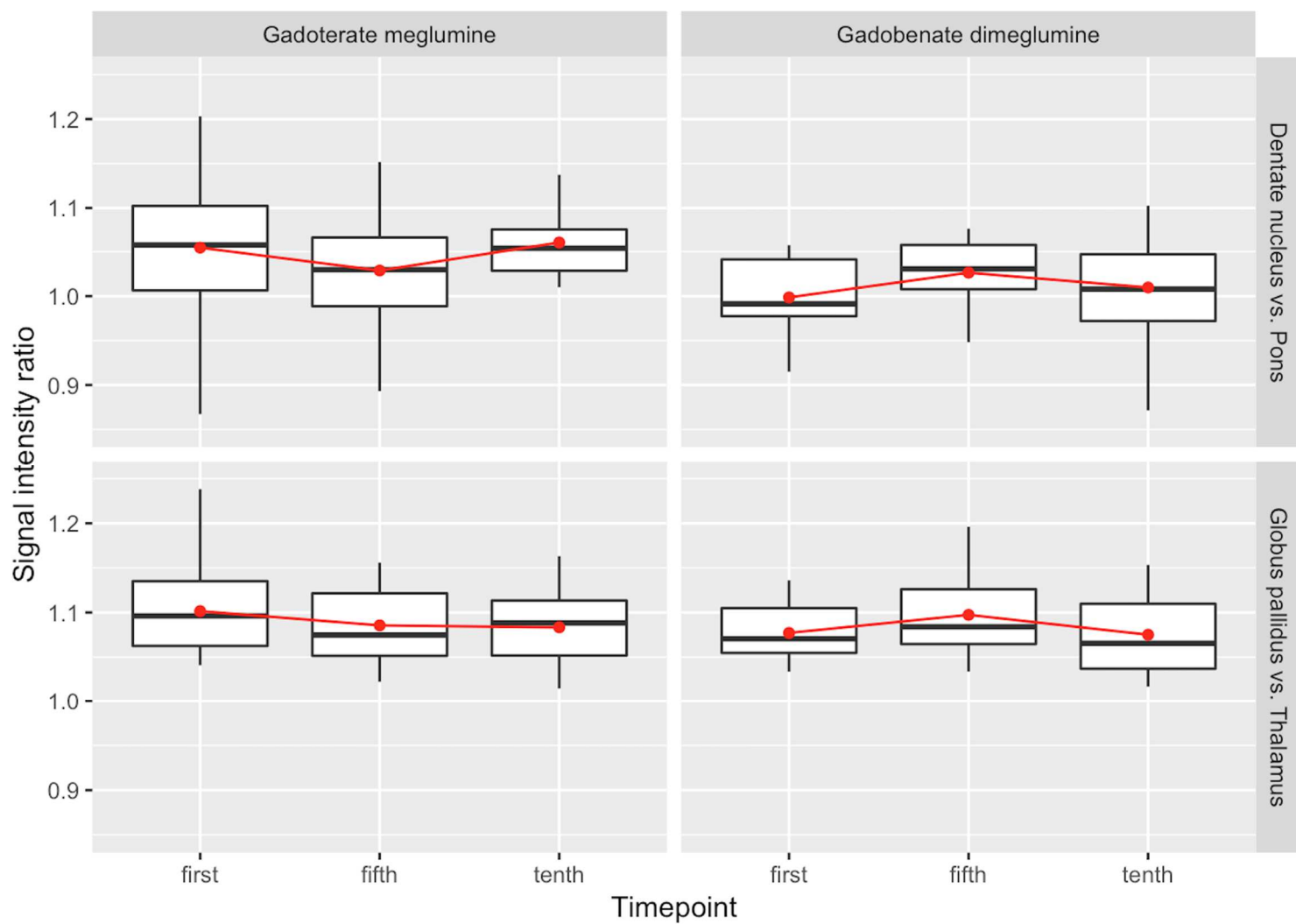
Model variable	p-value
Contrast agent	0.057
ROI	< 0.001
Time point	0.841
Interaction of contrast agent and ROI	0.025
Interaction of contrast agent and time point	0.003
Interaction of ROI and time point	0.858
Interaction of contrast agent, ROI, and time point	0.632

Table 3a: Signal variation between timepoints (Dentate nucleus versus Pons)

Contrast agent	Time points	95% confidence interval	p-value
Dotarem®	Fifth - first	[-0.082, 0.000]	0.053
Dotarem®	Tenth - first	[-0.064, 0.018]	0.359
Multihance®	Fifth - first	[-0.002, 0.078]	0.064
Multihance®	Tenth - first	[-0.018, 0.062]	0.379

Table 3b: Signal variation between timepoints (Globus Pallidus versus Thalamus)

Contrast agent	EstimateTime points	95 % confidence interval	p.-value
Dotarem®	Fifth - first	[-0.066, 0.016]	0.302
Dotarem®	Tenth - first	[-0.069, 0.014]	0.246
Multihance®	Fifth - first	[-0.020, 0.060]	0.427
Multihance®	Tenth - first	[-0.033, 0.048]	0.866



Graphical abstract : Signal variation between timepoints