



**HAL**  
open science

## Identification and measurement of cervical spinal cord atrophy in neuromyelitis optica spectrum disorders (NMOSD) and correlation with clinical characteristics and cervical spinal cord MRI data

François Lersy, Vincent Noblet, Thibault Willaume, Nicolas Collongues, Laurent Kremer, Marie-Céline Fleury-Lesaunier, Jerome de Seze, Stephane Kremer

### ► To cite this version:

François Lersy, Vincent Noblet, Thibault Willaume, Nicolas Collongues, Laurent Kremer, et al.. Identification and measurement of cervical spinal cord atrophy in neuromyelitis optica spectrum disorders (NMOSD) and correlation with clinical characteristics and cervical spinal cord MRI data. *Revue Neurologique*, 2021, 177 (1-Z), 10.1016/j.neurol.2020.05.007 . hal-03235722

**HAL Id: hal-03235722**

**<https://hal.science/hal-03235722>**

Submitted on 13 Feb 2023

**HAL** is a multi-disciplinary open access archive for the deposit and dissemination of scientific research documents, whether they are published or not. The documents may come from teaching and research institutions in France or abroad, or from public or private research centers.

L'archive ouverte pluridisciplinaire **HAL**, est destinée au dépôt et à la diffusion de documents scientifiques de niveau recherche, publiés ou non, émanant des établissements d'enseignement et de recherche français ou étrangers, des laboratoires publics ou privés.



Distributed under a Creative Commons Attribution - NonCommercial 4.0 International License

## **Identification and measurement of cervical spinal cord atrophy in neuromyelitis optica spectrum disorders (NMOSD) and correlation with clinical characteristics and cervical spinal cord MRI data.**

Dr. François LERSY, neuroradiologist, University hospital of Strasbourg  
(corresponding author)

Mr. Vincent NOBLET, research engineer, University hospital of Strasbourg

Dr. Thibault WILLAUME, radiologist, University hospital of Strasbourg

Dr. Nicolas COLLONGUES, neurologist, University hospital of Strasbourg

Dr. Laurent KREMER, neurologist, University hospital of Strasbourg

Dr. Marie FLEURY, neurologist, University hospital of Strasbourg

Pr. Jérôme de SEZE, neurologist, University hospital of Strasbourg

Pr. Stéphane KREMER, neuroradiologist, University hospital of Strasbourg

### **Abstract**

**Introduction:** *The spinal cord is one of the two main targets of neuromyelitis optica (NMO). The aim of this study was to highlight cervical spinal cord atrophy in NMO patients as compared to controls and to assess correlations between atrophy and clinical characteristics and cervical spinal cord MRI data.*

**Methods:** *This prospective study investigated 15 patients with a diagnosis of NMOSD and 15 healthy controls. The whole cervical spinal cord was explored by MRI. The cross-sectional area (CSA) was estimate at every level of cup. This measurement was then averaged on the whole cervical spinal cord, providing a single measurement for every subject, denoted as mean CSA.*

**Results:** *Mean CSA was 68.5 mm<sup>2</sup> in the population of NMO patients and 72.8 mm<sup>2</sup> in the population of healthy subjects. NMO patients had significantly smaller cervical spinal cord area than healthy controls ( $T_{test} = 0.009$ ). Cervical spinal cord atrophy was associated with clinical signs of medullary involvement ( $T_{test} = 0.0006$ ). There was a tendency toward a relation between cervical spinal cord atrophy and the Expanded Disability Status Scale (EDSS) ( $T_{test} = 0.07$ ). This correlation seems statistically significant ( $T_{test} < 0.05$ ) at the level of the upper cervical spinal cord (C2-C3)*

**Conclusion:** *This study provides the first evidence of cervical spinal cord atrophy in NMOSD by studying the entire cervical spinal cord. Upper cervical spinal cord atrophy was substantially correlated to clinical disability and seems more involved in the development of clinical disability in NMOSD patients in comparison to the lower cervical spinal cord.*

# Identification and measurement of cervical spinal cord atrophy in neuromyelitis optica spectrum disorders (NMOSD) and correlation with clinical characteristics and cervical spinal cord MRI data.

## Abstract

**Introduction:** *The spinal cord is one of the two main targets of neuromyelitis optica (NMO). The aim of this study was to highlight cervical spinal cord atrophy in NMO patients as compared to controls and to assess correlations between atrophy and clinical characteristics and cervical spinal cord MRI data.*

**Methods:** *This prospective study investigated 15 patients with a diagnosis of NMOSD and 15 healthy controls. The whole cervical spinal cord was explored by MRI. The cross-sectional area (CSA) was estimate at every level of cup. This measurement was then averaged on the whole cervical spinal cord, providing a single measurement for every subject, denoted as mean CSA.*

**Results:** *Mean CSA was 68.5 mm<sup>2</sup> in the population of NMO patients and 72.8 mm<sup>2</sup> in the population of healthy subjects. NMO patients had significantly smaller cervical spinal cord area than healthy controls ( $T_{test} = 0.009$ ). Cervical spinal cord atrophy was associated with clinical signs of medullary involvement ( $T_{test} = 0.0006$ ). There was a tendency toward a relation between cervical spinal cord atrophy and the Expanded Disability Status Scale (EDSS) ( $T_{test} = 0.07$ ). This correlation seems statistically significant ( $T_{test} < 0.05$ ) at the level of the upper cervical spinal cord (C2-C3)*

**Conclusion:** *This study provides the first evidence of cervical spinal cord atrophy in NMOSD by studying the entire cervical spinal cord. Upper cervical spinal cord atrophy was substantially correlated to clinical disability and seems more involved in the development of clinical disability in NMOSD patients in comparison to the lower cervical spinal cord.*

## Introduction

Neuromyelitis optica (also known as Devic's disease (1)) is a rare, severe, idiopathic, inflammatory, demyelinating disease of the central nervous system that preferentially affects the optic nerve and spinal cord. Neuromyelitis optica (NMO) is associated with recurrent episodes of optic neuritis and longitudinally extensive acute transverse myelitis, often resulting in permanent blindness and/or paralysis (2). NMO had long been considered as a variant of multiple sclerosis (MS). The presence of a highly specific serum autoantibody marker (NMO-IgG) further differentiates NMO from MS and has helped to define a neuromyelitis optica spectrum of disorders (NMOSD) (3). NMO-IgG is now known to target aquaporin-4 (AQP4), an astrocyte water channel that is widely distributed within the central nervous system (4,5,6,7). NMO is the first example of a novel class of autoimmune channelopathies (8,9). Owing to its very high specificity to NMO, the anti-AQP4 antibody was included in the revised diagnostic criteria for NMO. In the spinal cord, AQP4 is abundant in the grey matter and glial cell processes adjacent to the ependymal cells of the central canal, and to a lesser degree, in the white matter of the spinal cord. The most distinct manifestation of NMO is longitudinally extensive transverse myelitis (LETM), defined as a lesion that spans over three or more contiguous vertebral segments (10). Short transverse myelitis (lesions defined by MRI as not extending to three vertebral segments) is not uncommon in NMOSD and does not exclude NMOSD diagnosis (11). MRI changes in LETM have been observed over the course of NMOSD, and MRI data indicate that LETM lesions may evolve into multiple shorter lesions during remission or after treatment with high-dose steroids (10)

MS is the most common inflammatory demyelinating disease of the central nervous system. Numerous studies have assessed cervical spinal cord atrophy in MS (12,13). The first studies estimated the medullary area at a single anatomic level, while it is now possible to measure the whole cervical spinal cord volume. These studies demonstrated

cervical spinal cord atrophy, especially in primary and secondary progressive disease, while the cervical spinal cord seems relatively spared in the relapsing-remitting form (14,15). There was an extremely strong correlation between cervical spinal cord volume and clinical disability measured by Kurtzke's Expanded Disability Status Scale (EDSS). Within MS, spinal cord damage is more significant in terms of the development of motor-related disability rather than overall brain damage (16). Several mechanisms participate in this tissue loss: inflammatory tissue injury, demyelination, axonal loss, and Wallerian degeneration. This measurement is helpful in understanding clinical disability and monitoring disease progression. Moreover, it seems useful in the case of a therapeutic clinical trial to evaluate the effect of treatments that aim to prevent neuroaxonal loss and irreversible disability (17).

A number of studies have evaluated brain volume in neuromyelitis optica (18,19,20). Global and focal brain atrophy of white matter but not of grey matter was found (18). White matter atrophy is more frequent in cases of cognitive disorders (18).

Only a few rare studies have assessed cervical spinal cord atrophy in neuromyelitis optica (21,22,23). In particular, to our knowledge, the entire cervical spinal cord has never been investigated.

The aims of this study were to (a) highlight cervical spinal cord atrophy in NMO patients as compared to controls and, (b) assess correlations between atrophy and clinical characteristics (including disability) and cervical spinal cord MRI abnormalities.

## **Methods**

## Population

In this prospective study, we studied 15 patients (from the Department of Neurology, Hautepierre Hospital, Strasbourg, France) with a diagnosis of NMOSD (twelve females; mean age 49.7 years; range, 28-66 years, three males; mean age, 50.7 years; range 38-67) and 15 healthy individuals without any known spinal cord disease or neurologic disorder (ten females; mean age, 49 years; range, 26-78 years; five males; mean age 50.8 years; range, 28-72). There was no statistically significant difference between the two groups concerning age ( $p = 0.96$ ) and gender ( $p = 0.40$ ).

The mean age at disease onset was 37.9 years. Enrollment began in January 2013 and ended in May 2015. All the patients were diagnosed according to the 2015 new diagnostic criteria of NMOSD (24). Disease duration was measured in years from the onset of the first symptoms until the last follow-up. The mean disease duration was 12 years (range, 0.5-33 years). Before MRI acquisition, NMO patients were clinically assessed by an experienced neurologist, who utilized the EDSS to standardize assessment of their neurological condition. Mean EDSS was 2.8 (range, 0-7). The functional system scores (FSS) impacted by a spinal cord injury (pyramidal, sensory, and bowel/bladder scores), as well as the visual score, were also evaluated. Mean pyramidal FSS was 1.5 (range, 0-4), mean sensory FSS was 1.3 (range, 0-2), mean bowel/bladder FSS was 1.1 (range, 0-3), and mean visual FSS was 0.4 (range, 0-4). None of the subjects had experienced a relapse or received a treatment with corticosteroids within 3 months prior to imaging.

Relapses were defined as new or recurrent neurological symptoms not associated with fever or infection that lasted at least 24 hours and were accompanied by new neurologic signs found by the clinical examination. The average number of relapses was 7.1, with 5.2 including medullary involvement. The average deadline sold since the last medullary relapse was of 2.4 years. In this study, 60% (9/15) of the patients clinically diagnosed with NMO were seropositive for NMO-IgG, and 40% (6/15) were seronegative.

Eighty percent (12/15) of the patients showed clinical signs of medullary involvement, including bowel or bladder dysfunction, movement disorders, and sensory disturbances. Eighty percent (12/15) of the cervical spinal cord MRIs were abnormal, with the presence of T2 hyperintense lesions in the cervical spinal cord. The demographic, clinical, biological, and MRI characteristics of the patients are shown in Tables 1 and 2.

The healthy subjects' demographic characteristics are shown in Table 3. This study was approved by the local ethical standards committee, and written informed consent was obtained from all participating subjects.

### **Magnetic resonance imaging (MRI) protocol**

All subjects underwent imaging of the cervical cord with the use of a 1.5T MR unit (Avanto; Siemens, Erlangen, Germany) equipped with standard matrix neck coils.

The following sequences were acquired :

- sagittal T2 3D Space (repetition time [TR]: 1500 ms; echo time [TE]: 119 ms; field of view [FOV]: 320mm; matrix: 640x640; 64 slices with 1mm thickness).

These images were examined by one experienced neuroradiologist and one junior radiologist.

### **Image post-processing**

Dicom files were first anonymized and converted into NIfTI format. In this study, we used the Spinal Cord Toolbox (SCT) (25), which is a comprehensive software dedicated to the processing of spinal cord MRI data. Preliminary applications of SCT cover a variety of studies, from cross-sectional area measures in large databases of patients, to the precise quantification of mpMRI metrics in specific spinal pathways. One of the goal of SCT is to perform cord-specific quantification such as quantification of cross-sectional area across

vertebral levels. The delineation of the spinal cord contour is a common procedure for quantifying CSA or spinal cord volume. The automatic segmentation algorithm consists of : a) detecting the center of the spinal cord using ellipse detection and information from the body symmetry, b) propagating a tubular surface along the spinal cord edge using deformable models.

The outputs include a binary mask of the spinal cord, a 3D parametric surface and CSA measure for each axial slice along the spinal cord. The algorithm has been validated against multiple contrasts (T1-, T2- and T2\*- weighted).

To restrict the analysis to the cervical part (C1-C7), a single reader identified the upper and lower limits, i.e., the summit of the tooth of the axis (equivalent of C1) and the lower edge of C7 (Figure 1).

Based on the centerline extraction, the software estimates the cross-sectional area (CSA) at every point along the spinal cord. This measurement was then averaged out on the whole cervical part, providing a single measurement for every subject, denoted as mean-CSA. Considering the mean-CSA rather than the volume of the cervical spinal cord enables us to remove the influence of the body height (26). Indeed, within each spinal level, the area of the spinal cord increased with body height, whereas age has a limited influence on the cervical spinal cord area (26).

## **Statistical analysis**

To verify that the populations were matched for age and gender, a bilateral Student t-test and a two-proportion z-test were used, respectively.

The mean-CSA between healthy individuals and NMO patients was compared using a Student t-test. Correlations between the mean-CSA of NMO patients and clinical and radiological data were analyzed using the general linear model. Tests whose p-value was less than 0.05 were considered as statistically significant.



## **Results**

### **MRI characteristics of NMO patients.**

In this study, 80% (12/15) of the cervical spinal cord MRIs were abnormal, with the presence of T2 hyperintense lesions in the cervical spinal cord. The extent in height was

visually estimated: lower than one-third, between one-third and two-thirds, and greater than two-thirds of the height of the cervical spinal cord. The majority (46.67%, 7/15), presented involvement extending over less than one-third of the height of the cervical spinal cord, 26.67% (4/15) between one-third and two-thirds, and 6.67% (1/15) greater than to two-thirds of the height of the cervical spinal cord.

### **Mean-CSA in the two populations**

The mean-CSA values are presented in Tables 2 and 3.

The average value was 68.5 mm<sup>2</sup> in the NMO patient population (range, 54.7–82.2 mm<sup>2</sup>).

The mean value was 72.8 mm<sup>2</sup> in the population of the healthy subjects (range, 57.6–87.5 mm<sup>2</sup>). These values are in accordance with the data reported in the literature (26).

NMO patients had significantly smaller cervical spinal cord area than healthy controls ( $T_{\text{test}} = 0.009$ ). Similar results were also found by adding the age as a covariate ( $T_{\text{test}} = 0.007$ ), which confirms that the age has a limited effect on the cervical spinal cord area (26).

### **Correlation between mean-CSA and clinical and MRI characteristics in patients with NMO**

A smaller mean-CSA was associated with clinical signs of medullary involvement including bowel or bladder dysfunction, movement disorders, and sensory disturbances ( $T_{\text{test}} = 0.0006$ ).

There was a tendency toward a relation between cervical spinal cord atrophy and EDSS ( $T_{\text{test}} = 0.07$ ). This correlation was statistically significant ( $T_{\text{test}} < 0.05$ ) at the level of the upper cervical spinal cord (C2-C3). (Figure 2)

Cervical spinal cord atrophy was associated with the sensory FSS ( $T_{\text{test}} = 0.006$ ), and there was a tendency toward a relationship between the former and the pyramidal FSS ( $T_{\text{test}} = 0.06$ ), and bowel/bladder FSS ( $T_{\text{test}} = 0.09$ ).

Logically, no correlation was found between cervical spinal cord atrophy and visual FSS ( $T_{\text{test}} = 0.34$ ).

There was also a trend toward an association between a smaller mean-CSA and disease duration ( $T_{\text{test}} = 0.14$ ), the number of relapses ( $T_{\text{test}} = 0.10$ ), and the number of relapses with a spinal cord involvement ( $T_{\text{test}} = 0.14$ ).

A similar but sharper trend was found toward an association between a lower mean-CSA and the presence of T2 hyperintense lesions in the cervical spinal cord ( $T_{\text{test}} = 0.09$ ) and their extensions in height ( $T_{\text{test}} = 0.09$ ).

## **Discussion**

This is the first study to evaluate cervical spinal cord atrophy with MRI scanning in NMOSD by studying the entire cervical spinal cord, in particular, the lower cervical spinal cord. In the first studies addressing this issue, cervical spinal cord atrophy was evaluated visually (22) or was defined as a sagittal diameter of  $\leq 4$ mm on T1-weighted sequences

(23). More recently, Wang et al. (21) measured a focal upper cervical spinal cord volume from C2 to C3, and Liu et al. (27) a mean upper cervical cord area. In the present study, mean-CSA was 68.5 mm<sup>2</sup> in the population of the NMO patients (range, 54.7–82.2 mm<sup>2</sup>) and 72.8 mm<sup>2</sup> in the population of healthy individuals (range, 57.6–87.5 mm<sup>2</sup>). These values are in compliance with the data reported in the literature (26). Ullrich et al. (26) defined normative ranges for the areas of the cervical spinal cord at C1, C3, and C6 for men and women. Moreover, they extracted data for three different height subgroups at the age of 45 years. In this study, the area of the cervical spinal cord remained almost identical from C1 to C6, while the anterior-posterior diameter of the cervical spinal cord decreased from C1 to C6. This is because the spinal cord area shape broadens at the lower levels, from circular at the C1 level to elliptical at the C6 level. Within each spinal level, the area of the spinal cord increases with body height. This is why choosing the mean-CSA rather than the volume of the cervical spinal cord enables us to remove the bias of body height. As indicated above, age has a limited effect on the cervical spinal cord area (26). None of the subjects had experienced a relapse or received a treatment with corticosteroids within the 3 months prior to imaging, to prevent inaccurate measurement of the cervical spinal cord volumes. Such exclusion criteria are used in the studies measuring brain and spinal cord volumes. Indeed, it is now certain that brain and spinal cord volumes may transiently decrease or increase for several weeks simply as the result of the acute effects of immune-mediated therapies (decreasing the volume) or during disease activity (increasing the volume) (28). Corticosteroids are frequently used to treat acute relapse in NMOSD, while high doses of intravenous corticosteroids are known to lead to reductions in volume after they are newly started, an effect lasting from weeks to months (29). The present study demonstrated the presence of cervical spinal cord atrophy in patients with NMO in comparison to healthy subjects ( $T_{\text{test}} = 0.009$ ). Studies focusing on cervical spinal cord atrophy in NMOSD are rare (21–23, 27). The first studies concluded that the

frequency of spinal cord atrophy in NMO patients was 14%, 52%, and 57% (21,22,23). In the study conducted by Wang et al. (21), the prevalence of spinal cord atrophy was 14% in 185 adult Chinese patients with NMOSD. Cassinotto and al. (22) studied the MRI data of 20 Afro-Caribbean patients diagnosed with either NMO or recurrent longitudinal extensive myelitis. Visually, cord atrophy was evident in 57% and was often associated with a pseudo-dilation of the ependymal canal. Asgari et al. (23) assessed spinal cord atrophy in 23 Danish NMO patients. Spinal cord atrophy was defined as a sagittal diameter of  $\leq 4$ mm on T1-weighted sequences and was seen in 52% of the subjects. More recently, Liu et al. (27) recruited 35 patients with NMO and 35 healthy subjects. Patients with NMO showed smaller mean upper cervical cord area (MUCCA) than healthy individuals ( $p=0.004$ ). Cervical spinal cord atrophy was strongly associated with clinical signs of medullary involvement, including bowel or bladder dysfunction, as well as mobility and sensory disturbances. These results are comparable to those of Wang et al. (21), who measured a focal upper cervical spinal cord volume from C2 to C3. In this study, compared to subjects without spinal cord atrophy, those with spinal cord atrophy presented more frequently with bowel or bladder dysfunction, movement disorders, and sensory disturbances (21). The clinical feature most likely to reflect spinal cord damage, namely the EDSS score for pyramidal, cerebellar, brainstem, sensory, visual, intellectual, and bowel and bladder dysfunction, was moderately associated with mean-CSA on the entire cervical spinal cord ( $T_{\text{test}} = 0.07$ ). In NMOSD patients, it has previously been observed that cervical spinal cord atrophy correlates well with measures of disability (21-23). In our study, a strong correlation ( $T_{\text{test}} < 0.05$ ) was observed between upper cervical spinal cord atrophy (C2-C3) and clinical disability as measured by neurological assessment (EDSS). Therefore, the upper cervical spinal cord seems more involved in the development of clinical disability in NMOSD patients than the lower cervical spinal cord. More precisely, cervical spinal cord

atrophy was associated with the sensory FSS (Ttest = 0.006). Concerning the pyramidal FSS and the bowel/bladder FSS the results are just above the significance threshold.

The correlation between disability and cervical cord atrophy is a common finding in MS and NMOSD research and can be explained by the composition of this structure: the cervical cord contains all descending corticospinal fibers destined for motor units in the trunk, arms, and legs. Therefore, damage in this region is likely to have a disproportionately severe effect on locomotor functions compared to damage to the brain or other cord segments.

Cervical spinal cord atrophy was also partially correlated to disease duration, suggesting a cumulative effect with time of all pathologic processes leading to irreversible tissue loss in the cord.

The absence of a statistically significant correlation between cervical spinal cord atrophy and cervical spinal cord lesions (presence of T2 hyperintense lesions and their extensions in height) is consistent with imaging findings in MS reported by Rocca et al. (15), Lukas et al. (30), and Schlaeger et al. (31) and with histopathologic studies in which it has been suggested that spinal cord atrophy is largely independent of lesion tissue loss (32).

Unfortunately, because we did not map the distribution of focal cord lesions, we cannot determine whether localized atrophy developed in the region of focal T2 lesions. However, the notion that individual lesions play a minor role in local atrophy of the cord is supported by previous pathologic (15, 30, 31) and in vivo (32) studies of atrophy, which have suggested that Wallerian degeneration of long fiber tracts, rather than local damage to these tracts, is one of the main factors leading to tissue loss in the cord.

For this study, we chose a T2-weighted spin-echo sequence in view of the conclusions of Kim et al. (33). Indeed, T2-weighted images may prove effective for measuring cervical spinal cord atrophy in MS, showing comparable effect sizes to T1-weighted images with the added advantage of lesion detectability(33). The accurate localization technique for

identifying cervical spinal cord atrophy in NMOSD used in this study holds promise for improving our understanding of the mechanisms responsible for the accumulation of irreversible disability in this condition. Cord pathology plays an important role in the development of irreversible clinical disability in NMOSD, and the quantification of cord atrophy might provide useful surrogate markers to monitor disease progression. Finally, mean-CSA quantification in the context of a multicenter study would be useful. A single operator could take all the measurements, giving more reliable results than multiple operators. This would be feasible because of the relatively short time required to measure mean-CSA with our method (approximately 5 min per measurement).

Some limitations apply to this work. Firstly, since this is a rare disease, the cohort consisted of only 15 patients in a monocentric study. In addition, several studies in MS suggested using normalization factors for spinal cord measurements (i.e., cord length, body mass index, or intracranial volume)(34,35). Various recent studies have indicated, however, that the ability of these factors to improve discrimination between groups is generally minor (35,36,37). Therefore, we did not normalize mean-CSA measurements. Finally, image quality in this study did not allow for a reliable distinction between gray and white matter within the cervical spinal cord; therefore, at present, we cannot determine whether cord atrophy is caused by loss of white matter rather than gray matter, as suggested by results of a histopathological study (36). The in vivo assessment of the relative contributions of these two tissue compartments to overall atrophy remains an open question for future MRI studies utilizing advanced high-spatial-resolution MRI sequences (37).

In conclusion, this study provides the first evidence of cervical spinal cord atrophy in NMOSD by studying the entire cervical spinal cord. This atrophy was strongly associated with clinical signs of medullary involvement. Upper cervical spinal cord atrophy was also strongly correlated to clinical disability and seems more involved in its development in

NMOSD patients than lower cervical spinal atrophy.

## **Abbreviations**

AQP4 : Aquaporin-4

CSA : Cross sectional-area

EDSS : Expanded Disability Status Scale

FSS : Functional system scores

HC : Healthy controls



LETM : Longitudinally extensive transverse myelitis

MS : Multiple sclerosis

MRI : Magnetic Resonance Imaging

MUCCA : Mean upper cervical cord area

NMO : Neuromyelitis optica

NMOSD : Neuromyelitis optica spectrum of disorders

SCT : Spinal Cord Toolbox

## References

- 1) Jarius S, Wildemann B, "The history of Neuromyelitis optica", *J. Neuroinflammation*, 2013 Jan 15,10:8
- 2) Levin MH, Bennett JL, Verkman AS, "Optic neuritis in neuromyelitis optica ", *Prog Retin Eye Res*, 2013 Sep; 36:159-71
- 3) Wingerchuk DM, Lennon VA, Lucchinetti CF, Pittock SJ, Weinshenker BG, "The spectrum of neuromyelitis optica", *Lancet Neurol.*, 2007 Sep; 6(9):805-15
- 4) Morrow MJ, Wingerchuk D, "Neuromyelitis optica", *J Neuroophthalmol.*, 2012 Jun ; 32(2):154-66
- 5) Nielsen S, Nagelhus EA, Amiry-Moghaddam M, Bourque C, Agre P, Ottersen OP, " Specialized membrane domains for water transport in glial cells : high-resolution

- immunogold cytochemistry of aquaporin-4 in rat brain" *J Neurosci.*, 1997 Jan 1 ; 17(1) : 171-80
- 6) Ameli R, R G Guttmann C, Prieto JC, Rollot F, Palotai M, Vukusic S, Marignier R, Cotton F, "Aquaporin 4 distribution in the brain and its relevance for the radiological appearance of neuromyelitis optica spectrum disease" *J Neuroradiol.*, 2019 Apr 11. pii: S0150-9861(18)30337-7. doi: 10.1016/j.neurad.2019.03.015.
  - 7) Denève M, Biotti D, Patsoura S, Ferrier M, Meluchova Z, Mahieu L, Heran F, Vignal C, Deschamps R, Gout O, Champfleury NM, Ayrignac X, Dallièrre CC, Labauge P, Dulau C, Tourdias T, Dumas H, Cognard C, Brassat D, Bonneville F. "MRI features of demyelinating disease associated with anti-MOG antibodies in adults" *J Neuroradiol.*, 2019 Sep;46(5):312-318. doi: 10.1016/j.neurad.2019.06.001.
  - 8) Lennon VA, Kryzer TJ, Pittock SJ, Verkman AS, Hinson SR, "IgG marker of optic-spinal multiple sclerosis binds to the aquaporin-4 water channel", *J Exo Med*, 2005 Aug 15;202(4):473-7
  - 9) Chanson JB, Alame M, Collongues N, Blanc F, Fleury M, Rudolf G, de Seze J, Vincent T, "Evaluation of clinical interest of anti-aquaporin-4 autoantibody follow-up in neuromyelitis optica", *Clin Dev Immunol*, 2013;2013:146219. Epub 2013 Apr 28
  - 10) Kim HJ, Paul F, Lana-Peixoto MA, Tenembaum S, Asgari N, Palace J, Klawiter EC, Sato DK, de Seze J, Wuerfel J, Banwell BL, Villoslada P, Saiz A, Fujihara K, Kim SH, Guthy-Jackson Charitable Foundation NMO International Clinical Consortium and Biorepository, "MRI characteristics of neuromyelitis optica spectrum disorder : an international update", *Neurology*, 2015 Mar 17;84(11):1165-73
  - 11) Flanagan EP, Weinshenker BG, Krecke KN, Lennon VA, Lucchinetti CF, McKeon A, Wingerchuk DM, Schuster EA, Jiao Y, Horta ES, Pittock SJ, "Short myelitis lesions in aquaporin-4-IgG-positive neuromyelitis optica spectrum disorders", *JAMA Neurol*, 2015 Jan;72(1):81-7
  - 12) Losseff NA, Webb SL, O'Riordan JI, Page R, Wang L, Barker GJ, Tofts PS, McDonald WI, Miller DH, Thompson AJ, " Spinal cord atrophy and disability in multiple sclerosis. A new reproducible and sensitive MRI method with potential to monitor disease progression", *Brain*, 1996 Jun;119 (Pt 3):701-8
  - 13) Cohen AB, Neema M, Arora A, Dell'oglio E, Benedict RH, Tauhid S, Goldberg-Zimring D, Chavarro-Nieto C, Ceccarelli A, Klein JP, Stankiewicz JM, Houtchens MK, Buckle GP, Alsop DC, Guttmann CR, Bakshi R, "The relationships among MRI-defined spinal cord involvement, brain involvement, and disability in multiple sclerosis", *J Neuroimaging*, 2012 Apr;22(2):122-8
  - 14) Valsasina P, Rocca MA, Horsfield MA, Absinta M, Messina R, Caputo D, Comi G, Filippi M, "Regional cervical cord atrophy and disability in multiple sclerosis : a voxel-based analysis", *Radiology*, 2013 Mar, 266(3): 853-61
  - 15) Rocca MA, Horsfield MA, Sala S, Copetti M, Valsasina P, Mesaros S, Martinelli V, Caputo D, Stosic-Opincal T, Drulovic J, Comi G, Filippi M, "A multicenter assessment of cervical cord atrophy among MS clinical phenotypes", *Neurology*, 2011 Jun 14;76(24):2096-102

- 16) Zivadinov R, Banas AC, Yella V, Abdelrahman N, Weinstock-Guttman B, Dwyer MG, "Comparison of three different methods for measurement of cervical cord atrophy in multiple sclerosis", *AJNR Am J Neuroradiol*, 2008 Feb; 29(2):319-25
- 17) Kearney H, Yiannakas MC, Abdel-Aziz K, Wheeler-Kingshott CA, Altmann DR, Ciccarelli O, Miller DH, "Improved MRI quantification of spinal cord atrophy in multiple sclerosis", *J Magn Reson Imaging*, 2014 Mar;39(3):617-23
- 18) Blanc F, Noblet V, Jung B, Rousseau F, Renard F, Bourre B, Longato N, Cremel N, Di Bitonto L, Kleitz C, Collongues N, Foucher J, Kremer S, Armspach JP, de Seze J, "White matter atrophy and cognitive dysfunctions in neuromyelitis optica", *PLoS One*, 2012;7(4). Epub 2012 Apr 3.
- 19) Sanchez-Catasus CA, Cabrera-Gomez J, Almaguer Melian W, Giroud Benitez JL, Rodriguez Rojas R, Bayard JB, Galan L, Sanchez RG, Fuentes NP, Valdes-Sosa P, "Brain Tissue Volumes and Perfusion Change with the Number of Optic Neuritis Attacks in Relapsing Neuromyelitis Optica : A Voxel-Based Correlation Study", *PLoS One*, 2013 Jun 18;8(6)
- 20) Duan Y, Liu Y, Liang P, Jia X, Yu C, Qin W, Sun H, Liao Z, Ye J, Li K, "Comparaison of grey matter atrophy between patients with neuromyelitis optica and multiple sclerosis : a voxel-based morphometry study", *Eur J Radiol*, 2012 Feb;81(2). Epub 2011 Feb 11.
- 21) Wang Y, Wu A, Chen X, Zhang L, Lin Y, Sun S, Cai W, Zhang B, Kang Z, Qiu W, Hu X, Lu Z, "Comparison of clinical characteristics between neuromyelitis optica spectrum disorders with and without spinal cord atrophy", *BMC Neurol*, 2014 Dec 20;14(1):246
- 22) Cassinotto C, Deramond H, Olindo S, Aveillan M, Smadja D, Cabre P, "MRI of the spinal cord in neuromyelitis optica and recurrent longitudinal extensive myelitis", *J Neuroradiol*. 2009 Oct;36(4):199-205
- 23) Asgari N, Skejoe HP, Lillevang ST, Steenstrup T, Stenager E, Kyvik KO, "Modifications of longitudinally extensive transverse myelitis and brainstem lesions in the course of neuromyelitis optica(NMO): a population-based, descriptive study", *BMC Neurol*. 2013 Apr 8;13:33
- 24) Wingerchuk DM, Banwell B, Bennett JL, Cabre P, Carroll W, Chitnis T, de Seze J, Fujihara K, Greenberg B, Jacob A, Jarius S, Lana-Peixoto M, Levy M, Simon JH, Tenenbaum S, Traboulsee AL, Waters P, Wellik KE, Weinshenker BG, "International consensus diagnostic criteria for neuromyelitis optica spectrum disorders", *Neurology*. 2015 Jun 19
- 25) De Leener B, Levy S, Dupont SM, Fonov VS, Stikov N, Louis Collins D, Callot V, Cohen-Adad J. SCT: Spinal Cord Toolbox, an open-source software for processing spinal cord MRI data. *Neuroimage* 2016
- 26) Ulbrich EJ, Schraner C, Boesch C, Hodler J, Busato A, Anderson SE, Eigenheer S, Zimmermann H, Sturzenegger M, "Normative MR cervical spinal canal dimensions ", *Radiology*, 2014 Apr;271(1):172-82.
- 27) Liu Y, Wang J, Daams M, et al. "Differential patterns of spinal cord and brain atrophy in NMO and MS", *Neurology*, 2015 Apr 7;84(14):1465-72
- 28) Houry S, Bakshi R, "Cerebral pseudoatrophy or real atrophy after therapy in

- multiple sclerosis", *Ann Neurol.*, 2010 Dec;68(6):778-9
- 29) Fox RJ, Fisher E, Tkach J, Lee JC, Cohen JA, Rudick RA, "Brain atrophy and magnetization transfer ratio following methylprednisolone in multiple sclerosis: short-term changes and long-term implications" *Mult Scler.*, 2005 Apr;11(2):140-5
- 30) Lukas C, Sombekke MH, Bellenberg B, Hahn HK, Popescu V, Bendfeldt K, Radue EW, Gass A, Borgwardt SJ, Kappos L, Neagelin Y, Knol DL, Polman CH, Geurts JJ, Barkhof F, Vrenken H "Relevance of spinal cord abnormalities to clinical disability in multiple sclerosis : MR imaging findings in a large cohort of patients", *Radiology*, 2013 Nov;269(2):542-52
- 31) Schlaeger R, Papinutto N, Panara V, Bevan C, Lobach IV, Bucci M, Caverzasi E, Gelfand JM, Green AJ, Jordan KM, Stern WA, von Büdingen HC, Waubant E, Zhu AH, Goodin DS, Cree BA, Hauser SL, Henry RG, "Spinal cord gray matter atrophy correlates with multiple sclerosis disability", *Ann Neurol*, 2014 Oct;76(4):568-80
- 32) Evangelou N, DeLuca GC, Owens T, Esiri MM, "Pathological study of spinal cord atrophy in multiple sclerosis suggests limited rôle of local lesions", *Brain*, 2005;128(Pt1):29-34
- 33) Kim G, Khalid F, Oommen VV, Tauhid S, Chu R, Horsfield MA, Healy BC, Bakshi R, "T1- vs. T2-based MRI measures of spinal cord volume in healthy subjects and patients with multiple sclerosis.", *BMC Neurol*, 2015 Jul 31;15:124
- 34) Song F, Huan Y, Yin H, Ge Y, Wei G, Chang Y, Zhao H "Normalized upper cervical spinal cord atrophy in multiple sclerosis", *J Neuroimaging*, 2008, Jul;18(3):320-7
- 35) Zivadinov R, Banas AC, Yella V, Abdelrahman N, Weinstock-Guttman B, Dwyer MG, "Comparison of three different methods for measurement of cervical cord atrophy in multiple sclerosis", *AJNR Am J Neuroradiol*, 2008 Feb;29(2):319-25
- 36) Healy BC, Arora A, Hayden DL, Ceccarelli A, Tauhid SS, Neema M, Bakshi R, "Approaches to normalization of spinal cord volume : application to multiple sclerosis", *J Neuroimaging*, 2012 Jul;22(3):e12-9
- 37) Daams M, Weiler F, Steenwijk MD, Hahn HK, Geurts JJ, Vrenken H, van Schijndel RA, Balk LJ, Tewarie PK, Tillema JM, Killesstein J, Uitdehaag BM, Barkhof F, "Mean upper cervical cord area (MUCCA) measurement in long-standing multiple sclerosis: relation to brain findings and clinical disability", *Mult Scler.*, 2014 Dec;20(14):1860-5

The authors declare no conflict of interests

Figure 1: Image post-processing

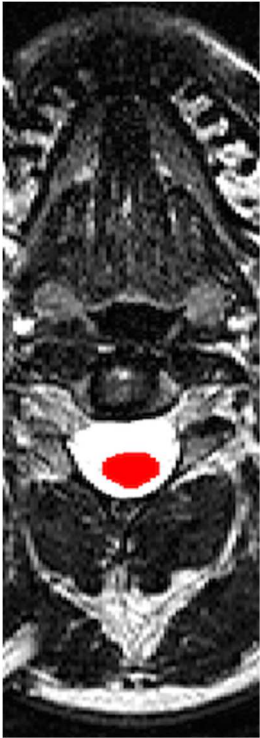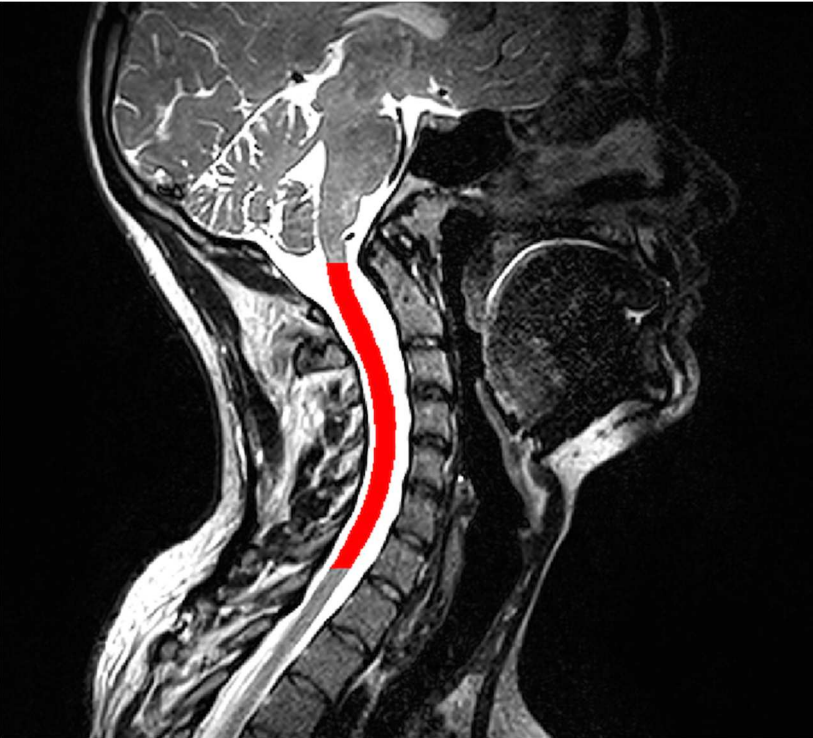


Figure 2 : Statistical correlations between EDSS and focal CSA according to the medullary level (p-value are reported in ordinate axis)

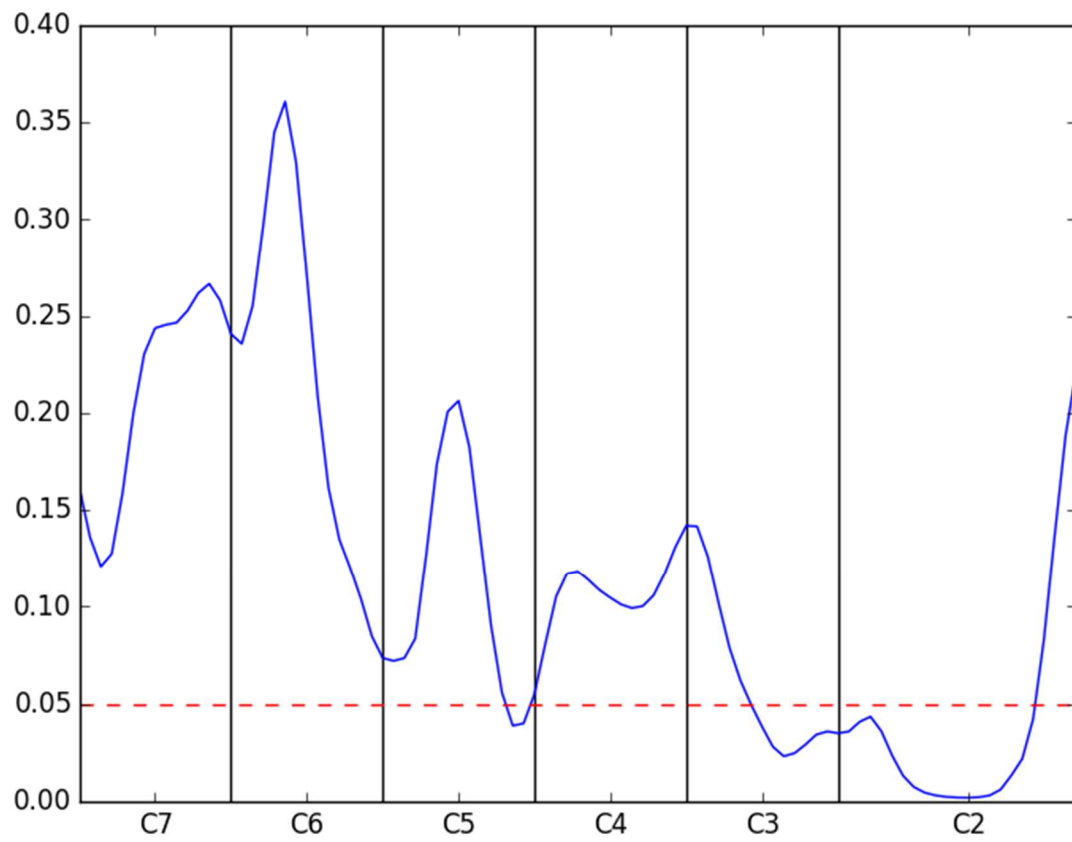


Table 1 : Demographic and clinicobiological characteristics of the patients

	Sex*	Age	Age at the beginning of the disease	Disease duration in years	Numbers of relapses	Numbers of relapses with medullary inv.	Deadline since the last medullary relapse in years	Clinical signs of medullary inv.	NMO-IgG
<b>NMO 1</b>	F	34	17	17	9	8	12	+	+
<b>NMO 2</b>	M	47	40	7	7	4	2	+	-
<b>NMO 3</b>	F	41	34	7	1	1	7	+	-
<b>NMO 4</b>	F	60	42	18	5	4	6	+	+
<b>NMO 5</b>	F	45	28	17	4	4	0,25	+	-
<b>NMO 6</b>	F	28	15	13	8	0	Not possible	-	+
<b>NMO 7</b>	F	43	34	9	6	5	0,5	-	-
<b>NMO 8</b>	M	38	32	6	13	12	0,25	+	-
<b>NMO 9</b>	F	52	38	14	16	11	3	+	+
<b>NMO 10</b>	F	50	17	33	6	5	0,25	+	-
<b>NMO 11</b>	F	57	50	7	7	7	0,5	+	+
<b>NMO 12</b>	F	64	55	9	3	1	3	+	+
<b>NMO 13</b>	F	56	56	0,5	1	0	Not possible	-	+
<b>NMO 14</b>	M	67	54	13	14	13	1	+	+
<b>NMO 15</b>	F	66	57	9	6	3	0,25	+	+

\* M=Male, F=Female

inv.=involvement

**Table 2 : Disability and MRI characteristics of the patients**

	EDSS	Pyr. FSS	Sen. FSS	BB FSS	Visual FSS	T2 hyperintense lesions in the cervical spinal cord	Extension in height of the T2 hyperintense lesions in the cervical spinal cord *	Mean-CSA (mm <sup>2</sup> )
<b>NMO 1</b>	3,5	0	1	1	1	+	Greater than 2/3	68,3
<b>NMO 2</b>	4	1	2	3	4	+	Between 1/3 and 2/3	67,9
<b>NMO 3</b>	2	2	1	1	0	-	0	73,2
<b>NMO 4</b>	6,5	4	2	1	0	+	Between 1/3 and 2/3	71,1
<b>NMO 5</b>	7	4	2	3	0	+	Lower than a 1/3	65,5
<b>NMO 6</b>	0	0	0	0	0	+	Between 1/3 and 2/3	75,7
<b>NMO 7</b>	0	0	0	0	0	+	Lower than a 1/3	74,2
<b>NMO 8</b>	1,5	1	1	1	0	+	Lower than a 1/3	82,2
<b>NMO 9</b>	1	0	1	0	1	+	Lower than a 1/3	57,6
<b>NMO 10</b>	2	1	2	0	0	+	Lower than a 1/3	64,2
<b>NMO 11</b>	4	2	2	1	0	-	0	66,5
<b>NMO 12</b>	6	4	2	2	0	+	Lower than a 1/3	54,7
<b>NMO 13</b>	0	0	0	0	0	-	0	81,9
<b>NMO 14</b>	1,5	1	1	1	0	+	Between 1/3 and 2/3	65,6
<b>NMO 15</b>	3	3	2	2	0	+	Lower than a 1/3	59,1
							Average value	68,5

Pyr. = Pyramidal

Sen. = Sensory

BB = Bowel/Bladder

\* : the extension in height was visually estimated : lower than one-third, between one-third and two-thirds, greater than two-thirds of the height of the cervical spinal cord



Table 3: Healthy controls demographic characteristics and mean-CSA

<b>Number of the healthy control</b>	<b>Sex</b>	<b>Age</b>	<b>Mean-CSA (mm<sup>2</sup>)</b>
1	Woman	44	68,4
2	Woman	33	86,5
3	Woman	37	77,1
4	Woman	38	83,3
5	Men	61	85,1
6	Woman	59	72,5
7	Woman	26	64,6
8	Woman	40	67,1
9	Men	28	87,5
10	Woman	68	59
11	Woman	78	57,6
12	Woman	67	58,6
13	Men	65	69,8
14	Men	72	75,4
15	Men	28	80,4
			Average value : 72,8