



Current results of left gonadal vein transposition to treat nutcracker syndrome

Anaïs Debucquois, Lucie Salomon Du Mont, Wilfried Bertho, Adrien Kaladji, Olivier Hartung, Simon Rinckenbach

► To cite this version:

Anaïs Debucquois, Lucie Salomon Du Mont, Wilfried Bertho, Adrien Kaladji, Olivier Hartung, et al.. Current results of left gonadal vein transposition to treat nutcracker syndrome. *Journal of Vascular Surgery: Venous and Lymphatic Disorders*, 2021, 9 (6), pp.1504-1509. 10.1016/j.jvsv.2021.03.003 . hal-03229079

HAL Id: hal-03229079

<https://hal.science/hal-03229079>

Submitted on 19 May 2021

HAL is a multi-disciplinary open access archive for the deposit and dissemination of scientific research documents, whether they are published or not. The documents may come from teaching and research institutions in France or abroad, or from public or private research centers.

L'archive ouverte pluridisciplinaire **HAL**, est destinée au dépôt et à la diffusion de documents scientifiques de niveau recherche, publiés ou non, émanant des établissements d'enseignement et de recherche français ou étrangers, des laboratoires publics ou privés.

Current results of left gonadal vein transposition to treat Nutcracker Syndrome

Short Title: Left gonadal vein transposition

Anaïs Debucquois, Department of Vascular and Endovascular Surgery, University Hospital of Besançon, Lucie Salomon du Mont MD, PhD, Department of Vascular and Endovascular Surgery, University Hospital of Besançon, Wilfried Bertho, Department of Vascular and Endovascular Surgery, University Hospital of Rennes, Adrien Kaladji MD, PhD, Department of Vascular and Endovascular Surgery, University Hospital of Rennes, Olivier Hartung MD, PhD, Department of Vascular and Endovascular Surgery, University Hospital of Marseille-Nord, Simon Rinckenbach MD, PhD, Department of Vascular and Endovascular Surgery, University Hospital of Besançon

Corresponding author : Anaïs Debucquois, Service de Chirurgie Vasculaire et Endovasculaire, CHU Jean Minjoz, 3 Boulevard Alexandre Fleming, 25000 Besançon, France, anaisdebucquois@gmail.com, +33 3 81 66 80 52

Post-publication corresponding author : Simon Rinckenbach, MD, PhD, Service de Chirurgie Vasculaire et Endovasculaire, CHU Jean Minjoz, 3 Boulevard Alexandre Fleming, 25000 Besançon, France, srinckenbach@chu-besancon.fr, +33 3 81 66 80 52

Article Highlights:

Type of Research: Multicenter, retrospective, observational study

Key Findings: Severe Nutcracker syndromes were treated by left gonadal vein transposition into the iliac vein by retroperitoneal approaches in 10 cases and into the inferior vena cava by midline

laparotomy in one case, leading to pain relief and resolution of hematuria.

Take home Message: Left gonadal vein transposition may be proposed as a first approach to treat severe nutcracker syndrome if the diameter of the left gonadal vein is sufficient.

Table of Contents Summary:

We present a multicenter retrospective study with 11 patients treated by transposition of the left gonadal vein for Nutcracker syndrome, finding pain relief, total resolution of hematuria, reduction of pelvic varicose veins and a low complication rate.

1 ABSTRACT:

2 Objective: Nutcracker syndrome can cause disabling chronic pain requiring surgical intervention.

3 Presently, there is a lack of data to describe a straightforward management approach.

4 Transposition of the left gonadal vein is one of the surgical therapeutic alternatives. The aim of
5 this work was to describe our clinical results with gonadal vein transposition.

6 Methods: All patients from 3 centers who had left gonadal vein transposition for nutcracker
7 syndrome between 2016 and 2019 were retrospectively included. Surgical cases were mainly
8 selected based on morphological criteria of the left gonadal vein. Diameter and length dictated
9 the type of approach, laparotomy or retroperitoneal, and the transposition level. Minimal
10 invasive retroperitoneal approach was preferred. Pain was assessed with a numerical rating scale.

11 Results: We included 11 patients (10 women) with a median age of 35 years [25; 69].

12 Preoperative computed tomography angiography showed anterior nutcracker syndrome in 10
13 cases (91%). All patients suffered from lower back and/or pelvic pain associated with pelvic
14 congestion syndrome in 6 cases (55%), and hematuria in 5 cases (45%). Preoperative numerical
15 rating scale assessment found a median pain score of 7.0 [3.5; 10.0] and 6.0 [3.5; 8.0]
16 respectively for lower back and pelvic pain. At the level of iliac vein crossing (external or
17 common), the median diameter of the left gonadal vein was 7.87 mm [6.45 ;11.28]. The left
18 gonadal vein was transposed to the inferior vena cava in 1 case (9%), the left external iliac vein
19 in 5 cases (45%) and the left common iliac vein in 5 cases (45%). The median in-hospital stay
20 was 4 days [2; 20]. Two early complications (18%) requiring surgical revision occurred: 1 active
21 bleeding and 1 hematoma. Median follow-up was 15 months [6; 44], postoperative median pain
22 assessment was 1.0 [0.0; 4.0] and 0.0 [0.0; 6.0] respectively for lower back and pelvic pain.
23 Incisional and/or neuropathic pain was noted with a median rating of 3.5 [1.0; 6.0] in 7 patients

1 (64%). Two late complications (18%) were observed, namely one thrombosis and one
2 anastomotic stenosis. Hematuria disappeared in all patients who presented with it initially.
3 Conclusions: Left gonadal vein transposition may be proposed as a first approach if the diameter
4 of the left gonadal vein is sufficient to perform the anastomosis. It is an easily achievable,
5 minimally invasive alternative that achieves satisfactory results without any foreign material.

1 Keywords: Nutcracker Syndrome, Left gonadal vein transposition, pelvic congestion syndrome

2

3 Conflict of interest disclosure: The authors have no competing interests.

INTRODUCTION

Nutcracker syndrome (NCS) corresponds, in the majority of cases, to the compression of the left renal vein (LRV) between the abdominal aorta and the superior mesenteric artery (SMA)¹. The result is an increase in pressure in the LRV and its collaterals, which can lead to several symptoms, varying in severity: abdominal pain, left flank pain, hematuria, orthostatic proteinuria, atypical varicose veins or pelvic congestion syndrome.

There is still a lack of data to underpin unequivocal patient management. Therefore, there are many surgical options, ranging from the most to the least invasive: nephrectomy², left kidney autotransplantation²⁻⁵, nephropexy^{2,3,6}, SMA transposition^{2,6,7}, LRV transposition (with or without adjunctive patch)^{2-4,6,8-10}, renocaval bypass^{2,4}, gonadal venous bypass^{3,4,10,11}, laparoscopic extravascular stent placement^{2,6,12} or LRV stenting^{2,4,6,10,13,14}.

Gong et al., first reported in 2012 three cases of left gonadal vein (LGV) transposition to the iliac vein, with promising results at 3 months. The authors advocated a simple, minimally invasive approach¹⁵. Other theoretical advantages of this technique include the absence of any need for foreign material, the use of an already adapted reverse flow in the LGV, which may guarantee a certain durability. More recently, Gilmore et al. published 18 cases of transposition in a standardized approach with median laparotomy⁴. In our practice, we tend to adjust the type of approach according to the LGV morphology, leading to a small retroperitoneal approach when feasible.

The goal of this study was to describe our experience of LGV transposition for the treatment of NCS. The aim was to describe clinical results, complications and results in terms of pain improvement.

METHODS

All patients from three French university hospitals, who underwent LGV transposition for NCS from January 2016 to December 2019 were retrospectively collected. Our institutional review board approved the present study and waived the requirement for informed consent.

Demographics and clinical data (age, gender, presence or absence of varicose veins and location, presence or absence of pelvic congestion syndrome, pain and location, gestations), biological data (hematuria, proteinuria, creatinuria) were retrospectively collected, pre and postoperatively. Abdominal and pelvic computed tomography angiography (CTA), abdominal Doppler Ultrasound (DUS), and digital subtraction venography with renocaval pressure gradient measurements were performed in patients with possible nutcracker syndrome. Pain was assessed using the Numerical Rating Scale (NRS)¹⁶.

Diagnosis:

We first eliminated all gynecological causes of pelvic pain.

The diagnosis of NCS was based on the combination of the clinical assessment, CTA, and venography findings with or without a renocaval pressure gradient ≥ 3 mmHg. The phlebography procedure was performed with echo-guided puncture of the left femoral vein under local anesthesia (lidocaine 10mg/ml), introducing a short (12cm) 6 Fr sheath. Phlebography had to include ilio-cavography to look for an associated ilio-caval obstructive lesion (mainly May-Thurner syndrome (MTS)) with injection of 5ml of iodinated contrast product diluted with 5ml of saline serum. Then, LRV angiography was performed using a 6Fr guiding-catheter or a 6Fr long sheath in order to perform the reno-caval gradient measurement with a guidewire in place to avoid catheter tip positioning in touch with the vein wall. The LGV had to be opacified to check for incompetence and anatomy (confluence level) (Figure 1). Pressure measurements were

performed at the level of the LRV, the inferior vena cava (IVC) and the left iliac vein. In case of absence of any differences, a right common femoral vein sheath was inserted and the LGV was catheterized in parallel, and an adequate sized balloon was inflated in the LGV in order to stop the reflux. A gradient $<3\text{mmHg}$ didn't eliminate the diagnosis. Indeed, patients could have no fluctuance of their LRV pressure according to cardiac activity while they had fluctuance in the IVC, due to a significant narrowing of the LRV able to stop the cardiac activity fluctuance in the LRV.

When intravascular ultrasound (IVUS) was required (CORE M2 Vascular System, Volcano Corporation Europe®, Zaventem, Belgium), the left common femoral vein sheath was changed for a 9Fr and the IVUS catheter (VISION PV.35, Volcano Corporation Europe®, Zaventem, Belgium) was advanced from the LRV down to the common femoral vein.

Patient selection

Patients were selected for LGV transposition based on morphological criteria, and pelvic symptoms. Thus, the necessary condition for the LGV transposition was, in our experience, an LGV diameter of at least 6 mm, at the level of the planned anastomosis. A dilated LGV (normal diameter is less than 5 mm¹⁷) is necessary to perform the anastomosis without an elevated risk of stenosis. A satisfactory reflux is also necessary in the LGV to ensure long-term patency. The level of implantation was mainly at the site of the natural crossing of the LGV with the left common (5 cases) or external (5 cases) iliac vein. In one case, the implantation needed to be at the level of the IVC because of an abdominal confluence of the pelvic branches and a short LGV trunk.

Surgical procedure:

Surgery was performed under general anesthesia, in the Trendelenburg and supine

position through left retroperitoneal approach or midline laparotomy, depending on the anastomosis site.

For ten cases, a left retroperitoneal approach was used, with an incision of about 5 centimeters.

In one case, this step was conducted through a small midline laparotomy.

The LGV was then dissected and ligated in its most distal segment (Figure 2). Collaterals identified on the initial venography were ligated. The anastomosis site was defined according to the location of the LGV – iliac vein crossing, and based on peri-operative findings. The common or external iliac vein was then dissected and clamped after systemic intravenous heparinization at 0.5 IU/kg. The gonadal vein was transected and anastomosed by a 7-0 polypropylene (Prolene, Ethicon®, Somerville, New Jersey, USA) running suture on the common or external left iliac vein (Figure 3). In order to avoid the purse-stringing of the suture line, the suture was knotted after clamp release.

The post-operative anticoagulation protocol was at the surgeon's discretion, and mainly consisted in one month of treatment with low molecular weight heparin (Enoxaparin 4000 IU per day). Thereafter, an antiplatelet agent (e.g. acetylsalicylic acid 75mg per day) was introduced in a long-term protocol.

Post-operative follow-up:

Patients were followed up according to the surgeon's recommendations. All patients had a follow-up visit within 4 to 6 weeks, with a Duplex scan or a CT scan (91% of cases). Then, two of the centers performed an annual Duplex scan for the first two years, while patients from the third center only attended follow-up in case of symptom recurrence.

Statistical analysis:

Data analysis was only observational. Continuous variables are presented as median

- 1 [range] and categorical variables as number (percentage).

RESULTS

Between January 2016 and December 2019, 11 patients underwent LGV transposition for NCS. Ten patients were women (91%). The median age at the time of surgery was 35 years [25; 69]. Demographic data are presented in Table I. Results are presented in Table II. All patients suffered from lower back and/or pelvic pain with pelvic congestion syndrome in 6 cases (55%) and micro or macroscopic hematuria in 5 cases (45%). NRS pain assessment showed a median preoperative pain score of 7.0 [3.5; 10.0] and 6.0 [3.5; 8.0] for lumbar and pelvic pain respectively.

Preoperative CTA found anterior NCS in 10 cases (91%) and 1 posterior (9%). At the left iliac vein crossing (external or common), the median diameter of the LGV was 7.87 mm [6.45 ;11.28]. The diagnosis was confirmed by phlebography with pressure measurements. Associated MTS was identified in 2 patients (18%), who had undergone primary stenting of the left common iliac vein. Phlebography also revealed a renocaval pressure gradient ≥ 3 mmHg in 6 patients (55%).

The median operating time was 122 minutes [72; 172]. The median post-operative in-hospital stay was 4 days [2; 20]. Two early complications occurred (18%): two hematomas requiring surgical revision, with a need for intensive care admission in one of these patients, with a laparostomy for 3 days. This patient returned to the conventional ward after 6 days and was discharged from hospital after 20 days.

At a median follow-up of 15 months [6; 44], median pain scores were 1.0 [0.0; 4.0] and 0.0 [0.0; 6.0] for lumbar and pelvic pain respectively. Seven patients (64%) had transitory incisional and/or neuropathic pain, with a median score of 3.5 [1.0; 6.0], all had resolved at the end of follow up. The 6 patients with initial pelvic congestion syndrome underwent post-

operative CTA, showing a significant reduction of pelvic varicose veins in 5 cases (Figure 4) and complete disappearance in 1 case. Hematuria disappeared in all patients who originally presented it.

Two late complications (18%) were observed: thrombosis in one patient presenting anti-phospholipid syndrome, and one case of anastomotic stenosis requiring stenting. The case of late thrombosis was detected by a CTA performed at more than 2 years post-surgery for sudden abdominal pain.

DISCUSSION

In our experience, LGV transposition, preferably via a retroperitoneal approach, appears to be an attractive and successful surgical technique, and this should be taken into account when considering NCS treatment. The type of anatomy of the NCS (anterior, posterior, atypical) does not influence the use of this technique. The only requirement is the presence of a refluxing and dilated LGV with a diameter sufficient to enable reimplantation. In the case of a high confluence of the pelvic branches of the LGV, reimplantation can be located at the level of the IVC, as in one case in this study, with an adapted surgical approach.

Treatment of NCS remains highly controversial. Conservative treatment is preferred in young patients (under 18 years) because of the accumulation of intra-abdominal fat during growth, which will alter the position of the vessels and may then release the entrapped LRV.^{1,18} At 2 years, 75% of patients will have complete resolution of hematuria. Angiotensin inhibitors may be helpful in improving orthostatic proteinuria⁷ and acetylsalicylic acid may improve renal perfusion¹⁹. For adults, intervention should only be considered when symptoms are severe and disabling, and/or persist⁷ beyond 6 months of conservative therapy¹⁹.

In our experience, the overall goal of NCS treatment is to decrease the vein reflux in the pelvis. However, when pelvic symptoms were not present or less predominant, alternatives were proposed. For instance, during the study period, 21 renocaval bypasses were performed in one participating center. In one case, pain relief was not obtained, leading us to perform another phlebographic assessment, which showed an associated MTS. The patient underwent left common iliac vein stenting, and pain relief ensued. Based on this experience, the diagnostic algorithm was changed, with the systematic elimination of a potential associated MTS by duplex scan, phlebography, or IVUS assessment when available. One of the participating centers

1 previously published a report of its experience with NCS with associated MTS, and showed that
2 about one third of MTS cases first treated by venous stenting subsequently required treatment of
3 the NCS²⁰. In this study, we included 2 patients with associated MTS that was initially treated by
4 iliac stenting, without significant improvement, prompting us to perform secondary LGV
5 transposition.

6 We have adopted the technique of LGV transposition for several reasons: it is achievable
7 through a minimally invasive retroperitoneal approach and it does not require the use of foreign
8 material, which is of particular interest in this young population of patients. Furthermore, several
9 studies have shown the value of incompetent vein embolization in pelvic congestion
10 syndrome^{21,22}. In the technique of LGV transposition, the LGV is ligated close to its origin which
11 therefore replaces the embolization procedure. The results seem satisfactory, since postoperative
12 CTA showed a reduction or even disappearance of pelvic varicose veins in patients who initially
13 had them.

14 However, bleeding complications were noted in one of the centers, leading us to review
15 the anticoagulation protocol. After this revision, no further bleeding events occurred. Indeed, in
16 the center where the bleeding complications were observed, the first patients were anticoagulated
17 at therapeutic doses for fear of thrombosis. Patients were subsequently anticoagulated with
18 prophylactic doses in all 3 centers.

19 The results of our study appear to be consistent with the current literature, however there
20 is an unavoidable heterogeneity in the data. White et al. reported 3 cases of NCS treated by LGV
21 transposition. Bleeding occurred in one case, and all patients recovered uneventfully with
22 complete relief of the pelvic congestion syndrome²³. More recently, Gilmore et al. reported 18
23 cases of NCS treated by LGV transposed to the inferior vena cava with a midline laparotomy,

with good results overall at a median 178 days follow up⁴. They advocated a standardized approach to diagnosis and management. Hao et al. reported a similar modified technique and demonstrated the effectiveness of a left spermatic vein transposed into the inferior epigastric vein for the treatment of NCS associated with varicocele. The size of the skin incision was 3-4 centimeters. There were no major complications. Thrombosis of the vascular anastomosis occurred in 2 of the 53 patients. Varicocele recurrence occurred in 5 cases.⁶

The limitations of our study are its retrospective nature, the small number of patients and medium-term results, which precludes any firm conclusions. The diagnosis and the technique have not yet been standardized, and not all the centers in this study performed the same complementary examinations and follow-up. However, it should be noted that, to the best of our knowledge, this is the first multicenter study to quantify and compare objective pain scores before and after surgery.

CONCLUSION

NCS remains complex in terms of diagnosis and management. LGV transposition into left iliac vein may be proposed as a first approach if the diameter of the LGV is sufficient to perform the anastomosis. It is an easily achievable, minimally invasive alternative that provides satisfactory results without the need for any foreign material.

REFERENCES

1. Ananthan K, Onida S, Davies AH. Nutcracker Syndrome: An Update on Current Diagnostic Criteria and Management Guidelines. *Eur J Vasc Endovasc Surg* 2017; 53: 886–94.
2. Macedo GL de, Santos MA dos, Sarris AB, Gomes RZ. Diagnóstico e tratamento da síndrome de quebra-nozes (nutcracker): revisão dos últimos 10 anos. *J Vasc Bras* 2018; 17: 220–8.
3. Velasquez CA, Saeyeldin A, Zafar MA, Brownstein AJ, Erben Y. A systematic review on management of nutcracker syndrome. *J Vasc Surg Venous Lymphat Disord* 2018;6: 271–8.
4. Gilmore BF, Benrashid E, Geersen D, Shortell CK. Gonadal vein transposition is a safe and effective treatment of nutcracker syndrome. *J Vasc Surg Venous Lymphat Disord* 2020; Online ahead of print.
5. Salehipour M, Rasekhi A, Haghpanah A, Eslahi SA, Jahanbini S, Shirazi M last. The Role of Renal Autotransplantation in Treatment of Nutcracker Syndrome. *Saudi J Kidney Dis Transpl*; 2010; 21: 237-41.
6. Hao J, Shi H, Xu H, Zhu J, Zhou J, Du T. Ultrasound-assisted microsurgical left spermatic-inferior epigastric vein anastomosis for treating nutcracker syndrome-associated varicocele. *Int Urol Nephrol* 2019; 51: 1925–32.
7. Kurklinsky AK, Rooke TW. Nutcracker Phenomenon and Nutcracker Syndrome. *Mayo Clin Proc* 2010; 85: 552–9.
8. Hartung O, Azghari A, Barthelemy P, Boufi M, Alimi YS. Laparoscopic transposition of the left renal vein into the inferior vena cava for nutcracker syndrome. *J Vasc Surg* 2010; 52: 738–41.
9. Thaveau F, Nicolini P, Lucereau B, Georg Y, Lejay A, Chakfe N. Associated Da Vinci and

- 1 Magellan Robotic Systems for Successful Treatment of Nutcracker Syndrome. *J Laparoendosc*
2 *Adv Surg Tech* 2015; 25: 60–3.
- 3 10. Erben Y, Gloviczki P, Kalra M, Bjarnason H, Reed NR, Duncan AA, et al. Treatment of
4 nutcracker syndrome with open and endovascular interventions. *J Vasc Surg Venous Lymphat*
5 *Disord* 2015; 3: 389–96.
- 6 11. Miler R, Shang EK, Park WM. Gonadal Vein Transposition in Nutcracker Syndrome. *Ann*
7 *Vasc Surg* 2018; 46: 205.e13-205.e16.
- 8 12. Wang SZ, Zhang WX, Meng QJ, Zhang XP, Wei JX, Qiao BP. Laparoscopic
9 Extravascular Stent Placement for Nutcracker Syndrome: A Report of 13 Cases. *J Endourol*
10 2015; 29: 1025-9.
- 11 13. Chen S, Zhang H, Shi H, Tian L, Jin W, Li M. Endovascular Stenting for Treatment of
12 Nutcracker Syndrome: Report of 61 Cases With Long-Term Followup. *J Urol* 2011; 186: 570–5.
- 13 14. Hartung O, Grisoli D, Boufi M, Marani I, Hakam Z, Barthelemy P, et al. Endovascular
14 stenting in the treatment of pelvic vein congestion caused by nutcracker syndrome: Lessons
15 learned from the first five cases. *J Vasc Surg* 2005; 42: 275–80.
- 16 15. Gong XY, Zheng W, Du H, Lei Y, Xue YH, Xue CH, et al. Treatment of nutcracker
17 syndrome with spermatic vein ligation and iliac vein anastomosis: Case report of three cases.
18 *Asian Pac J Trop Med* 2012; 5: 923-4.
- 19 16. Rosas S, Paço M, Lemos C, Pinho T. Comparison between the Visual Analog Scale and
20 the Numerical Rating Scale in the perception of esthetics and pain. *Int Orthod* 2017; 15: 543–60.
- 21 17. Bookwalter CA, VanBuren WM, Neisen MJ, Bjarnason H. Imaging Appearance and
22 Nonsurgical Management of Pelvic Venous Congestion Syndrome. *RadioGraphics* 2019; 39:
23 596–608.

- 1 18. Shin JI, Baek SY, Lee JS, Kim MJ. Follow-up and Treatment of Nutcracker Syndrome.
2 Ann Vasc Surg 2007; 21: 402.
- 3 19. He Y, Wu Z, Chen S, Tian L, Li D, Li M, et al. Nutcracker Syndrome—How Well Do We
4 Know It? Urology 2014; 83: 12–7.
- 5 20. Boyer T, Ejargues M, Hartung O, Bonnabel J, Marechal M, Boufi M, et al. Value of direct
6 stenting of the left common iliac vein to treat a nutcracker syndrome (NCS) associated with a
7 cockett's syndrome (CS). Ann Vasc Surg 2020; Abstract Only
- 8 21. Meneses L, Fava M, Diaz P, Andía M, Tejos C, Irarrazabal P, et al. Embolization of
9 Incompetent Pelvic Veins for the Treatment of Recurrent Varicose Veins in Lower Limbs and
10 Pelvic Congestion Syndrome. Cardiovasc Intervent Radiol 2013; 36: 128–32.
- 11 22. Hartung O. Embolization is essential in the treatment of leg varicosities due to pelvic
12 venous insufficiency. Phleb J Venous Dis 2015; 30(1_suppl): 81–5.
- 13 23. White JV, Ryjewski C, Messersmith RN, Sbrana F, Schwartz LB. Left ovarian to left
14 external iliac vein transposition for the treatment of nutcracker syndrome. J Vasc Surg Venous
15 Lymphat Disord 2016; 4: 114–8.

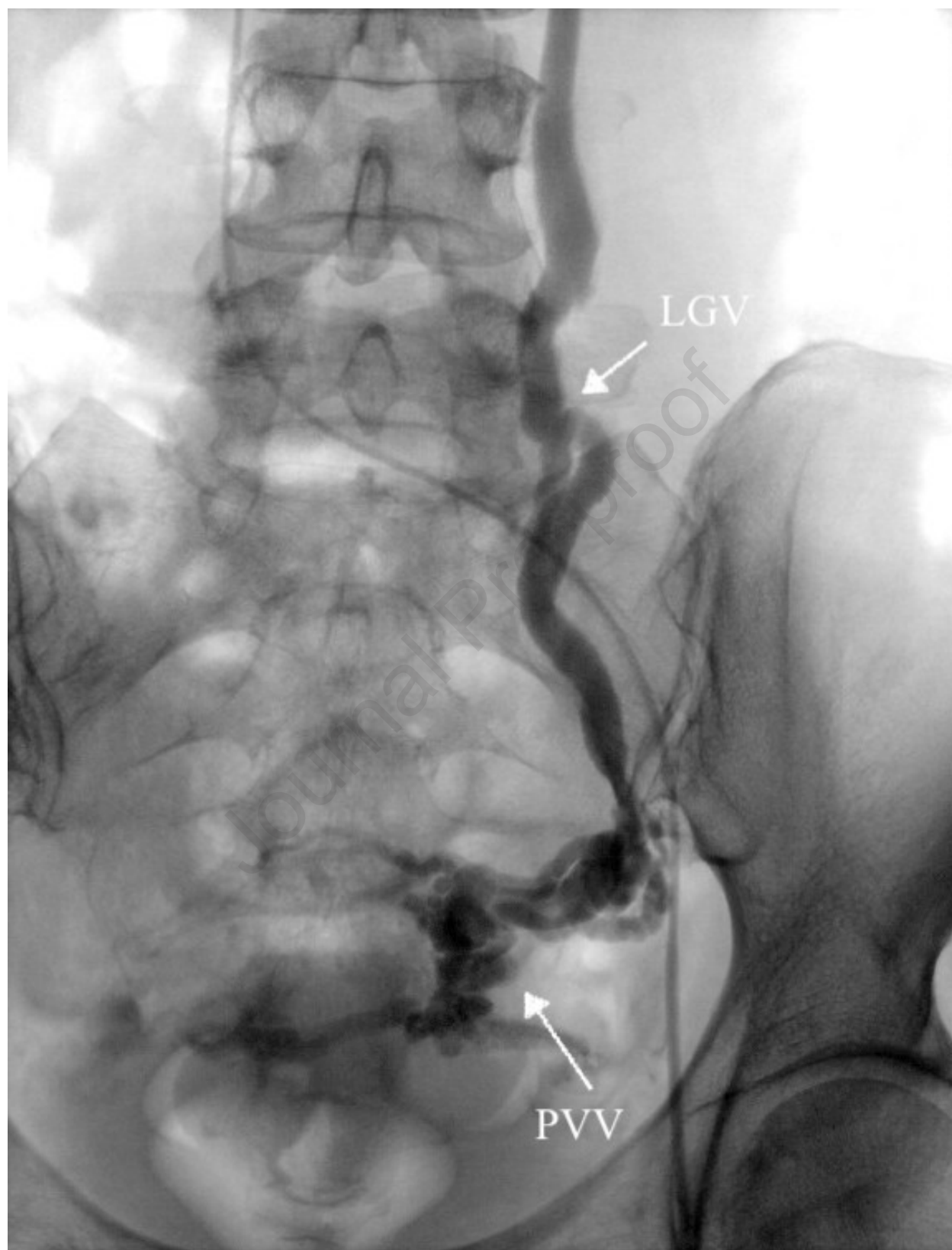
Table I. Patient demographics and clinical data

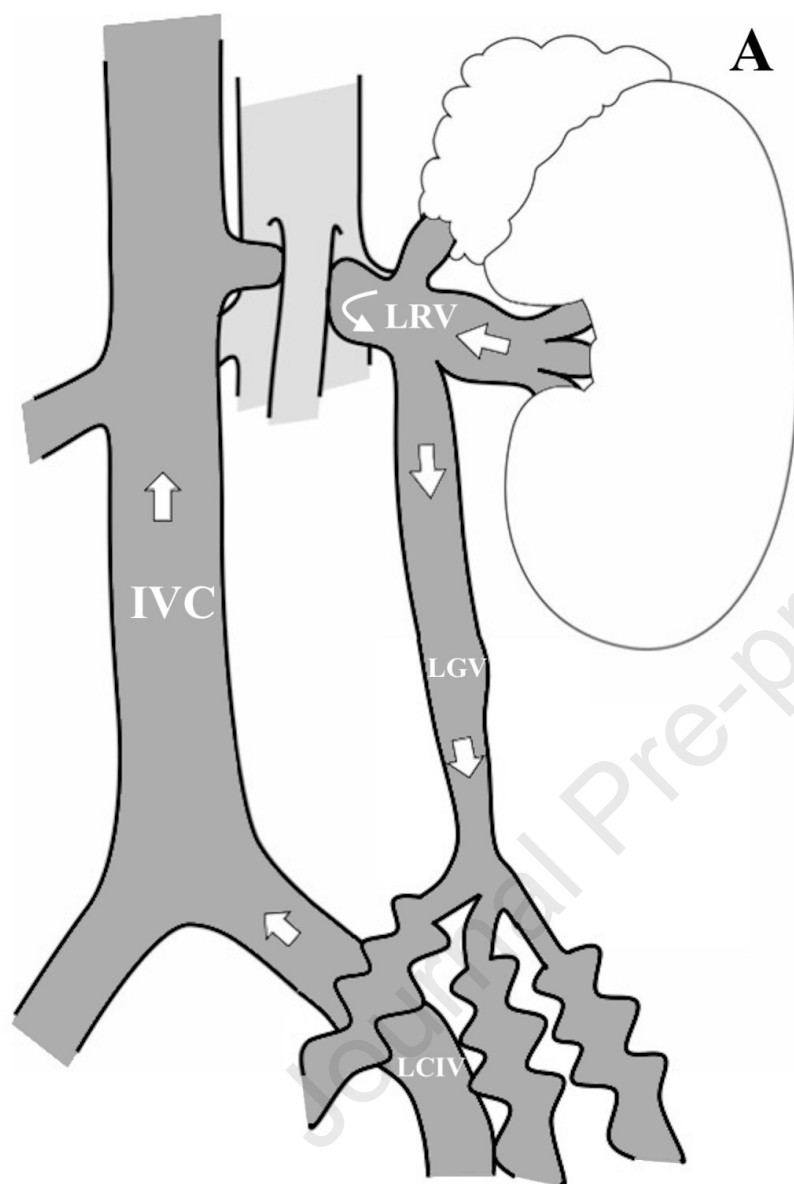
Variables	<i>N=11</i>
Females	10
Age, years, Median [range]	35 [25 ; 69]
Body Mass Index, Median [range]	19.83 [16.33 ; 22.86]
Pregnancies, Median [range]	2 [0 ; 6]
Symptoms	
Abdominal pain	11
Pelvic congestion syndrome	6
Hematuria	5
Pelvic varicose veins	9
Anatomy	
Anterior Nutcracker	10
Posterior Nutcracker	1

Table II. Main results

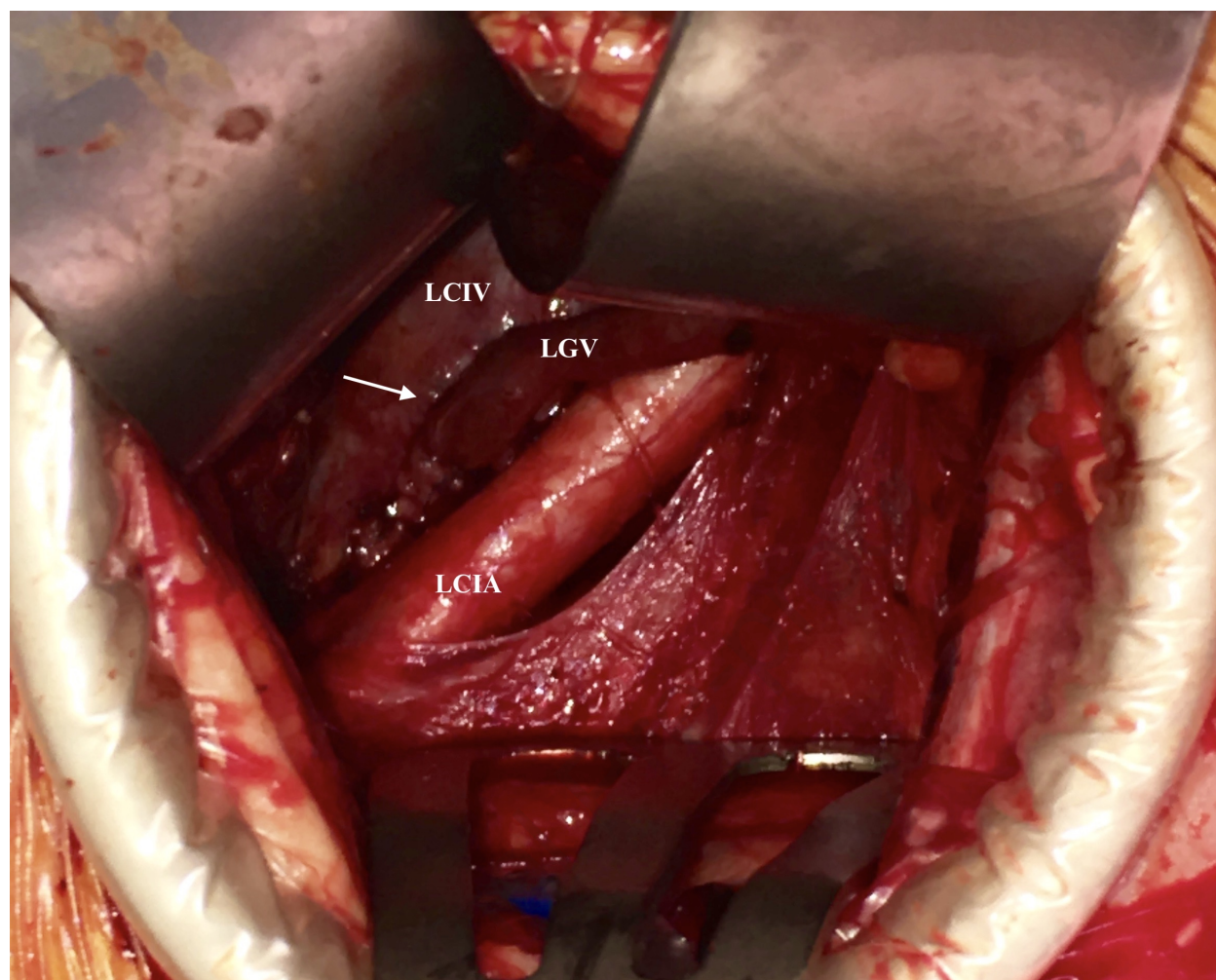Variables	<i>N=11</i>
Preoperative pain	
Lumbar, Median [range]	7.0 [3.5 ; 10.0]
Pelvic, Median [range]	6.0 [3.5 ; 8.0]
Primary stenting for Cockett's syndrome	2
Difference in reno-caval pressure ≥ 3 mmHg	6
Left gonadal vein diameter (mm), Median [range]	
At left renal vein junction	9.74 [5.07 ; 14.52]
At left iliac vein crossing (external or common)	7.87 [6.45 ; 11.28]
Anastomosis site	
Inferior vena cava	1
Left common iliac vein	5
Left external iliac vein	5
Operating time, minutes, Median [range]	122 [72 ; 172]
Post-operative hospital stay, days, Median [range]	4 [2 ; 20]
Discharged before day 5 after surgery	9
Complications	
Early	2
Late	2
Follow-up, months, Median [range]	15 [6 ; 44]

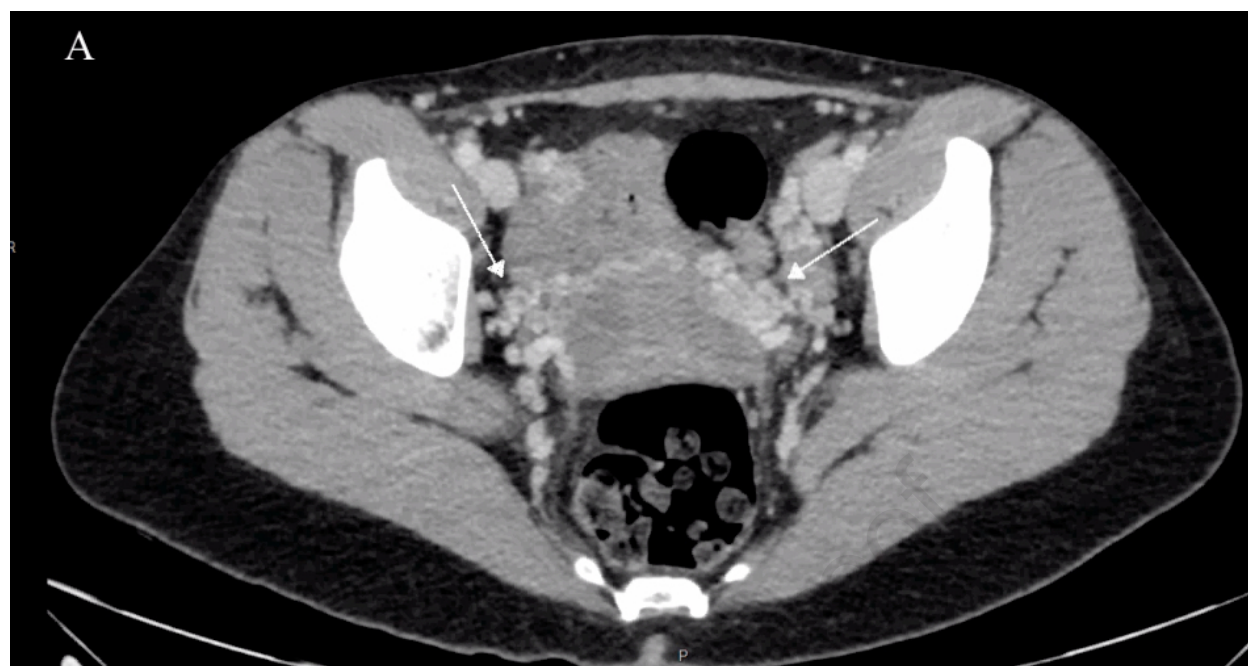Post-operative pain score	
Lumbar, median [range]	1.0 [0.0 ; 4.0]
Pelvic, Median [range]	0.0 [0.0 ; 6.0]
Other, Median [range]	3.5 [1.0 ; 6.0]
Reduction/disappearance of pelvic varicose veins	6
Disappearance of hematuria	5





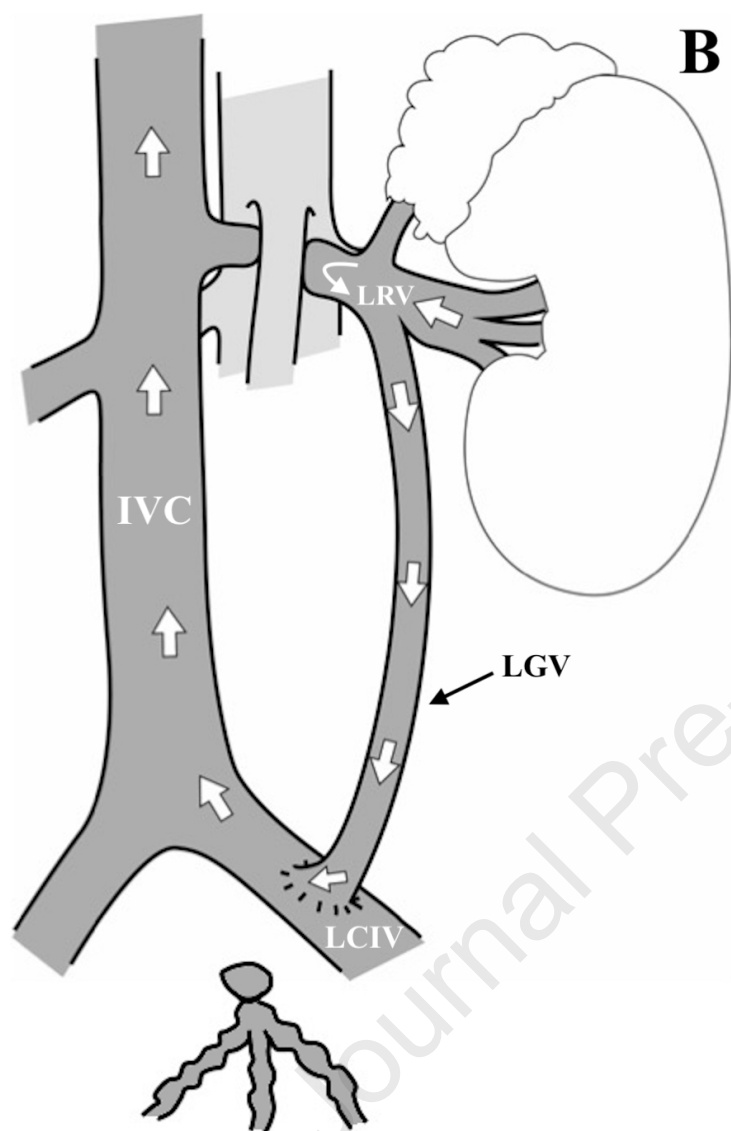





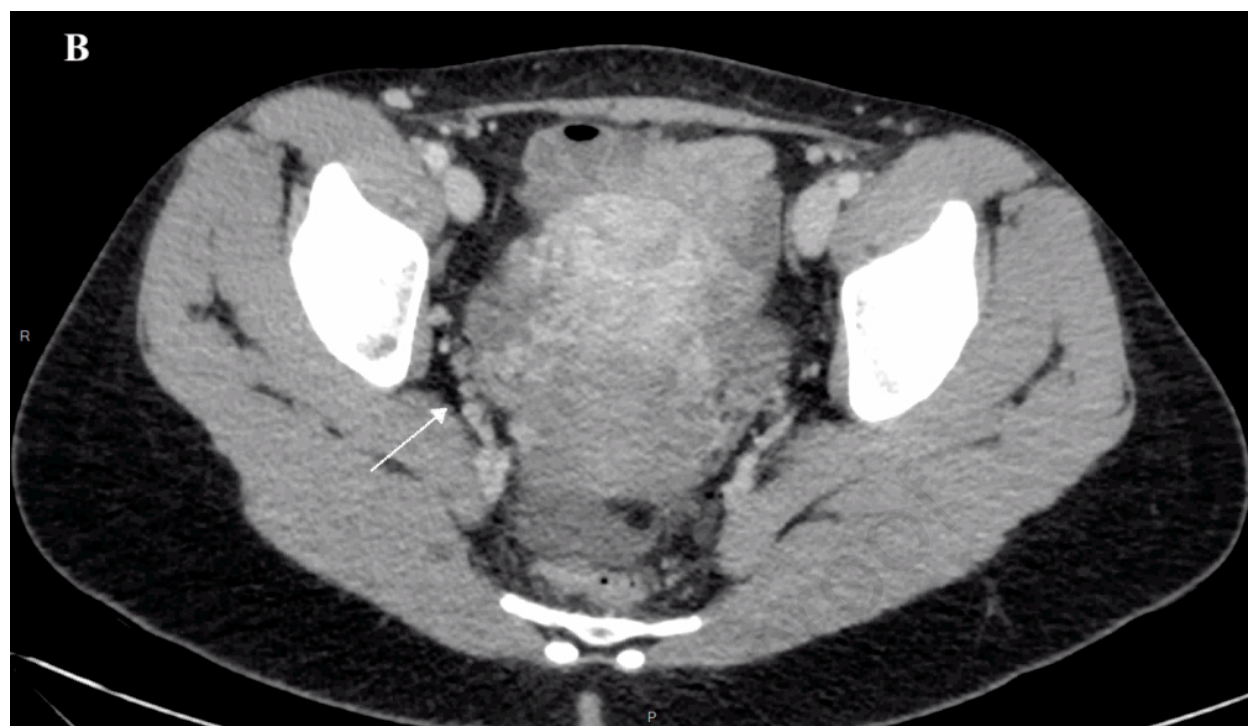


Figure Legends

Figure 1. Phlebography showing dilatation of the left gonadal vein (LGV) with pelvic varicose veins (PVV).

Figure 2. A. Illustration showing obstructed venous return of the left kidney causing venous hyper pressure. The left renal vein (LRV) thus drains into the left gonadal vein (LGV), which dilates and leads to pelvic varicose veins. **B.** Ligation surgery followed by reimplantation of the LGV reduces the venous hyper pressure by draining the venous return from the left kidney into the LGV, then into the left common iliac vein (LCIV) and then into the inferior vena cava (IVC).

Figure 3. Photograph taken intraoperatively after reimplantation of the left gonadal vein (LGV) into the left common iliac vein (LCIV). The arrow indicates the anastomosis. Note the proximity to the left common iliac artery (LCIA).

Figure 4. Late injection computed tomography angiography in the axial plane showing **A.** preoperative pelvic varicose veins and **B.** reduction of the varicose veins in the same patient 1 month after left gonadal vein reimplantation surgery.