



**HAL**  
open science

## Prevalence and characterisation of vocal fold motion impairment (VFMI) in patients with Multiple system atrophy compared with Parkinson's disease

S. Grimaldi, M. Renaud, D. Robert, A. Lagier, H. Somma, S. Soulayrol, D. Korchia, F. Fluchère, O. Lagha-Boukbiza, M. Schaeffer, et al.

### ► To cite this version:

S. Grimaldi, M. Renaud, D. Robert, A. Lagier, H. Somma, et al.. Prevalence and characterisation of vocal fold motion impairment (VFMI) in patients with Multiple system atrophy compared with Parkinson's disease. *Revue Neurologique*, 2020, 176 (7-8), pp.608-613. 10.1016/j.neurol.2020.01.351 . hal-03222579

**HAL Id: hal-03222579**

**<https://hal.science/hal-03222579>**

Submitted on 14 Sep 2022

**HAL** is a multi-disciplinary open access archive for the deposit and dissemination of scientific research documents, whether they are published or not. The documents may come from teaching and research institutions in France or abroad, or from public or private research centers.

L'archive ouverte pluridisciplinaire **HAL**, est destinée au dépôt et à la diffusion de documents scientifiques de niveau recherche, publiés ou non, émanant des établissements d'enseignement et de recherche français ou étrangers, des laboratoires publics ou privés.



Distributed under a Creative Commons Attribution - NonCommercial 4.0 International License

**Prevalence and characterisation of vocal fold motion impairment (VFMI) in patients with  
Multiple system atrophy compared with Parkinson's Disease**

Stephan Grimaldi <sup>1\*</sup>, Mathilde Renaud <sup>4</sup>, Danièle Robert <sup>2</sup>, Aude Lagier <sup>2</sup>, H el ene Somma <sup>3</sup>,  
Sophie Soulayrol <sup>1</sup>, Daniel Korchia <sup>2</sup>, Fr ed erique Fluch ere <sup>1</sup>, Ouha id Lagha-Boukbiza <sup>6</sup>, Micka el  
Schaeffer <sup>5</sup>, Tatiana Witjas <sup>1</sup>, Jean-Philippe Azulay <sup>1</sup>, Alexandre Eusebio <sup>1</sup>

<sup>1</sup> Department of Neurology and Movement Disorders APHM Timone, 13005 Marseille, France

<sup>2</sup> Otolaryngology, APHM Conception, 13005 Marseille, France

<sup>3</sup> Department of Clinical Neurophysiology, APHM Nord, 13015 Marseille, France

<sup>4</sup> Service de G en etique Clinique, CHU de Nancy, H opitaux de Brabois, 54500, Vandoeuvre, France

<sup>5</sup> D epartement d'informations m edicales, CHRU Strasbourg, 67098, Strasbourg, France

<sup>6</sup> Department of Neurology, CHRU Strasbourg, 67098, Strasbourg, France

Stephan Grimaldi and Mathilde Renaud contributed equally to this work.

\* Corresponding author: Dr Stephan Grimaldi, MD

Postal address: Department of Neurology and movement disorders, CHU Timone

264 rue Saint Pierre, 13385 Marseille cedex 05, France

E-mail: [stephan.grimaldi@ap-hm.fr](mailto:stephan.grimaldi@ap-hm.fr)

Authors' mailing & email addresses:

Sophie Soulayrol, Alexandre Eusebio, Tatiana Witjas, Frederique Fluchere, Jean-Philippe Azulay:

Department of Neurology and Movement Disorders

CHU Timone

264 rue Saint-Pierre

13385 Marseille Cedex 05, France

Mathilde Renaud

Service de Génétique Clinique,

CHU de Nancy, Hôpitaux de Brabois,

54500 Vandoeuvre

Danièle Robert, Aude Lagier, Daniel Korchia:

Otolaryngology, Assistance publique - Hôpitaux de Marseille, Hôpital de la Conception,

13005 Marseille, France

Hélène Somma

Department of Clinical Neurophysiology, Assistance publique - Hôpitaux de Marseille,

Hôpital Nord, 13015 Marseille

Ouhaïd Lagha-Boukbiza

Department of Neurology,

CHRU Strasbourg,

1 Avenue Molière,

67098, Strasbourg Cedex, France

Mickaël Schaeffer,

Département d'informations médicales,

CHRU Strasbourg,

1 Avenue Molière,

67098, Strasbourg Cedex, France

Sophie Soulayrol : sophie.soulayrol@ap-hm.fr

Alexandre Eusebio: alexandre.eusebio@ap-hm.fr

Tatiana Witjas: tatiana.witjas@ap-hm.fr

Frédérique Fluchère: Frederique.FLUCHERE@ap-hm.fr

Jean-Philippe Azulay: Jean-philippe.AZULAY@ap-hm.fr

Mathilde Renaud: mhodille@gmail.com

Danièle Robert : Daniele.ROBERT2@ap-hm.fr

Aude Lagier: aude.lagier@laposte.net

Daniel Korchia: docteur.daniel.korchia@gmail.com

Hélène Somma: HeleneSylvie.SOMMA@ap-hm.fr

Ouhaïd Lagha-Boukbiza : ouhaid.boukbiza@chru-strasbourg.fr

Mickaël Schaeffer: mschaeffer@alstats.fr

# **Prevalence and characterisation of vocal fold motion impairment (VFMI) in patients with Multiple system atrophy compared with Parkinson's Disease**

## **Abstract:**

**Introduction:** Multiple system atrophy (MSA) is a neurodegenerative disorder in which vocal fold mobility can be affected, sometimes leading to life-threatening situations. Our aim was to know if laryngeal examination could help differentiate MSA from Parkinson's disease (PD).

**Materials and methods:** Between 2004 to 2014, all consecutive patients diagnosed with probable MSA were included in this retrospective, monocentric study. Flexible laryngoscopy was obtained in 51 MSA patients and compared with 27 patients with Parkinson's disease (PD). Laryngeal muscles EMG was available in 6 MSA patients.

**Results:** Vocal fold motion impairments (VFMI) was found in 35 (68.6%) MSA patients: 15 (29.4%) had uni- or bilateral vocal fold abnormal movement (VFAM), 13 (25.5%) had uni- or bilateral vocal fold abductor paresis (VFABP), 4 (7.8%) had uni- or bilateral vocal fold adductor paresis (VFADP), 10 (19.6%) had bilateral vocal fold paralysis (BVFP). VFMI was found in 13 PD patients (48.1%) all of whom had VFADP. Presence of BVFP was found associated with stridor ( $p<0.001$ ) and dysphagia ( $p=0.002$ ). In all muscles examined in 6 MSA patients, the EMG showed neuropathic patterns.

**Conclusions:** Our data support that VFMI may be encountered in two-thirds of MSA with a variable degree of gravity. Laryngological examination should be considered as a supplementary tool for the diagnosis and prognosis of MSA. VFMI in particular VFAM, VFABD and BVFP should be discussed as an additional possible red flag even at an early stage of MSA and could help discriminate MSA from PD.

## **Introduction**

Multiple system atrophy (MSA) is a neurodegenerative disorder of the central and autonomic nervous system that classically presents with parkinsonism, cerebellar ataxia and autonomic failure. The second consensus statement on MSA retains the designations of “possible”, “probable” or “definite” MSA [1]. Despite these criteria, the differential diagnosis with Parkinson’s disease (PD) is still a challenge. In MSA patients, presence of stridor, sleep-disordered breathing and respiratory insufficiency are linked to the obstruction of the larynx due to vocal fold motion impairment (VFMI) [2] and to central causes and may be a prominent cause of death in MSA. Stridor is one of the expressions of laryngeal dysfunction but the exact nature of these VFMI remains largely unknown [3]. Our objective was to know if laryngeal examination could help differentiate MSA from PD.

## **Materials and methods**

### Patients

From 2004 to 2014, patients diagnosed as having probable MSA according to Gilman criteria [1] at the tertiary department of movement disorders at University Hospital in Marseille and who had at least one laryngeal evaluation were included in a retrospective study. Also, we selected only the patients with a follow-up consistent with a diagnosis of probable MSA [1]. Fifty-one patients with MSA and with available result of laryngeal endoscopy were included. For comparison, a group of 27 patients suffering from PD with laryngeal endoscopy (performed because of dysphagia or hypophonia) were also analyzed. In addition, we analyzed the data of laryngeal EMG obtained in 6 MSA patients.

The study was approved by our local ethics committee in accordance with the Declaration of Helsinki.

### Clinical details

The following items were collected: age, disease duration, UPDRS III, urinary features, orthostatic blood pressure (BP), signs of dysphagia, stridor, invasive therapeutic procedure (gastrostomy, tracheostomy, surgical cordectomy) or continuous positive airway pressure (CPAP).

### Laryngeal endoscopy

Laryngeal examination was performed in all MSA patients even if there were no laryngeal symptoms. The evaluations were performed by an otorhinolaryngologist expert in phoniatrics and swallowing disorders. The last laryngological and clinical evaluation performed was considered for this study when multiple exams had been performed. VFMI was evaluated by fiberoptic laryngoscopy to evaluate vocal cord motion and morphologic features. VFMI was defined as modified, reduced or absent vocal fold motion.

### Laryngeal EMG recording

Electromyographic recordings of laryngeal muscles was available in 6 MSA patients. Recordings from the thyroarytenoid (vocal cord adductor) and the posterior cricoarytenoid muscles (vocal cord abductor) were successively performed using concentric 1.5"x26G needle electrodes (Ambu® Neuroline Concentric) and a Dantec Keypoint® system G4 (Natus). Insertion techniques were based on techniques reported previously [4].

### Statistical analysis

Proportions were compared using Chi-squared test and Fisher exact test for small effectives. Distributions of quantitative variables were compared using t-test and Mann-Whitney Wilcoxon non-parametric test when needed. Logistic regressions were used to check for association between binary variable, qualitative and quantitative covariables. A p-value of less than .05 was considered to indicate statistical significance.

## **Results**

The clinical data of the 51 MSA patients and 27 control PD patients are summarized in table 1.

### Fiberoptic laryngoscopy

Four distinct types of VFMI were found and defined as VFAM (vocal fold abnormal movement), VFABP (uni- or bilateral vocal fold abductor paresis), VFADP (uni- or bilateral vocal fold adductor paresis) and BVFP (bilateral vocal fold paralysis).

VFAM could be defined as flapping movements of the arytenoids, irregular in frequency and amplitude, seen during quiet breathing, with normal adduction movements during phonation and abduction during sniffing (Video 1). VFABP was defined as a reduction or absence of abduction movements in one fold during the sniffing task (that makes the normal vocal folds to abduct). Both VFAM and VFABP could be intermittent and were sometimes observed after an effort of phonation or deglutition (Video 2A and 2B). In BVFP, both vocal folds are immobile and are similar to a bilateral abductor vocal cord paralysis with marked reduction of laryngeal diameter (Video 3). VFADP is visualized during phonation and corresponds to vocal fold adductor paresis and induce a hypophonia. VFADP can be isolated (Video 4).



VFMI was found in 35 (68.6%) MSA patients: 15 (29.4%) had VFAM, 13 (25.5%) VFABP, 4 (7.8%) VFADP, and 10 (19.6%) BVFP. An association of different subtypes of VFMI could be found in seven patients (4 with VFAM and VFABP, 1 with VFAM and VFADP, 2 with VFABP and VFADP). No significant statistically difference could be found between MSA-P vs C patients, neither association of VFMI with autonomic dysfunction. VFMI was found in 13 PD patients (48.1%) and exclusively of the VFADP subtype (Table 1).

#### Laryngeal muscles EMG activity

In all 6 MSA patients for whom the EMG data was available (recording for exploratory purposes and/or to discuss possible botulinum toxin injection), the EMG of the thyroarytenoid and the posterior cricoarytenoid muscles showed neuropathic patterns with decreased number of Motor Unit Potentials (MUPs), neuropathic potentials (duration > 7ms, amplitude > 1 mV) and polyphasic potentials. No abnormal activity at rest was found like fibrillation potentials or positive sharp waves (Figure 1, Table 2).

#### Evolution of MSA patients

16 MSA patients were followed till they died. 11 of them had VFMI. The mean age at death was 66.5 +/- 8.2 years. Cause of death was obtained in 15 patients (10: respiratory infection complications; 3: sudden death; 2: others). Presence of BVFP was associated with stridor ( $p < 0.001$ ) and dysphagia ( $p = 0.002$ ) but not associated with mortality ( $p = 0.31$ ) and tracheostomy ( $p = 0.997$ ). Other VFMI subtypes were neither associated with swallowing or respiratory complications nor with mortality.

Twelve MSA patients had several laryngeal follow-up evaluations: 6 patients (50%) were stable and 6 (50%) progressed and several successively developed different types of VFMI (Table 3).

## **Discussion**

In our study, VFAM, VFABP and BVFP were exclusively found in MSA patients whereas VFADP was found in both MSA and PD patients. This is consistent with the very few reports of VFABP or BVFP associated with PD in the literature [5, 6]. The European MSA Study Group established that the presence of at least two out of 6 red flags is highly specific with a good sensitivity for differential diagnosis when comparing MSA-P versus PD [7]. Our results join those of Warnecke et al., who recently described 8 MSA patients presenting with irregular arytenoid cartilages and movements and vocal fold abduction restriction. 3/8 also showed vocal fold fixation [8]. Together, our works clearly highlight the importance of a laryngeal examination in these patients for diagnosis and follow-up. We propose that VFMI and in particular VFAM, VFABD and BVFP should be discussed as an additional red flag of the disease.

Besides, our data suggest that VFAM may be the earliest stage of MSA-related laryngeal dysfunction followed by VFABP. BVFP was found at later stages in more severe patients and was associated with dysphagia and stridor. However, our study lacked the power to confirm this succession of impairments over time and needs to be confirmed. It is also of interest to note that some MSA patients initially had a normal laryngological examination which became pathological highlighting the need to repeat the examination.

The laryngeal muscles are innervated by vagal motoneurons with the neuronal cell bodies located in the nucleus ambiguus. There is a differential distribution of laryngeal abductor

and adductor motoneurons in the nucleus ambiguus indicating the possibility of a selective vulnerability and neuronal loss of laryngeal abductor motoneurons in MSA patients [9, 10]. Whether denervation of laryngeal muscles and in particular the posterior cricoarytenoid (abductor) [11] causes these laryngeal abnormalities remains controversial as some studies suggest that the underlying mechanism is dystonic [12]. The recordings in our study are rather in favor of the first hypothesis since we found denervation in all our EMG recordings although dystonic features may have been missed because muscles were recorded sequentially and not simultaneously. In PD patients, pharyngeal muscles were found to display histopathological changes with evidence of chronic denervation and reinnervation. These pathological findings were caused by neurodegeneration of the motor branches of the pharyngeal nerves of PD patients, especially in dysphagic subjects. Synucleinopathy is also observed in cervical vagal nerve fibers [13].

Semiologically, VFAM may be described as irregular movements of the vocal fold bearing some similarities with the jerky postural tremor of the hands frequently observed in MSA [14]. A more precise analysis of these movements as well as their underlying mechanisms and evolution will require further studies. Warnecke et al., developed a standardized easy-to-implement task-protocol to be performed during flexible endoscopic evaluation of swallowing for detection of MSA-related pharyngolaryngeal movement disorders [8].

The retrospective and monocentric nature of this study are obvious limitations. However, great care was taken to select only patients with probable MSA and sufficient follow-up to increase the level of confidence in the diagnosis. In addition, many of these patients performed a brain PET 18 FDG and/or a cardiac <sup>123</sup>I-metaiodobenzylguanidine (MIBG) scintigraphy providing an additional argument for the diagnosis of MSA. A further and broader prospective study is required to strengthen the precision of these data.

In conclusion, our data clearly described 4 subtypes of VFMI in MSA. Three of these subtypes were exclusively found in MSA (VFAM, VFABP and BVFP) and the other one in both MSA and PD (VFADP). Thus, identification of laryngeal abnormalities may help with the diagnosis process. BVFP was associated with stridor and dysphagia. Appropriate evaluation and stratification of VFMI could help determine the individual patient risk of developing severe consequences and lead to appropriate therapeutic actions.

## References

- [1] Gilman S, Wenning GK, Low PA, Brooks DJ, Mathias CJ, Trojanowski JQ, et al. Second consensus statement on the diagnosis of multiple system atrophy. *Neurology*. 2008 Aug 26;71(9):670–6.
- [2] Lalich IJ, Ekbom DC, Starkman SJ, Orbelo DM, Morgenthaler TI. Vocal fold motion impairment in multiple system atrophy: Vocal Fold Motion Impairment in MSA. *The Laryngoscope*. 2014 Mar;124(3):730–5.
- [3] Higo R. Vocal fold motion impairment in patients with multiple system atrophy: evaluation of its relationship with swallowing function. *Journal of Neurology, Neurosurgery & Psychiatry*. 2003 Jul 1;74(7):982–4.
- [4] Volk GF, Hagen R, Pototschnig C, Friedrich G, Nawka T, Arens C, et al. Laryngeal electromyography: a proposal for guidelines of the European Laryngological Society. *European Archives of Oto-Rhino-Laryngology*. 2012 Oct;269(10):2227–45.
- [5] Isozaki E, Shimizu T, Takamoto K, Horiguchi S, Hayashida T, Oda M, et al. Vocal cord abductor paralysis (VCAP) in Parkinson's disease: difference from VCAP in multiple system atrophy. *Journal of the Neurological Sciences*. 1995 Jun;130(2):197–202.
- [6] Gan EC, Lau DP, Cheah KL. Stridor in Parkinson's disease: a case of 'dry drowning'? *The Journal of Laryngology & Otology*. 2010 Jun;124(6):668–73.
- [7] Köllensperger M, Geser F, Seppi K, Stampfer-Kountchev M, Sawires M, Scherfler C, et al. Red flags for multiple system atrophy. *Movement Disorders*. 2008 Jun 15;23(8):1093–9.
- [8] WARNECKE T, VOGEL A, AHRING S, GRUBER D, HEINZE, HJ, DZIEWAS R, et al. The Shaking Palsy of the Larynx-Potential Biomarker for Multiple System Atrophy: A Pilot Study and Literature Review. *Frontiers in Neurology*, 2019, vol. 10, p. 241.

- [9] Bannister R, Gibson W, Michaels L, Oppenheimer DR. LARYNGEAL ABDUCTOR PARALYSIS IN MULTIPLE SYSTEM ATROPHY: A REPORT ON THREE NECROPSIED CASES, WITH OBSERVATIONS ON THE LARYNGEAL MUSCLES AND THE NUCLEI AMBIGUI. *Brain*. 1981;104(2):351–68.
- [10] Benarroch EE. Brainstem respiratory control: Substrates of respiratory failure of multiple system atrophy. *Movement Disorders*. 2007 Jan 15;22(2):155–61.
- [11] Guindi GM, Bannister R, Gibson WP, Payne JK. Laryngeal electromyography in multiple system atrophy with autonomic failure. *Journal of Neurology, Neurosurgery & Psychiatry*. 1981 Jan 1;44(1):49–53.
- [12] Merlo IM, Occhini A, Pacchetti C, Alfonsi E. Not paralysis, but dystonia causes stridor in multiple system atrophy. *Neurology*. 2002 Feb 26;58(4):649–52.
- [13] ERTEKIN C. Electrophysiological evaluation of oropharyngeal Dysphagia in Parkinson's disease. *Journal of movement disorders*, 2014, vol. 7, no 2, p. 31.
- [14] Kaindlstorfer C, Granata R, Wenning GK. Tremor in Multiple System Atrophy – a review. *Tremor and Other Hyperkinetic Movements*. 2013 Sep 9;Tremor and Other Hyperkinetic Movements-.

**Table 1. Main characteristics of the MSA and PD patients.**

Abbreviations: VFMI: vocal fold motion impairments, VFAM = (uni- or bilateral) vocal fold abnormal movement, VFABP: (uni- or bilateral) vocal fold abductor paresis, VFADP: (uni- or bilateral) vocal fold adductor paresis, BVFP: bilateral vocal fold paralysis.

**Table 2. MSA patients with laryngeal muscles EMG activity.**

**Table 3. Evolution of 12 MSA patients who had several laryngeal examinations by fiberoptic laryngoscopy.**

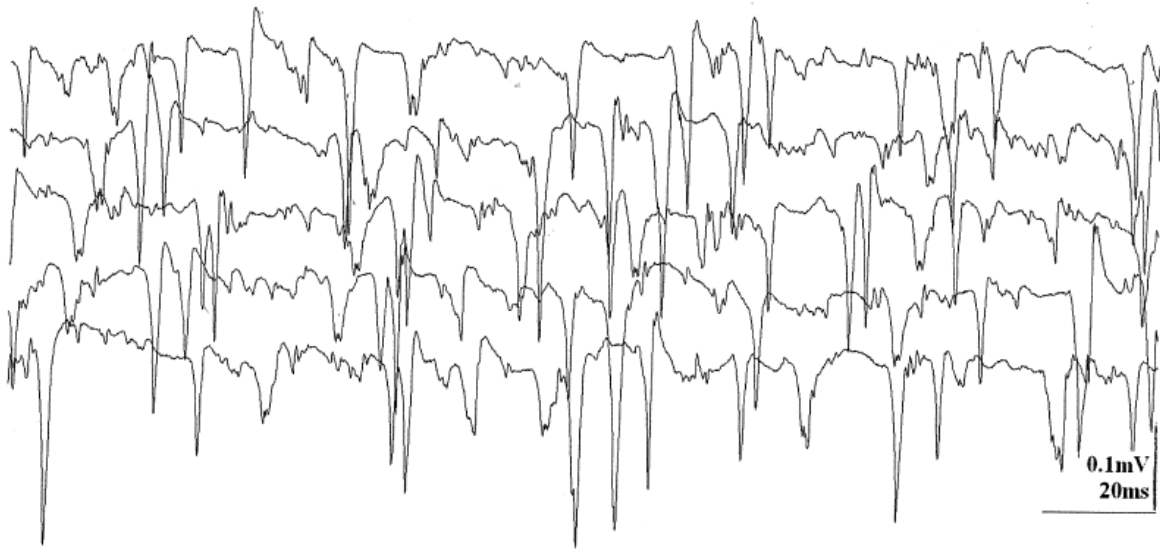Abbreviations: VFMI: vocal fold motion impairments, VFAM = (uni- or bilateral) vocal fold abnormal movement, VFABP: (uni- or bilateral) vocal fold abductor paresis, VFADP: (uni- or bilateral) vocal fold adductor paresis, BVFP: bilateral vocal fold paralysis, TA: thyroarytenoid, PCA: posterior cricoarytenoid.

**Figure 1: One-channel EMG recording in a MSA patient aged 53 years with vocal fold abnormal movement.**

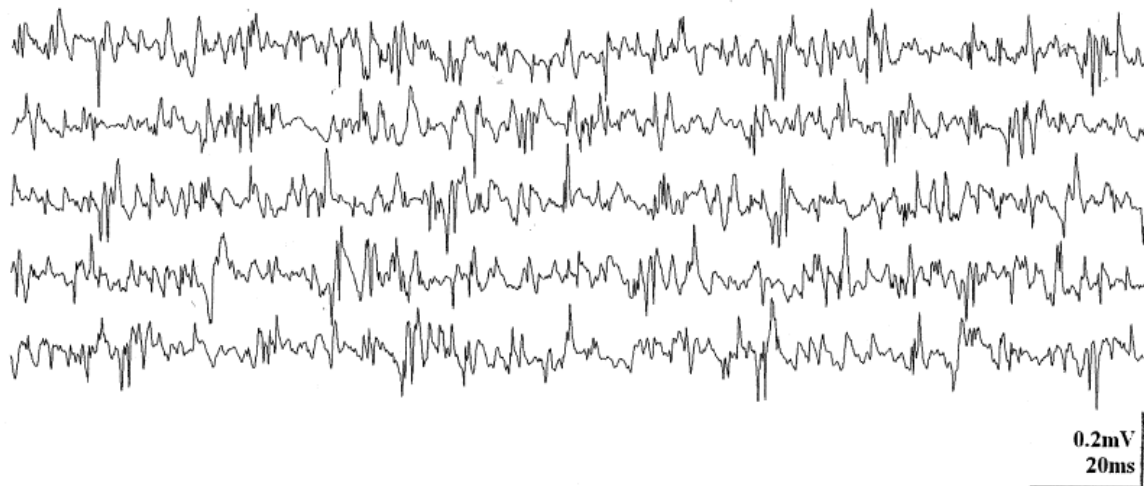
**A:** right posterior cricoarytenoid muscle: reduced pattern with long duration potentials during sniffing.

**B:** right thyroarytenoid muscle normal pattern during phonation.

**A: right posterior cricoarytenoid muscle : reduced pattern with long duration potentials**



**B: right thyroaryenoid muscle : normal pattern**



**Table 1. Main characteristics of the MSA and PD patients.**

	MSA patients (n=51)	PD patients (n=27)	<i>p</i>
<b>Demographic features</b>			
Male/ female	31/20	25/2	<b>0.032</b>
Mean age at evaluation, (range)	64 years (49-78)	68 years (41-79)	0.097
Disease duration at examination, (range)	4 years (1-17)	11 years (4-24)	<b>0.012</b>
Time to death from onset, range (n= 16 MSA)	6 years (2-19)	0	0.195
<b>Clinical evaluation</b>			
<b>MSA-P</b>	40 (78.4%)	0	
<b>MSA-C</b>	11 (21.6%)	0	
Parkinsonism	48 (94.1%)	27 (100%)	0.992
UPDRS III off, range	33.5 (7-65)	26 (8-43)	0.135
Autonomic dysfunction	51 (100%)	6 (22%)	<b>&lt;0.001</b>
Orthostatic hypotension	44 (86.3%)	4 (16%)	<b>0.001</b>
Urinary dysfunction	44 (86.3%)	2 (7%)	<b>&lt;0.001</b>
Dysphagia	7 (13.7%)	5 (19%)	0.763
Stridor	7 (13.7%)	0	0.144
Gastrostomy	8 (17.8%)	0	0.107
Tracheostomy	3 (6.2%)	0	0.389
Surgical cordectomy	1 (2%)	0	0.737
Continuous positive airway pressure (CPAP)	2 (3.9%)	0	0.790
<b>VFMI</b>	35 (68.6%)	0	0.493
VFAM	15 (29.4%)	0	<b>0.010</b>
VFABP	13 (25.5%)	0	<b>0.019</b>
VFADP	4 (7.8%)	13 (48%)	<b>0.013</b>
BVFP	10 (19.6%)	0	0.060

Abbreviations: VFMI: vocal fold motion impairments, VFAM = (uni- or bilateral) vocal fold abnormal movement, VFABP: (uni- or bilateral) vocal fold abductor paresis, VFADP: (uni- or bilateral) vocal fold adductor paresis, BVFP: bilateral vocal fold paralysis.



**Table 2. MSA patients with laryngeal muscles EMG activity.**

Patient no./sex/age at the last examination, years	VFMI	Thyroarytenoid muscle (MUPs)	Posterior cricoarytenoid muscle (MUPs)
1/F/60	BVFP	TA right /left : Normal recruitment Normal Potentials 1 mV	PCA right /left: Reduced recruitment Polyphasic potentials 0.5 mV
2/M/73	VFABP	TA right /left: Reduced recruitment Polyphasic potentials 0.5 mV	PCA right /left: Reduced recruitment++ Potentials 0.5 mV
3/M/63	VFAM	TA right /left: Reduced recruitment Polyphasic potentials 0.5 mV	No EMG
4/M/53	VFAM	TA right /left : Normal recruitment Normal Potentials 0.5 mV	PCA right /left: Reduced recruitment Long duration potentials 0.5 mV
5/M/72	VFABP	TA right /left: Reduced recruitment Normal potentials 1 mV	PCA right /left: Reduced recruitment Potentials 1 to 2 mV
6/M/64	VFABP	TA right /left: Reduced recruitment (Right TA++) Polyphasic potentials 0.5 mV to 1mV	PCA right /left : Normal recruitment Normal Potentials 0.5 to1 mV

Abbreviations: MUPs = Motor Unit Potentials, PCA = Posterior cricoarytenoid muscle, TA = Thyroarytenoid muscle, VFMI: vocal fold motion impairments, VFABP: (uni- or bilateral) vocal fold abductor paresis, VFAM = (uni- or bilateral) vocal fold abnormal movement, BVFP: bilateral vocal fold paralysis.

**Table 3. Evolution of 12 MSA patients who had several laryngeal examinations by fiberoptic laryngoscopy.**

Patient no./sex/age at the last examination, years	Age at onset, last years	Number of laryngeal examination	Duration of MSA at laryngeal examination, years	Evolution of examination	laryngeal	Treatment of VFMI
1/F/60	56	3 (2011, 2012 and 2014)	1, 2 and 4	VFAM → VFABP → BVFP		CPAP
2/M/73	70	2 (2012 and 2014)	1 and 3	normal → VFABP		no
3/M/63	56	2 (2011 and 2012)	6 and 7	normal → VFAM		no
4/F/59	51	2 (2011, 2012 and 2013)	6 and 8	normal → VFABP		no
7/F/67	64	2 (2011 and 2012)	2 and 3	VFAM → BVFP		no
8/M/60	55	3 (2012, 2013 and 2014)	3, 4 and 5	normal → normal → VFABP		no
9/M/55	50	2 (2011 and 2012)	4 and 5	VFAM → VFAM		no
10/F/62	57	3 (2011, 2013 and 2015)	1, 3 and 5	VFABP → VFABP → VFABP		no
11/M/73	65	2 (2013 and 2014)	7 and 8	VFAM → VFAM		no
12/M/66	62	2 (2012 and 2013)	3 and 4	normal → normal		no
13/M/62	56	2 (2013 and 2013)	5 and 6	VFABP → VFABP		no
14/M/66	40	3 (2011, 2013, 2014)	13, 15, 16	BVFP → BVFP → BVFP		tracheostomy

Abbreviations: VFMI: vocal fold motion impairments, VFAM = (uni- or bilateral) vocal fold abnormal movement, VFABP: (uni- or bilateral) vocal fold abductor paresis, VFADP: (uni- or bilateral) vocal fold adductor paresis, BVFP: bilateral vocal fold paralysis, TA: thyroarytenoid, PCA: posterior cricoarytenoid.