



HAL
open science

Consensus on resectability in N3 head and neck squamous cell carcinomas: GETTEC recommendations

Florent Carsuzaa, Philippe Gorphe, Sébastien Vergez, Olivier Malard, Nicolas Fakhry, Christian Righini, Pierre Philouze, Audrey Lasne-Cardon, Patrice Gallet, Denis Tonnerre, et al.

► To cite this version:

Florent Carsuzaa, Philippe Gorphe, Sébastien Vergez, Olivier Malard, Nicolas Fakhry, et al.. Consensus on resectability in N3 head and neck squamous cell carcinomas: GETTEC recommendations. Oral Oncology, 2020, 106, pp.104733. 10.1016/j.oraloncology.2020.104733 . hal-03222429

HAL Id: hal-03222429

<https://hal.science/hal-03222429>

Submitted on 22 Aug 2022

HAL is a multi-disciplinary open access archive for the deposit and dissemination of scientific research documents, whether they are published or not. The documents may come from teaching and research institutions in France or abroad, or from public or private research centers.

L'archive ouverte pluridisciplinaire **HAL**, est destinée au dépôt et à la diffusion de documents scientifiques de niveau recherche, publiés ou non, émanant des établissements d'enseignement et de recherche français ou étrangers, des laboratoires publics ou privés.



Distributed under a Creative Commons Attribution - NonCommercial 4.0 International License

Consensus on resectability in N3 head and neck squamous cell carcinomas: GETTEC recommendations

Florent Carsuzaa¹, Philippe Gorphe², Sébastien Vergez³, Olivier Malard⁴, Nicolas Fakhry⁵, Christian Righini⁶, Pierre Philouze⁷, Audrey Lasne-Cardon⁸, Patrice Gallet⁹, Denis Tonnerre¹, Alexandre Bozec¹⁰, Erwan de Mones¹¹, Bertrand Baujat¹², Laurent Laccourreye¹³, Emmanuel Babin⁸, Xavier Dufour^{1*} and Juliette Thariat^{14*}

Affiliations: ¹: Head and neck surgery, University Hospital of Poitiers, France; ²: Department of Head and Neck Oncology, Gustave Roussy, University Paris-Saclay, Villejuif, France; ³: Institut Universitaire du Cancer de Toulouse Oncopole – University Hospital of Toulouse, France; ⁴: Head and neck surgery, University Hospital of Nantes, France; ⁵: Head and neck surgery, APHM, La Conception University Hospital, Marseille, France; ⁶: Head and neck surgery, University Hospital of Grenoble, France; ⁷: Head and Neck Surgery, Croix Rousse Hospital, Hospices Civils de Lyon (Hospital Group of Lyon), France; ⁸: Head and neck surgery, Centre François Baclesse, Caen, France; ⁹: Head and neck surgery, University Hospital of Nancy, France; ¹⁰: Head and neck surgery, Institut Universitaire de la Face et du Cou, Nice, France; ¹¹: Head and neck surgery, University Hospital of Bordeaux, France; ¹²: Head and neck surgery, Tenon Hospital, Paris, France; ¹³: Head and neck surgery, University Hospital of Angers, France; ¹⁴: Radiation oncology, Centre François Baclesse / ARCHADE, Caen, France.

*equally contributed to the study

Collaborators: Karine Aubry, Vianney Bastit, Esteban Brenet, Ingrid Breuskin, Vincent Castetbon, Philippe Céruse, Dominique Chevalier, Olivier Choussy, Sophie Deneuve, Agnès Dupret-Bories, Florent Espitalier, Joanne Guerlain, Renaud Hibon, Frédéric Lagarde, Jean-Pascal Lebreton, Hélène Lebrun-Loslier, Jean-Christophe Leclere, Maria Lesnik, Marc Makeieff, Olivier Mauvais, Jean-Claude Merol, Haitham Mirghani, Annabelle Picard, Gaël Potard, Jérôme Sarini, Nicolas Saroul, Philippe Schultz, Bruno Toussaint, Jean-Paul Trijolet

Corresponding author:

Prof. Juliette Thariat

Centre François-Baclesse, département de radiothérapie, 3, avenue Général-Harris, 14000 Caen, France

Electronic address: jthariat@gmail.com.

Word count: 1803 words

Abstract

Background: Among patients with T0-2 N3 head and neck squamous cell carcinomas (HNSCC), those undergoing upfront neck dissection have better oncological outcomes. However, there is no consensual definition of disease resectability of N3 nodes, leading to major treatment attrition and interpretation biases between studies. We established a Delphi method-based consensus to define resectability and impact on decision-making for upfront neck dissection in N3 patients.

Methods: The Delphi method was designed as recommended by the French Haute Autorite de Sante among head and neck surgeons from university hospitals and cancer centers, using a 24-item questionnaire. Strong and relative agreements were subsequently established, and recommendations were written. The resulting recommendations were assessed by 30 independent surgeons.

Results: N3 nodes with intraparenchymal brain invasion, foramen invasion, skull base erosion, nodes requiring bilateral XIIth cranial nerve sacrifice, retropharyngeal N3 node or a node above the plan of soft palate are major contraindications to neck dissection. When neck dissection requires unilateral sacrifice of the IXth or Xth or XIIth cranial nerves or cervical nerve roots, upfront neck dissection may be performed, based on a case-by-case assessment of other patient and tumor estimates.

Conclusion: Consensual contraindications to neck dissection in patients with T0-2 N3 HNSCC were defined among French head and neck surgeons as concerns skull base invasion, retropharyngeal nodes and bilateral XIIth cranial nerve sacrifice. This consensus should allow more reliable comparisons between surgical and non-surgical strategies in N3 patients.

Key words: neck dissection, head and neck squamous cell carcinoma, cervical nodes, surgery, contraindication, chemoradiation

Background

In patients with head and neck squamous cell carcinomas (HNSCC), bulky N3 nodes are associated with a high risk of regional relapse and distant failure. When bulky nodal disease is associated with a small primary (T1-2) or an unknown primary (T0), the prognosis is mostly related to nodal disease [1–3]. Consequently, strategies vary between concurrent chemoradiotherapy (CCRT) or induction chemotherapy versus upfront neck dissection depending on initial nodal presentation [4–6]. Patients with N3 disease who undergo upfront neck dissection have better locoregional outcomes than non-operated patients (with unavoidable intrinsic biases), albeit at the price of increased morbidity. While neck dissection may be recommended based on these data, neck dissection practice is highly variable among institutions and is an important confounding factor in the interpretation of studies evaluating surgical or non-surgical strategies in patients with bulky nodal disease. Such variability is at least partially due to variable appreciation of nodal resectability, i.e. the capacity to remove the nodes to yield worthy oncologic outcomes, compared to non-surgical options, while assuring reasonable postoperative morbidity using reconstructive surgery. Neck dissection in N3 disease is usually radical or modified radical but additional critical structures can be involved, such as the internal carotid artery, the X or XIIth cranial nerves or skull base, which may require extended radical neck dissection. Consensus regarding N3 neck dissection with implicit integration of technical resection possibilities, oncologic prognosis, potential morbidity and reconstruction possibilities both functionally and aesthetically is lacking [7,8]. We aimed at establishing a national consensus among French head and neck surgeons for neck dissections in patients with T0-2 N3 squamous cell carcinoma, using the Delphi method as recommended by the French Haute Autorité de Santé.

Material and methods

A steering committee convened by the GETTEC “Groupe Français des Tumeurs de la Tête et du Cou” was tasked with identifying the critical clinical and imaging criteria when managing the neck in cases of bulky N3 nodes associated with an early primary T stage (T0-2). Our guidelines were established according to a two-round Delphi method [9,10]. Delphi was specifically designed for first-line patients who had never previously received radiotherapy. A rating committee of 15 experts in head and neck surgery, from university hospitals and comprehensive cancer centers, was set up. A 24-item questionnaire was created by the

steering committee. Each expert had to rate each proposal between 1 and 9 (1: totally disagrees; 9: totally agrees). After the first round, strong positive and negative agreements emerged (Table 1). For the other items without consensus, the steering committee provided an anonymized summary of the experts' forecasts from the previous round as well as the reasons they provided for their judgments. The rating committee had to revise their early rating in lights of the replies of the other experts. After this second round, strong and relative agreements emerged (Table 2). Recommendations were evaluated by an independent reading committee composed of 30 head and neck cancer surgeons and accepted if 90% of the reading group agreed on the recommendation.

Results

The decision to perform neck dissection relies on patient parameters (age, comorbidities, anaesthetic scores, ASA score, to estimate surgical and postoperative risks), tumor parameters (involvement of adjacent structures) and outcome-related parameters (oncologic outcomes including prognosis, anticipated quality of resection, and functional recovery including potential for reconstructive surgery and prosthetic / physical rehabilitation). The complexity of this multilevel assessment results in some variability in the final decision of neck dissection.

Our Delphi consensus methodology was able to achieve strong agreement in 13 out of 24 clinical situations, relative agreement in 3 and no consensus in 8.

A strong agreement was immediately achieved for three contraindications to neck dissection: intracranial intraparenchymal brain invasion, invasion of skull base foramen or bilateral sacrifice of the XIIth cranial nerve. Strong agreement was achieved after a second round of quotation for contraindication to a neck dissection in cases of skull base erosion, even limited to the cortical bone, because of the risk of microvascular spread and the high probability of incomplete resection.

Strong agreement in favor of neck dissection was achieved in cases of unilateral sacrifice of either the IXth or Xth or XIIth cranial nerve or cervical nerve roots. In contrast, there was no consensus for or against neck dissection when sacrifice of both the ipsilateral Xth and the XIIth cranial nerve was needed. Some experts considered it unreasonable to increase morbidity and decrease quality of life (difficulties to recover normal oral nutrition). Others considered that a functional treatment with vocal fold medialization could help maintain good quality of life.

A retropharyngeal N3 node was considered a contraindication to neck dissection (strong agreement). There was relative agreement against neck dissection in cases of a lateral N3 node associated to a retropharyngeal node above the plan of the soft palate. There was no consensus about neck management in cases of an operable lateral N3 node associated with a retropharyngeal node under the level of the soft palate. Some experts considered it unreasonable to significantly increase morbidity with a surgical treatment. There was relative agreement against neck dissection when sacrifice of the prevertebral muscles or fascia would be needed.

There was a strong agreement in favor of neck dissection in cases of cutaneous invasion requiring a locoregional flap or relative agreement when needing a free flap.

Extracapsular invasion associated with N3 nodes should not be considered as a contraindication to neck dissection (strong agreement). Nor should invasion of infrahyoid muscles be considered as a contraindication to neck dissection (strong agreement).

In cases of continuity between an oropharyngeal primary or a primary of the oral cavity and a cervical N3 node, there was no consensus in favor or against neck dissection. Some experts contraindicated neck dissection because of the probability of invasion of the parapharyngeal spaces. Continuity between a hypopharyngeal or laryngeal primary and a N3 neck node was not considered as an obstacle to neck dissection (relative agreement).

Internal carotid artery encasement over 270° without dissection plan on imaging was a contraindication to neck dissection (relative agreement). There was no consensus on use of a carotid bypass if carotid invasion was circumferential or more localized without a dissection plan. There was no consensus for neck dissection regardless of the degree of involvement, even in the presence of a dissection plan (Figure 1).

Discussion

The current study was conducted according to validated Delphi consensus methodology [10]. Strong agreement was achieved for most situations, either in favor of or against a neck dissection, depending on the involvement of given structures and expected oncologic and functional outcomes. Accurate description of resectability criteria should be possible in the future using this consensus. This may contribute to better, less biased assessment of the pros and cons of neck dissection versus non-surgical strategies. Several studies have compared oncological outcomes in patients with N3 bulky nodes between neck dissection and CCRT [11].

One of the more important biases in these studies was the lack of comparability between patients according to therapeutic strategies: operated patients had more favorable tumor characteristics, including resectable N3 nodes.

The methodology used in this study made it possible to obtain a reliable consensus between experts. Consensual contraindications were mainly related to oncological arguments and concerned extensions to the skull base, the retropharyngeal and prevertebral region and the internal carotid artery. In many tumors, intracerebral invasion is considered as an important criteria against surgical treatment [12–14]. Our experts also considered parenchymal invasion, skull base erosion, even limited, and skull base foramen invasion as strong criteria against neck dissection. In patients with intracranial invasion, achieving complete resection without residual microscopic disease seems unlikely. In these situations, upfront chemoradiotherapy should be indicated.

For N3 nodes and nodes of any size above the soft palate, oncologic outcomes and morbidity were arguments against neck dissection. Requiring transcervical, transparotid, and transmandibular retropharyngeal neck dissection, these nodes can provide potentially serious surgical morbidities and complications.

Vascular involvement in head and neck cancer is a marker for poor survival [15]. The definition of carotid vessel encasement per radiographic imaging and management depending on carotid involvement is less consensual between cancer centers. A retrospective study by Pons *et al.* showed that a combination of carotid artery deformation, encasement of more than 180 degrees of the carotid perimeter, and segmental obliteration of the fat between the node and the carotid artery were highly predictive of massive invasion of the carotid artery. The isolated existence of encasement of more than 180 degrees or segmental obliteration of fat could not strictly indicate massive invasion of the carotid artery, and neck dissection with carotid artery dissection could be planned [16]. For our panel of head and neck French cancer surgeons, artery involvement over 270° without dissection plan was a major contraindication to neck dissection. Surgical treatment using a carotid bypass letting the carotid invasion be circumferential or more localized without dissection plan was an area of controversy and could not be solved. For the majority of the experts, initial tumor resection involving the carotid artery should not be performed because surgical treatment with dissection or resection – bypass of the internal or common carotid artery usually leads to poor oncological outcomes [17,18]. Postoperative chemoradiation can also complicate bypass results with

stenosis or breaking. A resection-bypass of the internal carotid artery should be contraindicated in general but may be discussed on a case-by-case basis in young patients without comorbidities. A multicentric study comparing oncological outcomes and morbidity depending on degree of carotid encasement seems necessary.

Consensual contraindications can also be linked to functional and quality of life arguments: such as sacrifice of the XIIth cranial nerves bilaterally. As regards neck dissection necessitating sacrifice of the Xth and the XIIth cranial nerve homolaterally, consensus could not be achieved, seemingly because of various expectation among experts for reconstructive surgery and rehabilitation.

A potential limitation of this study is that it was conducted only in French cancer centers. International validation would increase the reliability of the consensus. Additionally, we may have omitted pertinent clinical situations where N3 neck dissection may significantly influence prognosis. In cases of salvage surgery, the decision to perform neck dissection and its contraindications would be somewhat different. The steering committee would probably modify the functional and aesthetic impairment limits to increase the oncologic outcomes. While these recommendations apply to a standard patient, they may be discussed on a case-by-case scenario during multidisciplinary committees to take into account individual clinical characteristics.

Conclusion

High levels of consensus on the N3 resectability could be obtained using a Delphi consensus depending on the involvement of given structures, accounting for estimates of postoperative oncological and functional risks as well as quality of life. Maintaining quality of life must be central to the therapeutic strategy. Refinement of these criteria should be useful for future N3 studies in view of achieving better assessment of the impact of strategies using neck dissection or not.

References

- [1] Hamoir M, Ferlito A, Schmitz S, Hanin F-X, Thariat J, Weynand B, et al. The role of neck dissection in the setting of chemoradiation therapy for head and neck squamous cell carcinoma with advanced neck disease. *Oral Oncol* 2012;48:203–10. <https://doi.org/10.1016/j.oraloncology.2011.10.015>.
- [2] Carsuzaa F, Thariat J, Gorphe P, Righini C, Cosmidis A, Thureau S, et al. Surgery or Radiotherapy of the Primary Tumor in T1-2 Head and Neck Squamous Cell Carcinoma with Resectable N3 Nodes: A Multicenter GETTEC Study. *Ann Surg Oncol* 2019;26:3673–80. <https://doi.org/10.1245/s10434-019-07589-0>.
- [3] Klausner G, Troussier I, Blais E, Carsuzaa F, Zilli T, Miralbell R, et al. Neck management in head and neck squamous cell carcinomas: where do we stand? *Med Oncol Northwood Lond Engl* 2019;36:40. <https://doi.org/10.1007/s12032-019-1265-1>.
- [4] Du C, Blanchard P, Even C, Boros A, Gorphe P, Breuskin I, et al. Induction chemotherapy followed by radiotherapy for N3 head and neck squamous cell carcinoma. *Head Neck* 2020;42:426–33. <https://doi.org/10.1002/hed.26021>.
- [5] Karabajakian A, Gau M, Reverdy T, Neidhardt E-M, Fayette J. Induction Chemotherapy in Head and Neck Squamous Cell Carcinoma: A Question of Belief. *Cancers* 2018;11. <https://doi.org/10.3390/cancers11010015>.
- [6] Geoffrois L, Martin L, De Raucourt D, Sun XS, Tao Y, Maingon P, et al. Induction Chemotherapy Followed by Cetuximab Radiotherapy Is Not Superior to Concurrent Chemoradiotherapy for Head and Neck Carcinomas: Results of the GORTEC 2007-02 Phase III Randomized Trial. *J Clin Oncol Off J Am Soc Clin Oncol* 2018;JCO2017762591. <https://doi.org/10.1200/JCO.2017.76.2591>.
- [7] Virk JS, Ingle M, Podesta CM, Gujral DM, Awad Z. Survival outcomes for head and neck cancer patients with N3 cervical nodal metastases. *Clin Otolaryngol Off J ENT-UK Off J Neth Soc Oto-Rhino-Laryngol Cervico-Facial Surg* 2019. <https://doi.org/10.1111/coa.13501>.
- [8] Spriano G, Pellini R, Manciooco V, Ruscito P. Treatment of advanced neck metastases. *Acta Otorhinolaryngol Ital Organo Uff Della Soc Ital Otorinolaringol E Chir Cerv-Facc* 2006;26:360–9.
- [9] Jones J, Hunter D. Consensus methods for medical and health services research. *BMJ* 1995;311:376–80. <https://doi.org/10.1136/bmj.311.7001.376>.
- [10] French Haute autorité de santé. Elaboration de recommandation de bonne pratique - Recommandations par consensus formalisé 2010.
- [11] Chen W-Y, Chen T-C, Lai S-F, Liang TH-K, Huang B-S, Wang C-W. Outcome of bimodality definitive chemoradiation does not differ from that of trimodality upfront neck dissection followed by adjuvant treatment for >6 cm lymph node (N3) head and neck cancer. *PloS One* 2019;14:e0225962. <https://doi.org/10.1371/journal.pone.0225962>.
- [12] Cannon RB, Dundar Y, Thomas A, Monroe MM, Buchmann LO, Witt BL, et al. Elective Neck Dissection for Head and Neck Cutaneous Squamous Cell Carcinoma with Skull Base Invasion. *Otolaryngol--Head Neck Surg Off J Am Acad Otolaryngol-Head Neck Surg* 2017;156:671–6. <https://doi.org/10.1177/0194599817691923>.
- [13] Shibuya TY, Doerr TD, Mathog RH, Burgio DL, Meleca RJ, Yoo GH, et al. Functional outcomes of the retromaxillary-infratemporal fossa dissection for advanced head and neck/skull base lesions. *Skull Base Surg* 2000;10:109–17. <https://doi.org/10.1055/s-2000-9319>.
- [14] Khoury T, Jang D, Carrau R, Ready N, Barak I, Hachem RA. Role of induction chemotherapy in sinonasal malignancies: a systematic review. *Int Forum Allergy Rhinol*

2019;9:212–9. <https://doi.org/10.1002/alr.22229>.

[15] Krol E, Brandt CT, Blakeslee-Carter J, Ahanchi SS, Dexter DJ, Karakla D, et al. Vascular interventions in head and neck cancer patients as a marker of poor survival. *J Vasc Surg* 2019;69:181–9. <https://doi.org/10.1016/j.jvs.2018.04.058>.

[16] Pons Y, Ukkola-Pons E, Clément P, Gauthier J, Conessa C. Relevance of 5 different imaging signs in the evaluation of carotid artery invasion by cervical lymphadenopathy in head and neck squamous cell carcinoma. *Oral Surg Oral Med Oral Pathol Oral Radiol Endod* 2010;109:775–8. <https://doi.org/10.1016/j.tripleo.2009.12.053>.

[17] Mourad M, Saman M, Stroman D, Lee T, Ducic Y. Carotid Artery Sacrifice and Reconstruction in the Setting of Advanced Head and Neck Cancer. *Otolaryngol--Head Neck Surg Off J Am Acad Otolaryngol-Head Neck Surg* 2015;153:225–30. <https://doi.org/10.1177/0194599815586719>.

[18] Meleca RJ, Marks SC. Carotid artery resection for cancer of the head and neck. *Arch Otolaryngol Head Neck Surg* 1994;120:974–8. <https://doi.org/10.1001/archotol.1994.01880330056010>.

Table 1: Judgment accepted after the first round, depending on median value and distribution of quotes.

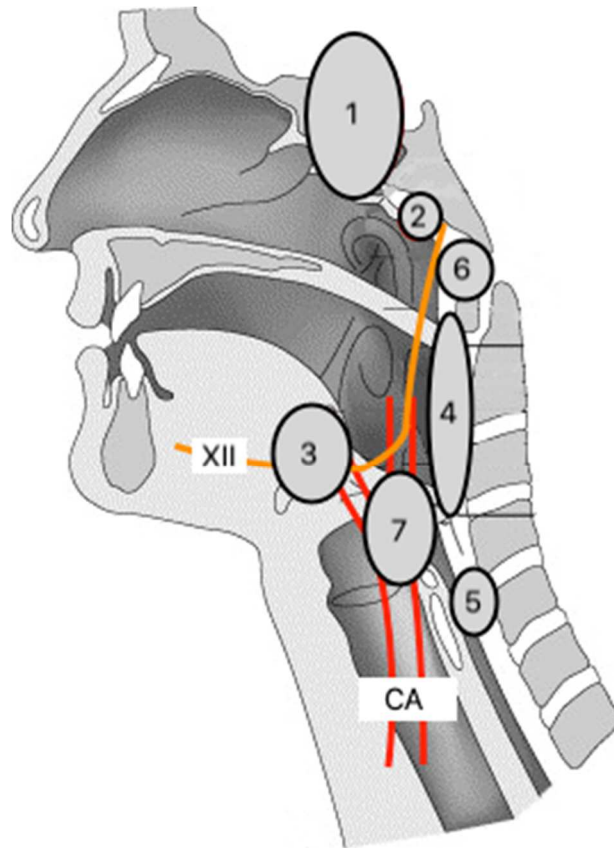
Proposal judged		Median value	Distribution of responses	Subjected to the second round
Appropriate	Strong agreement	≥ 7	All the quotes between [7- 9]	No, recommendation accepted
	Relative agreement	≥ 7	All the quotes between [5- 9]	Yes
Inappropriate	Strong agreement	≤ 3	All the quotes between [1- 3]	No, recommendation rejected
	Relative agreement	≤ 3.5	All the quotes between [1- 5]	Yes
Uncertain	Indecision		All the quotes between [4- 6.5]	Yes
	Lack of consensus	≥ 7	At least one quote < 5	Yes
		≤ 3.5	At least one quote > 5	Yes

Table 2: Conditions for agreement between experts and accepted judgment, depending on median value and distribution of quotes.

Proposal judged		Median value	Distribution of responses
Appropriate	Strong agreement	≥ 7	[7- 9]
	Relative agreement	≥ 7	[5- 9]
Inappropriate	Strong agreement	≤ 3	[1- 3]
	Relative agreement	≤ 3.5	[1- 5]

For a group of 9 to 15 experts, analysis in the second round tolerates, exclusion of a missing value or a value opposite that of the majority of the group.

Figure 1: Diagram summarizing contraindications to neck dissection in patients with T0-2 N3 HNSCC



CA: carotid artery

Strong agreement

- Intracranial intraparenchymal extension (1)
- Invasion of skull base foramen (2)
- Skull base erosion (2)
- Sacrifice of the XIIth cranial nerve bilaterally (3)
- Retropharyngeal N3 node (4)
- Invasion of prevertebral muscles or fascia (5)

Relative agreement

- Retropharyngeal node above the plan of soft palate (6)
- Encasement more than 270° of the internal carotid artery without dissection plan on imaging (7)