



HAL
open science

Bilateral methachronous testicular germ cell tumor and testicular microlithiasis in a child: Genetic analysis and insights. A case report

N. Boudaoud, G. Loron, M. Pons, E. Landais, S. Kozal, M. Doco-Fenzy, M.L. Poli-Merol

► To cite this version:

N. Boudaoud, G. Loron, M. Pons, E. Landais, S. Kozal, et al.. Bilateral methachronous testicular germ cell tumor and testicular microlithiasis in a child: Genetic analysis and insights. A case report. *International Journal of Surgery Case Reports*, 2017, 41, pp.76-79. 10.1016/j.ijscr.2017.09.035 . hal-03219936

HAL Id: hal-03219936

<https://hal.science/hal-03219936v1>

Submitted on 18 Mar 2024

HAL is a multi-disciplinary open access archive for the deposit and dissemination of scientific research documents, whether they are published or not. The documents may come from teaching and research institutions in France or abroad, or from public or private research centers.

L'archive ouverte pluridisciplinaire **HAL**, est destinée au dépôt et à la diffusion de documents scientifiques de niveau recherche, publiés ou non, émanant des établissements d'enseignement et de recherche français ou étrangers, des laboratoires publics ou privés.



ELSEVIER

Contents lists available at ScienceDirect

International Journal of Surgery Case Reports

journal homepage: www.casereports.com

Bilateral methachronous testicular germ cell tumor and testicular microlithiasis in a child: Genetic analysis and insights. A case report



N. Boudaoud^a, G. Loron^b, M. Pons^a, E. Landais^c, S. Kozal^a, M. Doco-Fenzy^c, M.L. Poli-Merol^{a,*}

^a Department of Pediatric Surgery, American Memorial Hospital, CHU REIMS, France

^b Department of Pediatrics, American Memorial Hospital, CHU REIMS, France

^c Genetic Department, CHU-Reims, SFR-CAP Santé, UFR Médecine Reims, EA 3801, France

ARTICLE INFO

Article history:

Received 3 August 2017

Received in revised form

25 September 2017

Accepted 27 September 2017

Available online 15 October 2017

Keywords:

Testicular microlithiasis

Testicular germ cell tumor

Genetics

Children

CGH array

ABSTRACT

OBJECTIVES: To report our experience with a case of a child with bilateral testicular micro-lithiasis (TML) who developed bilateral metachronous testicular germ cell tumor (TGCT) and determine the most appropriate follow-up and care management in children with testicular micro calcifications in regards to the theoretical risk of testicular cancer.

CASE REPORT: A 12 year-old boy was diagnosed with TGCT and TML. Ten years after complete remission, he presented with a recurrence on the contralateral testis. Genetic screening was performed on both resected and the patient's karyotype was analyzed.

RESULTS: Blood karyotype was normal. Aberrations were found in the tumor karyotype. CGH array showed alterations in chromosome arm 12p.

DISCUSSION: TML is frequently associated with testicular malignancy in adults: in 16.9% of cases the normal contralateral testicle develops TML in TGCT. Recent works of literature find no relationship between TML and cancer in general, but in patients with additional risks, the relationship becomes stronger. Some authors suggest that environmental components and genetics are determinant factors. This is highly suspected in our reported case. It would seem that TML is not a precancerous lesion per se, but rather a marker of an at-risk situation. Long term evolution is uncertain and regular self-palpation that starts before puberty is the only way to ensure proper screening and monitoring.

CONCLUSION: TML have been suspected to be a sign of testicular dysgenesis syndrome, which yields a risk of developing TGCT in case of noxious associations.

In patients with a history of TGCT contralateral TML is alarming and aggressive surgical management should be discussed. Therapeutic education of these patients on self-palpation is the best way to ensure proper follow-up.

© 2017 The Authors. Published by Elsevier Ltd on behalf of IJS Publishing Group Ltd. This is an open access article under the CC BY-NC-ND license (<http://creativecommons.org/licenses/by-nc-nd/4.0/>).

1. Introduction

The management of TML is still being discussed in the literature, especially in children. We report the case of a child who presented with TGCT associated with TML and a long term contralateral recurrence. Due to the rarity of the case, the association with TML, both tumor were explored genetically. As far as we know, this is the first case of a Yolk sac tumor reporting the results of karyotype and DNA oligo-array in tumors developed within an interval of 10 years, in both testis in a young adult presenting TML.

2. Case report

A 12 year-old boy presented to our clinic for testicular tumor discovered by the family physician during routine examination. The right testis was enlarged, firm, tender to the touch and irregular. The left testicle was normal. The boy presented with clinical symptoms of precocious puberty.

Ultrasound confirmed an enlarged testicle infiltrated by a vascularized, heterogeneous tumor (Fig. 1). TML were noticed both in the remaining right parenchyma and in the left testis. Preoperative laboratory tests showed increased Alpha-fetoprotein levels. β CGH and testosterone levels were also elevated due to peripheral secretion, responsible of the precocious puberty. The tumor was still localized and orchiectomy was performed, after initial control of testicular vessels, via an inguinal approach. Histopathology validated the ter-

* Corresponding author at: Pediatric Surgery – AMH 47 Rue Cognac Jay, 51100 Reims, France.

E-mail address: mpolimerol@chu-reims.fr (M.L. Poli-Merol).

<https://doi.org/10.1016/j.ijscr.2017.09.035>

2210-2612/© 2017 The Authors. Published by Elsevier Ltd on behalf of IJS Publishing Group Ltd. This is an open access article under the CC BY-NC-ND license (<http://creativecommons.org/licenses/by-nc-nd/4.0/>).

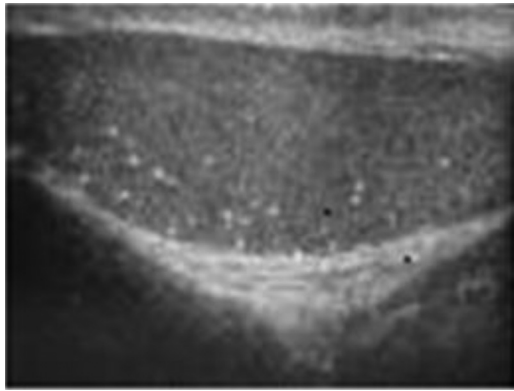


Fig. 1. Left testis US at 12 year-old.

atocarcinoma. Postoperative recovery was uneventful and biology lab results were totally normalized after 3 weeks of follow-up.

The child was then regularly assessed, every three months then twice a year, and finally once a year until he reached the age of 18. During this 6-year follow-up, ultrasound examinations of the remaining testis and empty scrotum were normal except for previously evidenced calcifications in the left testicle. Self-palpation was strongly recommended and the systematic follow-up ended.

Ten years later, during a routine examination again, his family physician noticed a change in his left testicle. The patient admitted he had noticed the change 3 months before. Additional examinations confirmed the recurrence with mediastinal and pulmonary metastases. Alpha-fetoprotein levels were increased. A left orchiectomy was performed after sperm storage. Adapted chemotherapy was done with a good response. Lung metastases were removed and the patient is now recurrence-free after a 62-month follow up.

Due to the rarity of the case, we retrospectively explored both tumors and a sample of the patient's blood via karyotype and CGH array. Patient consent was mandatory and obtained.

Tumour samples from both sides were enzymatically dissociated; cells were cultured on ECM coated flask surfaces and fed with an enriched culture medium. The cells did grow slowly. After about 20 days the monolayer cultures were trypsinised and cells were karyotyped after banding.

3. Array-CGH

Genomic DNA samples were extracted from peripheral blood using the QIAamp DNA Blood Midi kit (Qiagen, Valencia, CA, USA) and from paraffin embedded slides using the QIAamp DNA Tissue Midi kit (Qiagen). Array-CGH was performed in all samples using the Agilent 44k oligoarrays (Human Genome CGH Microarray Kit, Agilent Technologies, Santa Clara, CA, USA). Random primer labelling and hybridization were carried out with sex-matched reference DNA according to the manufacturer's recommendations. Images were acquired using an Agilent scanner. Data were processed with Cytogenomics software (Agilent Technologies), and results were analysed with the CGH Analytics software (v3.5.14; Agilent Technologies) using the ADM2 algorithm and a three-point filter.

Results are reported in Table 1.

3.1. Interpretation

Unfortunately, the M-FISH could not be realised to better characterise the chromosomes breakpoints, but instead the array-CGH showed the global gains and losses of the chromosomes. With this analysis, less rearrangements were detected than expected consid-

ering the complex structural abnormalities on the Karyotype. The micro-array results confirmed and defined the size of the *i*(12p) observed on both tumours, it showed the quantitative rearrangements present in both tumours and not in the peripheral blood of the patient.

4. Discussion

TML have recently been increasingly documented in the literature especially regarding the potential relationship between TML and TGCT, and its impact on the follow-up. TML are usually asymptomatic and detected during routine ultrasound examination of the testicles [1–6]. Radiologists established TML definition by the presence of at least five small non-shadowing hyperechoic foci ranging from 1 to 3 mm in diameter. Three stages have been described depending on the number of calcifications, without any clinical validated significance regarding evolution toward regression or tumor development [4,6,7,8].

Different studies on TML prevalence reported that 2.4–5.6% of asymptomatic adults and 1.1–4.2% of asymptomatic children present with TML [5–11].

TML are present in 45% of malignant testicular tumors in adults and in 14–16.9% of the normal testicle in case of contralateral malignant tumor and some authors report a high testicular recurrence rate in cases of previous germ-cell tumor associated with ML in the contralateral testicle, with an odd-ratio ranging between 12 and 17 [12,13].

In 2010, a meta-analysis reported no causal link between TML and cancer in the absence of additional risk factors. Yet, in the presence of risk factors, TML was associated with a substantially elevated risk of TGCT [14].

TML are supposed to originate from Seminiferous tubules degeneration, with intratubular calcium deposits, showing concentrically laminations containing DNA, phospholipid and protein scraps [1,4,10,12]. Drut suggested the role of an early disruption in gonad development leading to Sertoli cells dysfunction [15]. From 2004, some authors brought up the hypothesis that TML was a feature of “testicular dysgenesis syndrome” (TDS) and that genetics plays a key role in the onset of TML [16–21].

Moreover, recent studies still underlines the statistically significant augmentation of TGCT in TML population, either in children or adults, even if they do not retain TML as a risk factor per se [22,23].

According to Skotheim, TGCT of adolescent and young adults develop from precursor lesions or carcinoma in situ (CIS) believed to originate from diploid primordial germ cells during foetal life [21]. The procedure starts with aneuploidisation and extensive chromosome instability [21,24,25]. The transformation into invasive TGCT is associated with increased copy number of chromosome arm 12p mostly *i*(12p), indeed 12p gain is the most consistent chromosomal abnormality in human testicular cell tumours [26,27]. TGCT karyotypes are characterized by hyperdiploidy and frequently in the triploid range. This is the case in our patient with the hypotriploid modal number of the chromosomes in the first culture. Interestingly when the cells were cultured during a few more days, the karyotype of the abnormal cells became triploid. We wonder if the development of the second tumour is dependent or independent of the first one. Do the cells of both testicular tumours originate from the same clone? We showed that the second tumour shares the 12p amplification with the first tumour but has less abnormal gain or losses. Is the acquisition of the 12p amplification (or *i*(12p)) in the second tumour due to a secondary clone deriving from the first abnormal embryonic germ cells or is it depending only on the predisposition factors or genes giving “life” to a second independent tumour clone?

Table 1
Array-CGH results.

	Blood sample	Right testis (first tumour)	Left testis (delayed tumor)
Karyotype	Normal, no aberrations	Normal on 3 cells	
Day 20 culture		Numerous clonal and non-clonal aberrations on a hypotriploid modal number on 11 cells. cp[49–55]XX,Y,+i(1)(q10),del(1)(q?),add(1)(pter),+i(5p?)x2,der(7)(t(7;11)(pter;q?11),+der(8)t(8;?;13)(q23;?;q10),der(9)t(9;?;11)(pter;?;qter),der(10)t(10;5)(q26;q21),–11,+i(12p),–13,+15,+16,+17,–18,der(22)t(7;22)(p10;q10),+mar1[7]/id,+8,+14[2]	
Day 40 culture		One triploid cell 69,XX,-Y,-1,+i(1)(q10),del(1)(q?),add(1)(pter),–2,–3,–4 × 3,+der(7)(t(7;11)(pter;q?11),der(8)t(8;?;12)(q13;?;q10),–9,der(9)t(9;?;11)(pter;?;qter),der(10)t(10;5)(q26;q22),der(10)(q?),–11,der(12)(pter;?),i(12p),–13,+14,+15,t(15;22)(q10;q10),+16,–18 × 2,–19,–20,+21,der(22)t(7;22)(p10;q10),+mar1,+mar2,+mar3.	
Array-CGH on paraffin embedded sections:		Several amplification: 34Mb amplification in 12p13.33p11.1 4,9Mb amplification on 12q15q21.1 arr12p13.33p11.1(49,967–34,278,525)x3,12q15q21.1(66,881,502–71,821,410)x3,Xp22.33q28(2,710,316–154,494,649)x3 [Hg18]	Several amplifications: 34Mb in 12p13.33p11.1Xp22.33q28 arr 12p13.33p11.1(192,403–34,278,525)x3, Xp22.33q28(21,186,384–154,494,649)

Skotheim et coll showed that the genes *CCND2*, *CD9*, *GAPD*, *NANOG* on 12p and *GDF3*, and *TEAD4* are the most highly over-expressed genes in those tumours. They also observed gains for 7p15.2 and 21q22.2, losses of 4p16.3 and 22q13.3 [26].

Tanaka et coll identified *Ddx1* a member of the DEAD-box protein family as a gene predominantly expressed in the primordial germ cells of mouse embryos. They are implicated in a number of cellular processes involving alteration of RNA secondary structure such as translation initiation, nuclear and mitochondrial splicing, and ribosome and spliceosome assembly. Based on their distribution patterns, some members of this family are believed to be involved in embryogenesis, spermatogenesis, and cellular growth and division. Tanaka et coll have shown that *DDX1* knockdown in the human TGCT cell line NEC8 repressed the expression of stem cell-associated genes localized on chromosome 12p13.3 including cyclin-D2, *CD9* and *NANOG* [27].

Literature then suggests that dysgenesis origins in utero while TDS is promoted by environmental factors, possibly hormone-disrupting compounds affecting the mother and developing fetus, yet genetics might also play a role [20–22,28,29].

We are far from fully understanding all the different factors involved in testicular TML yet some pathways emerge: a possible interaction with genetic predisposition, environmental factors and TML; the risk of developing testicular tumor during childhood is very rare. The onset of a second tumor is even rarer, but in cases of previous TGCT associated with TML in the contralateral testicle, the risk of recurrence is high [13,19,29].

Conversely, some reported and well-documented cases showed that TML in children can spontaneously resolves over time [7,11].

The undisputable way to detect testicular tumor is repeated palpation [29]. In our case, the patient was informed yet it was the family physician who detected the second tumor, which had already metastasized at the time. Should we have done biopsies of the contralateral testicle initially? Should we have proposed fertility preservation via sperm storage early-on before prophylactic removal of the left testis? This brings up the issue of long-term

follow-up in children, especially the transition between adolescence and adulthood.

Before adolescence, the risk is almost non-existent, but even if educating patients and their family might be stressful for them; we think that in case of incidental discovery of bilateral TML, regular self-palpation starting before puberty is the only way to ensure proper monitoring and screening. A yearly ultrasound might in fact remind everyone; patient and family alike, of the underlying risk and thus increase their compliance with palpation.

Finally, in case of TGCT history associated with ML and contralateral ML, the option of fertility preservation via sperm storage and biopsies of the remaining testicle, with or without bilateral prophylactic orchiectomy should be brought up.

5. Conclusion

TML should not be considered a premalignant lesion but precise information have to be done to the child and his parents as well. History of personal or familial TGCT is alarming and should bring up the issue of aggressive surgical management in these cases. Therapeutic education on life duration self-palpation is the best way to ensure proper follow-up and screen for recurrence. If yearly ultrasounds can be suggested, parents and patients should be aware of the possibility of developing a tumor between two examinations.

One major issue is to ensure an excellent transition between pediatric and adult physicians.

Conflicts

No disclosure.

Funding

No funding.

Ethical approval

Approved by the ethic comission.

Consent

Consent obtained.

Author contribution

Nadia Boudaoud: final redaction.

Gauthier Loron: Références and revision.

Maguelone Pons initial redaction, initial drafts.

Emilie Landais: CGH Array.

Martine Doco fenzy: genetic analysis.

Marie-Laurence Poli-Merol: revision.

Guarantor

ML POLI-MEROL.

References

- [1] F.N. Miller, P.S. Sidhu, Does testicular microlithiasis matter? A review, *Clin. Radiol.* 57 (October (10)) (2002) 883–890.
- [2] S. Serter, B. Gümüş, M. Unlü, O. Tunçyürek, S. Tarhan, V. Ayyıldız, Y. Pabuscı, Prevalence of testicular microlithiasis in an asymptomatic population, *Scand. J. Urol. Nephrol.* 40 (3) (2006) 212–214.
- [3] J. Goede, W.W. Hack, L.M. van der Voort-Doedens, F.H. Pierik, L.H. Looijenga, K. Sijstermans, Testicular microlithiasis in boys and young men with congenital or acquired undescended (ascending) testis, *J. Urol.* 183 (April (4)) (2010) 1539–1543.
- [4] A.S. Leenen, T.W. Riebel, Testicular microlithiasis in children: sonographic features and clinical implications, *Pediatr. Radiol.* 32 (August (8)) (2002) 575–579.
- [5] A.C. Peterson, J.M. Bauman, D.E. Light, L.P. McMann, R.A. Costabile, The prevalence of testicular microlithiasis in an asymptomatic population of men 18–35 years old, *J. Urol.* 166 (December (6)) (2001) 2061–2064.
- [6] H. Dagash, E.A. Mackinnon, Testicular microlithiasis: what does it mean clinically? *BJU Int.* 99 (January (1)) (2007) 157–160.
- [7] Y.V. Volokhina, U.E. Oyoyo, J.H. Miller, Ultrasound demonstration of testicular microlithiasis in pediatric patients: is there an association with testicular germ cell tumors? *Pediatr. Radiol.* 44 (January (1)) (2014) 50–55.
- [8] S. Von Eckardstein, G. Tsakmakidis, A. Kamischke, C. Rolf, E. Nieschlag, Sonographic testicular microlithiasis as an indicator of premalignant conditions in normal and infertile men, *J. Androl.* 22 (September–October (5)) (2001) 818–824.
- [9] N.J. van Casteren, L.H. Looijenga, G.R. Dohle, Testicular microlithiasis and carcinoma in situ overview and proposed clinical guideline, *Int. J. Androl.* 32 (August (4)) (2009) 279–287.
- [10] B. Slaughenhaupt, A. Kadlec, C. Schrepferman, Testicular microlithiasis preceding metastatic mixed germ cell tumor—first pediatric report and recommended management of testicular microlithiasis in the pediatric population, *Urology* 73 (May (5)) (2009) 1029–1031.
- [11] L.W. Chiang, T.L. Yap, M.M. Asiri, C.C. Phaik Ong, Y. Low, A.S. Jacobsen, Implications of incidental finding of testicular microlithiasis in paediatric patients, *J. Pediatr. Urol.* 8 (April (2)) (2012).
- [12] F. Nicolas, R. Dubois, S. Laboure, H. Dodat, I. Canterino, O. Rouviere, Testicular microlithiasis and cryptorchism: ultrasound analysis after orchidopexy, *Prog. Urol.* 11 (April (2)) (2001) 357–361.
- [13] M. Holm, C.E. Hoei-Hansen, E. Rajpert-De Meyts, N.E. Skakkebaek, Increased risk of carcinoma in situ in patients with testicular germ cell cancer with ultrasonomicrolithiasis in the contralateral testicle, *J. Urol.* 170 (October (4 Pt1)) (2003) 1163–1167.
- [14] I.B. Tan, K.K. Ang, B.C. Ching, C. Mohan, C.K. Toh, M.H. Tan, Testicular microlithiasis predicts concurrent testicular germ cell tumors and intratubular germ cell neoplasia of unclassified type in adults: a meta-analysis and systematic review, *Cancer* 116 (October (19)) (2010) 4520–4532.
- [15] R. Drut, R.M. Drut, Testicular microlithiasis: histologic and immunohistochemical findings in 11 pediatric cases, *Pediatr. Dev. Pathol.* 5 (November–December (6)) (2002) 544–550.
- [16] M.L. Cooper, M. Kaefer, R. Fan, R.C. Rink, S.G. Jennings, B. Karmazyn, Testicular microlithiasis in children and associated testicular cancer, *Radiology* 270 (March (3)) (2014) (857-).
- [17] M.H. Tan, Eng C. Medscape, Testicular microlithiasis: recent advances in understanding and management, *Nat. Rev. Urol.* 8 (March (3)) (2011) 153–163.
- [18] T. Kawakami, K. Okamoto, O. Ogawa, Y. Okada, 63XIST unmethylated DNA fragments in male-derived plasma as a tumour marker for testicular cancer, *Lancet* 363 (January (9402)) (2004) 40–42.
- [19] J. Coffey, R.A. Huddart, F. Elliott, S.A. Sohaib, E. Parker, D. Dudakia, J.L. Pugh, D.F. Easton, D.T. Bishop, M.R. Stratton, E.A. Rapley, Testicular microlithiasis as a familial risk factor for testicular germ cell tumour, *Br. J. Cancer* 97 (December (12)) (2007) 1701–1706.
- [20] L.H. Looijenga, J.W. Oosterhuis, Pathogenesis of testicular germ cell tumours, *Rev. Reprod.* 4 (May (2)) (1999) 90–100.
- [21] R.I. Skotheim, R. Autio, G.E. Lind, S.M. Kraggerud, P.W. Andrews, O. Monni, O. Kallioniemi, R.A. Lothe, Novel genomic aberrations in testicular germ cell tumors by array-CGH, and associated gene expression changes, *Cell. Oncol.* 28 (5–6) (2006) 315–326.
- [22] A. Marte, L. Pintozzi, G. Creti, P.L. Chiesa, D.D. Renzo, M. Gasparella, G.D. Maggio, V. Bagnara, E. Merlini, B. Tadini, E. Caldarulo, L. Sangiorgio, G. Battagliano, S.G. Nappo, P. Caione, Long-term follow-up of testicular microlithiasis in children and adolescents: multicenter prospective cohort study of the Italian society of pediatric urology, *Eur. J. Pediatr. Surg.* 27 (April (2)) (2017) 155–160.
- [23] A.T. Trout, J. Chow, E.R. McNamara, K. Darge, R. Ramirez Grueso, M. Munden, S.M. Rothan, O.M. Navarro, M. Tijerín Bueno, K.E. Bove, K.R. Chikwava, A. Heider, M.J. Hicks, G.R. Somers, B. Zhang, J.R. Dillman, Association between testicular microlithiasis and testicular neoplasia: large multicenter study in a pediatric population, *Radiology* (July) (2017) 162625.
- [24] N.E. Skakkebaek, M. Holm, C. Hoei-Hansen, N. Jørgensen, E. Rajpert-De Meyts, Association between testicular dysgenesis syndrome (TDS) and testicular neoplasia: evidence from 20 adult patients with signs of maldevelopment of the testis, *APMIS* 111 (January (1)) (2003) 1–9, discussion 9–11.
- [25] S.B. Sonne, D.M. Kristensen, G.W. Novotny, I.A. Olesen, J.E. Nielsen, N.E. Skakkebaek, E. Rajpert-De Meyts, H. Leffers, Testicular dysgenesis syndrome and the origin of carcinoma in situ testis, *Int. J. Androl.* 31 (April (2)) (2008) 275–287.
- [26] R.I. Skotheim, R. Autio, G.E. Lind, S.M. Kraggerud, P.W. Andrews, O. Monni, O. Kallioniemi, R.A. Lothe, Novel genomic aberrations in testicular germ cell tumors by array-CGH, and associated gene expression changes, *Cell. Oncol.* 28 (5–6) (2006) 315–326.
- [27] K. Tanaka, S. Okamoto, Y. Ishikawa, H. Tamura, T. Hara, DDX1 is required for testicular tumorigenesis, partially through the transcriptional activation of 12p stem cell genes, *Oncogene* 28 (May (21)) (2009) 2142–2151.
- [28] M.H. Greene, P.L. Mai, J.T. Loud, A. Pathak, J.A. Peters, L. Mirabello, M.L. McMaster, P. Rosenberg, D.R. Stewart, Familial testicular germ cell tumors (FTGCT) – overview of a multidisciplinary etiologic study, *Andrology* 3 (January (1)) (2015) 47–58.
- [29] M.R. Pedersen, S.R. Rafaelsen, H. Møller, P. Vedsted, P.J. Osther, Testicular microlithiasis and testicular cancer: review of the literature, *Int. Urol. Nephrol.* 48 (July (7)) (2016) 1079–1086.

Open Access

This article is published Open Access at [sciencedirect.com](https://www.sciencedirect.com). It is distributed under the [IJSCR Supplemental terms and conditions](#), which permits unrestricted non commercial use, distribution, and reproduction in any medium, provided the original authors and source are credited.