



HAL
open science

Breast cancer, screening and diagnostic tools: All you need to know

Diego Barba, Ariana León-Sosa, Paulina Lugo, Daniela Suquillo, Fernando Torres, Frederic Surre, Lionel Trojman, Andrés Caicedo

► To cite this version:

Diego Barba, Ariana León-Sosa, Paulina Lugo, Daniela Suquillo, Fernando Torres, et al.. Breast cancer, screening and diagnostic tools: All you need to know. *Critical Reviews in Oncology/Hematology*, 2021, 157, pp.103174. 10.1016/j.critrevonc.2020.103174 . hal-03218320

HAL Id: hal-03218320

<https://hal.science/hal-03218320>

Submitted on 5 May 2021


HAL is a multi-disciplinary open access archive for the deposit and dissemination of scientific research documents, whether they are published or not. The documents may come from teaching and research institutions in France or abroad, or from public or private research centers.

L'archive ouverte pluridisciplinaire **HAL**, est destinée au dépôt et à la diffusion de documents scientifiques de niveau recherche, publiés ou non, émanant des établissements d'enseignement et de recherche français ou étrangers, des laboratoires publics ou privés.

Journal Pre-proof

Breast Cancer, Screening and Diagnostic Tools: All You Need to Know

Diego Barba (Methodology) (Investigation) (Visualization) <ce:contributor-role>Writing - review and editing), Ariana León-Sosa (Methodology) (Investigation) (Visualization) (Writing - review and editing), Paulina Lugo (Methodology) (Investigation) (Visualization) <ce:contributor-role>Writing - review and editing), Daniela Suquillo-Yépez (Methodology) (Investigation) (Visualization) <ce:contributor-role>Writing - review and editing), Fernando Torres (Investigation) (Writing - review and editing) (Funding acquisition), Frederic Surre (Methodology) (Investigation) <ce:contributor-role>Writing - review and editing), Lionel Trojman (Methodology) (Investigation) (Writing - review and editing) (Project administration) (Funding acquisition), Andrés Caicedo (Conceptualization) (Methodology) (Investigation) (Visualization) <ce:contributor-role>Writing - review and editing) (Supervision) (Project administration) (Funding acquisition)



PII: S1040-8428(20)30310-3
DOI: <https://doi.org/10.1016/j.critrevonc.2020.103174>
Reference: ONCH 103174

To appear in: *Critical Reviews in Oncology / Hematology*

Received Date: 28 April 2020
Revised Date: 18 September 2020
Accepted Date: 5 November 2020

Please cite this article as: Barba D, León-Sosa A, Lugo P, Suquillo-Yépez D, Torres F, Surre F, Trojman L, Caicedo A, Breast Cancer, Screening and Diagnostic Tools: All You Need to Know, *Critical Reviews in Oncology / Hematology* (2020), doi: <https://doi.org/10.1016/j.critrevonc.2020.103174>

This is a PDF file of an article that has undergone enhancements after acceptance, such as the addition of a cover page and metadata, and formatting for readability, but it is not yet the definitive version of record. This version will undergo additional copyediting, typesetting and review before it is published in its final form, but we are providing this version to give early visibility of the article. Please note that, during the production process, errors may be discovered which could affect the content, and all legal disclaimers that apply to the journal pertain.

© 2020 Published by Elsevier.

REVISÉD MANUSCRIPT TEXT UNMARKÉD

*Review***Breast Cancer, Screening and Diagnostic Tools: All You Need to Know**

Diego Barba^{1,2,3*} & *Ariana León-Sosa*^{1,2,3,4*}, *Paulina Lugo*^{5,6*} & *Daniela Suquillo-Yépez*^{2,3,7*},
Fernando Torres^{1,5} *Frederic Surre*⁸, *Lionel Trojman*^{9,10} & *Andrés Caicedo*^{1,2,3,4,11+}

1 Escuela de Medicina, Universidad San Francisco de Quito USFQ, Quito, Ecuador.

2 Instituto de Investigaciones en Biomedicina, Universidad San Francisco de Quito USFQ, Quito, Ecuador.

3 Mito-Act Research Consortium, Quito, Ecuador.

4 CEDIA-USFQ Research Initiative, Corporación Ecuatoriana para el Desarrollo de la Investigación y Académica CEDIA & Universidad San Francisco de Quito USFQ.

5 Hospital de los Valles HDLV, Quito, Ecuador.

6 Fundación Ayuda Familiar y Comunitaria AFAC, Quito Ecuador.

7 Ingeniería en Procesos Biotecnológicos, Colegio de Ciencias Biológicas y Ambientales COCIBA, Universidad San Francisco de Quito USFQ, Quito, Ecuador.

8 University of Glasgow, James Watt School of Engineering, Glasgow, G12 8QQ, United Kingdom.

9 LISITE, Isep, 75006 Paris, France.

10 Universidad San Francisco de Quito USFQ, Colegio de Ciencias e Ingenierías Politécnico - USFQ, Instituto de Micro y Nanoelectrónica, IMNE, USFQ, Quito, Ecuador

11 Sistemas Médicos SIME, Universidad San Francisco de Quito USFQ, Quito, Ecuador

*Contributed equally, authors are mentioned in alphabetical order.

+Corresponding author: Andrés Caicedo, Universidad San Francisco de Quito USFQ, Colegio de Ciencias de la Salud, Escuela de Medicina, 17-12-841, Quito, Ecuador acaicedo@usfq.edu.

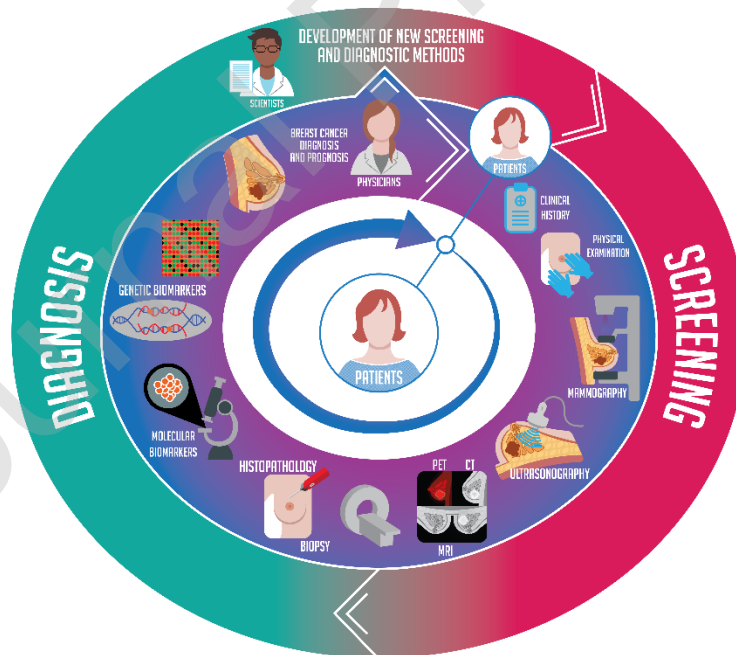
Table of contents

1. Introduction	5
2. Normal Breast Tissue	9
3. Breast Cancer Generalities	11
4. Breast Cancer Screening Recommendations	14
4.1 Women with Average Risk	14
4.2 Women with High Risk	15
5. Established Methods of Screening and Diagnosis	15
5.1 Breast Physical Examination	17
5.2 Mammography	17
5.2.1 Full-Field Digital Mammography	18
5.2.2 Digital Breast Tomosynthesis	18
5.3 Ultrasonography	19
5.4 Magnetic Resonance Imaging	19
5.5 Positron Emission Tomography/Computed Tomography	20
6. Emerging Methods of Screening and Diagnosis	21

6.1 Optical Imaging	21
6.2 Digital Infrared Thermography Imaging	22
6.3 Contrast-Enhanced Mammography	23
6.4 Scintimammography	24
6.5 Future Role of Positron Emission Tomography and New Tracers	25
6.6 Magnetic Resonance Elastography	26
6.7 Acoustic Radiation Force Impulse Imaging	27
6.8 Diffusion-Weighted Magnetic Resonance Imaging	27
6.9 Ductoscopy and Ductal Lavage	28
6.10 Radiomics	28
6.11 Internet of Things and Machine Learning Based Diagnosis Tool	30
7. Biopsy	31
8. Staging and Grading of Breast Tumors	32
9. Breast Cancer Classification	33
9.1 Carcinomas	33
9.1.1 Ductal Carcinoma	33
9.1.1.1 Ductal Carcinoma <i>In Situ</i>	33
9.1.1.2 Invasive Ductal Carcinoma	33
9.1.2 Lobular Carcinoma	34
9.1.2.1 Lobular Carcinoma <i>In Situ</i>	34
9.1.2.2 Invasive Lobular Carcinoma	35
9.1.3 Metastatic Carcinomas	36
9.2 Sarcomas	37
10. Breast Cancer Biomarkers	37
10.1 Established Molecular Biomarkers	39
10.1.1 Ki67	39
10.1.2 Estrogen Receptor	39
10.1.3 Progesterone Receptor	39
10.1.4 Human Epidermal Growth Factor Receptor 2	40
10.1.5 Molecular Subtypes Based on Immunohistochemistry Detection of Established Biomarkers	40
10.2 Emerging Molecular Biomarkers	42
10.2.1 Estrogen Related Receptors	42
10.2.2 MicroRNAs	43
10.2.3 Exosomes	44
10.2.4 Circulating Tumor DNA	44
10.3 Genetic Tests and Biomarkers	45
10.3.1 Gene Sequencing	45
10.3.2 Gene Expression Profiling/Signatures	46
10.3.2.1 MammaPrint®	46

10.3.2.2 Prosigna®	47
10.3.2.3 Oncotype DX®	48
10.3.2.4 EndoPredict®	49
10.3.2.5 Breast Cancer Index®	50
10.3.2.6 Genetic Signatures & Clinical Guidelines Recommendations: Towards the Prognostic Staging	51
11. Issues with Current Screening and Diagnostic Tools: The Need for New or Improved Techniques	56
12. Conclusion	59
Data Availability Statement	60
Author Contributions	60
Funding	60
Role of the Funding Source	60
Acknowledgments	60
Conflict of Interest	61
Abbreviations	61
13. Bibliography	64

Graphical Abstract



Highlights

- Nearly two million cases of breast cancer are diagnosed each year worldwide.

- Multidisciplinary approaches are used to develop screening and diagnostic tools.
- Key information is provided on breast cancer for medical and research professionals.
- Breast cancer biology, standard and innovative detection tools are presented.
- This information is needed to develop better diagnostic and screening tools.

Abstract

Breast cancer is one of the most frequent malignancies among women worldwide. Methods for screening and diagnosis allow health care professionals to provide personalized treatments that improve the outcome and survival. Scientists and physicians are working side-by-side to develop evidence-based guidelines and equipment to detect cancer earlier. However, the lack of comprehensive interdisciplinary information and understanding between biomedical, medical, and technology professionals makes innovation of new screening and diagnosis tools difficult. This critical review gathers, for the first time, information concerning normal breast and cancer biology, established and emerging methods for screening and diagnosis, staging and grading, molecular and genetic biomarkers. Our purpose is to address key interdisciplinary information about these methods for physicians and scientists. Only the multidisciplinary interaction and communication between scientists, health care professionals, technical experts and patients will lead to the development of better detection tools and methods for an improved screening and early diagnosis.

Abbreviations

ACCE	Analytical validity, Clinical validity, Clinical utility, Ethical, legal, and social implications
ACS	American Cancer Society
ADC	Apparent Diffusion Coefficient
AI	Artificial Intelligence
AIB1	Coactivator Amplified in Breast Cancer 1
AJCC	American Joint Committee on Cancer
ACR	American College of Radiology
anti-CTLA-4	Anti-Cytotoxic T-Lymphocyte-Associated Protein 4
anti-PD1	Anti-Programmed Cell Death Protein 1
anti-PD-L1	Anti-Programmed Cell Death-1 Ligand 1
AR	Androgen Receptor
ARFI	Acoustic Radiation Force Impulse Imaging
ASCO	American Society of Clinical Oncology
BCSC	Breast Cancer Surveillance Consortium
BI-RADS	Breast Imaging-Reporting and Data System
BMI	Body Mass Index
BPx	Breast Physical Examination
BCS	Breast Cancer Screening
CAD	Computer-Aided Detection
CAFs	Cancer-Associated Fibroblasts

CBE	Clinical Breast Examination
CDC	Centers for Disease Control and Prevention
CEM	Contrast-Enhanced Mammography
CE-MRI	Contrast Enhanced-MRI
Chi3L1	Chitinase 3-like 1
CSCs	Cancer Stem Cells
ctDNA	Circulating Tumor DNA
CTS	Clinical Treatment Score
CTX	Chemotherapy
CXCL4	Chemokine (C-X-C motif) Ligand 4
DBT	Digital Breast Tomosynthesis
DCIS	Ductal Carcinoma <i>In Situ</i>
DNA	Deoxyribonucleic Acid
DITI	Digital Infrared Thermography Imaging
DOT	Diffuse Optical Tomography
DW-MRI	Diffusion Weighted-MRI
ECIBC	European Breast Guidelines of the European Commission Initiative on Breast Cancer
EGFR	Epidermal Growth Factor Receptor
EMT	Epithelial to Mesenchymal Transition
EORTC	European Organization for Research and Treatment of Cancer
EPclin [®]	EndoPredict Clinical [®]
ER+/-	Estrogen/Estradiol Receptor Positive/Negative
EREs	Estrogen Response Elements
ERRs $\alpha/\beta/\gamma$	Estrogen-Related Receptors $\alpha/\beta/\gamma$
ESMO	European Society for Medical Oncology
EXET	Extended Endocrine Trial
EXOs	Exosomes
FES	16α - $18F$ -fluoro- 17β -estradiol
FDA	Food and Drug Administration
FDG	Fluorodeoxyglucose
FDS	Fiberoptic Ductoscopy
FFA	Free Fatty Acids
FFDM	Full-Field Digital Mammography
GEP/S	Gene Expression Profiling/Signatures
GLOBOCAN	Global Cancer Observatory
HbT	Hydrogen Breast Test
HDA1	Histone Deacetylase 1
HER1/2/3 +/-	Human Epidermal Growth Factor Receptor 1/2/3 Positive/Negative
HR+/-	Hormone Receptor Positive/Negative

HT	Hormonal Therapy
IDC	Invasive Ductal Carcinoma
IDO	Indoleamine 2,3-Dioxygenase
IHC	Immunohistochemistry
IHC4	Immunohistochemical 4
IL	Interleukin
IoT	Internet of Things
IR	InfraRed
LCIS	Lobular Carcinoma <i>In Situ</i>
LN+/-	Lymph-Nodes Positive/Negative
mAbs	Monoclonal Antibodies
MHC-I	Major Histocompatibility Complex I
MINDACT	Microarray in Node-Negative Disease May Avoid Chemotherapy Trial
miRNAs	MicroRNAs
ML	Machine Learning
MRE	Magnetic Resonance Elastography
MRI	Magnetic Resonance Imaging
MSCs	Mesenchymal Stem Cells
mTOR	Mammalian Target of Rapamycin
NADH	Reduced Nicotinamide Adenine Dinucleotide
NCCN	National Comprehensive Cancer Network
N-CoR	Nuclear Receptor Co-Repressor
NmU	Neuromedin U
OCT	Optical Coherence Tomography
PET/CT	Positron Emission Tomography/Computed Tomography
PGC1 α /1 β	Peroxisome Proliferator-Activated Receptor Gamma Co-Activator 1 α /1 β
PPAR γ	Peroxisome Proliferator-Activated Receptor- γ
PR+/-	Progesterone Receptor Positive/Negative
RASTER	microarRAY-prognOSTics-in-breast-cancER
ROI	Region of Interest
ROS	Reactive Oxygen Species
RTK	Receptor Tyrosine Kinase
SBI	Society of Breast Imaging
SEER	Surveillance, Epidemiology and End Results
SG	St. Gallen International Breast Cancer Conference
SND	Spontaneous Nipple Discharge
SoC	System-on-Chip
STAT3	Signal Transducer and Activator of Transcription 3
StO ₂	Oxygen Saturation
TA-MUC1	Tumor-Associated Transmembrane Glycoprotein Mucin 1

^{99m} Tc-MIBI	Technetium-99m Sestamibi
TFF1	Trefoil Factor 1
TMA	Tissue Microarray
TME	Tumor Microenvironment
TNM	Tumor, Node and Metastasis
TransATAC trial	Trans Arimidex, Tamoxifen, Alone or in Combination trial
UCPs	Uncoupling Proteins
US	United States
USPSTF	U.S. Preventive Services Task Force
VEGF	Vascular Endothelial Growth Factor
YAP	Yes-Associated Protein

Key words: Breast cancer, screening, diagnosis, tools, mammography, biopsy, genetic profiling, artificial intelligence.

1. Introduction

Each year, 2.1 million women are diagnosed with breast cancer [1]. In the United States (US), the five-year relative survival after diagnosis for localized breast cancer is 98.8%, for regional cancer is 85.5%, for distant cancer is 27.4% and for unknown disease stage is 54.5% [2]. Early diagnosis strategies aim to increase the number of accurately identified early stage breast cancers by increasing the access to diagnostic services and by providing opportune cancer treatment [1]. Early diagnosis is key for improving patients' survival, as it gives insight regarding the most appropriate therapeutic strategy for each case [3]. Breast cancer screening (BCS) is defined as testing women before any evident symptoms appear, generally by mammography and clinical breast examination (CBE) to detect and treat cancers or pre-cancers [1]. Public and professional knowledge with patient awareness of the disease is necessary to take actions such as determining what cases need to use screening and diagnostic tools (**Fig. 1**). It is our opinion that multidisciplinary communication between technology experts, biomedical researchers and physicians should be improved with the goal to ameliorate the survival rate of patients by providing reliable screening and diagnostic tools.

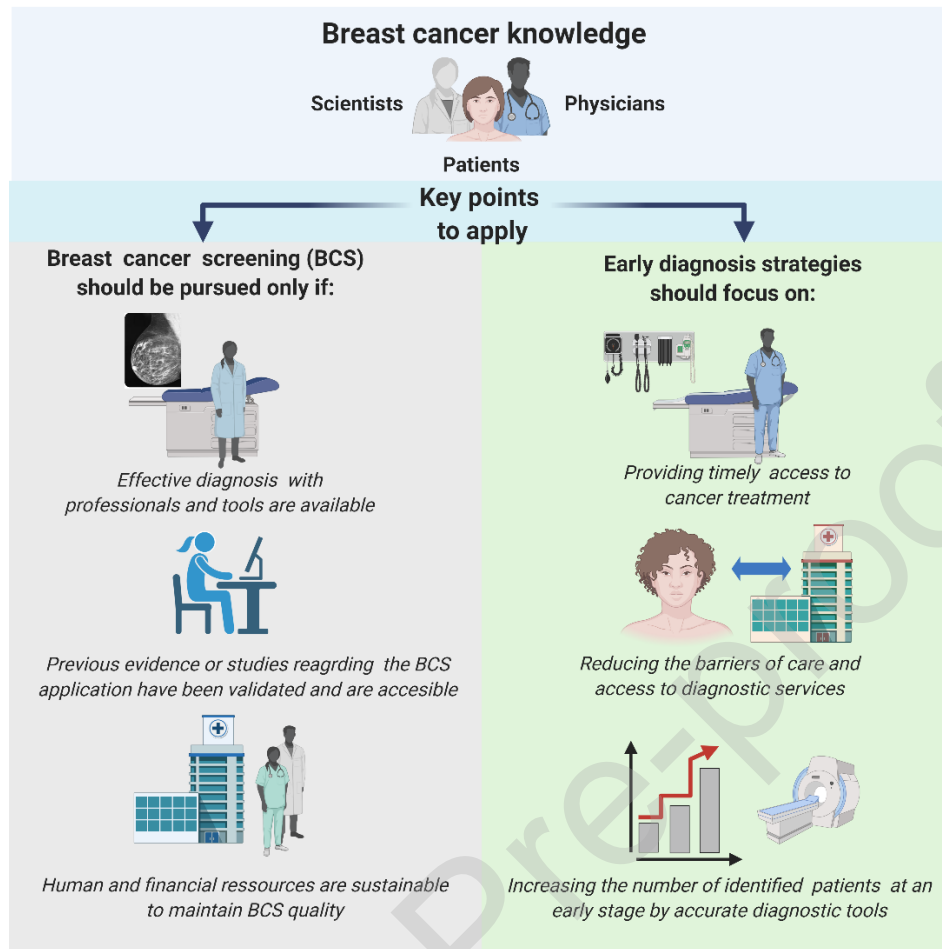


Figure 1. Breast cancer knowledge from scientists, physicians and patients lead to the implementation of adequate screening and breast cancer early diagnosis. The implementation of breast cancer screening must be done only if professionals and tools are available to provide effective diagnosis. Previous evidence reports the success of a screening campaign/initiative and assure that the BCS campaign or initiative is sustainable with allocated human and financial resources to ensure its quality. Even if these recommendations are concise, there is no evidence still that the interventions for raising breast cancer awareness in women work, as there is a lack of high-quality studies with larger samples and follow up for a longer time. Early diagnosis is the best strategy so far that increase the survival rate of patients and allows an effective therapeutic decision. The best strategies for an early diagnosis aim to provide a timely access to cancer treatment, reduce the barriers between patients and health care services and finally being able to increase the number of correctly identified patients with breast cancer with accurate diagnostic tools. Created with BioRender.com.

The US National Comprehensive Cancer Network (NCCN) 2019 guidelines recommended performing an annual CBE and mammography for women over 40 years old, as there are no randomized studies that suggest a benefit in screening women under this age [4–7]. This

recommendation is the preferred screening approach, making it the gold standard in the US [4–6]. It has been observed that BCS for women of all ages, with an average risk of having the disease, is associated with a mortality reduction in the US [8]. However, more studies regarding which specific populations in terms of age and ethnicity are recommended for early BCS as there is still uncertainty [4–6,8]. The practice of BCS lies in the clinical judgement of health care professionals based on scientific evidence. Nevertheless, the interaction between physicians, researchers and technology experts is necessary to refine the application of BCS.

The results obtained from BCS and diagnostic tools could be misinterpreted leading to false positives, false negatives, re-tests, and overdiagnosis [9]. Hence, artificial intelligence (AI) based algorithms are under constant development and evaluation by technology experts, biomedical researchers and physicians to decrease the possibility of misinterpretations. Another issue is the discomfort and stress generated during screening and diagnostic procedures which reduce the willingness of patients to perform the tests [10–14]. It is common that diagnostic equipment and tests are mostly accessible in specialized hospitals and cannot be easily reached by the population living in rural areas or that have transportation impairments [15]. Due to this possible obstacle, BCS campaigns have been done, emphasizing rural areas, which have helped women at risk to increase their survival rate [16]. In definitive terms, improving accessibility and comfort of BCS and diagnostic tools could improve the detection of patients living in rural areas allowing early therapy if required.

Molecular analysis such as the identification of mutations and gene expression profiling/signatures (GEP/S) are commonly used to determine breast cancer predisposition, subtype and aggressiveness, respectively. It has been observed that 5% to 10% of breast cancer patients have a genetic predisposition to develop the disease [17]. After initial screening, the analysis of GEP/S in breast biopsies is a complex task as each cancer develops differently in many aspects from one person to another, impairing the accuracy of the analysis [18]. The comprehension of gene-set expression abnormalities and their correlation with the aggressiveness involves an exhaustive and accurate task using bioinformatics and machine learning (ML) tools [19]. Recent studies support the use of GEP/S to improve treatment decisions which could lead to better patient outcomes [6,20,21].

A great amount of patient's data has been collected worldwide during different phases of breast cancer with the use of multiple screening and diagnostic tools (**Graphical abstract**). These data correspond to a variety of tests, including physical examination, imaging, immunohistochemical analysis, GEP/S, and large-scale genomics. The analysis of these data would help in the understanding of what is needed to develop devices or diagnostic algorithms updating clinical guidelines. Advances in systems biology could integrate the available information, to generate new biomarker panels and devices [22]. However, many low-to-middle income countries lack the capacity to condense information and integrate an international medical

and scientific network such as the Global Cancer Observatory (GLOBOCAN) [23–25]. Combining different low-cost analysis procedures would lead to better access for more accurate recommendations and the treatment of cancer at an early stage in developing countries [26,27].

It is important to provide the necessary information concerning the most common diagnostic procedures and the use of new combinatorial approaches. This will support the decision of health professionals regarding the application of one tool over another. In addition, understanding the physiology of the breast and how it changes during cancer is key to develop new screening and diagnostic tools (**Graphical abstract**). In this comprehensive review, we introduce and summarize key information about the normal breast tissue, cancer biology, current methods of screening and detection, emerging methods of detection, staging, grading and classification of breast cancer, as well as molecular and genetic biomarkers (**Fig. 2**). Nowadays, the ability to comprehend the main aspects of breast cancer biology and the most used methods of detection will allow the development of innovations to satisfy patient needs in three aspects: accuracy, comfort and accessibility.

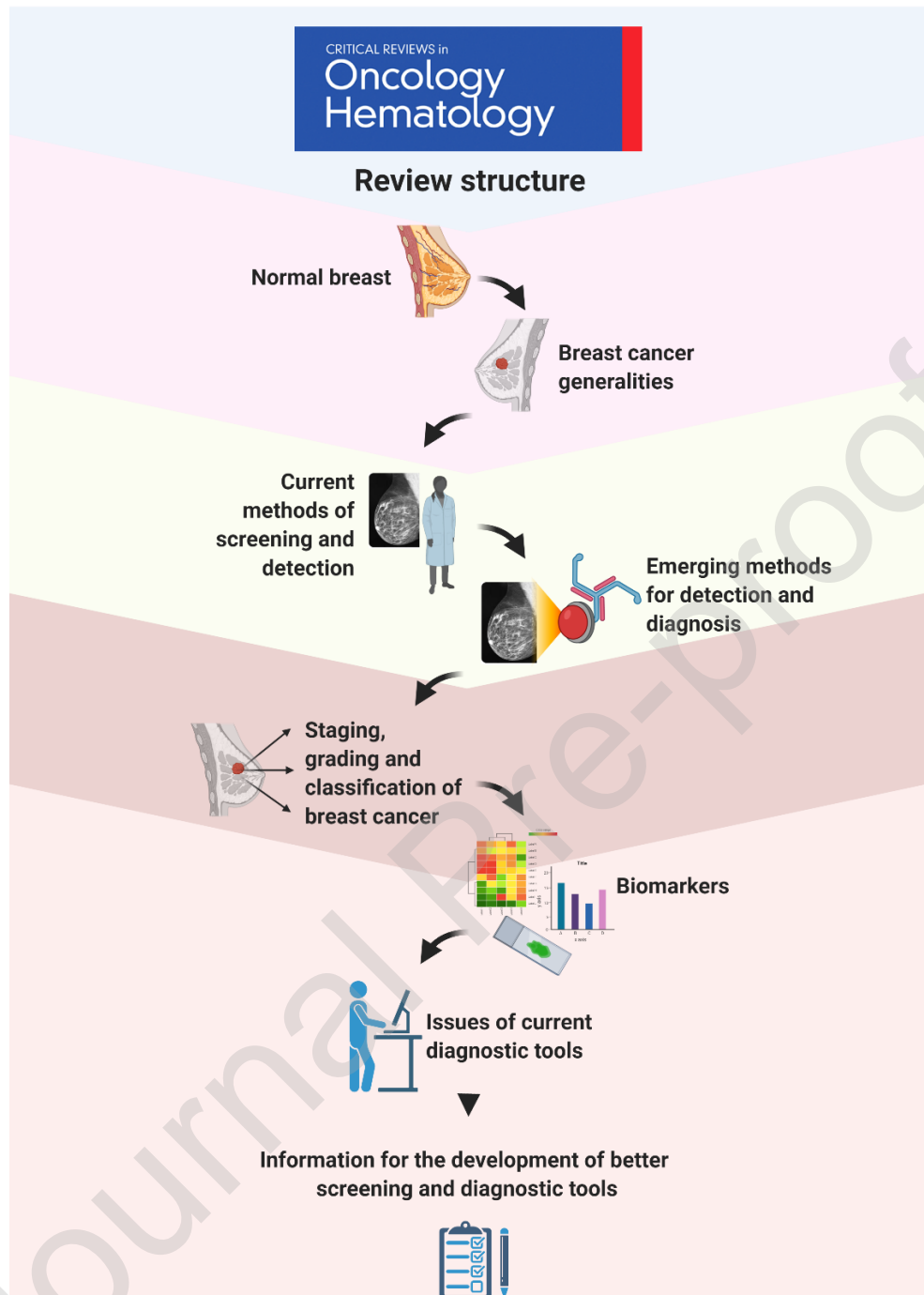


Figure 2. Review structure. The aim of this review is to provide patients, technology experts, physicians and scientists with key information to understand breast cancer screening and diagnosis. We will provide you with the information concerning the normal breast and cancer biology, the established and emerging methods for screening and detection, staging and grading, molecular and genetic biomarkers. Finally, we discuss current key issues in the journey of screening and diagnosis, and how these information could help to generate better tools. Created with BioRender.com.

2. Normal Breast Tissue

Breast cancer awareness entails the understanding of the differences between the normal physiology of the breast and a lesion that could result benign, precancerous or cancerous [28–30]. The NCCN recommends that women should be familiar with their breast and be able to communicate with the health care provider to transmit any sign of alarm [7]. Strengthen the knowledge of the normal physiology would prevent or decrease the negligence of women regarding self-inspection and search for help from a physician for CBE timely [31]. It is our belief that having basic knowledge of breast anatomy would help technology experts to communicate better with physicians and develop better screening and diagnostic procedures (**Fig. 3**).

The micro and macro-anatomy of mammary glands change according to age and hormonal secretions throughout a female's lifetime. Breast development stages are: fetal, neonatal/prepubertal and post pubertal [32]. It continues with pubertal expansion (only women who experiment pregnancy and childbirth experiment all breast developmental stages which includes pregnancy/lactation cycle and post-lactation involution) and postmenopausal involution [32]. Mammary glands start forming at the sixth week of gestational growth. By the end of the fetal formation, only the main lactiferous ducts are completely structured and the mammary glands do not develop further until puberty [32,33]. In females, breasts start growing around 8-12 years of age in response to hormonal changes related to puberty. This includes an increase in plasma concentration of estrogen, prolactin, luteinizing hormone, follicle-stimulating hormone and growth hormone. Later, the breast duct development continues until menstruation [32,34]. A mature breast is made up of multiple tissue layers such as fatty, glandular and dense tissue [35].

Anatomically, the breast is located over the pectoral muscles and sustained by the suspensory ligaments of the breast (Cooper's) [36]. It is composed of a complex network of arteries, veins and lymph vessels that carry blood, nutrients and chemical messengers as well as drain waste material. Blood supply of the breast is provided by the internal mammary and the lateral thoracic arteries in addition to small blood vessels. The venous drainage of the breast consists of veins localized in the thoracic, axillary and cephalic regions. The lymphatic drainage from the breast comprehends the axillary nodes and the internal mammary nodes. The lymph is mainly drained from the medial and lateral nodes to the axillary node [32]. The fat layer surrounds the glandular tissue which is organized into 15 to 20 sections called lobes of adipose tissue, and within each lobe there are smaller structures called lobules that contain between 10 and 100 alveoli (0.12mm diameter) [32,36]. These glands become fully mature during pregnancy and lactation cycle, where the organ is prepared to synthesize and secrete milk, a process that requires about 25% of daily maternal energy [32,33].

Normal interindividual differences in breast tissue distribution are influenced by genetic background and lifestyle [37]. The heterogeneous distribution of breast tissues does not permit to establish standard measures. However, the breast density ratio between fibro glandular and adipose tissue is estimated to be 1:1 by mammography screening [32]. According to the Centers for Disease Control and Prevention (CDC), 10% of women possess fatty breasts, 40% breasts with few areas of dense tissue, 40% heterogenous breasts and 10% have extremely dense breasts. Studies have shown that around 66% of premenopausal women and 33% of elderly women (75-79 years) have breasts with a 50% of density or more [38,39]. The Breast Imaging-Reporting and Data System (BI-RADS) classifies breast density into: BI-RADS A: mostly composed by fatty tissue (low density), BI-RADS B: scattered fibro glandular tissue (medium density), BI-RADS C: heterogeneous tissue (high density) and BI-RADS D: extremely dense tissue (very high density) [38,39]. Dense breast tissue is considered an independent biological risk factor for the development of breast cancer. Additionally, it restrains the evaluation of breast cancer by health professionals and limits the detection of early stage tumors due to its masking effect, decreasing the sensitivity of mammograms [38–40].

Breasts are in constant change due to several factors such as hormonal changes, genetics, breast density and lifestyle. Understanding the anatomy and physiology of normal breast tissue is critical to conceive breast cancer development and could support early detection of suspicious lesions. Breast cancer awareness provides valuable information to reduce negligence in women about their health. It could also encourage presentation to a healthcare professional and promotes communication among patients and physicians (Fig. 3).

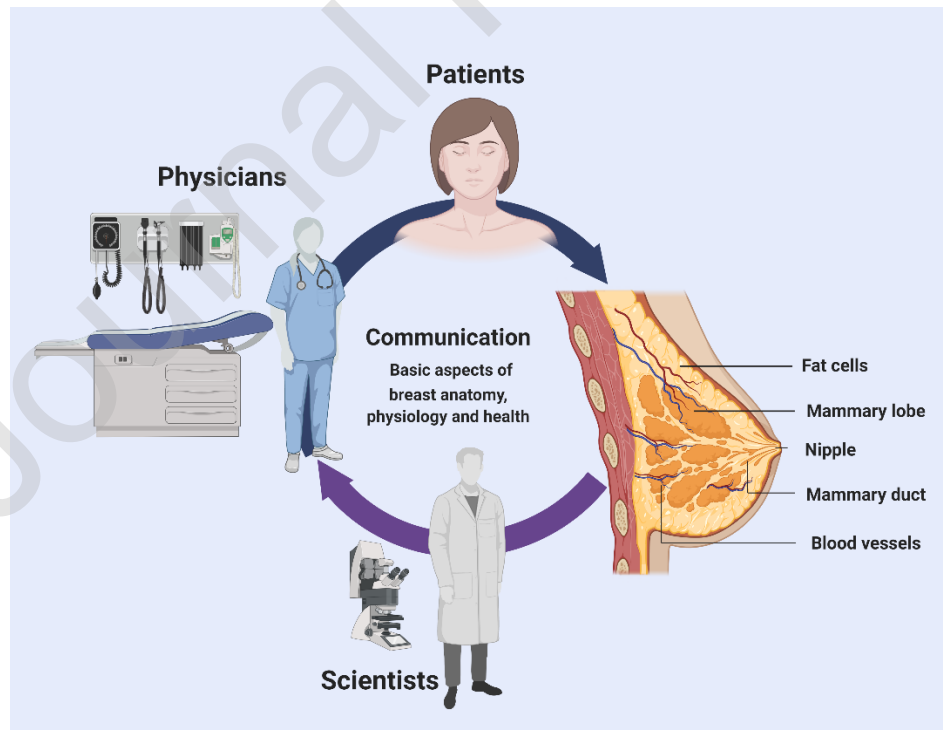


Figure 3. Communication among patients, physicians, and scientists is essential to understand the basic aspects of breast anatomy and health. Transmitting information about normal breast tissue, its physiology, lesion symptoms, and clinical management is key for an early diagnosis and development of better diagnostic approaches. Created with BioRender.com.

3. Breast Cancer Generalities

Cancer can be caused by a mix of genetic predisposition, environmental agents and lifestyle (Fig. 4) [2]. Age and breast density are naturally occurring factors that could increase the risk of developing the disease [41]. In addition, it is well known that changes in the circadian rhythm, as well as alcohol and tobacco consumption are agents that augment the probability of having breast cancer [42–44]. These factors can cause cellular stress, increase the production of reactive oxygen species (ROS) and induce changes in hormone concentrations of estrogen and progesterone, amplifying the aggressiveness of the tumor [45,46]. It has been observed that poor eating habits augment the risk of breast cancer [47–49]. Women with a body mass index (BMI) over 25 are at higher risk of developing cancer and recurrence in comparison to those with a normal BMI. Estrogen overproduction within adipose breast tissue, in combination with chronic inflammation due to obesity, stimulates the growth of hormone receptor positive (HR+) tumors [50,51]. An effective immune-surveillance as a result of a healthy lifestyle could reinforce the detection and elimination of abnormal cancer cells in an early stage, thereby decreasing the possibilities of cancer progression [48,49,52]. However, when cancer cells are already installed, they modify their microenvironment generating immune-scape and facilitating the growth and invasion of other tissue compartments [53,54].

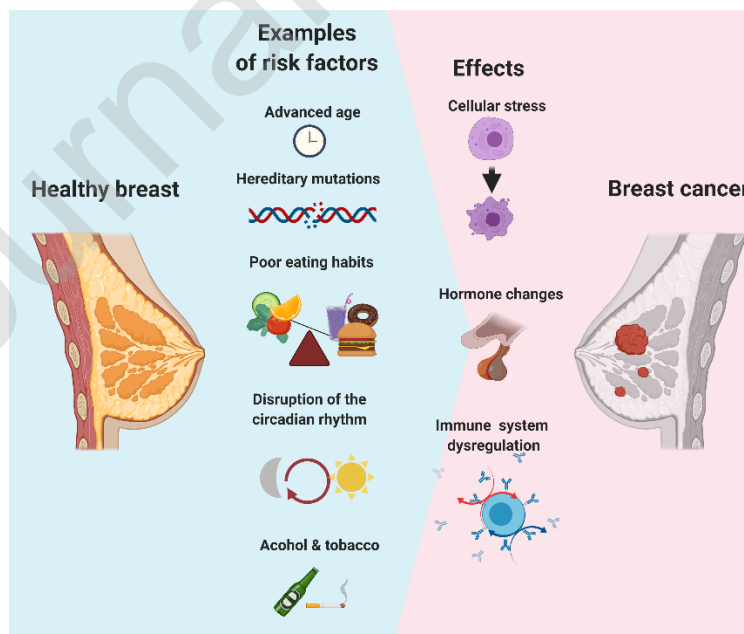


Figure 4. Breast cancer risks and effects. Factors such as advanced age, hereditary mutations, poor eating habits, disruption of the circadian rhythm, alcohol and tobacco consumption can cause cellular stress, hormone changes and perturbations in the immune cells leading to cancer. Created with BioRender.com.

Cancer could start from a variety of cell types within breast tissue (**Refer to Breast Cancer Classification**). Both differentiated and adult stem cells could carry inherited or acquired mutations [55,56]. These mutations grant cells independence from their self-control mechanisms, such as division checkpoints, leading to excessive proliferation, resistance to cell death and survival, treatment resistance and even replicative immortality [57]. These hallmarks result in an advantage to intratumor selective pressure and natural selection leading to adaptation and tumor progression [56–58]. Cancer stem cells (CSCs) and differentiated cells at the origin of cancer will grow with increasing complexity and generate multiple interactions with the surrounding stroma [55,59]. Cancer cells interact with host cells such as mesenchymal stem cells (MSCs), immune cells, vascular endothelial cells, and adipocytes [55,59–62]. These interactions shape the tumor microenvironment (TME) and play an essential role in the development of the disease. TME interactions which involve the secretion of micro vesicles, cytokines and other molecules can be measured and correlated with the rate of tumor development or aggressiveness [57,63–65]. During tumor progression, cells lose their epithelial markers, causing them to remodel their interaction with the TME's extracellular matrix, detach themselves from each other and from the underlying basement membrane and become mobile [66]. This process is known as the epithelial to mesenchymal transition (EMT), which is associated with an increased tumor-initiating capacity, metastatic potential and resistance to chemotherapy (CTX) agents [57,66].

Multiple interactions occur inside the breast's TME promoting or interrupting its development [67]. The presence and number of immune cells in the TME vary among individuals, as various factors can influence their homing to the tumor and their activity [68]. Depending on individual immunity, innate and adaptive immune cells could promote or stop tumorigenesis. Inflammation in the TME can trigger molecules such as indoleamine 2,3-dioxygenase (IDO) in a first instance, however, this molecule can promote immune tolerance to cancer in a later stage [69]. Cancer cells can also generate multiple adaptations to be unrecognized by immune cells. These cells can express specific surface antigens to diminish the response of the immune system, can lose expression of major histocompatibility complex I (MHC-I), and can lose cell death inducers, among other mechanisms [70–72]. Cancer cells can also change the phenotype of stromal cells such as fibroblasts and MSCs, transforming them in cancer-associated fibroblasts (CAFs) which provide the cancer with nutrients, survival factors and intracellular material, such as mitochondria [61,73,74]. CAFs can also impair the activation of immune cells by secreting interleukin (IL)-4, IL-6 and IL-8, inducing myeloid cell differentiation [75]. Expression of chemokine (C-X-C motif) ligand 4 (CXCL4) by CAFs affect the recruitment of macrophages to the tumor, and the secretion

of factors such as Chitinase 3-like 1 (Chi3L1), which promote the transformation of macrophages in M2 (immune-regulatory function) [75,76]. Chronic inflammation in the tumor can also promote its progression and metastasis as it suppresses the immune responses [77]. Yes-associated protein (YAP), Signal transducer and activator of transcription 3 (STAT3) and Notch are stem cell activation factors that respond to inflammatory signals promoting the emergence of CSCs in the tumor [77,78]. Chronic inflammation has been observed to change the physical and temperature dynamics in the breast, which can be measured together with the aberrant levels of inflammatory cytokines during cancer progression [79–81].

The great cell heterogeneity of breast cancer is due to the increasing number of mutations supported by a high proliferation rate and individual environmental risk factors that influence and promote carcinogenesis [82,83]. During the process of cancer development, multiple interactions between mutations and signaling pathways inside cells drive the tumor and its malignancy. It has been shown that tumor cells can pass through metabolic changes and overexpress proteins related to thermogenesis such as the uncoupling proteins (UCPs), which could increase and modify normal temperature dynamics in the breast [84]. Breast cancer cells can switch to a glycolytic metabolism and increase lactate production in a process called the “Warburg effect” [85]. The most aggressive breast cancers tend to have an increased glucose consumption, using glucose carbon sources to support tumorigenesis. This process is activated by several receptors including the receptor tyrosine kinase (RTK), epidermal growth factor receptor (EGFR), among others which are highly expressed in cancers with the worst prognosis [86,87]. Glycolysis has been correlated with the overexpression of the neuropeptide Neuromedin U (NmU), inflammatory factors such as IL-6 and the presence of CSCs [88]. The presence of free fatty acids (FFA) in blood, a factor associated with obesity, has shown to be related to higher proliferation and aggressiveness in breast cancer cells. These FFA activates the mammalian Target of Rapamycin (mTOR) pathway increasing the metabolic rate and growth of cancer. These adaptations rewire the metabolism of tumor cells, allowing their adaptation to poor perfusion, lack of nutrients and accumulation of metabolic byproducts such as lactate in the TME [57,89]. The characteristics of cellular energetics deregulation are being used as targets for diagnosis and development of treatments in breast cancer [57,90,91].

Breast cancer acquires specific biological characteristics during its development that can be used to generate better diagnostic tools. Tumor metabolic changes, temperature variations and texture dynamics could offer the possibility to increase the number of measurable factors for sensors. Devices and software could use these factors for the development of an integrative analysis of cancer aggressiveness leading to better prognosis. Liquid biopsies that could contain micro vesicles, tumor circulating deoxyribonucleic acid (DNA), cytokines and other factors located in the TME are becoming more studied to develop minimally invasive procedures. Before the arrival of all these potential devices, software and new biopsy procedures in clinical practices,

they must be validated in a process that could take time and investment as they move along each step of clinical trials generating evidence of safety and efficacy [92,93].

4. Breast Cancer Screening Recommendations

Recommendations for BCS depend on the risk factors of each woman. Nonetheless, patients can be classified into two major groups: average population risk and high associated risk (e.g. BRCA1/2 mutations).

4.1 Women with Average Risk

The NCCN recommends breast awareness and CBE as part of routine check-ups, every one to three years from the age of 25 to 39, and annually from the age of 40 [7]. On the contrary, the American Cancer Society (ACS) does not recommend BSE or CBE, however it highlights the need for women to become familiar with their breasts and to promptly inform their doctor if they notice any changes [94].

The most recommended screening method for average-risk women is mammography. Even though the test has its limitations, it has been shown to decrease breast cancer mortality and detect smaller cancers leading to less invasive treatments. Beyond this agreement, there is controversy regarding the range age and frequency for mammography screening. Several organizations publish recommendations based on scientific evidence that assess benefits, risks, and side effects of screening methods for its inclusion in clinical practice [7,94,95]. Current guidelines consider the variables noted above for screening recommendations. According to the NCCN [7] and American College of Radiology (ACR) [95], mammography is suggested from the age of 40. The European Breast Guidelines of the European Commission Initiative on Breast Cancer (ECIBC) [96] and the ACS [94] propose to begin mammography at 45 years of age. Nonetheless, the ACS raises the possibility to start the screening at 40 years of age in patients who agree with their physician. Regarding the frequency of screening, the NCCN and the ACR recommend annual mammography [7,94,95]. The ACS suggests annual screening in women aged 45 to 54, and biennial screening from 55 onwards or annual depending on the patient preference [94]. The ECIBC proposes biennial or triennial mammography in women aged 45 to 49, biennial between 50 and 69 (higher level of evidence on mortality reduction), and triennial for patients aged 70 to 74. The ECIBC establishes an upper age limit of 75 for breast screening [96]. However, the NCCN, ACS and ACR guidelines do not determine an age limit, but highlight that such decision should be assessed considering the comorbidities and life expectancy of each patient [7,94,96].

Clinical guidelines also recommend digital breast tomosynthesis (DBT) for BCS considering its risks and benefits. The NCCN suggests its use since it can decrease the rate of clinical recall and increase cancer detection. However, the guidelines warn of higher radiation

exposure and lack of evidence on mortality reduction. The ACS agrees with the benefits of DBT in accordance with current and general recommendations pointing out a possible higher cost of examination [94]. The ACR highlights its usefulness in women under 50 years of age with dense breasts, spiculated masses and asymmetries in mammograms [95]. Regardless, previous indications, the ECIBC recommends mammography over DBT alone or combined to mammography. The guidelines justify this decision, based on the increased human, time and economic resources involved in DBT as well as its limited evidence on mortality improvement [96].

4.2 Women with High Risk

The NCCN, ACS and ACR agree to incorporate magnetic resonance imaging (MRI) in addition to annual mammography at younger age, for the population with a high risk of developing the disease: 1) lifetime risk greater than 20% measured with risk assessment tools based on family history; 2) carriers of genetic mutation (BRCA1/2) or their unproven first-degree relatives; 3) non-BRCA mutations associated with hereditary breast cancer syndromes (Li-Fraumeni, Cowden, Bannayan-Riley-Ruvalcaba syndrome or first degree relatives with the syndrome); 4) history of mantle radiation for Hodgkin lymphoma between the ages of 10 and 30. There is absence of strong evidence in favor or against MRI screening in women with history of breast cancer, *in situ* lobular neoplasia, atypical ductal and lobular hyperplasia, or life risk of 15-20% [7,94–96].

Since the sensitivity of mammography is limited by high breast density, the NCCN, ACR and ECIBC suggest that manual/automated ultrasound or DBT increases breast cancer detection; however, ultrasound could result in a high false positive rate and unnecessary biopsies. Finally, MRI is not recommended for mammographically high dense breasts. [7,94–96]. Recommendations on breast screening will continue to change as new techniques are developed and current methods evolve. The goal is to provide an informed and personalized BCS with a balance between risks and benefits.

5. Established Methods of Screening and Diagnosis

Current methods of screening and detection in clinical practice include Breast Physical Examination (BPx), Mammography (including full-field digital mammography (FFDM) and DBT), Ultrasonography and MRI (**Fig. 5**). Positron Emission Tomography/Computed Tomography (PET/CT) is commonly used for diagnosis and staging. All these methods vary between one another regarding their utility, sensitivity and specificity.

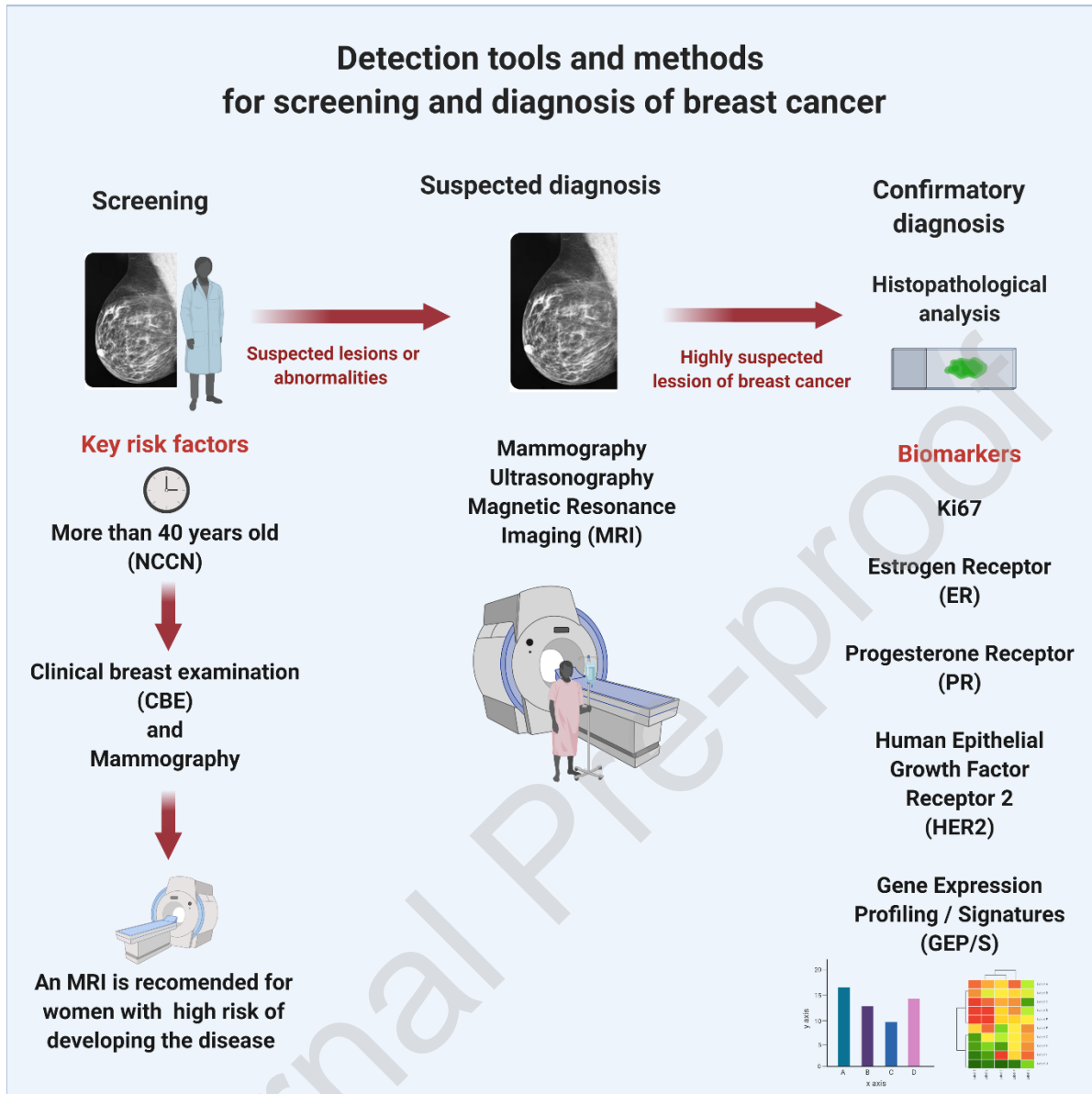


Figure 5. Detection tools and methods for screening and diagnosis of breast cancer. Screening should be performed with a tool that is appropriate according to each patient's breast cancer risk (e.g. The NCCN recommends annual mammography for average risk women of >40 of age). If a lesion is detected during screening, further examinations are required to evaluate such breast abnormality. Finally, if all studies suggest a high probability of cancer, it is suitable to confirm the diagnosis and assess the prognosis with biopsy analysis and biomarkers. Created with BioRender.com.

As mentioned before, mammography is recommended for BCS by the ACR, Society of Breast Imaging (SBI), ACS, U.S. Preventive Services Task Force (USPSTF), NCCN, European Society for Medical Oncology (ESMO), and others [6,7,94,97–100]. However, this imaging

technique is limited by dense breast tissue for which other methods such as Ultrasonography could be used in combination to provide a more accurate analysis [101]. In this section we explore the established methods of detection, representative studies with recommendations to be taken in consideration for their use.

5.1 Breast Physical Examination

BPx refers to the inspection and palpation of the breast, nipple and lymph-draining areas surrounding the armpit. This can be performed by a physician (CBE) or by the patient itself (BSE). BPx has low cost and no special equipment is required [102,103]. Abnormal physical features detected by CBE include breast and axillary lumps, thickening, redness, swelling, asymmetry of the breasts and nipple abnormalities such as ulceration and discharge [102,103]. CBE has a sensitivity of 40% to 69% and a specificity of 88% to 99%. For BSE, sensitivity ranges from 12% to 41% [104]. However, BSE can detect tumors of similar size to those found by CBE (SD: 22.1mm versus CBE: 21.9mm of diameter; $p=0.991$). Moreover, BSE usually detects tumors in younger women than CBE, since the median age of detection is 60 years and 67 years respectively ($p<0.001$). This is due to older women tend to omit their palpable lesions or do not attend screening consultation. Such situations could be prevented with more frequent CBE as an integral part of general care [105]. Nonetheless, it has been evidenced that BSE does not decrease breast cancer mortality [7].

5.2 Mammography

Mammography is the current gold standard method for BCS. This method aims to identify malignant tumors before they are noticed. A mammogram consists of an X-ray examination of the breast in the standard craniocaudal and mediolateral oblique views. The test can detect abnormal areas but cannot prove that it is cancer. If there is any suspicion of cancer, a biopsy of the breast tissue is recommended for histopathology analysis and molecular evaluation [9]. A major pitfall of conventional mammography is overdiagnosis, where benign tissue abnormalities or non-aggressive tumors can be misinterpreted, leading to unnecessary procedures and treatment [106]. In addition, the sensitivity of mammograms is influenced by age and the density of breast tissue [107,108]. Dense tissue layers limit detection of cancer tumors in mammograms which could lead to additional screening to confirm detection [109].

According to the Breast Cancer Surveillance Consortium (BCSC), conventional mammography has a sensitivity of 86.9% and a specificity of 88.9% [110]. A study conducted by Luczynska et al. showed a sensitivity of 90% and an accuracy of 62% [111]. Moreover, Helal et al. reported a sensitivity of 52.4%, a specificity of 50% and an accuracy of 51.4% [112]. However, alternative mammogram modalities such as FFDM and DBT could help to overcome conventional mammography issues, especially dense breast tissue.

5.2.1 Full-Field Digital Mammography

FFDM uses digital detectors to transform X-ray photons into electrical signals with the aid of analog-to-digital converters to create the digital image. FFDM allows easier access to images and post-processing manipulation to improve resolution and contrast through computer-aided detection (CAD) [113,114]. Physical performance and discomfort are similar to conventional mammography, however, digital mammography has a slighter lower radiation exposure [115]. A study conducted by Li et. al showed a sensitivity of 88.8%, a specificity of 75.2%, a positive predictive value of 62.1% and a negative predictive value of 93.6% corresponding to FFDM [116]. A multicenter trial that included 49,528 asymptomatic women, reported overall FFDM sensitivity of 70% and specificity of 92%. In addition, the study found a sensitivity of 78% for FFDM vs 51% for conventional mammography, in women younger than 50 years. Similarly, the sensitivity of FFDM in women with dense breast tissue was higher compared to conventional mammography (70% vs 55%) The specificity value did not vary between both mammography methods and among populations [117]. FFDM appears to benefit young women and women with heterogeneously or extremely dense breasts [7,117]. Since its approval in 2000, FFDM has largely replaced conventional film-screen mammography [113].

5.2.2 Digital Breast Tomosynthesis

DBT is an advanced mammography technique that uses a low dose X-ray system to make a 3D high-resolution reconstruction of the breast tissue using multiple images taken from thin sections (1mm). Fiona and colleagues reported that DBT has potential to increase detection rates and decrease recall rates [118,119]. However, the major pitfalls of this technique are the high cost of the test, uncomfortable procedure and use of radiation. The combination of 2D and 3D mammography results in a better screening for more invasive cancers [120–123]. A study conducted by Gennaro et al., which enrolled 200 women with a breast lesion previously identified by mammography and/or ultrasonography. The study showed no significant difference regarding overall performance of DBT compared to FFDM [124]. In 2012, Svahn and colleagues tested the ability of radiologists to identify anomalies in 185 patients using DBT. The study showed that the sensitivity of DBT compared to digital mammography were approximately 90% vs 79%, and no significant difference was found in the specificity between the two imaging techniques [125]. This technique is commonly used as an adjunct to mammography for breast cancer diagnosis since its approval by the US Food and Drug Administration (FDA) in 2011 [113] However, using both techniques could surpass the radiation limit in normal mammography allowed by the FDA. This situation could be avoided by using newer DBT techniques that produce synthetic 2D images using less radiation [7].

5.3 Ultrasonography

Ultrasonography is a diagnostic imaging technique that uses high-frequency sound waves to produce images of internal body structures, allowing the detection of anomalous tissues such as breast cancer [113]. An ultrasound can also be used to discern fluid-filled cysts and solid tumors. [107,126] Moreover this is the primary imaging modality for guiding interventional procedures such as core biopsy, cyst aspiration, preoperative needle localization and drainage [127–129]. Advantages of ultrasonography also include the absence of ionizing radiation and intravenous contrast. Nevertheless, ultrasonography has a low detection rate for calcifications, has a lower specificity compared to mammography and a highly trained technician is required to carry out the test [107].

Zanello and colleagues analyzed the diagnostic performance of ultrasonography in 241 patients with a previous mammography result of BI-RADS category 0. Ultrasonography was considered diagnostic when the BI-RADS changed to a category 2, 4 or 5 and indeterminate when results required a mammographic follow-up. The imaging technique was diagnostic in 60.6% patients and indeterminate in 39.4% patients. Additionally, ultrasonography had a sensitivity and specificity of 100% and 89.1% respectively, and an overall accuracy of 89.6% [130]. Studies have shown that ultrasonography can be useful as an adjunct to mammography to increase detection rates in women with dense breasts [131–133]. Currently, this technique is usually used in conjunction with mammography for a better diagnosis [107,134].

5.4 Magnetic Resonance Imaging

MRI uses strong magnetic fields and low-energy electromagnetic waves to produce detailed images or information about physiological processes of the body such as blood flow and nerve activity. Contrast Enhanced-MRI (CE-MRI) for breast cancer diagnosis relies on the neovascularity generated by tumors during growth and development. Intravenous administration of a gadolinium-containing contrast material is required in order to visualize lesions and malignant angiogenesis as it is carried by the bloodstream into the affected breast [135,136].

Breast MRI is a non-invasive tumor detection tool with a reliable sensitivity that does not use radiation. MRI has improved BCS in high-risk women [107,136]. If used as an adjunct to conventional imaging, MRI can detect breast cancers with an incremental sensitivity of 58% in high risk women compared to mammography alone. MRI in addition to conventional mammography has reported a sensitivity of 93 to 100% [137]. A prospective study conducted by Schelfout et al. described a greater capacity of CE-MRI at detecting ipsilateral and contralateral breast tumors in comparison to other imaging techniques. The study reported that CE-MRI was able to identify 96% of multifocal and 95% of multicentric breast tumors, while mammography detected 37% and 18%, and ultrasound found 41% and 9% accordingly [138]. The major

drawbacks are the high cost of MRI examinations and high rates of false positives. It is important to note that patients with specific psychological conditions (e.g. claustrophobia) cannot perform the test without being previously prepared for examination (e.g. sedation). Moreover, patients with implantable electronic devices (e.g. pacemakers) or tissue expanders (e.g. for breast reconstructions) are usually contraindicated for MRI testing [136,139].

5.5 Positron Emission Tomography/Computed Tomography

PET/CT refers to the technique which combines PET and X-ray CT scanners to obtain images that identify the anatomic location of anomalous metabolic activity within the body. PET provides information of cancer physiology at the molecular level using radiotracers (such as F-18 fluorodeoxyglucose or FDG, and other lesion-specific radiotracers), while CT produces pictures with the anatomic information [140–142]. FDG-PET uses glucose upregulated transport in cancer cells to visualize tumors, therefore the patients should fast for several hours before PET/CT to optimize the study [143].

The main benefit of the PET/CT procedure is its combination of functional and anatomical imaging, permitting clearer visualization of the lesions than conventional screening [142]. The NCCN 2020 guidelines do not suggest PET/CT scanning in patients with clinical stage I or II and operable stage III breast cancer. FDG-PET/CT is most helpful in situations where standard staging tests are equivocal or doubtful, especially in the setting of inflammatory breast cancer, regional nodal disease and/or whole body distant metastasis [6,141,144].

Wahl et al. enrolled 360 women with positive primary invasive breast cancer to determine the accuracy of FDG-PET in the detection of axillary nodal metastases. The sensitivity and specificity of the method were 61% and 80% respectively [145]. In another study, 47 FDG-PET/CT screens of women with a history of breast cancer were used to evaluate the sensitivity, specificity and accuracy of PET/CT versus CT. The results were 85% vs 70%; 76% vs 47% and 81% vs 59% respectively [146]. The main drawback of this technique is the radiation exposure to the patient and the operator, which cannot be mitigated [142].

As presented earlier, BCS is based on physical examination and imaging-based methods. Among the last ones, mammography is the primary screening tool, and has become the gold standard technique for BCS. Improvements in conventional mammography that led to the development of FFDM have provided a more accurate tumor detection in terms of sensitivity and specificity, especially in women with high dense breast tissue. Moreover, clinical practices could include an adjuvant imaging technique, such as DBT and ultrasonography to improve cancer detection. The remaining imaging methods covered previously target specific subpopulations. For example, MRI screening is suggested only for women with high risk of breast cancer, while PET/CT is commonly used for cancer monitoring, specially to determine nodal and distant

metastasis. Even though these are well established techniques, ongoing studies aim to enhance current screening practices. The process of BCS culminates when radiologists categorize imaging findings based on the BI-RADS lexicon scale to recommend further analysis for diagnosis (e.g. biopsy), if required.

6. Emerging Methods of Screening and Diagnosis

Besides current methods of BCS such as BPx, mammography, ultrasonography and MRI, new technologies have emerged fusing biophysics characteristics with clinical data [147]. For instance, tissue rigidity and other mechanical characteristics of the tumor during breast cancer progression may lead to novel diagnostic tools [147,148]. It has been suggested that changes in the rigidity and stiffness of the extracellular matrix persist for longer periods of time in cancer and may have less heterogeneity in the results in comparison to other methods such as GEP/S [147]. In addition, detecting breast temperature variations using thermograms could reveal abnormalities since temperature can be influenced by the increased metabolic activity of cancer cells in comparison to healthy breasts [79,149,150]. In this section we show how beyond improving hardware for the biophysical analysis of breast cancer and the use of new software tools for better analysis and interpretation of data is key for the future applicability of these tools. As new methods of diagnosis continue to emerge, it is important to evaluate their clinical validity before being recommended by clinical guidelines [7]. This section reviews relevant information regarding the application of these innovations including: Optical Imaging, Digital Infrared Thermography Imaging (DITI), Contrast-Enhanced Mammography (CEM), Scintimammography, emerging PET radiotracers, Magnetic Resonance Elastography (MRE), Acoustic Radiation Force Impulse Imaging (ARFI), Diffusion Weighted-MRI (DW-MRI) or DWI, Ductoscopy and Ductal Lavage, Radiomics and Internet of Things (IoT).

6.1 Optical Imaging

Optical Imaging is a detection method that uses light to identify anomalies inside body tissues. This technology uses the electromagnetic spectrum from ultraviolet to infrared waves of light to provide information regarding tissue structure, physiology, and biochemical processes [147,151]. This imaging modality can detect femto or even picomolar concentrations of an optical reporter or contrast element [152]. Optical images are contrasted with elements such as exogenous agents (e.g. dyes or probes), endogenous molecules (e.g. reduced nicotinamide adenine dinucleotide (NADH), hemoglobin or collagen), or reporter genes (e.g. Green Fluorescent Protein) [152,153]. This technology includes modalities such as Fluorescence Imaging, Bioluminescent Imaging, Optical Coherence Tomography (OCT), Photoacoustic Imaging, Diffuse Optical Tomography (DOT), Super-resolution Microscopy and Terahertz Tomography [152,154,155]. In addition, according to Grosenick et al., optical breast imagers can be classified in time-domain, frequency-domain, and continuous-wave systems taking into account the measurement geometry

and the temporal profile of the laser radiation employed [156]. Optical imaging has the potential to be noninvasive, nontoxic and cost-effective to quantify vascularization, permeability, hemoglobin, oxygen saturation (StO₂) and concentration in breast tumors. Studies have shown that vascularization and StO₂ of breast tumors are related to hypoxia, which is highly associated with malignant tumors due to their size [151,153].

Several clinical trials have been conducted to evaluate optical imaging modalities mentioned above in the detection and characterization of breast cancer, dynamic response to external impact, assessment of breast density and cancer risk estimation [156]. Nowadays, large clinical results comparing functional properties (Hydrogen Breast Test (HbT), Tissue blood StO₂, water, lipids and scatter power) from breast cancer lesions and healthy tissue are available. Grosenick et al. found that the average HbT and StO₂ of healthy tissue are 17.3 ± 6.2 and 74 ± 7 while in malignant lesions the average is 53 ± 32 and 72 ± 14 respectively [157]. In another study, Cerussi et al. determined that the average of HbT and StO₂ in healthy tissue are 17.5 ± 7.5 and 67.7 ± 9.3 while in malignant lesions they are 24.7 ± 9.8 and 67.5 ± 8.4 respectively [156,158,159].

Various optical imaging clinical studies have demonstrated that functional properties can improve breast cancer diagnosis [156]. In addition, other trials have been performed to evaluate dynamic changes of functional properties when external factors such as pressure are applied for the distinction among malignant lesions, benign lesions and healthy tissue [156]. Local pressure in tumors can cause an accelerated reduction of StO₂ compared to healthy tissue and benign lesions. Fournier et al. using dynamic optical mammography reported a statistical difference in the characterization of benign and malignant lesions. The study revealed a 74% and 92% of sensitivity and specificity respectively [160]. However, Xu et al. in a trial using a handheld probe with continuous waveform light sources reported that pressure appliances in 36 cases had no significant difference in the decrease of StO₂ [156,161]. The actual knowledge on functional and scattering properties is improving the future perspectives of optical imaging in breast cancer diagnosis [156].

Optical imaging research has a promising role in cancer detection. It represents an interesting tool to provide functional and molecular characteristics assessment in breast cancer [152,154]. However, methodological preparation and optical data can be time-consuming and difficult to interpret. The ACR establishes that further evidence is required to support the use of optical technology in BCS [162]. Currently, these modalities are in early phases of clinical trials [153]. Further studies regarding how it captures and interprets images to provide better detection of cancer are still needed [151,154].

6.2 Digital Infrared Thermography Imaging

DITI is a technique that detects the heat patterns of blood flow in body tissues. This technique is based on the principle that temperature increases in areas of the tumor due to

neovascularization, increased vasodilation and inflammation influenced by cancer cells [163]. The human body and its different constituents radiate infrared heat energy from the skin. These heat patterns can be detected by specialized cameras and interpreted by a software that generates temperature values. As a result, a thermograph is created with the temperature distribution of the breast. This technique is promising since it could enable a total exploration of the breast with the great advantage of being non-invasive and without radiation exposure [164].

Temperature distribution patterns are measured, recorded, and processed to pinpoint areas related to cancer development during preventive and diagnostic evaluations of the breast. However, since DITI provides a thermal image, it is unable to reveal specific anatomical borders in tissue abnormalities for biopsy analysis. Additionally, the measurement is carried out only on the surface, so deep tumor diagnosis is excluded for such detection[164]. Moreover, the image processing at some points is an extrapolation of the real measurements. In other words, one could easily assume errors and mistakes possibly leading to erroneous diagnosis. To overcome these limitations, an image processing technique has been introduced that enables the creation of a 3D picture of thermography. This technique is the implementation of the inverse problem[165], which is well documented by mathematics. In this technique, the collected values of the skin temperature are computed to deduce the temperature and the location of the source. This is done using heat equations[165] and the physical characteristics of the biological tissues such as the thermal conductivity[166].

A study carried by Kontos et al. determined the sensitivity and specificity of DITI in 63 symptomatic patients who had undergone surgical excision or core biopsy of breast lesions (benign and malignant). They found sensitivity and specificity values of 25% and 85% respectively [167]. A prospective clinical trial conducted by Arora et al. included 92 patients with biopsy referrals based on mammograms or ultrasound results to evaluate DITI performance. Results reported a sensitivity of 97% and specificity of 44%. Authors conclude that DITI could be valuable as an additional method to mammography and ultrasonography for breast cancer detection [168]. Several studies have shown that thermography could be used as a method for early diagnosis of the disease. Still, its effectiveness is questioned due to the large variation of results in terms of sensitivity and specificity. Currently, thermography has not been approved as a standalone method for breast cancer diagnosis [163,169,170].

6.3 Contrast-Enhanced Mammography

CEM is an imaging modality that uses X-rays, a dual-energy technique and a standard iodinated intravenous contrast agent to highlight breast abnormalities on the basis of neovascularization and morphologic assessment of breast lesions. After the intravenous administration of the contrast agent, paired low-energy and high-energy images of the breast are obtained. The low-energy image resembles an unenhanced conventional 2D mammogram,

whereas the high-energy image reveals areas of iodinated contrast uptake. Post-processing results in a recombined image showing areas of contrast enhancement with subtracted background breast tissue [171–173].

The main benefit of CEM is that both breasts can be imaged using a contrast agent in a noninvasive manner [172]. CEM was approved by the FDA in 2011 and originally conceived as an alternative method to CE-MRI when it was not available or limited [113]. Nonetheless, CE-MRI is still the technique of choice over CEM for BCS in high-risk patients [174]. CEM has been reported to have better sensitivity and specificity than conventional 2D imaging, and similar performance, lower cost, and shorter examination time than CE-MRI [172]. Creation of CEM-specific BI-RADS lexicon would improve sensitivity of the technique and provide a more accurate biopsy referral [174]. Mokhtar and Mahmoud assessed the diagnostic accuracy of CEM in 60 women with suspected anomalies detected by mammography and/or ultrasound. They found a sensitivity of 97.7% and a specificity of 50% for CEM and concluded that is more accurate than mammography alone and mammography plus ultrasound, when diagnosing anomalies in women with dense breasts [175]. Lobbes et al., found CEM sensitivity of 100% and specificity of 87.7% in a study that compared its diagnostic performance to conventional mammography. Additionally, they found that tumor localization and diameter measurements described by CEM are in accordance with MRI and histopathology analysis [176]. Since no new equipment is needed apart from an upgrade to conventional mammography units, there is not a significant extra cost for CEM. Something that needs to be considered before screening is that CEM increases radiation exposure by about 20-80% when compared to standard mammography. However, this higher radiation exposure still lies within the range of accepted radiation levels in patients. [172,177].

6.4 Scintimammography

Scintimammography is a nuclear medicine imaging test that uses radioactive isotopes such as Technetium-99m sestamibi ($^{99m}\text{Tc-MIBI}$) to investigate a breast anomaly previously detected by mammograms. The radioactive isotope accumulates in the breast and gives off a small amount of gamma rays which are detected by a specialized camera. The image resulting from this test, provides details in the structure and function of the breast allowing a better cancer detection and estimation of its aggressiveness. This technique could be used to assess cancer treatment response or when other imaging methods (e.g. mammography) are limited to interpretation or when MRI is not feasible [140,178,179]. In addition, scintimammography could be valuable for screening women with dense breast tissue and breast implants [178,180]. However, it exposes the patient to a considerably higher radiation dose than mammography. This high radiation risk contraindicates its use in pregnancy. A trained technologist is required to perform the test and in some cases the image resolution is not as clear as in other techniques such as mammography and ultrasonography. [7,178–180]. Since false positives and negatives results can occur, a negative scintimammography

should not stop diagnostic confirmation by biopsy after a suspicious mammography and/or ultrasonography [179].

A systematic review that included twenty-five studies with a total of 4,094 patients, evaluated the diagnostic performance of scintimammography vs mammography. The study established a sensitivity of 86.64% and a specificity of 83.42% for the nuclear medicine method compared to 75.82% and 59.58% respectively for standard mammography [181]. A systematic review and meta-analysis conducted by Guo and colleagues investigated the efficiency of MIBI scintimammography as a predictor of neoadjuvant CTX response in 503 patients with proven breast cancer. They found a pooled sensitivity of 86% and a pooled specificity of 69% [182]. More trials are required to validate the efficacy of this technique, since it is still considered as an emerging screening method for breast cancer in mammographically dense breasts [7,183].

6.5 Future Role of Positron Emission Tomography and New Tracers

Due to the PET's high sensitivity and spatial resolution compared to other imaging techniques, several new radiopharmaceuticals are in ongoing trials [184,185]. The tracers in late clinical phases are commonly small molecules or peptides labeled with short-live isotopes (^{18}F and ^{68}Ga), longer-lived isotopes (^{64}Cu , ^{89}Zr , ^{124}I , ^{52}Mn), monoclonal antibodies (mAbs) or nanoparticles. FDG PET/CT has limitations in the detection of mixed and low FDG uptake cancers, therefore, new agents that can easily detect specific receptor status or antigens in the disease are mostly developed as FDG replacement. Also, agents are being developed for disease characterization and to evaluate target treatment for patients ([185]).

Instead of FDG, other alternatives such as the analog of estradiol, the 16α - ^{18}F -fluoro- 17β -estradiol (FES) is used in combination with PET. This technique is non-invasive, reproducible and provides valuable information of the tumor stage. In addition, [^{18}F]-FES uptake is correlated with ER overexpression, such correlation can predict the patient's response to hormonal therapy (HT) [186]. [^{18}F]-FES PET as a diagnostic tool can differ from early stage tumors and metastases, this modality is usually used instead of biopsy or when it has undetermined results [186–188]). A study carried by van Kruchten et al. in 33 patients who underwent [^{18}F]-FES PET reported [^{18}F]-FES positive lesions in 22 patients, higher bone metastases lesions were detected by [^{18}F]-FES PET compared with other conventional imaging methods (341 vs 246 bone metastases lesions respectively), additionally, an 88% improvement in diagnosis and 48% of the patients reported a change in therapy [186,188]. Several studies performed with [^{18}F]-FES PET have shown a 84% and 98% sensitivity and specificity respectively [186].

Another modality is immuno-PET, which uses radiolabeled mAbs as markers. The mAbs have shown high specificity and selectivity in tumor targeting, antibodies such as anti-cytotoxic T-lymphocyte-associated protein 4 (anti-CTLA-4), anti-programmed cell death-1 ligand 1 (anti-

PD-L1), anti-programmed cell death protein 1 (anti-PD1) and GSK-1/30 are labeled with long-lived isotopes such as ^{89}Zr . Immuno-PET has shown fewer or no side effects, however further studies are needed [184,189]. An example of immuno-PET is the mAb GSK-1/30, which exclusively targets the human tumor-associated transmembrane glycoprotein Mucin 1 (TAMUC1), a protein expressed in over 90% of all breast cancer cases. In a study conducted by Stergiou et al., 10 sections of healthy human breast tissue and 144 sections of HT+ breast cancer tissue were stained by mAb GSK-1/30. Results reported that 96.5% of breast cancer tissue sections stained by the radiolabeled mAb were positive and 3.5% were negative, while 100% of the stained healthy tissue was negative. The authors described this tracer as a promising agent with potential use as a diagnostic tool, prognostic biomarker, and a companion diagnostic test [189].

In oncology, PET and PET/CT have shown promising results to provide an accurate assessment in breast cancer patients. FDG PET/CT technique is widely used in clinical imaging and remains as tracer by excellence due to its wide applicability [185]. Nevertheless, new tracers and PET imaging tools are emerging in order to achieve a better diagnosis, earlier detection and personalized assessment in therapy selection [187].

6.6 Magnetic Resonance Elastography

MRE is a dynamic elasticity imaging technique useful to obtain a visual map of the body. MRE uses a combination of MRI and mechanical shear waves to obtain information about the stiffness of tissues. The process involves three steps: first, shear waves are induced in the tissue, then, the propagating waves are imaged with MRI and finally, waved data is processed to generate a stiffness map (elastogram) [190]. None of the conventional methods of detection (e.g. mammography, ultrasound, MRI, CT, PET) can measure mechanical properties of tissues except for physical palpation, which is commonly used by physicians to detect masses near to the breast surface. However, not all tumors are superficial, as breast cancer lesions can be hidden in dense breast tissue where palpation or established imaging methods cannot detect. Several studies have shown that malignant tumors are stiffer than benign, thus, MRE can provide a truthful shear modulus or modulus of rigidity of tumors to provide a better diagnosis [190–194].

MRE has been tested as a complement to contrast-enhanced MRI, which has very high sensitivity but low specificity for breast tumor detection [192]. Sinkus et al. investigated viscoelastic tissue properties in 68 patients using CE-MRI and MRE. They found that CE-MRI alone showed a sensitivity and specificity of 100% and 40% respectively, whereas combining CE-MRI and MRE techniques reported an improved specificity from 40% to 60%, retaining a sensitivity of 100% [195]. Another study conducted by Siegmann and colleagues combined CE-MRI and MRE to evaluate breast tumor identification in 57 patients. They found an improved specificity from 75% to 90% when α_0 (expression of the hardness of the tissue) from MRE was combined to CE-MRI, maintaining a sensitivity of 90% [196]. Thus, studies have shown that MRE

may improve diagnosis of breast lesions, specially by enhancing the performance of CE-MRI specificity which may lead to the reduction of false positives and unnecessary biopsies. However, further research is required to validate previous results and decrease patient discomfort during examination [197].

6.7 Acoustic Radiation Force Impulse Imaging

ARFI is a new acoustic imaging modality based on ultrasound elastography. This technique uses a short-duration, focused, high intensity ultrasound to provide information about the mechanical properties of tissue by generating radiation force (the interaction of an acoustic wave with an object) and using ultrasonic correlation-based methods [121,198]. This new ultrasound-based elastography is a promising tool which provides quantitative and semiquantitative measurements of the strain of hardness of a tissue lesion [199]. Several studies have shown that malignant tumors are usually stiffer than benign masses and the transmission of shear waves differ in both cases [121,199]. Jayaraman et al., revealed that velocity of shear waves of 34 benign lesions (2.08 m/s) were lower than that of 16 cancer specimens (6.28 m/s) [199]. A retrospective study evaluated the diagnostic performance of ARFI with virtual touch tissue imaging and quantification in 83 patients with benign and malignant breast lesions. Results showed a sensitivity and a specificity of 82.4% and 80.4% respectively [200]. ARFI may be used as an adjuvant diagnostic tool to conventional imaging to differentiate malignant breast tumors from benign ones without extra radiation or invasive methods [199,201,202].

6.8 Diffusion-Weighted Magnetic Resonance Imaging

DW-MRI or DWI is a technique that generates images of water diffusion in the tissue to visualize the internal structure and its properties. The study of diffusion patterns is useful to identify and contrast healthy tissue from abnormal lesions [203]. In oncology, a DWI image is a useful diagnostic tool to improve detection and biological characterization of breast tumors. In addition, DW-MRI images can characterize benign from malignant lesions according to the apparent diffusion coefficient (ADC) which is lower in malignant tumors [203,204]. The application of DWI-MRI as an adjuvant technique to CE-MRI may also reduce false positive results. Thus, DW-MRI could be valuable to inform the malignancy likelihood of a lesion detected by conventional imaging techniques in order to prevent unnecessary biopsies [204].

Bickel et al. assessed retrospectively the ADC obtained from DW-MRI in 170 primary malignant breast tumors. The objective was to evaluate DW-MRI as a tool to discern invasive breast cancer from ductal carcinoma *in situ* (DCIS). They reported a sensitivity and specificity of 78.06% and 90.5% respectively, therefore this technique showed potential as an indicator for breast cancer invasiveness [205]. Additionally, ADC has become a marker of interest to evaluate neoadjuvant treatment response, since its values can be influenced by tumor cells and necrosis,

and can be monitored before lesion progression [206]. A retrospective study evaluated the predictive value of ADC in neoadjuvant CTX response in 118 women with locally advanced breast cancer. Results showed that ADC obtained before treatment can predict the response of breast cancer to neoadjuvant CTX if tumor subtypes are considered [207]. However, further studies are required to validate ADC as a predictive marker to assess therapeutic efficacy [204].

6.9 Ductoscopy and Ductal Lavage

Fiberoptic ductoscopy (FDS) is a type of breast ductoscopy which permits direct visualization of the ductal epithelium of mammary glands through the nipple orifice cannulation. To perform this technique, the duct orifices are dilated with a suitable probe such as Bowmann's lacrimal dilator to insert the sub-millimetre fiberoptic micro endoscope. Injecting a saline solution improves visibility and eases passage of the endoscope through the intraductal space [208,209]. Mammary ductoscopy is commonly practiced in women with spontaneous nipple discharge (SND), which can be produced by malignant or benign ductal lesions [210,211]. Liu et al evaluated the ability of the FDS technique in combination with cytological tests to diagnose SND in 1,048 women. They reported a sensitivity 94.2% for FDS versus 98.1% for FDS + cytology testing [212]. A study led by Zielinski et al. assessed the diagnostic value of FDS in 164 patients with intraductal proliferative lesions. Results showed sensitivity and specificity of 68.1%, 77.3% respectively [208]. This evolving technology still requires further research to establish a consensus criteria for diagnosis and the association of its findings with malignancy [211].

On the other hand, ductal lavage is a procedure which collects atypical epithelial cells from the milk ducts for cytologic analysis. This technique is commonly used to detect precancerous and cancerous cells in women with a high risk to develop breast cancer. A microcatheter is introduced in the ductal orifices after nipple aspiration and all the ducts are cannulated with a fluid (commonly 1-3ml of 1% lidocaine). Then the ductal system is infused with normal saline and the breast is compressed to collect ductal fluid with cellular material to analyze [213,214]. Matos Do Canto et al., studied the metabolomic profile of breast ductal fluids collected by ductal lavage from 43 women with confirmed unilateral breast cancer. The metabolic analysis showed a sensitivity of 90.7% and specificity of 88.4% for breast cancer detection [215]. The routine use of ductal lavage is still not recommended for BCS due to missing support from actual evidence [7]. Even though these techniques can provide additional diagnostic information, their limitations regarding the sensitivity and specificity are currently analyzed since they could vary depending on the classification scale and cut-off applied [216].

6.10 Radiomics

In the past two decades, the field of medical image analysis has grown exponentially due to the significant technological advancements in pattern recognition tools and high-throughput

computing which led to the development of radiomics [217]. Radiomics involves the extraction of hidden quantitative features from a single or multiple digital medical images which could be applied in cancer detection, diagnosis and prognosis [218–220]. In breast cancer, these features are related to morphological aspects of lesions (tumor size, shape, intensity and texture) and functional characteristics of tumors (blood flow and cell metabolism) [219,221]. Thus, radiomics data could provide information about the underlying physiological and molecular mechanisms which are reflected by the genotypic and phenotypic characteristics of the cancerous tissue [218,221].

Radiomics analysis is a complex process that begins with the acquisition of high-quality images from the different imaging methods available. The process continues with the selection of a region of interest (ROI) which is segmented either manually or automatically (i.e., delineate the borders of the ROI that will be targeted for image analysis). Then, the selected region is converted into three dimensions to form volumes for the feature extraction step. In this imaging processing phase, candidate high-dimensional imaging parameters are extracted for classification and analysis. Finally, the data is analyzed and organized to develop models to predict outcomes in combination with clinical information, histology data and genomic profiles [217,219,221,222]. In breast cancer, radiomics has mostly been used in combination with MRI. However, recent studies have explored its potential use with other imaging techniques such as mammography, DBT and ultrasonography [221].

Radiomics has shown potential to serve not only as an emerging method of breast cancer detection but also as a tool for tumor characterization, prediction of tumor behavior, treatment response and recurrence which contributes to personalized monitoring, management and treatment. For example, a radiomics approach on ultrasonography imaging was proposed by Zhang et al. in 2017 to classify benign and malignant breast tumors. This consisted of the extraction of high-throughput features from sonoelastograms which quantified the shape, hardness and hardness heterogeneity of tumors for further analysis and clustering. This approach showed a sensitivity of 85.7% and a specificity of 89.3% [223]. Additionally, a retrospective study explored the ability of radiomics to predict cancer risk recurrence using MRI and multigene assays. This study enrolled 84 patients diagnosed with invasive ductal and lobular tumors. Tumor size, shape, margin morphologic appearance, enhancement texture, kinetic curve assessment, and enhancement-variance kinetics were the parameters extracted from MRI sequences. These MRI imaging features were then correlated with the risk of recurrence scores, estimated by the multigene assays MammaPrint[®], Oncotype DX[®], and PAM-50[®] (currently known as Prosigna[®]). The analysis showed promising results, combining the evaluation of both phenotypic and genomic data used to assess the risk of cancer recurrence [224]. Therefore, the integration of imaging, radiomics and GEP/S could provide a more accurate diagnosis and prognosis for personalized cancer management and treatment decisions. However, the use of radiomics by itself and its correlation with GEP/S or other prognostic tools needs to be further studied.

6.11 Internet of Things and Machine Learning Based Diagnosis Tool

Recently, electronic systems opened new perspectives on ergonomic and human-machine interfaces with the introduction of embedded technologies allowing applications such as Internet of Things (IoT) and more specifically connected sensor nodes [225]. The ongoing automation of processes uses modern smart technology, development of wearable medical devices with IoT and novel human-machine interfaces thanks to the recent possibilities offered by on-chip sensor devices or System-on-Chip (SoC) [226]. Furthermore, AI allows new approaches to understand multi-parameter systems processing different sources of biological data as input. Such a system could improve the diagnosis of breast cancer by implementing a continuous monitoring of specific parameters (e.g. temperature, glucose rate, stiffness, etc.) of the biological tissues involved in this illness.

As it is explained in the subsections throughout this review, different diagnostic methods rely on punctual measurements of biological parameters. However, to reduce the uncertainties coming from sparse measurement, improved monitoring methods should involve continuous data analysis over an extended period of time. This would generate a large amount of information (Big Data) that should considerably increase the patient history and lead to a more accurate medical evaluation. Indeed, AI concepts applied to Big Data have recently enabled the development of electronic systems able to interpret the data and to make decisions based on these interpretations, also called ML [227]. Additionally, this would build a contextualized history of the patient diagnosis. For example, and as already explained earlier, the temperature distribution inside the breast could change during the circadian clock or in response to TME selective pressure through metabolic adaptations [228]. Engineers could combine this physiological information with (non-invasive) wearable sensors and embedded electronics to detect the temperature pattern as a function of time. Such systems need to be on the patient's body (or at least in their clothes) and must be communication enabled (e.g. wireless communications) to transmit data to a cloud using concepts of connected objects like IoT. For safety reasons the cloud could send the data to ML based electronic systems for analysis after which, the conclusions will be sent to medical professionals [225]. To do so, it is important to consider different sensors that can be embedded into underwear like bras and electronic devices that are able to receive, send and store data. Eventually, these wearable systems could preprocess data and clinical history from breast cancer patients (e.g. age, weight, height, antecedents etc.) prior to sending them to the cloud after which more complex statistical analysis such as ML is employed [229].

At this time, the combination of ML and embedded systems for breast cancer detection needs to be further investigated. For the hardware, two key questions need to be answered considering different settings, such as thermal sensing. First, which type of temperature sensor provides the best compromise between accuracy, precision and ease-of-use? Possible options

include InfraRed (IR) [230,231], Millimeter-wave/THz [232,233] and flexible electronics [234]. Second, which electronic architecture of the embedded system for preprocessing and communication is the best suited? This discussion opens an interesting perspective to create a complete modern system for breast cancer diagnosis, incorporating the measurement of different biomarkers to achieve multiparameter sensing.

The established and emerging methods for detection and diagnosis of breast cancer are constantly improving. Established methods are being combined to provide a more accurate result and allow personalized treatments. The emerging methods are adapting new, wearable and connected technologies to analyze and store data, reducing the time of processing, delivery of results and the costs of medical devices. The interaction between patients, researchers and physicians is of great importance as the emerging technologies will need multidisciplinary communication and technical expertise to understand the biological complexity of breast cancer, and to meet patients' needs during breast cancer detection (**Fig. 3**). Women could be more willing to perform non-invasive methods such as optical imaging, DITI, ARFI, DW-MRI or DWI if they are comfortable and affordable. New ways of interpreting imaging data with emerging techniques such as Radiomics, as well as improving processing and delivery of results, will gain interest and applicability in the upcoming years.

7. Biopsy

After the detection of an anomaly in breast tissue by imaging techniques, biopsies are required to provide an accurate diagnosis. A biopsy is an invasive procedure where abnormal breast fluid or tissue is removed for cytological, histological and molecular analyzes. The test is recommended only in suspected cases of cancer based on the BI-RADS lexicon scale used by radiologists [235]. Tumor biopsy is still the gold standard technique that confirms if a tumor is benign or malignant [236]. There are three types of biopsies: 1) fine needle aspiration which is chosen to assess the liquid characteristics from cysts or abscess, 2) core needle biopsy which removes a small amount of the suspicious tissue, and 3) excisional biopsy that removes most or all of the abnormal tissue in conjunction with some healthy tissue [7,237]. Fine needle aspiration involves a small needle but does not provide information regarding the architecture of the tumor and requires experienced cytologists. Core needle biopsy requires a bigger needle equipment compared to the first one but is analyzed by standard histopathology which gives information about tissue structure and morphology. Excisional biopsy is also evaluated by standard histopathology but includes a surgical procedure for the excision of a bigger tumor sample [237]. In the past, performing excisional biopsy of breast lesions was commonly guided only by palpation. Nowadays, image-guided biopsy is preferred to sample the tissue as it showed better precision and accounts for cancer cases with nonpalpable tumors [238]. Biopsies are commonly guided by mammography, ultrasound and MRI which can also allow optimal preoperative workup. The core needle biopsy is preferred for evaluation of primary breast lesions while the fine needle aspiration

and sentinel lymph-node (LN) biopsy are useful for LN evaluation [113,183,239,240]. A correlation of imaging and pathology findings is imperative to provide an accurate diagnosis. Biopsies can also be analyzed by GEP/S where gene expression aberrations can be detected to determine the type of treatment recommended by physicians [241,242].

8. Staging and Grading of Breast Tumors

Anatomical staging and grading methods are used to determine tumor characteristics such as size, growth rate and spread. They are usually performed after diagnosis by established imaging methods and biopsies to select the most appropriate treatment (**Fig. 5**). Grading refers to the appearance of cancer cells compared to healthy cells and how quickly they may grow and spread. Breast tumors can be low-grade (uniform like appearance and slow-growing cells), intermediate-grade (bigger cells with variable shape and faster growth than normal cells) and high-grade (faster-growing cells with different sizes and shapes compared to healthy cells). Aggressiveness is associated with a higher grade breast cancer.

The American Joint Committee on Cancer (AJCC)'s Cancer Staging Manual uses the Tumor, Node and Metastasis (TNM) system to describe tumor size, involvement of LN and spread to other tissues. Stage 0 stands for a DCIS or Paget disease without nodal involvement or distant metastasis. Stage 1 is divided into A and B. IA involves tumors that are ≤ 20 mm in size, but IB represents from no evidence of the primary tumor to a tumor size of ≤ 20 mm. But independent of the tumor size, a nodal involvement (also called micrometastasis) of 0.2-2mm (or 200 cells). Stage II is also divided into A and B, the first of which comprehends tumors of ≤ 20 mm (or without evidence of primary tumor) with ipsilateral level I or II axillary nodes, in addition to 20-50mm tumors without LN compromise. IIB are tumors that measure 20-50mm with I or II level axillary LN, or tumors with a size greater than 50mm without LN metastases [243].

Stage III is subdivided into three groups A, B and C. The IIIA group is mainly assigned to tumors with ipsilateral axillary nodes level I or II physically fixed or matted in the tissue at the examination, or tumors with ipsilateral internal mammary nodes. The IIIA group contains a range of tumor sizes, from no evidence of primary tumor up to tumor size greater than 50mm. IIIB are tumors of any size with direct extension to the chest wall or skin invasion by malignant cells. The group can or cannot have the same IIIA LN type of involvement to be included. On the contrary, IIIC are tumors of any size that satisfy one of the following criteria regarding LN: ≥ 10 nodes involvement; or infraclavicular level III; or ipsilateral internal mammary plus I or II axillary; or three axillary nodes plus micro or macro metastases by sentinel LN biopsy (in negative internal mammary nodes); or supraclavicular ipsilateral nodes. At last, Stage IV can have any kind of tumor size and LN entanglement but is the only group on which there must be evidence of proven metastasis by any means necessary (e.g. imaging). Even though anatomical staging is a crucial step for cancer diagnosis, it cannot provide an accurate prognosis. Nowadays, anatomical staging

is combined with prognostic staging which comprises tumor grading, receptor status and genomic testing for a more complete diagnosis, prognosis and cancer management (**Refer to Genetic Signatures & Clinical Guidelines Recommendations: Towards the Prognostic Staging** for an example of the current integrated staging system) [243].

9. Breast Cancer Classification

Breast cancer can be classified according to the area and cell types that are originally affected. Based on these criteria, the two main categories are carcinomas and sarcomas.

9.1 Carcinomas

Carcinomas are malignant tumors that originate in the epithelial tissue, compromising the cells that compose the lobules and breast milk ducts. Hence, they can be divided into ductal and lobular carcinomas. In addition, depending on the invasiveness of the cancer, carcinomas can be further classified as *in situ*, invasive and metastatic [41].

9.1.1 Ductal Carcinoma

Ductal carcinoma is a type of cancer that begins with the proliferation of malignant epithelial cells in the lining of breast milk ducts which are connected to the nipples (**Fig. 6**) [244].

9.1.1.1 Ductal Carcinoma *In Situ*

DCIS can be defined as the proliferation of ductal epithelial cells with morphological features of malignancy without invading further than the basement membrane (**Fig. 6**) [245]. The development of carcinomas is complex due to their multifactorial nature and the lack of precise risk information [244]. DCIS can measure from 1mm to ≤ 25 mm in size, depending on their tumor grade [246]. In most cases, they are presented as non-palpable lesions which can be detected by mammography [247,248]. It has been observed that 30 to 50% of DCIS can progress to invasive cancer [249].

9.1.1.2 Invasive Ductal Carcinoma

Invasive ductal carcinoma (IDC) is the most common breast cancer type. Malignant epithelial cells in the lining of the breast milk ducts grow and surpass the basal membrane into the surrounding breast tissue and in late-stage cases they can migrate to other body tissues. IDC symptoms such as swelling, nipple discharge, lumps and pain are related to this stage of the tumor (**Fig. 6**) [41,250].

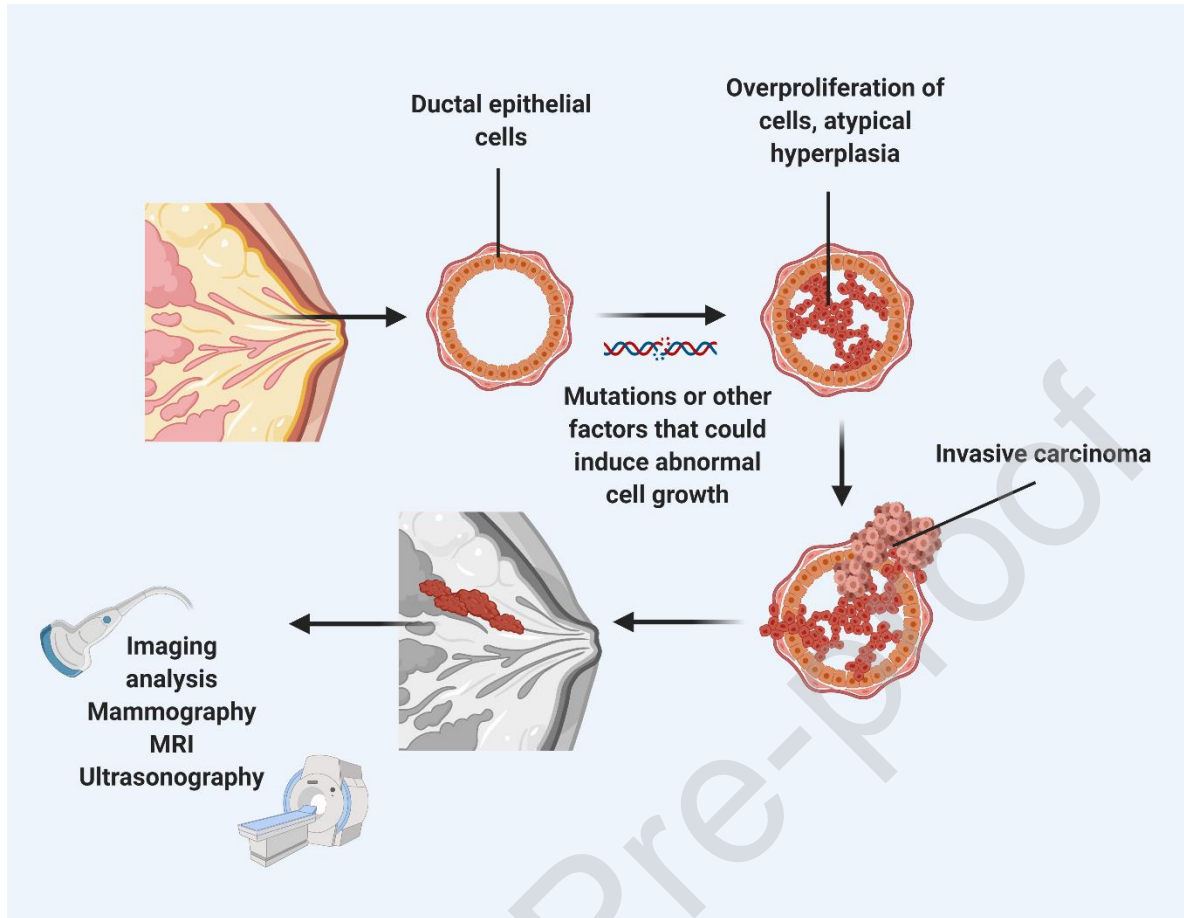


Figure 6. Development of ductal carcinoma *in situ* to invasive ductal carcinoma. Mutations in ductal epithelial cells can cause dysregulations in their growth and proliferation, leading to atypical hyperplasia. These cells can gain a different phenotype becoming malignant within the ductal walls. In turn, this lesion can infiltrate the surrounding tissue crossing the basal membrane, and thus progress to invasive cancer. Ductal carcinomas usually can be detected by imaging techniques such as mammography, MRI, and ultrasonography. Created with BioRender.com.

9.1.2 Lobular Carcinoma

Lobular carcinoma is a type of lesion that affects the lobules of the breast. They usually develop as non-cohesive dispersed cells or organized in single files with a linear pattern (**Fig. 7**) [41].

9.1.2.1 Lobular Carcinoma *In Situ*

Lobular carcinoma *in situ* (LCIS), also called lobular neoplasia, is a breast lesion associated with abnormal cell growth in the lobules. The AJCC eight edition no longer considers LCIS as breast cancer and is considered as a benign lesion [243,251].

9.1.2.2 Invasive Lobular Carcinoma

Invasive lobular carcinoma (ILC) refers to the spread of the tumor beyond the lobule to other parts of the breast tissue (**Fig. 7**). Depending on the cancer stage, it can further spread to other parts of the body. ILC is the second most common type of breast cancer comprising up to 15% of all cases. ILC can develop at any age but tends to affect women in the early 60s [41]. Even though ILC tumors have a good prognostic phenotype, cancer detection and long-term control of patients are still challenging. ILC tumors can be difficult to diagnose through current methods due to its growth pattern, which allows its infiltration in a diffuse manner, hiding its actual size [252,253]. Additionally the ILC has a more frequent multicentric, multifocal and bilateral presentation than IDC [253,254].

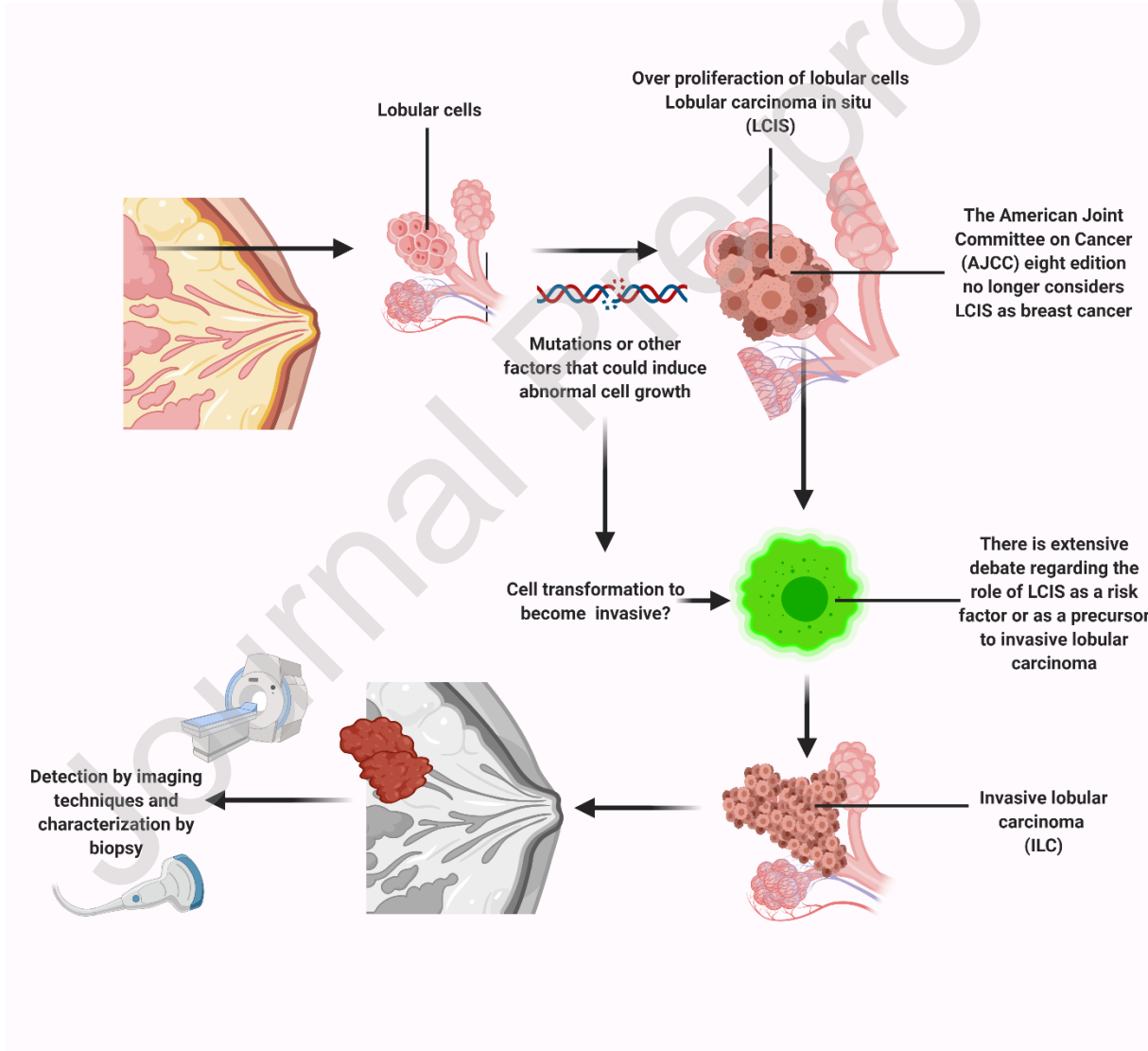


Figure 7. Development of lobular carcinoma *in situ*, a possible origin to invasive lobular carcinoma. LCIS is a breast lesion that is confined to the lobule limits and whose origin could be linked to mutations or other factors inducing abnormal cell growth. However, LCIS is not considered as breast cancer. The role of LCIS as a direct precursor of ILC is controversial since not all LCIS develop further into invasive cancer. ILC is characterized by the spread of cancerous cells beyond the lobules reaching distant breast tissue. ILC diagnosis may be challenging, usually requiring the combination of imaging techniques, biopsy, and molecular analyses. Created with BioRender.com.

9.1.3 Metastatic Carcinomas

Metastatic breast cancer, also called advanced breast cancer or stage IV, refers to the state in which tumor cells have spread beyond the boundaries of their location of origin, invading other organs (**Fig. 8**). Breast secondary tumors or metastases are commonly found in distant organs such as the bones, lungs, liver and brain [41]. It is estimated that about 30% of the women diagnosed with breast cancer at an early stage progress to recurrent or metastatic stages [255]. After cancer treatment, including mastectomy, recurrence is common due to microscopic tumor cells that may remain after surgery and metastasize again [41,250]. A study by [256]. that evaluated local recurrence of breast cancer after mastectomy showed a 6% of local cancer reappearance. Additionally, no correlation was found between age, tumor size and grade or LN involvement [256]. The risk factors affecting breast cancer relapse are poorly understood as it varies depending on the tumor stage and its specific molecular and genetic markers [41,250].

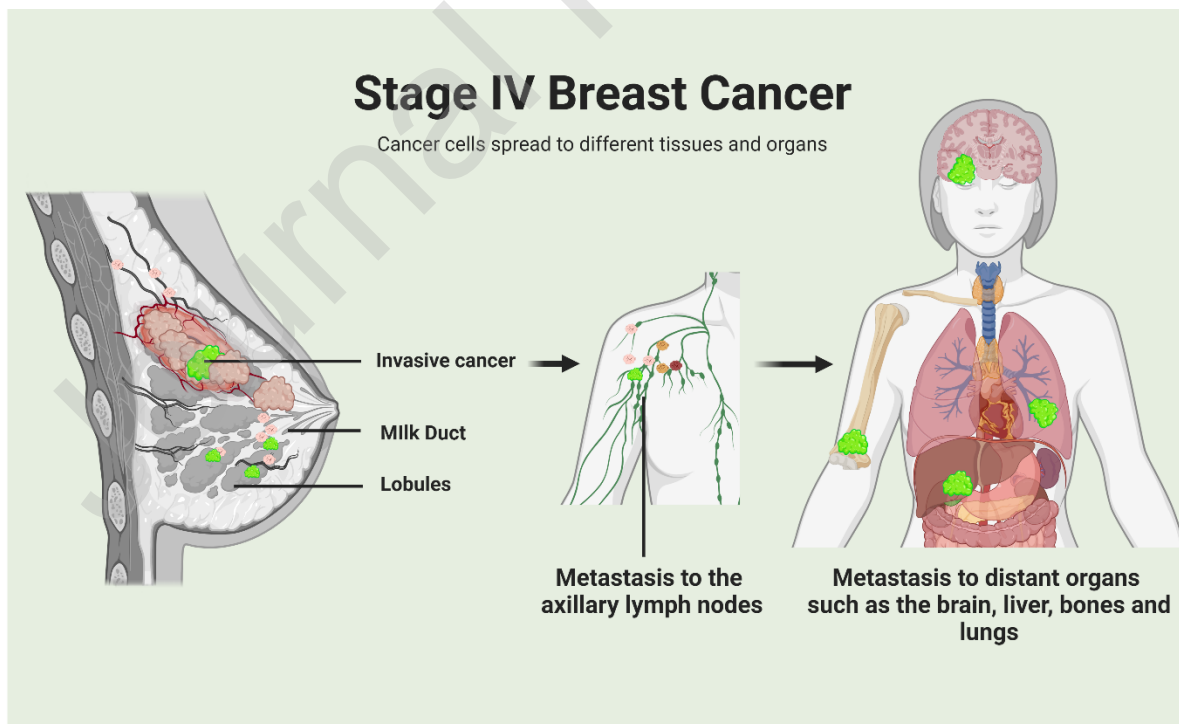


Figure 8. Metastatic breast cancer or stage IV. This stage of cancer progression is characterized by cell heterogeneity and the spread of malignant cells beyond the limits of its original location. At this stage, cancer cells metastasize to axillary lymph nodes and distant organs such as the brain, liver, bones, and lungs. Created with BioRender.com.

9.2 Sarcomas

Sarcomas are less common, constituting about 1% of malignant breast cancers. Sarcomas arise from the stromal tissue of the breast which consists of myofibroblasts, connective tissue and blood vessels. They can be divided into primary sarcomas which have *de novo* development or secondary sarcomas which are related to therapy radiation or chronic lymphedema [257]. Affected patients are usually women in their 50s or 60s with a painless mobile unilateral lump of variable size characterized by a faster growth rate, high risk of recurrence and worse prognosis compared to breast carcinomas [258]. Typically, the dissemination of the sarcoma does not involve LN, instead, it spreads through the blood to the bone marrow, lungs and liver. As breast sarcomas are rare and heterogenous, there is not a conclusive treatment strategy. However, current treatment guidelines include surgical excision as the first option, and CTX/radiotherapy for patients with a high risk of relapse [257].

10. Breast Cancer Biomarkers

Breast cancers are phenotypically diverse among patients in terms of growth rate, aggressiveness, hormone dependence and therapy response. Molecular biomarkers have been identified in an attempt to characterize such heterogeneity and define molecular subtypes for a better prognosis and cancer management [41,91,259,260]. The current established molecular biomarkers are those related to cell proliferation (Ki67) and receptor status: estrogen/estradiol receptor (ER), progesterone receptor (PR) and human epidermal growth factor receptor 2 (HER2) [41,261]. Estrogen-related receptors (ERRs) and extracellular elements such as microRNAs (miRNAs), exosomes (EXOs) and circulating tumor DNA (ctDNA) are emerging molecular biosignatures currently under research [261]. Genetic biomarkers for breast cancer include gene variants identified in genetic testing by sequencing, and GEP/S performed by multi-gene prognostic assays [262,263]. The use of suitable biomarkers for diagnosis could provide insights into breast cancer pathogenesis and contribute to personalized cancer management and therapeutic approaches (**Fig. 5 & 9**).

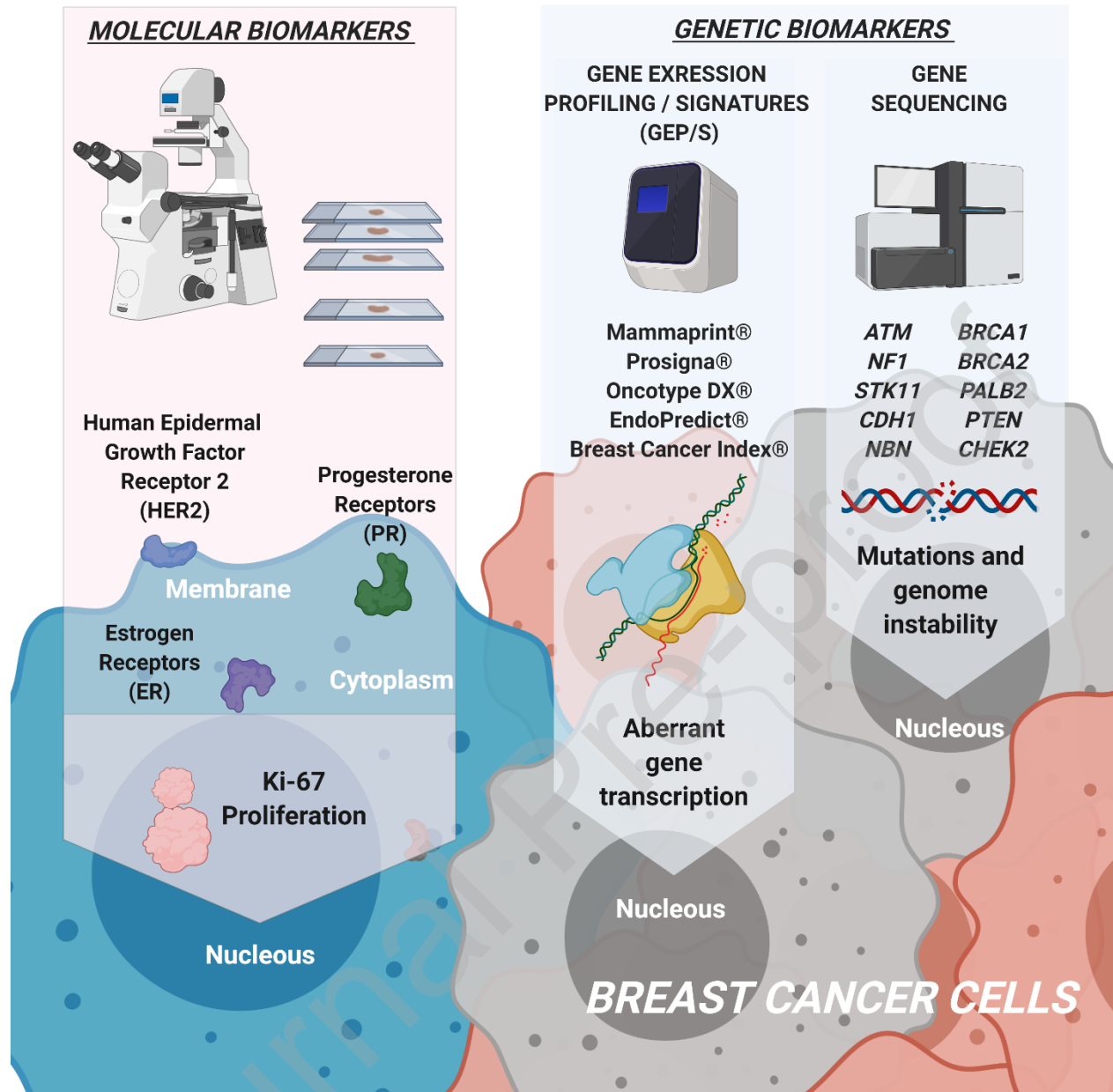


Figure 9. Molecular and genetic biomarkers, localization and tools of analysis. After detecting breast cancer, molecular and genetic biomarkers help the physician to choose the best therapeutic strategy. Molecular biomarkers are identified by IHC, from the cell membrane (HER2), the cytoplasm (PR and ER), and nucleus (Ki-67). These biomarkers provide information regarding hormone response and proliferative state of the tumor cells. Genetic biomarkers are key to characterize mutations that could increase the possibility to detect aggressive breast cancer. Gene expression profiles/signatures help to understand how a cancer behaves, allowing a better prediction of its future aggressiveness and response to therapy. Created with BioRender.com.

10.1 Established Molecular Biomarkers

10.1.1 Ki67

Ki67 is a nuclear protein that has been associated with cell proliferation in breast cancer pathogenesis. It is known that Ki67 is expressed during the cell cycle, from late G1, during G2 and S phase, and peaking at mitosis. However, Ki67 is missing in resting cells (G0) [264]. Studies have shown that high Ki67 levels are associated with a higher incidence of metastasis and recurrence in breast cancer, concluding that this protein could be considered as an important prognostic marker of tumor proliferation in breast cancer [83,264,265]. A study conducted by Soliman and Yussif, evaluated the prognostic value of Ki67 in breast cancer. Results showed that patients with less than 15% of Ki67 levels had better overall survival than those with higher Ki67 levels. Additionally, individuals with Ki67 levels higher than 15% displayed higher incidence of metastasis and recurrence. Finally authors conclude that Ki67 could be considered a valuable prognostic biomarker of breast cancer according to receptor status (e.g. molecular subtypes) [265]. However, the immunohistochemical profile of Ki67 and its implication in tumor aggressiveness could vary among populations with different ethnic backgrounds [266]. Hence, breast cancer biochemical markers should be interpreted with caution in terms of cancer heterogeneity by race and ethnicity.

10.1.2 Estrogen Receptor

The hormone estrogen/estradiol and its receptor (ER) are involved in breast cancer initiation and progression. It has been reported that some types of breast cancer initiate as estrogen dependent, therefore expressing ER, especially in the epithelial tissue [91]. Upon estrogen/estradiol binding, the ligand-activated receptor is translocated to the nucleus where it binds to a responsive element in the promoter region of genes related to tumor progression and metastasis [83]. Among ER subtypes, ER α has shown interaction with EMT regulators such as Snail and Slug which results in tumor invasion. ER α is thought to regulate Snail transcription by making a co-repressor complex along with histone deacetylase 1 (HDA1) and nuclear receptor co-repressor (N-CoR) [267]. ER β is associated with tumor proliferation and metastasis. Its upregulation has anti-proliferative effects and decreased expression seems to induce a metastatic stage in breast cancer [83,268]. ER+ tumors comprise approximately 75% of breast cancer patients. In general, ER+ tumors are less aggressive and are associated with better clinical outcome after surgery when compared with ER- tumors. About 50% of ER+ patients have a positive treatment response to HT with anti-estrogen or aromatase inhibitors. Even though ER status is the most prevalent breast cancer biomarker, others such as PR and HER2 have also been considered for breast tumor subtyping and cancer management [91].

10.1.3 Progesterone Receptor

PR is a member of the nuclear HR family which is activated by the steroid hormone progesterone [269]. In breast cancer, progesterone-PR interaction can lead to the transcription of genes associated with cancer pathogenesis. Therefore, PR is a HR biomarker used in cancer subtype diagnosis [269,270]. PR+ tumors comprise 65% to 75% of breast cancers [91]. Since PR expression is regulated by estrogen signaling, more than 50% of PR+ breast tumors are also ER+ [269,270]. However, some cases have been reported in which breast tumors resulted PR+ but not ER- [271]. In addition, some studies found that ER+PR+ breast tumors are more susceptible to HT as compared to ER+PR- tumors [272]. Absence of PR expression in ER+ tumors may indicate abnormal growth factor signaling which could contribute to tamoxifen resistance. This emphasizes the importance of PR and ER testing in breast cancer diagnosis and treatment choice [91].

10.1.4 Human Epidermal Growth Factor Receptor 2

HER2 is a member of the epidermal growth factor receptor family whose homo or heterodimerization with HER1 or HER3 leads to the auto-phosphorylation of tyrosine residues which triggers a series of signaling pathways that could contribute to tumorigenesis, cell growth and proliferation [271]. Up-regulation of HER has been detected in about 15-30% of patients with breast cancer [83,273] HER2+ breast cancers are usually aggressive and its overexpression has been linked to unfavorable prognosis and good clinical outcome with systemic CTX [91,274]. Moreover, overexpression of HER2 is observed in 13% to 20% of IDCs [91]. HER2 status is also considered in clinical practice for treatment decisions regarding anthracycline-based chemotherapy and use of taxanes [91,275]. Clinical results suggest that HER2 overexpression contributes to resistance to HT in ER+ and PR+ tumors, thus ER+, PR+ and HER2+ cancers may not benefit from HT based on a single agent. In these cases, targeted anti-HER2 therapy in combination with HT may improve patient outcome [91,276]. Overall, ER+, PR+ and HER2- tumors have the best prognosis, whereas ER-, PR- and HER+ tumors are poorly differentiated, have more aggressiveness, poor prognosis and are least likely to respond to HT [91].

10.1.5 Molecular Subtypes Based on Immunohistochemistry Detection of Established Biomarkers

The use of immunohistochemistry (IHC) to detect molecular markers such as ER, PR, HER2 and androgen receptor (AR) on tumor cells provides significant information on the pathophysiology of the tumor and treatment sensitivity [270] (**Fig. 9**). Combinations between these markers can define molecular subtypes (**Refer to Table 1**). Luminal A, Luminal B, HER2+, Triple Negative and Basal-like subtypes are commonly described in clinical guidelines, whereas Normal-like and Molecular Apocrine are not usually included. It is also possible to find subclassification phenotypes in between subtypes such as the Luminal B-HER2-Like [41,91,277–279]. Molecular subtypes not commonly used in clinical guidelines are a concern because they are correlated to cases in which diverse diagnostic tools like histopathology and GEP/S fail to provide an accurate

prognosis [41,91,277–280]. Detection of molecular subtypes in combination with clinicopathological variables, such as tumor size and stage, provides a better prognosis determination and treatment selection.

Table 1.- Molecular subtypes of breast cancer

Subtypes	Molecular Profile	Properties
Luminal A	ER+ PR+ HER2- Low Ki67	<ul style="list-style-type: none"> • Most common subtype that characterizes about 50% of breast cancers. • Best prognosis with HT and sometimes adding CTX.
Luminal B	ER+ PR+/- HER2- High Ki67	<ul style="list-style-type: none"> • About 10-20% of breast cancers. • Worse prognosis compared to Luminal A due to high proliferative capacity and lower response to treatment.
HER2-enriched	ER- PR- HER2+	<ul style="list-style-type: none"> • Poor prognosis compared to luminal subtypes due to its fast growth and invasion. • Treatment with anti-HER2 (Herceptin), or CTX with anthracyclines.
Basal like	ER+ PR+/- HER2- Low Ki67	<ul style="list-style-type: none"> • Dysfunction of the <i>BRCA1</i> gene (Refer to Genetic Tests and Biomarkers) by hereditary or spontaneous mutations have the worst prognosis. • Categorized as Basal A when expressing basal markers or B when presenting less basal markers and more mesenchymal ones. • Basal B subtype linked to a more metastatic phenotype
Triple-negative	ER- PR- HER2-	<ul style="list-style-type: none"> • Common in younger African American women. • Highly related to <i>BRCA1</i> mutations. • Poor prognosis • Treated by CTX only.
Normal-like	ER+ PR+ HER2- KI67-	<ul style="list-style-type: none"> • Molecular and genetic profiles resemble normal breast tissue. • Hardest to identify • Intermediate grade tumors from 1 to 3 (Refer to Staging and Grading of Breast Cancer). • Worst prognosis due to cancer diagnosis is made in late disease phases.

Molecular apocrine cancer	ER- PR- AR+	<ul style="list-style-type: none"> • Besides its molecular marker profile, Ki67 is usually found elevated, giving it a high proliferative characteristic. • Better prognosis than ER+ and PR+ tumors because of the good response to taxanes. • Poor prognosis is imminent if there is no good treatment response.
----------------------------------	-------------------	---

Source: [41,91,278,279].

10.2 Emerging Molecular Biomarkers

10.2.1 Estrogen Related Receptors

ERRs which share a high degree of homology with the canonical ERs, are associated with regulation of metabolic genes and cellular energy metabolism [281]. However, ERRs also modulate molecular pathways involved in breast cancer cell metabolism, growth and proliferation [282,283]. Unlike ERs, ERRs do not bind to ER endogenous ligands such as estrogen. ERRs are known as orphan nuclear receptors since to our knowledge no physiological ligand has been found to bind them yet [282,284]. The transcriptional activity of ERRs seems to depend on the interaction with co-regulator proteins such as peroxisome proliferator-activated receptor- γ (PPAR γ), peroxisome proliferator-activated receptor gamma co-activator 1 α (PGC1 α) and PGC1 β , and is regulated by HER2 (also called ERBB2) signaling pathway [283].

ERR α , ERR β , and ERR γ are the three subtypes that constitute the ERR family. ERR α expression is often observed in tumors with poor prognosis. ERR α mRNA expression positively correlates to *HER2* and coactivator amplified in breast cancer 1 (*AIB1*) expression. However, it has a negative correlation to that of ER α and PR [285]. Moreover, ERR α activates or represses estrogen response elements (EREs) for transcriptional control based on ER status. In ER- breast tumors, it serves as an estrogen-independent activator by interacting with coactivators and binding to EREs of genes such as estrogen-regulated trefoil factor 1 (*TFF1*) and vascular endothelial growth factor (*VEGF*) [282]. In ER+ breast tumors, ERR α competes with ER α for DNA binding and acts as a modulator of estrogen responsiveness by interacting with corepressors and binding to negative EREs [286]. ERR α promotes progression and invasion of primary tumors contributing to bone metastasis, and is thus considered as an unfavorable prognosis biomarker [282,283].

ERR β expression is controversial in breast tumors. ERR β mRNA levels are positively correlated with that of ER β and inversely correlated with the S-phase fraction measurement in the cell cycle suggesting inhibition of cellular proliferation or favoring cellular differentiation [282]. In addition, ERR β signaling pathways have been found to inhibit EMT through Follistatin-mediated regulation of E-cadherin [287]. However, the precise role of ERR β in breast cancer remains elusive and still needs to be investigated.

ERR γ is frequently found to be overexpressed in breast tumors. However, high ERR γ mRNA expression levels are related to less aggressive and steroid receptor cancer cells, which may indicate hormonal sensitivity and good prognosis in breast cancer patients [285,288]. Co-expression of ERR γ with ER and PR is associated with upregulation of E-cadherin which induces mesenchymal-to-epithelial transition, possibly decreasing tumor invasiveness [288]. An AAAG tetranucleotide polymorphism in the untranslated region of the *ERR γ* gene is related to breast cancer susceptibility and HT resistance in invasive lobular carcinoma [282,289].

10.2.2 MicroRNAs

miRNAs have also been identified as potential biomarkers for breast cancer. miRNAs are small non-coding RNA molecules that function as epigenetic regulators, since they are involved in gene expression control on a post-transcriptional level. Methods such as microarrays, Northern blot and qRT-PCR have been used to detect miRNAs levels [83]. Deregulation of miRNAs has been related to development and progression of some diseases including cancer [83,290]. Recent reports have shown that particular miRNA expression profiles correlate with tumor aggressiveness, drug resistance and clinical outcome in breast cancer. Increased levels of oncogenic miRNAs are thought to inhibit tumor suppressor genes, while downregulation of tumor suppressive miRNAs induces the expression of target oncogenes, overall leading to cancer initiation and progression [291]. In addition, studies have found that miRNA levels and functions vary among the different molecular subtypes of breast cancer [83,291].

In 2014, Park and his colleagues reported increased expression levels of certain circulating miRNAs including miR-1280, miR-1260 and miR-720 in patients with ER+ breast cancer. However, a downregulation of miR-1280 expression was observed after HT [292]. Other miRNAs such as miR-16, miR-34c, miR-183, miR-200c, miR-203 and Let-7 have also been associated with breast cancer pathogenesis, especially during cancer initiation [83]. Expression levels of miRNAs in breast CSCs have also been studied. Shimono et al. found different expression patterns in 37 miRNAs between breast CSCs and nontumorigenic cancer cells. In addition, the study reported the downregulation of three specific clusters (miR-200c-141, miR-183-96-182 and miR-200b-200a-429) in breast CSCs. Moreover, they demonstrated that miR-200c is able to regulate *BMI1* expression, which is involved in self-renewal of stem cell niche. Regulation of miR-200c over *BMI1* resulted in clonal expansion inhibition of breast cancer cells, hence preventing tumor formation [293]. However, deregulation of miR-200c, miR-141, miR-34c, miR-106b-25 cluster, miR-30a, and miR-30c has been related to metastasis initiation via EMT-related molecular processes [83,294–296]. Therefore, analysis of miRNA expression profiles could be useful for cancer diagnosis and prognosis.

10.2.3 Exosomes

EXOs are nano-size membrane encapsulated vesicles with 40-100 nm diameter that are candidates to be used as diagnostic biomarkers for breast cancer. They transfer various molecular signals such as proteins, DNA, mRNA, miRNAs. EXOs and their cargoes have modulating roles in the cellular activity of target cells [62,83,297]. Tumor-related EXOs have been implicated in the initiation and development of cancer including immunosuppression, angiogenesis, metastasis and drug resistance [298–300]. It is known that breast cancer cells produce EXOs containing miRNAs, which can induce normal breast cells to undergo malignant transformation, thus contributing to tumor growth and progression [301].

Various studies observed associations between alterations in expression levels of circulating EXO-encapsulated miRNAs and breast cancer. Hannafon et al. showed that exosomal miR-21 and miR-1246 were upregulated in plasma of breast cancer patients compared to healthy subjects [302]. Others have reported correlation between exosomal miRNAs and breast tumor subtype and pathological stage. High levels of exosomal miR-939 have been found in basal-like breast cancer and it is associated with unfavorable prognosis in triple negative tumor subtypes [303]. Moreover, miR-195 has been found to be a potential biomarker for non-invasive and early stage breast cancer whereas miR-21 levels have been found in early and advanced stages of the disease [304,305]. Singh et al. found high concentrations of exosomal miR-10b in metastatic MDA-MB-231 cells as opposed to non-metastatic or normal breast cells [306]. miRNA biological markers could serve as complementary diagnostic tools in breast cancer by analyzing them at different times during the disease progression (e.g. baseline, pre-treatment, follow-up) [300].

10.2.4 Circulating Tumor DNA

ctDNA refers to short cell-free DNA fragments that originate from tumors. These can be detected by molecular analysis of noninvasive liquid biopsies using PCR techniques or genome sequencing, thereby becoming promising biomarkers in BCS, disease monitoring and treatment response [236,307]. A 2019 study performed plasma ctDNA analysis for the detection of somatic mutation in *PIK3CA*, *ESR1*, *ERBB2* and *AKT1* in 234 metastatic patients. Mutations were identified in 63 patients (39.6%) showing potential gene variant patterns in this subpopulation of breast cancer patients which could be useful for clinical management [308]. Similarly, a prospective multicenter study evaluated the predictive factor of ctDNA for cancer relapse in a cohort of 101 patients. This study found that ctDNA detection during follow-up (every 3 months for the first year and every 6 months afterwards) is linked to a high risk of future relapse in early-stage breast cancer. Moreover, the study found an association between ctDNA detection at diagnosis, before treatment and relapse-free survival [309]. The potential of ctDNA to aid treatment decisions has also been evaluated. A study conducted by Schiff et al. identified three driver mutations (*RBI*, *PIK3CA*, *ESR1*) of resistance to fulvestrant and palbociclib and presented

promising results that support ctDNA analysis to monitor targeted drug resistance [310]. Moreover, Bidard et al are currently investigating the efficacy of palbociclib in combination with HT through ctDNA analysis of ESR1 mutation in ER+, HER2- metastatic breast cancer patients. [311]. Thus, ctDNA testing as a potential biomarker tool for breast cancer management has been elucidated in clinical studies. Nonetheless, more evidence is still required to validate the efficacy of this biomarker for cancer prognosis and treatment response.

10.3 Genetic Tests and Biomarkers

10.3.1 Gene Sequencing

Gene sequencing is used as a method for detecting the pathogenic variants of genes associated with high-risk breast cancer. Sanger sequencing is the classical method to detect these genetic variations. However, it has less sensitivity and sequencing volume than newer techniques. Such techniques as Next generation sequencing and Whole genome sequencing have enabled large-scale sequencing which allows the identification of novel mutations and candidate genes associated with breast cancer. Nevertheless, validation studies and co-segregation analysis of novel identified variants are required to determine their clinical significance [312–315]. Mutations in *BRCA1* and *BRCA2* genes have been associated with hereditary breast and ovarian cancer. Women with *BRCA1* or *BRCA2* mutation by the age of 70 could have an approximate breast cancer risk between 57% to 65% and 45% to 49% respectively, depending on the study [316]. Other pathogenic variants in genes such as *PALB2*, *PTEN*, *CHEK2*, *ATM*, *NF1*, *STK11*, *CDH1*, and *NBN* have also been associated with breast cancer risk. Individuals with a personal or/and family history of breast and ovarian cancer are recommended to seek counseling for genetic screening in order to endeavor appropriate preventive measures [262,317]. Genetic testing counseling should be considered before and after the genetic screening to provide appropriate information regarding test options, interpretation of results and following screening. Furthermore, genetic tests should be performed based on the analytical validity, clinical validity, clinical utility, ethical, legal and social implications (ACCE) test framework [262,318] (**Fig. 9**).

Genetic tests are highly sensitive and accurate. For example, BRACAnalysis® has a sensibility of >99.98%, with a rate of errors of <1%. The accuracy of this test >99% in a patient with a 10% probability of being positive based on personal or family history [319]. However, there are some limitations that can occur when performing the genetic sequencing of *BRCA1* and *BRCA2* inheritable mutations. These situations will impede the detection during the sequencing: 1) some sequences can only be determined in one direction (forward or reverse); 2) sometimes the polymorphisms are less frequent and difficult to detect; 3) presence of certain inversions, insertions or regulatory mutations. For example, some insertions that do not result in duplications will not be detected by sequencing. Valencia et al. describes that the test result could be issued to the physicians between one to several weeks, and these are presented in three forms: 1) positive for

deleterious mutation, 2) no deleterious mutation, 3) genetic variant without an identified breast cancer risk. Genetic testing for non-*BRCA* mutations associated with hereditary breast cancer syndromes (e.g. Li-Fraumeni), have poor indications and interpretations. Moreover, they have variable costs (e.g. 400-3000) depending on the number of genes tested, laboratory pricing and insurance [319,320].

After a positive test result, preventive procedures and medication should be considered to reduce breast cancer risk of development. These preventive measures can be chosen depending on the age, medical history, prior treatments, past surgeries and other factors related to the patient. Risk-reducing strategies in *BRCA1/2* mutation patients include chemoprevention, oral contraceptives and risk reduction surgery [321,322].

10.3.2 Gene Expression Profiling/Signatures

After a confirmation of breast cancer by biopsy, there are some clinical recommendations (**Refer to section Genetic Signatures & Clinical Guidelines**) to perform a multigene expression analysis of the tumor biopsy to guide therapeutic decisions. GEP/S is a helpful tool for breast cancer prognosis and management as it identifies differences in the aggressiveness among tumors with the same anatomical staging, genetic predisposition or IHC markers [243]. For example, GEP/S could assist the therapeutic decision in low grade breast cancer which might become aggressive and resistant to CTX [323]. Among the commercially available assays, in this section we described the most used and discussed in clinical guidelines: MammaPrint[®], Prosigna[®], Oncotype DX[®], EndoPredict[®] and Breast Cancer Index[®]. Most of the genes used for GEP/S are dissimilar making each signature not interchangeable. Clinical guidelines recommendations regarding each signature are mentioned at the end of this section. (Table 2) [97,243,263,324,325] (**Fig. 9**).

10.3.2.1 MammaPrint[®]

MammaPrint[®], developed by the company Agendia[®], is a 70-gene expression prognostic test used to determine breast cancer recurrence risk within the 10 years after diagnosis (Table 2). It was designed for patients with an early stage of breast cancer with LN+ (1-3 nodes) or LN-diagnosis. This test classifies results into two low-risk and high-risk groups. The use of MammaPrint[®] provides an accurate assessment of prognostic risk among ER+ tumors. This is not the case for ER- tumors because they are mostly classified as a high-risk group [263,326,327]. The signature was developed using an Agilent microarray platform of 25,000 genes that analyzed 78 frozen tumor samples with a complete medical history of the patients from the Netherlands Cancer Institute. The tested samples had to fulfill the following inclusion criteria: LN-, tumor diameter <5cm, no previous malignancies and issued from patients under 55-years-old. Then, using a supervised classification algorithm to find the fittest model, a significant correlation was found

between 231 out of the 25,000 genes and distant metastases within 5 years. Later, they ranked the 231 genes and chose the top 70 that most accurately classified the tumors into low or high risk groups. Finally, 19 external samples (from the same institute) were used to validate the signature. MammaPrint[®] predicted the risk group correctly in 17 of the 19 samples [328,329].

In 2019, Brandao and colleagues mentioned three key studies that assessed the clinical validation of MammaPrint[®], including the TRANSBIG consortium study, the RASTER and the MINDACT trials [327]. The TRANSBIG consortium study (an international network conformed by physicians, scientists, patient advocates and biotechnology professionals) performed an independent multicenter retrospective validation in 302 patients under the age of 61 with T1-2, LN- and 70% ER+ tumors. The goal of the study was to compare the prognostic value between MammaPrint[®] and a clinicopathologic prognostic tool (Adjuvant! Online). Results showed that MammaPrint[®] determined a strong prognostic factor of cancer recurrences, distant metastasis, (hazard ratio of 2.32; $\alpha = 0.05$) and overall survival (hazard ratio of 2.79; $\alpha = 0.05$) for up to 10 years after diagnosis. Authors concluded that the signature could provide additional independent prognostic information from the data obtained by the clinicopathologic prognostic tool [330,331]. The microarray-prognostics-in-breast-cancer (RASTER) trial was the first prospective study that assessed 427 patients regarding MammaPrint[®]'s performance. The aim of the study was to analyze the recurrence prognostic factor of MammaPrint[®] as a guidance for adjuvant therapy decisions compared to clinicopathological tools (Adjuvant! Online). Patient inclusion criteria consisted of: ≤ 54 years of age, T1-3, LN- and adjuvant systemic treatment. The results confirmed an additional prognostic value of MammaPrint compared to the clinicopathological risk estimation in a 5 years period [332].

The Microarray in Node-Negative Disease May Avoid Chemotherapy Trial (MINDACT) sponsored by the European Organization for Research and Treatment of Cancer (EORTC) is a prospective randomized multicenter validation study that included 6,693 patients with early stage breast cancer. The preliminary results showed that the use of MammaPrint[®] at classifying patients with low genetic recurrence risk, may help to avoid CTX in patients previously identified in the high clinicopathological risk group. Therefore, using MammaPrint[®] could avoid CTX in patients with a high clinical but low genomic recurrence risk within a 5-year period. Additionally, MINDACT validated the use of adjuvant CTX in those classified in the high-risk group. The trial is still ongoing and will end in June 2022 [333–335].

10.3.2.2 Prosigna[®]

PAM-50[®], the previous version of Prosigna[®], was created by the NanoString[®] company to define an alternative option for conventional molecular subtyping (e.g. IHC) (Table 2) [336]. The current purpose of Prosigna[®] is to provide a risk of recurrence score (from 0 to 100%) up to 10 years after diagnosis, employing 50 genes plus clinicopathological indicators (e.g. tumor size)

[337,338]. The score is applicable in postmenopausal patients with HR+, LN- or LN+ (1-3 nodes) and stage I-II tumors treated with HT [339–341]. Prosigna[®] divides node-negative patients into low (≤ 40 score), intermediate (41-60 score), and high risk of recurrence (>60 score). For node-positive patients, the cut-offs for risk of recurrence vary depending on the number of node involvement [342].

Prosigna[®] was validated by using formalin-fixed paraffin-embedded tissue samples across multiple clinical laboratories, showing no significant variations on its analytical performance [341]. A retrospective validation study used 1,017 ER+, HER2- and LN+/- primary breast cancer samples [from the TransATAC (Arimidex, Tamoxifen, Alone or in Combination) trial] treated with anastrozole or tamoxifen to assess the prognostic information from the score. This prognostic information was also compared to the prognostic data from Oncotype DX and immunohistochemical 4 (IHC4). The study found that the Prosigna[®] score provides more prognostic information than Oncotype DX, with a better differentiation in intermediate and high risk groups. ICH4 provided similar information to Prosigna[®] in all patients but lower in the HER2- and LN- patients [343]. Gnant et al. assessed 1,478 samples from the ABCSG-8 trial that used postmenopausal women with early breast cancer ER+ and treated with adjuvant HT alone (tamoxifen or tamoxifen followed by anastrozole), to see if the prediction score provides additional information than clinical variables [Clinical Treatment Score (CTS)]. The signature significantly ($p < 0.0001$) adds prognostic information to the clinical variables. These results, in addition to the results from the ATAC trial, provide Level 1 evidence (one or more validation studies with consistent results) for the signature clinical validity [336,344]. A retrospective study comprehended 2,485 samples from both ATAC and ABCSG-8 trials. Patients were postmenopausal women that had early breast cancer with HR+ and LN- or LN+ (1-3 nodes). The patients were also treated with tamoxifen and/or anastrozole. The study aimed to know if Prosigna[®] could classify the patients providing additional information regarding their prognosis compared to clinical variables (CTS). Results showed that Prosigna[®] provided more information than clinical variables in LN- ($p < 0.0001$) and LN+ ($p < 0.0002$) patients, and classified them into the risk of recurrence subgroups for up to 10 years after diagnosis [345]. Additionally, this signature retrospectively analyzed 122 tumor samples that were HR+ and HER2- patients who had received multiple cycles of a standard anthracycline and taxane therapy before surgery. Prosigna[®] provided a significant prediction of recurrence risk for patient response to neoadjuvant CTX [346]. In 2015, Alvarado and colleagues prospectively compared the recurrence risk estimates of Prosigna and Oncotype from 52 patients showing a poor correlation between these signatures and none interchangeability [347].

10.3.2.3 Oncotype DX[®]

Oncotype DX Breast Recurrence Score[®], provided by the Exact Sciences Corp., analyzes the expression of 16 cancer-related and 5 housekeeping genes using RT-PCR. These genes are

divided into six representative groups: 1) Estrogen group, 2) HER2 group, 3) proliferation group, 4) invasion group, 5) others and 6) reference group (Table 2) [348]. The test is able to report a quantitative recurrence score value for each patient, with a standard deviation of 2 recurrence score units in a 100-unit scale [349]. Oncotype DX® provides a cancer relapse score that divides patients into high-risk (score ≥ 31), intermediate-risk (score 18 to 30) and low-risk (score < 18) groups. These scores predict disease recurrence for up to 10 years and the probable efficacy of using adjuvant CTX in high risk patients [263,350–353]. This test intends to benefit patients with an early stage of invasive cancer, ER+, HER2- and LN- or LN+ (1-3 nodes) breast cancer [354].

Based on a meta-analysis study performed in 2013, the signature showed an elevated prevalence of patients with an intermediate recurrence risk. A classification of intermediate risk could represent an unnecessary investment for the patient as results lack clinical utility [355]. The TAILORx trial compared patients receiving HT and chemo-endocrine therapy to find out if those with an Oncotype DX® intermediate score could avoid adjuvant CTX. This study concluded that patients with an intermediate risk score could not benefit from the administration of CTX. Approximately 85% of these patients could be spared from adjuvant CTX if the recurrence score is lower than 25 and the age is > 50 years or if the recurrence score is lower than 15 and the age is < 50 years [354]. The TAILORx results were consistent across multiple studies with thousands of samples. Among them; two studies with 38,568 and 6,768 samples respectively, both from the Surveillance, Epidemiology and End Results (SEER) databases [356,357]; a retrospective study with 709 samples from the Clalit Health Services registry [358]; and the prospective West German Study Group Phase III PlanB Trial with over 3,198 samples [359].

10.3.2.4 EndoPredict®

EndoPredict®, provided by the Myriad company, quantifies the mRNA levels of 8 genes and 4 reference genes in formalin-fixed paraffin-embedded tissue samples by RT-PCR (Table 2). When combined with clinical characteristics such as nodal status and tumor size, this signature becomes the EndoPredict Clinical® (EPclin®) analysis [360,361]. EPclin® is capable of predicting the risk of distant metastasis within 10-year period after diagnosis, in breast cancer of postmenopausal women with ER+, HER2-, LN- or LN+ (1-3 nodes) and, receiving HT or CTX. The score classifies the patients into a high (≥ 3.32867) and low (< 3.32867) risk groups [362–365].

A retrospective 10-year study compared the prognostic classification between EPclin® and clinical guidelines, such as the NCCN, German S3 and SG. The study included 1702 postmenopausal woman from the ABCSG-6 (tamoxifen-only arm) or ABCSG-8 trials, that had ER+ and HER2- tumors and received only HT (either tamoxifen or tamoxifen followed by anastrozole). The genetic signature showed an absolute risk reduction of 18.7% for distant metastasis compared to clinical guidelines. EPclin® reclassified 58%-61% of the patients to a low risk group, from the high risk group originally determined by the clinical guidelines. On the

contrary, EPclin incorrectly reclassified 5% of women to a low risk group, when actually having a high risk of distant metastasis within the 10 years [360]. Buus et al. compared the assessment for the risk of distant metastasis of EndoPredict[®] and EPclin[®] with Oncotype DX[®]. The retrospective study evaluated 928 breast cancer patients (from the TransATAC monotherapy arm trial) with ER+ and HER2- tumors treated with anastrozole or tamoxifen for 5 years. EndoPredict[®] alone had a similar performance to Oncotype DX[®] when predicting metastasis in a 5-year period, but it was superior in the 10-year period. EPclin[®] outperformed Oncotype DX[®] when estimating the risk of metastasis in the 10-year period, with the exception of LN- patients in the 5-year period [366]. The ongoing Extended Endocrine Trial (EXET) is evaluating the benefit from receiving HT for longer than 5 years (extended therapy) in patients classified in the high risk group. Results will be available in 2022. [367].

10.3.2.5 Breast Cancer Index[®]

Breast Cancer Index[®], created by Biotheranostics Inc., is a RT-PCR test designed for the prediction of early (0-5 years) or late (5-10 years) breast cancer recurrence after diagnosis, in patients with ER+, LN- or LN+ (1-3 nodes). The test uses two parameters to calculate the score: 1) the gene ratio of *HOXB13:IL17BR*, and 2) the molecular grade index of 5 proliferation-related genes (Table 2). Depending on the score, patients can be classified into low (<5.0825), intermediate (≥ 5.0825 to <6.5025), or high (≥ 6.5025) risk groups [263,368–372].

In a prospective study, 665 samples of postmenopausal patients with ER+ breast cancer from the TransATAC tissue bank were used to compare Breast Cancer Index[®] with Oncotype DX[®] and the IHC4 assay. The study found that Breast Cancer Index[®] was the only significant prognostic test for early and late distant recurrence. The test could also identify patients who can benefit from HT as indicated by a high risk score [373]. Sgroi et al. evaluated the prognostic performance of Breast Cancer Index[®] for distance recurrence and treatment benefit from extending letrozole 5 more years after a 5-year treatment with tamoxifen. The retrospective study assessed 5,157 eligible breast cancer ER+ and/or PR+ patients from the MA.17 trial. Results showed that a high risk score was statistically associated with decreased late recurrence in patients with extended letrozole treatment (2,575 patients) compared with placebo (2,582 patients) (adjusted OR: 0.33; 95% CI: 0.15-0.73; $p=0.006$) [374]. The prospective phase III trial Tras-aTTom randomized 6,953 HR+ patients, to stop or continue tamoxifen after 4 years of initial therapy. This trial showed a statistical association between the signature and a high risk score with a 9.8% benefit for a 10-year treatment with tamoxifen and no association with a low risk score. Therefore, this study provided a level 1B of evidence for Breast Cancer Index as a predictive biomarker for extending HT [375]. Overall, studies have provided evidence for the prognostic value of GEP/S in breast cancer. However, clinical guidelines are required to considerate the use of GEP/S in clinical practice.

10.3.2.6 Genetic Signatures & Clinical Guidelines Recommendations: Towards the Prognostic Staging

In 2017, the St. Gallen International Breast Cancer Conference (SG) panel gathered more than 3,000 experts from >100 countries to evaluate the use of the five genetic signatures covered above (Table 2) in clinical practice. Only 64% of the panelists agreed that molecular subtypes of breast cancer should be determined by a multigene test instead of conventional techniques used at the time (e.g. IHC). However, 86% agreed not to consider necessary the use of GEP/S in ER+, PR+, HER2-, low-Ki67, T1a-b, LN- and low-grade early breast cancer patients. Aside from this, all panelists concurred that gene signatures provide valuable information regarding prognosis in patients with high clinicopathological risk factors (e.g. HER2+). Additionally, SG accepted that these signatures could help in the therapeutic decision regarding the omission of CTX, especially for ER+, HER2- and LN- in early breast cancer. Panelists conceded that using gene signatures for ER+, HER2- and LN+ is not advisable at decision making for treatment. Finally, just 46% of the panelists agreed that the genetic signatures provide valuable information for the clinical decision, regarding extended HT (more than 5 years) for breast cancer [324].

Most of the panel (93.8%) endorsed the practice of Oncotype DX[®] for breast cancer prognosis for up to 5 years after diagnosis in patients with ER+, HER- and LN- tumors. While MammaPrint[®] and Prosigna[®] had an acceptance of 81.3% and 80% respectively in these cases. The least preferred options were EndoPredict[®] with 70% and Breast Cancer Index[®] with 60% of the experts' approval. Addressing the use of the signatures in LN+ cases, the percentage of approval decreased to 60% for Oncotype DX[®], 42.9% for MammaPrint[®], 75% for Prosigna[®], 43.3% for Breast Cancer Index[®] and 55.6% for EndoPredict[®]. When considering CTX prescription in ER+, HER2- and LN+ patients, the acceptance percentage did not abate much for MammaPrint[®] and Oncotype DX[®]. This was not the case for Prosigna[®], leading to an acceptance of 46.7%, and even lower for EndoPredict[®] and Breast Cancer Index[®] with 15.8% and 8.1% respectively [324].

In the SG panel of 2019, the discussion about genetic signatures was less debated compared to 2017. The 93% of panelists recommended the use of genetic signatures to endorse CTX in ER+, HER2- and LN- tumors whereas 74% suggested their application in T3 and LN- patients, and 78% in T3 and LN+ cases. For Luminal A-like tumors with ER+, HER2-, grade 1 and ≥ 4 LN+ involved, only 65% of the experts consented to use the genetic signatures. After the TAILORx trial, the experts preferred CTX for women younger than 50 years with LN- breast cancer and an Oncotype DX[®] recurrence score of 21-25. Such score was considered before the study as indeterminate, which did not provide prognostic information to guide clinical decision. Based on the MINDACT trial results, 80.9% of the experts decided to spare CTX in patients older than 50 years, LN+ and within the MammaPrint[®]-low risk group [376].

The 2019 recommendations from the American Society of Clinical Oncology (ASCO) regarding the use of Oncotype DX[®] stated that: 1) the test is suggested in ER+, PR+, HER2- and LN- tumors to guide adjuvant systemic CTX; 2) HT alone is recommended for patients with a recurrence score of <26 that are >50 year of age, or with a recurrence score of <16 that are ≤50-years-old, due to there is little to no benefit from CTX on these cases; 3) CTX is recommended for patients ≤50-years-old with a recurrence score between 16 and 25; 4) high quality evidence recommends that patients should be considered for a chemo-endocrine therapy if they have a recurrence score of >30. Based on the expert panel's consensus there is insufficient quality evidence to apply the same recommendation if the patient has a recurrence score from 26 to 30; 5) the signature should not be used to guide decision for adjuvant systemic CTX if the patient is ER-, PR-, HER2-, and LN+, or HER2+, or triple negative breast cancer [377].

ASCO recommendations for EndoPredict[®] include: 1) the signature is suggested to guide adjuvant CTX decision in patients ER+, PR+, HER2- and LN-; 2) the signature is not recommended to guide the decision within HER2+ and LN+, or triple negative. Regarding MammaPrint[®]: 1) the withholding of CTX can be suggested by a high-risk categorization, because of a potential but limited benefit from the treatment; 2) in patients with a low clinical risk, the genetic signature would not change treatment decisions, because even with a high genetic risk, CTX is not recommended; 3) a high genetic risk categorization recommends to withhold CTX if the patients are ER+, PR+, HER2- and LN+. However the patients should be informed that there is a chance to benefit from CTX in these cases, and even more if there are >1 LN+ involved; 4) the genetic signature is not recommended in low clinical risk, HER2+, or triple negative patients due to insufficient data [377]. For Breast Cancer Index[®], ASCO stated that: 1) the signature is helpful for adjuvant systemic treatment decisions if patients have ER+, PR+, HER2- and LN- tumors; 2) the test is not recommended in LN+, HER2+, or triple negative patients to help in treatment decisions. A final recommendation is to avoid using Oncotype DX[®], EndoPredict[®] or Breast Cancer Index[®] to decide on extending HT, if the patient is ER+, PR+, HER2- and has had at least 5 years of HT without evidence of recurrence [377].

The NCCN panel states that GEP/S provide prognostic information in addition to the anatomical staging and biomarker information. GEP/S could be considered for assessing the risk of recurrence, but not all of them foresee if systemic CTX could reduce the risk of recurrence. The panel avails Oncotype[®] as the only GEP/S that is capable of predicting the benefit of adding adjuvant CTX to further reduce the risk of recurrence. For patients with axillary LN-, HR+ and HER2-, the panel has specific recommendations regarding GEP/S: 1) Oncotype[®] is suggested in patients with invasive or ductal breast cancer of >0.5cm diameter and LN- to estimate risk of recurrence and CTX predictive benefit; 2) Mammprint[®] is being capable of identifying patients with low genomic risk but high clinical risk that could avoid CTX. The panel also recommends GEP/S prognostic information in axillary LN+, HR+ and HER2- to assist treatment decisions [6].

ESMO recommends the use of MammaPrint[®], Oncotype DX[®], Prosigna[®], EndoPredict[®] or Breast Cancer Index[®], as an additional guide for treatment decision in cases of uncertainty after considering all clinicopathological factors. MammaPrint[®] or Oncotype DX[®] could be applied in ER+ and HER2- patients to obtain prognostic information, to prescribe adjuvant CTX if high risk or high score is obtained. After considering the tumor size and LN status in their final risk assessment, Prosigna[®] or EndoPredict[®] are recommended to indicate adjuvant CTX in ER+ and HER2- patients [97]. ESMO do not recommended GEP/S to patients who have: 1) ER+, LN-, T1a-b and grade 1 tumors; 2) presence of a comorbid condition that limits to receive adjuvant CTX; 3) special cellular subtypes of luminal-like breast cancer (e.g. low-grade encapsulated papillary carcinoma) that are treatable with locoregional treatment only and have a good prognosis estimated by clinical factors; 4) presence of up to 3 LN+ and high risk factors (e.g. comorbidities); 5) ≥ 4 LN+ and adjuvant CTX eligibility [97].

There is a vast amount of published information that validates and compares the signatures reviewed above. Even though the scope of employability among patients is similar between signatures (**Refer to Table 2**), their performance and/or applicability could vary depending on the type of validations (e.g. prospective or retrospective studies, number of samples) and the population used in such validations (e.g. age, TNM anatomical stage, molecular subtype) [326,366,378–380]. Buus et al. presented an abstract at the “San Antonio Breast Cancer Symposium” that showed an ongoing study aiming to evaluate the concordance of prognostic information of the four genetic signatures (All of the above except for MammaPrint[®]) using a Spearman rank correlation. The preliminary results from 785 patients of the TransATAC sample set revealed the following: 1) EndoPredict[®] scores are moderately correlated to the other three signatures; 2) Oncotype DX[®] recurrence scores are divergent from those of Breast Cancer Index[®] and Prosigna[®] [380]. Therefore, besides the fact that all signatures give prognostic information of breast cancer, their use is limited by the wide spectrum of tumor’s characteristics. It is crucial to identify which signature is the most appropriate for each patient, even if all have powerful validation studies. The key is to achieve a more personalized cancer management with the help of genetic signatures.

Clinical guidelines can avail the use of genetic signatures in clinical practice. Hence, guidelines recommendation serve as a powerful tool because they consider clinical expert opinion, the signature scope, patients characteristics and the quality of evidence available [7,243]. The latest AJCC’s Cancer Staging Manual proposed “Prognostic staging” as a change from the previous edition, where only anatomical staging (TNM) was considered. The new edition combines TNM with tumor grade, receptor status and genomic tests to provide a more accurate prognosis. For instance, previously a “T0-2, N2, M0, ER+ and HER2-” tumor received a stage IIIa. If the patient also obtained an Oncotype DX[®] of < 11 (low-risk), the stage would change from IIIa to Ib [243]. The updated prognostic staging can concede physicians a more holistic comprehension of the final

diagnosis prognosis. Thus, physicians are able to generate a more thoughtful treatment decision with the most favorable prognosis possible for each patient.

Table 2.- Genetic signatures for breast cancer prognosis

Characteristics	MammaPrint®	Prosigna®	Oncotype DX®	EndoPredict®	Breast Cancer Index®
Number of genes	70 ¹	50 ²	21 ³	12 ⁴	7 ⁵
Molecular method	Microarray	RT-PCR	RT-PCR	RT-PCR	RT-PCR
Scope of employability	Early stage invasive breast cancer ER+, HER2-, and LN- or LN+ (1-3 nodes).	HR+, LN- or LN+ (1-3 nodes) and stage I-II breast cancer when treated with HT.	Early stage invasive breast cancer ER+, HER2-, and LN- or LN+ (1-3 nodes).	Breast cancer in postmenopausal women with ER+, HER2-, LN- or LN+ (1-3 nodes) and while treated with HT or CTX	Early stage invasive breast cancer ER+, HER2-, LN- or LN+ (1-3 nodes) and the benefit when extending HT.
Manufacturer	Agendia BV®	NanoString Technologies, Inc.	Exact Sciences Corp.	Myriad®	Biotheranostics, Inc.

FDA status	Cleared, submissions: K101454, K081092, K080252, K070675, K062694.	Cleared, submissions: K130010	Not cleared or approved	Not cleared or approved	Not cleared or approved
Guidelines inclusion*	ASCO NCCN ESMO EGTM SG	ASCO NCCN ESMO EGTM SG	ASCO NCCN ESMO EGTM SG	ASCO NCCN ESMO EGTM SG	ASCO NCCN ESMO EGTM SG
Cost[±]	≈ \$3,200	≈ \$4,000	≈ \$4,000	≈ \$2,100	≈ \$3,450

Abbreviations: ASCO: American Society of Clinical Oncology; NCCN: National Comprehensive Cancer Center Network; ESMO: European Society for Medical Oncology; SG: St. Gallen International Breast Cancer Conference; EGTM: European Group on Tumor Markers.

*Recommendations from guidelines vary from the scope of employability, for more information refer to "Genetic Signatures & Clinical Guidelines Recommendations: Towards the Prognostic Staging" or to the guidelines cited web pages to see evidence-based levels.

±Prices listed are an approximate and may vary according to the region time and supplier. Any conversion was applied at the moment of consult.

1. *MS4A7, TGFB3, CENPA, Contig32185_RC, COL4A2, CMC2, CDC42BPA, HRASLS, RFC4, LPCAT1, ALDH4A1, FGF18, GMPS, CCN4, PRC1, NDC80, ECI2, CCNE2, DRS1, Contig48328_RC, AA555029_RC, ORC6, ESM1, SCUBE2, Contig51464_RC, MMP9, TSPYL5, ADGRG6, PALM2-AKAP2, Contig55377_RC, IGFBP5, BCL2, MCM6, NMU, MELK, Contig38288_RC, PITRM1, Contig55725_RC, NUSAP1, SLC2A3, Contig46223_RC, DTL, MTDH, Contig20217_RC, EBF4, RAB6B, Contig28552_RC, Contig40831_RC, DIAPH3, UCHL5, Contig63102_RC, EXT1, Contig63649_RC, TMEM74B, STK32B, Contig2399_RC,*

SMIM5, SERF1A, OXCT1, Contig35251_RC, Contig56457_RC, AP2B1, IGFBP5, FLT1, Contig46218_RC, GNAZ, Contig32125_RC, Contig25991, DCK, GSTM3.

2. *ACTR3B, ANLN, BAG1, BCL2, BIRC5, BLVRA, CCNB1, CCNE1, CDC20, CDC6, CDCA1, CDH3, CENPF, CEP55, CXXC5, EGFR, ERBB2, ESRI, EXO1, FGFR4, FOXA1, FOXC1, GPR160, GRB7, KIF2C, KNTC2, KRT14, KRT17, KRT5, MAPT, MDM2, MELK, MIA, MKI67, MLPH, MMP11, MYBL2, MYC, NAT1, ORC6L, PGR, PHGDH, PTTG1, RRM2, SFRP1, SLC39A6, TMEM45B, TYMS, UBE2C, UBE2T.*

3. The six gene groups analyzed are categorized as the Estrogen group (*ER, PGR, BCL2, SCUBE2*), HER2 group (*GRB7, HER2*), Proliferation group (*Ki67, STK15, Survivin, CCNB1, MYBL2*), Invasion group (*MMP11, CTSL2*), Others (*GSTM1, CD68, BAG1*) and Reference group (*B-actin, GAPDH, RPLPO, GUS, TFRC*).

4. *BIRC5, UBE2C, DHCR7, RBBP8, IL6ST, AZGP1, MGP, STC2*; Reference genes: *CALM2, OAZ1, RPL37A, HBB.*

5. Genetic index: *HOXB13, IL17BR*; Proliferation genes: *BUB1B, CENPA, RACGAP1, RRM2, NEK2.*

Source: [6,97,324,325,327,377,381–386].

11. Issues with Current Screening and Diagnostic Tools: The Need for New or Improved Techniques

Breast cancer diagnosis and treatment could involve repeated visits of patients to fully equipped medical centers. It has been shown that living in rural areas can affect the access to breast cancer diagnostic tools, potentially resulting in delays in cancer diagnosis [387]. Additionally, being far from primary health centers and hospitals, prevents the availability of treatment, surgery, or appropriate interventions, decreasing the possibility of positive outcomes and patient recovery [387–390]. Another issue is the discomfort and stress that is generated during screening and diagnostic procedures that reduce the willingness of patients to perform the tests [11–14]. There is a need for accurate, non-invasive data collection and comfortable equipment to perform screening and diagnosis. Hence, future screening and diagnostic tools should be developed aiming for portability, possible wearable features, comfort, and improved connectivity for data sharing. New devices should take into consideration the possibility to connect to wireless and global networks (e.g. Starlink) to share clinical data between patients and physicians. Data shared in wireless networks often pose a threat of privacy leakage during the process of communication for analysis [391,392]. Strengthening the security and protecting the privacy of participants, patients, and cluster centers should be considered when developing new technologies [392]. A tool with such attributes, in addition to well-planned screening and awareness campaigns for specific populations at risk, could increase accessibility for patients living in rural areas and thus overcome travel distance barriers [393].

The effectiveness of community campaigns for BCS is still under question as evidence is sparse and not accurately reported or reviewed [394–396]. Transmitting clear and accurate information regarding breast cancer prevention and improving the accessibility to screening and diagnostic equipment could influence how many women could be tested [397]. However, in our opinion, this could also lead to overdiagnosis and unnecessary examination if clinical recommendations regarding BCS and diagnosis are not followed (**Fig. 1**) [7,96,106]. For example, in one study Hispanic women at the Columbia University Medical Center in New York were found to be screened more frequently than non-Hispanic white women even if they had a lower risk. This could increase the possibility of false positives, unneeded recall for breast imaging, and biopsies for Hispanic women [398]. Interestingly, in another study it has been shown that Hispanic women living on the US border have knowledge about breast cancer, however, they were under screened due to the lack of accessibility to equipment [399]. Offering information regarding breast cancer awareness and the possibility of access to risk-stratified screening should come together for early diagnosis.

Screening could lead to overdiagnosis and then to overtreatment, including surgery, radiation, and HT. This problem could be prevented if screening and diagnosis are performed with a risk-factor stratification or more advanced methods for the classification of tumor aggressiveness [7,398,400,401]. Overdiagnosis is defined as when cancer is identified; however, it won't progress or cause symptoms or death [106,402]. Overdiagnosis should not be confused with false-positive results as this happens when a positive test in an individual is recognized subsequently as not cancer. It has been reported that the magnitude of overdiagnosis in breast cancer using mammography is estimated to be up to 25% [402]. This seems to be an inevitable effect of mammography screening as the objective is to diagnose breast cancer before clinical detectability [403]. Even if mammography is detecting smaller cancer lesions, the problem of overdiagnosis occurs when detected cancers are slow-growing or don't progress at all, even if they are treated [400]. GEP/S could help in the analysis of cancer samples and the distinction of indolent from aggressive tumors leading to the reduction of overdiagnosis and better clinical management [400]. Currently, most GEP/S are able to detect the molecular differences between noncancerous tissues and those with different degrees of aggressiveness [400]. GEP/S and the analysis of the three-dimensional structure of the tumor biopsy could improve the detection of cells and niches of cancer stem-like cells that could be associated with higher aggressiveness and resistance to therapy [404]. However, a biopsy is needed still to determine the aggressiveness of a cancer lesion by GEP/S analysis which is invasive and painful [405]. An ideal BCS and diagnostic tool should be non or minimally invasive with a high capacity to detect cancers and predict accurately its aggressiveness leading to an increase in the assessment of the aggressiveness of breast cancer and decrease of overdiagnosis. One of the most appealing diagnostic and screening methods in research is the use of liquid biopsies to analyze circulating cells or cell-free DNA as prognostic and predictive classifiers [307,406,407].

Analysis of the predisposition to cancer and prognosis in a specific population based on its genetics has shown to be necessary to improve treatment selection [23]. Genetic testing of hereditary mutations or gene expression analysis is becoming more accessible regarding its price and offering capacity [408]. However, physicians and patients' knowledge of these tools is still missing limiting the advancement of disease treatment [409]. It should be emphasized during medical training and awareness campaigns what is genetic testing and how to apply it [408]. It could be important to test GEP/S and NGS in populations with multiple ethnic origins and with variable predisposition to develop cancer. It is common to find variations in gene expression among different populations [410–412]. These variations should be taken into consideration when recommended or used for breast cancer prognosis and therapeutic decision [23,413]. Therefore, genetic tools should be evaluated and approved by considering how they were developed, tested, and validated in large and ethnically diverse groups.

Measurement methods and interpretation of diagnostic biomarkers vary among laboratories, thus possibly influencing the accuracy in cancer diagnosis [414]. For example, the threshold for determining Ki67 levels could vary between exams as it depends on the experience of the observer, biopsy quality, and representativeness of the chosen microscopy fields. It is still unknown whether choosing hotspot areas or averaging all areas in the microscopic field would provide a more accurate measurement of Ki67 [415]. A study carried by Jang et al. compared the prognostic impact of Ki67 labeling index in luminal/HER2- breast tumors between the average method versus the hot spot method. Results showed that when using the hot spot method, the most suitable cutoff was 22% with a sensitivity of 75% and a specificity of 60%, whereas the most appropriate Ki67 cutoff for the average method was 18% with sensitivity and specificity of 67.9% and 63.4% respectively. The authors concluded that both methods have good predictive performances for tumor recurrence in luminal/HER2- breast cancers. However, they acknowledge that the average method has a greater reproducibility [414]. Similarly, methodological factors in the IHC analysis such as tissue fixation, choice of antibody, and threshold for interpretation can vary, affecting test accuracy and reproducibility [416]. A study conducted by Dekker et al. evaluated the reproducibility of IHC ER and PR testing using tissue microarray (TMA) from nine pathology departments. Overall sensitivity and specificity for testing ER expression were 99.7 and 95.4% respectively whereas for PR testing were 94.8 and 92.6% [417]. In 2012, a study evaluated the feasibility of retesting HER2 status on TMA using SP3 and 4B5 antibodies, and mono color silver *in situ* hybridization, as a quality control approach for HER2 IHC testing. Results showed that out of 1,210 invasive breast carcinomas, 1.3% of the tumors were identified as false positives and 0.7% as false negatives. Finally, the study proposed this method to improve HER2-testing standardization [418]. Applying ML algorithms on data measured in a large worldwide population along the last decades from a prognostic tool would certainly improve data interpretation from mammography or IHC images. These key assets could increase the reproducibility of clinical diagnosis and standardization of methods even applied to a particular population.

The accessibility and effectiveness of current screening and diagnosis breast cancer tools still needs to be improved. Technical innovations in diagnosis tests must be proved clinically with a process that may take several years and could discourage research groups [419]. It is our belief that an agreement and coordination between multidisciplinary research team members, regarding the constraints to develop new screening and diagnostic tools should be considered before starting a project. Regulatory agencies, such as the FDA monitor the development and safety from established to emerging biomarkers, with requirements that should be included as milestones in the development of new projects. Newer methods such as next generation sequencing would help to find low-frequency genetic variants that increase the possibilities to develop breast cancer helping to risk-stratify patients [420]. Risk-stratification approaches could combine genetic and non-genetic risk factors in order to provide a personalized cancer management.

12. Conclusion

Even though breast cancer survival rate after 5 years of diagnosis is very high, it is still a disease difficult to diagnose and treat as its behavior differs from one person to another. Our capacity to detect cancer, define its stage and future aggressiveness is based on multiple tools for screening and diagnosis. This represents a multidisciplinary challenge for biomedical and technological scientists, as understanding tumor heterogeneity and physiological variations among patients requires multiple sources of information in order to provide newer and more accurate methods or improve existing ones. As current methods and tools to detect cancer are being improved, new technologies are on their way to provide an increase in portability, connectivity, price, and data management that will have important consequences for the maintenance or recovery of health from any individual and patient. Thus, medical practitioners have to be constantly updated on new practices, and interpretation of its results. This comprehensive and critical review fuses biological, technological and medical information in an attempt to provide physicians and people interested in the field, with the necessary knowledge to communicate needs and provide better support for the decisions during screening and diagnosis before the eventual treatment. The use of tools to screen and diagnose are part of a bigger strategy to fight cancer which can influence decisions for better treatments without recurring to invasive procedures or unnecessary CTX.

Many challenges need to be solved to achieve better screening and diagnosis tools in order to accurately predict cancer progression. Image-based techniques such as mammography, MRI and ultrasound are commonly used as primary detection methods in breast cancer. However, as mentioned in this work, these are expensive, have image resolution limitations and vary in diagnostic accuracy. On the other hand, biomarker-based methods are still under development with promising results. In addition, there is still a lack of evidence, consensus in guidelines and protocols for the generalized use of GEP/S in clinical practice, where more studies considering population and ethnic diversity are needed. Furthermore, advanced diagnostic tools such as genetic

testing and GEP/S are expensive and require highly trained physicians and technicians. Finally, the combination of image-based techniques such as mammography, biopsies and immunohistochemical tests is still the current applicable approach that can discriminate benign from malignant breast tumors. Beyond this current and accepted standard, the ideal detection method would be balanced between comfort, accessibility, cost, and effectiveness. This ideal detection technique would function as an automated device that identifies breast lesions and differentiates benign from malignant masses at early stages. This would also allow long term compilation of ongoing data that could be easily interpreted by the patient, health professional and scientists. The goal of these specifications would be to avoid unnecessary surgery, overdiagnosis and overtreatment.

Data Availability Statement

The corresponding author can answer or provide information on request to any comments or questions regarding this publication.

Author Contributions

DB & AL: methodology, investigation, writing, visualization, review, and editing.

PL & DS: methodology, investigation, writing, visualization, review, and editing.

FT: investigation, review and editing, funding acquisition.

FS: methodology, investigation, writing, review, and editing.

LT: methodology, investigation, writing, review and editing, project administration, funding acquisition.

AC: conceptualization, methodology, investigation, writing, visualization, review and editing, figures, supervision, project administration, funding acquisition.

Conflict of Interest

The authors declare that this work was conducted in the absence of any commercial or financial relationships that could be construed as a potential conflict of interest.

Funding

Collaboration grants Universidad San Francisco de Quito, USFQ HUBi: 12468, 12467; School of Medicine Grant HUBi:16925.

Role of the Funding Source

The funding source is the Universidad San Francisco de Quito, USFQ. This institution was not involved in the study design, in the collection, analysis and interpretation of data; in the writing of the manuscript; and in the decision to submit the manuscript for publication.

Acknowledgments

We are thankful to the Universidad San Francisco de Quito - USFQ, and the School of Medicine - USFQ, for funding this project, their constant support to our work and initiatives. To the "Servicio de Cirugía" at the "Hospital de Los Valles," "Instituto de Investigaciones en Biomedicina - USFQ," to the Mico-Act Research Consortium, Quito, Ecuador and "Sistemas Médicos," SIME-USFQ. We would like to special thank Estefania Roldán for revising our article and comments, to Esther Wisdom, Serena Sanon, and Kevin Zambrano for their suggestions. Daniela Suquillo would like to thank her parents Silvia Yépez and Edwin Suquillo as they are her greatest support in every step she takes, their pride is her happiness. Ariana León would like to express her special thanks to her parents Concepción Sosa and Arturo León, and her sister Liz León for their unconditional love, support, and guidance throughout her life. Diego Barba thanked Fabián Quelal Naranjo, who collaborated with us in making the "Graphical Abstract", for his constant support and friendship; his parents Isabel Carrera and Diego F. Barba for their everlasting love and support; and all breast cancer patients for whom he works devotedly. Paulina Lugo thanks Marianita Soria, her mother; to José M. Aguirre M.D., her surgical mentor, and her patients, who are a source of inspiration to carry out a work with excellence and humanism. Andrés Caicedo expressed his gratitude to the Biomedical Discovery Team, to the Universidad San Francisco de Quito - USFQ and especially to his family María Luisa Páliz and Diego R. Caicedo, the greatest support he could ever have.

References

- [1] W H O. Breast cancer. World Health Organization 2020. <https://www.who.int/cancer/prevention/diagnosis-screening/breast-cancer/en/> (accessed April 17, 2020).
- [2] Surveillance, Epidemiology, and End Results (SEER) Program. Female Breast Cancer - Cancer Stat Facts. National Cancer Institute n.d. <https://seer.cancer.gov/statfacts/html/breast.html> (accessed April 10, 2019).
- [3] Rivera-Franco MM, Leon-Rodriguez E. Delays in breast cancer detection and treatment in developing countries. *Breast Cancer (Auckl)* 2018;12:1178223417752677. doi:10.1177/1178223417752677.
- [4] Qaseem A, Snow V, Sherif K, Aronson M, Weiss KB, Owens DK, et al. Screening mammography for women 40 to 49 years of age: a clinical practice guideline from the American College of Physicians. *Ann Intern Med* 2007;146:511–5.
- [5] Chetlen A, Mack J, Chan T. Breast cancer screening controversies: who, when, why, and how? *Clin Imaging* 2016;40:279–82. doi:10.1016/j.clinimag.2015.05.017.
- [6] Gradishar WJ, Anderson BO, Abraham J, Aft R, Agnese D, Allison KH, et al. Breast cancer, version 3.2020, NCCN clinical practice guidelines in oncology. *J Natl Compr Canc Netw* 2020;18:452–78. doi:10.6004/jnccn.2020.0016.
- [7] Bevers T, Helvie M, Bonaccio E, Calhoun K, Camp M, Daly M, et al. Breast cancer,

- version 1.2019, NCCN screening and diagnosis. *J Natl Compr Canc Netw* 2019.
- [8] Myers ER, Moorman P, Gierisch JM, Havrilesky LJ, Grimm LJ, Ghate S, et al. Benefits and harms of breast cancer screening: A systematic review. *JAMA* 2015;314:1615–34. doi:10.1001/jama.2015.13183.
- [9] Welch HG, Prorok PC, O'Malley AJ, Kramer BS. Breast-Cancer Tumor Size, Overdiagnosis, and Mammography Screening Effectiveness. *N Engl J Med* 2016;375:1438–47. doi:10.1056/NEJMoa1600249.
- [10] Fang S-Y, Chang H-T, Shu B-C. Objectified body consciousness, body image discomfort, and depressive symptoms among breast cancer survivors in taiwan. *Psychol Women Q* 2014;38:563–74. doi:10.1177/0361684314552652.
- [11] Dullum JR, Lewis EC, Mayer JA. Rates and correlates of discomfort associated with mammography. *Radiology* 2000;214:547–52. doi:10.1148/radiology.214.2.r00fe23547.
- [12] Aro AR, Absetz-Ylöstalo P, Eerola T, Pamiilo M, Lönnqvist J. Pain and discomfort during mammography. *Eur J Cancer* 1996;32A:1674–9. doi:10.1016/0959-8049(96)00140-2.
- [13] Mazzocco K, Masiero M, Carriero MC, Pravettoni G. The role of emotions in cancer patients' decision-making. *Ecancermedicalsecience* 2019;13:914. doi:10.3332/ecancer.2019.914.
- [14] Rutter DR, Calnan M, Vaile MS, Field S, Wade KA. Discomfort and pain during mammography: description, prediction, and prevention. *BMJ* 1992;305:443–5. doi:10.1136/bmj.305.6851.443.
- [15] Iezzoni LI, Kilbridge K, Park ER. Physical access barriers to care for diagnosis and treatment of breast cancer among women with mobility impairments. *Oncol Nurs Forum* 2010;37:711–7. doi:10.1188/10.ONF.711-717.
- [16] Poiseuil M, Coureau G, Payet C, Savès M, Debled M, Mathoulin-Pelissier S, et al. Deprivation and mass screening: Survival of women diagnosed with breast cancer in France from 2008 to 2010. *Cancer Epidemiol* 2019;60:149–55. doi:10.1016/j.canep.2019.03.016.
- [17] Claus EB, Schildkraut JM, Thompson WD, Risch NJ. The genetic attributable risk of breast and ovarian cancer. *Cancer* 1996;77:2318–24. doi:10.1002/(SICI)1097-0142(19960601)77:11<2318::AID-CNCR21>3.0.CO;2-Z.
- [18] Dagogo-Jack I, Shaw AT. Tumour heterogeneity and resistance to cancer therapies. *Nat Rev Clin Oncol* 2018;15:81–94. doi:10.1038/nrclinonc.2017.166.
- [19] Futschik ME, Morkel M, Schäfer R, Sers C. The Human Transcriptome. *Molecular Pathology*, Elsevier; 2018, p. 135–64. doi:10.1016/B978-0-12-802761-5.00007-9.
- [20] Katz G, Romano O, Foa C, Vataire A-L, Chantelard J-V, Hervé R, et al. Economic Impact of Gene Expression Profiling in Patients with Early-Stage Breast Cancer in France. *PLoS ONE* 2015;10:e0128880. doi:10.1371/journal.pone.0128880.
- [21] Özmen V, Çakar B, Gökmen E, Özdoğan M, Güler N, Uras C, et al. Cost effectiveness of Gene Expression Profiling in Patients with Early-Stage Breast Cancer in a Middle-

- Income Country, Turkey: Results of a Prospective Multicenter Study. *Eur J Breast Health* 2019;15:183–90. doi:10.5152/ejbh.2019.4761.
- [22] Generalov E, Clarke T, Iddamalagoda L, Sundararajan VS, Suravajhala P, Goltsov A. Systems biology in biomarker development for cancer signaling therapy. *Companion and complementary diagnostics*, Elsevier; 2019, p. 27–51. doi:10.1016/B978-0-12-813539-6.00003-1.
- [23] Guerrero S, López-Cortés A, Indacochea A, García-Cárdenas JM, Zambrano AK, Cabrera-Andrade A, et al. Analysis of racial/ethnic representation in select basic and applied cancer research studies. *Sci Rep* 2018;8:13978. doi:10.1038/s41598-018-32264-x.
- [24] de Souza JA, Hunt B, Asirwa FC, Adebamowo C, Lopes G. Global Health Equity: Cancer Care Outcome Disparities in High-, Middle-, and Low-Income Countries. *J Clin Oncol* 2016;34:6–13. doi:10.1200/JCO.2015.62.2860.
- [25] Ferlay J, Colombet M, Soerjomataram I, Mathers C, Parkin DM, Piñeros M, et al. Estimating the global cancer incidence and mortality in 2018: GLOBOCAN sources and methods. *Int J Cancer* 2019;144:1941–53. doi:10.1002/ijc.31937.
- [26] Liedtke C, Jackisch C, Thill M, Thomssen C, Müller V, Janni W, et al. AGO Recommendations for the Diagnosis and Treatment of Patients with Early Breast Cancer: Update 2018. *Breast Care (Basel)* 2018;13:196–208. doi:10.1159/000489329.
- [27] van Seijen M, Mooyaart AL, Mulder L, Hoogstraat M, Drukker CA, Loo CE, et al. Enrichment of high-grade tumors in breast cancer gene expression studies. *Breast Cancer Res Treat* 2018;168:327–35. doi:10.1007/s10549-017-4622-9.
- [28] Sasaki J, Geletzke A, Kass RB, Klimberg VS, Copeland EM, Bland KI. Etiology and management of benign breast disease. *The Breast*, Elsevier; 2018, p. 79-92.e5. doi:10.1016/B978-0-323-35955-9.00005-2.
- [29] Waldman RA, Finch J, Grant-Kels JM, Stevenson C, Whitaker-Worth D. Skin diseases of the breast and nipple: Benign and malignant tumors. *J Am Acad Dermatol* 2019;80:1467–81. doi:10.1016/j.jaad.2018.08.066.
- [30] Srivastava S, Ghosh S, Kagan J, Mazurchuk R, National Cancer Institute's HTAN Implementation. The making of a precancer atlas: promises, challenges, and opportunities. *Trends Cancer* 2018;4:523–36. doi:10.1016/j.trecan.2018.06.007.
- [31] Akram M, Iqbal M, Daniyal M, Khan AU. Awareness and current knowledge of breast cancer. *Biol Res* 2017;50:33. doi:10.1186/s40659-017-0140-9.
- [32] Geddes DT. Inside the lactating breast: the latest anatomy research. *J Midwifery Womens Health* 2007;52:556–63. doi:10.1016/j.jmwh.2007.05.004.
- [33] Hassiotou F, Geddes D. Anatomy of the human mammary gland: Current status of knowledge. *Clin Anat* 2013;26:29–48. doi:10.1002/ca.22165.
- [34] Pandya S, Moore RG. Breast development and anatomy. *Clin Obstet Gynecol* 2011;54:91–5. doi:10.1097/GRF.0b013e318207ffe9.
- [35] Bhateja V, Misra M, Urooj S. Breast cancer and mammographic anomalies. *Non-Linear*

- Filters for Mammogram Enhancement: A Robust Computer-aided Analysis Framework for Early Detection of Breast Cancer, vol. 861, Singapore: Springer Singapore; 2020, p. 9–20. doi:10.1007/978-981-15-0442-6_2.
- [36] Lee CI, Lehman CD, Bassett LW, editors. *Breast Imaging*. vol. 1. Oxford University Press; 2018. doi:10.1093/med/9780190270261.001.0001.
- [37] Huh SJ, Oh H, Peterson MA, Almendro V, Hu R, Bowden M, et al. The proliferative activity of mammary epithelial cells in normal tissue predicts breast cancer risk in premenopausal women. *Cancer Res* 2016;76:1926–34. doi:10.1158/0008-5472.CAN-15-1927.
- [38] Yuan W-H, Hsu H-C, Chen Y-Y, Wu C-H. Supplemental breast cancer-screening ultrasonography in women with dense breasts: a systematic review and meta-analysis. *Br J Cancer* 2020;123:673–88. doi:10.1038/s41416-020-0928-1.
- [39] C D C. What Does It Mean to Have Dense Breasts? . Centers for Disease Control and Prevention 2020. https://www.cdc.gov/cancer/breast/basic_info/dense-breasts.htm (accessed August 20, 2020).
- [40] Destounis SV, Santacroce A, Arieno A. Update on breast density, risk estimation, and supplemental screening. *AJR Am J Roentgenol* 2020;214:296–305. doi:10.2214/AJR.19.21994.
- [41] Feng Y, Spezia M, Huang S, Yuan C, Zeng Z, Zhang L, et al. Breast cancer development and progression: Risk factors, cancer stem cells, signaling pathways, genomics, and molecular pathogenesis. *Genes Dis* 2018;5:77–106. doi:10.1016/j.gendis.2018.05.001.
- [42] Lin X, Chen W, Wei F, Ying M, Wei W, Xie X. Night-shift work increases morbidity of breast cancer and all-cause mortality: a meta-analysis of 16 prospective cohort studies. *Sleep Med* 2015;16:1381–7. doi:10.1016/j.sleep.2015.02.543.
- [43] Stevens RG. Circadian disruption and breast cancer: from melatonin to clock genes. *Epidemiology* 2005;16:254–8.
- [44] Heitz AE, Baumgartner RN, Baumgartner KB, Boone SD. Healthy lifestyle impact on breast cancer-specific and all-cause mortality. *Breast Cancer Res Treat* 2018;167:171–81. doi:10.1007/s10549-017-4467-2.
- [45] Passarelli MN, Newcomb PA, Hampton JM, Trentham-Dietz A, Titus LJ, Egan KM, et al. Cigarette Smoking Before and After Breast Cancer Diagnosis: Mortality From Breast Cancer and Smoking-Related Diseases. *J Clin Oncol* 2016;34:1315–22. doi:10.1200/JCO.2015.63.9328.
- [46] Chajès V, Romieu I. Nutrition and breast cancer. *Maturitas* 2014;77:7–11. doi:10.1016/j.maturitas.2013.10.004.
- [47] Bamia C. Dietary patterns in association to cancer incidence and survival: concept, current evidence, and suggestions for future research. *Eur J Clin Nutr* 2018;72:818–25. doi:10.1038/s41430-018-0128-8.
- [48] Zitvogel L, Pietrocola F, Kroemer G. Nutrition, inflammation and cancer. *Nat Immunol*

- 2017;18:843–50. doi:10.1038/ni.3754.
- [49] Agnoli C, Grioni S, Pala V, Allione A, Matullo G, Gaetano CD, et al. Biomarkers of inflammation and breast cancer risk: a case-control study nested in the EPIC-Varese cohort. *Sci Rep* 2017;7:12708. doi:10.1038/s41598-017-12703-x.
- [50] Brown KA. Impact of obesity on mammary gland inflammation and local estrogen production. *J Mammary Gland Biol Neoplasia* 2014;19:183–9. doi:10.1007/s10911-014-9321-0.
- [51] Lee K, Kruper L, Dieli-Conwright CM, Mortimer JE. The impact of obesity on breast cancer diagnosis and treatment. *Curr Oncol Rep* 2019;21:41. doi:10.1007/s11912-019-0787-1.
- [52] Zumwalde NA, Haag JD, Sharma D, Mirrieles JA, Wilke LG, Gould MN, et al. Analysis of Immune Cells from Human Mammary Ductal Epithelial Organoids Reveals V δ 2+ T Cells That Efficiently Target Breast Carcinoma Cells in the Presence of Bisphosphonate. *Cancer Prev Res (Phila Pa)* 2016;9:305–16. doi:10.1158/1940-6207.CAPR-15-0370-T.
- [53] Xiao Y, Ma D, Zhao S, Suo C, Shi J, Xue M-Z, et al. Multi-Omics Profiling Reveals Distinct Microenvironment Characterization and Suggests Immune Escape Mechanisms of Triple-Negative Breast Cancer. *Clin Cancer Res* 2019;25:5002–14. doi:10.1158/1078-0432.CCR-18-3524.
- [54] Gil Del Alcazar CR, Alečković M, Polyak K. Immune Escape during Breast Tumor Progression. *Cancer Immunol Res* 2020;8:422–7. doi:10.1158/2326-6066.CIR-19-0786.
- [55] Aponte PM, Caicedo A. Stemness in cancer: stem cells, cancer stem cells, and their microenvironment. *Stem Cells Int* 2017;2017:5619472. doi:10.1155/2017/5619472.
- [56] Fortunato A, Boddy A, Mallo D, Aktipis A, Maley CC, Pepper JW. Natural selection in cancer biology: from molecular snowflakes to trait hallmarks. *Cold Spring Harb Perspect Med* 2017;7. doi:10.1101/cshperspect.a029652.
- [57] Hanahan D, Weinberg RA. Hallmarks of cancer: the next generation. *Cell* 2011;144:646–74. doi:10.1016/j.cell.2011.02.013.
- [58] Vogelstein B, Papadopoulos N, Velculescu VE, Zhou S, Diaz LA, Kinzler KW. Cancer genome landscapes. *Science* 2013;339:1546–58. doi:10.1126/science.1235122.
- [59] Dykes SS, Hughes VS, Wiggins JM, Fasanya HO, Tanaka M, Siemann D. Stromal cells in breast cancer as a potential therapeutic target. *Oncotarget* 2018;9:23761–79. doi:10.18632/oncotarget.25245.
- [60] Nwabo Kamdje AH, Kamga PT, Simo RT, Vecchio L, Seke Etet PF, Muller JM, et al. Mesenchymal stromal cells' role in tumor microenvironment: involvement of signaling pathways. *Cancer Biol Med* 2017;14:129–41. doi:10.20892/j.issn.2095-3941.2016.0033.
- [61] Caicedo A, Fritz V, Brondello J-M, Ayala M, Dennemont I, Abdellaoui N, et al. MitoCeption as a new tool to assess the effects of mesenchymal stem/stromal cell mitochondria on cancer cell metabolism and function. *Sci Rep* 2015;5:9073. doi:10.1038/srep09073.

- [62] Miliotis S, Nicolalde B, Ortega M, Yopez J, Caicedo A. Forms of extracellular mitochondria and their impact in health. *Mitochondrion* 2019;48:16–30. doi:10.1016/j.mito.2019.02.002.
- [63] Quail DF, Dannenberg AJ. The obese adipose tissue microenvironment in cancer development and progression. *Nat Rev Endocrinol* 2019;15:139–54. doi:10.1038/s41574-018-0126-x.
- [64] Gallo M, Frezzetti D, Roma C, Chicchinelli N, Barbieri A, Arra C, et al. RANTES and IL-6 cooperate in inducing a more aggressive phenotype in breast cancer cells. *Oncotarget* 2018;9:17543–53. doi:10.18632/oncotarget.24784.
- [65] Pearce OMT, Delaine-Smith RM, Maniati E, Nichols S, Wang J, Böhm S, et al. Deconstruction of a metastatic tumor microenvironment reveals a common matrix response in human cancers. *Cancer Discov* 2018;8:304–19. doi:10.1158/2159-8290.CD-17-0284.
- [66] Dongre A, Weinberg RA. New insights into the mechanisms of epithelial-mesenchymal transition and implications for cancer. *Nat Rev Mol Cell Biol* 2019;20:69–84. doi:10.1038/s41580-018-0080-4.
- [67] Kim H, Lin Q, Glazer PM, Yun Z. The hypoxic tumor microenvironment in vivo selects the cancer stem cell fate of breast cancer cells. *Breast Cancer Res* 2018;20:16. doi:10.1186/s13058-018-0944-8.
- [68] Keren L, Bosse M, Marquez D, Angoshtari R, Jain S, Varma S, et al. A Structured Tumor-Immune Microenvironment in Triple Negative Breast Cancer Revealed by Multiplexed Ion Beam Imaging. *Cell* 2018;174:1373-1387.e19. doi:10.1016/j.cell.2018.08.039.
- [69] Munn DH, Mellor AL. IDO in the Tumor Microenvironment: Inflammation, Counter-Regulation, and Tolerance. *Trends Immunol* 2016;37:193–207. doi:10.1016/j.it.2016.01.002.
- [70] Siska PJ, Rathmell JC. T cell metabolic fitness in antitumor immunity. *Trends Immunol* 2015;36:257–64. doi:10.1016/j.it.2015.02.007.
- [71] Thomas A, Routh ED, Pullikuth A, Jin G, Su J, Chou JW, et al. Tumor mutational burden is a determinant of immune-mediated survival in breast cancer. *Oncoimmunology* 2018;7:e1490854. doi:10.1080/2162402X.2018.1490854.
- [72] Wang M, Zhang C, Song Y, Wang Z, Wang Y, Luo F, et al. Mechanism of immune evasion in breast cancer. *Onco Targets Ther* 2017;10:1561–73. doi:10.2147/OTT.S126424.
- [73] Vallabhaneni KC, Penfornis P, Dhule S, Guillonneau F, Adams KV, Mo YY, et al. Extracellular vesicles from bone marrow mesenchymal stem/stromal cells transport tumor regulatory microRNA, proteins, and metabolites. *Oncotarget* 2015;6:4953–67. doi:10.18632/oncotarget.3211.
- [74] Rodriguez A-M, Nakhle J, Griessinger E, Vignais M-L. Intercellular mitochondria trafficking highlighting the dual role of mesenchymal stem cells as both sensors and

- rescuers of tissue injury. *Cell Cycle* 2018;17:712–21. doi:10.1080/15384101.2018.1445906.
- [75] Kalluri R. The biology and function of fibroblasts in cancer. *Nat Rev Cancer* 2016;16:582–98. doi:10.1038/nrc.2016.73.
- [76] Cohen N, Shani O, Raz Y, Sharon Y, Hoffman D, Abramovitz L, et al. Fibroblasts drive an immunosuppressive and growth-promoting microenvironment in breast cancer via secretion of Chitinase 3-like 1. *Oncogene* 2017;36:4457–68. doi:10.1038/onc.2017.65.
- [77] Shalpour S, Karin M. Immunity, inflammation, and cancer: an eternal fight between good and evil. *The Journal of Clinical Investigation* 2015.
- [78] Taniguchi K, Karin M. NF- κ B, inflammation, immunity and cancer: coming of age. *Nat Rev Immunol* 2018;18:309–24. doi:10.1038/nri.2017.142.
- [79] Salhab M, Al Sarakbi W, Mokbel K. The evolving role of the dynamic thermal analysis in the early detection of breast cancer. *Int Semin Surg Oncol* 2005;2:8. doi:10.1186/1477-7800-2-8.
- [80] Shaheed S-U, Tait C, Kyriacou K, Linforth R, Salhab M, Sutton C. Evaluation of nipple aspirate fluid as a diagnostic tool for early detection of breast cancer. *Clin Proteomics* 2018;15:3. doi:10.1186/s12014-017-9179-4.
- [81] Kaur RP, Vasudeva K, Singla H, Benipal RPS, Khetarpal P, Munshi A. Analysis of pro- and anti-inflammatory cytokine gene variants and serum cytokine levels as prognostic markers in breast cancer. *J Cell Physiol* 2018;233:9716–23. doi:10.1002/jcp.26901.
- [82] Skibinski A, Kuperwasser C. The origin of breast tumor heterogeneity. *Oncogene* 2015;34:5309–16. doi:10.1038/onc.2014.475.
- [83] Jafari SH, Saadatpour Z, Salmaninejad A, Momeni F, Mokhtari M, Nahand JS, et al. Breast cancer diagnosis: Imaging techniques and biochemical markers. *J Cell Physiol* 2018;233:5200–13. doi:10.1002/jcp.26379.
- [84] Valle A, Oliver J, Roca P. Role of uncoupling proteins in cancer. *Cancers (Basel)* 2010;2:567–91. doi:10.3390/cancers2020567.
- [85] Morais-Santos F, Granja S, Miranda-Gonçalves V, Moreira AHJ, Queirós S, Vilaça JL, et al. Targeting lactate transport suppresses in vivo breast tumour growth. *Oncotarget* 2015;6:19177–89. doi:10.18632/oncotarget.3910.
- [86] Lanning NJ, Castle JP, Singh SJ, Leon AN, Tovar EA, Sanghera A, et al. Metabolic profiling of triple-negative breast cancer cells reveals metabolic vulnerabilities. *Cancer Metab* 2017;5:6. doi:10.1186/s40170-017-0168-x.
- [87] Butti R, Das S, Gunasekaran VP, Yadav AS, Kumar D, Kundu GC. Receptor tyrosine kinases (RTKs) in breast cancer: signaling, therapeutic implications and challenges. *Mol Cancer* 2018;17:34. doi:10.1186/s12943-018-0797-x.
- [88] Martinez VG, Crown J, Porter RK, O’Driscoll L. Neuromedin U alters bioenergetics and expands the cancer stem cell phenotype in HER2-positive breast cancer. *Int J Cancer* 2017;140:2771–84. doi:10.1002/ijc.30705.
- [89] Kulkoyluoglu-Cotul E, Arca A, Madak-Erdogan Z. Crosstalk between Estrogen

- Signaling and Breast Cancer Metabolism. *Trends Endocrinol Metab* 2019;30:25–38. doi:10.1016/j.tem.2018.10.006.
- [90] Marini C, Ravera S, Buschiazzi A, Bianchi G, Orenzo AM, Bruno S, et al. Discovery of a novel glucose metabolism in cancer: The role of endoplasmic reticulum beyond glycolysis and pentose phosphate shunt. *Sci Rep* 2016;6:25092. doi:10.1038/srep25092.
- [91] Dai X, Xiang L, Li T, Bai Z. Cancer hallmarks, biomarkers and breast cancer molecular subtypes. *J Cancer* 2016;7:1281–94. doi:10.7150/jca.13141.
- [92] Semenza GL. The hypoxic tumor microenvironment: A driving force for breast cancer progression. *Biochim Biophys Acta* 2016;1863:382–91. doi:10.1016/j.bbamcr.2015.05.036.
- [93] Sansone P, Savini C, Kurelac I, Chang Q, Amato LB, Strillacci A, et al. Packaging and transfer of mitochondrial DNA via exosomes regulate escape from dormancy in hormonal therapy-resistant breast cancer. *Proc Natl Acad Sci USA* 2017;114:E9066–75. doi:10.1073/pnas.1704862114.
- [94] Oeffinger KC, Fontham ETH, Etzioni R, Herzig A, Michaelson JS, Shih Y-CT, et al. Breast cancer screening for women at average risk: 2015 guideline update from the american cancer society. *JAMA* 2015;314:1599–614. doi:10.1001/jama.2015.12783.
- [95] Mainiero MB, Moy L, Baron P, Didwania AD, diFlorio RM, Green ED, et al. ACR appropriateness criteria® breast cancer screening. *J Am Coll Radiol* 2017;14:S383–90. doi:10.1016/j.jacr.2017.08.044.
- [96] Schünemann HJ, Lerda D, Quinn C, Follmann M, Alonso-Coello P, Rossi PG, et al. Breast cancer screening and diagnosis: A synopsis of the european breast guidelines. *Ann Intern Med* 2020;172:46–56. doi:10.7326/M19-2125.
- [97] Cardoso F, Kyriakides S, Ohno S, Penault-Llorca F, Poortmans P, Rubio IT, et al. Early breast cancer: ESMO Clinical Practice Guidelines for diagnosis, treatment and follow-up†. *Ann Oncol* 2019;30:1194–220. doi:10.1093/annonc/mdz173.
- [98] Lee CH, Dershaw DD, Kopans D, Evans P, Monsees B, Monticciolo D, et al. Breast cancer screening with imaging: recommendations from the Society of Breast Imaging and the ACR on the use of mammography, breast MRI, breast ultrasound, and other technologies for the detection of clinically occult breast cancer. *J Am Coll Radiol* 2010;7:18–27. doi:10.1016/j.jacr.2009.09.022.
- [99] Siu AL, U.S. Preventive Services Task Force. Screening for breast cancer: U.S. preventive services task force recommendation statement. *Ann Intern Med* 2016;164:279–96. doi:10.7326/M15-2886.
- [100] Monticciolo DL, Newell MS, Moy L, Niell B, Monsees B, Sickles EA. Breast Cancer Screening in Women at Higher-Than-Average Risk: Recommendations From the ACR. *J Am Coll Radiol* 2018;15:408–14. doi:10.1016/j.jacr.2017.11.034.
- [101] Rahbar H, Lee JM, Lee CI. Optimal screening in breast cancer survivors with dense breasts on mammography. *J Clin Oncol* 2020;JCO2001641. doi:10.1200/JCO.20.01641.
- [102] Hassan LM, Mahmoud N, Miller AB, Iraj H, Mohsen M, Majid J, et al. Evaluation of

- effect of self-examination and physical examination on breast cancer. *Breast* 2015;24:487–90. doi:10.1016/j.breast.2015.04.011.
- [103] Sultania M, Kataria K, Srivastava A, Misra MC, Parshad R, Dhar A, et al. Validation of different techniques in physical examination of breast. *Indian J Surg* 2017;79:219–25. doi:10.1007/s12262-016-1470-5.
- [104] US Preventive Services Task Force. Screening for breast cancer: U.S. Preventive Services Task Force recommendation statement. *Ann Intern Med* 2009;151:716–26, W. doi:10.7326/0003-4819-151-10-200911170-00008.
- [105] Schwab FD, Huang DJ, Schmid SM, Schötzau A, Güth U. Self-detection and clinical breast examination: comparison of the two “classical” physical examination methods for the diagnosis of breast cancer. *Breast* 2015;24:90–2. doi:10.1016/j.breast.2014.11.008.
- [106] Løberg M, Lousdal ML, Bretthauer M, Kalager M. Benefits and harms of mammography screening. *Breast Cancer Res* 2015;17:63. doi:10.1186/s13058-015-0525-z.
- [107] Geisel J, Raghu M, Hooley R. The role of ultrasound in breast cancer screening: the case for and against ultrasound. *Semin Ultrasound CT MR* 2018;39:25–34. doi:10.1053/j.sult.2017.09.006.
- [108] Mandelson MT, Oestreicher N, Porter PL, White D, Finder CA, Taplin SH, et al. Breast density as a predictor of mammographic detection: comparison of interval- and screen-detected cancers. *J Natl Cancer Inst* 2000;92:1081–7. doi:10.1093/jnci/92.13.1081.
- [109] Bakker MF, de Lange SV, Pijnappel RM, Mann RM, Peeters PHM, Monninkhof EM, et al. Supplemental MRI Screening for Women with Extremely Dense Breast Tissue. *N Engl J Med* 2019;381:2091–102. doi:10.1056/NEJMoa1903986.
- [110] BCSC. Screening Mammography Sensitivity, Specificity, & False Negative Rate. Breast Cancer Surveillance Consortium (BCSC) 2017. <http://bcsc-research.org/> (accessed August 21, 2020).
- [111] Luczynska E. Comparison of degree of enhancement on Contrast-Enhanced Spectral Mammography (CESM) and lesion characteristics on Mammography (MG) based on lesion histology. *European Congress of Radiology* 2017. doi:10.1594/ecr2017/c-0831.
- [112] Helal M, Abu Samra MF, Ibraheem MA, Salama A, Hassan EE, Hassan NE-H. Accuracy of CESM versus conventional mammography and ultrasound in evaluation of BI-RADS 3 and 4 breast lesions with pathological correlation. *The Egyptian Journal of Radiology and Nuclear Medicine* 2017. doi:10.1016/j.ejrn.2017.03.004.
- [113] Smetherman DH. Screening, imaging, and image-guided biopsy techniques for breast cancer. *Surg Clin North Am* 2013;93:309–27. doi:10.1016/j.suc.2013.01.004.
- [114] Singh V, Saunders C, Wylie L, Bourke A. New diagnostic techniques for breast cancer detection. *Future Oncol* 2008;4:501–13. doi:10.2217/14796694.4.4.501.
- [115] Evans T, Burlton B, Devenish G, Stevens G, Lewis M, Gower Thomas K. A comparison of two digital mammography systems: are there any differences? *Clin Radiol* 2016;71:27–31. doi:10.1016/j.crad.2015.07.009.

- [116] Li J, Zhang H, Jiang H, Guo X, Zhang Y, Qi D, et al. Diagnostic Performance of Digital Breast Tomosynthesis for Breast Suspicious Calcifications From Various Populations: A Comparison With Full-field Digital Mammography. *Comput Struct Biotechnol J* 2019;17:82–9. doi:10.1016/j.csbj.2018.12.004.
- [117] Pisano ED, Gatsonis C, Hendrick E, Yaffe M, Baum JK, Acharyya S, et al. Diagnostic performance of digital versus film mammography for breast-cancer screening. *N Engl J Med* 2005;353:1773–83. doi:10.1056/NEJMoa052911.
- [118] Helvie MA. Digital mammography imaging: breast tomosynthesis and advanced applications. *Radiol Clin North Am* 2010;48:917–29. doi:10.1016/j.rcl.2010.06.009.
- [119] Gilbert FJ, Tucker L, Young KC. Digital breast tomosynthesis (DBT): a review of the evidence for use as a screening tool. *Clin Radiol* 2016;71:141–50. doi:10.1016/j.crad.2015.11.008.
- [120] Tagliafico A, Mariscotti G, Durando M, Stevanin C, Tagliafico G, Martino L, et al. Characterisation of microcalcification clusters on 2D digital mammography (FFDM) and digital breast tomosynthesis (DBT): does DBT underestimate microcalcification clusters? Results of a multicentre study. *Eur Radiol* 2015;25:9–14. doi:10.1007/s00330-014-3402-8.
- [121] Baltzer PAT, Kapetas P, Marino MA, Clauser P. New diagnostic tools for breast cancer. *Memo* 2017;10:175–80. doi:10.1007/s12254-017-0341-5.
- [122] Borgstede JP, Bagrosky BM. Screening of High-Risk Patients. Early diagnosis and treatment of cancer series: breast cancer, Elsevier; 2011, p. 141–9. doi:10.1016/B978-1-4160-4932-6.50014-7.
- [123] Lowry KP, Trentham-Dietz A, Schechter CB, Alagoz O, Barlow WE, Burnside ES, et al. Long-Term Outcomes and Cost-Effectiveness of Breast Cancer Screening With Digital Breast Tomosynthesis in the United States. *J Natl Cancer Inst* 2020;112:582–9. doi:10.1093/jnci/djz184.
- [124] Gennaro G, Toledano A, di Maggio C, Baldan E, Bezzon E, La Grassa M, et al. Digital breast tomosynthesis versus digital mammography: a clinical performance study. *Eur Radiol* 2010;20:1545–53. doi:10.1007/s00330-009-1699-5.
- [125] Svahn TM, Chakraborty DP, Ikeda D, Zackrisson S, Do Y, Mattsson S, et al. Breast tomosynthesis and digital mammography: a comparison of diagnostic accuracy. *Br J Radiol* 2012;85:e1074-82. doi:10.1259/bjr/53282892.
- [126] Sehgal CM, Weinstein SP, Arger PH, Conant EF. A review of breast ultrasound. *J Mammary Gland Biol Neoplasia* 2006;11:113–23. doi:10.1007/s10911-006-9018-0.
- [127] Bick U, Trimboli RM, Athanasiou A, Balleyguier C, Baltzer PAT, Bernathova M, et al. Image-guided breast biopsy and localisation: recommendations for information to women and referring physicians by the European Society of Breast Imaging. *Insights Imaging* 2020;11:12. doi:10.1186/s13244-019-0803-x.
- [128] James TA, Harlow S, Sheehy-Jones J, Hart M, Gaspari C, Stanley M, et al. Intraoperative ultrasound versus mammographic needle localization for ductal

- carcinoma in situ. *Ann Surg Oncol* 2009;16:1164–9. doi:10.1245/s10434-009-0388-6.
- [129] Daly CP, Bailey JE, Klein KA, Helvie MA. Complicated breast cysts on sonography: is aspiration necessary to exclude malignancy? *Acad Radiol* 2008;15:610–7. doi:10.1016/j.acra.2007.12.018.
- [130] Zanello PA, Robim AFC, Oliveira TMG de, Elias Junior J, Andrade JM de, Monteiro CR, et al. Breast ultrasound diagnostic performance and outcomes for mass lesions using Breast Imaging Reporting and Data System category 0 mammogram. *Clinics (Sao Paulo)* 2011;66:443–8. doi:10.1590/s1807-59322011000300014.
- [131] Berg WA, Blume JD, Cormack JB, Mendelson EB, Lehrer D, Böhm-Vélez M, et al. Combined screening with ultrasound and mammography vs mammography alone in women at elevated risk of breast cancer. *JAMA* 2008;299:2151–63. doi:10.1001/jama.299.18.2151.
- [132] Hooley RJ, Greenberg KL, Stackhouse RM, Geisel JL, Butler RS, Philpotts LE. Screening US in patients with mammographically dense breasts: initial experience with Connecticut Public Act 09-41. *Radiology* 2012;265:59–69. doi:10.1148/radiol.12120621.
- [133] Scheel JR, Lee JM, Sprague BL, Lee CI, Lehman CD. Screening ultrasound as an adjunct to mammography in women with mammographically dense breasts. *Am J Obstet Gynecol* 2015;212:9–17. doi:10.1016/j.ajog.2014.06.048.
- [134] He H, Plaxco JS, Wei W, Huo L, Candelaria RP, Kuerer HM, et al. Incremental cancer detection using breast ultrasonography versus breast magnetic resonance imaging in the evaluation of newly diagnosed breast cancer patients. *Br J Radiol* 2016;89:20160401. doi:10.1259/bjr.20160401.
- [135] Morris EA. Breast cancer imaging with MRI. *Radiol Clin North Am* 2002;40:443–66. doi:10.1016/S0033-8389(01)00005-7.
- [136] Mann RM, Balleyguier C, Baltzer PA, Bick U, Colin C, Cornford E, et al. Breast MRI: EUSOBI recommendations for women's information. *Eur Radiol* 2015;25:3669–78. doi:10.1007/s00330-015-3807-z.
- [137] Cheng Y-C, Wu N-Y, Ko JS, Lin P-W, Lin W-C, Juang S-J, et al. Breast cancers detected by breast MRI screening and ultrasound in asymptomatic Asian women: 8 years of experience in Taiwan. *Oncology* 2012;82:98–107. doi:10.1159/000335958.
- [138] Schelfout K, Van Goethem M, Kersschot E, Colpaert C, Schelfhout AM, Leyman P, et al. Contrast-enhanced MR imaging of breast lesions and effect on treatment. *Eur J Surg Oncol* 2004;30:501–7. doi:10.1016/j.ejso.2004.02.003.
- [139] Kuhl CK. Abbreviated magnetic resonance imaging (MRI) for breast cancer screening: rationale, concept, and transfer to clinical practice. *Annu Rev Med* 2019;70:501–19. doi:10.1146/annurev-med-121417-100403.
- [140] Greene LR, Wilkinson D. The role of general nuclear medicine in breast cancer. *J Med Radiat Sci* 2015;62:54–65. doi:10.1002/jmrs.97.
- [141] Groheux D, Cochet A, Humbert O, Alberini J-L, Hindié E, Mankoff D. ¹⁸F-FDG

- PET/CT for Staging and Restaging of Breast Cancer. *J Nucl Med* 2016;57 Suppl 1:17S-26S. doi:10.2967/jnumed.115.157859.
- [142] Cazzato RL, Garnon J, Shaygi B, Koch G, Tsoumakidou G, Caudrelier J, et al. PET/CT-guided interventions: Indications, advantages, disadvantages and the state of the art. *Minim Invasive Ther Allied Technol* 2018;27:27–32. doi:10.1080/13645706.2017.1399280.
- [143] Bland KI, Klimberg VS. Master techniques in surgery: breast surgery. *Master Techniques in Surgery: Breast Surgery* 2018.
- [144] van Uden DJP, van Laarhoven HWM, Westenberg AH, de Wilt JHW, Blanken-Peeters CFJM. Inflammatory breast cancer: an overview. *Crit Rev Oncol Hematol* 2015;93:116–26. doi:10.1016/j.critrevonc.2014.09.003.
- [145] Wahl RL, Siegel BA, Coleman RE, Gatsonis CG, PET Study Group. Prospective multicenter study of axillary nodal staging by positron emission tomography in breast cancer: a report of the staging breast cancer with PET Study Group. *J Clin Oncol* 2004;22:277–85. doi:10.1200/JCO.2004.04.148.
- [146] Mankoff DA, Gralow JR. 3–12 The Role of FDG-PET/CT in Suspected Recurrence of Breast Cancer. *Breast Diseases: A Year Book Quarterly* 2007;18:251–2. doi:10.1016/S1043-321X(07)80306-7.
- [147] Yadav S, Barton MJ, Nguyen N-T. Biophysical properties of cells for cancer diagnosis. *J Biomech* 2019;86:1–7. doi:10.1016/j.jbiomech.2019.02.006.
- [148] Lozano A, Hayes JC, Compton LM, Azarnoosh J, Hassanipour F. Determining the thermal characteristics of breast cancer based on high-resolution infrared imaging, 3D breast scans, and magnetic resonance imaging. *Sci Rep* 2020;10:10105. doi:10.1038/s41598-020-66926-6.
- [149] Hakim A, Awale RN. Thermal Imaging - An Emerging Modality for Breast Cancer Detection: A Comprehensive Review. *J Med Syst* 2020;44:136. doi:10.1007/s10916-020-01581-y.
- [150] Laila Fadhilah UD, Nur Afikah ZA, Safiee NEN, Asnida AW, Mohammed Rafiq AK, Ramlee MH. Development of A Low-Cost Wearable Breast Cancer Detection Device. 2018 2nd International Conference on BioSignal Analysis, Processing and Systems (ICBAPS), IEEE; 2018, p. 41–6. doi:10.1109/ICBAPS.2018.8527419.
- [151] Ntziachristos V, Chance B. Breast imaging technology: Probing physiology and molecular function using optical imaging - applications to breast cancer. *Breast Cancer Res* 2000;3:41. doi:10.1186/bcr269.
- [152] Luker GD, Luker KE. Optical imaging: current applications and future directions. *J Nucl Med* 2008;49:1–4. doi:10.2967/jnumed.107.045799.
- [153] Pirovano G, Roberts S, Kossatz S, Reiner T. Optical imaging modalities: principles and applications in preclinical research and clinical settings. *J Nucl Med* 2020. doi:10.2967/jnumed.119.238279.
- [154] Elson DS. Optical imaging. *Bioengineering innovative solutions for cancer*, Elsevier;

- 2020, p. 95–122. doi:10.1016/B978-0-12-813886-1.00002-4.
- [155] NIBIB. Optical Imaging. National Institute of Biomedical Imaging and Bioengineering 2016. <https://www.nibib.nih.gov/science-education/science-topics/optical-imaging#pid-1231> (accessed August 21, 2020).
- [156] Grosenick D, Rinneberg H, Cubeddu R, Taroni P. Review of optical breast imaging and spectroscopy. *J Biomed Opt* 2016;21:091311. doi:10.1117/1.JBO.21.9.091311.
- [157] Grosenick D, Wabnitz H, Moesta KT, Mucke J, Schlag PM, Rinneberg H. Time-domain scanning optical mammography: II. Optical properties and tissue parameters of 87 carcinomas. *Phys Med Biol* 2005;50:2451–68. doi:10.1088/0031-9155/50/11/002.
- [158] Spinelli L, Torricelli A, Pifferi A, Taroni P, Danesini G, Cubeddu R. Characterization of female breast lesions from multi-wavelength time-resolved optical mammography. *Phys Med Biol* 2005;50:2489–502. doi:10.1088/0031-9155/50/11/004.
- [159] Cerussi A, Shah N, Hsiang D, Durkin A, Butler J, Tromberg BJ. In vivo absorption, scattering, and physiologic properties of 58 malignant breast tumors determined by broadband diffuse optical spectroscopy. *J Biomed Opt* 2006;11:044005. doi:10.1117/1.2337546.
- [160] Fournier LS, Vanel D, Athanasiou A, Gatzemeier W, Masuykov IV, Padhani AR, et al. Dynamic optical breast imaging: a novel technique to detect and characterize tumor vessels. *Eur J Radiol* 2009;69:43–9. doi:10.1016/j.ejrad.2008.07.038.
- [161] Xu RX, Young DC, Mao JJ, Povoski SP. A prospective pilot clinical trial evaluating the utility of a dynamic near-infrared imaging device for characterizing suspicious breast lesions. *Breast Cancer Res* 2007;9:R88. doi:10.1186/bcr1837.
- [162] Mainiero MB, Lourenco A, Mahoney MC, Newell MS, Bailey L, Barke LD, et al. ACR appropriateness criteria breast cancer screening. *J Am Coll Radiol* 2013;10:11–4. doi:10.1016/j.jacr.2012.09.036.
- [163] Vreugdenburg TD, Willis CD, Mundy L, Hiller JE. A systematic review of elastography, electrical impedance scanning, and digital infrared thermography for breast cancer screening and diagnosis. *Breast Cancer Res Treat* 2013;137:665–76. doi:10.1007/s10549-012-2393-x.
- [164] Kennedy DA, Lee T, Seely D. A comparative review of thermography as a breast cancer screening technique. *Integr Cancer Ther* 2009;8:9–16. doi:10.1177/1534735408326171.
- [165] Stolz G. Numerical solutions to an inverse problem of heat conduction for simple shapes. *J Heat Transfer* 1960;82:20–5. doi:10.1115/1.3679871.
- [166] Liang XG, Ge XS, Zhang YP, Wang GJ. A convenient method of measuring the thermal conductivity of biological tissue. *Phys Med Biol* 1991;36:1599–605. doi:10.1088/0031-9155/36/12/005.
- [167] Kontos M, Wilson R, Fentiman I. Digital infrared thermal imaging (DITI) of breast lesions: sensitivity and specificity of detection of primary breast cancers. *Clin Radiol* 2011;66:536–9. doi:10.1016/j.crad.2011.01.009.

- [168] Arora N, Martins D, Ruggerio D, Tousimis E, Swistel AJ, Osborne MP, et al. Effectiveness of a noninvasive digital infrared thermal imaging system in the detection of breast cancer. *Am J Surg* 2008;196:523–6. doi:10.1016/j.amjsurg.2008.06.015.
- [169] Lashkari A, Pak F, Firouzmand M. Full intelligent cancer classification of thermal breast images to assist physician in clinical diagnostic applications. *J Med Signals Sens* 2016;6:12–24.
- [170] F D A. FDA Warns Thermography Should Not Be Used in Place of Mammography to Detect, Diagnose, or Screen for Breast Cancer: FDA Safety Communication. US Food & Drug Administration 2019. <https://www.fda.gov/medical-devices/safety-communications/fda-warns-thermography-should-not-be-used-place-mammography-detect-diagnose-or-screen-breast-cancer> (accessed July 23, 2019).
- [171] Covington MF, Pizzitola VJ, Lorans R, Pockaj BA, Northfelt DW, Appleton CM, et al. The Future of Contrast-Enhanced Mammography. *AJR Am J Roentgenol* 2018;210:292–300. doi:10.2214/AJR.17.18749.
- [172] Phillips J, Fein-Zachary VJ, Slanetz PJ. Pearls and Pitfalls of Contrast-Enhanced Mammography. *J Breast Imaging* 2019;1:64–72. doi:10.1093/jbi/wby013.
- [173] Gilbert FJ, Pinker-Domenig K. Diagnosis and Staging of Breast Cancer: When and How to Use Mammography, Tomosynthesis, Ultrasound, Contrast-Enhanced Mammography, and Magnetic Resonance Imaging. In: Hodler J, Kubik-Huch RA, von Schulthess GK, editors. *Diseases of the Chest, Breast, Heart and Vessels 2019-2022: Diagnostic and Interventional Imaging*, Cham (CH): Springer; 2019. doi:10.1007/978-3-030-11149-6_13.
- [174] Cozzi A, Schiaffino S, Sardanelli F. The emerging role of contrast-enhanced mammography. *Quant Imaging Med Surg* 2019;9:2012–8. doi:10.21037/qims.2019.11.09.
- [175] Mokhtar O, Mahmoud S. Can contrast enhanced mammography solve the problem of dense breast lesions? *The Egyptian Journal of Radiology and Nuclear Medicine* 2014;45:1043–52. doi:10.1016/j.ejrnm.2014.04.007.
- [176] Lobbes MBI, Lalji U, Houwers J, Nijssen EC, Nelemans PJ, van Roozendaal L, et al. Contrast-enhanced spectral mammography in patients referred from the breast cancer screening programme. *Eur Radiol* 2014;24:1668–76. doi:10.1007/s00330-014-3154-5.
- [177] Perry H, Phillips J, Dialani V, Slanetz PJ, Fein-Zachary VJ, Karimova EJ, et al. Contrast-Enhanced Mammography: A Systematic Guide to Interpretation and Reporting. *AJR Am J Roentgenol* 2019;212:222–31. doi:10.2214/AJR.17.19265.
- [178] Berg WA. Nuclear breast imaging: clinical results and future directions. *J Nucl Med* 2016;57 Suppl 1:46S-52S. doi:10.2967/jnumed.115.157891.
- [179] American College of Radiology. ACR practice parameter for the performance of magnetic resonance imaging-guided breast interventional procedures. 2016 2016.
- [180] Mettler FA, Huda W, Yoshizumi TT, Mahesh M. Effective doses in radiology and diagnostic nuclear medicine: a catalog. *Radiology* 2008;248:254–63.

- doi:10.1148/radiol.2481071451.
- [181] Heydarheydari S, Rezaeijo SM, Cheki M, Khodamoradi E, Khoshgard K. Diagnostic Efficacy of Technetium-99m-Sestamibi Scintimammography in Comparison with Mammography to Detect Breast Lesions: A Systematic Review. *Archives of Breast Cancer* 2018.
- [182] Guo C, Zhang C, Liu J, Tong L, Huang G. Is Tc-99m sestamibi scintimammography useful in the prediction of neoadjuvant chemotherapy responses in breast cancer? A systematic review and meta-analysis. *Nucl Med Commun* 2016;37:675–88. doi:10.1097/MNM.0000000000000502.
- [183] Silverstein MJ, Lagios MD, Recht A, Allred DC, Harms SE, Holland R, et al. Image-detected breast cancer: state of the art diagnosis and treatment. *J Am Coll Surg* 2005;201:586–97. doi:10.1016/j.jamcollsurg.2005.05.032.
- [184] Alauddin MM, Khawli LA. Advances in Immuno-PET in the Detection of Cancer and Assessment of Response to Therapy. *Curr Med Chem* 2020. doi:10.2174/0929867327666200128102958.
- [185] Zhang J, Knopp MV, editors. *Advances in PET: the latest in instrumentation, technology, and clinical practice*. Cham: Springer International Publishing; 2020. doi:10.1007/978-3-030-43040-5.
- [186] Signore A, Lauri C, Auletta S, Varani M, Onofrio L, Glaudemans AWJM, et al. Radiopharmaceuticals for breast cancer and neuroendocrine tumors: two examples of how tissue characterization may influence the choice of therapy. *Cancers (Basel)* 2020;12. doi:10.3390/cancers12040781.
- [187] Jodłowska E, Czepczyński R, Czarnywojtek A, Rewers A, Jarząbek G, Kędzia W, et al. The application of positron emission tomography (PET/CT) in diagnosis of breast cancer. Part II. Diagnosis after treatment initiation, future perspectives. *Contemp Oncol (Pozn)* 2016;20:205–9. doi:10.5114/wo.2016.61560.
- [188] van Kruchten M, Glaudemans AWJM, de Vries EFJ, Beets-Tan RGH, Schröder CP, Dierckx RA, et al. PET imaging of estrogen receptors as a diagnostic tool for breast cancer patients presenting with a clinical dilemma. *J Nucl Med* 2012;53:182–90. doi:10.2967/jnumed.111.092734.
- [189] Stergiou N, Nagel J, Pektor S, Heimes A-S, Jäkel J, Brenner W, et al. Evaluation of a novel monoclonal antibody against tumor-associated MUC1 for diagnosis and prognosis of breast cancer. *Int J Med Sci* 2019;16:1188–98. doi:10.7150/ijms.35452.
- [190] Mariappan YK, Glaser KJ, Ehman RL. Magnetic resonance elastography: a review. *Clin Anat* 2010;23:497–511. doi:10.1002/ca.21006.
- [191] Sinkus R, Tanter M, Xydeas T, Catheline S, Bercoff J, Fink M. Viscoelastic shear properties of in vivo breast lesions measured by MR elastography. *Magn Reson Imaging* 2005;23:159–65. doi:10.1016/j.mri.2004.11.060.
- [192] Litwiller DV, Mariappan YK, Ehman RL. Magnetic Resonance Elastography. *Curr Med Imaging Rev* 2012;8:46–55. doi:10.2174/157340512799220562.

- [193] Solamen LM, McGarry MD, Tan L, Weaver JB, Paulsen KD. Phantom evaluations of nonlinear inversion MR elastography. *Phys Med Biol* 2018;63:145021. doi:10.1088/1361-6560/aacb08.
- [194] Joy JE, Penhoet EE, Petitti DB. Breast cancer technology overview. *Saving Women's Lives: Strategies for Improving Breast Cancer Detection and Diagnosis* 2005.
- [195] Sinkus R, Siegmann K, Xydeas T, Tanter M, Claussen C, Fink M. MR elastography of breast lesions: understanding the solid/liquid duality can improve the specificity of contrast-enhanced MR mammography. *Magn Reson Med* 2007;58:1135–44. doi:10.1002/mrm.21404.
- [196] Siegmann KC, Xydeas T, Sinkus R, Kraemer B, Vogel U, Claussen CD. Diagnostic value of MR elastography in addition to contrast-enhanced MR imaging of the breast-initial clinical results. *Eur Radiol* 2010;20:318–25. doi:10.1007/s00330-009-1566-4.
- [197] Hawley JR, Kalra P, Mo X, Raterman B, Yee LD, Kolipaka A. Quantification of breast stiffness using MR elastography at 3 Tesla with a soft sternal driver: A reproducibility study. *J Magn Reson Imaging* 2017;45:1379–84. doi:10.1002/jmri.25511.
- [198] Palmeri ML, Frinkley KD, Zhai L, Gottfried M, Bentley RC, Ludwig K, et al. Acoustic radiation force impulse (ARFI) imaging of the gastrointestinal tract. *Ultrason Imaging* 2005;27:75–88. doi:10.1177/016173460502700202.
- [199] Jayaraman J, Indiran V, Kannan K, Maduraimuthu P. Acoustic radiation force impulse imaging in benign and malignant breast lesions. *Cureus* 2017;9:e1301. doi:10.7759/cureus.1301.
- [200] Kapetas P, Pinker-Domenig K, Woitek R, Clauser P, Bernathova M, Spick C, et al. Clinical application of Acoustic Radiation Force Impulse Imaging with Virtual Touch IQ in breast ultrasound: diagnostic performance and reproducibility of a new technique. *Acta Radiol* 2017;58:140–7. doi:10.1177/0284185116641347.
- [201] Nightingale K. Acoustic radiation force impulse (ARFI) imaging: a review. *Curr Med Imaging Rev* 2011;7:328–39. doi:10.2174/157340511798038657.
- [202] Lin Y-H, Yeh M-L, Huang C-I, Yang J-F, Liang P-C, Huang C-F, et al. The performance of acoustic radiation force impulse imaging in predicting liver fibrosis in chronic liver diseases. *Kaohsiung J Med Sci* 2016;32:362–6. doi:10.1016/j.kjms.2016.05.008.
- [203] Chilla GS, Tan CH, Xu C, Poh CL. Diffusion weighted magnetic resonance imaging and its recent trend-a survey. *Quant Imaging Med Surg* 2015;5:407–22. doi:10.3978/j.issn.2223-4292.2015.03.01.
- [204] Partridge SC, Nissan N, Rahbar H, Kitsch AE, Sigmund EE. Diffusion-weighted breast MRI: Clinical applications and emerging techniques. *J Magn Reson Imaging* 2017;45:337–55. doi:10.1002/jmri.25479.
- [205] Bickel H, Pinker-Domenig K, Bogner W, Spick C, Bagó-Horváth Z, Weber M, et al. Quantitative apparent diffusion coefficient as a noninvasive imaging biomarker for the differentiation of invasive breast cancer and ductal carcinoma in situ. *Invest Radiol*

- 2015;50:95–100. doi:10.1097/RLI.0000000000000104.
- [206] Padhani AR, Liu G, Koh DM, Chenevert TL, Thoeny HC, Takahara T, et al. Diffusion-weighted magnetic resonance imaging as a cancer biomarker: consensus and recommendations. *Neoplasia* 2009;11:102–25. doi:10.1593/neo.81328.
- [207] Richard R, Thomassin I, Chapellier M, Scemama A, de Cremoux P, Varna M, et al. Diffusion-weighted MRI in pretreatment prediction of response to neoadjuvant chemotherapy in patients with breast cancer. *Eur Radiol* 2013;23:2420–31. doi:10.1007/s00330-013-2850-x.
- [208] Zielinski J, Jaworski R, Irga-Jaworska N, Haponiuk I, Jaskiewicz J. The significance of ductoscopy of mammary ducts in the diagnostics of breast neoplasms. *Wideochir Inne Tech Malo Inwazyjne* 2015;10:79–86. doi:10.5114/wiitm.2014.46823.
- [209] Mokbel K, Escobar PF, Matsunaga T. Mammary ductoscopy: current status and future prospects. *Eur J Surg Oncol* 2005;31:3–8. doi:10.1016/j.ejso.2004.10.004.
- [210] Valdes EK, Boolbol SK, Cohen J-M, Balassanian R, Feldman SM. Clinical experience with mammary ductoscopy. *Ann Surg Oncol* 2016;23:9015–9. doi:10.1245/ASO.2006.08.025.
- [211] Han Y, Li J, Han S, Jia S, Zhang Y, Zhang W. Diagnostic value of endoscopic appearance during ductoscopy in patients with pathological nipple discharge. *BMC Cancer* 2017;17:300. doi:10.1186/s12885-017-3288-3.
- [212] Liu G-Y, Lu J-S, Shen K-W, Wu J, Chen C-M, Hu Z, et al. Fiberoptic ductoscopy combined with cytology testing in the patients of spontaneous nipple discharge. *Breast Cancer Res Treat* 2008;108:271–7. doi:10.1007/s10549-007-9598-4.
- [213] Dooley WC, Ljung BM, Veronesi U, Cazzaniga M, Elledge RM, O’Shaughnessy JA, et al. Ductal lavage for detection of cellular atypia in women at high risk for breast cancer. *J Natl Cancer Inst* 2001;93:1624–32. doi:10.1093/jnci/93.21.1624.
- [214] De Censi A, Cazzaniga M, Casadio C, Chiapparini L, Gandini S, Guerrieri-Gonzaga A, et al. Association of atypia in ductal lavage and breast cancer risk. *J Clin Oncol* 2017;35:e13040–e13040. doi:10.1200/JCO.2017.35.15_suppl.e13040.
- [215] Matos Do Canto L, Marian C, Varghese RS, Ahn J, Da Cunha PA, Willey S, et al. Metabolomic profiling of breast tumors using ductal fluid. *Int J Oncol* 2016;49:2245–54. doi:10.3892/ijo.2016.3732.
- [216] Waaijer L, Simons JM, Borel Rinkes IHM, van Diest PJ, Verkooijen HM, Witkamp AJ. Systematic review and meta-analysis of the diagnostic accuracy of ductoscopy in patients with pathological nipple discharge. *Br J Surg* 2016;103:632–43. doi:10.1002/bjs.10125.
- [217] Gillies RJ, Kinahan PE, Hricak H. Radiomics: Images Are More than Pictures, They Are Data. *Radiology* 2016;278:563–77. doi:10.1148/radiol.2015151169.
- [218] Valdora F, Houssami N, Rossi F, Calabrese M, Tagliafico AS. Rapid review: radiomics and breast cancer. *Breast Cancer Res Treat* 2018;169:217–29. doi:10.1007/s10549-018-4675-4.

- [219] Tran WT, Jerzak K, Lu F-I, Klein J, Tabbarah S, Lagree A, et al. Personalized breast cancer treatments using artificial intelligence in radiomics and pathomics. *J Med Imaging Radiat Sci* 2019;50:S32–41. doi:10.1016/j.jmir.2019.07.010.
- [220] Conti A, Duggento A, Indovina I, Guerrisi M, Toschi N. Radiomics in breast cancer classification and prediction. *Semin Cancer Biol* 2020. doi:10.1016/j.semcancer.2020.04.002.
- [221] Crivelli P, Ledda RE, Parascandolo N, Fara A, Soro D, Conti M. A new challenge for radiologists: radiomics in breast cancer. *Biomed Res Int* 2018;2018:6120703. doi:10.1155/2018/6120703.
- [222] Tagliafico AS, Piana M, Schenone D, Lai R, Massone AM, Houssami N. Overview of radiomics in breast cancer diagnosis and prognostication. *Breast* 2020;49:74–80. doi:10.1016/j.breast.2019.10.018.
- [223] Zhang Q, Xiao Y, Suo J, Shi J, Yu J, Guo Y, et al. Sonoelastomics for Breast Tumor Classification: A Radiomics Approach with Clustering-Based Feature Selection on Sonoelastography. *Ultrasound Med Biol* 2017;43:1058–69. doi:10.1016/j.ultrasmedbio.2016.12.016.
- [224] Li H, Zhu Y, Burnside ES, Drukker K, Hoadley KA, Fan C, et al. MR imaging radiomics signatures for predicting the risk of breast cancer recurrence as given by research versions of mammaprint, oncotype DX, and PAM50 gene assays. *Radiology* 2016;281:382–91. doi:10.1148/radiol.2016152110.
- [225] Javaid M, Haleem A. Industry 4.0 applications in medical field: A brief review. *Current Medicine Research and Practice* 2019;9:102–9. doi:10.1016/j.cmrp.2019.04.001.
- [226] Chen W, Ray S, Bhadra J, Abadir M, Wang L-C. Challenges and trends in modern soc design verification. *IEEE Des Test* 2017;34:7–22. doi:10.1109/MDAT.2017.2735383.
- [227] Alfred R. The rise of machine learning for big data analytics. 2016 2nd International Conference on Science in Information Technology (ICSITech), IEEE; 2016, p. 1–1. doi:10.1109/ICSITech.2016.7852593.
- [228] Blakeman V, Williams JL, Meng Q-J, Streuli CH. Circadian clocks and breast cancer. *Breast Cancer Res* 2016;18:89. doi:10.1186/s13058-016-0743-z.
- [229] Jordan MI, Mitchell TM. Machine learning: Trends, perspectives, and prospects. *Science* 2015;349:255–60. doi:10.1126/science.aaa8415.
- [230] Teng F, Cormier T, Sauer-Budge A, Chaudhury R, Pera V, Istfan R, et al. Wearable near-infrared optical probe for continuous monitoring during breast cancer neoadjuvant chemotherapy infusions. *J Biomed Opt* 2017;22:14001. doi:10.1117/1.JBO.22.1.014001.
- [231] Bezerra LA, Oliveira MM, Rolim TL, Conci A, Santos FGS, Lyra PRM, et al. Estimation of breast tumor thermal properties using infrared images. *Signal Processing* 2013;93:2851–63. doi:10.1016/j.sigpro.2012.06.002.
- [232] Enander B, Larson G. Microwave radiometric measurements of the temperature inside a body. *Electron Lett* 1974;10:317. doi:10.1049/el:19740250.
- [233] IET Digital Library: IEE Proceedings A (Physical Science, Measurement and

- Instrumentation, Management and Education, Reviews) 1987. <https://digital-library.theiet.org/content/journals/ip-a-1/134/2> (accessed April 15, 2020).
- [234] Dankoco MD, Tesfay GY, Benevent E, Bendahan M. Temperature sensor realized by inkjet printing process on flexible substrate. *Materials Science and Engineering: B* 2016;205:1–5. doi:10.1016/j.mseb.2015.11.003.
- [235] Elmore JG, Longton GM, Carney PA, Geller BM, Onega T, Tosteson ANA, et al. Diagnostic concordance among pathologists interpreting breast biopsy specimens. *JAMA* 2015;313:1122–32. doi:10.1001/jama.2015.1405.
- [236] Buono G, Gerratana L, Bulfoni M, Provinciali N, Basile D, Giuliano M, et al. Circulating tumor DNA analysis in breast cancer: Is it ready for prime-time? *Cancer Treat Rev* 2019;73:73–83. doi:10.1016/j.ctrv.2019.01.004.
- [237] Bui MM, Dodd LG. *Atlas of Soft Tissue and Bone Pathology*. Atlas of Soft Tissue and Bone Pathology 2014.
- [238] Mango VL, D'Alessio D, Morris EA, Ha R, Bernard-Davila B, Jochelson MS. Stereotactic breast biopsy efficiency: Does a pre-biopsy grid image help? *Clin Imaging* 2019;53:108–11. doi:10.1016/j.clinimag.2018.10.007.
- [239] Pijnappel RM, van den Donk M, Holland R, Mali WPTM, Peterse JL, Hendriks JHCL, et al. Diagnostic accuracy for different strategies of image-guided breast intervention in cases of nonpalpable breast lesions. *Br J Cancer* 2004;90:595–600. doi:10.1038/sj.bjc.6601559.
- [240] Pisano ED, Fajardo LL, Caudry DJ, Sneige N, Frable WJ, Berg WA, et al. Fine-needle aspiration biopsy of nonpalpable breast lesions in a multicenter clinical trial: results from the radiologic diagnostic oncology group V. *Radiology* 2001;219:785–92. doi:10.1148/radiology.219.3.r01jn28785.
- [241] Marino N, German R, Johnson ML, Rao X, Xuei X, Wan J, et al. Abstract 5054: Transcriptional changes in breast cancer initiation. *Tumor Biology*, American Association for Cancer Research; 2018, p. 5054–5054. doi:10.1158/1538-7445.AM2018-5054.
- [242] Szalayova G, Ogrodnik A, Spencer B, Wade J, Bunn J, Ambaye A, et al. Human breast cancer biopsies induce eosinophil recruitment and enhance adjacent cancer cell proliferation. *Breast Cancer Res Treat* 2016;157:461–74. doi:10.1007/s10549-016-3839-3.
- [243] Amin MB, Edge SB, Greene FL, Byrd DR, Brookland RK, Washington MK, et al., editors. *AJCC cancer staging manual*. Cham: Springer International Publishing; 2017. doi:10.1007/978-3-319-40618-3.
- [244] Toss M, Miligy I, Thompson AM, Khout H, Green AR, Ellis IO, et al. Current trials to reduce surgical intervention in ductal carcinoma in situ of the breast: Critical review. *Breast* 2017;35:151–6. doi:10.1016/j.breast.2017.07.012.
- [245] Sopik V, Sun P, Narod SA. Impact of microinvasion on breast cancer mortality in women with ductal carcinoma in situ. *Breast Cancer Res Treat* 2018;167:787–95.

- doi:10.1007/s10549-017-4572-2.
- [246] Rakovitch E, Nofech-Mozes S, Hanna W, Baehner FL, Saskin R, Butler SM, et al. A population-based validation study of the DCIS Score predicting recurrence risk in individuals treated by breast-conserving surgery alone. *Breast Cancer Res Treat* 2015;152:389–98. doi:10.1007/s10549-015-3464-6.
- [247] Ward EM, DeSantis CE, Lin CC, Kramer JL, Jemal A, Kohler B, et al. Cancer statistics: Breast cancer in situ. *CA Cancer J Clin* 2015;65:481–95. doi:10.3322/caac.21321.
- [248] Siegel RL, Miller KD, Jemal A. Cancer statistics, 2016. *CA Cancer J Clin* 2016;66:7–30. doi:10.3322/caac.21332.
- [249] Owusu-Brackett N, Meric-Bernstam F. Ductal Carcinoma In Situ: Risk Factor or Cancer. In: Amersi F, Calhoun K, editors. *Atypical breast proliferative lesions and benign breast disease*, Cham: Springer International Publishing; 2018, p. 37–49. doi:10.1007/978-3-319-92657-5_3.
- [250] Veronesi U, Boyle P, Goldhirsch A, Orecchia R, Viale G. Breast cancer. *Lancet* 2005;365:1727–41. doi:10.1016/S0140-6736(05)66546-4.
- [251] Koh J, Kim MJ. Introduction of a new staging system of breast cancer for radiologists: an emphasis on the prognostic stage. *Korean J Radiol* 2019;20:69–82. doi:10.3348/kjr.2018.0231.
- [252] McCart Reed AE, Kutasovic JR, Lakhani SR, Simpson PT. Invasive lobular carcinoma of the breast: morphology, biomarkers and 'omics. *Breast Cancer Res* 2015;17:12. doi:10.1186/s13058-015-0519-x.
- [253] Korourian S. *Infiltrating carcinomas of the breast*. The Breast, Elsevier; 2018, p. 145-155.e4. doi:10.1016/B978-0-323-35955-9.00010-6.
- [254] Arpino G, Bardou VJ, Clark GM, Elledge RM. Infiltrating lobular carcinoma of the breast: tumor characteristics and clinical outcome. *Breast Cancer Res* 2004;6:R149-56. doi:10.1186/bcr767.
- [255] O'Shaughnessy J. Extending survival with chemotherapy in metastatic breast cancer. *Oncologist* 2005;10 Suppl 3:20–9. doi:10.1634/theoncologist.10-90003-20.
- [256] Amirkhanlo Z, Noorbaran A, Hajian KL, Siadati S, Asghari Y, Kamali Ahangar S, et al. Evaluation of Local Recurrence of Breast Cancer after Mastectomy and Breast Preservation Therapy. *Journal of Guilan University of Medical Sciences* 2019.
- [257] Ramalho I, Campos S, Rebelo T, Figueiredo Dias M. A scary onset of a rare and aggressive type of primary breast sarcoma: A case report. *Case Rep Oncol* 2016;9:796–801. doi:10.1159/000452946.
- [258] Yin M, Mackley HB, Drabick JJ, Harvey HA. Primary female breast sarcoma: clinicopathological features, treatment and prognosis. *Sci Rep* 2016;6:31497. doi:10.1038/srep31497.
- [259] Mosly D, Turnbull A, Sims A, Ward C, Langdon S. Predictive markers of endocrine response in breast cancer. *World J Exp Med* 2018;8:1–7. doi:10.5493/wjem.v8.i1.1.
- [260] Hilton HN, Clarke CL, Graham JD. Estrogen and progesterone signalling in the normal

- breast and its implications for cancer development. *Mol Cell Endocrinol* 2018;466:2–14. doi:10.1016/j.mce.2017.08.011.
- [261] Colomer R, Aranda-López I, Albanell J, García-Caballero T, Ciruelos E, López-García MÁ, et al. Biomarkers in breast cancer: A consensus statement by the Spanish Society of Medical Oncology and the Spanish Society of Pathology. *Clin Transl Oncol* 2018;20:815–26. doi:10.1007/s12094-017-1800-5.
- [262] Easton DF, Pharoah PDP, Antoniou AC, Tischkowitz M, Tavtigian SV, Nathanson KL, et al. Gene-panel sequencing and the prediction of breast-cancer risk. *N Engl J Med* 2015;372:2243–57. doi:10.1056/NEJMsr1501341.
- [263] Györfy B, Hatzis C, Sanft T, Hofstatter E, Aktas B, Pusztai L. Multigene prognostic tests in breast cancer: past, present, future. *Breast Cancer Res* 2015;17:11. doi:10.1186/s13058-015-0514-2.
- [264] Scholzen T, Gerdes J. The Ki-67 protein: from the known and the unknown. *J Cell Physiol* 2000;182:311–22. doi:10.1002/(SICI)1097-4652(200003)182:3<311::AID-JCP1>3.0.CO;2-9.
- [265] Soliman NA, Yussif SM. Ki-67 as a prognostic marker according to breast cancer molecular subtype. *Cancer Biol Med* 2016;13:496–504. doi:10.20892/j.issn.2095-3941.2016.0066.
- [266] Preat F, Simon P, Noel J-C. Differences in breast carcinoma immunohistochemical subtypes between immigrant Arab and European women. *Diagn Pathol* 2014;9:26. doi:10.1186/1746-1596-9-26.
- [267] Saha Roy S, Vadlamudi RK. Role of estrogen receptor signaling in breast cancer metastasis. *Int J Breast Cancer* 2012;2012:654698. doi:10.1155/2012/654698.
- [268] Skliris GP, Munot K, Bell SM, Carder PJ, Lane S, Horgan K, et al. Reduced expression of oestrogen receptor beta in invasive breast cancer and its re-expression using DNA methyl transferase inhibitors in a cell line model. *J Pathol* 2003;201:213–20. doi:10.1002/path.1436.
- [269] Obr AE, Edwards DP. The biology of progesterone receptor in the normal mammary gland and in breast cancer. *Mol Cell Endocrinol* 2012;357:4–17. doi:10.1016/j.mce.2011.10.030.
- [270] Patani N, Martin L-A, Dowsett M. Biomarkers for the clinical management of breast cancer: international perspective. *Int J Cancer* 2013;133:1–13. doi:10.1002/ijc.27997.
- [271] Brennan M, Lim B. The actual role of receptors as cancer markers, biochemical and clinical aspects: receptors in breast cancer. *Adv Exp Med Biol* 2015;867:327–37. doi:10.1007/978-94-017-7215-0_20.
- [272] Bardou V-J, Arpino G, Elledge RM, Osborne CK, Clark GM. Progesterone receptor status significantly improves outcome prediction over estrogen receptor status alone for adjuvant endocrine therapy in two large breast cancer databases. *J Clin Oncol* 2003;21:1973–9. doi:10.1200/JCO.2003.09.099.
- [273] Iqbal N, Iqbal N. Human epidermal growth factor receptor 2 (HER2) in cancers:

- overexpression and therapeutic implications. *Mol Biol Int* 2014;2014:852748. doi:10.1155/2014/852748.
- [274] Miles DW, Harris WH, Gillett CE, Smith P, Barnes DM. Effect of c-erbB(2) and estrogen receptor status on survival of women with primary breast cancer treated with adjuvant cyclophosphamide/methotrexate/fluorouracil. *Int J Cancer* 1999;84:354–9. doi:10.1002/(sici)1097-0215(19990820)84:4<354::aid-ijc4>3.0.co;2-6.
- [275] Pritchard KI, Shepherd LE, O'Malley FP, Andrulis IL, Tu D, Bramwell VH, et al. HER2 and responsiveness of breast cancer to adjuvant chemotherapy. *N Engl J Med* 2006;354:2103–11. doi:10.1056/NEJMoa054504.
- [276] Cuzick J, Dowsett M, Wale C, Salter J, Quinn E, Zabaglo L, et al. Prognostic Value of a Combined ER, PgR, Ki67, HER2 Immunohistochemical (IHC4) Score and Comparison with the GHI Recurrence Score – Results from TransATAC. General Session Abstracts, American Association for Cancer Research; 2009, p. 74–74. doi:10.1158/0008-5472.SABCS-09-74.
- [277] Kondov B, Milenković Z, Kondov G, Petrushevska G, Basheska N, Bogdanovska-Todorovska M, et al. Presentation of the molecular subtypes of breast cancer detected by immunohistochemistry in surgically treated patients. *Open Access Maced J Med Sci* 2018;6:961–7. doi:10.3889/oamjms.2018.231.
- [278] Eliyatkin N, Yalçın E, Zengel B, Aktaş S, Vardar E. Molecular Classification of Breast Carcinoma: From Traditional, Old-Fashioned Way to A New Age, and A New Way. *J Breast Health (2013)* 2015;11:59–66. doi:10.5152/tjbh.2015.1669.
- [279] Dai X, Li T, Bai Z, Yang Y, Liu X, Zhan J, et al. Breast cancer intrinsic subtype classification, clinical use and future trends. *Am J Cancer Res* 2015;5:2929–43.
- [280] Sieuwerts AM, Kraan J, Bolt J, van der Spoel P, Elstrodt F, Schutte M, et al. Anti-epithelial cell adhesion molecule antibodies and the detection of circulating normal-like breast tumor cells. *J Natl Cancer Inst* 2009;101:61–6. doi:10.1093/jnci/djn419.
- [281] Huss JM, Garbacz WG, Xie W. Constitutive activities of estrogen-related receptors: Transcriptional regulation of metabolism by the ERR pathways in health and disease. *Biochim Biophys Acta* 2015;1852:1912–27. doi:10.1016/j.bbadis.2015.06.016.
- [282] Misawa A, Inoue S. Estrogen-Related Receptors in Breast Cancer and Prostate Cancer. *Front Endocrinol (Lausanne)* 2015;6:83. doi:10.3389/fendo.2015.00083.
- [283] Deblois G, Giguère V. Oestrogen-related receptors in breast cancer: control of cellular metabolism and beyond. *Nat Rev Cancer* 2013;13:27–36. doi:10.1038/nrc3396.
- [284] Kumari K, Adhya AK, Rath AK, Reddy PB, Mishra SK. Estrogen-related receptors alpha, beta and gamma expression and function is associated with transcriptional repressor EZH2 in breast carcinoma. *BMC Cancer* 2018;18:690. doi:10.1186/s12885-018-4586-0.
- [285] Ariazi EA, Clark GM, Mertz JE. Estrogen-related receptor alpha and estrogen-related receptor gamma associate with unfavorable and favorable biomarkers, respectively, in human breast cancer. *Cancer Res* 2002;62:6510–8.

- [286] Kraus RJ, Ariazi EA, Farrell ML, Mertz JE. Estrogen-related receptor alpha 1 actively antagonizes estrogen receptor-regulated transcription in MCF-7 mammary cells. *J Biol Chem* 2002;277:24826–34. doi:10.1074/jbc.M202952200.
- [287] Sengupta D, Bhargava DK, Dixit A, Sahoo BS, Biswas S, Biswas G, et al. ERR β signalling through FST and BCAS2 inhibits cellular proliferation in breast cancer cells. *Br J Cancer* 2014;110:2144–58. doi:10.1038/bjc.2014.53.
- [288] Tiraby C, Hazen BC, Gantner ML, Kralli A. Estrogen-related receptor gamma promotes mesenchymal-to-epithelial transition and suppresses breast tumor growth. *Cancer Res* 2011;71:2518–28. doi:10.1158/0008-5472.CAN-10-1315.
- [289] Galindo CL, McCormick JF, Bubb VJ, Abid Alkadem DH, Li L-S, McIver LJ, et al. A long AAAG repeat allele in the 5' UTR of the ERR- γ gene is correlated with breast cancer predisposition and drives promoter activity in MCF-7 breast cancer cells. *Breast Cancer Res Treat* 2011;130:41–8. doi:10.1007/s10549-010-1237-9.
- [290] Mirzaei H, Fathollahzadeh S, Khanmohammadi R, Darijani M, Momeni F, Masoudifar A, et al. State of the art in microRNA as diagnostic and therapeutic biomarkers in chronic lymphocytic leukemia. *J Cell Physiol* 2018;233:888–900. doi:10.1002/jcp.25799.
- [291] Kurozumi S, Yamaguchi Y, Kurosumi M, Ohira M, Matsumoto H, Horiguchi J. Recent trends in microRNA research into breast cancer with particular focus on the associations between microRNAs and intrinsic subtypes. *J Hum Genet* 2017;62:15–24. doi:10.1038/jhg.2016.89.
- [292] Park IH, Kang JH, Lee KS, Nam S, Ro J, Kim J-H. Identification and clinical implications of circulating microRNAs for estrogen receptor-positive breast cancer. *Tumour Biol* 2014;35:12173–80. doi:10.1007/s13277-014-2525-5.
- [293] Shimono Y, Zabala M, Cho RW, Lobo N, Dalerba P, Qian D, et al. Downregulation of miRNA-200c links breast cancer stem cells with normal stem cells. *Cell* 2009;138:592–603. doi:10.1016/j.cell.2009.07.011.
- [294] Smith AL, Iwanaga R, Drasin DJ, Micalizzi DS, Vartuli RL, Tan AC, et al. The miR-106b-25 cluster targets Smad7, activates TGF- β signaling, and induces EMT and tumor initiating cell characteristics downstream of Six1 in human breast cancer. *Oncogene* 2012;31:5162–71. doi:10.1038/onc.2012.11.
- [295] Bockhorn J, Yee K, Chang Y-F, Prat A, Huo D, Nwachukwu C, et al. MicroRNA-30c targets cytoskeleton genes involved in breast cancer cell invasion. *Breast Cancer Res Treat* 2013;137:373–82. doi:10.1007/s10549-012-2346-4.
- [296] Zhang G, Zhang W, Li B, Stringer-Reasor E, Chu C, Sun L, et al. MicroRNA-200c and microRNA-141 are regulated by a FOXP3-KAT2B axis and associated with tumor metastasis in breast cancer. *Breast Cancer Res* 2017;19:73. doi:10.1186/s13058-017-0858-x.
- [297] Li A, Zhang T, Zheng M, Liu Y, Chen Z. Exosomal proteins as potential markers of tumor diagnosis. *J Hematol Oncol* 2017;10:175. doi:10.1186/s13045-017-0542-8.

- [298] Valadi H, Ekström K, Bossios A, Sjöstrand M, Lee JJ, Lötvald JO. Exosome-mediated transfer of mRNAs and microRNAs is a novel mechanism of genetic exchange between cells. *Nat Cell Biol* 2007;9:654–9. doi:10.1038/ncb1596.
- [299] Iero M, Valenti R, Huber V, Filipazzi P, Parmiani G, Fais S, et al. Tumour-released exosomes and their implications in cancer immunity. *Cell Death Differ* 2008;15:80–8. doi:10.1038/sj.cdd.4402237.
- [300] Jia Y, Chen Y, Wang Q, Jayasinghe U, Luo X, Wei Q, et al. Exosome: emerging biomarker in breast cancer. *Oncotarget* 2017;8:41717–33. doi:10.18632/oncotarget.16684.
- [301] Halvaei S, Daryani S, Eslami-S Z, Samadi T, Jafarbeik-Iravani N, Bakhshayesh TO, et al. Exosomes in cancer liquid biopsy: A focus on breast cancer. *Mol Ther Nucleic Acids* 2018;10:131–41. doi:10.1016/j.omtn.2017.11.014.
- [302] Hannafon BN, Trigos YD, Calloway CL, Zhao YD, Lum DH, Welm AL, et al. Plasma exosome microRNAs are indicative of breast cancer. *Breast Cancer Res* 2016;18:90. doi:10.1186/s13058-016-0753-x.
- [303] Di Modica M, Regondi V, Sandri M, Iorio MV, Zanetti A, Tagliabue E, et al. Breast cancer-secreted miR-939 downregulates VE-cadherin and destroys the barrier function of endothelial monolayers. *Cancer Lett* 2017;384:94–100. doi:10.1016/j.canlet.2016.09.013.
- [304] Heneghan HM, Miller N, Kelly R, Newell J, Kerin MJ. Systemic miRNA-195 differentiates breast cancer from other malignancies and is a potential biomarker for detecting noninvasive and early stage disease. *Oncologist* 2010;15:673–82. doi:10.1634/theoncologist.2010-0103.
- [305] Asaga S, Kuo C, Nguyen T, Terpenning M, Giuliano AE, Hoon DSB. Direct serum assay for microRNA-21 concentrations in early and advanced breast cancer. *Clin Chem* 2011;57:84–91. doi:10.1373/clinchem.2010.151845.
- [306] Singh R, Pochampally R, Watabe K, Lu Z, Mo Y-Y. Exosome-mediated transfer of miR-10b promotes cell invasion in breast cancer. *Mol Cancer* 2014;13:256. doi:10.1186/1476-4598-13-256.
- [307] Heitzer E, Haque IS, Roberts CES, Speicher MR. Current and future perspectives of liquid biopsies in genomics-driven oncology. *Nat Rev Genet* 2019;20:71–88. doi:10.1038/s41576-018-0071-5.
- [308] Bujak AZ, Weng CF, Silva MJ, Yeung M, Lo L, Ftouni S, et al. Prospective testing of circulating tumour DNA in metastatic breast cancer facilitates clinical trial enrollment and precision oncology. *Ann Oncol* 2019;30:v30. doi:10.1093/annonc/mdz239.016.
- [309] Garcia-Murillas I, Chopra N, Comino-Méndez I, Beaney M, Tovey H, Cutts RJ, et al. Assessment of Molecular Relapse Detection in Early-Stage Breast Cancer. *JAMA Oncol* 2019. doi:10.1001/jamaoncol.2019.1838.
- [310] Schiff R, Jeselsohn R. Is ctDNA the Road Map to the Landscape of the Clonal Mutational Evolution in Drug Resistance? Lessons from the PALOMA-3 Study and

- Implications for Precision Medicine. *Cancer Discov* 2018;8:1352–4. doi:10.1158/2159-8290.CD-18-1084.
- [311] Bidard FC, Sabatier R, Berger F, Pistilli B, Dalenc F, De La Motte Rouge T, et al. PADA-1: A randomized, open label, multicentric phase III trial to evaluate the safety and efficacy of palbociclib in combination with hormone therapy driven by circulating DNA *ESR1* mutation monitoring in ER-positive, HER2-negative metastatic breast cancer patients. *J Clin Oncol* 2018;36:TPS1105–TPS1105. doi:10.1200/JCO.2018.36.15_suppl.TPS1105.
- [312] Chen S, Huang X. DNA sequencing: the key to unveiling genome. *Sci China Life Sci* 2020. doi:10.1007/s11427-020-1709-6.
- [313] Rossing M, Sørensen CS, Ejlersen B, Nielsen FC. Whole genome sequencing of breast cancer. *APMIS* 2019;127:303–15. doi:10.1111/apm.12920.
- [314] Tacar SY, Bozgeyik E, Seber ES, Yetisyigit T, Tozkir H, Avci O, et al. Next generation sequencing analysis of BRCA1 and BRCA2 identifies novel variations in breast cancer. *Life Sci* 2020:118334. doi:10.1016/j.lfs.2020.118334.
- [315] illumina. Key differences between next-generation sequencing and Sanger sequencing. *Next-Generation Sequencing* 2020. [https://www.illumina.com/science/technology/next-generation-sequencing/ngs-vs-sanger-sequencing.html#:~:text=next%2Dgeneration%20sequencing%20\(NGS\)%20technologie%20are%20similar.&text=The%20critical%20difference%20between%20Sanger,of%20ofragments%20simultaneously%20per%20run](https://www.illumina.com/science/technology/next-generation-sequencing/ngs-vs-sanger-sequencing.html#:~:text=next%2Dgeneration%20sequencing%20(NGS)%20technologie%20are%20similar.&text=The%20critical%20difference%20between%20Sanger,of%20ofragments%20simultaneously%20per%20run). (accessed August 28, 2020).
- [316] Godet I, Gilkes DM. BRCA1 and BRCA2 mutations and treatment strategies for breast cancer. *Integr Cancer Sci Therap* 2017;4. doi:10.15761/ICST.1000228.
- [317] Willoughby A, Andreassen PR, Toland AE. Genetic Testing to Guide Risk-Stratified Screens for Breast Cancer. *J Pers Med* 2019;9. doi:10.3390/jpm9010015.
- [318] Genetic Alliance, The New York-Mid-Atlantic Consortium for Genetic and Newborn Screening Services. *Understanding Genetics: A New York, Mid-Atlantic Guide for Patients and Health Professionals*. Washington (DC): Genetic Alliance; 2009.
- [319] Myriad Genetic Laboratories. BRCAAnalysis technical specifications. 2016. https://s3.amazonaws.com/myriad-library/technical-specifications/BRCA+Tech+Specs_Integrated.pdf (accessed August 28, 2020).
- [320] Valencia OM, Samuel SE, Viscusi RK, Riall TS, Neumayer LA, Aziz H. The role of genetic testing in patients with breast cancer: A review. *JAMA Surg* 2017;152:589–94. doi:10.1001/jamasurg.2017.0552.
- [321] Garcia C, Wendt J, Lyon L, Jones J, Littell RD, Armstrong MA, et al. Risk management options elected by women after testing positive for a BRCA mutation. *Gynecol Oncol* 2014;132:428–33. doi:10.1016/j.ygyno.2013.12.014.
- [322] Narod S. The prevention of hereditary breast and ovarian cancer: a personal view. *Hered Cancer Clin Pract* 2004;2:5–10. doi:10.1186/1897-4287-2-1-5.
- [323] Geyer FC, Pareja F, Weigelt B, Rakha E, Ellis IO, Schnitt SJ, et al. The Spectrum of

- Triple-Negative Breast Disease: High- and Low-Grade Lesions. *Am J Pathol* 2017;187:2139–51. doi:10.1016/j.ajpath.2017.03.016.
- [324] Gnant M, Harbeck N, Thomssen C. St. Gallen/Vienna 2017: A Brief Summary of the Consensus Discussion about Escalation and De-Escalation of Primary Breast Cancer Treatment. *Breast Care (Basel)* 2017;12:102–7. doi:10.1159/000475698.
- [325] Duffy MJ, Harbeck N, Nap M, Molina R, Nicolini A, Senkus E, et al. Clinical use of biomarkers in breast cancer: Updated guidelines from the European Group on Tumor Markers (EGTM). *Eur J Cancer* 2017;75:284–98. doi:10.1016/j.ejca.2017.01.017.
- [326] Beumer I, Witteveen A, Delahaye L, Wehkamp D, Snel M, Dreezen C, et al. Equivalence of MammaPrint array types in clinical trials and diagnostics. *Breast Cancer Res Treat* 2016;156:279–87. doi:10.1007/s10549-016-3764-5.
- [327] Brandão M, Pondé N, Piccart-Gebhart M. MammprintTM: a comprehensive review. *Future Oncol* 2019;15:207–24. doi:10.2217/fo-2018-0221.
- [328] van de Vijver MJ, He YD, van't Veer LJ, Dai H, Hart AAM, Voskuil DW, et al. A gene-expression signature as a predictor of survival in breast cancer. *N Engl J Med* 2002;347:1999–2009. doi:10.1056/NEJMoa021967.
- [329] van 't Veer LJ, Dai H, van de Vijver MJ, He YD, Hart AAM, Mao M, et al. Gene expression profiling predicts clinical outcome of breast cancer. *Nature* 2002;415:530–6. doi:10.1038/415530a.
- [330] Mook S, Van't Veer LJ, Rutgers EJT, Piccart-Gebhart MJ, Cardoso F. Individualization of therapy using Mammprint: from development to the MINDACT Trial. *Cancer Genomics Proteomics* 2007;4:147–55.
- [331] Buyse M, Loi S, van't Veer L, Viale G, Delorenzi M, Glas AM, et al. Validation and clinical utility of a 70-gene prognostic signature for women with node-negative breast cancer. *J Natl Cancer Inst* 2006;98:1183–92. doi:10.1093/jnci/djj329.
- [332] Drukker CA, Bueno-de-Mesquita JM, Retèl VP, van Harten WH, van Tinteren H, Wesseling J, et al. A prospective evaluation of a breast cancer prognosis signature in the observational RASTER study. *Int J Cancer* 2013;133:929–36. doi:10.1002/ijc.28082.
- [333] Cardoso F, Van't Veer L, Rutgers E, Loi S, Mook S, Piccart-Gebhart MJ. Clinical application of the 70-gene profile: the MINDACT trial. *J Clin Oncol* 2008;26:729–35. doi:10.1200/JCO.2007.14.3222.
- [334] Cardoso F, van't Veer LJ, Bogaerts J, Slaets L, Viale G, Delaloge S, et al. 70-Gene Signature as an Aid to Treatment Decisions in Early-Stage Breast Cancer. *N Engl J Med* 2016;375:717–29. doi:10.1056/NEJMoa1602253.
- [335] N I H. Genetic Testing or Clinical Assessment in Determining the Need for Chemotherapy in Women With Breast Cancer That Involves No More Than 3 Lymph Nodes (MINDACT). *ClinicalTrialsGov* 2019. <https://clinicaltrials.gov/ct2/show/NCT00433589> (accessed August 20, 2020).
- [336] Gnant M, Filipits M, Greil R, Stoeger H, Rudas M, Bago-Horvath Z, et al. Predicting distant recurrence in receptor-positive breast cancer patients with limited

- clinicopathological risk: using the PAM50 Risk of Recurrence score in 1478 postmenopausal patients of the ABCSG-8 trial treated with adjuvant endocrine therapy alone. *Ann Oncol* 2014;25:339–45. doi:10.1093/annonc/mdt494.
- [337] Parker JS, Mullins M, Cheang MCU, Leung S, Voduc D, Vickery T, et al. Supervised risk predictor of breast cancer based on intrinsic subtypes. *J Clin Oncol* 2009;27:1160–7. doi:10.1200/JCO.2008.18.1370.
- [338] Vieira AF, Schmitt F. An Update on Breast Cancer Multigene Prognostic Tests- Emergent Clinical Biomarkers. *Front Med (Lausanne)* 2018;5:248. doi:10.3389/fmed.2018.00248.
- [339] Wallden B, Storhoff J, Nielsen T, Dowidar N, Schaper C, Ferree S, et al. Development and verification of the PAM50-based Prosigna breast cancer gene signature assay. *BMC Med Genomics* 2015;8:54. doi:10.1186/s12920-015-0129-6.
- [340] Boccia RV. Translating Research into Practice: the Prosigna® (PAM50) Gene Signature Assay. *Clin Adv Hematol Oncol* 2015;13:3–13.
- [341] Nielsen T, Wallden B, Schaper C, Ferree S, Liu S, Gao D, et al. Analytical validation of the PAM50-based Prosigna Breast Cancer Prognostic Gene Signature Assay and nCounter Analysis System using formalin-fixed paraffin-embedded breast tumor specimens. *BMC Cancer* 2014;14:177. doi:10.1186/1471-2407-14-177.
- [342] Lænholm A-V, Jensen M-B, Eriksen JO, Rasmussen BB, Knoop AS, Buckingham W, et al. PAM50 Risk of Recurrence Score Predicts 10-Year Distant Recurrence in a Comprehensive Danish Cohort of Postmenopausal Women Allocated to 5 Years of Endocrine Therapy for Hormone Receptor-Positive Early Breast Cancer. *J Clin Oncol* 2018;36:735–40. doi:10.1200/JCO.2017.74.6586.
- [343] Dowsett M, Sestak I, Lopez-Knowles E, Sidhu K, Dunbier AK, Cowens JW, et al. Comparison of PAM50 risk of recurrence score with oncotype DX and IHC4 for predicting risk of distant recurrence after endocrine therapy. *J Clin Oncol* 2013;31:2783–90. doi:10.1200/JCO.2012.46.1558.
- [344] Simon RM, Paik S, Hayes DF. Use of archived specimens in evaluation of prognostic and predictive biomarkers. *J Natl Cancer Inst* 2009;101:1446–52. doi:10.1093/jnci/djp335.
- [345] Gnant M, Sestak I, Filipits M, Dowsett M, Balic M, Lopez-Knowles E, et al. Identifying clinically relevant prognostic subgroups of postmenopausal women with node-positive hormone receptor-positive early-stage breast cancer treated with endocrine therapy: a combined analysis of ABCSG-8 and ATAC using the PAM50 risk of recurrence score and intrinsic subtype. *Ann Oncol* 2015;26:1685–91. doi:10.1093/annonc/mdv215.
- [346] Prat A, Galván P, Jimenez B, Buckingham W, Jeiranian HA, Schaper C, et al. Prediction of Response to Neoadjuvant Chemotherapy Using Core Needle Biopsy Samples with the Prosigna Assay. *Clin Cancer Res* 2016;22:560–6. doi:10.1158/1078-0432.CCR-15-0630.
- [347] Alvarado MD, Prasad C, Rothney M, Cherbavaz DB, Sing AP, Baehner FL, et al. A

- Prospective Comparison of the 21-Gene Recurrence Score and the PAM50-Based Prosigna in Estrogen Receptor-Positive Early-Stage Breast Cancer. *Adv Ther* 2015;32:1237–47. doi:10.1007/s12325-015-0269-2.
- [348] Flanagan MB, Dabbs DJ, Brufsky AM, Beriwal S, Bhargava R. Histopathologic variables predict Oncotype DX recurrence score. *Mod Pathol* 2008;21:1255–61. doi:10.1038/modpathol.2008.54.
- [349] Cronin M, Sangli C, Liu M-L, Pho M, Dutta D, Nguyen A, et al. Analytical validation of the Oncotype DX genomic diagnostic test for recurrence prognosis and therapeutic response prediction in node-negative, estrogen receptor-positive breast cancer. *Clin Chem* 2007;53:1084–91. doi:10.1373/clinchem.2006.076497.
- [350] Orucevic A, Bell JL, McNabb AP, Heidel RE. Oncotype DX breast cancer recurrence score can be predicted with a novel nomogram using clinicopathologic data. *Breast Cancer Res Treat* 2017;163:51–61. doi:10.1007/s10549-017-4170-3.
- [351] Kozick Z, Hashmi A, Dove J, Hunsinger M, Arora T, Wild J, et al. Disparities in compliance with the Oncotype DX breast cancer test in the United States: A National Cancer Data Base assessment. *Am J Surg* 2018;215:686–92. doi:10.1016/j.amjsurg.2017.05.008.
- [352] Syed YY. Oncotype DX Breast Recurrence Score®: A Review of its Use in Early-Stage Breast Cancer. *Mol Diagn Ther* 2020. doi:10.1007/s40291-020-00482-7.
- [353] Paik S, Shak S, Tang G, Kim C, Baker J, Cronin M, et al. A multigene assay to predict recurrence of tamoxifen-treated, node-negative breast cancer. *N Engl J Med* 2004;351:2817–26. doi:10.1056/NEJMoa041588.
- [354] Sparano JA, Gray RJ, Makower DF, Pritchard KI, Albain KS, Hayes DF, et al. Adjuvant Chemotherapy Guided by a 21-Gene Expression Assay in Breast Cancer. *N Engl J Med* 2018;379:111–21. doi:10.1056/NEJMoa1804710.
- [355] Carlson JJ, Roth JA. The impact of the Oncotype Dx breast cancer assay in clinical practice: a systematic review and meta-analysis. *Breast Cancer Res Treat* 2013;141:13–22. doi:10.1007/s10549-013-2666-z.
- [356] Roberts MC, Miller DP, Shak S, Petkov VI. Breast cancer-specific survival in patients with lymph node-positive hormone receptor-positive invasive breast cancer and Oncotype DX Recurrence Score results in the SEER database. *Breast Cancer Res Treat* 2017;163:303–10. doi:10.1007/s10549-017-4162-3.
- [357] Petkov VI, Miller DP, Howlader N, Gliner N, Howe W, Schussler N, et al. Breast-cancer-specific mortality in patients treated based on the 21-gene assay: a SEER population-based study. *NPJ Breast Cancer* 2016;2:16017. doi:10.1038/npjbcancer.2016.17.
- [358] Stemmer SM, Steiner M, Rizel S, Geffen DB, Nisenbaum B, Peretz T, et al. Clinical outcomes in ER+ HER2 -node-positive breast cancer patients who were treated according to the Recurrence Score results: evidence from a large prospectively designed registry. *NPJ Breast Cancer* 2017;3:32. doi:10.1038/s41523-017-0033-7.

- [359] Gluz O, Nitz UA, Christgen M, Kates RE, Shak S, Clemens M, et al. West German Study Group Phase III PlanB Trial: First Prospective Outcome Data for the 21-Gene Recurrence Score Assay and Concordance of Prognostic Markers by Central and Local Pathology Assessment. *J Clin Oncol* 2016;34:2341–9. doi:10.1200/JCO.2015.63.5383.
- [360] Dubsy P, Filipits M, Jakesz R, Rudas M, Singer CF, Greil R, et al. EndoPredict improves the prognostic classification derived from common clinical guidelines in ER-positive, HER2-negative early breast cancer. *Ann Oncol* 2013;24:640–7. doi:10.1093/annonc/mds334.
- [361] Warf MB, Rajamani S, Krappmann K, Doedt J, Cassiano J, Brown K, et al. Analytical validation of a 12-gene molecular test for the prediction of distant recurrence in breast cancer. *Future Science OA* 2017;3:FSO221. doi:10.4155/foa-2017-0051.
- [362] Dubsy P, Brase JC, Jakesz R, Rudas M, Singer CF, Greil R, et al. The EndoPredict score provides prognostic information on late distant metastases in ER+/HER2- breast cancer patients. *Br J Cancer* 2013;109:2959–64. doi:10.1038/bjc.2013.671.
- [363] Martin M, Brase JC, Calvo L, Krappmann K, Ruiz-Borrego M, Fisch K, et al. Clinical validation of the EndoPredict test in node-positive, chemotherapy-treated ER+/HER2- breast cancer patients: results from the GEICAM 9906 trial. *Breast Cancer Res* 2014;16:R38. doi:10.1186/bcr3642.
- [364] Sestak I, Martín M, Dubsy P, Kronenwett R, Rojo F, Cuzick J, et al. Prediction of chemotherapy benefit by EndoPredict in patients with breast cancer who received adjuvant endocrine therapy plus chemotherapy or endocrine therapy alone. *Breast Cancer Res Treat* 2019;176:377–86. doi:10.1007/s10549-019-05226-8.
- [365] Penault-Llorca F, Kwiatkowski F, Arnaud A, Levy C, Leheurteur M, Uwer L, et al. Decision of adjuvant chemotherapy in intermediate risk luminal breast cancer patients: A prospective multicenter trial assessing the clinical and psychological impact of EndoPredict® (EpClin) use (UCBG 2-14). *Breast* 2020;49:132–40. doi:10.1016/j.breast.2019.10.013.
- [366] Buus R, Sestak I, Kronenwett R, Denkert C, Dubsy P, Krappmann K, et al. Comparison of endopredict and epclin with oncotype DX recurrence score for prediction of risk of distant recurrence after endocrine therapy. *J Natl Cancer Inst* 2016;108. doi:10.1093/jnci/djw149.
- [367] N I H. EndoPredict® Extended Endocrine Trial (EXET). *ClinicalTrialsGov* 2020. <https://clinicaltrials.gov/ct2/show/NCT04016935> (accessed August 3, 2020).
- [368] Zhang Y, Schnabel CA, Schroeder BE, Jerevall P-L, Jankowitz RC, Fornander T, et al. Breast cancer index identifies early-stage estrogen receptor-positive breast cancer patients at risk for early- and late-distant recurrence. *Clin Cancer Res* 2013;19:4196–205. doi:10.1158/1078-0432.CCR-13-0804.
- [369] Jerevall PL, Ma XJ, Li H, Salunga R, Kesty NC, Erlander MG, et al. Prognostic utility of HOXB13:IL17BR and molecular grade index in early-stage breast cancer patients from the Stockholm trial. *Br J Cancer* 2011;104:1762–9. doi:10.1038/bjc.2011.145.

- [370] Jankowitz RC, Cooper K, Erlander MG, Ma X-J, Kesty NC, Li H, et al. Prognostic utility of the breast cancer index and comparison to Adjuvant! Online in a clinical case series of early breast cancer. *Breast Cancer Res* 2011;13:R98. doi:10.1186/bcr3038.
- [371] Rutqvist LE, Johansson H, Stockholm Breast Cancer Study Group. Long-term follow-up of the randomized Stockholm trial on adjuvant tamoxifen among postmenopausal patients with early stage breast cancer. *Acta Oncol* 2007;46:133–45. doi:10.1080/02841860601034834.
- [372] Sanft T, Aktas B, Schroeder B, Bossuyt V, DiGiovanna M, Abu-Khalaf M, et al. Prospective assessment of the decision-making impact of the Breast Cancer Index in recommending extended adjuvant endocrine therapy for patients with early-stage ER-positive breast cancer. *Breast Cancer Res Treat* 2015;154:533–41. doi:10.1007/s10549-015-3631-9.
- [373] Sgroi DC, Sestak I, Cuzick J, Zhang Y, Schnabel CA, Schroeder B, et al. Prediction of late distant recurrence in patients with oestrogen-receptor-positive breast cancer: a prospective comparison of the breast-cancer index (BCI) assay, 21-gene recurrence score, and IHC4 in the TransATAC study population. *Lancet Oncol* 2013;14:1067–76. doi:10.1016/S1470-2045(13)70387-5.
- [374] Sgroi DC, Carney E, Zarrella E, Steffel L, Binns SN, Finkelstein DM, et al. Prediction of late disease recurrence and extended adjuvant letrozole benefit by the HOXB13/IL17BR biomarker. *J Natl Cancer Inst* 2013;105:1036–42. doi:10.1093/jnci/djt146.
- [375] Bartlett J, Sgroi D, Treuner K, Zhang Y, Piper T, Salunga RC, et al. Trans-aTTom: Breast Cancer Index for prediction of endocrine benefit and late distant recurrence (DR) in patients with HR+ breast cancer treated in the adjuvant tamoxifen—To offer more? (aTTom) trial. *J Clin Oncol* 2019;37:505–505. doi:10.1200/JCO.2019.37.15_suppl.505.
- [376] Morigi C. Highlights of the 16th St Gallen International Breast Cancer Conference, Vienna, Austria, 20-23 March 2019: personalised treatments for patients with early breast cancer. *Ecancermedicalscience* 2019;13:924. doi:10.3332/ecancer.2019.924.
- [377] Andre F, Ismaila N, Henry NL, Somerfield MR, Bast RC, Barlow W, et al. Use of Biomarkers to Guide Decisions on Adjuvant Systemic Therapy for Women With Early-Stage Invasive Breast Cancer: ASCO Clinical Practice Guideline Update-Integration of Results From TAILORx. *J Clin Oncol* 2019;37:1956–64. doi:10.1200/JCO.19.00945.
- [378] Nguyen B, Cusumano PG, Deck K, Kerlin D, Garcia AA, Barone JL, et al. Comparison of molecular subtyping with BluePrint, MammaPrint, and TargetPrint to local clinical subtyping in breast cancer patients. *Ann Surg Oncol* 2012;19:3257–63. doi:10.1245/s10434-012-2561-6.
- [379] Dabbs DJ, Brufsky A, Jankowitz RC, Puhalla S, Lee A, Oesterreich S, et al. Comparison of test results and clinical outcomes of patients assessed with both MammaPrint and Oncotype DX with pathologic variables: An independent study. *JCO* 2014;32:550–550. doi:10.1200/jco.2014.32.15_suppl.550.

- [380] Buus R, Sestak I, Dowsett M, Kronenwett R, Ferree S, Schnabel C, et al. Abstract P3-07-05: Correlation between and molecular drivers of oncotype DX, prosigna, EndoPredict and breast cancer index: A TransATAC study. Poster Session Abstracts, American Association for Cancer Research; 2020, p. P3-07-05-P3-07-05. doi:10.1158/1538-7445.SABCS19-P3-07-05.
- [381] F D A. Nucleic Acid Based Tests. US Food & Drug Administration 2020. <https://www.fda.gov/medical-devices/vitro-diagnostics/nucleic-acid-based-tests> (accessed July 27, 2020).
- [382] Bio-IT World. MPI Launches MammaPrint. Personalized Medicine 2020. <http://www.bio-itworld.com/newsitems/2005/05/05-06-05-news-MammaPrint/> (accessed August 3, 2020).
- [383] Breast Cancer Org. Oncotype DX: Genomic Test to Inform Breast Cancer Treatment. Oncotype DX 2020. https://www.breastcancer.org/symptoms/testing/types/oncotype_dx (accessed August 3, 2020).
- [384] Baskota SU, Dabbs DJ, Clark BZ, Bhargava R. Prosigna® breast cancer assay: histopathologic correlation, development, and assessment of size, nodal status, Ki-67 (SiNK™) index for breast cancer prognosis. *Mod Pathol* 2020. doi:10.1038/s41379-020-0643-8.
- [385] Neusser S, Philipp L, Schlake G, Neumann A, Tönnies P, Wilhelms S, et al. Retrospective cost-analysis of the EndoPredict test in patients with primary breast cancer in a German breast center. *J Public Health (Bangkok)* 2020. doi:10.1007/s10389-020-01193-3.
- [386] Sanft T, Berkowitz A, Schroeder B, Hatzis C, Schnabel CA, Brufsky A, et al. A prospective decision-impact study incorporating Breast Cancer Index into extended endocrine therapy decision-making. *Breast Cancer Manag* 2019;8:BMT22. doi:10.2217/bmt-2019-0001.
- [387] Ambroggi M, Biasini C, Del Giovane C, Fornari F, Cavanna L. Distance as a barrier to cancer diagnosis and treatment: review of the literature. *Oncologist* 2015;20:1378–85. doi:10.1634/theoncologist.2015-0110.
- [388] Liff JM, Chow WH, Greenberg RS. Rural-urban differences in stage at diagnosis. Possible relationship to cancer screening. *Cancer* 1991;67:1454–9. doi:10.1002/1097-0142(19910301)67:5<1454::aid-cnrcr2820670533>3.0.co;2-k.
- [389] Celaya MO, Rees JR, Gibson JJ, Riddle BL, Greenberg ER. Travel distance and season of diagnosis affect treatment choices for women with early-stage breast cancer in a predominantly rural population (United States). *Cancer Causes Control* 2006;17:851–6. doi:10.1007/s10552-006-0025-7.
- [390] Kadam YR, Quraishi SR, Dhoble RV, Sawant MR, Gore AD. Barriers for early detection of cancer amongst urban indian women: A cross sectional study. *Iran J Cancer Prev* 2016;9:e3900. doi:10.17795/ijcp.3900.
- [391] Taitsman JK, Grimm CM, Agrawal S. Protecting patient privacy and data security. N

- Engl J Med 2013;368:977–9. doi:10.1056/NEJMp1215258.
- [392] Guo X, Lin H, Wu Y, Peng M. A new data clustering strategy for enhancing mutual privacy in healthcare IoT systems. *Future Generation Computer Systems* 2020;113:407–17. doi:10.1016/j.future.2020.07.023.
- [393] Dolgopyatova AV, Kudryashova AY. Modern satellite solutions for internet broadcasting. *2020 Systems of Signals Generating and Processing in the Field of on Board Communications, IEEE*; 2020, p. 1–5. doi:10.1109/IEEECONF48371.2020.9078590.
- [394] Gøtzsche PC, Jørgensen KJ. Screening for breast cancer with mammography. *Cochrane Database Syst Rev* 2013:CD001877. doi:10.1002/14651858.CD001877.pub5.
- [395] Kösters JP, Gøtzsche PC. Regular self-examination or clinical examination for early detection of breast cancer. *Cochrane Database Syst Rev* 2003:CD003373. doi:10.1002/14651858.CD003373.
- [396] Bonfill X, Marzo M, Pladevall M, Martí J, Emparanza JI. Strategies for increasing women participation in community breast cancer screening. *Cochrane Database Syst Rev* 2001:CD002943. doi:10.1002/14651858.CD002943.
- [397] Anastasi N, Lusher J. The impact of breast cancer awareness interventions on breast screening uptake among women in the United Kingdom: A systematic review. *J Health Psychol* 2019;24:113–24. doi:10.1177/1359105317697812.
- [398] McGuinness JE, Ueng W, Trivedi MS, Yi HS, David R, Vanegas A, et al. Factors Associated with False Positive Results on Screening Mammography in a Population of Predominantly Hispanic Women. *Cancer Epidemiol Biomarkers Prev* 2018;27:446–53. doi:10.1158/1055-9965.EPI-17-0009.
- [399] Banegas MP, Bird Y, Moraros J, King S, Prapsiri S, Thompson B. Breast cancer knowledge, attitudes, and early detection practices in United States-Mexico border Latinas. *J Womens Health (Larchmt)* 2012;21:101–7. doi:10.1089/jwh.2010.2638.
- [400] Srivastava S, Koay EJ, Borowsky AD, De Marzo AM, Ghosh S, Wagner PD, et al. Cancer overdiagnosis: a biological challenge and clinical dilemma. *Nat Rev Cancer* 2019;19:349–58. doi:10.1038/s41568-019-0142-8.
- [401] Seigneurin A, Labarère J, François O, Exbrayat C, Dupouy M, Filippi M, et al. Overdiagnosis and overtreatment associated with breast cancer mammography screening: A simulation study with calibration to population-based data. *Breast* 2016;28:60–6. doi:10.1016/j.breast.2016.04.013.
- [402] Welch HG, Black WC. Overdiagnosis in cancer. *J Natl Cancer Inst* 2010;102:605–13. doi:10.1093/jnci/djq099.
- [403] Evans A, Vinnicombe S. Overdiagnosis in breast imaging. *Breast* 2017;31:270–3. doi:10.1016/j.breast.2016.10.011.
- [404] Tanaka N, Kanatani S, Kaczynska D, Fukumoto K, Louhivuori L, Mizutani T, et al. Three-dimensional single-cell imaging for the analysis of RNA and protein expression in intact tumour biopsies. *Nat Biomed Eng* 2020. doi:10.1038/s41551-020-0576-z.

- [405] Sinha R, Pati S. Molecular diagnostics in breast cancer. In: Shukla KK, Sharma P, Misra S, editors. *Molecular diagnostics in cancer patients*, Singapore: Springer Singapore; 2019, p. 89–102. doi:10.1007/978-981-13-5877-7_6.
- [406] Lim SB, Di Lee W, Vasudevan J, Lim W-T, Lim CT. Liquid biopsy: one cell at a time. *NPJ Precis Oncol* 2019;3:23. doi:10.1038/s41698-019-0095-0.
- [407] Panagopoulou M, Karaglani M, Balgouranidou I, Biziota E, Koukaki T, Karamitrousis E, et al. Circulating cell-free DNA in breast cancer: size profiling, levels, and methylation patterns lead to prognostic and predictive classifiers. *Oncogene* 2019;38:3387–401. doi:10.1038/s41388-018-0660-y.
- [408] Rayes N, Bowen DJ, Coffin T, Nebgen D, Peterson C, Munsell MF, et al. MAGENTA (Making Genetic testing accessible): a prospective randomized controlled trial comparing online genetic education and telephone genetic counseling for hereditary cancer genetic testing. *BMC Cancer* 2019;19:648. doi:10.1186/s12885-019-5868-x.
- [409] Tang J, Lu M, Cui Q, Zhang D, Kong D, Liao X, et al. Overexpression of ASPM, CDC20, and TTK Confer a Poorer Prognosis in Breast Cancer Identified by Gene Co-expression Network Analysis. *Front Oncol* 2019;9:310. doi:10.3389/fonc.2019.00310.
- [410] Ding YC, Steele L, Warden C, Wilczynski S, Mortimer J, Yuan Y, et al. Molecular subtypes of triple-negative breast cancer in women of different race and ethnicity. *Oncotarget* 2019;10:198–208. doi:10.18632/oncotarget.26559.
- [411] Chang C-S, Kitamura E, Johnson J, Bollag R, Hawthorn L. Genomic analysis of racial differences in triple negative breast cancer. *Genomics* 2019;111:1529–42. doi:10.1016/j.ygeno.2018.10.010.
- [412] Li CI, Malone KE, Daling JR. Differences in breast cancer hormone receptor status and histology by race and ethnicity among women 50 years of age and older. *Cancer Epidemiol Biomarkers Prev* 2002;11:601–7.
- [413] Kim D, Li R, Dudek SM, Ritchie MD. Predicting censored survival data based on the interactions between meta-dimensional omics data in breast cancer. *J Biomed Inform* 2015;56:220–8. doi:10.1016/j.jbi.2015.05.019.
- [414] Jang MH, Kim HJ, Chung YR, Lee Y, Park SY. A comparison of Ki-67 counting methods in luminal Breast Cancer: The Average Method vs. the Hot Spot Method. *PLoS ONE* 2017;12:e0172031. doi:10.1371/journal.pone.0172031.
- [415] Brown JR, DiGiovanna MP, Killelea B, Lannin DR, Rimm DL. Quantitative assessment Ki-67 score for prediction of response to neoadjuvant chemotherapy in breast cancer. *Lab Invest* 2014;94:98–106. doi:10.1038/labinvest.2013.128.
- [416] Gown AM. Current issues in ER and HER2 testing by IHC in breast cancer. *Mod Pathol* 2008;21 Suppl 2:S8–15. doi:10.1038/modpathol.2008.34.
- [417] Dekker TJA, ter Borg S, Hooijer GJK, Meijer SL, Wesseling J, Boers JE, et al. Quality assessment of estrogen receptor and progesterone receptor testing in breast cancer using a tissue microarray-based approach. *Breast Cancer Res Treat* 2015;152:247–52. doi:10.1007/s10549-015-3444-x.

- [418] Dekker TJA, Borg ST, Hooijer GKJ, Meijer SL, Wesseling J, Boers JE, et al. Determining sensitivity and specificity of HER2 testing in breast cancer using a tissue micro-array approach. *Breast Cancer Res* 2012;14:R93. doi:10.1186/bcr3208.
- [419] Bhidé A. Constraining Knowledge: Traditions and Rules that Limit Medical Innovation. *Critical Review* 2017;29:1–33. doi:10.1080/08913811.2017.1288464.
- [420] Luh F, Yen Y. FDA guidance for next generation sequencing-based testing: balancing regulation and innovation in precision medicine. *NPJ Genom Med* 2018;3:28. doi:10.1038/s41525-018-0067-2.

Short bibliography of each author**Diego Barba****Orcid:** <http://orcid.org/0000-0003-3237-0068>**Medical Doctor, Biomedical Discovery Team Research Fellow****Universidad San Francisco de Quito USFQ, Colegio de Ciencias de la Salud, Escuela de Medicina**

Diego obtained his medical doctor degree on October 4th, 2019 at the Universidad San Francisco de Quito, USFQ. He joined the Biomedical Discovery Team in 2016, his work is centered on bioinformatics, gene expression analysis, and development of genetic signatures for breast cancer diagnosis. Diego was a medical trainee in Oncology and Rheumatology in Lapeyronie and Saint Éloi Hospitals in Montpellier, France. He also was part of the Oncology Team at the Hospital Metropolitano in Quito, Ecuador. Diego plans a career as an oncologist while doing research to support advances in the field and provide adequate help to cancer patients as a medical doctor and scientist.

Ariana León-Sosa**Orcid:** <https://orcid.org/0000-0001-7030-2942>**Biomedical Discovery Team Manager and Research Fellow****Universidad San Francisco de Quito USFQ, Colegio de Ciencias de la Salud, Escuela de Medicina**

Ariana obtained her B.Sc. degree with an extended major in Biomedical Science from the University of Queensland, Australia in 2017. She was part of the Metabolism and Microbiome in Pregnancy lab from the School of Chemistry and Molecular Biosciences as an undergraduate student. In early 2019, she collaborated in the “Instituto Nacional de Salud Pública-INSPI” in Guayaquil- Ecuador developing research projects related to epidemiology and public health. Later in the same year, Ariana joined the Biomedical Discovery Team at USFQ. Her current work focuses on understanding cancer progression and the therapeutic potential of mitochondria in various diseases including tissue damage.

Paulina Lugo**Medical Doctor, General Surgeon, Breast Surgeon, Hospital de los Valles, Quito-Ecuador**

Paulina is a general surgeon with eight years of experience in Spain and Ecuador. She completed her master’s degree in Senology at the University of Barcelona, Spain, in 2018. She has completed internships in the Breast Unit of the Clínica Universidad de Navarra in Pamplona, Spain; Hospital Clinic y Vall d’Hebron in Barcelona, Spain, and the European Institute of Oncology in Milán, Italy. She is currently a member of the Surgery staff of the Hospital de Los Valles in Quito Ecuador being her main interest to improve hospital management and the application of high-quality standards for breast cancer screening, diagnostic, and treatments.

Paulina also collaborates with the Biomedical Discovery Team at the USFQ, in research projects related to understanding breast cancer progression.

Daniela Suquillo-Yépez

Biomedical Discovery Team Trainee

Universidad San Francisco de Quito USFQ, Colegio de Ciencias Biológicas y Ambientales, Escuela de Biotecnología

Daniela is a Biotechnology Engineering Student at the Universidad San Francisco de Quito, USFQ. She has been working with Andres Caicedo and the Biomedical Discovery Team since 2019 in research projects related to cancer progression. Daniela's future perspectives are focused on continuing its research career in the biomedical field, specifically on understanding the biological processes involved in genetic diseases and cancer in order to provide effective therapies.

Fernando Torres

Medical Doctor, Surgeon, Hospital de los Valles, Quito-Ecuador

Professor at the Universidad San Francisco de Quito USFQ, Colegio de Ciencias de la Salud, Escuela de Medicina

Fernando is a Doctor of Medicine and Surgery who graduated from the Central University of Ecuador, and Surgeon General graduated from the International University of Ecuador. Fernando completed two medical degrees at the Catholic University of Chile in Advanced Laparoscopy and Esophageal-Gastric Bariatric Surgery; he is Fellow of the American College of Surgeons since 2014; Instructor in Medical Simulation endorsed by the Harvard Medical Simulation Center and the Valdecilla Virtual Hospital and the Francisco de Vitoria University of Madrid. Regional director of the ATLS program (advanced life support for trauma) and director of the Program of Experimental Surgery and Surgical Research (CEIQ).

Fernando is Professor and Coordinator within the School of Medicine of the Universidad San Francisco de Quito in the subjects of Anatomy, Surgery, Surgical Techniques as well as support in the coordination of the international rotary at the Hospital de Los Valles. He shows great interest in surgical and technological research directing the manufacture of medical simulation equipment for the region.

Frederic Surre

Assistant Professor and Researcher at the University of Glasgow

Frederic has been working on designing sensors systems for applications in gas sensing, biomedical and civil engineering. He received the French MEng, Master of Advanced Studies and PhD in Electronic Engineering (computational electromagnetics) from Toulouse INP, France in 1998, 1998 and 2003, respectively. After post-doctoral positions at Queen Mary, University of London, Trinity College Dublin, and Dublin City University, he was appointed Assistant Professor in Optical Systems at City, University of London. His research interests include modelling of light

matter interactions and the design of optical sensor systems using optical fibers and integrated photonic circuits.

Lionel Trojman

Orcid: <http://orcid.org/0000-0003-2316-4959>

**Professor Electrical and Electronics Engineering Department of the USFQ, Ecuador
Professor Institut Supérieur d'Électronique de Paris (ISEP) in France**

Lionel Trojman was born in Marseille, France. He received the B.Sc. degree in physics from the Faculty of Saint-Charles, University of Provence, Marseille, France, in 2002. He received the M.Sc. degree in physics applied to micro- and nano-electronics and in electrical engineering in microelectronic and Telecommunication from the Ecole Polytechnique Universitaire de Marseille, University of Provence, in 2004. He received his Ph.D. degree in Electrical Engineering at the KULeuven in partnership with the IMEC, Belgium, in 2009. He was working as full time Professor to the electrical and electronics engineering department of the USFQ, Ecuador, since 2009 and he is currently working as professor for Isep, France, since 2019. His current research interests include transport for ultra-scaled MOSFET (down to 22nm) with UTEOT high-k dielectrics with conventional and novel architectures (FDSOI) for CMOS technologies. He is also working on memory devices such as ReRAM, MTJ, and finally power electronic devices implemented in GaN technology. Recently he is involved in Integrated circuit topic using 180, 90 and 32/28nm technology node for IoT application.

Andrés Caicedo

Orcid: <https://orcid.org/0000-0001-8821-0333>

Professor at the Universidad San Francisco de Quito USFQ, Colegio de Ciencias de la Salud, Escuela de Medicina

Andrés obtained his Ph.D. with Honors in Biomedicine in 2013, he has a specialization in Regenerative Medicine by the Biomedicine Research Institute and Biotherapies (IRMB) and a specialization in Management, all of them from the University of Montpellier. From 2016 to the present, he is a Professor and Researcher at the School of Medicine of the San Francisco University of Quito (USFQ). He is the leader of the “Biomedical Discovery Team”. His team is interested in the generation of new therapies for the repair of tissue affected by age, environmental stress, or damage. He also has experience in the understanding of the tumor microenvironment especially in how stem cells could affect its progression. In 2017 he was part of the awarded Innovators Under 35 in Latin America prize by the Massachusetts Institute of Technology Review with the technique of "Artificial transplantation of mitochondria for medical purposes, MitoCeption". Winner of the 2017 Innovation Call “Ecuador Changes the World” for the Alliance for Entrepreneurship and Innovation of Ecuador (AEI) with the project “Prediction of susceptibility to Diabetes and Metabolic Syndrome by the Measurement of Circulating Mitochondrial DNA”. Member and Chairman of the Scientific Commission of the National Institute of Transplantation of Tissue Organs and Cells (INDOT) in 2019. Since 2018, he has been responsible for the R&D department at “Sistemas Médicos USFQ”. In 2020 he was elected Regional Secretary of the International Society for Gene and Cell Therapy (ISCT), <https://isctglobal.org/>. He seeks to develop solid ventures with the support and interaction between the private sector, academia and the Government to position Ecuador and the region as leaders in the application of effective and safe stem cells-based therapies.