

1 **Novel Insights**

2 **Multicolor-FISH characterization of a prenatal mosaicism for a chromosomal rearrangement undetected**
3 **by molecular cytogenetic**

4 Laura Mary^{1,2,3}, Philippe Loget², Sylvie Odent⁴, Dominique Aussel⁵, Gwénaelle Le Bouar⁶, Erika Launay¹,
5 Catherine Henry¹, Marc-Antoine Belaud-Rotureau^{1,3}, Sylvie Jaillard^{1,3}

6
7 ¹Service de Cytogénétique et Biologie Cellulaire, CHU Rennes, Rennes, France

8 ²Service d'Anatomie et Cytologie Pathologiques, CHU Rennes, Rennes, France

9 ³Université Rennes 1, INSERM, EHESP, IRSET – UMR_S 1085, Rennes, France

10 ⁴Service de Génétique Clinique, CHU Rennes, CLAD Ouest, Rennes, France

11 ⁵Service de Gynécologie-Obstétrique, Clinique de La Sagesse, Rennes, France

12 ⁶Unité de Médecine foetale, Service de Gynécologie-Obstétrique, CHU Rennes, Rennes, France

13
14 Short Title: Multicolor-FISH characterization of a prenatal low-level mosaicism chromosomal
15 rearrangement.

16
17 Corresponding author:

18 Dr. Laura Mary, laura.mary@chu-rennes.fr

19 Service de Cytogénétique et Biologie Cellulaire

20 CHU Pontchaillou

21 2 rue Henri Le Guilloux

22 35000 RENNES, France

23 Phone: +33 2 99 28 83 38

24
25 Number of Tables: 0

26 Number of Figures: 4

27 Word count: 3046 (main body text)

28
29 Keywords: Multicolor-FISH; prenatal; mosaicism; aCGH; chromosome rearrangement

31 **Established Facts and Novel Insights**

Established Facts

- Fetal mosaicism is frequent
- Most of these mosaics are aneuploidies
- Chromosomal microarray analysis (CMA) is now used as a first-tier technique in prenatal diagnosis

Novel Insights

- CNV diagnosed with CMA may be associated with additional genomic imbalances present in low level mosaicism,
- These rearrangements require morphological cytogenetic techniques to be properly diagnosed

33

34 **ABSTRACT**

35 Fetal mosaicism for chromosomal rearrangements remains a challenge to diagnose, even in the era of
36 whole genome sequencing. We present here a case of fetal mosaicism for a chromosomal rearrangement
37 explored in amniocytes and fetal muscle, consisting of a major cell population (95%) with 4q partial
38 monosomy and a minor population (5%) with additional material replacing the 4qter deleted segment.
39 Molecular techniques (MLPA, array-CGH) failed to assess the origin of this material. Only multicolor-FISH
40 identified the additional segment on chromosome 4 as derived from chromosome 17. Due to the poor
41 prognosis, the couple chose to terminate the pregnancy. Because of low-level mosaicism, chromosomal
42 microarray analyses (CMA), now considered as first-tier prenatal genetic analysis, did not allow the
43 identification of the minor cell. In case of large CNV (>5Mb) detected by CMA, realization of a karyotype
44 may be considered to elucidate the mechanism of the underlying rearrangement and eliminate mosaicism.

45

46 **I) INTRODUCTION**

47 Fetal mosaicism (i.e. the presence, in an individual, of two or more distinct cellular populations) can
48 concern 0.64% of amniotic fluid samples (AFS) and up to 2% of chorionic villus samples (CVS) (Grati et al.,
49 2017). For these CVS, most of mosaicisms are confined to the placenta (Grati et al., 2017), and only fetal
50 sampling (e.g. AFS or cord blood samples) can prove true fetal mosaicism (Malvestiti et al., 2015).

51 Mosaicism can also be the consequence of culture artifacts (Pipiras et al., 2004). Most fetal mosaicisms are
52 aneuploidies (Grati et al., 2017) corresponding to mitotic, post-zygotic events, mainly underpinned by two
53 mechanisms: chromosome missegregation in a somatic cell of a euploid conceptus and trisomy or
54 monosomy rescue after a meiotic nondisjunction (Grati et al., 2017; Taylor et al., 2014). Mosaicism for
55 small supernumerary marker chromosomes (sSMCs) are also described in prenatal samples and are
56 involved in 14% of fetal mosaicisms (Grati et al., 2017). Mosaicism may finally also involve structural
57 chromosomal abnormalities and thus are observed for balanced or unbalanced translocations (Malvestiti et

58 al., 2015; Pipiras et al., 2004; Stallings et al., 1997). Mosaicism remains a challenge to diagnose, even with
59 routine techniques of prenatal testing. When diagnosed, the clinical consequences of such mosaicisms are
60 also highly difficult to predict, depending both on the anomalies involved and the level of mosaicism in
61 each tissue (Taylor et al., 2014).

62 Among cytogenetic techniques, multicolor-FISH (M-FISH), consisting in using up to 24 chromosome painting
63 probes in a single FISH technique is overthrown by molecular techniques such as chromosomal microarray
64 analyses (CMA) or high throughput sequencing. However, M-FISH is still of interest to supplement these
65 techniques in some cases, such as characterizing small supernumerary marker chromosomes (sSMC,(Jang
66 et al., 2016)) or mosaic complex chromosomal rearrangements (Lin et al., 2018).

67 We present here a case-report of a fetal mosaicism for an unexpected unbalanced translocation solved by
68 M-FISH after failure of both MLPA and CMA to conclude on the complete nature of the rearrangement.

69 **II) CLINICAL REPORT**

70 **II.1) Case Presentation**

71 A 28 year-old primigravida woman was referred to our center at 15 gestation weeks (GW) for an isolated
72 increased nuchal translucency (95th percentile). Familial and personal medical histories were unremarkable.
73 Consanguinity was discounted. Amniotic fluid was sampled to find a possible genetic caused of the
74 increased nuchal translucency.

75 **II.2) Methods and Results**

76 RHG -banding karyotype was performed on cultured amniocytes (for the fetus) and cultured lymphocytes
77 obtained from peripheral blood (for the parents) according to standard cytogenetic procedures. Two
78 abnormal cell populations were observed on both fetal karyotypes realized on two different amniotic fluid
79 samples (performed at 15 gestation weeks (GW) and 23 GW respectively): one major population (95% of
80 cells) carrying a distal deletion of the long arm of a chromosome 4 (Figure 1A), and a second population (5%
81 of cells) presenting with additional material of unknown origin on the deleted chromosome 4 (Figure 1B).
82 No normal cell was observed. FISH was performed using chromosome 4 whole chromosome painting and
83 subtelomeric probes on cultured amniocytes according to manufacturers' protocols. FISH confirmed that
84 the subtelomeric 4qter region was deleted in both populations and that the additional material did not
85 originate from a chromosome 4 (data not shown). To identify the additional chromosomal material,
86 different molecular techniques were used. DNA was extracted from cultured amniocytes. The MLPA kits
87 SALSA P036B and P070 (MRC Holland, Amsterdam, The Netherlands) were used according to the
88 manufacturer's protocol. Electrophoresis of the PCR products was run on an AbiPrism 3130xl and analyzed
89 using Coffalyser.Net software. This analysis showed a homogeneous heterozygous deletion of chromosome
90 4 long arm subtelomeric region and failed to detect a gain of another subtelomeric region (data not
91 shown).

92 Oligonucleotide array-CGH (aCGH) was performed using the Agilent Human Genome CGH microarray
93 4x180K (Agilent Technologies, Santa Clara, CA, USA), on DNA extracted from both cultured amniocytes and

94 frozen fetal muscle. Scanning, extraction and analysis methods were described elsewhere (Jaillard et al.,
95 2011). The probes were mapped using GRCh37 genome version. Aberration detection was set as follow:
96 minimal number of deviated probes = 3, with ADM-2 as aberration algorithm (threshold = 6) with fuzzy zero
97 off. aCGH on both samples highlighted a terminal deletion starting at 4q33 and spanning 19.9Mb (Figure
98 2A). The mean log ratio of the deletion was -0.92, a result in favor of a homogeneous heterozygous
99 4q33q35.2 terminal deletion. The profiles of the other chromosomes showed no pathogenic gain, even in
100 mosaic (assessed through multisample analyses).

101 Parental karyotypes were normal.

102 Due to the difficulties in identifying the additional material on fetal chromosome 4q with MLPA and aCGH,
103 an M-FISH on cultured amniocytes was performed using the 24Xcyte-MetaSystems 24-color kit and
104 according to the manufacturer's protocol. Counting 100 metaphases, we finally concluded that the
105 additional material, present in 5% of the metaphases, originated from chromosome 17 (Figure 3B). In 95%
106 of the metaphases, we only observed the terminal 4q deletion.

107 Retrospective analysis of the karyotype in light of the M-FISH findings suggested that the additional
108 material corresponded to the long arm of a chromosome 17. Reanalysis of the aCGH profiles of
109 chromosome 17 did not show any deviation (Figure 2B). We performed an additional FISH analysis using
110 the ZytoLight® ERBB2/CEP17 probes (Zytovision GmbH, Bremerhaven, Germany) on frozen fetal muscle.
111 Mosaicism for partial trisomy 17q was estimated to be 7-8% in this tissue. In all the cells carrying an extra
112 signal of the ERBB2 probe (at 17q12q21.1 locus) we did not identify additional spots for the probe targeting
113 the chromosome 17 centromere. Thus, these results discounted the presence of centromere of
114 chromosome 17 in the additional segment of chromosome 17 located on 4q.

115 In conclusion, the fetal karyotype presented with a major cellular population showing a terminal deletion
116 4q33qter (95% of cells), and a minor population showing the same 4q33qter deletion, replaced by a
117 chromosome 17 long arm (5% of cells) leading to chromosome 17 partial trisomy. Both populations were
118 otherwise disomic for normal chromosomes 17. The final formula was

119 $\text{mos } 46,XY,\text{del}(4)(q33)[95]/46,XY,\text{der}(4)t(4;17)(q33;q11)[5].\text{arr}[GRCh37]$

120 $4q33q35.2(170684863_190679684)\times 1$

121

122 **II.3) Pregnancy outcome**

123 Due to the poor prognosis resulting from the chromosomal anomalies, the couple chose to terminate the
124 pregnancy at 24 GW. A male fetus was delivered. He presented with a dolichocephaly associated with
125 prefrontal edema, hypertelorism, retrognathism and a narrow palate. Careful examination of the
126 extremities highlighted brachymesophalangia of the 5th fingers and a bilateral single palmar crease. At
127 autopsy, the fetus also had a single left umbilical artery, cryptorchidism, a common mesentery with an
128 intestinal malrotation and a small atrial septal defect. Delayed bone maturation (bone maturation
129 compatible with a 22 GW-old fetus) was diagnosed at standard radiographies. Histopathological analyses

130 revealed asymmetric testes, with one normal testis and one showing an immature parenchyma.

131 Histological analyses of the other organs were unremarkable.

132 III) **DISCUSSION**

133 Mosaicism in prenatal samples is a phenomenon favored by advanced parental age (Taylor et al., 2014) that
134 can reach up to 2% of CVS samples (Grati et al., 2017) but is more uncommon in AFS (between 0.3% and
135 0.64% (Grati et al., 2017; Ing et al., 1999; Li et al., 2019; LI et al., 2019)). Most of these mosaicisms,
136 especially when confirmed on fetal-derived tissues, are aneuploidies (Grati et al., 2017). However, some of
137 these mosaic anomalies may involve structural chromosomal abnormalities. If most of these anomalies are
138 sSMCs, mosaicism for balanced or unbalanced translocations are also observed (Pipiras et al., 2004;
139 Stallings et al., 1997). We present here a case of mosaicism in a fetus presenting with a major cell
140 population showing a 4q partial monosomy and a minor population with a 4q partial monosomy plus a 17q
141 partial trisomy.

142 4q terminal deletions are rare and responsible for various phenotypes, combining cleft lip and palate,
143 congenital heart defects and neurodevelopmental delay, as well as other minor anomalies depending on
144 the size of the deletion (Tidrenczel et al., 2019). Large 17q duplications are also very rare and seem to
145 generate more severe phenotypes, as Ellis-Van-Creveld-like features (Serotkin et al., 1988), delayed
146 psychomotor development, micrognathia, skeletal anomalies, and central nervous system (CNS) defects
147 and even hydrops fetalis (Lenzini et al., 1988). The fetus presented here had an association of several mild
148 anomalies including facial dysmorphism, single left umbilical artery, cryptorchidism intestinal malrotation
149 and small atrial septal defect. This phenotype may recall 4q terminal deletion syndrome rather than 17q
150 duplication. This may be explained by the very low prevalence of cells carrying a 17q trisomy contrary to
151 homogeneous 4qter deletion.

152 The threshold of mosaicism detection for prenatal cytogenetic techniques is around 19% for karyotype (for
153 a routine number of 15 metaphases analyzed, with 95% degree of confidence, reaching 5% with 99%
154 degree of confidence if 100 cells are analyzed (Hook, 1977)), 40% for MLPA (Chen et al., 2014) and 20% for
155 BoBs (BACs on Beads,(Cheng et al., 2013)). The use of CMA lowered the capacities of mosaic detection, and
156 the sensitivity of this technique for both gains and losses is around 10% (9-15% (Ballif et al., 2006; Carey et
157 al., 2014)).The lowest level of prenatal mosaicism detected previously reported in the literature was 6% in a
158 case of trisomy 21 (detected through karyotype on amniocytes, (Sifakis et al., 2008)). In our case, karyotype
159 identified 2 cell populations but MLPA and aCGH failed to identify the nature of the additional material
160 located on chromosome 4q, because of a very low level of mosaicism for the cell line with the der(4)t(4;17)
161 chromosome (5%). Only M-FISH led to the identification of the additional material, corresponding to
162 additional chromosome 17 long arm material on chromosome 4q. As previously mentioned, M-FISH is now
163 used in rare pre- and postnatal cases of sSMC when CMA does not allow to characterize the abnormal
164 chromosome (Jang et al., 2016), by painting all chromosomes in one experiment. However, M- FISH shows
165 limitations when exact localization of a chromosomal breakpoint is required or intrachromosomal

166 aberrations are present. Another limitation is the size of the chromosomal segment involved in a
167 rearrangement. Apart from M-FISH, massive parallel sequencing MPS with Whole Genome Sequencing
168 (WGS), is predicted helpful to shed light on chromosomal rearrangements but CNV smaller than 100 kb may
169 still be challenging to diagnose in routine practice (Gross et al., 2019) and repetitive DNA sequences, such
170 as centromeres, cannot be explored. Moreover, WGS detection threshold for mosaicism is estimated
171 between 10 and 20% depending on the anomaly (Hochstenbach et al., 2019), lower detection thresholds
172 being currently achieved only for point variations through targeted MPS (Brewer et al., 2020; Liu et al.,
173 2020). These statements suggest that MPS is probably not suitable for an accurate characterization of our
174 rearrangement.

175

176 Chromosomal rearrangements are a common finding in early human embryos (Vanneste et al., 2009).
177 These rearrangements include segmental terminal imbalances or double-strand breaks (DSB) within the
178 centromeric regions, whole arm deletions and duplications. Multiple rearrangements can coexist in the
179 same blastomere, revealing a high chromosomal instability (Vanneste et al., 2009). Most of these anomalies
180 may be rescued through various mechanisms or be overwhelmed by normal cells (Popovic et al., 2020), but
181 milder anomalies can persist and generate mosaicism (Grati et al., 2017). Four hypotheses can be
182 formulated to elucidate the mechanism generating the rearrangement observed in our case (Figure 4).
183 A) A balanced translocation (4;17)(q33;q11) appeared in one parent's gamete and the zygote received the
184 der(4) chromosome. Then, during the early mitotic divisions of the embryo, a break occurred on the
185 derivative chromosome with loss of the additional segment of 17q attached to 4q. The broken der(4) is
186 then stabilized by neotelomere formation, resulting in a minor "native" cell line with the der(4) and a major
187 "derived" cell line with a pure 4q deletion (Figure 4A). This hypothesis has been proposed by (Kulikowski et
188 al., 2006) as a statement for a similar mosaicism observed in a patient, which associated a pure monosomy
189 9p23pter in a major cell line and a minor cell line showing additional material from chromosome 1
190 (1q41qter) in place of the deleted 9p23pter segment. This hypothesis seems to be the most relevant to
191 explain the results obtained in this case.

192 B) A DSB occurred at 4q33 during early embryogenesis. Microhomology Mediated Break-Induced Repair
193 (MMBIR) mechanism took place to repair the DSB during replication. Briefly, MMBIR allows a collapsed
194 replication fork to invade any single stranded template in close physical proximity that it shares
195 microhomology to (Colnaghi et al., 2011). Here, instead of using a replication fork on chromosome 4 as a
196 template to correct the DSB, the cell used a fork on chromosome 17, resulting in an aberrant chromosome
197 4 in which the 4q33q35 region is replaced by a segment originating from chromosome 17 (Figure 4B).
198 These previous hypotheses may be promoted by the abundance of segmental duplications and Low-Copy-
199 Repeats (LCR) on chromosome 17 (Cardone et al., 2008), some of them having strong homologies with LCR
200 on distal chromosome 4q. The presence of intrachromosomal telomeric-like sequences at both centromeric
201 region of chromosome 17 and 4q32q33 band may favor telomere capture as a way to "heal" broken

202 chromosomes but also chromosomal rearrangements and breakages (Ruiz-Herrera et al., 2005). The
203 characterization of the breakpoints in the minor cell line would have been of interest to explore the
204 hypothesis of the invasion of a chromosome 17 template by a collapsed fork on chromosome 4, but
205 unfortunately, we did not have enough fetal material to do so.

206 C) A balanced translocation (4;17)(q33;q11) appears in early embryogenesis. The centromere of the
207 chromosome 17 was included in the translocation leading to the generation of an acentric chromosome 17
208 derivative (lost during mitoses) and a dicentric chromosome 4 derivative. Endoreplication or similar
209 mechanisms rescues the monosomy 17 (Taylor et al., 2014). Then, absence of centromere inactivation in
210 some cells may result in a breakage of the chromosome 4 derivative during mitosis and thus to a pure
211 4q33qter-deleted population (Figure 4C). This hypothesis was discounted by complementary FISH analyses
212 showing the absence of chromosome 17 centromere in the der(4) of the minor cell line.

213 D) Finally, it has also been recently demonstrated that chromoanagenesis may occur in the germline,
214 resulting in high complexity rearrangements. These rearrangements are often stable, but rare cases of
215 instability generating mosaicism are described. In an autistic patient, Collins *et al.* found a somatic mosaic
216 unbalanced chromoanasythesis of chromosome 19, resulting from a *de novo* duplication-inversion-
217 duplication in the germline (or in early embryogenesis) followed by mitotic missegregation leading to 6
218 mosaic duplications (Collins et al., 2017). Due to the extensive explorations performed, this hypothesis
219 seems very unlikely (Figure 4D).

220 **IV) CONCLUSION**

221 Chromosomal mosaicism is frequent in prenatal period but remains a challenge to diagnose. After assessing
222 the presence of a mosaicism in a fetal-derived sample, determining the nature of the chromosomal
223 anomaly can raise unexpected issues, even in the era of WGS. For prenatal diagnosis, CMA analysis should
224 now be considered as a gold standard technique performed in first tier, as recommended by the
225 Association des Cytogénéticiens de Langue Française (ACLF) in some indications presented in the
226 guidelines. Its limitations in detecting low-level mosaicisms is now well described but may be tolerated,
227 given the fact that low-mosaic anomalies are very rare, thus chromosomal mosaic anomalies overlooked by
228 CMA are estimated less than 1% (Tuke et al., 2019). However, the case reported here highlights the
229 limitations of aCGH analysis for the detection of multiple abnormal cell lines and the necessity to associate
230 morphological techniques with CMA (as karyotype or M-FISH) to conclude properly on the mechanism
231 underlying the anomaly. In case of large CNV (>5Mb) detected by CMA, the realization of a karyotype may
232 be considered to elucidate the mechanism of the underlying rearrangement and eliminate low-level
233 mosaicism.

234

235 **STATEMENTS**

236 **Acknowledgements**

237 We are grateful to Dr K. Pluquailec, who performed the initial karyotypes, and Dr D. D'Hervé who referred
238 the patient.

239 **Statement of Ethics**

240 The research was conducted ethically in accordance with the World Medical Association Declaration of
241 Helsinki. Written informed consent was obtained from the parents of the fetus for publication of this case
242 report and any accompanying images.

243 **Conflict of Interest**

244 The authors have no conflicts of interest to declare.

245 **Funding sources**

246 This research did not receive any specific grant from funding agencies in the public, commercial, or not-for-
247 profit sectors.

248 **Author Contributions**

249 SJ conceived and designed the study. SO, DA and GLB were involved in the patient care and evaluation. EL,
250 CH and LM acquired the cytogenetic data. SJ, LM, CH and EL analyzed and interpreted the data. PL
251 performed the fetal autopsy. LM wrote the manuscript. SJ and MABR critically reviewed the manuscript and
252 all authors read and approved the final manuscript.

253

254

REFERENCES

- 255 Ballif, B.C., Rorem, E.A., Sundin, K., Lincicum, M., Gaskin, S., Coppinger, J., Kashork, C.D., Shaffer, L.G.,
256 Bejjani, B.A., 2006. Detection of low-level mosaicism by array CGH in routine diagnostic specimens.
257 *Am. J. Med. Genet. A.* 140, 2757–2767. <https://doi.org/10.1002/ajmg.a.31539>
- 258 Brewer, C.J., Gillespie, M., Fierro, J., Scaringe, W.A., Li, J.M., Lee, C.-Y., Yen, H.-Y., Gao, H., Strom, S.P., 2020.
259 The Value of Parental Testing by Next-Generation Sequencing Includes the Detection of Germline
260 Mosaicism. *J. Mol. Diagn. JMD* 22, 670–678. <https://doi.org/10.1016/j.jmoldx.2020.02.001>
- 261 Cardone, M.F., Jiang, Z., D'Addabbo, P., Archidiacono, N., Rocchi, M., Eichler, E.E., Ventura, M., 2008.
262 Hominoid chromosomal rearrangements on 17q map to complex regions of segmental duplication.
263 *Genome Biol.* 9, R28. <https://doi.org/10.1186/gb-2008-9-2-r28>
- 264 Carey, L., Scott, F., Murphy, K., Mansfield, N., Barahona, P., Leigh, D., Robertson, R., McLennan, A., 2014.
265 Prenatal diagnosis of chromosomal mosaicism in over 1600 cases using array comparative genomic
266 hybridization as a first line test. *Prenat. Diagn.* 34, 478–486. <https://doi.org/10.1002/pd.4332>
- 267 Chen, X., Li, H., Mao, Y., Xu, X., Lv, J., Zhou, L., Lin, X., Tang, S., 2014. Subtelomeric multiplex ligation-
268 dependent probe amplification as a supplement for rapid prenatal detection of fetal chromosomal
269 aberrations. *Mol. Cytogenet.* 7, 96. <https://doi.org/10.1186/s13039-014-0096-1>
- 270 Cheng, Y.K.Y., Wong, C., Wong, H.K., Leung, K.O., Kwok, Y.K., Suen, A., Wang, C.C., Leung, T.Y., Choy, K.W.,
271 2013. The detection of mosaicism by prenatal BoBsTM. *Prenat. Diagn.* 33, 42–49.
272 <https://doi.org/10.1002/pd.4006>
- 273 Collins, R.L., Brand, H., Redin, C.E., Hanscom, C., Antolik, C., Stone, M.R., Glessner, J.T., Mason, T., Pregno,
274 G., Dorrani, N., Mandrile, G., Giachino, D., Perrin, D., Walsh, C., Cipicchio, M., Costello, M.,
275 Stortchevoi, A., An, J.-Y., Currall, B.B., Seabra, C.M., Ragavendran, A., Margolin, L., Martinez-Agosto,
276 J.A., Lucente, D., Levy, B., Sanders, S.J., Wapner, R.J., Quintero-Rivera, F., Kloosterman, W.,
277 Talkowski, M.E., 2017. Defining the diverse spectrum of inversions, complex structural variation,
278 and chromothripsis in the morbid human genome. *Genome Biol.* 18.
279 <https://doi.org/10.1186/s13059-017-1158-6>

280 Colnaghi, R., Carpenter, G., Volker, M., O'Driscoll, M., 2011. The consequences of structural genomic
281 alterations in humans: genomic disorders, genomic instability and cancer. *Semin. Cell Dev. Biol.* 22,
282 875–885. <https://doi.org/10.1016/j.semcdb.2011.07.010>

283 Grati, F.R., Malvestiti, F., Branca, L., Agrati, C., Maggi, F., Simoni, G., 2017. Chromosomal mosaicism in the
284 fetoplacental unit. *Best Pract. Res. Clin. Obstet. Gynaecol.* 42, 39–52.
285 <https://doi.org/10.1016/j.bpobgyn.2017.02.004>

286 Gross, A.M., Ajay, S.S., Rajan, V., Brown, C., Bluske, K., Burns, N.J., Chawla, A., Coffey, A.J., Malhotra, A.,
287 Scocchia, A., Thorpe, E., Dzidic, N., Hovanes, K., Sahoo, T., Dolzhenko, E., Lajoie, B., Khouzam, A.,
288 Chowdhury, S., Belmont, J., Roller, E., Ivakhno, S., Tanner, S., McEachern, J., Hambuch, T., Eberle,
289 M., Hagelstrom, R.T., Bentley, D.R., Perry, D.L., Taft, R.J., 2019. Copy-number variants in clinical
290 genome sequencing: deployment and interpretation for rare and undiagnosed disease. *Genet.*
291 *Med. Off. J. Am. Coll. Med. Genet.* 21, 1121–1130. <https://doi.org/10.1038/s41436-018-0295-y>

292 Hochstenbach, R., van Binsbergen, E., Schuring-Blom, H., Buijs, A., Ploos van Amstel, H.K., 2019. A survey of
293 undetected, clinically relevant chromosome abnormalities when replacing postnatal karyotyping by
294 Whole Genome Sequencing. *Eur. J. Med. Genet.* 62, 103543.
295 <https://doi.org/10.1016/j.ejmg.2018.09.010>

296 Hook, E.B., 1977. Exclusion of chromosomal mosaicism: tables of 90%, 95% and 99% confidence limits and
297 comments on use. *Am. J. Hum. Genet.* 29, 94–97.

298 Ing, P.S., Van Dyke, D.L., Caudill, S.P., Reidy, J.A., Bice, G., Bieber, F.R., Buchanan, P.D., Carroll, A.J., Cheung,
299 S.W., Dewald, G., Donahue, R.P., Gardner, H.A., Higgins, J., Hsu, L.Y., Jamehdor, M., Keitges, E.A.,
300 Laundon, C.H., Luthardt, F.W., Mascarello, J., May, K.M., Meck, J.M., Morton, C., Patil, S., Peakman,
301 D., Pettenati, M.J., Rao, N., Sanger, W.G., Saxe, D.F., Schwartz, S., Sekhon, G.S., Vance, G.H.,
302 Wyandt, H.E., Yu, C.W., Zenger-Hain, J., L. Chen, A.T., 1999. Detection of Mosaicism in amniotic
303 fluid cultures: A CYTO2000 collaborative study. *Genet. Med.* 1, 94–97.
304 <https://doi.org/10.1097/00125817-199903000-00006>

305 Jaillard, S., Andrieux, J., Plessis, G., Krepischi, A.C.V., Lucas, J., David, V., Le Brun, M., Bertola, D.R., David, A.,
306 Belaud-Rotureau, M.-A., Mosser, J., Lazaro, L., Treguier, C., Rosenberg, C., Odent, S., Dubourg, C.,
307 2011. 5q12.1 deletion: delineation of a phenotype including mental retardation and ocular defects.
308 *Am. J. Med. Genet. A.* 155A, 725–731. <https://doi.org/10.1002/ajmg.a.33758>

309 Jang, W., Chae, H., Kim, J., Son, J.-O., Kim, S.C., Koo, B.K., Kim, M., Kim, Y., Park, I.Y., Sung, I.K., 2016.
310 Identification of small marker chromosomes using microarray comparative genomic hybridization
311 and multicolor fluorescent in situ hybridization. *Mol. Cytogenet.* 9.
312 <https://doi.org/10.1186/s13039-016-0273-5>

313 Kulikowski, L.D., Christ, L.A., Nogueira, S.I., Brunoni, D., Schwartz, S., Melaragno, M.I., 2006. Breakpoint
314 mapping in a case of mosaicism with partial monosomy 9p23 → pter and partial trisomy 1q41 →
315 qter suggests neo-telomere formation in stabilizing the deleted chromosome. *Am. J. Med. Genet.*
316 *A.* 140A, 82–87. <https://doi.org/10.1002/ajmg.a.31045>

317 Lenzini, E., Leszl, A., Artifoni, L., Casellato, R., Tenconi, R., Baccichetti, C., 1988. Partial duplication of 17 long
318 arm. *Ann. Genet.* 31, 175–180.

319 Li, C., Chen, B., Zheng, J., Cheng, L., Song, T., Guo, F., Xu, H., Yan, F., Xu, Y., Li, Y., Zhang, J., 2019. Prenatal
320 Diagnosis of BACs-on-Beads Assay in 3647 Cases of Amniotic Fluid Cells. *Reprod. Sci. Thousand Oaks*
321 *Calif* 26, 1005–1012. <https://doi.org/10.1177/1933719118804416>

322 LI, H., LI, Y., ZHAO, R., ZHANG, Y., 2019. Cytogenetic Analysis of Amniotic Fluid Cells in 4206 Cases of High-
323 Risk Pregnant Women. *Iran. J. Public Health* 48, 126–131.

324 Lin, S.-Y., Lee, C.-N., Peng, A.-Y., Yuan, T.-J., Lee, D.-J., Lin, W.-H., Ma, G.-C., Chen, M., 2018. Application of
325 molecular cytogenetic techniques to characterize the aberrant Y chromosome arising de novo in a
326 male fetus with mosaic 45,X and solve the discrepancy between karyotyping, chromosome
327 microarray, and multiplex ligation dependent probe amplification. *J. Formos. Med. Assoc. Taiwan Yi*
328 *Zhi* 117, 1027–1031. <https://doi.org/10.1016/j.jfma.2018.04.011>

329 Liu, Q., Karolak, J.A., Grochowski, C.M., Wilson, T.A., Rosenfeld, J.A., Bacino, C.A., Lalani, S.R., Patel, A.,
330 Breman, A., Smith, J.L., Cheung, S.W., Lupski, J.R., Bi, W., Stankiewicz, P., 2020. Parental somatic
331 mosaicism for CNV deletions - A need for more sensitive and precise detection methods in clinical
332 diagnostics settings. *Genomics* 112, 2937–2941. <https://doi.org/10.1016/j.ygeno.2020.05.003>

- 333 Malvestiti, F., Agrati, C., Grimi, B., Pompilii, E., Izzi, C., Martinoni, L., Gaetani, E., Liuti, M.R., Trotta, A.,
 334 Maggi, F., Simoni, G., Grati, F.R., 2015. Interpreting mosaicism in chorionic villi: results of a
 335 monocentric series of 1001 mosaics in chorionic villi with follow-up amniocentesis. *Prenat. Diagn.*
 336 35, 1117–1127. <https://doi.org/10.1002/pd.4656>
- 337 Pipiras, E., Dupont, C., Chantot-Bastaraud, S., Siffroi, J.P., Bucourt, M., Batallan, A., Largillière, C., Uzan, M.,
 338 Wolf, J.P., Benzacken, B., 2004. Structural chromosomal mosaicism and prenatal diagnosis. *Prenat.*
 339 *Diagn.* 24, 101–103. <https://doi.org/10.1002/pd.797>
- 340 Popovic, M., Dhaenens, L., Boel, A., Menten, B., Heindryckx, B., 2020. Chromosomal mosaicism in human
 341 blastocysts: the ultimate diagnostic dilemma. *Hum. Reprod. Update* 26, 313–334.
 342 <https://doi.org/10.1093/humupd/dmz050>
- 343 Ruiz-Herrera, A., García, F., Mora, L., Egozcue, J., Ponsà, M., Garcia, M., 2005. Evolutionary conserved
 344 chromosomal segments in the human karyotype are bounded by unstable chromosome bands.
 345 *Cytogenet. Genome Res.* 108, 161–174. <https://doi.org/10.1159/000080812>
- 346 Serotkin, A., Stamberg, J., Waber, L., 1988. Duplication 17q mosaicism: an infant with features of Ellis-van
 347 Creveld syndrome. *J. Med. Genet.* 25, 258–260. <https://doi.org/10.1136/jmg.25.4.258>
- 348 Sifakis, S., Koukoura, O., Mantas, N., Velissariou, V., Koumantakis, E., 2008. Hydrops fetalis, thickened
 349 placenta and other sonographic findings in a low-level trisomy 21 mosaicism: a case report. *Fetal*
 350 *Diagn. Ther.* 24, 310–312. <https://doi.org/10.1159/000160218>
- 351 Stallings, R., Vaughn, D., Hall, K., Joyce, C., Ryan, F., Barton, D., Geraghty, M., 1997. Mosaicism for trisomy
 352 3q arising from an unbalanced, de novo t(3;15). *J. Med. Genet.* 34, 512–514.
 353 <https://doi.org/10.1136/jmg.34.6.512>
- 354 Taylor, T.H., Gitlin, S.A., Patrick, J.L., Crain, J.L., Wilson, J.M., Griffin, D.K., 2014. The origin, mechanisms,
 355 incidence and clinical consequences of chromosomal mosaicism in humans. *Hum. Reprod. Update*
 356 20, 571–581. <https://doi.org/10.1093/humupd/dmu016>
- 357 Tidrenczel, Z., Tardy, E.P., Pikó, H., Sarkadi, E., Böjtös, I., Demeter, J., Simon, J., Kósa, J.P., Beke, A., 2019.
 358 Prenatal Diagnosis of 4q Terminal Deletion and Review of the Literature. *Cytogenet. Genome Res.*
 359 158, 63–73. <https://doi.org/10.1159/000500735>
- 360 Tuke, M.A., Ruth, K.S., Wood, A.R., Beaumont, R.N., Tyrrell, J., Jones, S.E., Yaghootkar, H., Turner, C.L.S.,
 361 Donohoe, M.E., Brooke, A.M., Collinson, M.N., Freathy, R.M., Weedon, M.N., Frayling, T.M.,
 362 Murray, A., 2019. Mosaic Turner syndrome shows reduced penetrance in an adult population
 363 study. *Genet. Med. Off. J. Am. Coll. Med. Genet.* 21, 877–886. [https://doi.org/10.1038/s41436-018-](https://doi.org/10.1038/s41436-018-0271-6)
 364 [0271-6](https://doi.org/10.1038/s41436-018-0271-6)
- 365 Vanneste, E., Voet, T., Le Caignec, C., Ampe, M., Konings, P., Melotte, C., Debrock, S., Amyere, M., Vikkula,
 366 M., Schuit, F., Fryns, J.-P., Verbeke, G., D’Hooghe, T., Moreau, Y., Vermeesch, J.R., 2009.
 367 Chromosome instability is common in human cleavage-stage embryos. *Nat. Med.* 15, 577–583.
 368 <https://doi.org/10.1038/nm.1924>

370 LEGENDS TO FIGURES

371 **Figure 1:** Fetal karyotype on cultured amniocytes demonstrating the co-existence of 2 cell lines in the fetus.
 372 Panel (A): karyotype of a metaphase with the del(4)(q33), indicated by the arrow. Panel B: karyotype of a
 373 metaphase with the der(4)t(4;17)(q33;q11) chromosome, indicated by the arrow.

374
 375 **Figure 2:** aCGH profile obtained from frozen fetal muscle DNA. Panel (A): 4q33qter non-mosaic
 376 heterozygous loss. Panel (B): normal chromosome 17 profile.

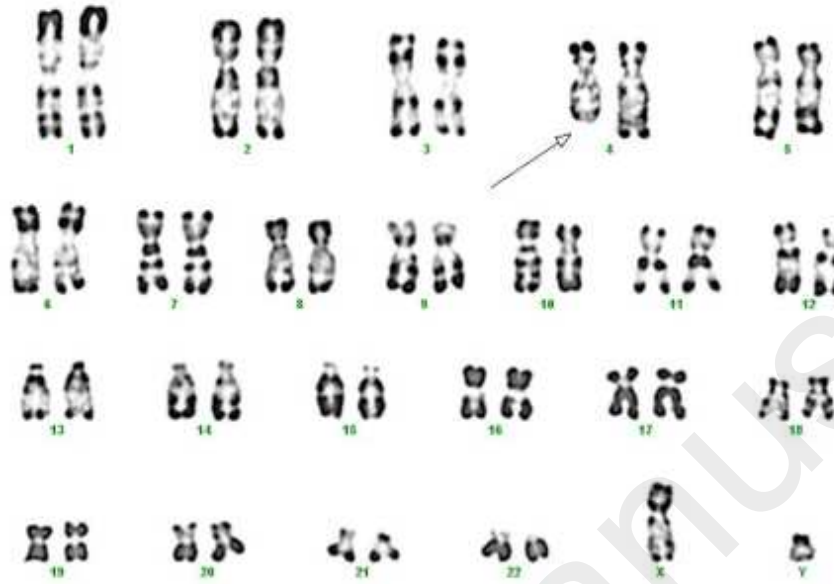
377
 378 **Figure 3:** M-FISH results on cultured amniocytes. Panel (A): karyotype of a metaphase with the del(4)(q33).
 379 Panel (B): karyotype of a metaphase with the der(4)t(4;17)(q33;q11) chromosome.

380

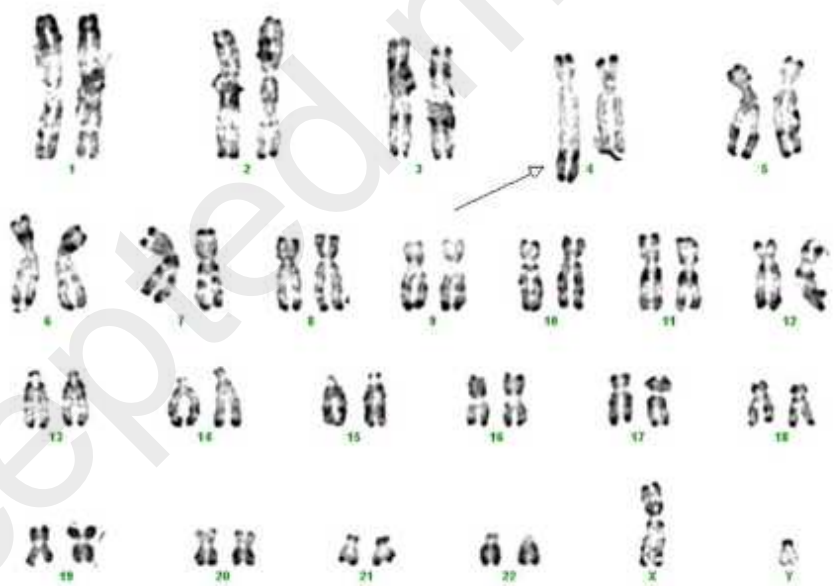
381 **Figure 4:** Schematic representation of the hypothesized mechanisms leading to the mosaic chromosomal
382 rearrangement. Pane (A): der(4)t(4;17) breakage and neotelomere formation. Pane (B): DSB at
383 chromosome 4q33 and aberrant MMBIR using a chromosome 17 template. Pane (C): t(4;17) with
384 formation of a dicentric der(4) and loss of the der(17) acentric fragment, followed by secondary der(4)
385 breakage in one cell line. Pane (D): chromoanagenesis. Fragmentation of one chromosome 4 and one
386 chromosome 17. Chromoanagenesis rescue generates a major cell line with a fully recovered chromosome
387 17 and an isolated 4qter deletion, and a minor cell line where the long arm of chromosome 17 replaces the
388 4qter segment. The 4qter segment and chromosome 17 short arm are lost and the monosomy 17 is
389 rescued.
390

Figure 1

A



B

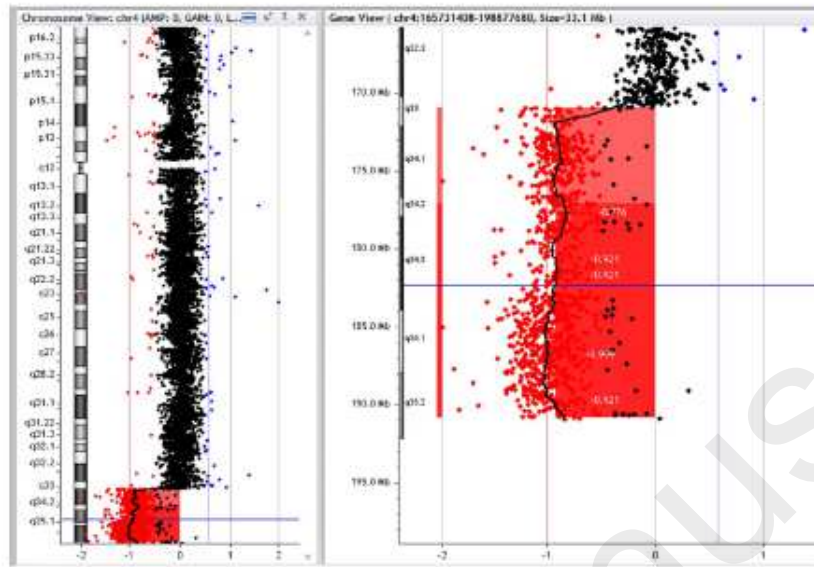


391

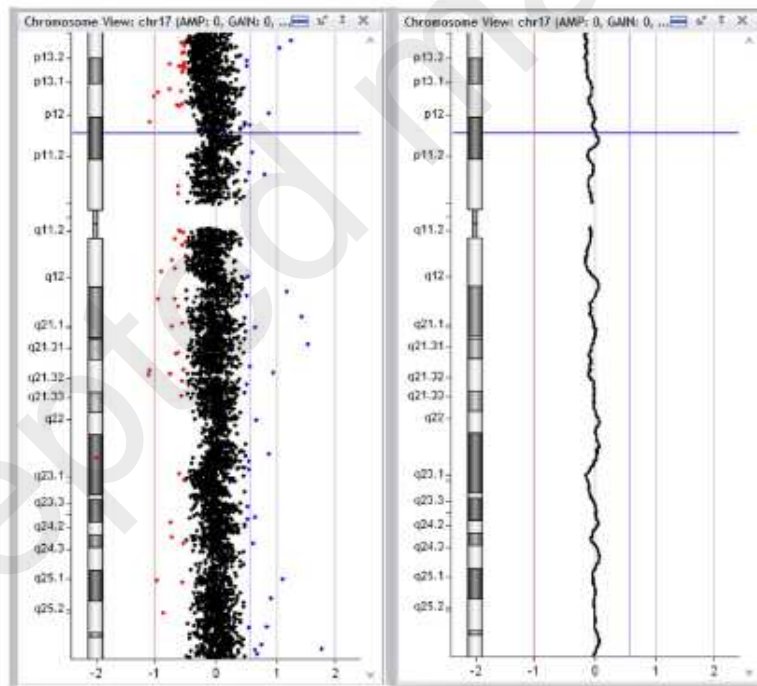
392

Figure 2

A



B

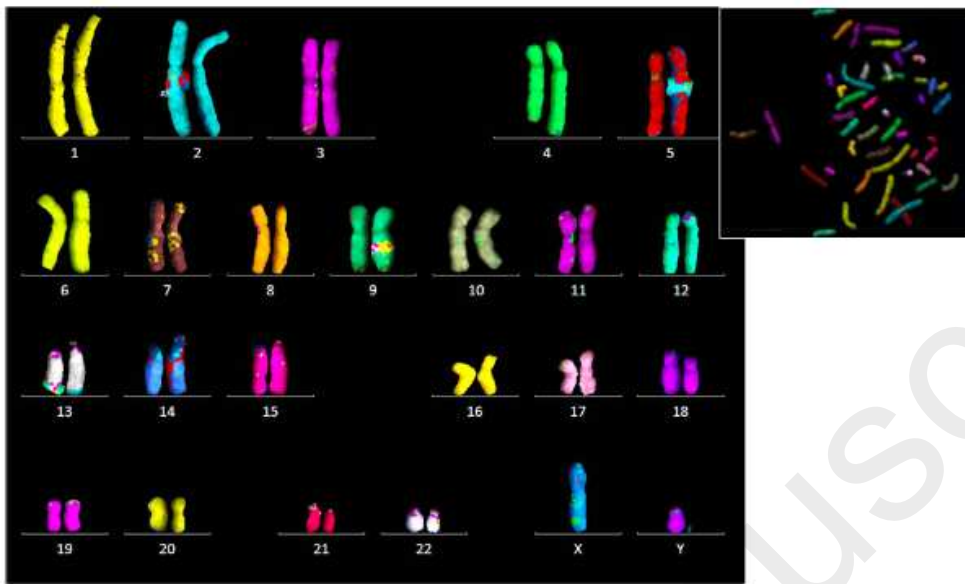


393

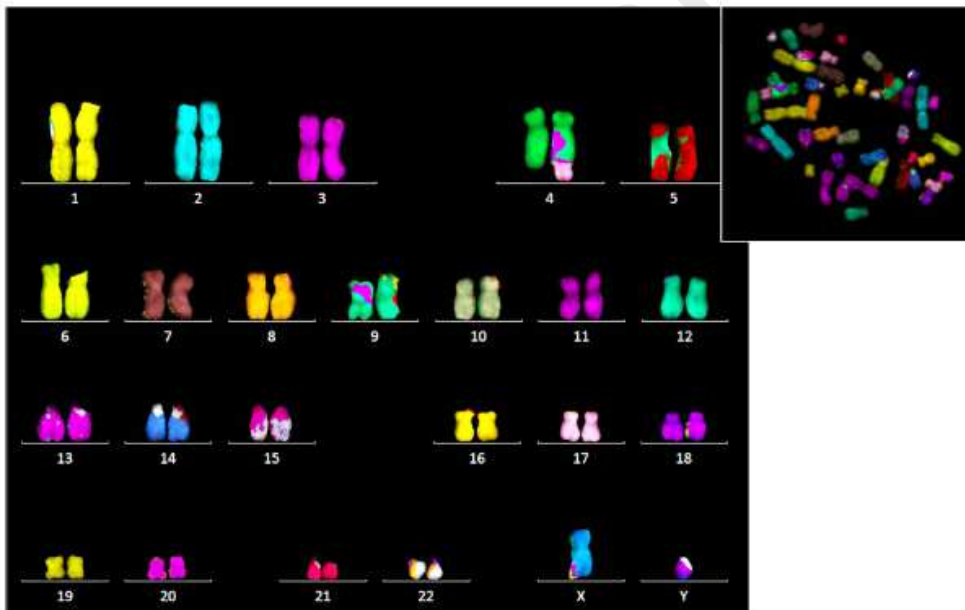
394

Figure 3

A



B



395

396

Figure 4

