



**HAL**  
open science

## Functional anatomy of the frontal aslant tract and surgical perspectives.

Eléonor Burkhardt, Masashi Kinoshita, Guillaume Herbet

► **To cite this version:**

Eléonor Burkhardt, Masashi Kinoshita, Guillaume Herbet. Functional anatomy of the frontal aslant tract and surgical perspectives.. *Journal of Neurosurgical Sciences*, 2021, 10.23736/S0390-5616.21.05344-3 . hal-03205920v1

**HAL Id: hal-03205920**

**<https://hal.science/hal-03205920v1>**

Submitted on 1 Apr 2022 (v1), last revised 5 Apr 2022 (v2)

**HAL** is a multi-disciplinary open access archive for the deposit and dissemination of scientific research documents, whether they are published or not. The documents may come from teaching and research institutions in France or abroad, or from public or private research centers.

L'archive ouverte pluridisciplinaire **HAL**, est destinée au dépôt et à la diffusion de documents scientifiques de niveau recherche, publiés ou non, émanant des établissements d'enseignement et de recherche français ou étrangers, des laboratoires publics ou privés.

# **Functional anatomy of the frontal aslant tract and surgical perspectives**

Running title: **Functional anatomy of the frontal aslant tract**

Eléonor BURKHARDT<sup>1</sup>, Masashi KINOSHITA<sup>2</sup>, Guillaume HERBET<sup>3,4</sup>

1 Praxiling, CNRS UMR 5267, Paul Valéry Montpellier 3 University, Montpellier, France

2 Department of Neurosurgery, Kanazawa University, Kanazawa, Ishikawa, Japan

3 University of Montpellier, CNRS UMR5203, INSERM U1191, Institute of Functional Genomics, Montpellier, France

4 Gui de Chauliac Hospital, Montpellier University Medical Center, Department of Neurosurgery, Montpellier, France

To whom correspondence should be addressed:

Guillaume Herbet

Guillaume.herbet@gmail.com

Institute of Functional Genomics

141, Rue de La Cardonille

34094 Montpellier

Abstract word count: 250

Main text word count:

Number of Figures: 5

Number of Tables: 0

## **Abstract**

The frontal aslant tract (FAT) is an intralobar white matter fasciculus providing dense connections between the medial part of the superior frontal gyrus, in particular the pre-supplementary motor area (SMA) and the SMA proper, and the lateral part of the frontal lobe, especially the inferior frontal gyrus. Although this tract has been characterized belatedly, it has received important attention in recent years due notably to its increasingly evidenced role in the speech and language networks. As cerebral tumors frequently affect the frontal lobe, an improved knowledge of the functional anatomy of the FAT is mandatory to refine the way neurosurgeries are performed and to give the patients the best opportunities to recover after surgery. In this work, we first describe the spatial arrangement of the FAT and detail its cortical projections. We then provide a comprehensive review of the functions supposedly mediated by this transverse frontal connectivity. It is structured following a tripartite organization where the linguistic (i.e. speech and language), supralinguistic (i.e. functions that interact with speech and language: executive functions, working memory, and social communication) and extralinguistic implications (i.e. functions outside the linguistic domain: visuospatial processing, praxis and motor skills) are successively addressed. We lastly discussed this knowledge in the context of wide-awake neurosurgeries for brain tumors. We emphasize the need to evaluate thoroughly the functions conveyed by FAT by means of longitudinally-designed studies to first estimate its plasticity potential and then to determine which tasks should be selected to avoid lasting impairments due to its disconnective breakdown.

**Keywords:** Frontal aslant tract, frontal connectivity, speech, language, executive functions, electrostimulation mapping, glioma, awake surgery

## Introduction

As white matter fiber tracts are increasingly viewed as critical building blocks of functional networks<sup>1,2</sup>, an improved knowledge of both their spatial organization and their putative functions is a vital step to provide accurate models of the neural circuitry underlying complex neurocognitive systems<sup>3</sup>. This knowledge is also crucial for neurosurgeons performing on a regular basis surgical resections of brain tumors spreading in the white matter connectivity, as it is mostly the case in the context of diffusive neoplasms such as low-grade or high-grade glioma. This is all the more true since white matter connections are reputed to be less prone to functional compensation contrary to the majority of the associative cortex<sup>4,5</sup>. This is likely due to their highly distributive (i.e. functional integration between anatomically remote cortical areas) and redistributive (i.e. involved in the redeployment of functional connectivity in the event of cerebral damage) roles within the anatomofunctional architecture<sup>3</sup>. As a consequence, white matter tracts have to be the target of special attention, as their disruption may result in irrevocable disconnection-related neuropsychological impairments – as previously evidenced in the context of low-grade glioma surgery<sup>6,7</sup>.

The frontal aslant tract (FAT) is no exception to this rule, though this white matter connectivity is to date less known than others due to its relatively late identification<sup>8</sup>. To better identify and eventually spare this tract, we first need to have a precise idea of both its spatial arrangement and its connective properties. Although it was already delineated in previous diffusion imaging and anatomical dissection studies,<sup>9-11; see also 12</sup> the FAT was termed later as such in a tractography work by Catani and colleagues (2012)<sup>13</sup> because “*this tract has an oblique course from the medial-superior to the inferior-lateral region.*” In a general way, it is accepted that the FAT provides dense connections between the complex pre-SMA/SMA proper and the inferior frontal gyrus, especially *pars opercularis* and to a lesser extent *pars triangularis*. However, as we will see in the next section, this general conception is currently evolving to include most widespread cortical projections. Second, we need to have a relatively clear picture of the functions that might be broadcasted by the FAT. It is relatively known that it conveyed information related to different aspects of verbal fluency in the left

hemisphere. However, new evidence suggests a potential role in functions modulating speech and language (e.g. executive functions) and in functions outside the linguistic domain.

In this work, we first describe in a comprehensive way the anatomical properties of the FAT. We then provide an in-depth review of the functions supposedly mediated by this transverse frontal connectivity. It is structured following a tripartite organization where the linguistic (i.e. speech and language, especially verbal fluency), supralinguistic (i.e. functions that interact with speech and language: executive functions, and working memory, social communication) and extralinguistic implications (i.e. functions outside the linguistic domain: visuospatial processing, praxis and motor skills) are successively addressed. We lastly discussed this knowledge in the context of wide-awake neurosurgeries for brain tumors. In this context, we emphasize the urgent need to evaluate thoroughly the functions conveyed by FAT by means of longitudinally-designed studies to first estimate its plasticity potential and then to determine which tasks should be selected to avoid lasting impairments due to its disconnective breakdown.

It is worth mentioning that a review of the FAT and its role in speech and executive functions has been already provided two years ago<sup>8</sup>. However, as the field is rapidly evolving with recent important findings, we feel the current review as a good adjunct with in addition clinical perspectives.

## **Spatial course and connective properties of the FAT**

### *First works on a possible direct, lateral-to-medial intralobar frontal connection*

In humans, the first description of a potential white matter pathway interconnecting the inferior frontal cortex with the medial superior frontal cortex has its origins in the work by Aron and colleagues (2007)<sup>14</sup>. Using probabilistic tractography in an attempt to determine the anatomical network that may underlie cognitive control in the prefrontal cortex, they found a direct connection between pre-SMA and the inferior frontal gyrus in 8 of 10 participants. A little later, in a validation study comparing diffusion-based tractography and post-mortem anatomical dissection, “*a track connecting the superior frontal gyrus and the pars triangularis of the inferior frontal gyrus*” was found using both anatomical approaches. However, the projective connections of the tract targeted the lateral part of the superior

frontal gyrus rather than the SMA, and in some subjects a supplementary component projecting in the posterior dorsolateral prefrontal cortex was revealed<sup>9</sup>. In a further diffusion tensor imaging (DTI) study based on the data from 81 participants and using a cortical parcellation composed of nine large “blade-like” anatomical regions commonly shared across participants, the authors found long and short cortico-cortical association fibers connecting the blades together; among them, a fiber pathway interconnecting the inferior frontal gyrus with the superior frontal gyrus termed “*frontal short association fibers*”<sup>12</sup>. In another DTI study specifically focusing on the white matter connectivity between Broca’s area (i.e. *pars triangularis* and *pars opercularis* in the left hemisphere) and the medial frontal cortex, direct connections were found again<sup>10</sup>. Interestingly, based on a parcellation of Broca’ area, an anterior-to-posterior gradient was identified, within which the anterior part of Broca’ area was connected to BA8 and BA9, whereas its posterior part was rather connected with the pre-SMA and SMA proper, albeit with some individual differences across the nine participants. This suggested the authors that this frontal connection may be layered, and that each of these layers may mediate different language functions.

A work by Kinoshita and colleagues (2012)<sup>11</sup> has then provided important insight into the possibility of a direct pathway between the lateral and dorsomedial aspects of the frontal lobe. In the first part of their study, the authors used postmortem anatomical dissection in eight specimens and found in all of them a bundle of white matter fibres originating from *pars triangularis* and *pars opercularis* (not from *pars orbitalis*) and ending in the lateral part of the superior frontal gyrus. This finding of a “*Broca-LSFG pathway*” was replicated in the second part of the study with *in vivo* tractography performed in 51 participants. Further analyses indicated that the tract was more widespread in the left hemisphere, and presented a leftward asymmetry in right-handed participants. The failure to observe cortical projections in the medial part of the superior frontal gyrus was explained by the procedure used to follow white matter fibres during the *ex vivo* (i.e. lateral-to-medial approach) and *in vivo* dissection (i.e. the used tractography algorithm was not optimized to appropriately tracked crossing and kissing fibers).

### *The modern definition of the FAT*

The new term of “*Frontal aslant tract*” was coined in a study by the Catani’s group (2012)<sup>13</sup> where the main aim consisted of mapping the short white matter connections of the entire frontal lobe. This study was conducted with HARDI (high angular resolution diffusion imaging) optimized for spherical deconvolution and based on the datasets of 12 right-handed healthy individuals. A *post-mortem* dissection was also achieved using the Klingner method in an 80 year-old patient at the time of death. The authors substantiated the evidence of a system of oblique fibers connecting together the posterior parts of the inferior and superior frontal gyri. More specifically, cortical endings were found, medially, in both the anterior part of the SMA proper and in the pre-SMA; inferiorly, in *pars opercularis* of the inferior frontal gyrus. Cortical projections were also identified, but in a much less extent, in *pars triangularis* and the ventral premotor cortex. Here again, a leftward asymmetry was found for the FAT. The existence of fibres interconnecting the medial frontal gyrus (most notably at the junction between pre-SMA and SMA-proper) with *pars opercularis* was confirmed in an anatomical dissection work (twelve hemispheres dissected) focusing on the connective architecture of the SMA in general<sup>15</sup>.

In another study aimed at better characterizing the cortical projections of the FAT in the inferior frontal gyrus, DTI-based tractography were performed in 49 participants (98 hemispheres). The authors confirmed the leftward asymmetry of the FAT in the majority of individuals, and showed that projections of the tract reached predominantly *pars opercularis* (88.9% of cases)<sup>16</sup>.

In a series of three successive studies<sup>17-19</sup>, the same research group proposed a more extended version of the FAT. In particular, on the basis of the HCP dataset, the authors found cortical projections more anteriorly in the superior frontal gyrus, beyond the anterior limit of the pre-SMA. They also suggest the possibility of different segments that may be concerned with distinct cognitive functions (see below).

Finally, a recent work based again on the diffusion data of the HCP (10 participants) offered a wider view of the connective properties of the FAT. In particular, the authors used different parcels of

the superior frontal gyrus as seeds for generating streamline tractography. On the one hand, cortical projections were identified in SMA proper, pre-SMA and the posterior and lateral part of the superior frontal gyrus; on the other hand, cortical projections were evidenced not only in different sectors of *pars opercularis* but also in the anterior part of the ventral precentral gyrus and the insula<sup>20</sup>. Other isolated studies, reviewed by Dick et al. (2019)<sup>8</sup> thoroughly, suggest a possible cortical projection in the cingulate gyrus.

To close this section, evidence about an oblique and direct connection between the medial and inferior parts of the frontal lobe have been accumulating over the years (Figure 1 for a tractography reconstruction of the FAT). Nevertheless, disagreements remain on the precise cortical projections of the tract. While it is increasingly established that the FAT share connections between *pars opercularis* and the complex pre-SMA/SMA proper, it remains unclear whether it targets other cortical structures, such as the ventral premotor cortex, the insula, the postero-lateral and the middle part (anterior to pre-SMA) of the superior frontal gyrus (See Figure 2 for a wiring diagram of established and discussed cortical projections of the FAT). Moreover, a detailed picture of the inter-individual variability in the tract projections is still lacking. Finally, works are needed to ascertain the extent to which the FAT may be layered in distinct segments possibly concerned with different cerebral processes.

### *Age-related development of the FAT*

Although there is an increasing number of studies modeling the development of white matter tracts across the lifespan, to the best of our knowledge none of them has included the FAT in their analyses. The only available data comes from the study of Garic et al. (2018)<sup>24</sup>, the goal of which was to ascertain the association between the development of FAT (from 7 months to 19 years) and executive functions and externalizing behaviors. The authors specifically focused on the connection between *pars opercularis* and pre-SMA, and showed that age-related difference in white matter (as assessed with fractional anisotropy) occurred rapidly during the first 6-years, plateaued until the age of 11 years (see also <sup>25</sup>, for the 5-8 age range), and then increased up to 20 years, approximatively.



### *Comparative anatomy of the FAT*

The FAT does not appear to be specific to humans, as monkeys show a very similar fiber connection. For example, in a comparative study, Thiebaut de Schotten and colleagues (2012)<sup>26</sup> compared the FAT tracked from a 29-year old healthy participant with spherical deconvolution tractography with the FAT reconstructed from a monkey (Case 25 from Schmahmann and Pandya, 2006<sup>27</sup>) using post-mortem axonal tracing. The spatial arrangement and the cortical projections across species were quite similar. Consistent with previous literature, the human FAT emerged from *pars opercularis* and terminated in SMA proper (BA 6) and Pre-SMA (BA 8). The monkey FAT showed the same oblique directionality. It was found to connect areas 44 and 6V to areas 6D and 8B. This is consistent with a previous work performed by Petrides and Pandya (2001)<sup>28</sup> in macaque monkey who showed connections in the medial frontal cortex (mainly areas 8B, 6DR and 9) when different sectors of area 45 and the caudal part of area 47/12 were serving as injection sites. In a more recent work focusing on the connectivity pattern of areas 44 and 45B, Frey and colleagues (2013)<sup>29</sup> confirmed that area 45B projected on area 8B, medially. However, no such a connectivity was found when tracers were injected in different sectors of area 44. All and all, humans and simians appear to share a transverse frontal pathway between the inferior-lateral and the medial frontal cortex, with possible dissimilarities in terms of cortical projections.

### **Putative functions of the FAT**

In this section, we provide a comprehensive review of the putative functions mediated by the FAT. The main findings emerge from works conducted with various populations, including healthy adult individuals<sup>14,30,31,17, 32, 19</sup> and children<sup>25, 24</sup> as well as patients presenting with brain tumors<sup>33-45</sup> or post-stroke aphasia<sup>46-48</sup>. A significant part of these studies also included patients with neurodegenerative diseases, in particular primary progressive aphasia<sup>49-51</sup>, Alzheimer's disease<sup>52</sup>, parkinsonian syndrome<sup>53</sup>

or multiple sclerosis<sup>54-55</sup>. Patients with developmental stuttering<sup>56-57</sup> or autism spectrum disorder (ASD) and/or unaffected siblings<sup>58-62</sup> have been also the target of frequent investigations.

From a methodological standpoint, studies focusing on this anatomical connectivity have generally used multimodal approaches, especially the combination of various MRI techniques with neuropsychological evaluations<sup>e.g. 25, 49-51, 59</sup>, direct electrical stimulation during awake surgery<sup>e.g. 34, 35, 38, 36</sup>, corticocortical evoked potentials<sup>63, 39</sup> and graph theory modeling<sup>51, 62</sup>. The neuropsychological tasks were selected by the authors according to their hypotheses, assuming the involvement of the FAT in wide array of cerebral processes including language<sup>e.g. 46, 44, 32</sup> and executive functions, attention<sup>e.g. 24, 45</sup>, working memory<sup>30, 17, 19</sup> and social cognition<sup>60, 61</sup>; visual and visuospatial processing<sup>31, 59, 52</sup>, visuo-constructive praxis<sup>52</sup> and manual motor skills<sup>31</sup>.

In the following, we draw up a complete inventory of the functions being supposedly supported by the FAT. In view of the current literature, we propose to segregate its functions according to three main domains. The first one is related to the FAT's linguistic component as the majority of works suggests a role in language and speech, explaining why the tract is frequently found to be lateralized to the left hemisphere. More precisely, we will see that the linguistic roles of the FAT are essentially linked to verbal fluency irrespective of the cognitive level considered (i.e. a high level corresponds to selection and verbal planning while a low level corresponds to initiation, motor execution and articulation) and the behavioral tasks used. The second one concerns the supralinguistic functions underpinned by the FAT, i.e. which co-exist and can interact with language and speech. This groups together its possible roles in social communication<sup>64, 60, 61</sup> and in executive functions (frequently linked to language and speech<sup>e.g. 59</sup>), attention<sup>24</sup> and working memory<sup>30, 17, 19</sup>. The third one is about the extralinguistic functional correlates of the FAT. This includes visual<sup>59</sup> and visuospatial processes<sup>52, 31</sup> as well as visuo-constructive praxis<sup>52</sup> and manual skills and motor control<sup>32, 42</sup>.

### *Linguistic functions: language production and verbal fluency*

Overall, studies investigating FAT linguistic functions reveal a contribution of the tract in the expressive component of language rather than in the receptive one. Indeed, apart from a very few

observations suggesting a role in lexical decision<sup>32</sup> and language comprehension in both children<sup>25</sup> and healthy individuals<sup>17, 19</sup>, the vast majority of works converge towards the idea of a critical implication in language production, particularly in verbal fluency considered from various aspects<sup>e.g. 49, 46, 56</sup>. In addition, several studies challenge the possible implication of FAT in language comprehension<sup>49, 50, 40</sup>. Before elaborating further on the functional implications of FAT in verbal fluency, we first discuss about the functional lateralization of the FAT.

*Linguistic functions of the FAT are mainly lateralized on the left*

In view of the commonly accepted functional lateralization of language in the left hemisphere, it is intuitive to think that the FAT's language functions are also lateralized to the left, more especially as the FAT appears to be structurally characterized by a leftward asymmetry<sup>13, 11, 15, 17</sup>. It is indeed the case: the left lateralization of the FAT for language functions has been supported by a range of anatomo-functional studies performed with neurosurgical<sup>33-44</sup> or stroke patients<sup>46-48</sup>, or with patients suffering either from the (non-fluent) primary progressive aphasia<sup>49-51</sup> or developmental stuttering<sup>56</sup>.

In the literature, however, there are a few counter-examples that do not support this functional lateralization. Varriano et al. (2020)<sup>19</sup> observed, for example, a correlation between the integrity of the right FAT (and not of the left FAT) and language comprehension. In the same way, whereas Blecher et al. (2019)<sup>54</sup> identified a correlation between semantic fluency and fractional anisotropy within the FAT bilaterally, Keser et al. (2020)<sup>55</sup> found the same bilateral correlation but with phonological fluency – both studies being performed in multiple sclerosis patients. These results echo those of Li et al. (2017)<sup>47</sup> in which the volume of the right FAT correlated with performance in terms of semantic fluency (note however that only one out of three categories correlated), an association which is also observed in patients with minimally verbal ASD children<sup>58</sup>.

In adults who stutter, the right FAT appears to be related to verbal fluency difficulties<sup>57</sup>. In this study, the connection strength in this fiber pathway (among others), especially when seeding in the right inferior frontal gyrus, was associated with stuttering severity. Another study performed with electrostimulation mapping reported the case of a patient in whom a Foix-Chavany-Marie syndrome (i.e. anarthria accompanied by bilateral facial hypotonia) was evoked following stimulation of the right

FAT<sup>33</sup>. In the study by Kinoshita et al (2015), intraoperative stimulation of the right fat often elucidated speech inhibition but did not cause postoperative speech disturbance in the right hemisphere.<sup>36</sup>

### *Fluency or Fluencies? A multi-level process*

Despite the various neurological conditions (surgical pathologies, developmental stammering, post-stroke aphasia, and so on) in which anatomo-functional correlations were performed, most of the studies greatly converge towards an implication of the FAT in verbal fluency. However, these studies have employed a wide variety of neuropsychological tasks to behaviorally assess this ability. This includes standard phonological and semantic fluency tasks<sup>47, 54, 55</sup>, image description<sup>49, 46, 50, 40</sup>, sentence completion<sup>48</sup> but also noun naming<sup>38</sup> or action naming<sup>44</sup>, unstructured interview<sup>56</sup>, morpho-syntactic derivation<sup>37</sup> and even description of spatial relationships between geometric shapes<sup>41</sup>. As these tasks differ in their construct, they are likely to tap into different aspects of verbal fluency. For example, it is somewhat inaccurate to conclude that patients with developmental stuttering, in whom verbal fluency has been previously assessed with unstructured interviews<sup>e.g. 56</sup>, show the same fluency difficulties as patients with multiple sclerosis evaluated with semantic and phonological fluency tasks<sup>e.g. 47</sup>. To assess verbal fluency, some authors take into account the number of syllables produced per second<sup>56</sup> or the number of words per sentence (i.e. the mean length of utterance)<sup>49, 40</sup>, sometimes associated with the number of speech distortions<sup>50</sup>. Catani et al. (2013)<sup>49</sup> also took into account the number of words produced per minute, as it is also usual to do when evaluating phonological and semantic fluencies<sup>47, 54, 55</sup>. Furthermore, subjective assessment scales<sup>46</sup>, eventually specific to the assessment of stuttering<sup>57</sup>, have been also used. It seems then that the assessed functions are not superimposable on each other. In brief, we should bear in mind that the tasks and indices used to assess verbal fluency does not exactly measure the same thing.

In a general way, speech fluency is the ability of a speaker to produce utterances without breaks or unintentional interruptions, with continuous transitions between sounds and syllables, while maintaining a relatively fast rate<sup>65</sup>. A fluent speech therefore supposes extensive knowledge of the

spoken language, from the viewpoint of its morphological, lexical, syntactic, phonological structures... so that the speaker can express his thoughts without any particular effort. From a physiological standpoint, maintaining fluent speech requires precise control of the respiratory system, the larynx and the activity taking place in the supraglottic cavities (tongue, lips, soft palate etc.)<sup>66</sup>. In other words, fluency depends on the constant control of the air flow during which laryngeal and articulatory events take place, the whole having to be carried out in a very precise timing<sup>67</sup>. It is therefore understood that fluency refers to aspects relating to the motor skills of speech, focused on the articulation of phonemes (i.e. execution of speech, motor control, coordination of articulatory patterns) as well as aspects related to language cognition (lexical selection, syntactic planning, etc.). Regarding the FAT, it seems that it is involved in these two components of verbal fluency which would be potentially mediated by different white matter subnetworks within the FAT.

In this respect, some authors suggest the existence of an anterior-to-posterior functional gradient in the white matter organization of the FAT. Its posterior part, connecting the inferior part of the precentral gyrus and *pars opercularis* to the junction between preSMA and the SMA proper, would be involved in the motor speech network while its anterior part, connecting *pars triangularis* to the preSMA would be rather involved in the lexico-semantic network<sup>42</sup>. This possible organization was inferred on the basis of the rostro-caudal distribution of errors evoked by direct electrostimulation correlated with disconnection maps. Stimulation of the anterior part of the FAT - but also of the FST - were associated with lexico-semantic difficulties (anomias, semantic paraphasias, perseverations, semantic pairing errors) while stimulation of the posterior part of both the FST and FAT were rather associated with disturbed speech processing (speech arrests – along or not with the arrest of movement of the upper limb -, stammering, vocalizations). However, this organization remains to be firmly established as the dorsolateral fibers of the inferior fronto-occipital fasciculus – this tract being involved in semantic cognition<sup>68, 69</sup> – is very close to the FAT.

#### FAT and lower-level aspect of verbal fluency

With regards to the role of FAT in aspects of speech initiation and execution, a number of studies conducted with electrostimulation mapping in wide-awake surgery has demonstrated motor speech

suspensions (also termed speech inhibitions or speech arrests) during inactivation of the tract in the left hemisphere<sup>34-39, 42</sup>. Furthermore, Kermedere et al. (2016)<sup>38</sup> showed that stimulation of the left FAT caused stuttering (repetitions, blockages and prolongations), in agreement with another study showing an association between diminished FAT integrity and speech fluency reduction in patients with developmental stuttering<sup>56</sup>. In addition, Young et al. (2019)<sup>43</sup> reported the onset of transcortical motor aphasia (i.e. initiation disturbances and speech hesitations along with picture naming deficits) following resection of the left FAT in a patient operated on for a low-grade glioma under general anesthesia; these clinical manifestations were nevertheless transient. Finally, and most importantly, Kinoshita et al. (2015)<sup>36</sup> showed that stimulation of left FAT (no the right) caused inhibition of speech (Figure 3). Using measurements of the distance between surgical cavity and FAT location determined with DTI-based tractography, the authors also observed that resections very close to the left FAT were associated with postoperative speech initiation disorders. Lastly, postoperative performances in semantic and phonological fluency were found to correlate with the average distance between surgical cavity and FAT (the same correlations were observed for the FST). The authors proposed that the FAT, in association with the FST, may be part of the self-initiated movement and speech network.

#### FAT and higher-level aspect of verbal fluency

Here we describe the studies that support a potential involvement of the FAT in lexico-semantic and syntactic aspects of verbal fluency. In a stimulation mapping study, a patient harboring a low-grade glioma was asked to produce verb-based noun by means of the expected semantic association<sup>37</sup>. Following stimulation of left FAT, the authors observed an overgeneralization of morpho-syntactic derivation rules resulting in the production of non-existent verbs (regularized on a lexical basis). This neuropsychological impairment was interpreted as arising from a lack of cognitive control (difficulty in inhibiting the pattern activated by the rule) or from a linguistic defect of lexical retrieval *per se*. In the same vein, Corrivetti et al. (2019)<sup>42</sup> reported semantic errors related to stimulation of left FAT (see above). At another level, in a population of stroke patients, abnormalities of left FAT microstructural properties were associated with decreased performances in semantic verbal fluency<sup>47</sup>, see also Blecher et al. (2019)<sup>54</sup> for whom left and right FAT supported the semantic fluency) and semantic pairing<sup>46</sup>.

Note however that Catani et al. (2013)<sup>49</sup>, Chernoff et al. (2018)<sup>40</sup> and Keser et al. (2020)<sup>55</sup> did not report any association between semantic processing and the left FAT.

Reminiscent of the work by Corrivetti et al. (2019)<sup>42</sup>, Mandelli et al. (2014)<sup>50</sup> showed in patients presenting with the non-fluent version of primary progressive aphasia that decreased integrity of the FAT's posterior connections (vPMC-SMA proper) specifically correlated with the number of speech distortions (*i.e.* 'apraxia of speech' type errors) on an image description task, whereas the FAT's anterior component (BA44 - preSMA) correlated not only with the number of speech distortions but also with the speech rate (measured by the number of words per minute) and performances obtained from higher level tasks *i.e.* syntax production (measured by the number of words per sentence). Here the higher aspect of verbal fluency was captured at least partially by the syntactic aspect of the task contrary to the work of Corrivetti et al. (2019)<sup>42</sup>.

On the other hand, Chernoff et al. (2019)<sup>41</sup> showed that a transient breakdown of the left FAT by means of electrostimulation induced a lengthening of the pauses between the words marking a phrasal boundary, not between the words-nouns or intra-word. So, according to Chernoff et al. (2018)<sup>40</sup> who show a reduction of mean length utterance as a consequence of a postoperative damage of the left FAT (and not following transection of the inferior longitudinal fasciculus) and Chernoff et al. (2019)<sup>41</sup>, the FAT would constitute an interface between syntactic planning and lexical access, without articulatory implication. More indirectly, this is supported by other studies measuring verbal fluency through low-constraint conditions. For example, syntactic production estimated from a description image task (measured with the number of words per sentence) were found to correlate with the posterior segment of the FAT in patients with non-fluent variant progressive primary aphasia)<sup>50</sup>. In a similar way, Catani et al. (2013)<sup>49</sup> showed an association between FAT integrity and the mean length of utterance. Taken together, these studies suggest an involvement of this fiber tract in the higher level of fluency, not only at the lexico-semantic level but also at a syntactic level.

#### Constraint *versus* spontaneous speech and language

Dragoy et al. (2020)<sup>44</sup> observed during subcortical electrostimulation a clinical manifestation related to transcortical motor aphasia. In particular, stimulation close to the cortical terminations of the FAT,

both ventrally and dorsally, caused an impairment of verbal fluency but only in the context of sentence completion and not during picture naming. In this study, picture naming required a verb while sentence completion called for a noun but, in both cases, the response called an inflection so, according the authors, the FAT would not be more involved in one or other tasks because of the syntactic category of the word expected; rather, its involvement in sentence completion would be due to the linguistic level of constraint. In other words, the difficulties only appeared in the more “spontaneous” condition. Indeed, while picture naming provides visual cues for conceptual selection and lemma retrieval, sentence completion is a vector of greater linguistic spontaneity. In the former case, competition between conflicting naming responses is lower and, in the latter, it offers the possibility of selecting competing concepts and lemmas, and also allows syntactic sequencing. Hence, the authors of this study suggest that the left FAT is rather involved in high level linguistic and executive demands. This proposal agrees with growing evidence showing that damage to the left FAT is associated with poor performance in image description<sup>49, 46, 50, 40</sup> while preserved performance in picture naming<sup>49, 40</sup>. Although these general results seem to contradict observations made in awake surgery (i.e. diminished speech fluidity during a naming task), this can be explained by the involvement of FAT (possibly through different anatomical layers) in two levels of fluency. More specifically, constraining tasks (i.e. providing external clues and therefore reducing the competition between conflicting responses, conceptual selection, etc.) would allow to estimate low level fluency related to motor aspects of speech, while tasks closer to spontaneous language (such as sentence completion or image description) would promote the assessment of a higher level of fluency, linked to syntactic and lexico-semantic aspects.

Zyryanov et al. (2020)<sup>48</sup> disagree with this strict dissociation; they rather propose the FAT as mediating the production of language under high executive demand, independently of the linguistic demand of the task. In their study based on chronic stroke patients, the authors showed a specific correlation between left FAT volume and performance obtained in a picture-word interference task (i.e. a picture naming task associated with a distractor consisting in semantically-related, unrelated or congruent written word) and not in a sentence completion task. Yet, the errors made mainly consisted in reading the distracting words and not in articulatory/motor errors.



### *Negative results*

To be as exhaustive as possible, we must mention here studies providing negative results with regard to the involvement of FAT in verbal fluency. Costentin et al. (2019)<sup>53</sup> did not find any correlation between the disconnective damage of the FAT (among other tracts) induced by the trajectory of the electrode implanted in a cohort of patients necessitating deep brain stimulation for a Parkinson disease and verbal fluency performances measured with standard phonological and semantic fluencies tasks. In healthy participants, the association between FAT and verbal fluency is not found<sup>56,32</sup>. For example, Vallesi et al. (2020)<sup>32</sup> did not observe any association between the scores obtained on the semantic and phonological fluency tasks and the number of streamlines, the volume and the fractional anisotropy within FAT.

### *Supralinguistic functions*

If the left FAT mainly supports language and speech-related functions, in particular speech initiation, stammering and verbal fluency (see also Dick et al. (2019)<sup>8</sup> for a review), this white matter tract may also underpin a range of other processes regrouped here as being “supralinguistic.”

### *Executive functions, attention and working memory*

Dick et al. (2019)<sup>8</sup> propose that the FAT would be a key component of a cortico-basal ganglia-thalamic cerebellar circuit involved in action control (i.e. planning, timing and coordination of sequential motor movements as well as the resolution of competition among conflicting motor programs), but specialized in the left hemisphere for speech action. Although this theory is derived from the DIVA (Directions Into and Velocities of Articulators) and the GODIVA (Gradient Order DIVA) models, which bring into play phoneme and syllable representations, the authors well noted that the FAT seems to be involved in lexical-level retrieval and selection too. The fact that the FAT could play a role in executive functions in general, and in the executive aspects of language related to verbal fluency in particular, has been previously suggested by the study of Sierpowska et al. (2015)<sup>37</sup>.

This is not surprising given that verbal fluency engages *de facto* an executive requirement by mobilizing the processes of lemma and lexical selection, syntactic planning, initiation and motor control of speech.

In the right hemisphere, the FAT may convey neural information related to inhibition control<sup>8</sup>; indeed, the authors suggest that the right IFG – pre-SMA interactions, as part of the basal ganglia loops bringing into play stopping mechanism and resolving conflict, would establish action plans of non-speech motor programs before to select one of them that will be outputted by means of a top-down connection between motor cortex and basal ganglia. In agreement with this, Rutten et al. (2021)<sup>45</sup> reported the case of a patient with a low-grade glioma in whom direct electrical stimulation likely applied to the right FAT impaired inhibition, assessed with the Stroop task. These findings fit well with the cortical projections of the FAT in pre-SMA and IFG, as both regions have been reportedly found to be involved in inhibition<sup>e.g. 70-72</sup>, irrespective of the output modality (i.e. behavioral *versus* verbal). It is worth mentioning that, in a network-behavior mapping study conducted with an impressive sample of 270 patients suffering from a low-grade glioma, powerful correlations were obtained between Stroop task performance and the left FAT as well the left superior longitudinal fasciculus (branch III and II)<sup>7</sup>.

In an interesting multimodal study combining electrostimulation, diffusion tractography, cortico-cortical evoked potentials and task-based electrocorticography, experimental support for the coordinated involvement of these two cortical areas in the preparation and stopping of action was established, this coordination being likely mediated by the right FAT<sup>63</sup>. Indeed, tractography revealed a direct connection between SMA and IFG, and stimulation of SMA (causing motor arrest) evoked strong local field potentials within 30 ms in IFG. Moreover, preparing to stop or stopping was associated by an increase of high-gamma amplitude in right SMA and then in right IFG. In a similar vein, Aron et al (2007)<sup>14</sup> found that areas activated by stopping action and conflict detection/resolution (i.e. among which the right inferior cortex and the pre-SMA) were connected by a pathway probably corresponding to the right FAT. Furthermore, a work associating fMRI and DTI found an association between the connection strength of right FAT and the severity of developmental stuttering<sup>57</sup>. According to the authors, right FAT would play a crucial role in the motor aspects of stuttering as its

changes may cause a hyper-functional suppression mechanism disrupting speech fluency. This interpretation challenges the view according to which the activation of right hemispheric regions could represent a compensatory process associated with a decrease of stuttering symptoms<sup>73</sup>. It could also explain that FA abnormalities within the right FAT are predictive of the rate of errors by syllabic insertion in the speech of ASD children<sup>58</sup>. It is worth mentioning however in the latter study that the authors reject the connotation of this type of errors with possible stammering (given the absence of excess muscle tension noted during disfluencies). This limitation is nevertheless relatively questionable insofar as the tension has not been evaluated other than visuo-perceptually. Moreover, given the particular characteristics of ASD children's prosody<sup>74</sup>, it is possible that muscular tension in these patients is lessened compared to people who stutter without other concomitant pathologies. To some extent, the possible implications of right FAT in verbal fluency noted by other studies<sup>33, 47, 54, 55</sup> could interact with the executive aspects of inhibition found by Neef et al. (2017)<sup>57</sup>.

In a related domain, Varriano et al. (2018)<sup>17</sup> established an association between the right exFAT and working memory as assessed by a 2-back paradigm based on the HCP imaging and behavioral dataset. In another study, they further showed that the more anterior component of this extended tract (i.e. the white matter pathway located in front of the traditional boundaries of the FAT) is in fact involved in working memory<sup>19</sup>. On the same line, a work by Rizio et Diaz (2016)<sup>30</sup> found that FAT microstructural properties, especially FA, was predictive of working memory performances (assessed in its verbal and spatial components) in both the left and the right hemisphere, in elderly but not in young adults. Rutten et al. (2021)<sup>45</sup> also noted the involvement of the right FAT in working memory, measured with a digit backward span task during direct electrostimulation. Lastly, in a study conducted by Garic et al. (2018)<sup>24</sup> in typical children, the degree of left lateralization of FAT was associated with greater attention problems, and this relationship was mediated by higher executive dysfunction. On the basis of this finding, the authors suggest the right FAT supports at least partially these functions.

*Social communication*

In the supralinguistic domain, some studies also defend the idea of an implication of the FAT in social communication. In particular, Catani and Bambini (2014)<sup>64</sup> assumed that the tract could play a role within the Social Communication and Language Evolution and Development (SCALED) model they built. This model is structured according to a hierarchical organization in 5 levels of increasing complexity, which are intended to fit with the development and evolution aspects of social communication. Each level matches a function to an anatomical network. The FAT white matter network is suggested to be involved in the expression and recognition of communicative intentions (level 2), and possibly in the inferential processes needed for mentalizing. In this context, Lo et al. (2017) and Lo et al. (2018)<sup>60, 61</sup> investigated the FAT in ASD children, unaffected siblings, and typical children. The authors found that FAT integrity was lower in ASD children compared to typical children<sup>60</sup> and intermediate in unaffected siblings<sup>61</sup>. Most importantly, FA changes within the FAT were associated with social interaction skills in ASD children and with social communication deficits in unaffected siblings<sup>61</sup>. Despite these preliminary findings, the potential role of the FAT in aspects of social cognition and communication remains to be firmly established.

### *Extralinguistic functions*

In this last section, we describe the results from studies in which the FAT was involved at an extralinguistic level, including visual and visuospatial processing as well as visuo-constructive praxis and motor skills. In this respect, Dick et al. (2019)<sup>8</sup> have already discussed the potential involvement of FAT in action control, with however a right-hemisphere dominance regarding sequential, non-speech motor programs (i.e. oculomotor and manual/limb actions) especially in the visuo-spatial domain.

### *Visual and visuospatial processing*

First, Serra et al. (2017)<sup>52</sup> observed in patients with Alzheimer's disease an FA decrease within the FAT bilaterally, compared to healthy individuals. In addition, they report a specific correlation between FAT integrity and the performance obtained by these patients in a visuospatial reasoning task

(i.e. assessed by means of the Raven's matrices). In a study conducted with ASD patients, Chien et al. (2017)<sup>59</sup> reported an association between the right FAT and visual short-term memory, not with spatial working memory. Taken together, these findings provide limited support for a role of the right FAT in visual/visuo-spatial short-term/working memory. Further studies are needed to gain insight on this matter.

### *Visuo-constructive praxes and manual motor skills*

Incidentally, Corrivetti et al. (2019)<sup>42</sup> noted a transient motor deficit of the upper / lower limbs during stimulation of the left FAT in awake surgery, but other studies of the same ilk did not find such a deficit<sup>e.g. 33, 36, 40</sup>. More robustly, Budislajevic et al. (2017)<sup>31</sup> showed using a specific behavioral paradigm that microstructural properties of bilateral FAT was associated with the movements of hands visually guided in reaching and reach-to-grasp, that is in visuomotor processing. They thus suggest an involvement of FAT in kinematic features of hand actions. Furthermore, Serra et al. (2017)<sup>52</sup> showed that FAT integrity correlated with the accuracy with which visuo-constructive praxis were performed (in drawing copy) in patients with Alzheimer's disease (but not in control participants). The involvement of FAT in manual behaviors is consistent with the action-related motor functions traditionally attributed to the SMA<sup>e.g. 75, 76, 63</sup> or the posterior IFG, in terms of fine motor skills<sup>77</sup> or inhibition of action<sup>63, 72</sup>. Finally, according to works of Budislajevic et al. (2017)<sup>31</sup> and Corrivetti et al. (2019)<sup>42</sup> in particular, the speech functions of FAT seem to be transposable at a more global motor manual and limb movement scale.

## **Surgical perspectives**

### *FAT's neuroplasticity potential*

As SMA and IFG are the frontal areas the most commonly affected by cerebral tumors, especially diffuse low-grade glioma<sup>78,4</sup> the FAT is frequently overwhelmed, most notably at the level of its cortical terminations. As a consequence, it is regularly targeted by the surgical procedure. In this context, optimizing the surgical intervention in the vicinity of this frontal pathway requires a precise

understanding of its neuroplasticity potential. It is established that white matter fiber tracts are rather refractory to functional compensation, in particular for association and projection tracts<sup>79, 3</sup>. This seems, however, not particularly the case for the FAT. In a recent work based on the anatomic MRI and intraoperative mapping data of 231 patients having undergone surgery for a diffuse low-grade glioma, a whole-brain neuroplasticity map of both cortical and subcortical structures was generated<sup>4</sup>. It contained 340 levels of probability, ranging from 0 (full functional compensation) to 1 (null functional compensation). This map was projected onto the main brain's white matter fasciculi and then clustered using an unsupervised learning approach. With regard to the FAT, an anterior-to-posterior neuroplastic gradient was found (Figure 4). More specifically, whereas the middle-to-anterior part of the FAT was highly compensable (~70% of the tract, average probability in the cluster < 0.2), the most posterior part was less compensable when damaged by the tumor (~30% of the tract, average probability in the cluster ~ 0.7). Collectively, these results suggest that the motor (posterior) segment of the FAT is less susceptible to be functionally compensated for. However, in view of the posterior FAT's neuroplasticity index, it is important to note that this segment was still "removable" in 30% of cases. Admittedly in this study however, plasticity was uniquely assessed on the basis of functional responses obtained with direct electrostimulation during counting or picture naming. Consequently, this plasticity potential cannot be generalized to all functions that may be mediated by the FAT.

The rather efficient plasticity of the fibers forming the FAT has been recently illustrated in a neurosurgical case study in which a 23-year-old patient was operated on asleep for a lower-grade glioma located in left the superior frontal gyrus and invading part of the FAT<sup>43</sup>. During the surgical procedure, the FAT was voluntarily interrupted to allow complete removal of the neoplasm. As expected, the patient was non-verbal immediately after surgery, but progressively regained her speech in few days. In view of the lack of definitive impairment, the authors proposed that preservation of the dominant FAT is not necessary in general during a surgical procedure planned to disrupt the tract. Although this fast speech recovery is in agreement with the plasticity potential we described above, cautions must be taken as, in this study, both the posterior FAT and the SMA proper were apparently not removed. It is thus possible that a functional connectivity still remains between the medial and lateral parts of the frontal lobe.

Although the physiological dynamics underpinning the reallocation of functions conveyed by the FAT are still unknown, the most likely hypothesis is that the tract abandons its functionalities as a function of the extent to which its cortical terminations are invaded. For example, extensive infiltration of the posterior SFG (including pre-SMA and SMA proper) is likely to make the FAT functionally unnecessary, as this structure - which is the unique recipient of FAT's cortical terminations at the dorsal level - is known to gradually reorganize in response to tumor progression<sup>80</sup>. Stated another way, the progressive loss of functions of SFG is mechanically and concomitantly associated with a functional loss of the FAT. Such a mechanism has been already described in the context of tumors affecting the anterior temporal lobe (ATL). Complete infiltration and compensation of this structure makes the inferior longitudinal fasciculus (ILF) functionally ineffective since all the ILF's cortical projections target the ATL<sup>81</sup>. Along with the established tumor-related homotopic plasticity of the pre-SMA/SMA e.g.<sup>82</sup>, it is a possibility that the lesioned FAT follows the same path (i.e. functionally compensated by the contra-lesional FAT network).

### *Do we need optimized tasks to map the FAT?*

Until now, the FAT was mainly mapped during awake surgery with a simple naming or counting task with the overt goal of preserving speech initiation and control<sup>34-36</sup> (see Figure 5 for illustrative cases). Given accumulating evidence that the FAT may support a broadest range of processes, consideration should be given as to whether other behavioral paradigms would be relevant to employ during the surgery procedure in the service of a more accurate mapping of the different sublayers forming the tract. This could potentially diminish the risk of inducing permanent and debilitating, postoperative disconnection-related deficits. For example, if the FAT is confirmed to convey neural signals related to inhibitory control, should we use a behavioral task aimed at monitoring this executive process?

In a general way, the decision of using new behavioral tasks without interfering with the onco-functional balance (i.e. the best trade-off between the extent of resection and preservation of functions) must be determined by a scientific way<sup>83</sup>. In other words, we need to show clinical evidence that resection of the FAT is associated with unrecoverable deficits despite cognitive and speech rehabilitation. This implies that patients with a resection concerning the FAT or in close location with

the FAT are comprehensively assessed in longitudinally-designed studies (i.e. before, immediately after, and a while after surgery) with a large set of neuropsychological tasks probing in particular the different functions described in this review. This also implies that structural disconnections induced by the surgical procedure are precisely characterized and directly correlated with behavioral outcomes. To the best of your knowledge, this kind of studies is still lacking and thus needs to be performed.

## **Conclusion**

Accumulating evidence suggests that the medial and lateral parts of the frontal lobe are directly connected with a large contingent of fibers forming what has been called the FAT. Current literature indicates that this transverse frontal pathway projects in more areas than previously thought, beyond the pre-SMA and SMA, dorsally, and *pars opercularis*, laterally. There is also some evidence that the FAT may be stratified into several layers organized according to an antero-to-posterior gradient reflecting the level of processing, in accordance with the known functional gradient identified within the complex pre-SMA/SMA for action and speech <sup>e.g. 84</sup>. However, research focusing on the functions mediated by the FAT is just beginning, so much of what we currently know, beyond the established role in speech initiation and control, has to be confirmed. From a neurosurgical perspective, current findings suggest that the FAT is associated with a certain degree of neuroplastic compensation, though the mechanistic aspects of this plasticity remain unknown. This is the reason why it is urgent to assess the extent to which the FAT may be compensated for a range of cerebral processes, ideally by means of well-powered, longitudinally-designed studies aimed at correlating the disconnectivity patterns induced by the surgical procedure and behavioral outcomes. This is the best way to determine whether we need new behavioral paradigms to better monitor on-line the functions underpinned by the FAT and to reduce if necessary the probability of causing irrevocable deficits.



## References

- [1] Geschwind N, Kaplan E. A human cerebral disconnection syndrome: A preliminary report. *Neurology*. 1962; 12: 675–675.
- [2] Thiebaut de Schotten M, Foulon C, Nachev P. Brain disconnections link structural connectivity with function and behaviour. *Nature Communications*. 2020;11:5094.
- [3] Herbert G, Duffau H. Revisiting the functional anatomy of the human brain: Toward a meta-networking theory of cerebral functions. *Physiological Reviews*. 2020;100:1181–1228.
- [4] Herbert G, Maheu M, Costi E, et al. Mapping neuroplastic potential in brain-damaged patients. *Brain*. 2016;139:829–844.
- [5] Picart T, Herbert G, Moritz-Gasser S, et al. Iterative surgical resections of diffuse glioma with awake mapping: How to deal with cortical plasticity and connectomal constraints? *Neurosurgery*. 2019;85:105–116.

- [6] Nakajima R, Kinoshita M, Okita H, et al. Glioma surgery under awake condition can lead to good independence and functional outcome excluding deep sensation and visuospatial cognition. *Neuro-Oncology Practice*. 2019;6:354–363.
- [7] Cochereau J, Lemaitre A-L, Wager M, et al. Network-behavior mapping of lasting executive impairments after low-grade glioma surgery. *Brain Struct Funct*. 2020;225:2415–2429.
- [8] Dick AS, Garic D, Graziano P, et al. The frontal aslant tract (FAT) and its role in speech, language and executive function. *Cortex*. 2019;111:148–163.
- [9] Lawes INC, Barrick TR, Murugam V, et al. Atlas-based segmentation of white matter tracts of the human brain using diffusion tensor tractography and comparison with classical dissection. *NeuroImage*. 2008;39:62–79.
- [10] Ford A, McGregor KM, Case K, et al. Structural connectivity of Broca's area and medial frontal cortex. *NeuroImage*. 2010;52:1230–1237.
- [11] Kinoshita M, Ozaki N, Hamada J. Association fibers connecting the Broca center and the lateral superior frontal gyrus: a microsurgical and tractographic anatomy. *J Neurosurg*. 2012;116:323-330.
- [12] Oishi K, Zilles K, Amunts K, et al. Human brain white matter atlas: Identification and assignment of common anatomical structures in superficial white matter. *NeuroImage*. 2008;43:447–457
- [13] Catani M, Dell'Acqua F, Vergani F, et al. Short frontal lobe connections of the human brain. *Cortex*. 2012;48:273–291.
- [14] Aron AR, Behrens TE, Smith S, et al. Triangulating a cognitive control network using diffusion-weighted magnetic resonance imaging (MRI) and functional MRI. *J. Neurosci.*, 2007;27:3743–52.
- [15] Vergani F, Lacerda L, Martino J, et al. White matter connections of the supplementary motor area in humans. *J Neurol Neurosurg Psychiatry*. 2014;85:1377–1385.
- [16] Szmuda T, Rogowska M, Słoniewski P, et al. Frontal aslant tract projections to the inferior frontal gyrus. *Folia Morphol*. 2017;76:8.

- [17] Pascual-Diaz S, Varriano F, Pineda J, et al. Structural characterization of the extended frontal aslant tract trajectory: A ML-validated laterality study in 3T and 7T. *NeuroImage*. 2020;222:117-260.
- [18] Varriano F, Pascual-Diaz S, Prats-Galino A. When the FAT goes wide: Right extended frontal aslant tract volume predicts performance on working memory tasks in healthy humans. *PLoS One*. 2018;13:e0200786.
- [19] Varriano F, Pascual-Diaz S, Prats-Galino A. Distinct components in the right extended frontal aslant tract mediate language and working memory performance: A tractography-informed VBM study. *Front Neuroanat*. 2020;14:21.
- [20] Briggs RG, Conner AK, Rahimi M, et al. A connectomic atlas of the human cerebrum—Chapter 14: Tractographic description of the frontal aslant tract. *Operative Neurosurgery*. 2018;15:S444–S449.
- [21] Yeh F-C, Tseng W-YI. NTU-90: A high angular resolution brain atlas constructed by q-space diffeomorphic reconstruction. *NeuroImage*. 2011;58:91–99.
- [22] Yeh, F. C. (2017). *Diffusion MRI Reconstruction in DSI Studio*. Advanced Biomedical MRI Lab, National Taiwan University Hospital. Available from: <http://dsi-studio.labsolver.org/Manual/Reconstruction#TOC-Q-Space-Diffeomorphic-Reconstruction-QSDR>
- [23] Yeh F-C, Panesar S, Fernandes D, et al. Population-averaged atlas of the macroscale human structural connectome and its network topology. *NeuroImage*. 2018;178:57–68.
- [24] Garic D, Broce I, Graziano P, et al. Laterality of the frontal aslant tract (FAT) explains externalizing behaviors through its association with executive function. *Dev Sci*. 2019;22:e12744
- [25] Broce I, Bernal B, Altman N, et al. Fiber tracking of the frontal aslant tract and subcomponents of the arcuate fasciculus in 5–8-year-olds: Relation to speech and language function. 2015;11.
- [26] Thiebaut de Schotten M, Dell’Acqua F, Valabregue R, et al. Monkey to human comparative anatomy of the frontal lobe association tracts. *Cortex*. 2012;48:82–96.
- [27] Schmahmann JD, Pandya DN, Wang R, et al. Association fiber pathways of the brain: parallel observations from diffusion spectrum imaging and autoradiography. *Brain*. 2007;130:630–653.

- [28] Petrides M, Pandya DN. Comparative cytoarchitectonic analysis of the human and the macaque ventrolateral prefrontal cortex and corticocortical connection patterns in the monkey: Ventrolateral prefrontal cortex in human and monkey. *European Journal of Neuroscience*. 2002;16:291–310.
- [29] Frey, S., Mackey, S. & Petrides, M. Cortico-cortical connections of areas 44 and 45B in the macaque monkey. *Brain Lang*. 2014;131:36–55.
- [30] Rizio AA, Diaz MT. Language, aging, and cognition: frontal aslant tract and superior longitudinal fasciculus contribute toward working memory performance in older adults. *NeuroReport*. 2016;27:689-293
- [31] Budisavljevic S, Dell’Acqua F, Djordjilovic V, et al. The role of the frontal aslant tract and premotor connections in visually guided hand movements. *NeuroImage*. 2017;146:419–428.
- [32] Vallesi A, Babcock L. Asymmetry of the frontal aslant tract is associated with lexical decision. *Brain Struct Funct*. 2020;225:1009–1017.
- [33] Martino J, de Lucas EM, Ibáñez-Plágaro FJ, et al. Foix-Chavany-Marie syndrome caused by a disconnection between the right pars opercularis of the inferior frontal gyrus and the supplementary motor area: Case report. *JNS*. 2012;117:844–850.
- [34] Vassal F, Boutet C, Lemaire J-J, et al. New insights into the functional significance of the frontal aslant tract—An anatomo–functional study using intraoperative electrical stimulations combined with diffusion tensor imaging-based fiber tracking. *Br J Neurosurg*. 2014 ; 28:685–687.
- [35] Fujii M, Maesawa S, Motomura K, et al. Intraoperative subcortical mapping of a language-associated deep frontal tract connecting the superior frontal gyrus to Broca’s area in the dominant hemisphere of patients with glioma. *JNS*. 2015;122:1390–1396.
- [36] Kinoshita M, de Champfleury NM, Deverdun J, et al. Role of fronto-striatal tract and frontal aslant tract in movement and speech: an axonal mapping study. *Brain Struct Funct*. 2015;220:3399–3412.
- [37] Sierpowska J, Gabarrós A, Fernandez-Coello A, et al. Morphological derivation overflow as a result of disruption of the left frontal aslant white matter tract. *Brain and Language*. 2015;142:54–64.

- [38] Kemerdere R, de Champfleury NM, Deverdun J, et al. Role of the left frontal aslant tract in stuttering: a brain stimulation and tractographic study. *J Neurol*. 2016;263:157–167.
- [39] Ookawa S, Enatsu R, Kanno A, et al. Frontal fibers connecting the superior frontal gyrus to Broca area: A corticocortical evoked potential study. *World Neurosurgery*. 2017;107:239–248.
- [40] Chernoff BL, Teghipco A, Garcea FE, et al. A role for the frontal aslant tract in speech planning: A neurosurgical case study. *Journal of Cognitive Neuroscience*. 2018;30:752–769.
- [41] Chernoff BL, Sims MH, Smith SO, et al. Direct electrical stimulation of the left frontal aslant tract disrupts sentence planning without affecting articulation. *Cognitive Neuropsychology*. 2019;36:178–192.
- [42] Corrivetti F, de Schotten MT, Poisson I, et al. Dissociating motor–speech from lexico-semantic systems in the left frontal lobe: insight from a series of 17 awake intraoperative mappings in glioma patients. *Brain Struct Funct*. 2019;224:1151–1165.
- [43] Young JS, Morshed RA, Mansoori Z, et al. disruption of frontal aslant tract is not associated with long-term postoperative language deficits. *World Neurosurgery*. 2020;133:192–195.
- [44] Dragoy O, Zyryanov A, Bronov O, et al. Functional linguistic specificity of the left frontal aslant tract for spontaneous speech fluency: Evidence from intraoperative language mapping. *Brain and Language*. 2020;208:104836.
- [45] Rutten, GJ.M., Landers, M.J.F., De Baene, W. *et al.* Executive functional deficits during electrical stimulation of the right frontal aslant tract. *Brain Imaging and Behavior*. 2021.
- [46] Basilakos A, Fillmore PT, Rorden C, et al. Regional white matter damage predicts speech fluency in chronic post-stroke aphasia. *Front Hum Neurosci*. 2014;8:845
- [47] Li M, Zhang Y, Song L, et al. Structural connectivity subserving verbal fluency revealed by lesion-behavior mapping in stroke patients. *Neuropsychologia*. 2017;101:85–96.
- [48] Zyryanov A, Malyutina S, Dragoy O. Left frontal aslant tract and lexical selection: Evidence from frontal lobe lesions. *Neuropsychologia*. 2020;147:107385.

- [49] Catani M, Mesulam MM, Jakobsen E, et al. A novel frontal pathway underlies verbal fluency in primary progressive aphasia. *Brain*. 2013;136:2619–2628.
- [50] Mandelli ML, Caverzasi E, Binney RJ, et al. frontal white matter tracts sustaining speech production in primary progressive aphasia. *Journal of Neuroscience*. 2014;34:9754–9767.
- [51] Mandelli ML, Vilaplana E, Brown JA, et al. Healthy brain connectivity predicts atrophy progression in non-fluent variant of primary progressive aphasia. *Brain*. 2016;139:2778–2791.
- [52] Serra L, Gabrielli GB, Tuzzi E, et al. Damage to the frontal aslant tract accounts for visuo-constructive deficits in Alzheimer’s disease. Galimberti D, editor. *JAD*. 2017;60:1015–1024.
- [53] Costentin G, Derrey S, Gérardin E, et al. White matter tracts lesions and decline of verbal fluency after deep brain stimulation in Parkinson’s disease. *Hum Brain Mapp*. 2019;40:2561–2570.
- [54] Blecher T, Miron S, Schneider GG, et al. Association between white matter microstructure and verbal fluency in patients with multiple sclerosis. *Front Psychol*. 2019;10:1607.
- [55] Keser Z, Hillis AE, Schulz PE, et al. Frontal aslant tracts as correlates of lexical retrieval in MS. *Neurological Research*. 2020;42:805–810.
- [56] Kronfeld-Duenias V. The frontal aslant tract underlies speech fluency in persistent developmental stuttering. *Brain Struct Funct*. 2016;221:365-381.
- [57] Neef NE, Anwender A, Bütfering C, et al. Structural connectivity of right frontal hyperactive areas scales with stuttering severity. *Brain*. 2018;141:191–204.
- [58] Chenausky K, Kernbach J, Norton A, et al. White matter integrity and treatment-based change in speech performance in minimally verbal children with autism spectrum disorder. *Front Hum Neurosci*. 2017;11:175.
- [59] Chien Y-L, Chen Y-J, Hsu Y-C, et al. Altered white-matter integrity in unaffected siblings of probands with autism spectrum disorders. 2017;38:6053-6067

- [60] Lo Y-C, Chen Y-J, Hsu Y-C, et al. Reduced tract integrity of the model for social communication is a neural substrate of social communication deficits in autism spectrum disorder. *J Child Psychol Psychiatr.* 2017;58:576–585.
- [61] Lo Y, Chen Y, Hsu Y, et al. Altered frontal aslant tracts as a heritable neural basis of social communication deficits in autism spectrum disorder: A sibling study using tract-based automatic analysis. *Autism Research.* 2018; 12:225-238
- [62] Zhang F, Savadjiev P, Cai W, et al. Whole brain white matter connectivity analysis using machine learning: An application to autism. *NeuroImage.* 2018;172:826–837.
- [63] Swann NC, Cai W, Conner CR, et al. Roles for the pre-supplementary motor area and the right inferior frontal gyrus in stopping action: Electrophysiological responses and functional and structural connectivity. *NeuroImage.* 2012;59:2860–2870.
- [64] Catani M, Bambini V. A model for social communication and language evolution and development (SCALED). *Current Opinion in Neurobiology.* 2014;28:165–171.
- [65] Starkweather CW. *Fluency and stuttering.* Englewood Cliffs, NJ, US: Prentice-Hall, Inc; 1987. p. xiv, 272.
- [66] Adams MR. A physiologic and aerodynamic interpretation of fluent and stuttered speech. *Journal of Fluency Disorders.* 1974;1:35–47.
- [67] Didirkova, I. *Parole, langues et disfluences : une étude linguistique et phonétique du bégaiement [Thèse de doctorat].* Ecole doctorale 58-Langues, littératures, cultures, civilisations, Université Paul-Valéry Montpellier 3. 2016.
- [68] Duffau H. New insights into the anatomo-functional connectivity of the semantic system: a study using cortico-subcortical electrostimulations. *Brain.* 2005;128:797–810.
- [69] Moritz-Gasser S, Herbet G, Duffau H. Mapping the connectivity underlying multimodal (verbal and non-verbal) semantic processing: A brain electrostimulation study. *Neuropsychologia.* 2013;51:1814–1822.

- [70] Aron AR, Fletcher PC, Bullmore ET, et al. Stop-signal inhibition disrupted by damage to right inferior frontal gyrus in humans. *Nat Neurosci*. 2003;6:115–116.
- [71] Aron AR, Robbins TW, Poldrack RA. Inhibition and the right inferior frontal cortex. *Trends in Cognitive Sciences*. 2004;8:170–177.
- [72] Xue G, Aron AR, Poldrack RA. Common neural substrates for inhibition of spoken and manual responses. *Cereb. Cortex*. 2008;18:1923-1932.
- [73] Braun A. Altered patterns of cerebral activity during speech and language production in developmental stuttering. An H<sub>2</sub>(15)O positron emission tomography study. *Brain*. 1997;120:761–784.
- [74] Diehl JJ, Paul R. Acoustic and perceptual measurements of prosody production on the profiling elements of prosodic systems in children by children with autism spectrum disorders. *Applied Psycholinguistics*. 2013;34:135–161.
- [75] Fontaine D, Duffau H. Somatotopy of the supplementary motor area: evidence from correlation of the extent of surgical resection with the clinical patterns of deficit. 2002;50:9.
- [76] Nachev P, Kennard C, Husain M. Functional role of the supplementary and pre-supplementary motor areas. *Nat. Rev. Neurosci*. 2008;9:856-869.
- [77] Liakakis G, Nickel J, Seitz RJ. Diversity of the inferior frontal gyrus—A meta-analysis of neuroimaging studies. *Behavioural Brain Research*. 2011; 225: 341-347.
- [78] Duffau H, Capelle L. Preferential brain locations of low-grade gliomas: Comparison with glioblastomas and review of hypothesis. *Cancer*. 2004;100:2622–2626.
- [79] Ius, T., Angelini, E., Thiebaut de Schotten, et al. Evidence for potentials and limitations of brain plasticity using an atlas of functional resectability of WHO grade II gliomas: Towards a “minimal common brain.” 2011;56:992-1000.
- [80] Krainik A, Lehericy S, Duffau H, et al. Postoperative speech disorder after medial frontal surgery: Role of the supplementary motor area. *Neurology*. 2003;60:587–594.



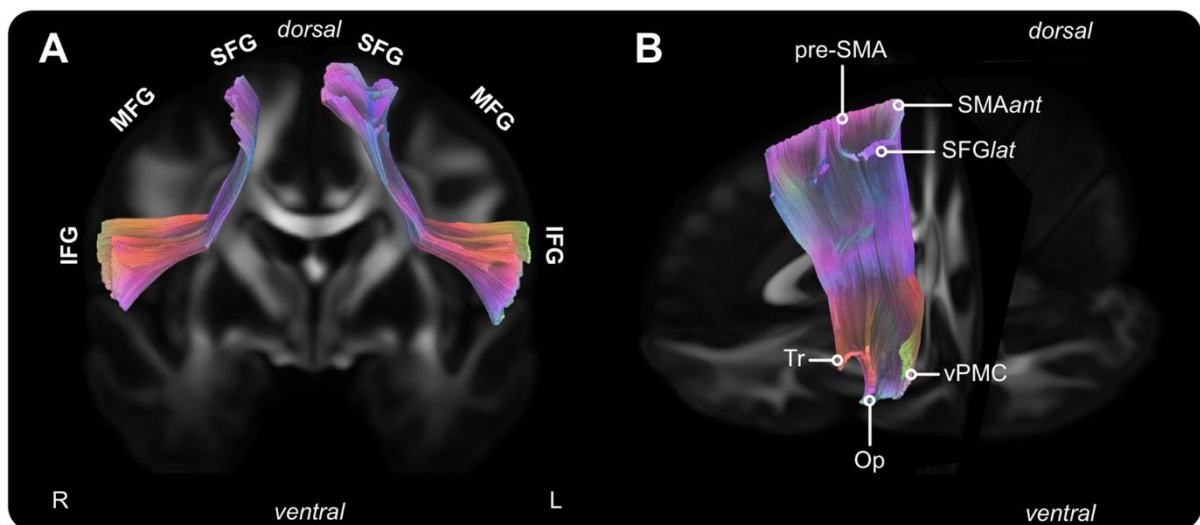
[81] Herbet G, Moritz-Gasser S, Lemaitre A-L, et al. Functional compensation of the left inferior longitudinal fasciculus for picture naming. *Cognitive Neuropsychology*. 2019;36:140–157.

[82] Chivukula S, Pikul BK, Black KL, et al. Contralateral functional reorganization of the speech supplementary motor area following neurosurgical tumor resection. *Brain and Language*. 2018;183:41–46.

[83] Mandonnet E, Herbet G, Duffau H. Letter: Introducing new tasks for intraoperative mapping in awake glioma surgery: Clearing the line between patient care and scientific research. *Neurosurgery*. 2020;86:E256–E257.

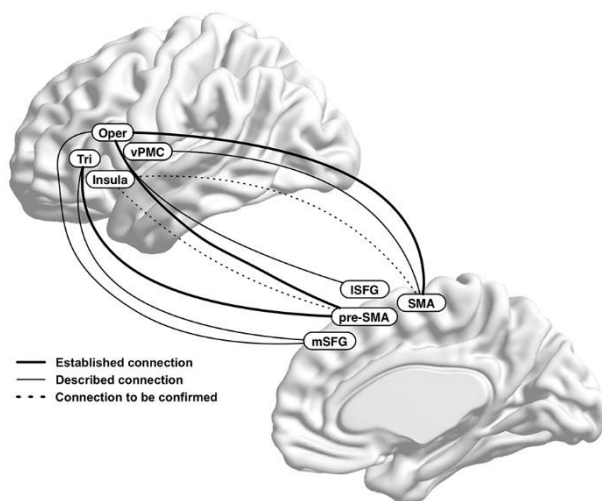
[84] Alario F-X, Chainay H, Lehericy S, et al. The role of the supplementary motor area (SMA) in word production. *Brain Research*. 2006;1076:129–143.

## Figures

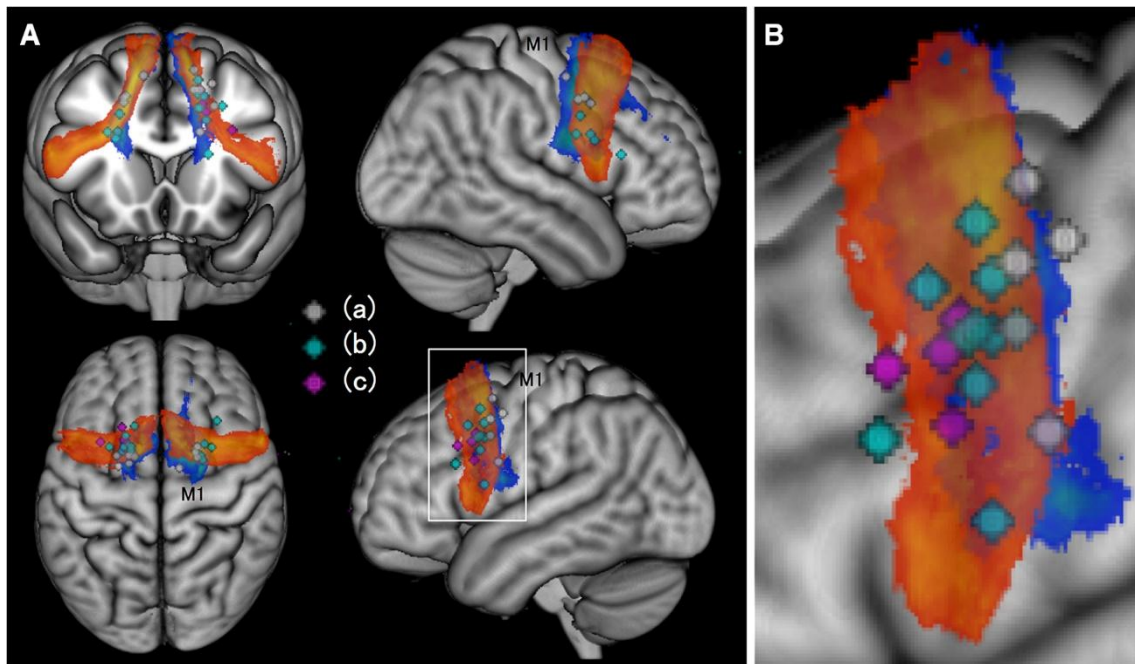


**Figure 1:** Population-based tractographic reconstruction of the FAT based on the 1021 HCP (Human Connectome project) dataset. (A) Bilateral FAT (frontal view). (B) Left FAT with tagged cortical terminations. *Tracking method.* A group average template was constructed from a total of 1021 subjects. A multishell diffusion scheme was used, and the b-values were 1000, 2000 and 3000 s/mm<sup>2</sup>. The number of diffusion sampling directions was 90 in the three directions. The *in-plane* resolution and slice thickness were 1.25 mm. The diffusion data were reconstructed in the MNI space using q-

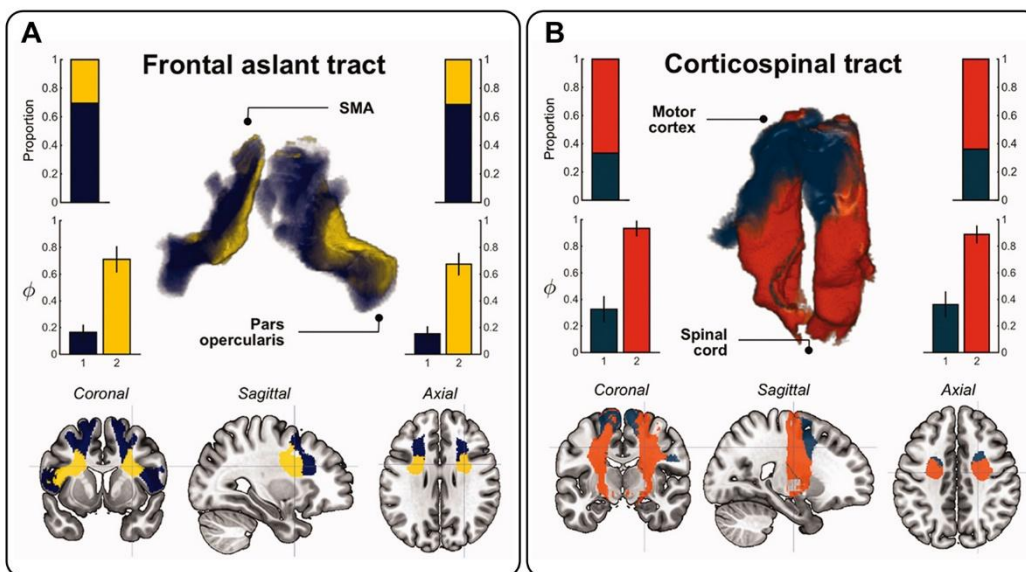
space diffeomorphic reconstruction <sup>21</sup> using DSI studio (<http://dsi-studio.labsolver.org/>) to obtain the spin distribution function. A diffusion sampling length ratio of 2.5 was used, and the output resolution was 1 mm. The restricted diffusion was quantified using restricted diffusion imaging <sup>22</sup>. The anisotropy threshold was 0.159581. The following parameters were used: change threshold of 10%, angular threshold of 45 degrees, and step size of 0.2 mm. The fiber trajectories were smoothed by averaging the propagation direction with 20% of the previous direction. Tracks with length shorter than 15 or longer than 150 mm were discarded. A total of 200000 seeds were placed. A deterministic fiber tracking algorithm was used to generate streamlines, and the FAT was mapped using the anatomy priors of a previous tractography atlas <sup>23</sup>. *Abbreviations: IFG*, inferior frontal gyrus; *MFG*, middle frontal gyrus; *SFG*, superior frontal gyrus; *ant*, anterior; *lat*, lateral; *Tr*, pars triangularis; *Op*, pars opercularis; *vMPC*, ventral premotor cortex.



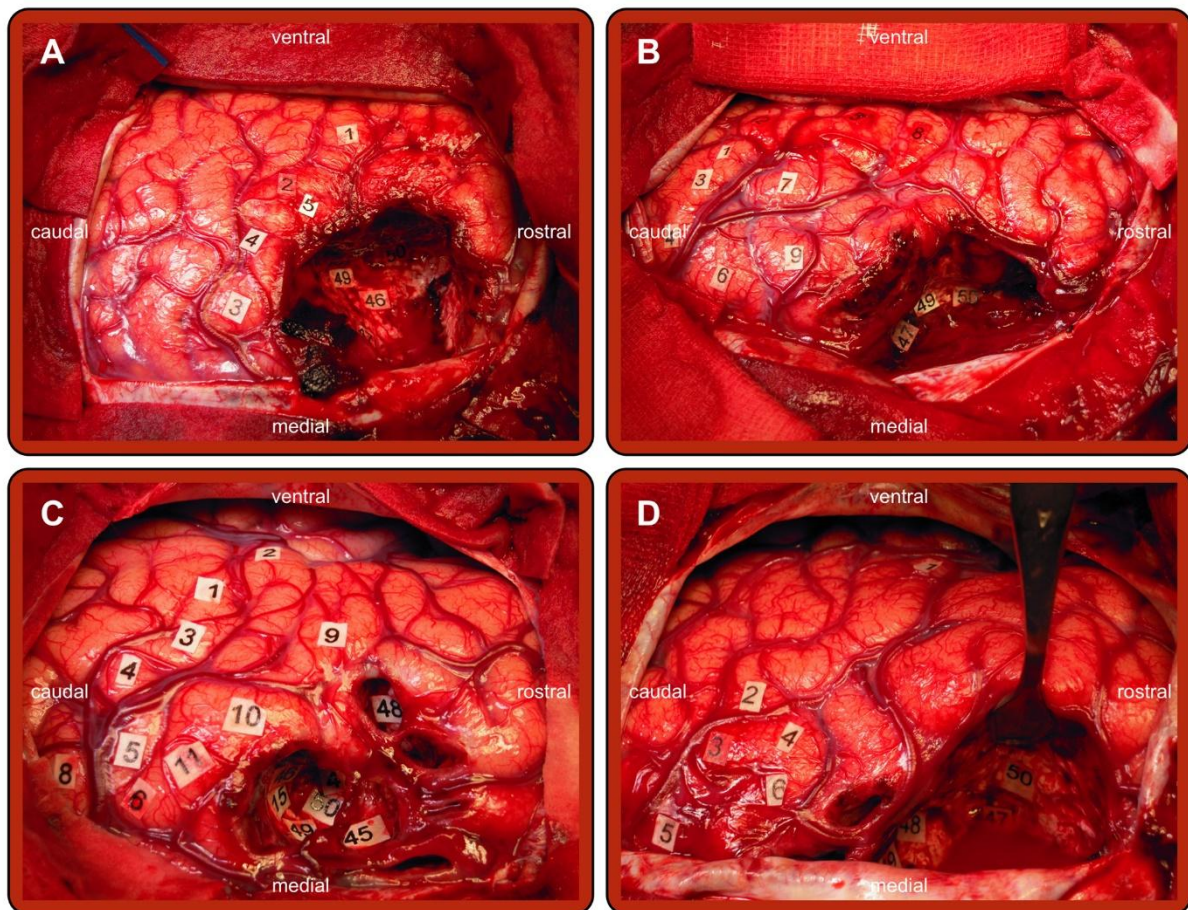
**Figure 2:** Wiring diagrams of FAT's cortical projections based on available literature. *Abbreviations: l*, lateral; *m*, middle; *oper*, pars opercularis; *Tri* pars, triangularis; *vPMC*, ventral premotor cortex.



**Figure 3:** Three-dimensional overlap maps of intraoperative mapping and postoperative tractography of 19 patients operated on for a lower glioma located in the vicinity of the FAT. (A) FAT (red-yellow) and fronto-striatal tract (blue-green) are overlaid with subcortical locations of sites eliciting inhibition of speech and/or motor actions during intraoperative electrical stimulation. A white line box in the sagittal image of left hemisphere is magnified in (B). *Gray dots* (a) motor inhibition; *cyan dots* (b) both speech and motor inhibition; *violet dots* (c) speech inhibition; M1 pre-central gyrus. Reused with permission from Kinoshita et al. (2015).



**Figure 4:** Antero-to-posterior gradient in the FAT's neuroplasticity potential. (A) FAT and (B) corticospinal tract for comparison (associated with poor functional plasticity). The upper bar shows the proportion of voxels contained in each cluster. The lower bar indicates the average index of functional plasticity (0 means *full* functional compensation whereas 1 means *null* functional compensation).



**Figure 5:** Illustrative cases of patients in whom speech difficulties were evoked by stimulation of left FAT. Only the subcortical mapping is described in the following. (A) [46] & [47] FAT, speech initiation; [50] IFOF, semantic paraphasia; [50] FST, motor arrest. (B) [47] FAT, speech initiation; [49] & [50] IFOF, semantic paraphasia. (C) [47] & [48] IFOF, anomia; [45] FAT, speech initiation; [49] & [50] FAT, speech and movement initiation; [15] FAT, stuttering. (D) [50] IFOF, semantic paraphasia; [47] FAT, speech initiation; [48] IFOF, semantic paraphasia and semantic pairing difficulties. These patients were operated on at Department of Neurosurgery's Montpellier University Medical center by Pr. Hugues Duffau.

**Conflicts of interest:** The authors certify that there is no conflict of interest with any financial organization regarding the material discussed in the manuscript.

**Funding:** This research was funding by a grant from the “*Agence Nationale pour la Recherche*” (ANR).

**Authors’ contributions:** The Three authors have participating to drafting the manuscript. Guillaume Herbet revisited it critically. All authors approved the final version of the manuscript.