



**HAL**  
open science

## Superior epigastric artery perforator flap for reconstruction of deep sternal wound infection

Nicolas Bertheuil, Franck-Marie Leclere, Farid Bekara, Eric Watier, Erwan Flecher, Jerome Duisit

► **To cite this version:**

Nicolas Bertheuil, Franck-Marie Leclere, Farid Bekara, Eric Watier, Erwan Flecher, et al.. Superior epigastric artery perforator flap for reconstruction of deep sternal wound infection. *Microsurgery*, 2021, 41 (5), pp.405-411. 10.1002/micr.30743 . hal-03203314

**HAL Id: hal-03203314**

**<https://hal.science/hal-03203314>**

Submitted on 10 Sep 2021

**HAL** is a multi-disciplinary open access archive for the deposit and dissemination of scientific research documents, whether they are published or not. The documents may come from teaching and research institutions in France or abroad, or from public or private research centers.

L'archive ouverte pluridisciplinaire **HAL**, est destinée au dépôt et à la diffusion de documents scientifiques de niveau recherche, publiés ou non, émanant des établissements d'enseignement et de recherche français ou étrangers, des laboratoires publics ou privés.

## **Superior epigastric artery perforator flap for reconstruction of deep sternal wound infection.**

Nicolas Bertheuil, MD, PhD<sup>1,2,3</sup>, Franck-Marie Leclere, MD, PhD<sup>4</sup>, Farid Bekara, MD<sup>5</sup>, Eric Watier, MD, PhD<sup>1</sup>, Erwan Flécher, MD, PhD<sup>6</sup>, Jérôme Duisit, DDS, MD, PhD<sup>7</sup>.

*1 - Department of Plastic, Reconstructive and Aesthetic Surgery, CHU Rennes, Rennes, France.*

*2 - INSERM U1236, University of Rennes 1, Rennes, France.*

*3 - SITI Laboratory, CHU Rennes, Rennes, France.*

*4 – Department of Plastic, Reconstructive and Aesthetic Surgery, CHU Poitiers, Poitiers, France.*

*5 - Department of Plastic, Reconstructive and Aesthetic Surgery, CHRU of Montpellier, Montpellier, France.*

*6 – Department of cardiac and thoracic surgery, CHU of Rennes, Rennes, France.*

*7- Department of Plastic, Reconstructive and Aesthetic Surgery, Cliniques Universitaires Saint-Luc, Brussels, Belgium.*

*Running Head : Superior epigastric artery perforator flap & sternal wound infection*

Word count: 1842

Conflict of interest statement and source of funding

The authors received no funding support for the research of this article and declared no potential conflicts of interest with the respect to the research, authorship and/or publication.

Corresponding author:

Dr Nicolas Bertheuil

Department of Plastic, Reconstructive and Aesthetic Surgery, Hospital Sud, Rennes, France.

16 Boulevard de Bulgarie, 35200, Rennes

Phone: 00 33 2 99 26 71 68

Fax: 00 33 2 99 26 67 18

E-mail: [nbertheuil@gmail.com](mailto:nbertheuil@gmail.com)

## Abstract

### **Background**

The treatment of deep wound sternal infection requires loco-regional pedicled flaps, usually with muscular flaps. Perforator propeller flaps represent the ultimate progress in the history of reconstructive surgery. Here, we report our experience with Superior Epigastric Artery Perforator (SEAP) flaps to repair sternal defect.

### **Patients and Methods**

Seven patients presenting deep sternal wounds infection were treated with SEAP propeller flap, between March 2015 and June 2017. The surgical technique was divided in three key steps and the peri-operative were described. The mean age was  $72.1 \pm 9.5$  years. The mean operative time was  $156.9 \pm 30.1$  min for the three steps procedure. The mean size of the skin paddle was  $155.7 \pm 52.8$  cm<sup>2</sup> (ranging 6-9 x 14-27 cm). The mean hospitalization time after flap coverage was  $31.6 \pm 16$  days.

### **Results**

All SEAP flaps achieved a successful entire coverage of the defect. Five patients experienced at least one complication, 5 venous congestion treated by leech therapy, one distal partial necrosis and two entire superficial flap layer necrosis but with viable tissue underneath the superficialis fascia, one infection recurrence that necessitate reoperation.

### **Conclusions**

The SEAP Perforator propeller flap is a reliable and safe surgical technique to achieve treatment of deep sternal wound infection.

### Glossary of Abbreviations

ASA : American Society of Anesthesiologists

CABG : coronary artery bypass grafting

IMAP : internal artery mammary perforator

SEAP : superior epigastric artery perforator

### **Introduction**

Patients who undergo to cardiac surgery have most often several comorbidities, often leading to multiple post-operative complications. Mediastinitis is a common complication after cardiac surgery, occurring approximately up to 3.4% of patients <sup>1</sup>. It's a life-threatening complication with a mortality rating up to 16% <sup>2</sup>. In few cases, after multiple reoperations with aggressive surgical debridement, a deep sternal wound dehiscence required to be covered by a plastic surgeon. Classical local or locoregional flaps such as pectoralis major muscle, rectus abdominis muscle, latissimus dorsi muscle or omentum can be used. <sup>3</sup> These flaps are quickly harvested, but are associated with subsequent donor site morbidities. In this context, perforator propeller flaps represent the ultimate progress in the history of reconstructive surgery: indeed, they provide a highly reliable reconstructive method, with two options regarding the anterior thoracic wall reconstruction: the internal mammary artery perforator (IMAP) <sup>4</sup> or the superior epigastric artery perforator (SEAP) flaps <sup>5</sup>. Their main interest is to be harvested quickly, as compared with free flaps (procedure duration), along with low donor site morbidity as

compared with the muscular flaps (functional sequelae). Moreover, the IMAP flap is not feasible after coronary artery bypass graft (CABG), when the entire length of both internal mammary vessels have been harvested: the SEAP flap remains feasible, due to the retrograde superior epigastric vessels flow.

Herein, we report one of the largest series of SEAP flaps for deep sternal wound coverage. We describe the flap harvesting, the post-operative outcomes and their management.

## **Methods**

We report our experience with seven patients who underwent prior reconstruction with SEAP flaps, between March 2015 and June 2017 in our department of Plastic and Reconstructive Surgery. During this period, we prospectively recorded the following features: age, sex, body mass index, type of cardiac surgery and comorbidities. The following peroperative data were recorded: American Society of Anesthesiologists (ASA) score, sternal defect size, dimension of the skin paddle of the flap, operative time, as well as the post-operative complication and postoperative survival. This study was performed in accordance with the principles of the Declaration of Helsinki (1964) and in agreement with the french Bioethics Laws of July 7<sup>th</sup>, 2011.

### *Surgical techniques*

The procedure is performed under general anesthesia, and in a supine position. Perforator vessels are identified vertically with an 8-MHz acoustic handheld Doppler (Hadeco ES 100 VX) <sup>6</sup>, on each side above the rectus muscle near the defect to choose the best perforating vessels. Preoperative design is based on the location of these perforators (as a propeller perforator mapping) and adapted perioperatively. We create an elliptical skin flap to allow

primary closure of the donor site oriented in the direction of the perforator<sup>7</sup>, in the inframammary fold. The surgery is divided in three steps: firstly, flap harvesting; secondly, deep sternal wound debridement; and finally, flap rotation and defect closure.

#### *Flap harvesting*

Firstly, the SEAP flap dissection starts: we perform a medial vertical small incision to search the previously detected perforators, and dissect under loupe magnification (x3.5). If the vessels are not found, or their caliber is too small to support the flap, a common feature in this population with polyarterial diseases, the dissection is pursued on the other side, through the same incision. When the SEAP vessels are found and selected, perforators are dissected under the fascia and skeletonized. Thereafter, the distance between the main vessel and the end of the loss of substance is measured, as well as the width of the defect. Finally, the drawing is readjusted and the skin ellipse incised and the flap elevated. The perforator vessels dissection is pursued intra-muscularly, to achieve optimal flap mobility without tension on the pedicle.

#### *Sternal wound debridement*

This step is always achieved once we have made sure that the flap could cover the defect. We then perform an aggressive debridement, with multiple bone sampling in order to provide an adequate antibiogram and adapt the infectious treatment.

#### *Defect closure*

The flap is then carefully rotated 90 degrees to cover the defect, and attached with weak tighten<sup>8</sup> Skoog interrupted sutures (3/0 Ethilon, Ethicon, Inc., Somerville, N.J), over suction drains. The donor site is closed primarily in three planes, by interrupted absorbable sutures (Polysorb 2 ; Covidien, Dublin, Ireland ; and Monocryl 3/0 ; Ethicon, Inc., Somerville, N.J.) and by a running suture (Monocryl 4/0) or staples.

### *Post-operative care*

Patients were monitored hourly on the first two days then 3 times a day until the end of the first week. The skin flap was checked on the following elements: color, heat, skin flexibility. Drains were removed if done less than 20 mL/24 h. Empirical antibiotic treatment was adapted to the result of the samples. All patients wore compression stockings and received subcutaneous low-molecular weight heparin to prevent phlebitis for 15 days after surgery.

### **Results**

The mean age was  $72.1 \pm 9.5$  years with a mean body mass index at  $27.5 \pm 6.1$  kg/m<sup>2</sup>. There were four male and three female patients. The initial cardiac procedure was a coronary artery CABG (n=2), aortic valve replacement (n=3) and a combined aortic valve replacement- CABG (n=2). The mean preoperative ASA score was 3 (n=5) and 4 (n=2) (Table 1). The defect size ranged between 32 to 170 cm<sup>2</sup> (Table 2).

The overall mean operative time was  $156.9 \pm 30.1$  min for the three steps procedure. The mean size of the skin paddle was  $155.7 \pm 52.8$  cm<sup>2</sup> (ranging 6-9 x 14-27 cm). The mean hospitalization time after flap coverage was  $31.6 \pm 16$  days. All SEAP flaps achieved a successful entire coverage of the defect, but only two patients were free from any flap-related complications. The figure 1 and 2 show a deep wound sternal infection cover with a SEAP flap.

Five patients had venous congestion of the flap, treated by leech therapy<sup>9</sup>: among them, the two first patients presented complete venous congestion resolution, one have distal partial necrosis treated by with V-Y wound closure. The last two patients presented a necrosis of the entire superficial flap layer, but the tissue underneath the superficialis fascia remained viable: the complication originated from a problem of venous return as well as arterial inflow (Table

2). For these last two patients wound closure was achieved by secondary healing using Algostérial® (Brothier, Nanterre, France) dressing. One patient had a recurrent infection with cutaneous fistula at 9 postoperative months. He was re-operated with re-elevation of the lateral haft of the flap for perform a total sternum bone ablation to allow disease-control and wound healing. One patient, discharged at postoperative day 18 died of a cardiac arrest at postoperative day 27.

## **Discussion**

Deep sternal wound infections and mediastinitis are serious complications following cardiac surgery and represent a real surgical challenge. In rare cases and despite initial surgical debridement and antibiotherapy, reconstructive surgery is needed for deep sternal wound coverage. Before the advent of perforator flaps, local muscular flaps such as pectoralis major and rectus abdominis flaps, or locoregional flaps like latissimus dorsi flap, were routinely used and associated with significant donor site morbidity. Omentum flaps were also used, associated with poor cosmetic results and major risk of eventration.

Perforator flaps offer new tools in the reconstructive armada, in which the propeller flaps are a refinement <sup>10</sup>. These flaps achieve a robust reconstruction with well-vascularized tissues and can address large tissue defects, offering a great flexibility and plasticity near to the defect, as well as a direct closure of donor site without any muscular sequelae.

Our study shows that this flap can achieve mediastinal coverage, regardless of cardiac surgery performed (even after CABG) unlike IMAP propeller flaps that are no longer feasible when both mammary arteries have been removed (4 of our 7 patients).

We achieved 100% success coverage, making SEAP flaps a good first choice option for these patients in our experience. However, the postoperative management remains difficult, with a



significant complication rate (71.4%). We do recommend close monitoring of the flap by a well-trained specialized plastic surgery team with dedicated nurse care. Post-operative complications can be explained by the fact that the caliber of the perforating vessels is often small, associated with a short length of the pedicle. These anatomical particularities may explain a great sensitivity of this flap to the twist and thus to the venous suffering. In a previous teams works <sup>11</sup> on propeller perforator flaps for chest wall defect, the SEAP flap had already been associated with a higher complication rate. As previously said, this can rely on intrinsic characteristic of the flap (caliber vessels, length of the pedicle, retrograde vessels flow after CABG) but also on specific characteristics of these patients (arterial disease, smoking status, ASA high score, etc...). In addition, experienced that the cover of the entire length of the sternum with SEAP flap, could favor the problem of venous return. Indeed, we observed that when the length to cover is greater than 20 cm we had a postoperative complication in venous return. Further studies will explore if this parameter may represent the limit of the venous perforasome <sup>12</sup>. Our results are comparable to those from Wettstein et al <sup>13</sup> using the same flap on a series of patients similar to ours. Indeed, they also reported 100% coverage success rate, but with an overall complication rate of 55.6% and among them three (33.3%) partial flap necrosis. Eburdery et al <sup>5</sup> reported a venous congestion in one of four patients treated with SEAP flap, resolving after leech therapy. As in our experience, it is interesting to note that the venous congestion appeared on a flap more than 20 cm-long. Moreover, in 1 patient a pectoralis major flap was needed to cover the upper third of the sternum to limit the SEAP length. Besides, Wettstein et al did not specify the length of their flaps in the manuscript.

The other perforator propeller flap being an alternative to cover sternal defect is the IMAP flap. Kannan et al <sup>4</sup> reported 4 patients covered by IMAP propeller flap with 2 patients presenting partial necrosis. The IMAP propeller flaps were used to treat superficial defect whereas they preferred musculo-cutaneous IMAP flap to cover deeper mediastinal defects. It should be noted

that the authors selected their cases to perform IMAP flaps, according to the initial cardiac surgery, even if in one case after CABG the perforating vessels were still present: maybe because the internal mammary artery was harvested being skeletonized. The IMAP flap is equivalent to the SEAP flap in term of cover capacity, as well as regarding the morbidity, but is not feasible in all patients especially after those after CABG. It has now been proved that muscle flaps do not provide any additional benefit in the treatment of underlying infections, as compared with perforator flap<sup>14-16</sup>, and create more donor site morbidity. In our opinion, these latest flaps should be used as a second intention, after perforator flap failure.

Even if demonstrative and representing one the largest series, this monocenter study remains limited by the small number of patients included. One should keep in mind that such population of patients remains rare even in high volume cardiac surgery departments. It is currently difficult to compare extensively SEAP and IMAP flaps, considering the lack of randomized studies and in view of the few cases published. Future meta-analytic studies are required to resolve this issue. However, since SEAP can be realized in all patients unlike IMAP, it became our preference as first line of treatment in this population. It would also be interesting in the future to compare the results of these flaps with those using the older classical muscle flap technique.

## **Conclusion**

The SEAP Perforator propeller flap is a reliable and safe surgical technique to achieve deep sternal wound infections treatment. This technique requires well-trained surgeons and postoperative team. Propeller perforator flaps change the management of these complex patients and may be currently considered as a first line option. These flaps open new possibilities in cardiac and thoracic reconstruction.

Authors contributions statement

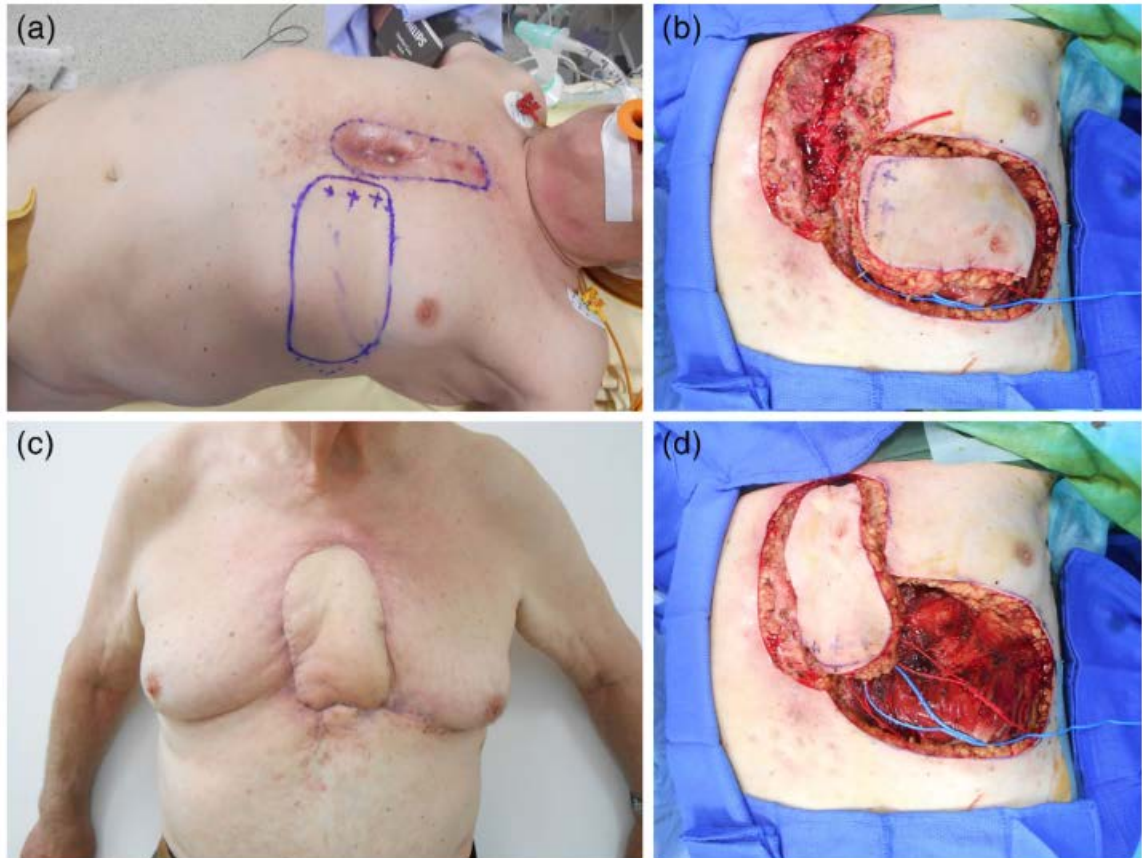


FIGURE 1(a) Preoperative SEAP flap markings with mapped perforating vessels. (b) Intraoperative view after debridement. (c) Intraoperative view after flap rotation at 90. (d) Postoperative view at 2 months

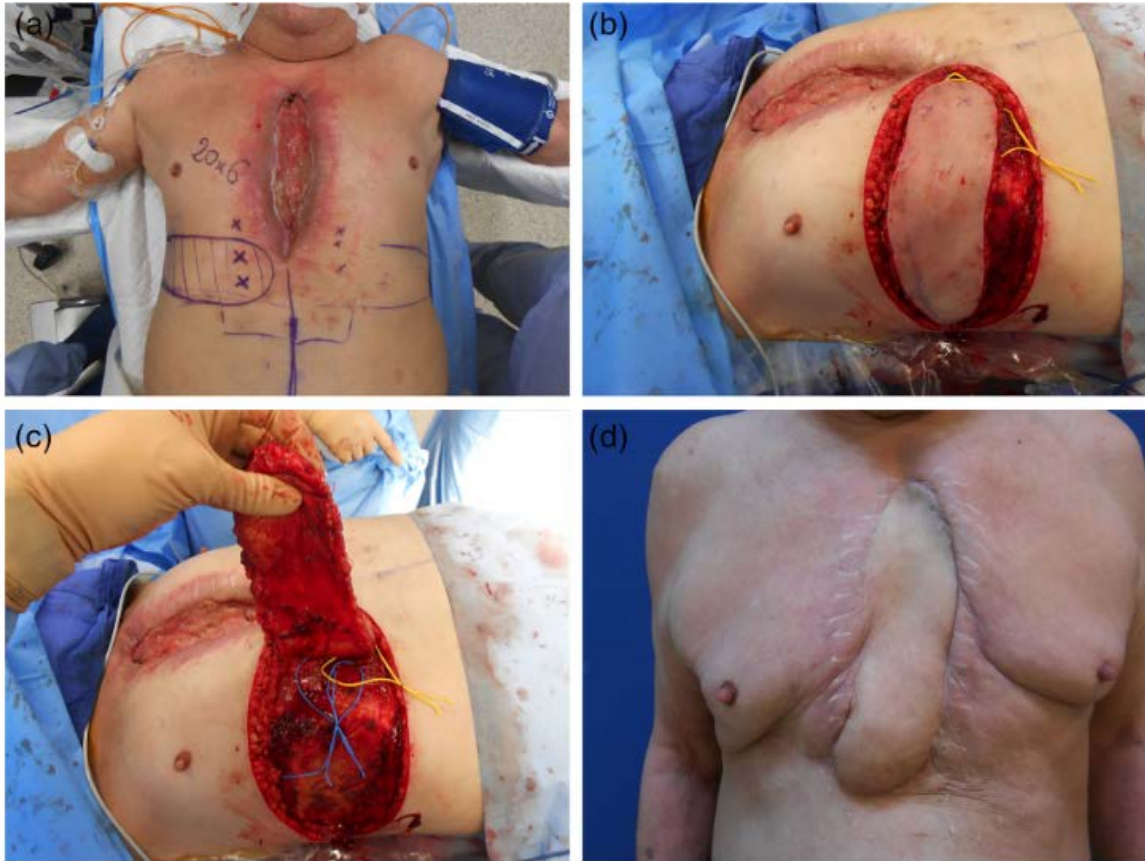

FIGURE 2(a) Preoperative SEAP flap markings with mapped perforating vessels. (b) Intraoperative view of flap harvesting (c) Intraoperative view of the perforating vessels. (d) Postoperative view at 12 months

Table 1 - General patient data

Patient	Age	Gender	BMI	Tobacco status	Original procedure	comorbidities	ASA
1	70	M	27.0	weaned tobacco	ARV	HBP, IHD, COB	3
2	76	M	25.7	weaned tobacco	CABG	HBP, IHD, obliterative arterial disease	3
3	78	F	40.1	active consumption	ARV	HBP, circulatory arrest, arrhythmias, smoking	4
4	74	M	28.7	non smoker	ARV	HBP, IHD	3
5	83	F	23.6	non smoker	CABG	IHD, obliterative arterial disease, immunosuppression	4
6	53	F	21.1	non smoker	CABG+ARV	HBP, IDH, obliterative arterial disease	3
7	71	M	26.1	non smoker	CABG+ARV	obliterative arterial disease	3

CABG: coronary artery bypass graft; ARV: Aortic Valve Replacement; HBP: high blood pressure; DM: Diabetes mellitus; IHD: Ischemic Heart Disease; COB: Chronic Obstructive Bronchopathy

Table 2 Flap Characteristics and outcomes

Patient	Age	Gender	Cause of defect	Defect size (in cm)	Flap skin paddle size (in cm)	Operative time	Flap related complications	Outcomes	Follow up (months)
1	70	M	Mediastinitis	20x6	27x8	190	Venous congestion, leech therapy	Healed wound, Alive	66
2	76	M	Mediastinitis	17x7	20x9	190	Venous congestion, leech therapy	Healed wound, death (D25)	1
3	78	F	Mediastinitis	17x10	24x9	152	No	Healed wound, Alive	56
4	74	M	Mediastinitis	16x10	18x8	180	No	Recurrent infection at 9 months, healed wound after reoperation, Alive	51
5	83	F	Mediastinitis	16x6	22x7	116	Venous congestion, leech therapy, partial distal necrosis	Healed wound, Alive	45
6	53	F	Mediastinitis	8x4	14x6	140	Venous congestion, leech therapy, superficial skin layer necrosis	Healed wound, Alive	42
7	71	M	Mediastinitis	20x6	16x6	130	Venous congestion, leech therapy, superficial skin layer necrosis	Healed wound, Alive	39

**Nicolas Bertheuil:** conception and design of the study, surgeon who operated patients, interpretation of the data and drafting of the manuscript, final approval of the version to be published.

**Franck Marie Leclere:** revising the article

**Farid Bekara:** revising the article

**Eric Watier:** revising the article

**Erwan Flécher:** critically revising the article, final approval of the version to be published.

**Jérôme Duisit:** drafting of the manuscript, final approval of the version to be published.

#### Funding statement

The authors received no funding support for the research of this article

#### Conflict of interest statement

The authors declared no potential conflicts of interest with the respect to the research, authorship and/or publication.

#### Figure Legends

Figure 1. **A** A 74-year old man with history of aortic valvular replacement, complicated with mediastinitis and deep sternal wound infection. The picture shows the pre-operative SEAP flap markings with mapped perforating vessels (crosses). **B** Intra-operative view after debridement, defect size 16x10 cm and flap size 18x8 cm. **C** Intra-operative view after flap rotation at 90°. **D** Post-operative view at 2 months.

Figure 2. **A** A 79 old year man with history of aortic valvular replacement, complicated by mediastinitis and deep sternal wound infection. The picture shows the pre-operative SEAP flap markings with mapped perforating vessels (crosses). **B** Intra-operative view of flap harvesting,

the skin paddle measured 27x8 cm. **C** Intra-operative view show the two perforating vessels. **D** Post-operative view at 12 months.

## REFERENCES

1. Goh SSC. Post-sternotomy mediastinitis in the modern era. *J Card Surg* 2017;32:556-66.
2. Aliu O, Diaz-Garcia RJ, Zhong L, McGlinn E, Chung KC. Mortality trends and the effects of debridement timing in the management of mediastinitis in the United States, 1998 to 2010. *Plastic and reconstructive surgery* 2014;134:457e-63e.
3. Jurkiewicz MJ, Bostwick J, 3rd, Hester TR, Bishop JB, Craver J. Infected median sternotomy wound. Successful treatment by muscle flaps. *Annals of surgery* 1980;191:738-44.
4. Kannan RY. The internal mammary artery perforator flap and its subtypes in the reconstruction of median sternotomy wounds. *The Journal of thoracic and cardiovascular surgery* 2016;152:264-8.
5. Eburdery H, Grolleau JL, Berthier C, Bertheuil N, Chaput B. Management of Large Sternal Wound Infections With the Superior Epigastric Artery Perforator Flap. *The Annals of thoracic surgery* 2016;101:375-7.
6. Chaput B, Bertheuil N, Gandolfi S, Grolleau JL, Herlin C. Perforator detection with a hand-held Doppler device: importance of the learning curve. *Burns : journal of the International Society for Burn Injuries* 2015;41:197.
7. Saint-Cyr M, Wong C, Schaverien M, Mojallal A, Rohrich RJ. The perforasome theory: vascular anatomy and clinical implications. *Plastic and reconstructive surgery* 2009;124:1529-44.



8. Chaput B, Herlin C, Grolleau JL, Bertheuil N, Bekara F. Reply: The Stitches Could Be the Main Risk for Failure in Perforator-Pedicled Flaps. *Plastic and reconstructive surgery* 2016;138:383e-5e.
9. Herlin C, Bertheuil N, Bekara F, Boissiere F, Sinna R, Chaput B. Leech therapy in flap salvage: Systematic review and practical recommendations. *Annales de chirurgie plastique et esthetique* 2017;62:e1-e13.
10. Pignatti M, Ogawa R, Hallock GG, et al. The "Tokyo" consensus on propeller flaps. *Plastic and reconstructive surgery* 2011;127:716-22.
11. Florczak AS, Chaput B, Herlin C, Rousseau P, Watier E, Bertheuil N. The Use of Pedicled Perforator Flaps in Chest Reconstruction: A Systematic Review of Outcomes and Reliability. *Annals of plastic surgery* 2018;81:487-94.
12. Chaput B, Grolleau JL, Garrido I, et al. Delayed procedure in propeller perforator flap: Defining the venous perforasome. *Journal of plastic, reconstructive & aesthetic surgery : JPRAS* 2017;70:286-9.
13. Wettstein R, Weisser M, Schaefer DJ, Kalbermatten DF. Superior epigastric artery perforator flap for sternal osteomyelitis defect reconstruction. *Journal of plastic, reconstructive & aesthetic surgery : JPRAS* 2014;67:634-9.
14. Buono P, Castus P, Dubois-Ferriere V, et al. Muscular Versus Non-Muscular Free Flaps for Soft Tissue Coverage of Chronic Tibial Osteomyelitis. *World J Plast Surg* 2018;7:294-300.
15. Hong JPJ, Goh TLH, Choi DH, Kim JJ, Suh HS. The Efficacy of Perforator Flaps in the Treatment of Chronic Osteomyelitis. *Plastic and reconstructive surgery* 2017;140:179-88.
16. Thiessen FE, Andrades P, Blondeel PN, et al. Flap surgery for pressure sores: should the underlying muscle be transferred or not? *Journal of plastic, reconstructive & aesthetic surgery : JPRAS* 2011;64:84-90.