



Closure of radial forearm free flap donor site: A comparative study between keystone flap and skin graft

Pauline Potet, Guillaume de Bonnecaze, Emilien Chabrillac, Agnès Dupret Bories, Sébastien Vergez, Benoit Chaput

► To cite this version:

Pauline Potet, Guillaume de Bonnecaze, Emilien Chabrillac, Agnès Dupret Bories, Sébastien Vergez, et al.. Closure of radial forearm free flap donor site: A comparative study between keystone flap and skin graft. *Head & Neck*, 2020, 42 (2), pp.217-223. 10.1002/hed.25977 . hal-03200476

HAL Id: hal-03200476

<https://hal.science/hal-03200476>

Submitted on 16 Apr 2021

HAL is a multi-disciplinary open access archive for the deposit and dissemination of scientific research documents, whether they are published or not. The documents may come from teaching and research institutions in France or abroad, or from public or private research centers.

L'archive ouverte pluridisciplinaire **HAL**, est destinée au dépôt et à la diffusion de documents scientifiques de niveau recherche, publiés ou non, émanant des établissements d'enseignement et de recherche français ou étrangers, des laboratoires publics ou privés.




Open Archive Toulouse Archive Ouverte (OATAO)

OATAO is an open access repository that collects the work of Toulouse researchers and makes it freely available over the web where possible

This is an author's version published in: <http://oatao.univ-toulouse.fr/27606>



Official URL: <https://doi.org/10.1002/hed.25977>

To cite this version:

Potet, Pauline and De Bonnecaze, Guillaume and Chabrillac, Emilien and Dupret Bories, Agnès  and Vergez, Sébastien and Chaput, Benoit *Closure of radial forearm free flap donor site: A comparative study between keystone flap and skin graft.* (2020) *Head & Neck*, 42 (2). 217-223. ISSN 1043-3074

Any correspondence concerning this service should be sent
to the repository administrator: tech-oatao@listes-diff.inp-toulouse.fr

Closure of radial forearm free flap donor site: A comparative study between keystone flap and skin graft

Pauline Potet MD¹  | Guillaume De Bonnecaze MD, PhD¹ | Emilien Chabrilac MD¹  | Agnès Dupret-Bories MD, PhD² | Sébastien Vergez MD, PhD^{1,2} | Benoit Chaput MD, PhD³

¹Department of ENT and Head and Neck Surgery, Toulouse University Hospital, Hôpital Larrey, Toulouse, France

²Department of surgery, Institut Universitaire du Cancer de Toulouse, Toulouse, France

³Department of Plastic and Aesthetic Surgery, Toulouse University Hospital, Hôpital Rangueil, Toulouse, France

Correspondence

Pauline Potet, Service ORLet CCF Hôpital Larrey, 24 chemin de Pouvoirville 31400 Toulouse, France.
Email: pauline.potet@hotmail.fr

Abstract

Background: The aim was to investigate the feasibility of radial forearm free flap (RFFF) donor site closure by keystone flap (KF) and compare its outcomes to those of skin graft (SG) closure.

Methods: One hundred and one patients who underwent RFFF for head and neck reconstruction were included (35 KF closure and 65 SG closure). Duration of wound healing and donor site complications was collected. After a minimal follow-up of 1 year, patients were questioned about functional and esthetic impairment.

Results: Coverage of donor site by KF was successful in all cases. The duration of wound healing was longer after SG than after KF (32 days vs 18 days, $P < .001$). Healing complications, esthetic and functional results were not statistically different.

Conclusion: Forearm donor site closure by KF is a feasible alternative to the traditional SG. Its main advantages are the reduced wound healing time and the avoidance of a second donor site.

KEY WORDS

esthetic and functional results, donor site morbidity, keystone flap, radial forearm free flap, skin graft

1 | INTRODUCTION

The fasciocutaneous radial forearm free flap (RFFF), increasingly used since Yang's description in a large series in 1981,¹ is commonly used in reconstructive surgery for head and neck tumors. Since the survival rate of the flap approaches 95%,² the attention of the surgeon has gradually focused on postoperative quality of life, most particularly on the donor site morbidity, which is often underestimated.³

Many possibilities of donor site closure have been described, ranging from direct closure to local flaps, including thin or full skin grafting, artificial dermis, expanders, or negative pressure therapy. Although skin grafting is the most frequently used technique, the question of an ideal way to close the donor site remains unanswered.⁴

We propose to adapt the use of keystone local flap to the closure of RFFF donor site. Keystone perforator island flap is a multiperforator advancement flap based on musculocutaneous or fasciocutaneous perforators, described by Behan in 2003.⁵

This study presents the Keystone local flap surgical technique and the outcomes of the RFFF donor site closure with both techniques.

Our objective was to prove the feasibility of closure by keystone flap (KF) and to compare its outcomes with skin graft (SG) in terms of wound healing, esthetic, and functional impairment.

2 | METHODS

We performed a monocentric retrospective study from January 2013 to October 2017 in the ENT and Head and Neck surgery

department of the University Institute of Cancer in Toulouse, France. We included 101 patients who received RFFF for reconstruction after head and neck tumor. Patient's agreement was collected in order to use their data for research and publication purposes.

We divided the population into two groups: a group of 36 patients for which a first surgical team systematically and consecutively performed a KF (group A), and a group of 65 patients for which a second surgical team systematically and consecutively performed a SG (group B).

Patients' demographics and characteristics were collected in the medical record: age, sex, co-morbidities (including tobacco use, diabetes, and cardiovascular disease), local complications, wound healing disorders and healing duration (in days).

The area of substance loss was calculated using the length and width of the antebrachial flap harvested (elliptical area for Keystone reconstructions and rectangular area for skin graft coverage).

After at least 12 months, patients were asked (on the phone or during consultation) about donor site current pain (visual analog scale for pain, out of 10), loss of grip strength (yes/no), local sensitivity (normal/decreased/abolished), esthetic self-assessment from 1 to 5 (1: ugly, 3: fair, 5: perfect). If necessary, the healing duration data were cross-referenced with the patient's statements. They were also asked a free description of their current global functional impairment. An esthetic hetero evaluation was performed for all donor sites by an independent examiner (same scale from 1 to 5), during consultation or by photograph.

2.1 | Surgical technique

The KF can be used for elliptical defects, with transfer of adjacent tissue for better color and contour match. The flap

is designed as two opposite V-Y flaps that are oriented parallel to the log axis of the defect.⁶

In the case of RFFF closure, the KF will be harvested from the ulnar side, vascularized by a rich network of ulnar artery perforators (Figures 1 and 2).⁷ Skin laxity is tested preoperatively by pinch test and must be sufficient to allow

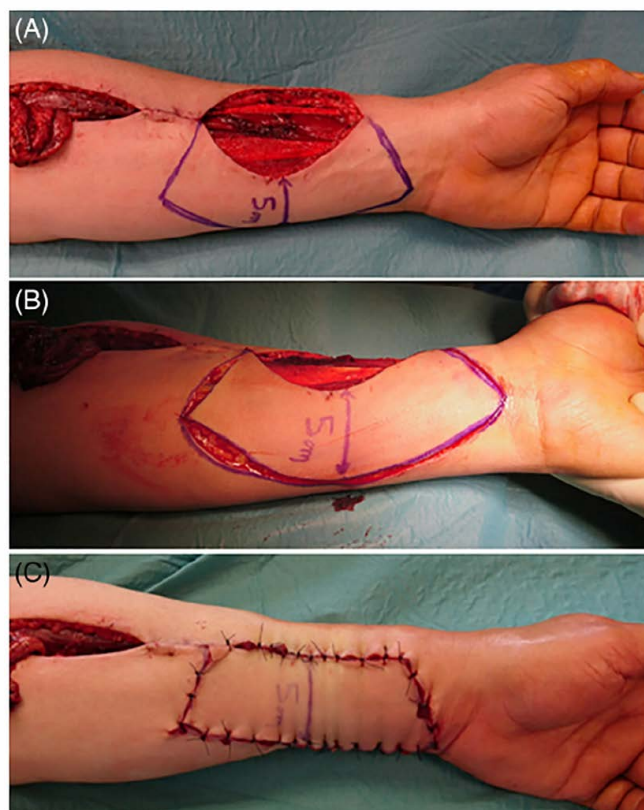


FIGURE 2 Surgical technique of coverage by keystone flap. A, Design of keystone flap. B, Blunt dissection. C, Closure with interrupted suture (nonabsorbable thread)

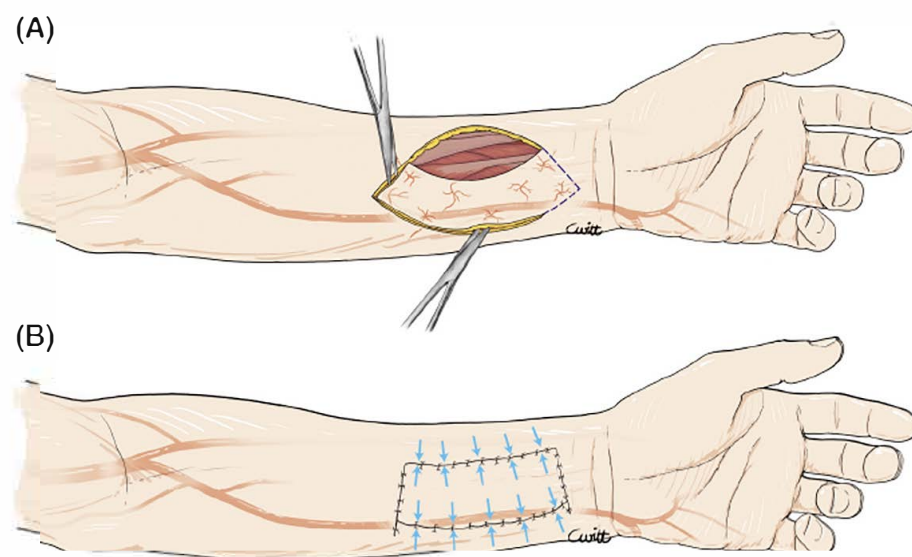


FIGURE 1 Design of keystone flap. A, Design of flap on ulnar side of defect. B, Distribution of tensions on the scar after closure

a direct closure by interrupted suture with nonabsorbable thread, generally at the cost of excessive tension.

An incision at 90° from the tip of the defect is performed to join the curvilinear line of the flap mark out. The flap width is equal to that of the defect. Blunt dissection of the subcutaneous tissue ensures mobilization of the flap and preserves venous and nervous networks. The closure is obtained with both subcutaneous and cutaneous interrupted suture.

3 | STATISTICAL ANALYSIS

Categorical variables were expressed as proportions and compared between groups using Fisher's exact test. Continuous variables were expressed as means with ranges and compared between groups using the Mann-Whitney *U* test. A two-sided *P* value < .05 was considered significant. All statistical analyses were performed using BiostaTGV software (Jussieu, France).

4 | RESULTS

Between January 2013 and October 2017, 101 patients underwent a head and neck reconstruction with forearm free

flap. A KF closure was performed for 36 of them (group A), and a SG coverage for 64 patients (group B).

One patient received an upfront SG closure, and a KF 15 days later due to SG loss with tendinous exposure. The latter was evaluated in group B concerning the initial outcomes, and then in group A.

KF postoperative care consisted of Redon drainage for 1 or 2 days, with a dry bandage. The sutures were removed after an average of 10 days.

The wound healing protocol after skin grafting consisted of an applied fixed fatty bandage removed after an average period of 5 days, as well as a wrist splint. Then the fat dressing was reproduced every day until complete healing.

Both groups were comparable in terms of age (*P* = .696), sex ratio (*P* = .109), and BMI (*P* = .912). The skin defect was significantly larger in group B compared to group A with 41.1 ± 13.4 and 28.7 ± 5.1 cm², respectively (*P* < .0001) (Table 1).

Coverage of the RFFF donor site was successful for all patients in group A. The median duration of local care was 14 days in group A and 28 days in group B (*P* < .001) (Table 2).

In group A, 11 patients had at least one wound healing complication. There were six wounds reopening (16.7%) with one

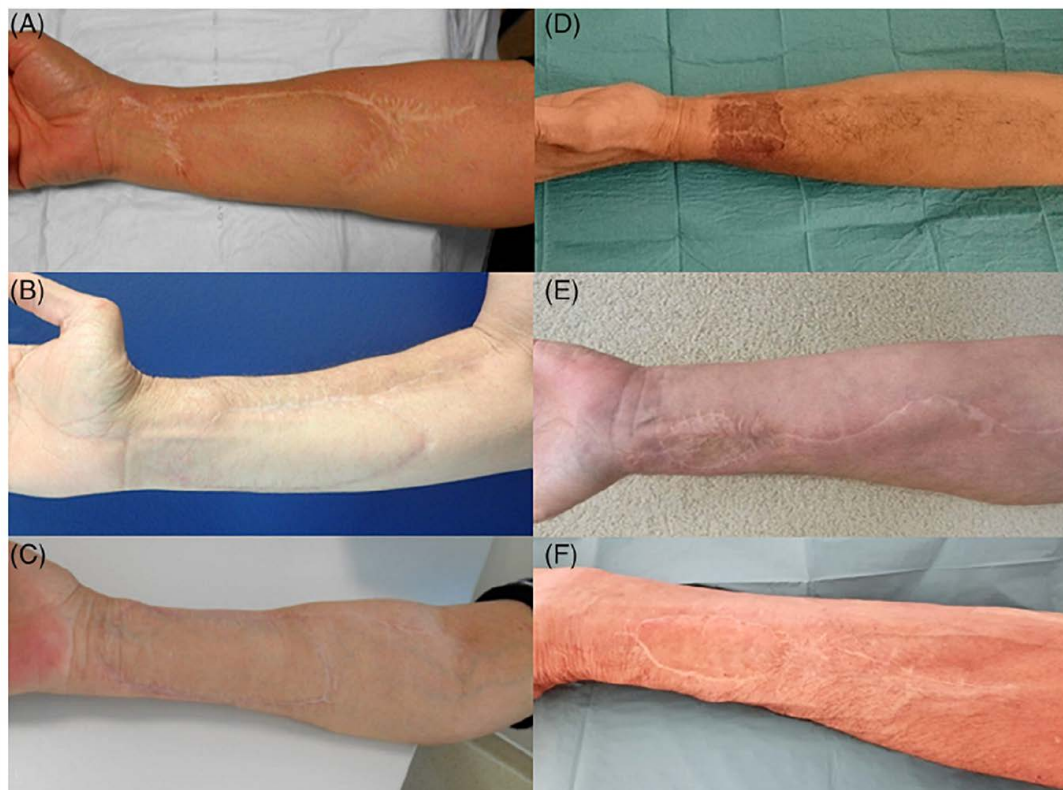

FIGURE 3 Esthetic results of radial forearm free flap donor site. A, Five years after closure by keystone flap. Esthetic score by patient: two of five. B, One year after closure by keystone flap. Esthetic score by patient: three of five. C, One year after closure by Keystone flap. Esthetic score by patient: all of five. D, Two years after closure by skin graft. Esthetic score by patient: one of five. E, Four years after closure by skin graft. Esthetic score by patient: three of five. F, Two years after closure by skin graft. Esthetic score by patient: all of five

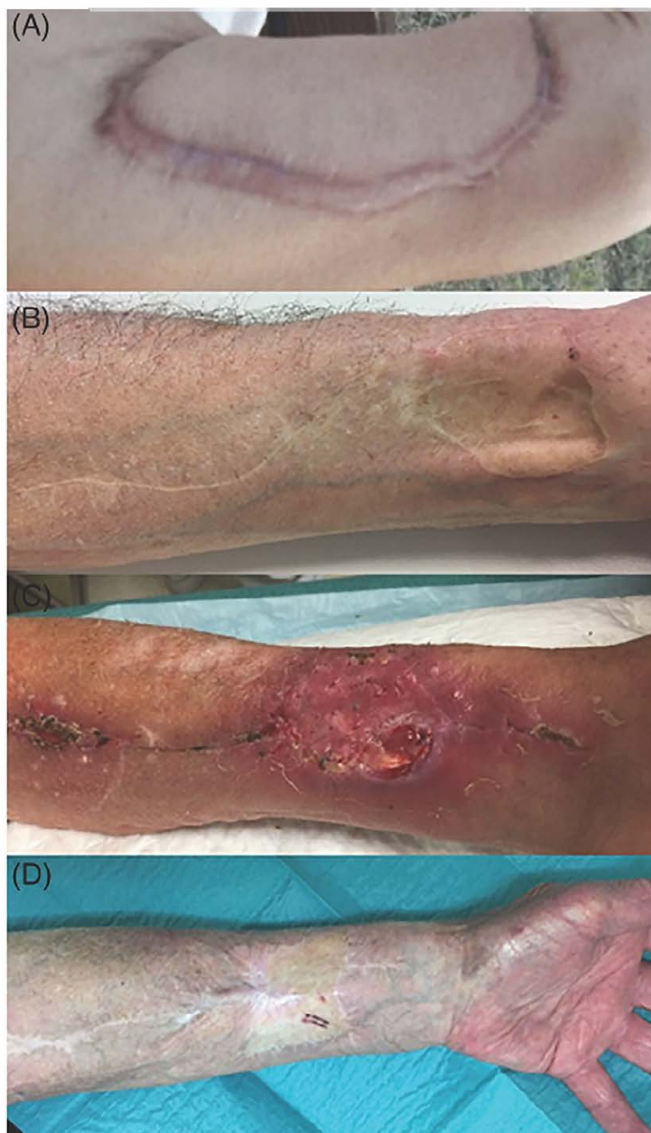

FIGURE 4 Wound complication examples. A, Hypertrophic scar after keystone flap. B, skin trough. C, Tendinous exposure. D, Pigmentation disorder

tendon exposure, three local infections, and four inflammations with significant distal edema (11%) also occurred, requiring in one case a stitch release to avoid compartment syndrome.

In group B, 21 patients presented at least one wound healing complication. There were 16 partial graft necroses (24.6%) with nine tendon exposures, three local infections, and four hematomas. One of the tendon exposures motivated a secondary coverage at 15 days by KF.

The morbidity was assessed after a minimum follow-up of 12 months (max: 5 years), either by telephone or during a consultation (Table 3). In group A, the average visual analog scale for pain was 0.61/10. Seven patients complained about hyperesthesia to touch or cold (27%), limited to the scar for three of them. Two patients (7%) deplored a “cardboardy” appearance of the reconstruction, and one patient described neuropathic pain (3.8%).

TABLE 1 Patient characteristics

	Group A keystone flap (n = 36)	Group B skin graft (n = 65)	P
Age, median (years)	60.5 [34 79]	61 [29 87]	
Sex			
• Male	23	51	.109
• Female	13	14	
BMI, median	23.15 [16.3 31.4]	23.3 [14.2 31.6]	.9
Comorbidities			
• Smoking	21	47	
• Diabetes	2	6	
• Cardiovascular disease	5	7	
Tumor site			
• Oral cavity	17	29	
• Oropharynx	15	22	
• Hypopharynx	3	9	
• Lip	0	2	
Flap surface (cm ²)	28.7	41.1	.001

TABLE 2 Healing complication and duration

	Group A keystone (n = 36)	Group B skin graft (n = 65)	P
Patients with at least one complication	11 (30.5%)	21 (32.3%)	
• Partial necrosis of skin graft		16 (24.6%)	
• Wound reopening	6 (16.7%)	0	
• Tendinous exposure	1 (2.8%)	9 (13.8%)	.091
• Hematoma	1 (2.8%)	4 (6.2%)	
• Infection	3 (8.3%)	3 (4.6%)	
• Edema (± epidermolysis)	4 (11.1%)	0	
Healing time, median (days)	14 [7 42]	28 [14 168]	.001

In group B, the average visual analog scale for pain was 1.4/10 (Figure 3). Ten patients (21%) had hyperesthesia, six patients (12%) complained about the cardboard-like appearance, and one felt neuropathic pain (2.1%).

Regarding the sensitivity of the reconstructed skin paddle, a disorder (hypoesthesia or anesthesia) was reported by nine patients (34%) in group A and 28 patients (59%) in group B ($P = .049$).

TABLE 3 Esthetic and functional evaluation after at least 1 year

	Group A keystone (n = 26)	Group B skin graft (n = 47)	P
Pain, mean (VAS from 0 to 10)	0.61	1.4	
Skin paddle sensitivity disorder	9 (34.6%)	28 (59.5%)	.049
Decreased grip strength	5 (19.2%)	11 (23.4%)	
Esthetic self evaluation, mean (from 1 to 5)	3.46	3.54	
Esthetic hetero evaluation, mean (from 1 to 5)	2.76	2.70	
Discomfort			
• Hyperesthesia	7 (26.9%)	10 (21.3%)	
• Cardboard like appearance	2 (7.7%)	6 (12.8%)	
• Neuropathic pain	1 (3.8%)	1 (2.1%)	

The patients' mean esthetic score was 3.46/5 and 3.51/5, respectively, in group A and B. The average score given by the independent examiner was 2.76/5 and 2.70/5, respectively. The esthetic score differences were not statistically significant.

5 | DISCUSSION

This case-control study compares SG with KF for donor site closure after forearm free flap harvesting.

In our study, the overall early wound healing complication rate after skin grafting (partial graft necrosis, hematoma, infection, and tendon exposure) was 32%. In a prospective study on 86 patients, Richardson et al.⁸ found 16% of partial SG necrosis, and 13% of tendon exposure, comparable to our results: 13% of tendinous exposure and 24% of partial graft necrosis.

Wound healing complications after donor site closure are responsible for an increased length of postoperative care (Figure 4). In our study, the average healing time after skin grafting was 4 weeks, which is consistent with the literature: 4.68 weeks in a study by Karini et al.⁹

The major late complaints described in the literature are lack of cutaneous thickness, loss of grip strength, decrease in joint amplitude, dysesthesia, hypoesthesia in the territory of the superficial sensory branch of the radial nerve, paresthesia, pruritus, hypersensitivity to cold, neuropathic pain, and unsightly scar.^{4,10-14} In group B, 59.5% of patients had sensitivity disorders of the reconstructed skin paddle (hypoesthesia or anesthesia). 34.6% patients reported hyperesthesia to touch. Twenty-two

patients reported a tolerable pain at rest (VAS 1.4). 23.8% of patients reported a subjective decrease in strength or amplitude of the wrist.

The sequelae as well as the healing disorders may be related to the RFFF harvesting itself and are therefore not modifiable: consequence of the vascular flow changes after radial artery flow interruption, causing, for example, hypersensitivity to cold.

These sequelae and complications may also be due to the flap dissection procedure, the patient's comorbidities and, finally, the covering technique. Several studies compared various closure techniques and failed to demonstrate the superiority of one of them.^{4,15,16}

Some procedures are known to reduce the donor site morbidity. Supra-fascial dissection can provide a complication rate of 6%.¹⁷ Closing by a purse string suture can reduce by up to 44% the area to be grafted and thus the risk of healing complication.^{9,18,19} A careful tendinous coverage by peritendinous tissue ensures both better support for engraftment and a lesser risk of postoperative tendon exposure.¹⁷ The use of a wrist splint in order to limit wrist mobility for a short time tends to improve healing, especially after skin grafting.¹³ The use of artificial dermis or collagen matrix associated or not with skin grafting, may allow for a reduction of scarring complications.²⁰

The split-thickness skin graft is widely used because it is simple and not limited by the size of the defect. However, it requires an additional donor site (frequently the anteromedial side of the thigh), involves more pain and wound care, and can cause skin depigmentation. This thin coverage provides a cutaneous depression, a risk of pruritus, and a lesser protection of the noble structures (particularly tendinous and nervous ones) favoring hypersensitivity to touch and cold.

Full-thickness skin graft is a comparable type of wound closure that provides slightly better esthetic outcomes than split-thickness skin graft. Its donor site is closed primarily and is thus less painful.²¹ Some authors harvested a full-thickness skin graft at the level of the RFFF pedicle, avoiding an additional donor site.^{9,22}

A primary coverage by local flap, with consistency and color similar to those of defect, theoretically provides greater protection against tendon exposure and skin paddle hyperesthesia.

Foissac et al. suggest the use of a perforator flap that arises distally to the ulnar artery for tendon exposure coverage after primary closure.²³ Elliot et al. in 1988²⁴ and then Jaquet et al. in 2012¹² described the use of ulnar transposition flap, based on an ulnar perforator artery, for primary closure of small and medium donor site defects.

Our study brings to light that KF provides a reduction in healing time, with a median duration of 14 days in group A and 28 days in group B ($P < .001$). Moreover, we observed less tendon exposure after KF closure, at the cost of an increased risk of

compartment syndrome. Early wound healing disorders were not greater in group A.

Concerning esthetic and functional outcomes, sensitivity disorders were less frequent after KF closure than after skin grafting (34.6% vs 59.5%, $P = .049$). This can be explained by the preservation of deep sensory pedicles. The skin paddle hypoesthesia, frequently reported after skin grafting, is limited to the scar with KF closure, thus decreasing the risk of injury. The analysis of other parameters (esthetic self and hetero-evaluation, grip strength, and distal pain) did not show any significant difference between the two groups.

Postoperative pain was not assessed because this criterion is neither reliable nor reproducible in a retrospective study. Nevertheless, it seems to us that the KF is more painful during the first few days (because of the significant tension of the closure, leading to local edema), while the skin graft preferentially causes burning pain on the secondary harvesting site.

The main complication of this closure is the compartment syndrome, requiring close monitoring of edema, tenderness, and distal motricity in the early postoperative days.

The KF is suitable for small to medium size defects. In our study, the calculated area of group A flaps (elliptical) is statistically smaller than the estimated area of group B grafts (rectangular) (28.69 vs 41.05 cm²; $P < .001$). The average area of group A flaps is comparable to literature data for local perforator flaps: between that of the series of Jaquet et al. (19.8 cm²)¹² and Hsieh et al. (47 cm²).²⁵

In our study, the preoperative assessment of KF coverage possibility is not based on the defect size, but on the ratio of the flap width to the forearm perimeter as well as on skin laxity.

This flap is less favorable on colored skin.²⁶ It is indeed based on tension distribution on scars, which is a risk factor for keloid scars.

The limitations of our study were the bias of retrospectively collected data and the absence of morbidity analysis of the SG secondary harvesting site. Our study does not establish clear-cut criteria for choosing this type of reconstruction, but it demonstrates that this technique is an interesting alternative to skin grafting.

Future studies should prospectively evaluate postoperative pain, skin graft donor site morbidity, and objective measures of the ratio of the flap width to the forearm perimeter in order to propose precise indications for KF.

6 | CONCLUSION

While the radial forearm is the ideal choice for closure of many defects, the donor site morbidity remains an issue, with no method of closure conclusively superior to another. This study offers a valuable alternative to the closure of small to medium sized radial forearm flap donor sites. Keystone-type local flap closure is an interesting option to skin graft closure that

provides coverage of the donor site with reduced healing time and acceptable outcomes.

CONFLICT OF INTEREST

There are no conflicts of interest.

ORCID

Pauline Potet  <https://orcid.org/0000-0001-6869-6284>

Emilien Chabrilac  <https://orcid.org/0000-0003-4113-2846>

REFERENCES

1. Yang G, Chen B, Gao Y, et al. Forearm free skin flap transplantation [in Chinese]. *Natl Med J China*. 1981;61:139.
2. Wood JW, Broussard KC, Burkey B. Preoperative testing for radial forearm free flaps to reduce donor site morbidity. *JAMA Otolaryngol Neck Surg*. 2013;139(2):183.
3. Harris BN, Bewley AF. Minimizing free flap donor site morbidity. *Curr Opin Otolaryngol Head Neck Surg*. 2016;24(5):447-452.
4. Pabst AM, Werkmeister R, Steegmann J, Hölzle F, Bartella A. Is there an ideal way to close the donor site of radial forearm free flaps? *Br J Oral Maxillofac Surg*. 2018;56(6):444-452.
5. Behan FC. The keystone design perforator Island flap in reconstructive surgery. *ANZ J Surg*. 2003;73(3):112-120.
6. Chaput B, Herlin C, Espié A, Meresse T, Grolleau JL, Garrido I. The keystone flap alternative in posttraumatic lower extremity reconstruction. *J Plast Reconstr Aesthet Surg*. 2014;67(1):130-132.
7. Abraham JT, Saint Cyr M. Keystone and pedicle perforator flaps in reconstructive surgery. *Clin Plast Surg*. 2017;44(2):385-402.
8. Richardson D, Fisher SE, Vaughan ED, Brown JS. Radial forearm flap donor site complications and morbidity: a prospective study. *Plast Reconstr Surg*. 1997 Jan;99(1):109-115.
9. Karimi A, Mahy P, Reyckler H. Closure of radial forearm free flap donor site defect with a local meshed full thickness skin graft: a retrospective study of an original technique. *J Cranio Maxillofac Surg*. 2007;35(8):369-373.
10. de Witt CA, de Bree R, Verdonck de Leeuw IM, Quak JJ, Leemans CR. Donor site morbidity of the fasciocutaneous radial forearm flap: what does the patient really bother? *Eur Arch Otorhinolaryngol*. 2007;264(8):929-934.
11. Orlik JR, Horwich P, Bartlett C, Trites J, Hart R, Taylor S. Long term functional donor site morbidity of the free radial forearm flap in head and neck cancer survivors. *J Otolaryngol Head Neck Surg*. 2014;43(1):1.
12. Jaquet Y. Radial forearm free flap donor site morbidity ulnar based transposition flap vs Split thickness skin graft. *Arch Otolaryngol Head Neck Surg*. 2012;138(1):38.
13. Emerick KS, Deschler DG. Incidence of donor site skin graft loss requiring surgical intervention with the radial forearm free flap. *Head Neck J*. 2007;29(6):573-576.
14. Fang Q G, Shi S, Zhang X, Li Z N, Liu F Y, Sun C F. Upper extremity morbidity after radial forearm flap harvest: a prospective study. *J Int Med Res*. 2014;42(1):231-235.

15. Ho T, Couch M, Carson K, Schimberg A, Manley K, Byrne PJ. Radial forearm free flap donor site outcomes comparison by closure methods. *Otolaryngol Head Neck Surg.* 2006;134(2):309 315.
16. Zuidam JM, Coert JH, Hofer SOP. Closure of the donor site of the free radial forearm flap: a comparison of full thickness graft and Split thickness skin graft. *Ann Plast Surg.* 2005;55(6):612 616.
17. Shonka DC, Kohli NV, Milam BM, Jameson MJ. Suprafascial harvest of the radial forearm free flap decreases the risk of postoperative tendon exposure. *Ann Otol Rhinol Laryngol.* 2017;126(3): 224 228.
18. D'arpa S, Cillino M, Mazzucco W, et al. An algorithm to improve outcomes of radial forearm flap donor site. *Acta Chir Belg.* 2018; 118(4):219 226.
19. Winslow CP, Hansen J, Mackenzie D, Cohen JI, Wax MK. Pursestring closure of radial forearm fasciocutaneous donor sites. *Laryngoscope.* 2000;110(11):1815 1818.
20. Wester JL, Pittman AL, Lindau RH, Wax MK. AlloDerm with Split thickness skin graft for coverage of the forearm free flap donor site. *Otolaryngol Head Neck Surg J.* 2014;150(1):47 52.
21. Kim TB, Moe KS, Eisele DW, Orloff LA, Wang SJ. Full thickness skin graft from the groin for coverage of the radial forearm free flap donor site. *Am J Otolaryngol.* 2007;28(5):325 329.
22. Riecke B, Assaf AT, Heiland M, et al. Local full thickness skin graft of the donor arm a novel technique for the reduction of donor site morbidity in radial forearm free flap. *Int J Oral Maxillofac Surg.* 2015;44(8):937 941.
23. Foissac R, Benatar M, Dassonville O, Bozec A, Poissonnet G, Camuzard O. Coverage of tendon exposure after radial forearm free flap by the Dorsoulnar artery perforator flap. *Otolaryngol Head Neck Surg.* 2017;156(5):822 827.
24. Elliot D, Bardsley AF, Batchelor AG, Soutar DS. Direct closure of the radial forearm flap donor defect. *Br J Plast Surg.* 1988;41(4):358 360.
25. Hsieh C H, Kuo Y R, Yao S F, Liang C C, Jeng S F. Primary closure of radial forearm flap donor defects with a bilobed flap based on the fasciocutaneous perforator of the ulnar artery. *Plast Reconstr Surg.* 2004;113(5):1355 1360.
26. Bhat S. Keystone flaps in coloured skin: flap technology for the masses ? *Indian J Plast Surg.* 2013;46(1):36.

How to cite this article: Potet P, De Bonnacaze G, Chabrilac E, Dupret-Bories A, Vergez S, Chaput B. Closure of radial forearm free flap donor site: A comparative study between keystone flap and skin graft. *Head & Neck.* 2020;42:217 223. <https://doi.org/10.1002/hed.25977>