



HAL
open science

Orthodontic treatment of children with class II division 1 with severe MIH involving first permanent molars extractions: A case report

Estelle Moulis, Stéphane Barthélemy, Laurent Delsol

► To cite this version:

Estelle Moulis, Stéphane Barthélemy, Laurent Delsol. Orthodontic treatment of children with class II division 1 with severe MIH involving first permanent molars extractions: A case report. *International Orthodontics*, 2020, 18 (4), pp.885-894. 10.1016/j.ortho.2020.09.008 . hal-03198221

HAL Id: hal-03198221

<https://hal.science/hal-03198221>

Submitted on 15 Dec 2022

HAL is a multi-disciplinary open access archive for the deposit and dissemination of scientific research documents, whether they are published or not. The documents may come from teaching and research institutions in France or abroad, or from public or private research centers.

L'archive ouverte pluridisciplinaire **HAL**, est destinée au dépôt et à la diffusion de documents scientifiques de niveau recherche, publiés ou non, émanant des établissements d'enseignement et de recherche français ou étrangers, des laboratoires publics ou privés.



Distributed under a Creative Commons Attribution - NonCommercial 4.0 International License

Case report

Orthodontic treatment of children with class II division 1 with severe MIH involving first permanent molars extractions: A case report

Estelle Moulis¹, Stéphane Barthélemy², Laurent Delsol²

¹ Department of Paediatric Dentistry, Montpellier University, Montpellier, France.

² Department of Orthodontics, Montpellier University, Montpellier, France.

Correspondence: Stéphane Barthélemy, Department of Orthodontics, Montpellier University, , 545 avenue du Professeur JL Viala, 34000 Montpellier, France.

Email: steph.barthelemy@wanadoo.fr

Abstract

Background > Class II division 1 is the most common malocclusion in Europe. When the overjet is severe, the risk of trauma on anterior maxillary teeth as well as the risk of being bullied at school is increased. From this point of view, early treatment reduces the risk of dental fracture and increases patient self-esteem. In another hand, MIH is frequent with a prevalence of around 15% in children with country specificity, and molars in particular are difficult to treat endodontically with good long-term results when the MIH is severe.

In many cases when the third molars are present, the extraction of the affected teeth followed by an orthodontic treatment remains the best solution but requires adequate orthodontic mechanics.

Objective > The purpose of this article is to display one case of class II division1 with MIH treated by orthopaedic therapy and followed by molar extractions and fixed appliance.

Keywords

Introduction

Class II division 1 is a very frequent malocclusion in Europe with an increased overjet [1] and mainly due to a retrognathic mandible. The risk of such overjet in young patients is anterior dental trauma [2] as well as being bullying at school which is particularly important in class II division 1 patients [3]. The Molar-Incisor Hypomineralisation (MIH) is also relatively frequent in young patients, around 15% of children with many country variations [4] and with many difficulties of restorative treatments. In these cases when the prognosis of the four first permanent molars is poor, the extractions followed by an orthodontic treatment with extraction space closure is a good issue when the third molars germs are present offering the patient a definitive solution to this problem. When the MIH is combined with the class II division 1 malocclusion, the orthodontic mechanics should be adequate to avoid side-effects of the extraction space closure. When the skeletal pattern is adequate, temporary bone anchorage devices (TADS) are helpful for anchorage control, but in young patients the loss rate is increased due to the quality of bone, and in some cases the orthodontist must deal with the dental anchorage only.

Molar-Incisor Hypomineralisation (MIH)

In 2001 Molar-Incisor Hypomineralisation (MIH) was suggested by Weerheijm et al. (5) to describe an enamel developmental defect defined as a hypomineralisation of systemic origin of one to four first permanent molars (FPM), sometimes associated with similarly affected permanent incisors. This structural qualitative enamel defect is caused by reduced mineralisation and inorganic components and leads to demarcated opacities, from white-creamy, yellow, yellowish brown to brown. Opacities are usually localized to the occlusal or buccal third of the crown, rarely involving the cervical third [5,6]. Hypomineralised enamel, more porous and less hard than normal enamel, has less distinct prism edges and crystals. This may contribute to the development of tooth decay; thus, a systematic review showed a significant association between MIH and tooth decay [7,8]. Affected teeth are more sensitive to thermal stimuli and children frequently report pain when brushing teeth, poor dental brushing facilitates plaque accumulation and decay development [7-10].

Prevalence of MIH

Prevalence of MIH worldwide has been reported from 2,8 to 40%. A lack of standardization of criteria for diagnosing MIH could explain these variations but a recent meta-analysis including 70 studies showed a high overall prevalence of MIH (14,2%) (4). Globally, in the studies, no statistical difference between genders were identified [10,11].

Aetiology of MIH

Etiological mechanisms are still unclear but seem to be multifactorial. Disruption to ameloblast function during the late stage of amelogenesis is thought to be involved. Prenatal, perinatal and post-natal factors have been explored and showed that acute or chronic illness or exposure to environmental pollution such as dioxins or bisphenol A during the last gestational trimester or the first three years of life may contribute to MIH occurrence. A combination of factors and their action in synergism have been suggested; perinatal complications, premature birth, oxygen starvation, low birth weight, respiratory tracts infections, fevers, childhood diseases, use of antibiotics or prolonged breast feeding [8,9,12-15].

Clinical appearance – diagnosis of MIH

MIH Intra and Inter-patient variability is very large. Defects are asymmetrical for both presence and severity but when a severe defect is found in a tooth it is likely that the contralateral tooth is also affected. Molars are generally more hypomineralised than incisors but when several molars are affected the risk of finding incisor opacities is increased [16,17]. However, similar enamel hypomineralisation have been reported in other teeth i.e. primary teeth and permanent cuspids, bicuspid and second molars [18]. The presence of hypomineralised second primary molars (HSPM) could be a predictive factor for MIH [14,17,19].

MIH clinical appearance depends on the severity of the lesions determined by the size (larger than 1 mm for MIH defect [19] and the depth of hypomineralisation. Hypomineralised brittle enamel can lead to post-eruptive breakdown, plaque deposit and rapid decay. Thus, MIH may be classified as mild, moderate or severe [19,20], *figure 1*. In mild MIH, opacities are located in non-stress bearing areas, there are no caries, no hypersensitivity and the incisors are usually mildly affected if concerned. In moderate MIH, limited post-eruptive enamel breakdown on molars are due to important masticatory forces and incisors are frequently involved. In severe MIH, the whole enamel layer is hypomineralised, and large cuspal breakdowns prone to rapid secondary caries due to hypersensitivity, lack of hygiene and dental plaque retention, crown

destruction and atypical restorations are likely. In addition, in severe cases of MIH, regular hypersensitivity, pain and re-treatment cycles affect children's quality of life [21,22]. Recently, severity systems have been proposed, taking particularly into account the particularly the opacities colours. Indeed, a long-term follow-up showed that yellow and brown opacities are more linked to breakdown than white ones. All these indexes aim to guide clinicians in managing and treatment of MIH [23-25].

Treatment challenge – First Permanent Molar (FPM) extractions and orthodontic treatment of MIH

Treatment of severely affected molars present real challenges for clinicians, and has many negative clinical impacts, teeth sensitivity resulting in poor local hygiene, caries susceptibility increase, chronic pulp inflammation and difficulties in obtaining adequate local analgesia, multiple dental procedures and restorations failures, and dental fear and behavioural management difficulties [23,24]. The first problem in severe MIH is to specify the cavity margins. Glass ionomer cement can be used as an intermediate approach when moisture control is not possible until permanent restoration by resin composite can be done. If composites are the most suitable materials, the enamel-adhesive interface in MIH is more porous and often lead to cohesive failures. Thus, preformed dental crowns can be used with a high success rate [9,21,26]. Finally, tooth removal combined with an orthodontic treatment must be considered as an alternative to avoid the spiral of failure and multiple dental procedures in anxious and fearful children. The first clinical step in severe MIH is to decide whether to restore or to extract these FMPs considering several factors such as child's age, dental crowding, malocclusion, overbite, agenesis, presence of the third molars, status of neighbouring teeth, FPMs restorations long-term prognosis or need for endodontic treatment if pulp is irretrievably damaged. Severe MIH treatment is demanding and requires close and early collaboration between the paediatric dentist and the orthodontist to determine the optimal moment to extract such molars. Ideal age should be radiographically indicated by the beginning of the calcification of the lower second molar's bifurcation (maxilla 8,5-10 years, mandible 10,5-11,5 years) [21, 26-27] when there is no associated malocclusion. Extraction of the four FMPs may achieve the best long-term prognosis and promotes the establishment of a functional arch by the mesial drift of the second permanent molar and later by the eruption of the third permanent molar [27].

When the mandibular aetiology is determined and when the skeletal pattern of the patient is deep bite, the extraction of permanent teeth is not suitable. However, when the class II malocclusion is associated with an MIH affecting the first permanent molars, orthodontic treatment involving extractions of the first molars with poor prognosis is sometimes necessary. The aim of this paper is to describe the treatment management of a case of class II division 1 with MIH, involving class II correction and extractions of the four FPM.

Diagnosis of the clinical case report

Anamnesis

A 10.3-year-old girl, without any general health problems was referred by her general dentist for orthodontic treatment. The patient did not like the overjet and her facial appearance, and expressed some difficulties with mastication due to the severe MIH on the four first molars.

Extraoral examination (figure 2)

Face: The face was "respiratory" on Sigaud classification. It was approximately symmetrical with a slight deviation of the nose to the right side and the chin to the left side. Bi-commissural and bi-pupillary lines were non-parallel with left side convergence. Nasal

pyramid was average. The left eye had an anti-mongoloid orientation. Nostrils were not very visible and did not look completely functional. The upper lip was quite thin, the lower lip was wider, and they were not closed at rest.

Profile: The profile was convex with a retrognathic mandible, but the chin was present in the profile. The nasal ensella was well defined; the naso-labial angle was very open. The labial relationship was reversed with retrusion of the lower lip and the labio-mental line was increased.

Smile: The smile was quite poor and revealed only the maxillary incisors and the primary cuspids.

Functional examination

Ventilatory function: Mixed. No allergy, no ENT procedure.

Tongue examination: Primary deglutition with anterior interposition. The volume was average and the mobility was limited due to lingual fraenum. The tonicity was good.

Labial and facial muscular tonicity: was weak for lips and average for facial muscles.

TMJ examination: Rectilinear closure and no joint noises.

C0/CR: Identical.

Adverse Habits: None.

Intraoral examination (figure 2)

The patient was in mixed dentition, the four second deciduous molars have been extracted due to MIH with mesial version of the four first permanent molars, resulting in a lack of space for the second bicuspid eruption and they present severe MIH. MIH was also visible on the central maxillary incisors. No restorations were visible. The over-bite was severe. The periodontium was average, inflammatory on the anterior area of maxillary arch due to mixed oral/nasal breathing. The upper lip fraenum had a normal insertion. Lateral bridles on the maxillary arch were present.

Panoramic radiograph (figure 3)

A severe MIH on the first four molars was visible. All permanent dental germs were visible including third molar germs. 55,65,75 and 85 were not present with a lack of space for second bicuspid eruption. There was a severe lack of space for 43 eruption and the risk of impaction of maxillary canines was high.

The length of the roots looked good without any root resorption and a good alveolar bone level.

The nasal cavities did not look clear and the maxillary sinus was not clear on the right side.

The condyles are symmetrical with a normal shape.

Lateral X-rays (figure 3)

Facial cavities were well developed and clear. The airways were wide and not obstructed by palatal or pharyngeal tonsils. The palatal plane was linear without rotation.

Mandible morphology according to Björk signs was normodivergent. The mental symphysis was thick. The soft tissues were thinner on the mental area and the labio-mental line was reduced due to lip closure with effort. The hyoid bone was situated towards C3.

The maxillary incisor edge was situated 2mm under the labial junction.

The patient presented a skeletal Class II malocclusion with a retrognathic mandible and chin compensation, a normal vertical skeletal pattern, an increased overbite and overjet with correct incisors angulation.

Treatment plan

A two-phase treatment was planned. The first step was to correct the transverse maxilla deficiency by alveolar expansion by Quad Helix, followed by a Lautrou class II activator to stimulate the mandibular growth and a tongue physiotherapy.

The second step was a fixed appliance straight wire technique with extractions of 16, 26, 36 and 46 to solve the severe MIH problem and the discrepancy at the mandible in particular.

A class II mechanics was associated to improve the mandibular growth.

-Multiband appliance .022x.028 straight wire technique with .020x.028 slot on maxillary incisors to increase the torque control, with 16, 26, 36 and 46 extractions. The third molars were scheduled to be controlled at the end of treatment and eventually placed on the arches.

-16, 26, 36 and 46 were extracted two months before the bonding

-The maxillary arch was equipped first followed by the mandibular arch 3 months later, waiting for the evolution of the blocked 35 and 46 due to the early extractions of 75 and 85

-After alignment, maxillary space closure was planned only by mesialisation of 16 and 26 to avoid the increase of the naso-labial angle which was already very open. At the mandible level, space closure was done on the right side by retracting the first bicuspid to allow cuspid alignment, and the remaining space closure was achieved by molar mesialisation

-Class II mechanics was applied when .019x.025 SS archwires were placed on the two arches with 4.5oz 5/16^e worn 22 hours/day to facilitate the mandibular extractions space closure and stimulate the mandibular growth

-Finishing and intercuspatation phases were done with TMA arch wires and class II elastics worn 14 hours per day.

- A physiotherapy accompanied the active treatment and the retention phase.

-A bonded retainer cuspid-to-cuspid for the mandible and tongue-repositioning device worn 14 hours per day were done to help stability and wait the third molars eruption.

Treatment follow-up

-At the end of the early treatment (Quad Helix 5 months and Class II activator 7 months), the transverse maxillary dimension was normalized and the overjet was reduced, but there was still a cuspid class II on the left side. On the facial point of view the lip closure was better, but the profile remained retrognathic (*figure 4*). At this point the discussion was focused on the MIH problem as the first four molars were compromised and the mandibular growth was disappointing despite an excellent cooperation in the activator wearing. The patient and the parents were in favour of the four first molar extractions due to permanent pain of the patient on these teeth and the presence of the four third molar germs, but were against surgery for the mandibular deficiency.

-The fixed appliance was placed at the age of 13.9 as it was necessary to wait for the evolution of the second molars and the mandibular second bicuspid which were impacted under the first molars. The key point was to control the maxillary incisor torque during the space closure of the first molar extractions, as the naso-labial angle was very wide. The use of .020x.022 slots on the maxillary incisors with .019x.025 SS archwire was helpful for this control. The fixed appliance duration was 22 months, which was relatively short for a first molar extraction treatment. The patient was debonded at 15.11 years old and fixed retainers cuspid to cuspid were placed in conjunction with a tongue repositioning device.

-Active treatment evaluation: At the completion of the treatment (*figure 5*), the profile was still retrognathic but was improved with a better chin projection. The naso-labial angle was still open but did not get worse. This was one of the key points of the treatment as it was necessary to mesialize the first maxillary molars. No bone anchorage was placed in this case, the torque control was done only by the adequate archwires. The smile was wide, revealing the maxillary teeth and up to the second bicuspids. On the intraoral point of view, at the end of active treatment, the overjet and the overbite were normalized with a molar and canine class I, the midlines were centred, and the extraction spaces were closed.

On the panoramic X-ray the roots are parallel and the third molars are still in the bone. On the lateral X-ray, the overjet and overbite were normalized (*figure 6*).

The general superimposition shows the limited retroclination of the maxillary incisor and the control of the mandibular incisor as well as the mandibular growth initiated by the early treatment. The local maxillary superimposition reveals a clockwise rotation of the maxilla and a vertical growth. The local mandibular superimposition shows the vertical growth of the ramus and the limited change in the mandibular incisor axis change (*figure 7*).

-Post retention evaluation: 5.9 years after debonding, at the age of 21.8 years old, the facial and occlusal results are stable and on the panoramic the third molars are erupting with a satisfactory axis. The profile was still retrognathic, but the patient is very satisfied by the results and no breathing disorders are noticeable as the airways are very wide on the lateral X-ray with no reduction due to the treatment. If one day the patient was not satisfied by her profile, a double maxillary advancement would be easily feasible as the occlusion is good six years after the active treatment (*figure 8*).

Conclusion

Young patients suffering from MIH are relatively frequent and first molar extraction and space closure when the third molars are present are often a good solution for the patient, avoiding very difficult endodontic and restorative treatment on these teeth, and most of all a sustainable solution. When the MIH is accompanied by a class II division 1 malocclusion, the orthodontic mechanics must be carefully controlled for the aesthetic preservation of the profile despite of the closure of the extraction spaces, especially when the use of bone anchorage is not easy.

Disclosure of interest: The authors declare that they have no competing interest.

References

1. Booi JW, Goeke J, Bronkhorst EM, Katsaros C, Ruf S. Class II treatment by extraction of maxillary first molars or Herbst appliance: dentoskeletal and soft tissue effects in comparison. *J Orofac Orthop.* 2013;74:52-63
2. Koroluk LD, Tulloch JF, Phillips C. : « Incisor trauma and early treatment for Class II Division 1 malocclusion ». *Am J Orthod Dentofacial Orthop.* 2003;123:117-25; discussion 125-6.

3. Seehra J, Fleming PS, Newton T, DiBiase AT. Bullying in orthodontic patients and its relationship to malocclusion, self-esteem and oral health-related quality of life. *J Orthod.* 2011;38:247-56;
4. Zhao D , Dong B, Yu D, Ren Q , Sun Y. The Prevalence of Molar Incisor Hypomineralization: Evidence From 70 Studies. *Int J Paediatr Dent.*2018;28:170-9.
5. Weerheijm KL, Jälevik B, Alaluusua S. Molar-incisor hypomineralisation. *Caries Res.* 2001;35:390-1.
6. Weerheijm KL, Duggal M, Mejäre I, Papagiannoulis L, Koch G, Martens LC, Hallonsten AL. Judgement criteria for molar incisor hypomineralisation (MIH) in epidemiologic studies: a summary of the European meeting on MIH held in Athens, 2003. *Eur J Paediatr Dent.* 2003;4:110-3.
7. Americano GC, Jacobsen PE, Soviero VM, Haubek D. A systematic review on the association between molar incisorhypomineralization and dental caries. *Int J Paediatr Dent.* 2017;27:11-21.
8. Almualllem Z, Busuttil-Naudi A. Molar incisor hypomineralisation (MIH) – an overview. *Br Dent J.* 2018;225:601-9.
9. Lygidakis NA, Wong F, Jälevik B, Vierrou AM, Alaluusua S, Espelid I. Best Clinical Practice Guidance for Clinicians Dealing With Children Presenting With Molar-Incisor-Hypomineralisation (MIH): An EAPD Policy Document *Eur Arch Paediatr Dent.* 2010,11:75-81.
10. Hernandez M, Boj JR, Espasa E. Do We Really Know the Prevalence of MIH? *J Clin Pediatr Dent.* 2016;40:259-63.
11. Chawla N, Messer LB, Silva M. Clinical studies on molar-incisor-hypomineralisation part 2: development of a severity index. *Eur Arch Paediatr Dent.* 2008;9:191-9.
12. Elhennawy K, Schwendicke F. Managing molar-incisor hypomineralization: A systematic review. *J Dent.* 2016;55:16-24.
13. Silva MJ, Scurrah KJ, Craig JM, David J Manton DJ, Kilpatrick N. Etiology of Molar Incisor Hypomineralization - A Systematic Review. *Community Dent Oral Epidemiol.* 2016;44:342-53.
14. Jedeon K, Marciano C, Loiodice S, Boudalia S, Canivenc Lavier MC, Berdal A, Babajko S. Enamel hypomineralization due to endocrine disruptors. *Connect Tissue Res.* 2014 Aug;55 (Suppl 1):43-7
15. Sapir S, Shapira J. Clinical Solutions for Developmental Defects of Enamel and Dentin in Children. *Pediatr Dent.* 2007;29:330-6.
16. Ghanim A, Mariño R, Manton DJ. Validity and reproducibility testing of the Molar Incisor Hypomineralisation (MIH) Index. *Int J Paediatr Dent.* 2019;29:6-13.
17. Mittal N. Phenotypes of Enamel Hypomineralization and Molar Incisor Hypomineralization in Permanent Dentition: Identification, Quantification and Proposal for Classification. *J Clin Pediatr Dent.* 2016;40:367-74.
18. Garot E, Denis A, Delbos Y, Manton D, Silva M, Rouas P. Are hypomineralised lesions on second primary molars (HSPM) a predictive sign of molar incisor hypomineralisation (MIH)? A systematic review and a meta-analysis. *J Dent.* 2018 ;72:8-13.
19. Wright JT. Diagnosis and treatment of molar-incisor hypomineralization. *Handbook of Clinical Techniques in Pediatric Dentistry.* Jane A. Soxman (Editor). Wiley, 2015:99-106.
20. Elhennawy K, Krois J, Jost-Brinkmann PG, Schwendicke F. Outcome and Comparator Choice in Molar Incisor Hypomineralisation (MIH) Intervention Studies: A Systematic Review and Social Network Analysis. *BMJ Open.* 2019;9:e028352.

21. Fütterer J, Ebel M, Bekes K, Klode C, Hirsch C. Influence of Customized Therapy for Molar Incisor Hypomineralization on Children's Oral Hygiene and Quality of Life. *Clin Exp Dent Res.* 2020;6:33-43.
22. Cabral RN, Nyvad B, Soviero VLVM, Freitas E, Leal SC. Reliability and Validity of a New Classification of MIH Based on Severity. *Clin Oral Investig.* 2020;24:727-34.
23. Oliver K, Messer LB, Manton DJ, Kan K et al. Distribution and Severity of Molar Hypomineralisation: Trial of a New Severity Index *Int J Paediatr Dent.* 2014;24:131-51.
24. Steffen R, Krämer N, Bekes K. The Würzburg MIH concept: the MIH treatment need index (MIH TNI) : A new index to assess and plan treatment in patients with molar incisor hypomineralisation (MIH). *Eur Arch Paediatr Dent.* 2017;18:355-61.
25. Elhennawy K, Schwendicke F. Managing molar-incisor hypomineralization: A systematic review. *J Dent.* 2016;55:16-24.
26. Mathu-Muju KR, Kennedy DB. Loss of Permanent First Molars in the Mixed Dentition: Circumstances Resulting in Extraction and Requiring Orthodontic Management. *Pediatr Dent.* 2016;38:46-53.
27. Cobourne MT, Williams A, M Harrison M. National Clinical Guidelines for the Extraction of First Permanent Molars in Children. *Br Dent J.* 2014;217:643-8.

Legends of figures

Figure 1: Severity score of teeth affected by MIH from J. Timothy Wright “Diagnosis and treatment of molar–incisor hypomineralization”. *Handbook of Clinical Techniques in Pediatric Dentistry.* Chapter 12 [19].

Figure 2: Extra- and intra-oral views before treatment.

Figure 3: X-rays before treatment.




Figure 4: Extra- and intra-oral views at completion of early treatment.

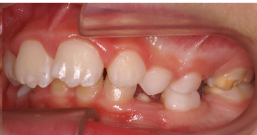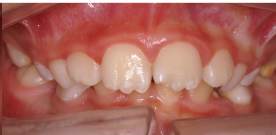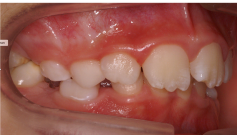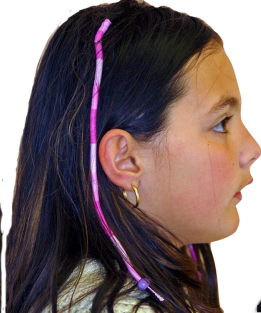Figure 5: Extra- and intra-oral views at completion of active treatment.

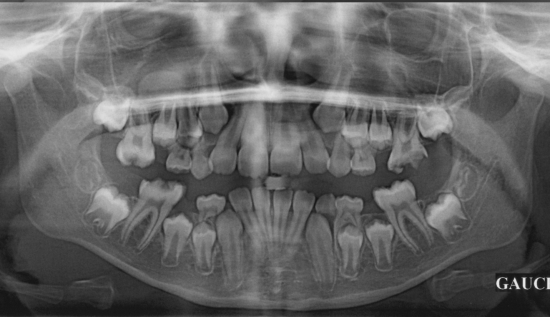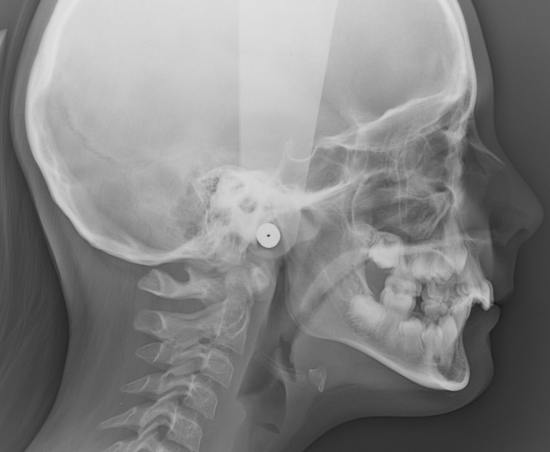Figure 6: X-rays at completion of active treatment and cephalometric measurements.

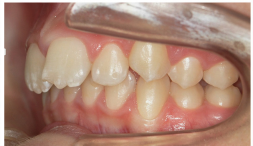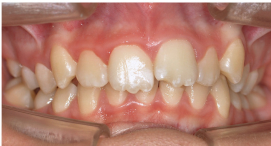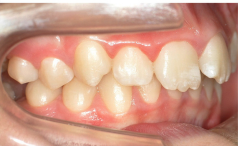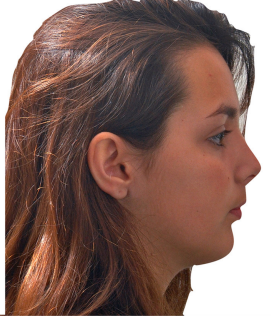Figure 7: Pre-post treatment comparison of lateral X-rays and structural superimpositions (black: before treatment, blue: at completion of early treatment, red at completion of active treatment).

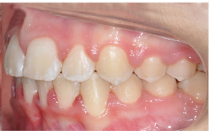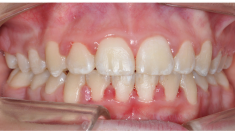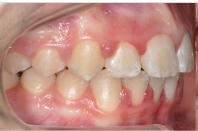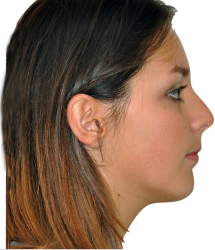Figure 8: Extra- intra-oral views and panoramic 5.9 years after the active treatment.

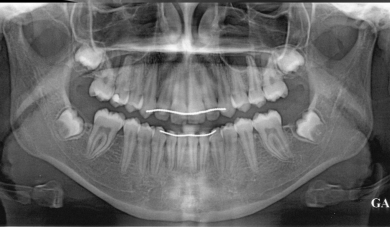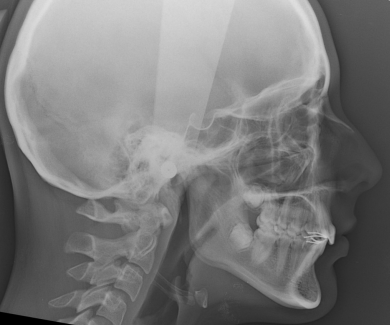	Mild MIH	Moderate MIH	Severe MIH
First Permanent Molars Clinical appearance			
Enamel loss	Isolated opacities	Occlusal/incisal without initial breakdown	Post eruptive initial breakdown
Caries	No caries	Post eruptive breakdown without cuspal involvement	Widespread caries of affected enamel
Sensitivity	Normal sensitivity	Usually normal sensitivity	History of distal sensitivity
Esthetics	Not an issue	Parents express concern	Parents typically concern











18/12/88, age: 10.3y

01/06/14, age: 15.11y

Sagittal Skeletal Relations

	Pretreatment	Early treatment	Posttreatment	Mean	SD
Maxillary Position S-N-A°	81	81.5	80	82° ± 3.5°	
Mandibular Position S-N-Pg°	77	79	77	80° ± 3.5°	
Sagittal Jaw Relation A-N-Pg°	4	2.5	3	2° ± 2.5°	

Vertical Skeletal Relations

Maxillary Inclination S-N/ANS-PNS°	8.5	8	7	8° ± 3.0°	
Mandibular Inclination S-N/Go-Gn°	33	33.5	36	33° ± 2.5°	
Vertical Jaw Relation ANS-PNS/Go-Gn°	24.5	25.5	29	25° ± 6.0°	

Dento-Basal Relations

Maxillary Incisor Inclination └ - ANS-PNS°	111.5	102	107	110° ± 6.0°	
Mandibular Incisor Inclination └ - Go-Gn°	95	94	98	94° ± 7.0°	
Mandibular Incisor Compensation └ - A-Pg (mm)	-2	-1.5	+0.5	2 ± 2.0	

Dental Relations

Overjet (mm)	+8	+5	+3	3.5 ± 2.5	
Overbite (mm)	+5	+3.5	+2.5	2 ± 2.5	
Interincisal Angle └ / └°	127	138	126	132° ± 6.0°	

