



HAL
open science

Conservative Management of Mature Permanent Teeth with Carious Pulp Exposure

Nessrin A Taha, Imad About, Christine M Sedgley, Harold H Messer

► **To cite this version:**

Nessrin A Taha, Imad About, Christine M Sedgley, Harold H Messer. Conservative Management of Mature Permanent Teeth with Carious Pulp Exposure. *Journal of Endodontics*, 2020, 46 (9), pp.S33-S41. 10.1016/j.joen.2020.06.025 . hal-03191476

HAL Id: hal-03191476

<https://hal.science/hal-03191476v1>

Submitted on 7 Apr 2021

HAL is a multi-disciplinary open access archive for the deposit and dissemination of scientific research documents, whether they are published or not. The documents may come from teaching and research institutions in France or abroad, or from public or private research centers.

L'archive ouverte pluridisciplinaire **HAL**, est destinée au dépôt et à la diffusion de documents scientifiques de niveau recherche, publiés ou non, émanant des établissements d'enseignement et de recherche français ou étrangers, des laboratoires publics ou privés.

Conservative Management of Mature Permanent Teeth with Carious Pulp Exposure

Nessrin A Taha*, Imad About, Christine M Sedgley, Harold H Messer

NA Taha, Department of Conservative Dentistry. Jordan University of Science and Technology. Irbid, Jordan

I About, Aix Marseille University, CNRS, ISM, Inst Movement Sci, Marseille, France.

CM Sedgley, School of Dentistry, Oregon Health & Science University, Portland, Oregon, USA

HH Messer, Melbourne Dental School, University of Melbourne, Melbourne, Australia

***Corresponding author**

NA Taha, BDS, MFDS RCSI, GradDipCliDent, DClinDent (Endo), FRACDS(Endo)

Professor, Department of Conservative Dentistry. Jordan University of Science and Technology.

P.O Box 3864, Irbid 21110, Jordan

Email: n.taha@just.edu.jo

Tel: +962 776566110

Acknowledgements

The authors declare no potential conflicts of interest related to the authorship or publication of this article.

Clinical significance: Conservative management of mature permanent teeth with carious pulp exposure is possible by virtue of the improved understanding of pulp biology, histopathology and the introduction of biologically active hydraulic calcium silicate based materials.

Abstract

Vital pulp therapy (VPT) in mature permanent teeth with carious pulp exposure has been a matter of debate, with root canal therapy being the conventional standard of care. Previously reported negative outcomes for VPT in these teeth were based on data from studies that have used calcium hydroxide in direct pulp capping, partial and full pulpotomy. The introduction of hydraulic calcium silicate based materials with sealing and bioactive potentials have opened a new era in VPT with more favorable results. Understanding the histopathology and histobacteriology of the cariously exposed pulp and the healing potential of the inflamed pulp could guide the decision making process toward an ultraconservative management of these teeth. However, proper case selection, strict aseptic condition, capping material and good coronal seal are crucial for long term success.

Key words

Caries, Mature teeth, Pulpitis, Vital Pulp Therapy, Pulp Biology

Introduction

Epidemiological studies consistently show a high global prevalence of dental caries, particularly in adults (1). A prerequisite for any intervention intended to preserve the pulp is the presence of either healthy pulp tissue or pulpal damage that can be reversed. Inflammation of the pulp accompanies the carious process well before carious pulp exposure; however the severity of the inflammation increases as the caries progresses toward the pulp. Nonetheless, even in the presence of carious pulp exposure, inflammation is typically limited to within 2 mm of the exposure site unless the carious exposure is of long standing, and it is not uncommon to find healthy pulpal architecture in the opposing pulp horn or further away in the pulp chamber (2,3).

Historically, the use of vital pulp therapy (VPT) for mature permanent teeth with carious pulp exposure has been discouraged, with the majority recommending pulpectomy and root canal therapy (4). The consensus that the pulp should be regarded as irreversibly inflamed whenever a carious exposure occurs in mature permanent teeth has been based on clinical outcomes of direct pulp capping with calcium hydroxide (CH). The biological rationale for this conclusion is that underlying pulpal inflammation has spread throughout the pulp and that the blood supply through a mature apex is insufficient to promote healing even after the insult is removed.

Significant improvement has occurred in the understanding of pulp biology and the response of the pulp to the carious process; the release of dentin-bound growth factors and active molecules such as SCF, IGFBP, NGF, GDNF and TGF- β 1 has highlighted the fact that the pulp in mature teeth has greater regenerative potential than what was previously thought (5,6). Placement of bioactive materials, specifically tricalcium silicate-based materials (Mineral Trioxide Aggregate (MTA), Biodentine, Bioceramics) has been shown to induce the release of these growth factors

and to stimulate differentiation of odontoblast-like cells that modulate the inflammatory process and induce repair. The clinical use of these bioactive materials which provide a good marginal sealing has the potential to transform the management of carious exposures in mature teeth. The role of fibroblasts, which are abundant in the pulp tissue of adults, in modulation of repair and dentinogenesis has been recently highlighted (7). Recent data have demonstrated that the pulp fibroblasts have an amazing anti-inflammatory potential through complement system activation (8). Indeed, fibroblasts can directly kill cariogenic bacteria infiltrating the pulp by forming a membrane attach complex on their surface that induces their lysis (9). Fibroblasts also produce other complement proteins such as C5a which recruits macrophages and C3b which binds to pathogen surface and stimulate their phagocytosis by the recruited macrophages (10).

In this paper we aim to review the pulp status beneath carious exposures and clinical management of mature teeth with carious pulp exposures from case selection to materials, clinical procures and outcomes.

1. Pulpal status beneath carious exposures and the classification of pulpitis

In carious teeth, the permeability of dentin is reduced by the presence of tubular sclerosis beneath the caries front. As the intensity of the bacterial insult increases, the inflammatory response intensifies and the odontoblasts underlying the carious lesion are likely to die. Dental pulp possesses the innate ability to heal if the insult is removed (11); odontoblast-like cells replace lost odontoblasts and form reparative dentin. The origin of these cells has been under debate; mesenchymal cells have been implicated in their derivation (12). Regardless of their origin these odontoblast-like cells secrete a matrix that is highly similar to that of primary dentin in terms of

molecular composition and structure (13). If the carious insult is not removed, pulpal inflammation will progress and ultimately affect the entire pulp, resulting in pulp necrosis and apical periodontitis. The point at which the pulpal inflammation becomes irreversible even with removal of the stimulus has been debated for more than 50 years (2), and is essentially impossible to determine by currently available diagnostic tests such as thermal and electrical stimulation.

The terms reversible and irreversible pulpitis have long been used as part of the endodontic diagnostic scheme to guide the clinical decision-making process (14). However, the validity of these terms has been questioned previously by Dummer et al. (15), who showed poor correlation between clinical symptoms and the actual histological status of the pulp and subsequently the healing potential of the inflamed pulp tissue. There is no clear cut off point between what is actually reversible and what is not reversible based on pulp tests and symptoms only.

The use of diagnostic terminology that is based on the predicted outcome of treatment rather than the actual pulp status before intervention is unusual: “reversible” or “irreversible” inflammation can be decided only after the carious insult is actually removed and the lesion is appropriately restored. Of course, once the pulp is extirpated the pulpal diagnosis is no longer relevant. If a conservative approach is chosen, then the outcome - and hence the classification of “reversible” or “irreversible” pulpitis - will largely depend on the nature of the procedure (direct pulp capping or pulpotomy) and the material used. Direct pulp capping with CH will most likely result in progressive pulpitis and ultimately pulp necrosis; this has served as the basis for the historic classification of irreversible pulpitis. Inadequate microbial control and persistent microleakage may also have contributed to the poor outcomes with CH. On the other hand, pulpotomy in association with a bioactive material such as a tricalcium silicate cement is much more likely to lead to resolution of pulpal inflammation and preservation of pulp vitality, which would lead to a

retrospective diagnosis of reversible pulpitis. In fact, numerous clinical studies have now been published on VPT with the newer materials, including pulp capping (16, 17), partial pulpotomy (18) and full pulpotomy (19-22) with high success rates. These studies, which will be considered in more details later, demonstrate the need for revision of the currently used diagnostic scheme. In our judgement, classification of inflammation of the pulp should be confined to “pulpitis” without any further designation.

2. Managing the cariously exposed pulp

Vital pulp therapy has long been an accepted procedure for primary teeth and young permanent teeth, typically pulpotomy involving the removal of part or all of the coronal pulp. The concept of VPT for mature teeth is also long established, with almost a century of history behind its beginning when gold foil was used to cap exposed pulps (23). Calcium hydroxide became the material of choice after its introduction in the 1930s, typically as a direct pulp capping over the carious exposure without removal of underlying pulp tissue (24, 25). The poor long term prognosis, perhaps resulting in large part from inadequate microbial control during the procedure and poor subsequent marginal seal, led to recommendations against its use for mature permanent teeth (16, 26).

The view that a carious exposure in mature teeth was associated with irreversible pulpitis and hence the routine need for pulpectomy was the natural consequence of this observation. Following the emergence of MTA as a root-end filling material (27), its proposed use in VPT was advocated (28), although it took 10 years for the first clinical reports of its effectiveness to emerge (29, 30).

Numerous clinical studies with excellent outcomes have led to the need for a reconsideration of definitions of pulpitis (as discussed above), as well as the development of clinical protocols for case selection and management.

Despite the fact that root canal therapy performed for teeth with vital pulps has a high success rate when performed to adequate technical standard and under aseptic conditions (31), cross sectional studies have documented the inadequate technical quality for root canal treatment to range between 30-60% across the world (32, 33). The technically less challenging procedures associated with VPT make its adoption an attractive alternative to root canal treatment. In the following section we will summarize briefly some of the key steps in clinical management of the vital pulp derived from clinical studies using newer materials.

A. Case selection:

Age: While most studies of VPT have been restricted to younger age groups, age does not appear to be a significant factor in outcomes of VPT (34- 36). *Preoperative signs and symptoms* might be expected to serve as a guideline in the choice of VPT vs pulpectomy, despite the acknowledged limitations of both pain history and pulp sensibility tests (37). However, even some of the earliest studies of MTA (30) involved teeth diagnosed with painful “irreversible pulpitis” (by traditional criteria), yet resulted in predictable healing. Numerous clinical studies have since shown that painful pulpitis is not a contraindication to VPT. Ultimately an untreated carious exposure will lead to the progressive spread of pulpal inflammation and necrosis, but signs and symptoms do not necessarily reflect this progression.

Pulp sensibility testing: cold testing is the most valid test for identifying necrotic pulps (38) and therefore continues to be essential before any attempt of operative work on teeth with deep carious lesions or lesions exposing the pulps.

Radiographic assessment: periapical radiography is essential for assessment of caries depth as well as periapical health. Although presence of periapical lesion in an inflamed vital pulp is not a contraindication for VPT, and several studies reported successful outcomes of pulpotomy in teeth with periapical lesions (21, 22)

Intraoperatively, after caries excavation, direct observation of the pulp wound under magnification is recommended, the ideal characteristics of a healthy pulp wound include a continuous blood-filled tissue surrounded by clean sound dentin. While if there is necrotic tissue, dentin debris or yellow areas within the pulp, then more tissue should be removed as in partial pulpotomy, and reassessed again for the need of full pulpotomy until reaching a healthy architecture (39).

The intensity of bleeding after pulp exposure has been suggested as an indicator for the severity of pulp inflammation (30,34); profuse bleeding implies severe inflammation and indicates the needs for further pulp tissue removal hoping to reach uninfamed tissue and achieve hemostasis.

B. Microbial control

Whenever a carious exposure is suspected from the preoperative radiograph, complete caries excavation should be attempted under rubber dam isolation followed by disinfection of the crown before caries excavation (40); most recent studies have included these precautions routinely. When the pulp is exposed, flushing the cavity with a disinfectant such as 1% NaOCl or chlorhexidine is encouraged to minimize bacterial load and prevent embedment of dentin debris into the pulp tissue which may interfere with subsequent healing. Hemostasis after the pulpotomy

procedure is often obtained using low concentrations of NaOCl (1-3%) on a cotton pellet (16, 17, 21, 41, 42). The difference in outcomes using NaOCl vs sterile saline has not been thoroughly investigated, only one randomized clinical trial in primary teeth reported improved outcomes of direct pulp capping after NaOCl hemostasis compared to saline (43). Following VPT, the restoration must provide an enduring seal against microleakage.

C. Extent of pulp tissue removal

Histologically in teeth with reversible pulpitis bacteria are confined to the deepest dentin, while teeth with irreversible pulpitis have a necrotic area of varying dimensions, colonized by bacteria in the pulp chamber, and contrary to what was believed in the past there is good correlation between clinical and histologic diagnosis (3). However, it is not possible to clinically diagnose the extent of pulp degeneration based on clinical symptoms. Taking this in consideration will affect the decision on how much tissue should be removed.

The prognosis of VPT is dependent on the stage of pulp inflammation and the ability to minimize the insult and remove the inflamed tissue. Direct pulp capping in teeth of young subjects, without removal of pulp tissue, has an excellent short-term prognosis (44); an inherent disadvantage of direct pulp capping is that inflamed pulp tissue remains beneath the capping material. Even partial removal of the injurious challenge can have a marked effect on clinical outcome; direct pulp capping and partial pulpotomy (Figure 1) in adult teeth with carious pulp exposure have a success rate of 80-85% over 2-3 years follow up, in both scenarios of symptoms of reversible or irreversible pulpitis (as conventionally defined) (16, 18, 42, 45). While when full pulpotomy is performed the success rate goes up to 90-98% (30, 21, 22, 46). A full pulpotomy to the canal orifices is technically less challenging than partial pulpotomy and may provide better restorative options (Figure 2).

D. Hemostasis as an indicator of pulpal inflammation

The association between the bleeding time and the degree of pulp inflammation has never been thoroughly investigated. Clinical studies with high success rates reported bleeding time between 1-10 minutes, with no significant association between bleeding time and outcome of VPT (22,47). In 84% of teeth with clinical signs and symptoms suggestive of irreversible pulpitis vital pulp tissue was present clinically and hemostasis could be achieved within 6 minutes after partial or full pulpotomy (18,22). The degree of bleeding on pulp exposure is not sufficient as a clinical index of the prognosis of treatment of pulp capping because of its low specificity by virtue that 55% of the cases with conspicuous bleeding were successful (34). Nonetheless, persistent bleeding despite attempts at hemostasis is considered a contraindication to VPT and pulpectomy is recommended (22,40).

E. Materials for direct contact with the pulp

The ideal material for VPT should be able to resist long term bacterial leakage and stimulate the remaining pulp tissue to return to a healthy state and promote dentin formation (48). Calcium hydroxide was the historic gold standard material for pulp capping, however studies have shown the results to be variable and unpredictable with success rates declining over time (26). Its use can no longer be recommended. Hydraulic calcium silicate-based materials (or tricalcium silicate cements) have shown superiority in outcome compared to CH; examples include MTA (Figure 1) and non-staining fast set (12 min) Biodentine™ (Septodont, Sant-Maur-des-Ditch Cedex, France) (Figure 2).

Biological properties of tricalcium silicate materials have been reported in several studies. They induce mineralization, cellular differentiation, and the release of dentin matrix components (DMCs) that upregulate angiogenesis and the differentiation of dentinogenic cells (6,49, 50). On the other hand, resin-based composites or calcium silicate-based materials containing resin have shown negative effects on the dental pulp (51,52).

F. Outcome measures for successful VPT

Teeth that received VPT should be followed up both clinically and radiographically. Clinically the tooth should be asymptomatic, no tenderness to palpation or percussion, no swelling or sinus tract and it should be responsive to sensibility testing if it has received pulp capping or partial pulpotomy. However, in teeth with full pulpotomy no response to sensibility testing is expected, and in the absence of clinical and radiographic signs of failure we can assume that the radicular pulp is normal and the treatment is successful. Radiographically there should be no signs of internal root resorption, no new periapical pathosis and healing of periapical pathosis if it was present preoperatively (21,35,40).

3: Clinical studies

Pitt Ford et al (28) first proposed the use of MTA for VPT, and its adoption for pulpotomy of primary teeth occurred rapidly (53). It took 10 years for the first case series in carious permanent teeth to be reported, involving both pulp capping (29) and pulpotomy (30), in both young and adult patients. Since those reports, clinical studies using several different materials (but all based on similar chemistry described above) have investigated outcomes over a broader age range and clinical parameters (Table 1, 2, 3).

Outcome in relation to preoperative signs and symptoms

Based on reports from several clinical studies it has been proposed that root canal therapy is not a necessity after carious pulp exposure in teeth with signs and symptoms indicative of irreversible pulpitis (37). The outcome of pulpotomy in adult teeth with symptoms of irreversible pulpitis was favorable using CH (54), calcium enriched mixture (CEM) (20), MTA (19,21, 30, 47) and Biodentine (22) with success rates similar to those reported for conventional root canal therapy. Asgary et al (36) conducted a randomized clinical trial of pulpotomy using CEM for teeth clinically diagnosed with irreversible pulpitis compared to root canal therapy over 5 years follow up. The operators were general dentists and comparable success rates were reported for the two procedures.

A recent systematic review (of 8 included studies) on pulpotomy of mature carious teeth with symptoms indicative of irreversible pulpitis reported very high success rates; 97% clinical and 95% radiographic success rate at 1 year follow up and 94% clinical and 88% radiographic success at 3 years follow up (46). The lower success rate at 3 years follow up was associated with studies that used CEM while studies that used MTA maintained a high success rate after 3 years. In general, the outcome reported in systematic reviews of pulpotomy in teeth with signs and symptoms indicative of irreversible pulpitis (46, 55) is comparable to the outcome reported in a systematic review for teeth with reversible pulpitis and closed apices (56).

Outcome in relation to extent of pulp tissue removal

Among adults, direct pulp capping with CH yielded a low success rate of 35% after 1 year (57). A randomized clinical trial has shown that MTA is more effective than CH in capping carious pulp exposures in adult patients (85% vs 52%) over 3 years follow up (16) which corresponds with the

findings of a meta-analysis of direct pulp capping and pulpotomy using CH or MTA (55,58). Pulp underlying a carious exposure will have a definite zone of inflammation beneath the exposure. Therefore, removal of affected pulp tissue is advised rather than simply placing material directly over the exposure, by partial or full pulpotomy.

A recent systematic review and meta-analysis considered partial pulpotomy as a conservative treatment option for teeth with carious pulp exposure, with high success rate over 2 years follow-up, as long as the symptoms are indicative of reversible pulpitis (45); their results were comparable to the success rate reported for full pulpotomy in teeth with a preoperative diagnosis of reversible pulpitis (56). The recommendation was to select partial pulpotomy since it is more conservative than full pulpotomy and sensibility testing can still be performed at follow-up visits. Ten out of 11 studies included in this review included young patients; only one study was limited to adults (18).

One randomized clinical trial reported the outcome of partial pulpotomy in teeth with symptoms indicative of irreversible pulpitis, the success rate was 85% over 2 years follow-up using MTA (18), which appears to be lower than that reported for full pulpotomy in similar situations (46).

Using a proprietary tricalcium silicate-based material, Asgary et al (17) reported on the outcome of VPT procedures including, indirect pulp capping, direct pulp capping, partial and full pulpotomy in mature teeth with variable clinical symptoms. All 4 VPTs were associated with favorable/comparable clinical and radiographic outcomes and the pulpal and periapical status had no effect on treatment outcomes. Considering the different pulp status of cases included in this study (normal, reversible, irreversible pulpitis); and hence their different histologic and microbiologic baseline condition the results of this study might be taken with caution.

Length of follow up

Two years follow-up has been considered adequate for direct pulp capping using CH and MTA (4, 34) and for pulpotomy using MTA (35), as failures tended to occur within this time frame. This period is probably not true for CH, since Barthel et al. (26) documented the progressive decline over longer intervals in the outcome of CH direct pulp capping. Longer-term studies of 5-10 years would be helpful to confirm the recommendation of 2 years as sufficient follow-up. While early failures reflect inaccurate assessment of the inflammatory status of the pulp, late failures usually reflect reinfection of the pulp space via a leaky restoration (59).

4: Is VPT a viable and even preferred alternative to pulpectomy for carious exposure in mature teeth?

There is a great benefit in considering VPT outcome and regenerative endodontics with respect to the goals of patients, clinicians and scientists (60). In terms of patient-related outcome, the prompt reduction in pain levels after pulpotomy, for example, reaches 95% which is well received by the patient (41,61), the tooth is functional and daily activities and quality of life are undisturbed.

Recommending minimally invasive dentistry reduces overtreatment and the restorative cycle by preserving tooth structure, while being cost effective. A cost effectiveness analysis has shown direct pulp capping to be superior to root canal treatment provided the cavity is class I and the patient is a young adult (62). Considering the advantages of VPT in maintaining proprioception, hydration of tooth structure, lower cost and less time consuming procedure, VPT can be a preferred alternative to root canal therapy in vital inflamed teeth. The high prevalence of a poor technical standard of root canal filling has been well documented, and VPT procedures may permit a higher

standard for general practitioners. This has not been demonstrated in any clinical study as yet. On the other hand, restorative options may be more restricted following VPT than with RCT, because the pulp chamber and canal space are not available for retention.

The high success rate reported for VPT procedures using calcium silicate based materials (MTA, Biodentine, CEM) in mature permanent teeth with carious pulp exposure over medium to long term follow-up provides an evidence based background for the adoption of VPT in these cases. The use of appropriate material and technique may allow the pulp to heal in adults at least as evident radiographically and clinically.

5: Future research needs

A diagnostic scheme should contain only categories that can be differentiated by signs and symptoms plus diagnostic tests; otherwise there would be no clinical value for such a scheme or multiple sub-categorizations. Current pulp testing is not reliable, to the extent that determining pulpal status has been described as “at best an educated guess”, and an urgent need exists for more definitive tests. The chairside application of rapid molecular tests that target the level of biomarkers of pulpal inflammation has been suggested as a potential tool of diagnosis of the pulp condition; however an accurate inflammatory threshold has to be established since many of the markers that reflect matrix degradation are actually required for repair as well (40,63). Efforts should be directed to introduce a new way for diagnosing pulpitis and relate this diagnosis to minimally invasive treatment choices of VPT based on the degree of pulp inflammation.

The limits of VPT also need to be addressed more fully, in relation to patient age, previous caries and restorative history, depth of carious lesion, time to achieve hemostasis, pain scores and severity of symptoms before treatment, and type of definitive restoration after VPT in long term clinical

trials. Given the past history of direct pulp capping with CH and the progressive failure of this treatment over a prolonged period (26), follow-up studies should be conducted over at least 5 years if possible.

The best studies on VPT are based on 1-arm prospective studies which may carry a high risk of bias (46), randomized clinical trials on VPT for cariously exposed pulps using CH are currently not feasible because of poor outcomes (16, 18,42). The only possible design is to compare different calcium silicate materials or comparative clinical trials for VPT and root canal therapy to further support the adoption of VPT, particularly in mature teeth with clinical symptoms suggestive of irreversible pulpitis.

Partial and full pulpotomy are associated with different levels of pulp preservation. In the literature there is no consistency with regard to the indications of each procedure; both procedures have been performed interchangeably without consideration of the pathological status of the remaining tissue (17). Further studies comparing these procedures in teeth with similar preoperative clinical diagnosis and possibly utilizing direct clinical observation of the exposed pulp are needed.

Materials: While the newer materials based on hydraulic silicate cements (tricalcium silicates) have resulted in excellent results to date, the possibility of incorporating bioactive agents into cements may further enhance healing. Examples of these bioactive agents may include previously extracted dentin matrix (64), or pharmaceuticals that modulate stem cell differentiation and the rate of dentinogenesis by modulating the p38 Map kinase and the Histone deacetylase (64). It will be difficult to demonstrate that such bioactive molecules would lead to improved outcomes over already available cements that are highly successful.

6. Conclusions

- Maintenance of pulp vitality by the adoption of minimally invasive procedures is highly encouraged in adult teeth with carious pulp exposure.
- Parallel with the need for an update of the diagnostic terminology of the state of the pulp there is an urgent need for more representative pulpal diagnostic methods.

Table 1: Treatment outcome of full pulpotomy in teeth with carious pulp exposure.

*Retrospective study, ** Randomized clinical trial

Author	Age	Sample size	Root maturity	Diagnosis	Material
Caliskan 1993 (69)	10-22	24	Mature	Hyperplastic pulpitis	CH
Caliskan 1995 (54)	10-24	26	Mature	Irreversible pulpitis	CH
Asgary et al. 2013 (20)**	27±8 26±9	167 179	Mature	Irreversible pulpitis	CEM MTA
Simon et al. 2013 (35)	7-54 Mean 37 Median 42	17	Mature	Reversible pulpitis	MTA
Asgary et al. 2015 (36)**	9-65	107 101	Mature	Irreversible pulpitis	CEM RCT
Galani et al. 2017 (41)**	15-36 16-38	54	Mature	Not specified	MTA RCT
Taha et al. 2017 (21)	11-51	52	Mature	Reversible & Irreversible pulpitis	MTA
Linswanont et al 2017* (47)	7-68	66	Mature	Reversible & Irreversible pulpitis	MTA
Asgary et al. 2018 (17)	26.5±7.4	69	Mature	Reversible & Irreversible pulpitis	CEM
Taha & Abdulkhader 2018 (22)	19-69	64	Mature	Irreversible pulpitis	Biodentin
Taha & Abdulkhader 2018 (70)	9-17	20	Mature Immature	Irreversible pulpitis	Biodentin

Table 2: Treatment outcome of partial pulpotomy in permanent teeth with carious pulp exposure

Authors	Age	Sample size	Root maturity	Diagnosis	Material	Follow up	Success
Mass & Zilberman 1993 (65)	7.5-25	35	Mature Immature	Reversible Pulpitis	CH	12 - >48 m	91.4%
Mass & Zilberman 2011 (66)	7-18	49	Mature Immature	Reversible Pulpitis	CH	12-154 m	93.9%
Kang et al 2017 (67)	29± 14.8	83	Mature	Reversible Pulpitis	MTA	1-12 m	96%
Taha & Khazali** 2017 (18)	20-52	46	Mature	Irreversible Pulpitis	MTA CH	2 y	85% 43%
Asgary et al. 2018 (17)	26.8 ±7.6	76	Mature	Irreversible Pulpitis	CEM	1 y	91.4%
Uesrichai et al 2019 (68) **	6-17	67	Mature 27 Immature 40	Irreversible Pulpitis	MTA Biodentine	32.2 ±17.9	92% 87%

** Randomized clinical trial

Table 3: Treatment outcome of direct pulp capping in teeth with carious pulp exposure.

Authors	Age	Sample size	Diagnosis	Root maturity	Type of material	Follow up	Success
Barthel et al 2000* (26)	10-70	123	Reversible	-	CH	5y 10y	37% 13%
Matsu et al 2006 (34)	20-69	44	Reversible Irreversible	Mature	CH	3m- 51m	83%
Bogen et al 2008 (29)	7-45	53	Reversible pulpitis	Mature Immature (15)	MTA	9y	95%
Asgary et al 2018 (17)	28±10	73	Irreversible pulpitis	Mature	CEM	1y	94.7%
Kundzina et al 2016 (16)**	18-55	70	Reversible pulpitis	Mature	MTA CH	3y	85% 52%
Suhag et al 2019 (42)	15-40	64 7<18	Reversible pulpitis	Mature	MTA CH	1y	93% 69%
Miles et al 2010* (71)	≥ 18	51	Reversible Irreversible	Mature	MTA	2Y	56%
Linu et al 2017* (72)	15-30	26	Reversible pulpitis	Mature	MTA Biodentine	18m	84.6% 92.3%
Caliskan 2016* (4)	14-55	152	Asymptomatic	Mature	MTA CH	24-72m	85.9% 77.6%

*Retrospective studies, ** randomized clinical trial

Figure legends

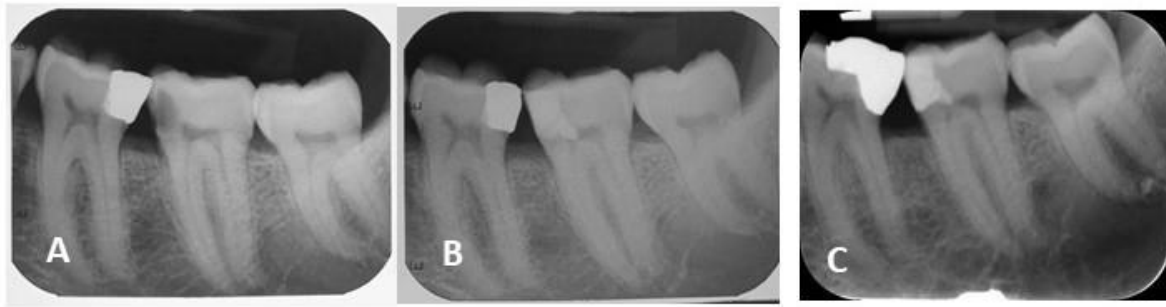

Figure 1: Radiographs of 48-year old male patient with signs and symptoms clinically suggestive of irreversible pulpitis and normal periapex in tooth 37 A: Preoperative radiograph, B: Immediate postoperative radiograph after partial pulpotomy using ProRoot MTA, C:5-year recall showing normal periapex.

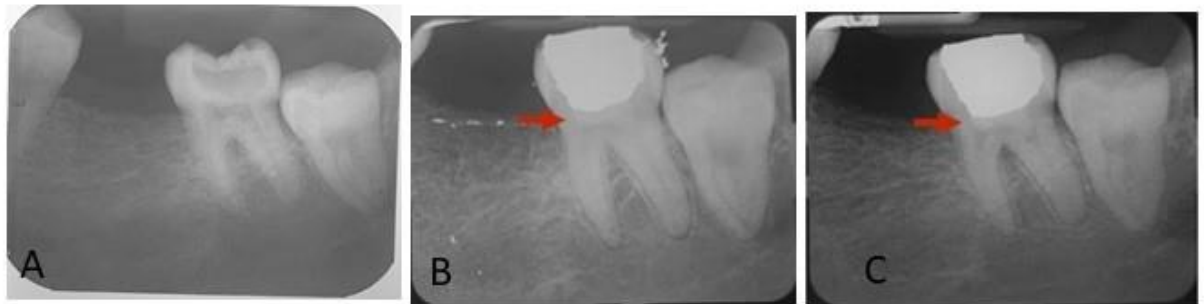


Figure 2: Radiographs of 25-year old female patient with signs and symptoms clinically suggestive of irreversible pulpitis and normal periapex in tooth 48. A: Preoperative radiograph, B: Immediate postoperative radiograph after full pulpotomy using Biodentine, C:3-year recall showing normal periapex.

References

1. Kassebaum NJ, Bernabé E, Dahiya M, et al. Global burden of untreated caries: a systematic review and metaregression. *J Dent Res* 2015;94:650-8.
2. Seltzer S, Bender IB, Ziontz M. The dynamics of pulp inflammation: correlations between diagnostic data and actual histologic findings in the pulp. *Oral Surg Oral Med Oral Pathol* 1963; 16: 846-71.
3. Ricucci D, Loghin S, Siqueira F. Correlation between clinical and histologic pulp diagnosis. *J Endod* 2014; 40: 1932-9.
4. Çalışkan MK, Güneri P. Prognostic factors in direct pulp capping with mineral trioxide aggregate or calcium hydroxide: 2- to 6-year follow-up. *Clin Oral Investig* 2017; 21:357-67.
5. Smith AJ, Duncan HF, Diogenes A, et al. Exploiting the Bioactive Properties of the Dentin-Pulp Complex in Regenerative Endodontics. *J Endod* 2016; 42:47-56.
6. Tomson PL, Lumley PJ, Smith AJ, et al. Growth factor release from dentine matrix by pulp-capping agents promotes pulp tissue repair-associated events. *Int Endod J* 2017 ; 50:281-92.
7. Jeanneau C, Lundy FT, El Karim IA, et al. Potential Therapeutic Strategy of Targeting Pulp Fibroblasts in Dentin-Pulp Regeneration. *J Endod.* 2017;43: S17-S24.
8. Chmilewsky F, Jeanneau C, Laurent P, et al. Pulp fibroblasts synthesize functional complement proteins involved in initiating dentin-pulp regeneration. *Am J Pathol* 2014; 184:1991–2000.
9. Jeanneau C, Rufas P, Rombouts C, et al. Can Pulp Fibroblasts Kill Cariogenic Bacteria? Role of Complement Activation. *J Dent Res.* 2015; 94:1765–72.
10. Le Fournis C, Hadjichristou C, Jeanneau C, et al. Human Pulp Fibroblast Implication in Phagocytosis via Complement Activation. *J Endod* 2019; 45:584–90.
11. Mjör IA, Tronstad L. The healing of experimentally induced pulpitis. *Oral Surg Oral Med Oral Pathol* 1974;38:115-21.
12. Dimitrova-Nakov S, Baudry A, Harichane Y, et al. Pulp stem cells: implication in reparative dentin formation. *J Endod.* 2014;40, S13-8.

13. Volponi AA, Gentleman E, Fatscher R, et al. Composition of Mineral Produced by Dental Mesenchymal Stem Cells. *J Dent Res* 2015; 94:1568-74.
14. Levin LG, Law AS, Holland GR, et al. Identify and define all diagnostic terms for pulpal health and disease states. *J Endod* 2009; 35:1645-57
15. Dummer PMH, Hicks R, Huws D. Clinical signs and symptoms in pulp disease. *Int Endod J* 1980; 13: 27-35
16. Kundzina R, Stangvaltaite L, Eriksen HM, et al. Capping carious exposures in adults: a randomized controlled trial investigating mineral trioxide aggregate versus calcium hydroxide. *Int Endod J* 2017; 50:924-32.
17. Asgary S, Hassanizadeh R, Torabzadeh H, et al. Treatment Outcomes of 4 Vital Pulp Therapies in Mature Molars. *J Endod* 2018; 44:529-35
18. Taha NA, Khazali MA. Partial Pulpotomy in Mature Permanent Teeth with Clinical Signs Indicative of Irreversible Pulpitis: A Randomized Clinical Trial. *J Endod* 2017;43: 1417-21.
19. Eghbal MJ, Asgary S, Baglue RA, et al. MTA pulpotomy of human permanent molars with irreversible pulpitis. *Aust Endod J* 2009; 35:4-8.
20. Asgary S, Eghbal MJ. Treatment outcomes of pulpotomy in permanent molars with irreversible pulpitis using biomaterials: a multi-center randomized controlled trial. *Acta Odontol Scand.* 2013;71:130-6.
21. Taha NA, Ahmad MB, Ghanim A. Assessment of Mineral Trioxide Aggregate pulpotomy in mature permanent teeth with carious exposures. *Int Endod J* 2017;50:117-25.
22. Taha NA, Abdelkader SZ. Outcome of full pulpotomy using Biodentine in adult patients with symptoms indicative of irreversible pulpitis. *Int Endod J* 2018;51:819-28.
23. Dammaschke, T. The history of direct pulp capping. *Journal of the History of Dentistry* 2008; 56, 9-23
24. Nyborg H. Healing processes in the pulp on capping; a morphologic study; experiments on surgical lesions of the pulp in dog and man. *Acta Odontol Scand* 1955; 13:1-130.
25. Haskell EW, Stanley HR, Chellemi J, et al. Direct pulp capping treatment: a long-term follow-up. *J Am Dent Assoc* 1978; 97:607-12.

26. Barthel CR, Rosenkranz B, Leuenberg A, et al. Pulp capping of carious exposures: treatment outcome after 5 and 10 years: a retrospective study. *J Endod* 2000; 26: 525-8
27. Torabinejad M, Hong CU, McDonald F, et al. Physical and chemical properties of a new root-end filling material. *J Endod*. 1995; 21:349-53.
28. Pitt Ford TR, Torabinejad M, Abedi HR, et al. Using mineral trioxide aggregate as a pulp-capping material. *J Am Dent Assoc* 1996;127; 1491-4.
29. Bogen G, Kim JS, Bakland LK. Direct pulp capping with mineral trioxide aggregate: an observational study. *J Am Dent Assoc* 2008; 139:305-15.
30. Witherspoon DE, Small JC, Harris GZ. Mineral trioxide aggregate pulpotomies: a case series outcomes assessment. *J Am Dent Assoc*. 2006; 137:610-8.
31. Sjogren U, Hagglund B, Sundqvist G, Wing K. Factors affecting the long-term results of endodontic treatment. *J Endod* 1990;16:498-504.
32. Dugas NN, Lawrence HP, Teplitsky PE, et al. Periapical health and treatment quality assessment of root-filled teeth in two Canadian populations. *Int Endod J* 2003; 36:181-92.
33. Di Filippo G, Sidhu SK, Chong BS. Apical periodontitis and the technical quality of root canal treatment in an adult sub-population in London. *Br Dent J* 2014;216, E22
34. Matsuo T, Nakanishi T, Shimizu H, et al. A clinical study of direct pulp capping applied to carious-exposed pulps. *J Endod* 1996; 22, 551-6
35. Simon S, Perard M, Zanini M et al. Should pulp chamber pulpotomy be seen as a permanent treatment? Some preliminary thoughts. *Int Endod J* 2013; 46: 79-87
36. Asgary S, Eghbal MJ, Fazlyab M, et al. Five-year results of vital pulp therapy in permanent molars with irreversible pulpitis: a non-inferiority multicenter randomized clinical trial. *Clin Oral Investig* 2015; 19:335-41.
37. Wolters WJ, Duncan HF, Tomson PL, et al. Minimally invasive endodontics: a new diagnostic system for assessing pulpitis and subsequent treatment needs. *In Endo J* 2017; 50, 825-9
38. Pigg M, Nixdorf DR, Nguyen RH, et al. Validity of Preoperative Clinical Findings to Identify Dental Pulp Status: A National Dental Practice-Based Research Network Study. *J Endod*. 2016; 42:935-42.

39. Ricucci D, Siqueira JF Jr, Li Y, et al. Vital pulp therapy: histopathology and histobacteriology-based guidelines to treat teeth with deep caries and pulp exposure. *J Dent.* 2019;86:41-52.
40. Duncan HF, Galler KM, Tomson PL, et al. European Society of Endodontology position statement: Management of deep caries and the exposed pulp. *Int Endod J* 2019; 52:923-34.
41. Galani M, Tewari S, Sangwan P, et al. Comparative Evaluation of Postoperative Pain and Success Rate after Pulpotomy and Root Canal Treatment in Cariously Exposed Mature Permanent Molars: A Randomized Controlled Trial. *J Endod* 2017; 43:1953-62.
42. Suhag K, Duhan J, Tewari S, et al. Success of Direct Pulp Capping Using Mineral Trioxide Aggregate and Calcium Hydroxide in Mature Permanent Molars with Pulp Exposed during Carious Tissue Removal: 1-year Follow-up. *J Endod* 2019; 45:840-47.
43. Tüzüner T, Alacam A, Altunbas DA, et al. Clinical and radiographic outcomes of direct pulp capping therapy in primary molar teeth following haemostasis with various antiseptics: a randomised controlled trial. *Eur J Paediatr Dent* 2012; 13:289-92.
44. Mente J, Geletneky B, Ohle M, et al. Mineral trioxide aggregate or calcium hydroxide direct pulp capping: an analysis of the clinical treatment outcome. *J Endod* 2010;36:806-13.
45. Elmsmari F, Ruiz XF, Miró Q, et al. Outcome of Partial Pulpotomy in Cariously Exposed Posterior Permanent Teeth: A Systematic Review and Meta-analysis. *J Endod.* 2019 Sep 9. doi: 10.1016/j.joen.
46. Cushley S, Duncan HF, Lappin MJ, et al. Pulpotomy for mature carious teeth with symptoms of irreversible pulpitis: A systematic review. *J Dent.* 2019 Sep;88:103158. doi: 10.1016/j.jdent.
47. Linsuwanont P, Wimonsutthikul K, Pothimoke U, et al. Treatment outcomes of mineral trioxide aggregate pulpotomy in vital permanent teeth with carious pulp exposure: the retrospective study. *J Endod* 2017; 43, 225-30.
48. Witherspoon DE. Vital pulp therapy with new materials: new directions and treatment perspectives--permanent teeth. *J Endod.* 2008;34:S25-8.

49. Parirokh M, Torabinejad M, Dummer PMH. Mineral trioxide aggregate and other bioactive endodontic cements: an updated overview - part I: vital pulp therapy. *Int Endod J.* 2018; 51:177-205.
50. Zanini M, Sautier JM, Berdal A, et al. Biodentine induces immortalized murine pulp cell differentiation into odontoblast-like cells and stimulates biomineralization. *J Endod* 2012; 38:1220-6.
51. de Souza Costa CA, Lopes do Nascimento AB, Teixeira HM, et al. Response of human pulps capped with a self-etching adhesive system. *Dent mater* 2001; 17:230-40.
52. Jeanneau C, Laurent P, Rombouts C, et al. Light-cured Tricalcium Silicate Toxicity to the Dental Pulp. *J Endod* 2017; 43:2074-80.
53. Eidelman E, Holan G, Fuks AB. Mineral trioxide aggregates vs. formocresol in pulpotomized primary molars: a preliminary report. *Pediatr Dent* 2001;23:15-8.
54. Caliskan MK. Pulpotomy of carious vital teeth with periapical involvement. *Int Endo J* 1995; 28, 172-6.
55. Li Y, Sui B, Dahl C, et al. Pulpotomy for carious pulp exposures in permanent teeth: A systematic review and meta-analysis. *J Dent* 2019; 84:1-8.
56. Alqaderi H, Lee CT, Borzangy S, Pagonis TC Coronal pulpotomy for cariously exposed permanent posterior teeth with closed apices: A systematic review and meta-analysis. *J Dent* 2016;44:1-7.
57. Bjørndal L, Reit C, Bruun G, et al. Treatment of deep caries lesions in adults: randomized clinical trials comparing stepwise vs. direct complete excavation, and direct pulp capping vs. partial pulpotomy. *Eur J Oral Sci.* 2010; 118:290-7
58. Li Z, Cao L, Fan M, et al. Direct Pulp Capping with Calcium Hydroxide or Mineral Trioxide Aggregate: A Meta-analysis. *J Endod.* 2015; 41:1412-7.
59. Tan SY, Yu VSH, Lim KC et al. Long-term pulpal and restorative outcomes of pulpotomy in mature permanent teeth. *J Endod.* 2020;46:383-90.
60. Diogenes A, Ruparel NB, Shiloah Y, et al. Regenerative endodontics: A way forward. *J Am Dent Assoc* 2016; 147:372-80.

61. Yazdani S, Jadidfarid MP, Tahani B, et al. Health Technology Assessment of CEM Pulpotomy in Permanent Molars with Irreversible Pulpitis. *Iran Endod J* 2014; 9:23-9.
62. Schwendicke F, Stolpe M. Direct pulp capping after a carious exposure versus root canal treatment: a cost-effectiveness analysis. *J Endod* 2014; 40:1764-70
63. Duncan HF, Bjørndal L, van der Sluis L, et al. Third European Society of Endodontology (ESE) research meeting: Deep caries and the exposed pulp: current and emerging therapeutic perspectives. *Int Endod J* 2019;52:135-38.
64. Bjørndal L, Simon S, Tomson PL, et al. Management of deep caries and the exposed pulp. *Int Endod J* 2019;52:949-73.
65. Mass E, Zilberman U. Clinical and radiographic evaluation of partial pulpotomy in carious exposure of permanent molars. *Pediatr Dent* 1993;15:257-9.
66. Mass E, Zilberman U. Long-term radiologic pulp evaluation after partial pulpotomy in young permanent molars. *Quintessence Int.* 2011;42:547-54.
67. Kang CM, Sun Y, Song JS, et al. A randomized controlled trial of various MTA materials for partial pulpotomy in permanent teeth. *J Dent.* 2017;60:8-13.
68. Uesrichai N, Nirunsittirat A, Chuveera P, et al. Partial pulpotomy with two bioactive cements in permanent teeth of 6- to 18-year-old patients with signs and symptoms indicative of irreversible pulpitis: a noninferiority randomized controlled trial. *Int Endod J.* 2019;52:749-59.
69. Caliskan M. Success of pulpotomy in the management of hyperplastic pulpitis. *Int Endod J* 1993; 26: 142-8
70. Taha NA, Abdulkhader SZ. Full pulpotomy with biodentine in symptomatic young permanent teeth with carious exposure. *J Endod.* 2018;44:932-37.
71. Miles JP, Gluskin AH, Chambers D, et al. Pulp capping with mineral trioxide aggregate (MTA): a retrospective analysis of carious pulp exposures treated by undergraduate dental students. *Oper Dent* 2010;35:20-8.
72. Linu S, Lekshmi MS, Varunkumar VS et al. Treatment Outcome Following Direct Pulp Capping Using Bioceramic Materials in Mature Permanent Teeth with Carious Exposure: A Pilot Retrospective Study. *J Endod* 2017;43:1635-39.

