



**HAL**  
open science

## Heparin-induced thrombocytopenia leading to a diagnosis of essential thrombocythemia

Adeline Pontis, Jessica Valaize, Martin Kerleveo, Pierre Gueret, Marc Bernard, Philippe Mabo, Isabelle Gouin-Thibault, Fabienne Nedelec-Gac

► **To cite this version:**

Adeline Pontis, Jessica Valaize, Martin Kerleveo, Pierre Gueret, Marc Bernard, et al.. Heparin-induced thrombocytopenia leading to a diagnosis of essential thrombocythemia. *International Journal of Laboratory Hematology*, 2021, 43 (4), pp.O193-O196. 10.1111/ijlh.13507 . hal-03188947

**HAL Id: hal-03188947**

**<https://hal.science/hal-03188947>**

Submitted on 7 Sep 2021

**HAL** is a multi-disciplinary open access archive for the deposit and dissemination of scientific research documents, whether they are published or not. The documents may come from teaching and research institutions in France or abroad, or from public or private research centers.

L'archive ouverte pluridisciplinaire **HAL**, est destinée au dépôt et à la diffusion de documents scientifiques de niveau recherche, publiés ou non, émanant des établissements d'enseignement et de recherche français ou étrangers, des laboratoires publics ou privés.



Distributed under a Creative Commons Attribution - NonCommercial 4.0 International License

## Title page

# Heparin induced thrombocytopenia leading to a diagnosis of essential thrombocythemia

An uncommon case of heparin induced thrombocytopenia

Pontis A.<sup>1, 2</sup>, Valaize J.<sup>1</sup>, Kerleveo M.<sup>3</sup>, Gueret P.<sup>1</sup>, Bernard M.<sup>4</sup>, Mabo P.<sup>3</sup>, Gouin-Thibault I.<sup>1, 2</sup>,  
Nedelec-Gac F.<sup>1</sup>

<sup>1</sup> Laboratoire d'Hématologie-Hémostase, Centre Hospitalo-Universitaire de Rennes, Rennes,  
France

<sup>2</sup> CIC-INSERM 1414 Université Rennes 1, Rennes, France

<sup>3</sup> Cardiologie, Centre Hospitalo-Universitaire de Rennes, Rennes, France

<sup>4</sup> Hématologie clinique, Centre Hospitalo-Universitaire de Rennes, Rennes, France

Correspondence: Pontis A., Laboratoire d'hématologie-hémostase, Centre Hospitalo-  
Universitaire de Rennes, 2 rue Henri le Guilloux 35033 RENNES Cedex 9, France

E-mail: [adeline.pontis@chu-rennes.fr](mailto:adeline.pontis@chu-rennes.fr)

**Keywords:** HIT, ET, platelets, thrombosis, anticoagulants

## Main body of text

Dear Editors,

Essential thrombocythemia (ET) belongs to the “BCR-ABL-negative” subcategory of Myeloproliferative Neoplasms (MPN) along with polycythemia vera (PV) and primary myelofibrosis (PM). Various recurrent molecular alterations have been described in classical MPN, such as JAK2 V617F, MPL W515L/K mutations, and deletion or insertions in the calreticulin (CALR) gene<sup>1</sup>. MPN are known for high incidence of thrombotic complications, with a predominance of arterial rather than venous events (16.2% vs 6.2%). Indeed, prevalence of overall thrombosis have been described in 28.6%, 20.7% and 9.5% of patients with PV, ET and PM respectively<sup>2</sup>. In addition to the traditional risk factors of thrombosis, blood cells count, mutational profile, chronic inflammation and abnormal cell adhesion appear to be specific risk factors of thrombosis in MPN-patients<sup>3</sup>. The classical initial treatment of these thrombotic complications includes unfractionated heparin (UFH).

Heparin-induced thrombocytopenia (HIT) is a rare but potentially life-threatening complication of heparin therapy. Its incidence has been lowered by the use of low molecular weight heparins (LMWH). Indeed, it occurs in 0.1 to 0.8% of patients treated by LMWH and in 1 to 2.6% of patients under UFH<sup>4</sup>. HIT diagnosis comprises the use of the clinical 4Ts scoring system and the detection of antibodies against the heparin/platelet factor 4 (PF4) complex. Diagnosis confirmation is based on platelet activation in the presence of heparin, classically measured by radiolabeled serotonin release assay (SRA)<sup>5</sup>. Treatment of HIT relies on the withdrawal of heparin and administration of an alternative non-heparin anticoagulant agent.

In the current work, we report the case of a patient developing multiple thrombosis in a context of HIT, who was diagnosed with essential thrombocythemia CALR-mutated.

A 45 year-old man referred to our hospital for worsening of exertional dyspnea was diagnosed with a massive bilateral pulmonary embolism. He had no specific medical history. His initial hemoglobin was 13.1 g/dL, platelet count 306 G/L, creatinine 118  $\mu\text{mol/L}$ . The patient improved on UFH therapy, but one week after treatment initiation a fall in platelet count to 64 G/L was noticed (figure 1). Since no obvious cause of thrombocytopenia was found (sepsis, disseminated intravascular coagulation, immune thrombocytopenia, drugs and viral infection), HIT was suspected. On day 8, the "4Ts" score was high (6 points) and the anti-PF4 IgG antibodies were positive by immunoassay (optical density=1.09). The functional assay SRA was then found positive. UFH was switched to argatroban. Four days later, platelet count reached its nadir: 35 G/L. The day after, the patient presented superficial (basilica vein) as well as deep (ulnar and brachial veins) venous thrombosis of the left arm, and deep venous thrombosis of the right lower limb (femoropopliteal and sural veins) while on therapeutic dose of argatroban (anti-IIa activity between 0.88 and 1.08  $\mu\text{g/mL}$ ). The argatroban dose was increased with a target anti-IIa of 1.5  $\mu\text{g/mL}$ . Despite this treatment, the patient worsened and developed a complete deep venous thrombosis of his lower limb. His platelet count remained low around 70 G/L for seven days. Warfarin, a vitamin K antagonist (VKA), was started at day 21 as platelet count improved and reached 163 G/L. On day 25, the INR was of 6.47, leading to a decrease in argatroban dose. The next day, skin necrosis appeared on the patient's hip so VKA was stopped and vitamin K was administered *per os* while argatroban was increased again to the previous anti-IIa target (1.5 $\mu\text{g/mL}$ ). Thrombophilia screening was negative (Protein C, protein S, antithrombin, activated protein C resistance, FV Leiden mutation, FII 20210 mutation, lupus anticoagulant and antiphospholipid antibodies). Screening for myeloproliferative neoplasm was also performed and a CALR type I mutation (deletion of 52-bp) was found. Bone marrow biopsy showed a megakaryocytic hyperplasia with reticulenic myelofibrosis (state 2) confirming the diagnosis of ET. Antithrombotic treatment with dabigatran (150 mg twice daily) and aspirin

Figure 1

(160 mg daily) was initiated, in association with hydrocarbamide, after collegial discussion with hematologists. The patient was discharged from hospital on day 33 with a platelet count of 220 G/L. To date, the patient is still on antithrombotic treatment (VKA and aspirin) and he has not experienced any new thrombotic event.

Mutations of *CALR*, a gene encoding the calcium-binding chaperone calreticulin, are the predominant mutations found in patients with non-*JAK2 V617F*-mutated ET, accounting for 20–25% of the overall somatic mutations in ET. Compared to *JAK2 V617F*-mutated-ET, *CALR*-mutated ET has a distinct clinical presentation: it is associated with male sex, younger patients, higher platelet count (>1000 G/L), lower hemoglobin levels, lower leukocyte count and a significantly lower risk of thrombosis<sup>6</sup>. In our case, the clinical presentation was marked by venous thromboembolic events, which is uncommon for a *CALR*-mutated ET. This atypical thrombotic presentation may be in relation with the HIT developed by the patient.

HIT is characterized by an immune reaction caused by IgG antibodies recognizing macromolecular complexes of PF4 and heparin. The pathogenicity of these IgG antibodies is linked to their activation of platelet Fc $\gamma$  receptors, particularly Fc $\gamma$ RIIA. In "classical" HIT, activated platelets release PF4 from their  $\alpha$  granules, leading to the formation of more PF4/heparin complexes<sup>5</sup>. This leads to powerful platelet activation, release of procoagulant microparticles and intense thrombin generation. It has been reported that ET is associated with a 173% increase in concentration of circulating PF4<sup>7</sup>. Whether this potential high level of plasmatic PF4 participates to the genesis and/or severity of HIT in patients with ET has to be established.

Patients with MPN seem to have a higher incidence of HIT<sup>8</sup>. The first case of HIT after heparin therapy in patient with ET was described in 1996 by Walther *et al*<sup>9</sup>. Twenty-three cases have been then reported (table 1), all in patients previously diagnosed with HIT.

Table 1
---------

Recently, Castelli *et al*<sup>10</sup> suggested that HIT could be more frequent in *JAK2*-mutated ET rather than non-*JAK2*-mutated-ET, in a retrospective study concerning twelve patients. In their study, the diagnosis of HIT was based on a high 4Ts score ( $\geq 7$ ) and the detection of IgG anti-heparin/PFA antibodies by optical density, with no confirmation by functional assays. Thus, we cannot eliminate a non-clinically relevant positivity of the anti-PF4 antibodies. In our case, the detection of antibodies against the heparin/PF4 complex by ELISA was confirmed by radiolabeled SRA.

HIT can be responsible for severe and extensive thrombotic events, but the originality of our case is that these complications, of particular severity, led to the screening for underlying myeloproliferative neoplasm and the diagnosis of *CALR*-mutated ET. This association is quite uncommon, as no HIT in *CALR*-mutated ET has been described so far. HIT in ET patients can be underdiagnosed or delayed with a risk of a worse prognosis, due to a high baseline platelet count and a nadir platelet count over 100 G/L. Whether this holds true for *CALR*-mutated ET, where baseline platelets counts are higher than in others ET, can be suspected but has not been proved so far. Interestingly, in our case, the platelet level at admission was particularly low considering the presence of *CALR*-mutated ET. This is probably in relation with the acute massive thrombosis (bilateral pulmonary embolism) presented by the patient, likely responsible of an important platelet consumption. Unfortunately, no platelet count history was available before hospitalization. Moreover, the nadir in platelet count was reached four days after stopping UFH. Overt platelet consumption in the context of multiple thrombosis may have contributed to this delayed nadir.

The association of superficial and deep vein thrombosis is uncommon in HIT but has already been described. We can thus wonder whether this superficial thrombosis is related to the patient's ET or if the HIT contributed to its onset. Moreover, HIT is known to be associated with an hypercoagulability state. In our case, the patient had to face a real "thrombotic storm" with multiple venous thrombotic manifestations at first and then skin necrosis. The combination of HIT and ET likely played an important role in the severity of these extensive thrombotic complications.

Concerning the occurrence of skin necrosis, although VKA was introduced when the platelet count was over 150 G/L, the overlap may have been too short, regarding the international recommendations<sup>11</sup>, before the argatroban dose was decreased (4 days). However, skin necrosis may also be related to the use of argatroban at high therapeutic dose. The specific strong anti-IIa activity of argatroban at this dose may have drastically lowered the protein C activation by thrombin-thrombomodulin complex, thus worsening the VKA-related activated protein C depletion and contributing to the skin necrosis. Argatroban alone was administered for 7 days and was then switched to the unusual combined treatment of dabigatran and aspirin, at usual posology.

In conclusion, this is the first report of a severe case of HIT that led to the diagnosis of *CALR*-mutated ET. In case of HIT with extended thrombosis while on therapeutic anticoagulant dose, a screening for all myeloproliferative neoplasm, including *CALR*-mutated ET, should therefore be considered even in the absence of high baseline platelet count.

Several cases of HIT diagnosed in patients with ET have been described. Thus, it would be interesting to further explore the potential association between ET and HIT, with particular focus on levels of circulating PF4 in ET patients.

**Conflicts of interest**

None declared.



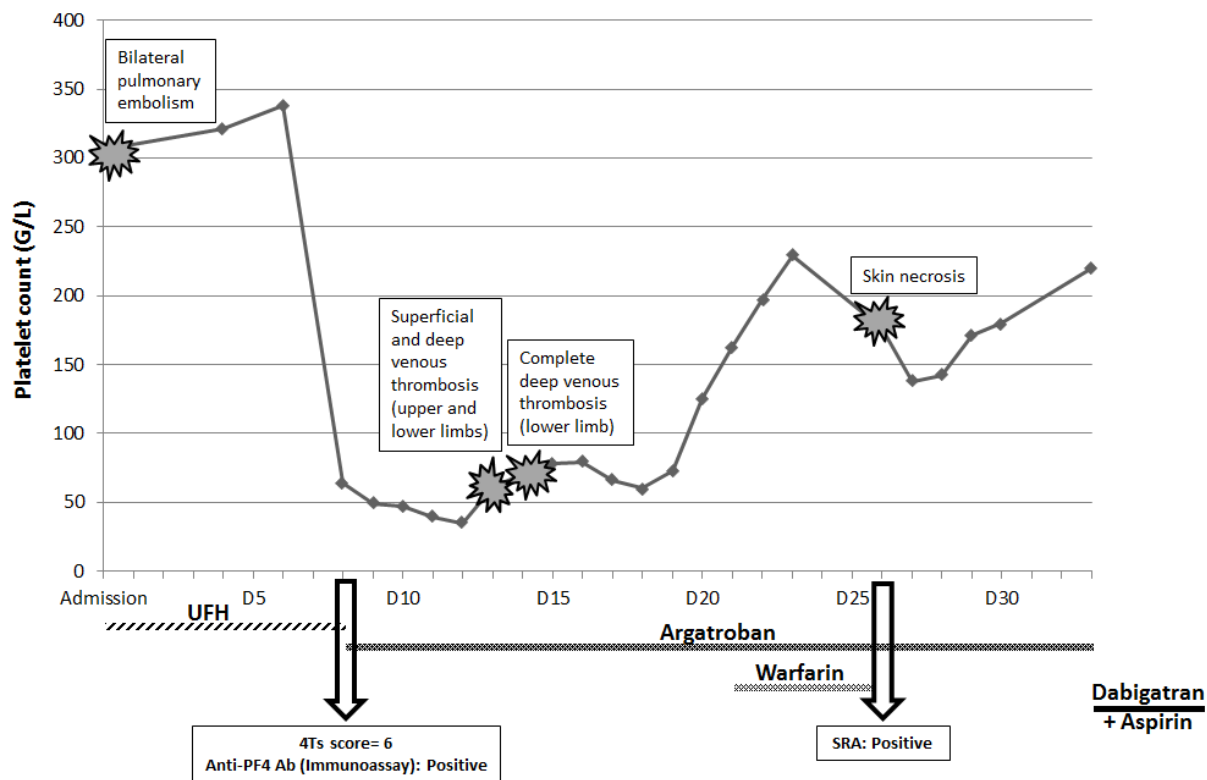
## Acknowledgments

FNG and IGT supervised the study. FNG, IGT and PG designed the study. AP, JV and MK collected data and wrote the manuscript. MK, MB and PM provided clinical information. All authors critically read and approved the manuscript.

## Reference list

1. Tefferi A, Pardanani A. Essential Thrombocythemia. *New England Journal of Medicine*. 2019;381(22):2135-2144. doi:10.1056/NEJMcp1816082
2. Rungjirajittranon T, Owattanapanich W, Ungprasert P, Siritanaratkul N, Ruchutrakool T. A systematic review and meta-analysis of the prevalence of thrombosis and bleeding at diagnosis of Philadelphia-negative myeloproliferative neoplasms. *BMC Cancer*. 2019;19(1):184. doi:10.1186/s12885-019-5387-9
3. Stein BL, Martin K. From Budd-Chiari syndrome to acquired von Willebrand syndrome: thrombosis and bleeding complications in the myeloproliferative neoplasms. *Hematology Am Soc Hematol Educ Program*. 2019;2019(1):397-406. doi:10.1182/hematology.2019001318
4. Martel N, Lee J, Wells PS. Risk for heparin-induced thrombocytopenia with unfractionated and low-molecular-weight heparin thromboprophylaxis: a meta-analysis. *Blood*. 2005;106(8):2710-2715. doi:10.1182/blood-2005-04-1546
5. Arepally GM. Heparin-induced thrombocytopenia. *Blood*. 2017;129(21):2864-2872. doi:10.1182/blood-2016-11-709873
6. Rumi E, Pietra D, Ferretti V, et al. JAK2 or CALR mutation status defines subtypes of essential thrombocythemia with substantially different clinical course and outcomes. *Blood*. 2014;123(10):1544-1551. doi:10.1182/blood-2013-11-539098
7. Małecki R, Gacka M, Kuliszkiwicz-Janus M, et al. Altered plasma fibrin clot properties in essential thrombocythemia. *Platelets*. 2016;27(2):110-116. doi:10.3109/09537104.2015.1042967
8. Bovet J, Maistre ED, Bejot Y, Girodon F. Are Myeloproliferative neoplasms a risk factor for Heparin-Induced Thrombocytopenia? *British Journal of Haematology*. 2016;175(3):537-539. doi:10.1111/bjh.13874
9. Walther EU, Tiecks FP, Haberl RL. Cranial sinus thrombosis associated with essential thrombocythemia followed by heparin-associated thrombocytopenia. *Neurology*. 1996;47(1):300-301. doi:10.1212/wnl.47.1.300-a
10. Castelli R, Gallipoli P, Schiavon R, Teatini T, Deliliers GL, Bergamaschini L. High prevalence of heparin induced thrombocytopenia with thrombosis among patients with essential thrombocythemia carrying V617F mutation. *Journal of Thrombosis and Thrombolysis*. 2018;45(1):106-113. doi:10.1007/s11239-017-1566-1
11. Linkins L-A, Dans AL, Moores LK, et al. Treatment and Prevention of Heparin-Induced Thrombocytopenia: Antithrombotic Therapy and Prevention of Thrombosis, 9th ed: American College of Chest Physicians Evidence-Based Clinical Practice Guidelines. *Chest*. 2012;141(2, Supplement):e495S-e530S. doi:10.1378/chest.11-2303

## Tables and figures caption list



**Figure 1:** Synthesis graph of the main thromboembolic and biological events during the patient's hospitalization. The chronology of treatments is represented under the graph. SRA: Serotonin Release Assay, UFH: Unfractionated Heparin

Case number	Age/sex	Disease treated with heparin	Initial platelet count x10 <sup>9</sup> /UL	Platelet Nadir x10 <sup>9</sup> /UL	New thrombotic event	Type of heparin	Mutation	Biological test	Author (year)
1	52/F	Cranial sinus thrombosis	1008	109	None	UFH	NA	NA	Walther et al. (1996)
2	57/M	Transient ischemic attack	1235	633	None	UFH	NA	ELISA	Risch et al. (2000)
3	78/F	Subclavian and axillary thrombosis	965	194	None	UFH	NA	SRA	Houston (2000)
4	71/F	Spleen infarction	640	383	Heparin-induced skin necrosis	UFH + LMWH	NA	ELISA	Spectre et al. (2008)
5	38/F	Budd-Chiari syndrome	175	78	Heparin-induced skin necrosis	UFH	V617F	HIPA	Randi et al. (2010)
6	66/F	DVT and pulmonary embolism	700	6	Not described	UFH	Not V617F	ELISA	Lapcorella et al. (2010)
7	61/F	Cerebral venous thrombosis	517	42	Extension of cerebral venous thrombosis	UFH	V617F	ELISA	Richard et al. (2011)
8	67/F	Cerebral infarction	1270	7	Cerebral infarct, femoral artery occlusion, and thrombophlebitis of extremities	UFH	NA	ELISA	Murawaki et al. (2012)
9	48, F	Ischemic stroke	665	135	None	UFH	V617F	ELISA+PAT	Bovet et al. (2015)
10	47, F	Cerebrovascular thrombosis	444	85	Thrombosis in central venous line and in radial artery	UFH	V617F	ELISA+PAT	Bovet et al. (2015)
11	67/F	NSTEMI	750	216	Cerebral infarct, popliteal vein thrombosis	UFH	NA	SRA	Noel et al. (2015)
12->23	F: n=7 M: n=5 Age: NA	Arterial thrombosis: n=5 Venous thrombosis: n=5 Surgery prophylaxy: n=2	>450: n=5 <450: n=7	>100: n=4 <100: n=8	Arterial: n=5 Venous: n=7	UFH: n=3 LMWH: n=9	V617F: n=10 Not V617F / none: n=2	ELISA: n=11 HIPA: n=1	Castelli et al (2018)
Present case	45/M	Bilateral pulmonary embolism	306	36	Deep venous thrombosis of lower limb, superficial and deep venous thrombosis of the left arm, skin necrosis	UFH	CALR	ELISA + SRA	Present case

**Table 1:** Reported cases of patients with essential thrombocythemia and HIT

F=Female, M=Male, NA=Not available, DVT= Deep venous thrombosis, NSTEMI=Non-ST Elevation Myocardial Infarction, UFH=Unfractionated heparin, LMWH=Low molecular weight heparin, CALR= Calreticulin, ELISA=Enzyme-Linked Immunosorbent Assay, HIPA=Heparin Induced Platelet Aggregation, PAT=Platelet Aggregation Test, SRA=Serotonin Release Assay