



HAL
open science

Simultaneous proteoglycans and hypoxia mapping of chondrosarcoma environment by frequency selective CEST MRI

Roxane Autissier, Leslie Mazuel, Elise Maubert, Jean-marie Bonny, Philippe Auzeloux, Sébastien Schmitt, Amidou Traoré, Caroline Peyrode, Elisabeth Miot-noirault, Guilhem Pagès

► To cite this version:

Roxane Autissier, Leslie Mazuel, Elise Maubert, Jean-marie Bonny, Philippe Auzeloux, et al.. Simultaneous proteoglycans and hypoxia mapping of chondrosarcoma environment by frequency selective CEST MRI. *Magnetic Resonance in Medicine*, inPress, 86 (2), pp.1008-1018. 10.1002/mrm.28781 . hal-03187913

HAL Id: hal-03187913

<https://hal.science/hal-03187913v1>


Submitted on 1 Apr 2021

HAL is a multi-disciplinary open access archive for the deposit and dissemination of scientific research documents, whether they are published or not. The documents may come from teaching and research institutions in France or abroad, or from public or private research centers.

L'archive ouverte pluridisciplinaire **HAL**, est destinée au dépôt et à la diffusion de documents scientifiques de niveau recherche, publiés ou non, émanant des établissements d'enseignement et de recherche français ou étrangers, des laboratoires publics ou privés.



Distributed under a Creative Commons Attribution 4.0 International License



Simultaneous proteoglycans and hypoxia mapping of chondrosarcoma environment by frequency selective CEST MRI

Journal:	<i>Magnetic Resonance in Medicine</i>
Manuscript ID	MRM-20-21766.R1
Wiley - Manuscript type:	Full Paper
Research Type:	Physiological Research, Translational Research < Physiological Research
Research Focus:	Cancer, Pathology < Function < Cartilage < Musculoskeletal

SCHOLARONE™
Manuscripts

1
2
3 **1 Simultaneous proteoglycans and hypoxia mapping of chondrosarcoma environment**
4 **2 by frequency selective CEST MRI**

5
6 3 Roxane Autissier^{1,2,3}; Leslie Mazuel^{1,2,3}; Elise Maubert²; Jean-Marie Bonny^{1,3}; Philippe Auzeloux²;
7 4 Sébastien Schmitt²; Amidou Traoré^{1,3}; Caroline Peyrode²; Elisabeth Miot-Noirault² & Guilhem
8 5 Pagès^{1,3}
9 6

10 7 ¹INRAE, UR QuaPA, F-63122 Saint-Genès-Champanelle, France

11 8 ²Université Clermont Auvergne, Inserm, IMoST, F-63000 Clermont-Ferrand, France

12 9 ³AgroResonance, INRAE, 2018. Nuclear Magnetic Resonance Facility for agronomy, food and health,
13 10 <https://doi.org/10.15454/1.5572398324758228E12>

14 11 Correspondence: Roxane Autissier, PhD student

15 12 UMR 1240 IMoST Inserm/Université Clermont Auvergne

16 13 58, rue Montalembert, 63005 Clermont Ferrand cedex, France

17 14 e-mail : Roxane.AUTISSIER@uca.fr

18 15
19 16
20 17 Grant: Ligue Contre le Cancer Auvergne - Rhône - Alpes.

21 18
22 19 Word count: 4201
23 20
24 21
25 22
26
27
28
29
30
31
32
33
34
35
36
37
38
39
40
41
42
43
44
45
46
47
48
49
50
51
52
53
54
55
56
57
58
59
60

1
2
3 **ABSTRACT**
4
5

6 **Purpose:** To evaluate the relevance of CEST frequency selectivity in simultaneous in vivo imaging of
7 both of chondrosarcoma's (CHS) phenotypic features, i.e. its high proteoglycan (PG) concentration and
8 its hypoxic core.
9

10
11 **Methods:** Swarm rat CHSs were implanted subcutaneously in NMRI Nude mice. When tumors were
12 measurable (between 12 and 16 days post-operative), mice were submitted to GAG, guanidyl and amide
13 proton transfer (APT) CEST imaging. PGs and hypoxia were assessed in parallel by nuclear imaging
14 exploiting ^{99m}Tc -NTP 15-5 and ^{18}F -FMISO, respectively. Data were completed by ex vivo analysis of
15 PGs (histology and biochemical assay) and hypoxia (immunofluorescence).
16
17

18
19 **Results:** Quantitative analysis of GAG CEST evidenced a significantly higher signal for tumor tissues
20 than for muscles. These results were in agreement with nuclear imaging and ex vivo data. For imaging
21 tumoral pH in vivo, the CEST ratio of APT/Guanidyl was studied. It highlighted an important
22 heterogeneity inside the tumor. The hypoxic status was confirmed by ^{18}F -FMISO TEP imaging and ex
23 vivo immunofluorescence.
24
25

26
27 **Conclusion:** CEST MRI simultaneously imaged both CHS properties during a single experimental run
28 and without the injection of any contrast agent. Both MR and nuclear imaging as well as ex vivo data
29 were in agreement and showed that this CHS animal model was rich in PGs. However, even if tumors
30 were lightly hypoxic at the stage studied; acidic areas were highlighted and mapped inside the tumor.
31
32

33
34
35 **Keywords:** CEST; Chondrosarcoma; Hypoxia; MRI; Nuclear imaging; Proteoglycans.
36
37
38
39
40
41
42
43
44
45
46
47
48
49
50
51
52
53
54
55
56
57
58
59
60

1. INTRODUCTION

Chondrosarcoma (CHS) is a malignant cartilaginous tumor representing the most common primary bone cancer in adults.^(1,2) CHS is characterized by a dense heterogeneous extracellular matrix (ECM), a low percentage of dividing cells and poor vascularity.⁽³⁾ The combination of these three factors leads to chemo and radiation therapy resistance.⁽⁴⁻⁸⁾

Dense and fibrotic ECM with high levels of collagen and proteoglycans (PGs) is recognized to impair interstitial transport of drug from blood to cancer cells.⁽⁹⁾ In addition, the acidic microenvironment associated with hypoxia may electrostatically charge the drugs, limiting their ability to cross biological membranes.⁽¹⁰⁾ In vivo assessment of the phenotypic topological heterogeneity of the tumor microenvironment is key to optimizing personalized therapies. Although, biopsy is subject to sampling and pathologist/observer variability, microenvironmental characterization is mainly achieved from biopsy samples to determine grade and staging of the disease.⁽¹¹⁾ Tumor evaluation requires access to morphological and protein information in a context that takes into account intratumoral heterogeneity as a whole. In such a situation, developing imaging methods to access the main recognized CHS features, i.e. chondrogenic matrix and hypoxia, would be of great interest for diagnosis and clinical follow-up. Indeed, the current clinical imaging methods recommended, i.e. CT and MRI,⁽¹²⁾ are used to define tumor morphology and distinguish postoperative residues from postoperative or post-chemotherapeutic residual lesions. However, such approaches cannot be used in the same manner as functional imaging to assess tumor environment.⁽¹³⁾

Functional imaging can be done with specific radiotracers to access metabolic data useful to diagnose and assess the therapeutic response of CHS. Due to their rarity, there is a lack of large trials on functional imaging of chondroid tumors. Nowadays, nuclear medicine used to image CHS in a clinical context targets either the bone remodeling or the glucose tumoral metabolism with radiotracers such as ^{99m}Tc-MDP or ¹⁸F-FDG, respectively.⁽¹⁴⁾ To more accurately image the CHS microenvironment, radiotracers should target either ECM PGs or the CHS hypoxia feature. ^{99m}Tc-NTP 15-5 emerged from our lab as a candidate SPECT tracer for the functional imaging of cartilage by targeting PG negative charges in ECM. It demonstrated its relevance to specifically diagnose on CHS animal model and is expected to enter clinical trials shortly.⁽¹⁵⁻¹⁷⁾ One of the radiotracers extensively used in clinic for hypoxia is ¹⁸F-FMISO.⁽¹⁸⁾ As with many nitroimidazole derivatives, under reduced oxygen conditions, this tracer is reduced into a R-NO₂ radical that binds covalently to intracellular molecules leading ultimately to the entrapment of the tracer in hypoxic cells. To image both tumor features, two nuclear exams are required with two injections of radioactive contrast agent. Therefore, it would be interesting to develop a method to simultaneously image both of the metabolic properties of CHS.

The recent rise of CEST MRI has opened up new perspectives in the imaging of biological molecules within the tumoral microenvironment.⁽¹⁹⁾ This method is based on the exchange between saturated labile protons of the solute with the bulk water, revealing the endogenous contrast of some chemical functions. CEST MRI indirectly maps these low concentration metabolites by monitoring the variation of an

1
2
3 81 elevated water signal. Typically, a CEST experiment is a 2-step process. First, the magnetic field
4 82 inhomogeneity has to be mapped; this is the function of the so-called water saturation shift referencing
5 83 (WASSR) acquisition. Second, MR images must be recorded at several saturation frequency offsets to
6 84 record a z-spectrum (normalized water signal as a function of the saturation offset for each voxel). This
7 85 z-spectrum, with a zero-frequency referenced to the water's frequency will display an extra water
8 86 attenuation at the metabolite exchangeable proton frequency, i.e. the CEST effect. To quantify this
9 87 CEST effect, the first proposed method was based on the analysis of the water signal intensity at the
10 88 offset of interest and its counterpart negative value. This magnetization transfer ratio asymmetry
11 89 (MTRasym) analysis hypothesizes the absence of the magnetization transfer effect for negative offsets.
12 90 As this hypotheses is not systematically verified, other z-spectrum analyses were developed, i.e. a three-
13 91 offset measurement approach or multiple-pool Lorentzian fitting method.^(20,21) Hydroxyl, guanidyl and
14 92 amide moieties were independently imaged by CEST MRI.^(22,23) Readers interested in a deeper
15 93 explanation of CEST MRI principles are referred to the following references.^(24–26)

16 94 CEST MRI has demonstrated its relevance for the quantitative evaluation and mapping of PGs in
17 95 cartilaginous tissues by assessing the chemical exchange of saturable protons with the hydroxyl groups
18 96 (i.e., around 0.5 – 1.5 ppm) of GAG molecules^(27,28) in both physiological and pathological situations.^{(29–}
19 97 ³¹⁾ In addition, CEST MRI has been demonstrated to be sensitive to pH variations, indirectly revealing
20 98 information on the metabolic switch in response to hypoxia.⁽³²⁾ Several studies have demonstrated that
21 99 pH variations impact the chemical exchange rate of both guanidyl and amide moieties.^(33,34) The change
22 100 in the chemical exchange rate with the pH leads to a variation of the CEST intensity at frequencies of
23 101 around 1.8 – 2.4 and 3.0 – 4.0 ppm for guanidyl and amide proton transfer (APT) CEST, respectively.
24 102 Therefore, the combination of both guanidyl and APT CEST has been proposed as a highly sensitive
25 103 method to explore extracellular pH acidification in tumors.^(35,36)

26 104 Considering that PGs and pH each have their own resonance frequencies, and are therefore sensitive
27 105 to different exchangeable moieties, we decided these two features would merit further study using a
28 106 single CEST MRI acquisition on CHS animal model. The aim of this study was to evaluate the relevance
29 107 of frequency-selected CEST MRI to simultaneously map PG concentration and pH of CHS tissue in
30 108 vivo. To validate this approach, CEST MRI was compared to the standard reference nuclear imaging as
31 109 well as ex vivo analysis.

32 110

33 111 2. METHODS

34 112 2.1. GAG and pH phantom experiments

35 113 Phosphate-buffered saline (PBS) 1X (Gibco Laboratories, Gaithersburg, MD, USA) containing 1%
36 114 of bovine serum albumin (BSA) solution (Sigma Aldrich, St. Louis, MO, USA) was used to prepare the
37 115 chondroitin 4-sulfate phantom. Five samples of the chondroitin 4-sulfate (Sigma Aldrich, St. Louis, MO,
38 116 USA) were prepared at: 1; 5; 10; 20; 40 mg/mL at pH 7.4. For protamine phantom, 15 mg/mL of
39 117 protamine (Sigma Aldrich, St. Louis, MO, USA) and 0.15 mM of MnCl₂ were dissolved in PBS. Four

1
2
3 118 samples of protamine were prepared with pH ranging from 6.5 to 7.7 in 0.4 unit increments. Both
4
5 119 phantoms (chondroitin 4-sulfate and protamine) were prepared with 15 % gelatin in water to fix the
6
7 120 syringes containing the different solutions. Phantoms were submitted to the same acquisition and
8
9 121 analysis protocols as described below except for B_1 , which was set to 3 μ T.
10

11 123 **2.2. Xenograft model of SWARM rat CHS**

12
13 124 Experiments were conducted in accordance with the European directive 2010/63/EU after approval
14
15 125 by the animal ethical committee C2E2A, authorization number: #15991.

16 126 SWARM rat CHS (SRC) xenografts were performed in 5 week old female NMRI Nude
17
18 127 immunodeficient mice (Janvier Labs, Le Genest-Saint-Isle, FR) from frozen fragments after reactivation
19
20 128 in 4 week old male Sprague Dawley rats (Charles River Laboratories France, Saint Germain Nuelles,
21
22 129 FR). For reactivation, SRC fragments were defrosted in Dulbecco's Modified Eagle Medium (DMEM,
23
24 130 Gibco Laboratories, Gaithersburg, MD, USA) then implanted subcutaneously on the right flank of 3
25
26 131 anesthetized rats (isoflurane; 2.5 %, 1 L/min, air/O₂, 70/30, v/v). After 22 days post-surgery, tumors
27
28 132 were resected and immediately placed in cold DMEM. Then, they were manually calibrated to 1 mm³
29
30 133 and transplanted subcutaneously between the shoulder blades on anesthetized (isoflurane; 1.5 %, 1
31
32 134 L/min, air/O₂, 70/30, v/v) NMRI Nude immunodeficient mice (n=10) and cutaneous wounds were
33
34 135 sutured.
35

36 137 **2.3. In vivo animal imaging**

37
38 138 All imaging experiments were performed at "In Vivo Imaging in Auvergne" (IVIA) facility
39
40 139 (<https://doi.org/10.18145/ivia>). Imaging protocols were performed on the same mice between 12 and 16
41
42 140 days after induction, corresponding to an average tumoral volume of 215.04 ± 86.28 mm³ (see
43
44 141 supporting Figure S1). During these in vivo acquisitions, all animals were anesthetized by isoflurane
45
46 142 (1.5 %, 1 L/min, air/O₂, 70/30, v/v). All animals were secured on a dedicated bed with both breathing
47
48 143 rate and temperature being monitored during acquisitions. Supporting Table S1 describes in details the
49
50 144 animal distribution for each imaging modality.
51

52 146 **2.3.1.MR imaging**

53
54 147 MR images of mice (n = 10) were acquired on an 11.7 Tesla Bruker BioSpec system (Bruker
55
56 148 BioSpin, Ettlingen, Germany) piloted by Paravision 6.0.1 software. A 72 mm circular polarizer volume
57
58 149 coil was used for RF transmission and a surface array coil (2x2) positioned on both the tumor and the
59
60 150 adjacent muscle received the NMR signal (Bruker BioSpin, Ettlingen, Germany).

151
152 *DW imaging:* Tumor imaging was performed with a DWI sequence ($b=500$ s.mm⁻², direction
153
154 [0,0,1]) with a TE of 27 ms and a TR of 2000 ms. The FOV was 40 mm with an axial slice thickness of
155
156 1 mm leading to a nominal resolution of $0.26 \times 0.26 \times 1$ mm³. The number of slices was adjusted to
157
158
159
160

1
2
3 154 image the whole tumor (generally, 12 slices were needed). Two averages were performed for a total
4
5 155 acquisition time of 7 min 32 s.

6 156 *CEST Imaging:* CEST acquisitions were based on a RARE sequence with an effective TE and
7
8 157 TR of 4.756 and 4500 ms, respectively and a RARE acceleration factor of 16. The slice thickness was
9
10 158 2 mm and the FOV 40 mm, i.e. the in-plane voxel size was $0.625 \times 0.625 \text{ mm}^2$. Each image was recorded
11
12 159 from a single transient. A first z-spectrum was recorded to correct for B_0 inhomogeneities by using the
13
14 160 WASSR approach⁽³⁷⁾ (saturation pulses B_1 0.1 μT , 54.8 ms gaussian pulses repeated 18 times with an
15
16 161 interpulse delay of a 0.010 ms, and a bandwidth of 20 Hz leading to a train of 1 s; saturation offsets from
17
18 162 ± 1000 Hz with $\Delta\omega$ 20 Hz) followed by the CEST z-spectrum (30 min acquisition duration with
19
20 163 saturation pulses: B_1 1.5 μT , 54.8 ms gaussian pulses repeated 72 times with a bandwidth of 50 Hz
21
22 164 leading to a train of 4 s and an equivalent continuous wave CEST saturation of 0.6 μT ; saturation offsets
23
24 165 from ± 2500 Hz with $\Delta\omega$ 50 Hz). CEST MRI data were analyzed with an in-house program written in
25
26 166 MATLAB[®] R2017a (MathWorks, Natick, MA USA). In brief, a ROI was manually drawn on the high-
27
28 167 resolution DW image to delineate the tumor and muscle of the scapular region. Then, B_0 shift was
29
30 168 corrected pixel-by-pixel with the WASSR approach. Finally, the CEST methodology applied to analyze
31
32 169 the data depended on the saturation offset. For GAG CEST, the analysis was performed on the whole
33
34 170 image and the z-spectrum was fitted with two Lorentzian shapes: the first one to estimate the signal
35
36 171 attenuation due to the water direct saturation (centered at 0 ppm) and the second one for the hydroxyl
37
38 172 moieties. The GAG CEST signal intensity corresponded to the area of this latter Lorentzian shape.
39
40 173 Regarding guanidyl and APT CEST, we applied the three-offset measurement approach proposed by Jin
41
42 174 et al.⁽²⁰⁾ to avoid nuclear overhauser enhancement (NOE) interferences. In practice, two limits were
43
44 175 chosen (1.60 to 2.40 and 3.20 to 4.00 ppm for the guanidyl and amide moieties, respectively) and a
45
46 176 baseline was drawn between these frequencies. The CEST effect for APT* and guanidyl* were
47
48 177 quantified as the difference between the baseline and the water signal at 1.96 and 3.68 ppm, respectively.
49
50 178 The ratio of APT*/guanidyl* was then calculated. The relative variation of this ratio was expressed from
51
52 179 the mean ratio value on the ROI.

180 181 **2.3.2. Nuclear Imaging**

182 *PGs imaging by SPECT/CT using ^{99m}Tc-NTP 15-5 radiotracer:* SPECT-CT images were
183
184 acquired using a camera (NanoScan[®], Mediso Ltd, Budapest, Hungary) equipped with four multi pinhole
185
186 detectors APT62. Acquisitions were performed on Nucline software (v3.00.018, Mediso Ltd, Budapest,
187
188 Hungary). 20 MBq of ^{99m}Tc-NTP 15-5, radiolabeled as described⁽³⁸⁾, were injected intravenously in the
189
190 tail vein. After 30 min, mice (n = 10) were anesthetized and imaged. Anatomic CT acquisition consisted
of a helical scan with 480 projections, 300 ms per projection, 50 kV, 590 μA . Then, SPECT images
were performed with 128 projections, 20 s per projection and an energy window set at 140 keV \pm 20 %.
After image reconstructions using the 3D ordered subset expectation maximization (3D OSEM)
algorithm, analyses were performed with InterviewTMFUSION (v3.03.074, Mediso Ltd, Budapest,

1
2
3 191 Hungary) software using an interpolated ellipse ROI for both tumor and scapular muscle manually
4 192 drawn slice by slice. Activity concentrations were obtained in kBq/mL.

5 193 *Hypoxia PET imaging using ¹⁸F-FMISO*: PET images were acquired using a small animal device
6 194 (eXplore Vista®, GE Healthcare, Chicago, IL, USA). 30 MBq of ¹⁸F-FMISO were injected intravenously
7 195 in the tail vein. Four hours later, the mice (n = 10) were anesthetized and PET imaging was performed
8 196 with a 250 to 700 keV energy window and 6 ns coincidence time window (30 min duration, 2 bed
9 197 positions) with MMWKS® Image software (GE Healthcare, Chicago, IL, USA). After 2D OSEM
10 198 reconstructions, analyses were performed with VivoQuant™ (v4.0 patch1, inviCRO, Boston, MA, USA)
11 199 software using a 3D ROI for tumor and scapular muscle manually drawn. ¹⁸F-FMISO uptake was
12 200 quantified in kBq/mL.

13 201

202 **2.4. Ex vivo analysis**

203 Histological and immunofluorescence analysis in tumoral tissues were performed at the
204 histopathology facility ANIPATH (CNRS UMR 6293 / Inserm U1103 GReD, Clermont-Ferrand, FR).

205 After a multimodal imaging session, 20 days post-induction, mice (n = 3) were sacrificed by cervical
206 dislocation under anesthesia and tumors were resected and cut into two samples. The first sample was
207 fixed into 10 % neutral buffered formalin for 24 h and embedded in paraffin for histological analysis
208 (alcian blue or pimonidazole staining). The second sample was frozen in liquid nitrogen for GAG assays.
209 For pimonidazole analysis, animals received an intraperitoneal injection of pimonidazole hydrochloride
210 (60 mg/kg, Hypoxyprobe™, Burlington, MA, USA) 1 hour before sacrifice.

211 *Alcian blue staining*: 5 µm thick sections of embedded tumors were cut and adhered to poly-L-
212 Lysine-coated microscope slides. After dewaxing and rehydration, slides were stained by Alcian blue
213 (pH 1) to visualize PGs, counterstained by nuclear red after which coverslips were fixed. Staining was
214 detected and images were recorded using a slide scanner (X20, Zeiss AxioScan Z1, ZEN software).

215 *Pimonidazole staining*: 5 µm thick sections of embedded tumors were cut and adhered to poly-L-
216 Lysine-coated microscope slides. After dewaxing and rehydration of tumor slices, antigens were
217 retrieved (boiling tris: 10 mM, pH 6) and slides were placed into the InsituPro VSi robot (Intavis
218 bioanalytical instruments, Köln, Germany). Endogenous peroxidases were quenched (H₂O₂: 0.3 %, 30
219 min) and saturated (BSA: 1 %, 1 h). Slides were then incubated with a primary antibody (anti-
220 pimonidazole: mouse monoclonal antibody, 1/300, 1h, RT; Hypoxyprobe™). Biotinylated secondary
221 antibody (1/500, BSA 0.1 %, 1 h; Vector Laboratories) was used to reveal the first antibody. Biotin was
222 then complexed with streptavidin-coupled horseradish peroxidase (HRP) (1/500, 30 min; Vector
223 Laboratories). Peroxidase was detected using tyramide signal amplification (TSA) as per manufacturer's
224 instructions (TSA-Alexa488; Invitrogen™). Then, nuclei were counterstained with Hoechst (33342) and
225 coverslips were fixed. Emitted fluorescences (461 nm for Hoechst and 519 nm for TSA) were imaged
226 and recorded as previously (X20, Zeiss AxioScan Z1, ZEN software, Oberkochen, Germany).

227 *GAG assay*: samples (n=10) were weighed (20-50 mg) and incubated overnight at 65°C in 1 mL of
228 a papain extraction buffer and then centrifuged (1000 g, 10 min). Sulfated GAG content was determined
229 using a Blyscan® Sulfated Glycosaminoglycan assay kit (Biocolor Ltd, Carrickfergus, UK) as per
230 manufacturer's instructions. Absorbance was measured at 656 nm using Thermo Scientific Multiskan
231 GO device (Thermo Fisher Scientific, Waltham, MA, USA). Experiments were performed in duplicates.

233 2.5. Statistical analyses

234 Statistical analyses were performed on Prism software version 6.0 (GraphPad Software, San Diego,
235 CA, USA). For in vivo and ex vivo studies, data were presented as individual values with mean \pm SD.
236 Data normal distributions were verified with Shapiro-Wilk tests before performing Student's *t*-tests. For
237 in vivo imaging quantification, paired Student's *t*-tests were applied and for ex vivo analyses, unpaired
238 Student's *t*-tests were performed. Results were considered significant at $P < 0.05$ (* $P < 0.05$, ** $P <$
239 0.01 , *** $P < 0.001$, **** $P < 0.0001$). Significance of results was verified with a Wilcoxon matched-
240 pairs signed rank test.

242 3. RESULTS

243 3.1. GAG, guanidyl and APT CEST on phantoms

244 GAG CEST effects were observed on the z-spectra of chondroitin 4-sulfate solutions (Figure 1A)
245 and guanidyl and APT CEST effects on that of protamine solutions (Figure 1C). The highest CEST
246 effect offset for each moiety appeared at different chemical shifts: 0.75, 1.96 and 3.68 ppm for GAGs,
247 guanidyl and APT, respectively.

248 Linear relationships were found between CEST AUCs and either the GAG concentration
249 ($R^2=0.9845$) or the pH ($R^2=0.8849$ and $R^2=0.8477$, for Guanidyl* and APT* respectively). An increase
250 in GAG concentration and in pH led to an increase of the CEST signal (Figure 1B, 1D). The relative
251 variation of the ratio (reference pH at 7.2) increased from pH 6.8 to 7.7.

252 ***Figure 1 appears near here***

254 3.2. Quantitative assessment of GAGs in CHS tumoral tissue

255 From signal analysis of GAGs by CEST MRI, a GAG concentration-related map (Figure 2A) was
256 constructed. The signal from GAG was clearly evidenced within tumoral tissue, and was observed to be
257 heterogeneously distributed. Regarding muscle, CEST MRI of GAGs was very low with $AUC = 2.15 \pm$
258 1.88 as compared to 27.29 ± 8.38 in tumor ($P < 0.0001$; n=9) (Figure 2B) leading to a tumor/muscle
259 ratio of 23.35 ± 16.97

260 Nuclear imaging, evidenced a significantly ($P < 0.0001$; n=9) higher uptake of the ^{99m}Tc -NTP 15-5
261 radiotracer in tumoral tissue (179.38 ± 38.39 kBq/mL) as opposed to muscle (35.07 ± 5.17 kBq/mL),
262 leading to a tumor/muscle ratio of 5.11 ± 0.69 (Figure 2C and 2D). Four images of ^{99m}Tc -NTP 15-5
263 SPECT imaging are shown on supporting Figure S3A.

264 Ex vivo experiments confirmed this high PG feature of CHS tissue. From biochemical assays, GAG
265 concentration was demonstrated to be $6.33 \pm 1.60 \mu\text{g}/\text{mg}$ in the tumor while it was only 0.41 ± 0.09
266 $\mu\text{g}/\text{mg}$ in the muscle ($P < 0.0001$) (Figure 2F). As illustrated on figure 2E, tumoral tissue was strongly
267 stained by alcian blue confirming its richness in GAGs.

268 ***Figure 2 appears near here***

270 3.3. Quantitative assessment of pH and hypoxia in CHS tumoral tissue

271 Figures 3A shows both the anatomical and relative variation of the APT*/guanidyl* ratio images
272 for 3 randomly chosen mice out of 7. The ratio was only calculated inside the tumor as it cannot be
273 compared with muscle due to extra CEST signal coming from creatine and phosphocreatine. The CEST-
274 based images highlighted a heterogeneous pH distribution inside the tumor.

275 Figure 3B displays a representative image of ^{18}F -FMISO PET. While on this slice, a clear difference
276 between the tumor and the muscle was observed, this was no longer the case once the signal was
277 integrated over the whole tumor (red dots on Figure 3C). At the group level ($n=5$), the tumor mean signal
278 ($18.70 \pm 10.54 \text{ kBq}/\text{mL}$) was different from the muscle's signal ($8.60 \pm 4.30 \text{ kBq}/\text{mL}$). However, the
279 inter-individual variations, especially for the tumor, led to the absence of differences between both
280 tissues. The three incidences of ^{18}F -FMISO PET imaging are shown on supporting Figure S3B.

281 Ex vivo experiments by immunofluorescence with pimonidazole evidenced a weak staining within
282 tumoral tissue, mainly localized in the center of CHS lobules (Figure 3D).

283 ***Figure 3 appears near here***

285 4. DISCUSSION

286 This work aimed to develop in one-scan multiple CEST MRI contrasts to characterize in vivo PG
287 and hypoxic features of the CHS microenvironment. By exploiting the CEST frequency selectivity, we
288 aimed to simultaneously image the PG concentration and pH as it relates to hypoxia. CEST MRI images
289 were compared to current state of the art imaging approaches, i.e. $^{99\text{m}}\text{Tc}$ -NTP 15-5 and ^{18}F -FMISO to
290 map PGs and hypoxia, respectively. To our knowledge, this work is the first one to investigate the
291 microenvironment of CHS by CEST MRI. In most published studies exploiting CEST MRI to image
292 GAG concentration and pH, different saturation protocols are used. Both level and duration of the
293 saturation RF trains are optimized depending on the exchangeable protons targeted. Typically, to image
294 the hydroxyl moieties, the saturation pulse level is moderate while the duration is long.^(39,40) For APT
295 CEST, a variety of saturation conditions have been used.⁽⁴¹⁾ However, to maximize the APT effect, Zhou
296 et al.⁽⁴¹⁾ recommend the usage of a saturation duration higher than 0.8 s and a level of around $2 \mu\text{T}$. Our
297 experimental conditions were close to the optimal ones for the different contrasts. As we wanted to
298 image both tumor features in a single acquisition, we chose to use a long saturation train ($t_{\text{sat}}=4 \text{ s}$) with
299 moderate power ($B_1=1.5 \mu\text{T}$) that was demonstrated from phantom experiments to be a satisfactory
300 compromise. Indeed, the GAG CEST effect was not too broad and did not overlap with the guanidyl

1
2
3 301 one. Obviously, this compromise on the saturation parameters is at the cost of the optimized sensitivity
4 302 for each CEST effect. Carefully choosing the saturation frequencies made it possible to simultaneously
5 303 assess PGs (GAG CEST) and pH (guanidyl and APT CEST). In vitro, we can note that we found an
6 304 increase of the guanidyl* signal like Oskolkov et al.⁽⁴²⁾ while Jin et al.⁽³⁴⁾ observed an opposite trend.
7
8 305 This discrepancy can be due to (i) our multiple-contrast CEST conditions, experimental conditions were
9 306 not set to the optimal values to maximize the CEST effect for pH, (ii) physical parameters, especially
10 307 the chemical exchange rate constant, are not comparable to what was simulated in the other study. To
11 308 obtain a pH variation independent of protein concentration, the ratio of the APT* and guanidyl* CEST
12 309 was calculated.

13
14
15
16
17 310 In vivo GAG CEST images were obtained by acquiring signals resulting from the chemical
18 311 exchange of the abundant hydroxyl groups in GAGs. A 23 times higher CEST effect was observed for
19 312 the tumor compared to muscle demonstrating the high PG density in the CHS microenvironment. CEST
20 313 signal studies of different forms of GAGs typically found in articular cartilage recently demonstrated
21 314 that the CEST effect arises mainly from chondroitin 4-sulfate.⁽⁴³⁾ SRC was demonstrated to highly
22 315 express aggrecan which is composed of a core protein with covalently attached side chains of linear
23 316 GAGs, including a high number of chondroitin sulfate, especially chondroitin 4-sulfate.⁽⁴⁴⁾ The GAG
24 317 CEST approach was combined with ^{99m}Tc-NTP 15-5 nuclear imaging, a radiotracer designed to target
25 318 negatively charged molecules of GAGs.^(16,45) As expected, a higher radiotracer accumulation was
26 319 observed in tumor in respect to muscle (ratio ~5), confirming the higher PG concentration measured by
27 320 GAG CEST. The discrepancies in the tumor to muscle ratios between the MRI and nuclear imaging can
28 321 be explained by the poor vascularization of the tumor, thereby limiting the delivery of the radiotracer.
29 322 Since CEST MRI provided signals from hydroxyl moieties of PGs, we also have to consider that
30 323 hydroxyl moieties are found in other molecules such as glucose or lactate.^(46,47) We therefore were
31 324 interested to complete GAG CEST with ¹H MRS to identify their respective contribution in the CEST
32 325 signal. Unfortunately, due to its high chondrogenic structure, CHS tissue did not provide enough
33 326 resolution on the MRS spectrum. Finally, ex vivo quantitative analysis, i.e. GAG assays, reinforced the
34 327 in vivo multimodal imaging results and evidenced high PG concentration within tumoral tissue (ratio
35 328 tumor/muscle ~18, i.e. in between SPECT and CEST ratios).

36 329 CEST MRI assessment of intratumoral pH variations was performed by exploiting both guanidyl
37 330 and amide to enhance the sensitivity of pH weighted MRI.⁽³⁴⁾ As acidosis is associated to hypoxia⁽⁴⁸⁾, it
38 331 was expected that mapping tumoral pH through CEST MRI would be a relevant methodology to
39 332 delineate areas of hypoxic and well oxygenated cells within tumoral tissue. The CEST signals from both
40 333 chemical groups were assigned to proteins. To have a map independent from protein concentration, the
41 334 APT*/guanidyl* ratio was calculated inside the tumor. This approach assumes that the guanidyl signal
42 335 is coming only from the proteins. This hypothesis is acceptable for tumors, although it cannot be applied
43 336 to other tissues, especially muscle, due to the presence of creatine and phosphocreatine. These
44 337 metabolites give a guanidyl signal, the APT*/guanidyl* ratio will depend on both pH and the metabolite

1
2
3 338 concentrations. In vivo ^{18}F -FMISO PET imaging confirmed the hypoxic status of CHS since the mean
4 339 tumor/muscle ratio value was approximately 2. However, at the group level there was no statistical
5
6 340 difference between the two tissues due to large inter-individual variations. Ex vivo immunofluorescence
7
8 341 with pimonidazole evidenced that hypoxic areas were heterogeneously distributed throughout the
9
10 342 tumoral tissue similarly to CEST MRI.

11 343 The assessment of pH by APT CEST is debated in the literature. Some authors reported a decrease
12
13 344 of the CEST effect on the pH ^(49,50) while others observed the opposite.^(51,52) Most of these APT CEST
14
15 345 effects were obtained after performing the so-called MTR_{asym} analysis. The key assumption in this data
16
17 346 processing is that for negative offsets, only the direct water saturation effect is recorded.⁽⁵³⁾ However, it
18
19 347 was shown in vivo that several NOE exchanges were recorded in the region of ~ -1 to -4 ppm, no longer
20
21 348 fulfilling the MTR_{asym} assumption.⁽⁵⁴⁾ Nevertheless, most of these studies used this estimator. To avoid
22
23 349 the interference of the NOE on our CEST quantifications, our data were analyzed by using the approach
24
25 350 inspired by Jin et al.⁽²⁰⁾ and described in section 2.3.1.

26
27 351 To conclude, our work on SRC bearing mice demonstrated the potential of imaging the different
28
29 352 tumoral microenvironment properties by a single CEST MRI acquisition. MRI presents the main
30
31 353 advantage when compared to nuclear imaging to give high-resolution spatial information. It is then
32
33 354 possible to delineate accurately the metabolism-related region of interest. Such parametric maps would
34
35 355 allow a better understanding of the relationship between tumor cells and their environment, thus
36
37 356 becoming a prerequisite to develop more individualized therapies.

38
39 357
40
41 358 **ACKNOWLEDGEMENTS** The authors thank Christelle Damon-Soubeyrand (Anipath facility) for
42
43 359 her precious technical help with histological equipment.

44 360 45 361 **REFERENCES**

- 46 362 1. Key Statistics for Bone Cancer: Key Statistics About Bone Cancer. American Cancer Society
47 363 Web site. <https://www.cancer.org/cancer/bone-cancer/about/key-statistics.html>. Updated January
48 364 12, 2021. Accessed January 22, 2021.
- 49 365 2. World Health Organization WHO, Fletcher C, Bridge JA, Hogendoorn PCW, Mertens F. WHO
50 366 Classification of Tumours of Soft Tissue and Bone. In: WHO Classification of Tumours, vol. 5.
51 367 4th ed. World Health Organization; 2013. p 264-268.
- 52 368 3. Gelderblom H, Hogendoorn PCW, Dijkstra SD, et al. The clinical approach towards
53 369 chondrosarcoma. *Oncologist*. 2008;13(3):320-329.
- 54 370 4. Mery B, Espenel S, Guy J-B, et al. Biological aspects of chondrosarcoma: Leaps and hurdles.
55 371 *Crit Rev Oncol Hemat*. 2018;126.
- 56 372 5. Angelini A, Guerra G, Mavrogenis AF, Pala E, Picci P, Ruggieri P. Clinical outcome of central
57 373 conventional chondrosarcoma. *J Surg Oncol*. 2012;106(8):929-937.

- 1
2
3 374 6. van Oosterwijk JG, Anninga JK, Gelderblom H, Cleton-Jansen A-M, Bovée JVMG. Update on
4 375 targets and novel treatment options for high-grade osteosarcoma and chondrosarcoma. *Hematol*
5 376 *Oncol Clin North Am.* 2013;27(5):1021-1048.
- 6
7
8 377 7. Nazeri E, Gouran Savadkoochi M, Majidzadeh-A K, Esmaeili R. Chondrosarcoma: An overview
9 378 of clinical behavior, molecular mechanisms mediated drug resistance and potential therapeutic
10 379 targets. *Crit Rev Oncol Hematol.* 2018;131:102-109.
- 11
12
13 380 8. Yeldag G, Rice A, Del Río Hernández A. Chemoresistance and the self-maintaining tumor
14 381 microenvironment. *Cancers (Basel).* 2018;10(12):471.
- 15
16 382 9. Davies C de L, Berk DA, Pluen A, Jain RK. Comparison of IgG diffusion and extracellular
17 383 matrix composition in rhabdomyosarcomas grown in mice versus in vitro as spheroids reveals
18 384 the role of host stromal cells. *Br J Cancer.* 2002;86(10):1639-1644.
- 19
20 385 10. Trédan O, Galmarini CM, Patel K, Tannock IF. Drug resistance and the solid tumor
21 386 microenvironment. *J Natl Cancer Inst.* 2007;99(19):1441-1454.
- 22
23 387 11. Skeletal Lesions Interobserver Correlation among Expert Diagnosticians (SLICED) Study
24 388 Group. Reliability of histopathologic and radiologic grading of cartilaginous neoplasms in long
25 389 bones. *J Bone Joint Surg Am.* 2007;89(10):2113-2123.
- 26
27 390 12. Murphey MD, Walker EA, Wilson AJ, Kransdorf MJ, Temple HT, Gannon FH. From the
28 391 archives of the AFIP: imaging of primary chondrosarcoma: radiologic-pathologic correlation.
29 392 *Radiographics.* 2003;23(5):1245-1278.
- 30
31 393 13. Logie CI, Walker EA, Forsberg JA, Potter BK, Murphey MD. Chondrosarcoma: A diagnostic
32 394 imager's guide to decision making and patient management. *Semin Musculoskelet Radiol.*
33 395 2013;17(2):101-115.
- 34
35 396 14. Jo I, Gould D, Schlicht S, Taubman K, Choong P. Diagnostic accuracy of functional imaging
36 397 modalities for chondrosarcoma: A systematic review and meta-analysis. *J Bone Oncol.*
37 398 2019;19:100262.
- 38
39 399 15. Miot-Noirault E, Gouin F, Vidal A, et al. First preclinical imaging of primary cartilage neoplasm
40 400 and its local recurrence using 99mTc-NTP 15-5 radiotracer. *J Nucl Med.* 2009;50(9):1541-1547.
- 41
42 401 16. Peyrode C, Gouin F, Vidal A, et al. A "Proteoglycan targeting strategy" for the scintigraphic
43 402 imaging and monitoring of the swarm rat chondrosarcoma orthotopic model. *Sarcoma.*
44 403 2011;2011:691608.
- 45
46 404 17. Miot-Noirault E, Vidal A, Auzeloux P, Peyrode C, Madelmont J-C, Chezal J-M. In vivo
47 405 scintigraphic imaging of proteoglycans. *Methods Mol Biol.* 2012;836:183-198.
- 48
49 406 18. Rajendran JG, Mankoff DA, O'Sullivan F, et al. Hypoxia and glucose metabolism in malignant
50 407 tumors: Evaluation by [18F]Fluoromisonidazole and [18F]Fluorodeoxyglucose positron
51 408 emission tomography imaging. *Clin Cancer Res.* 2004;10(7):2245-2252.
- 52
53 409 19. Goldenberg JM, Pagel MD. Assessments of tumor metabolism with CEST MRI. *NMR Biomed.*
54 410 2019;32(10):e3943.

- 1
2
3 411 20. Jin T, Wang P, Zong X, Kim S-G. MR imaging of the Amide-Proton Transfer effect and the pH-
4 412 insensitive Nuclear Overhauser Effect at 9.4 T. *Magn Reson Med*. 2013;69(3):760-770.
5
6 413 21. Zhou Y, van Zijl PCM, Xu X, et al. Magnetic resonance imaging of glycogen using its magnetic
7 414 coupling with water. *Proc Natl Acad Sci USA*. 2020;117(6):3144-3149.
8
9 415 22. Jones KM, Pollard AC, Pagel MD. Clinical applications of chemical exchange saturation transfer
10 416 (CEST) MRI. *J Magn Reson Imaging*. 2018;47(1):11-27.
11
12 417 23. Kogan F, Hariharan H, Reddy R. Chemical Exchange Saturation Transfer (CEST) imaging:
13 418 Description of technique and potential clinical applications. *Curr Radiol Rep*. 2013;1(2):102-
14 419 114.
15
16 420 24. van Zijl PCM, Yadav NN. Chemical Exchange Saturation Transfer (CEST): what is in a name
17 421 and what isn't? *Magn Reson Med*. 2011;65(4):927-948.
18
19 422 25. Wu B, Warnock G, Zaiss M, et al. An overview of CEST MRI for non-MR physicists. *EJNMMI*
20 423 *Phys*. 2016;3(1):19.
21
22 424 26. Dou W, Lin C-YE, Ding H, et al. Chemical exchange saturation transfer magnetic resonance
23 425 imaging and its main and potential applications in pre-clinical and clinical studies. *Quant*
24 426 *Imaging Med Surg*. 2019;9(10):1747-1766.
25
26 427 27. Ling W, Regatte RR, Navon G, Jerschow A. Assessment of glycosaminoglycan concentration in
27 428 vivo by chemical exchange-dependent saturation transfer (gagCEST). *Proc Natl Acad Sci USA*.
28 429 2008;105(7):2266-2270.
29
30 430 28. Brinkhof S, Nizak R, Khlebnikov V, Prompers JJ, Klomp DWJ, Saris DBF. Detection of early
31 431 cartilage damage: feasibility and potential of gagCEST imaging at 7T. *Eur Radiol*.
32 432 2018;28(7):2874-2881.
33
34 433 29. Krusche-Mandl I, Schmitt B, Zak L, et al. Long-term results 8 years after autologous
35 434 osteochondral transplantation: 7 T gagCEST and sodium magnetic resonance imaging with
36 435 morphological and clinical correlation. *Osteoarthr Cartil*. 2012;20(5):357-363.
37
38 436 30. Krishnamoorthy G, Nanga RPR, Bagga P, Hariharan H, Reddy R. High Quality 3D gagCEST
39 437 Imaging of In Vivo Human Knee Cartilage at 7T. *Magn Reson Med*. 2017;77(5):1866-1873.
40
41 438 31. Wei W, Lambach B, Jia G, Kaeding C, Flanigan D, Knopp MV. A Phase I clinical trial of the
42 439 knee to assess the correlation of gagCEST MRI, delayed gadolinium-enhanced MRI of cartilage
43 440 and T2 mapping. *Eur J Radiol*. 2017;90:220-224.
44
45 441 32. Corbet C, Feron O. Tumour acidosis: from the passenger to the driver's seat. *Nat Rev Cancer*.
46 442 2017;17(10):577-593.
47
48 443 33. Chen LQ, Pagel MD. Evaluating pH in the extracellular tumor microenvironment using CEST
49 444 MRI and other imaging methods. *Adv Radiol*. 2015;2015:1-25.
50
51 445 34. Jin T, Wang P, Hitchens TK, Kim S-G. Enhancing sensitivity of pH-weighted MRI with
52 446 combination of amide and guanidyl CEST. *Neuroimage*. 2017;157:341-350.
53
54
55
56
57
58
59
60

- 1
2
3 447 35. Maloney E, Wang Y-N, Vohra R, et al. Magnetic resonance imaging biomarkers for pulsed
4 448 focused ultrasound treatment of pancreatic ductal adenocarcinoma. *World J Gastroenterol.*
5 449 2020;26(9):904-917.
6
7
8 450 36. Loi L, Zimmermann F, Goerke S, et al. Relaxation-compensated CEST (chemical exchange
9 451 saturation transfer) imaging in breast cancer diagnostics at 7T. *Eur J Radiol.* 2020;129:109068.
10
11 452 37. Kim M, Gillen J, Landman BA, Zhou J, van Zijl PCM. Water saturation shift referencing
12 453 (WASSR) for chemical exchange saturation transfer (CEST) experiments. *Magn Reson Med.*
13 454 2009;61(6):1441-1450.
14
15 455 38. Vidal A, Gaumet V, Galmier M-J, et al. Development of a freeze-dried kit formulation for the
16 456 preparation of ^{99m}Tc-NTP 15-5, a radiotracer for scintigraphic imaging of proteoglycans. *Appl*
17 457 *Radiat Isot.* 2015;101:1-9.
18
19 458 39. Zhou Z, Bez M, Tawackoli W, et al. Quantitative chemical exchange saturation transfer MRI of
20 459 intervertebral disc in a porcine model. *Magn Reson Med.* 2016;76(6):1677-1683.
21
22 460 40. Nasrallah FA, Pagès G, Kuchel PW, Golay X, Chuang K-H. Imaging brain deoxyglucose uptake
23 461 and metabolism by glucoCEST MRI. *J Cereb Blood Flow Metab.* 2013;33(8):1270-1278.
24
25 462 41. Zhou J, Heo H-Y, Knutsson L, van Zijl PCM, Jiang S. APT-Weighted MRI: techniques, current
26 463 neuro applications, and challenging issues. *J Magn Reson Imaging.* 2019;50(2):347-364.
27
28 464 42. Oskolkov N, Bar-Shir A, Chan KWY, et al. Biophysical characterization of human protamine-1
29 465 as a responsive CEST MR Contrast Agent. *ACS Macro Lett.* 2015;4(1):34-38.
30
31 466 43. Einarsson E, Peterson P, Önnérffjord P, et al. The role of cartilage glycosaminoglycan structure in
32 467 gagCEST. *NMR Biomed.* 2020;33(5):e4259.
33
34 468 44. Choi HU, Meyer K, Swarm R. Mucopolysaccharide and protein-polysaccharide of a
35 469 transplantable rat chondrosarcoma. *Proc Natl Acad Sci USA.* 1971;68(5):877-879.
36
37 470 45. Miot-Noirault E, Gouin F, Vidal A, et al. First preclinical imaging of primary cartilage neoplasm
38 471 and its local recurrence using ^{99m}Tc-NTP 15-5 radiotracer. *J Nucl Med.* 2009;50(9):1541-1547.
39
40 472 46. Walker-Samuel S, Ramasawmy R, Torrealdea F, et al. In vivo imaging of glucose uptake and
41 473 metabolism in tumors. *Nat Med.* 2013;19(8):1067-1072.
42
43 474 47. DeBrosse C, Nanga RPR, Bagga P, et al. Lactate Chemical Exchange Saturation Transfer
44 475 (LATEST) Imaging in vivo A Biomarker for LDH Activity. *Sci Rep.* 2016;6:19517.
45
46 476 48. Chiche J, Brahim-Horn MC, Pouysségur J. Tumour hypoxia induces a metabolic shift causing
47 477 acidosis: a common feature in cancer. *J Cell Mol Med.* 2010;14(4):771-794.
48
49 478 49. Schüre J, Shrestha M, Breuer S, et al. The pH sensitivity of APT-CEST using phosphorus
50 479 spectroscopy as a reference method. *NMR Biomed.* 2019;32(11).
51
52 480 50. Wang E, Wu Y, Cheung JS, et al. Mapping tissue pH in an experimental model of acute stroke -
53 481 Determination of graded regional tissue pH changes with non-invasive quantitative amide proton
54 482 transfer MRI. *Neuroimage.* 2019;191:610-617.
55
56
57
58
59
60

- 1
2
3 483 51. Krikken E, van der Kemp WJM, Khlebnikov V, et al. Contradiction between amide-CEST signal
4 484 and pH in breast cancer explained with metabolic MRI. *NMR Biomed.* 2019;32(8).
5
6 485 52. Schmidt H, Schwenzer NF, Gatidis S, et al. Systematic evaluation of amide proton Chemical
7 486 Exchange Saturation Transfer at 3 T: Effects of protein concentration, pH, and acquisition
8 487 parameters. *Invest Radiol.* 2016;51(10):635-646.
9
10 488 53. Liu G, Song X, Chan K W Y, McMahon MT. Nuts and bolts of chemical exchange saturation
11 489 transfer MRI. *NMR Biomed.* 2013;26(7):810-828.
12
13 490 54. Zhang X-Y, Wang F, Li H, et al. Accuracy in the quantification of chemical exchange saturation
14 491 transfer (CEST) and relayed nuclear Overhauser enhancement (rNOE) saturation transfer effects.
15 492 *NMR Biomed.* 2017;30(7):e3716.
16
17
18
19 493
20
21
22
23
24
25
26
27
28
29
30
31
32
33
34
35
36
37
38
39
40
41
42
43
44
45
46
47
48
49
50
51
52
53
54
55
56
57
58
59
60

For Peer Review

1
2
3 4944 495 **FIGURE CAPTIONS**

5 496

6 497 **FIGURE 1:** z-spectra of (A) chondroitin 4-sulfate and (C) protamine at several concentrations and pH,
7
8 498 respectively. The CEST effects were estimated by measuring the AUC from 0.02 to 1.50 ppm for
9 499 chondroitin 4-sulfate (GAG CEST) and the signal intensity at 1.96 and 3.60 for guanidyl* and APT*
10 500 CEST, respectively. The relationship between CEST quantification and concentrations or pH are
11 501 represented on panels (B) and (D), respectively.

12 502

13 503 **FIGURE 2:** In vivo multimodal imaging of GAGs in SRC bearing mice (A) GAG CEST parametric
14 504 image. To clearly identify the tumor, the high-resolution image was added inside the inset. (C) SPECT-
15 505 CT imaging with ^{99m}Tc-NTP 15-5. ROI quantitative analysis of GAG CEST and SPECT-CT are
16 506 presented in (B) and (D), respectively. (E) Ex vivo tumor slice (X20 magnification) stained with both
17 507 alcian blue and nuclear red. Data were presented by individual values with mean ± SD. Paired t-test and
18 508 unpaired t-test (**** $P < 0.0001$) were applied for in vivo and ex vivo quantifications, respectively. Red
19 509 data points on panels (B), (D) and (F) correspond to the images shown in (A), (C) and (E), respectively.
20 510 Abbreviations: T: Tumor; M: muscle.

21 511

22 512 **FIGURE 3:** In vivo multimodal imaging of pH acidification (MRI) and hypoxia (PET) in SRC bearing
23 513 mice. (A) High resolution and relative variation of APT*/guanidyl* ratio images for 3 representative
24 514 mice. (B) PET imaging with ¹⁸F-FMISO. ROI quantitative analysis of PET is presented in (C). (D) Ex
25 515 vivo tumor slice (X20 magnification) stained with pimonidazole and Hoechst. Data were presented by
26 516 individual values with mean ± SD. Paired t-test (* $P = 0.0164$) were applied for in vivo quantifications.
27 517 Red data points on panels (C) correspond to the image shown in (B). Abbreviations: T: Tumor; M:
28 518 muscle.

29 519

30 520
31
32
33
34
35
36
37
38
39
40
41
42
43
44
45
46
47
48
49
50
51
52
53
54
55
56
57
58
59
60

1
2
3 521 **SUPPORTING FIGURE AND TABLE CAPTIONS**
4
5 522

6 523 **Supporting Table S1:** Overview of the experimental design and analysis by *in vivo* modality.
7
8 524

9 525 **Supporting Figure S1:** Tumoral volumes measured by MRI at 15-16 days post-induction and presented
10 as individual values with mean \pm SD. Averaged volume $215.04 \pm 86.28 \text{ mm}^3$.
11 526
12 527

13
14 528 **Supporting Figure S2:** Representative data obtained *in vivo* for a ROI positioned in (blue) the tumor
15 and (red) the muscle. (A) Mean z-spectra for all animals; dotted lines represent \pm 1SD. (B) z-spectra of
16 529 a representative animal; dotted lines represent the linear baselines applied for guanidyl (from 1.66 to
17 530 2.30 ppm) and APT CEST (from 3.36 to 3.78 ppm) analyses. (C) Lorentzian fit of the GAG CEST from
18 531 the z-spectra shown in (B).
19 532
20 533

21
22
23 534 **Supporting Figure S3:** (A) $^{99\text{m}}\text{Tc}$ -NTP 15-5 SPECT-CT image of a representative animal. From left to
24 535 right: axial slice with tumor, coronal slice with tumor, coronal slice with radiotracer body dispersion
25 536 and sagittal slice with tumor and radiotracer body dispersion. The areas are annotated T for tumor, M
26 537 for muscle, B for bladder and Li for liver. (B) ^{18}F -FMISO PET image of a representative animal. From
27 538 left to right: axial slice with tumor, coronal and sagittal slices with tumor and radiotracer body
28 539 dispersion. The areas were annotated T for tumor, M for muscle, DT for digestive tract. Orientations
29 540 were annotated A for anterior, D for dorsal, L for left, P for posterior, R for right and V for ventral.
30
31
32
33
34
35
36
37
38
39
40
41
42
43
44
45
46
47
48
49
50
51
52
53
54
55
56
57
58
59
60

1
2
3 541 **ABBREVIATIONS**
4
5 542

6 543 APT: Amide proton transfer
7

8 544 AUC: Area under the curve
9

10 545 BSA: Bovine serum albumin
11

12 546 CHS: Chondrosarcoma
13

14 547 DMEM: Dulbecco's modified eagle medium
15

16 548 DWI: Diffusion-weighted imaging
17

18 549 ECM: Extracellular matrix
19

20 550 GAG: Glycosaminoglycan
21

22 551 HRP: Horseradish peroxidase
23

24 552 IVIA: In vivo imaging in Auvergne
25

26 553 MTC: Magnetization transfer contrast
27

28 554 MTR_{asym} : Magnetization transfer asymmetry
29

30 555 NOE: Nuclear overhauser enhancement
31

32 556 OSEM: Ordered subset expectation maximization
33

34 557 PBS: Phosphate-buffered saline
35

36 558 PG: Proteoglycan
37

38 559 RARE: Rapid acquisition with relaxation enhancement
39

40 560 ROI: Region of interest
41

42 561 SRC: Swarm rat chondrosarcoma
43

44 562 TSA: Tyramide signal amplification
45

46 563 WASSR: Water saturation shift reference
47

48 564
49

50 565
51
52
53
54
55
56
57
58
59
60

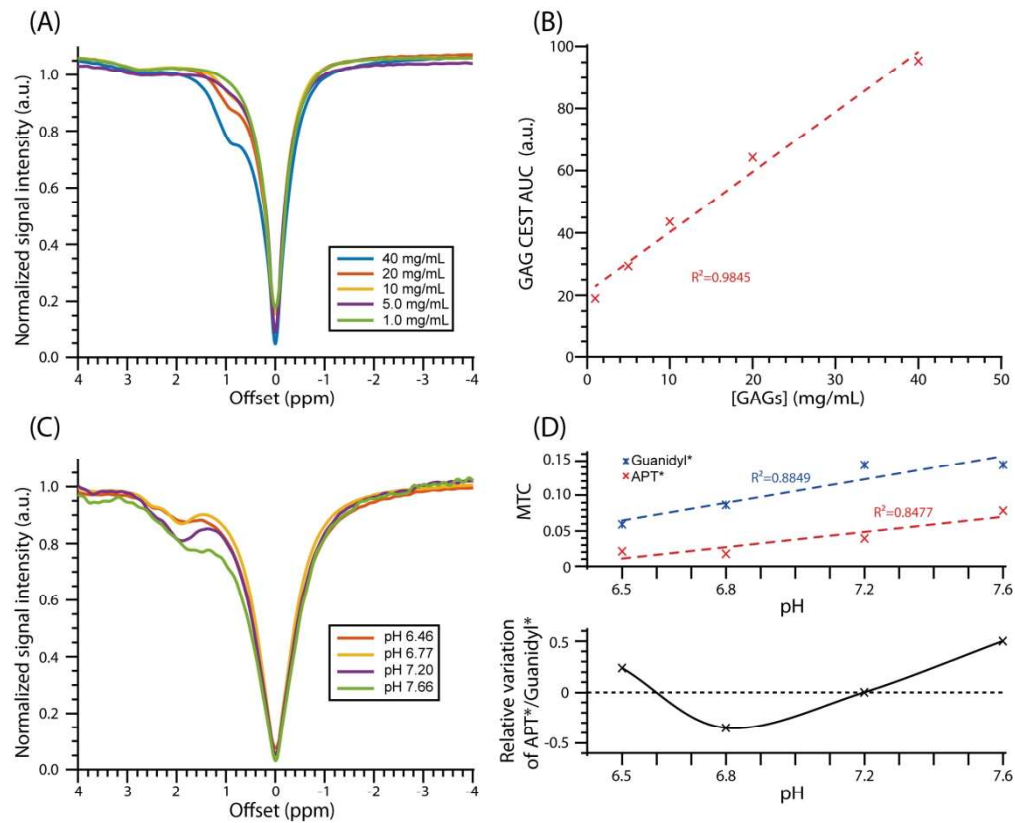


FIGURE 1: z-spectra of (A) chondroitin 4-sulfate and (C) protamine at several concentrations and pH, respectively. The CEST effects were estimated by measuring the AUC from 0.02 to 1.50 ppm for chondroitin 4-sulfate (GAG CEST) and the signal intensity at 1.96 and 3.60 for guanidyl* and APT* CEST, respectively. The relationship between CEST quantification and concentrations or pH are represented on panels (B) and (D), respectively.

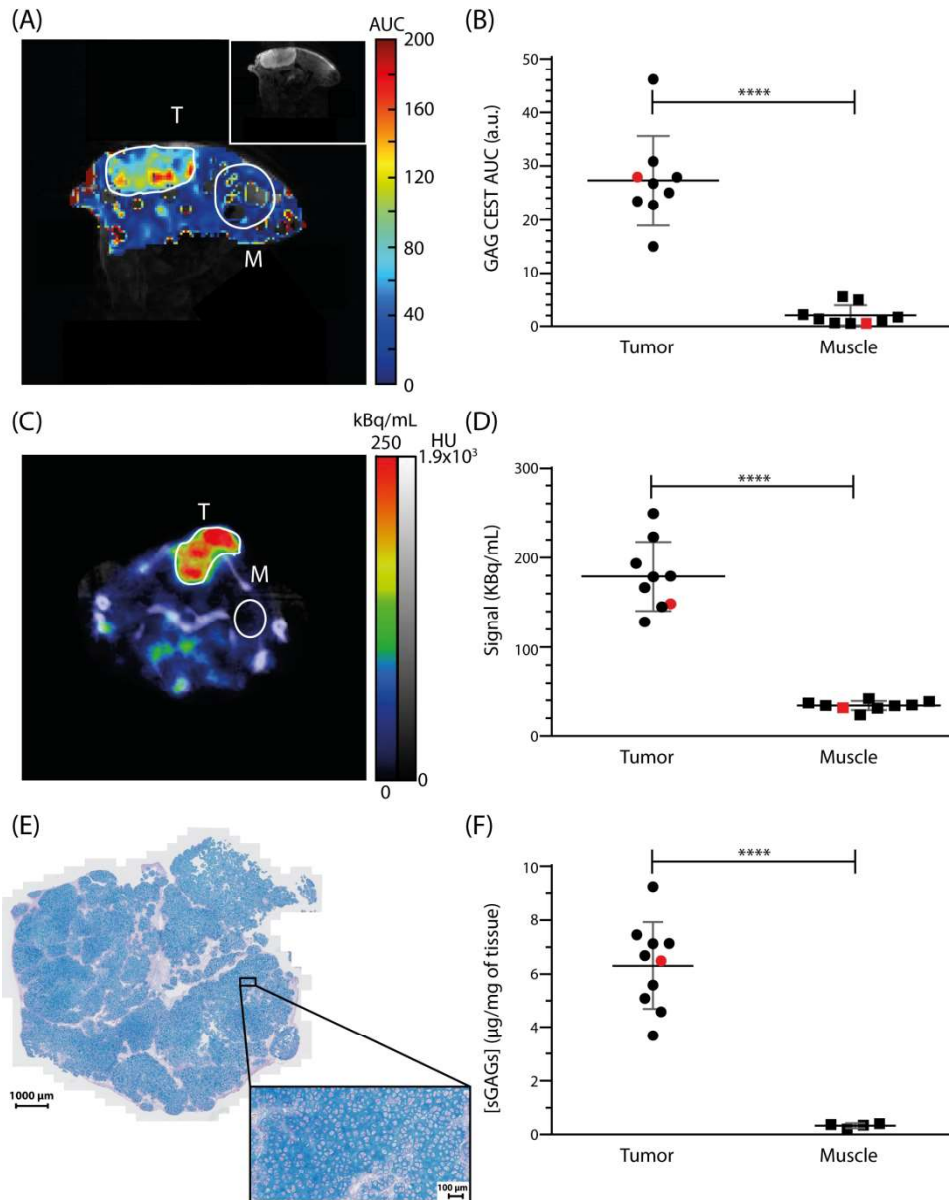
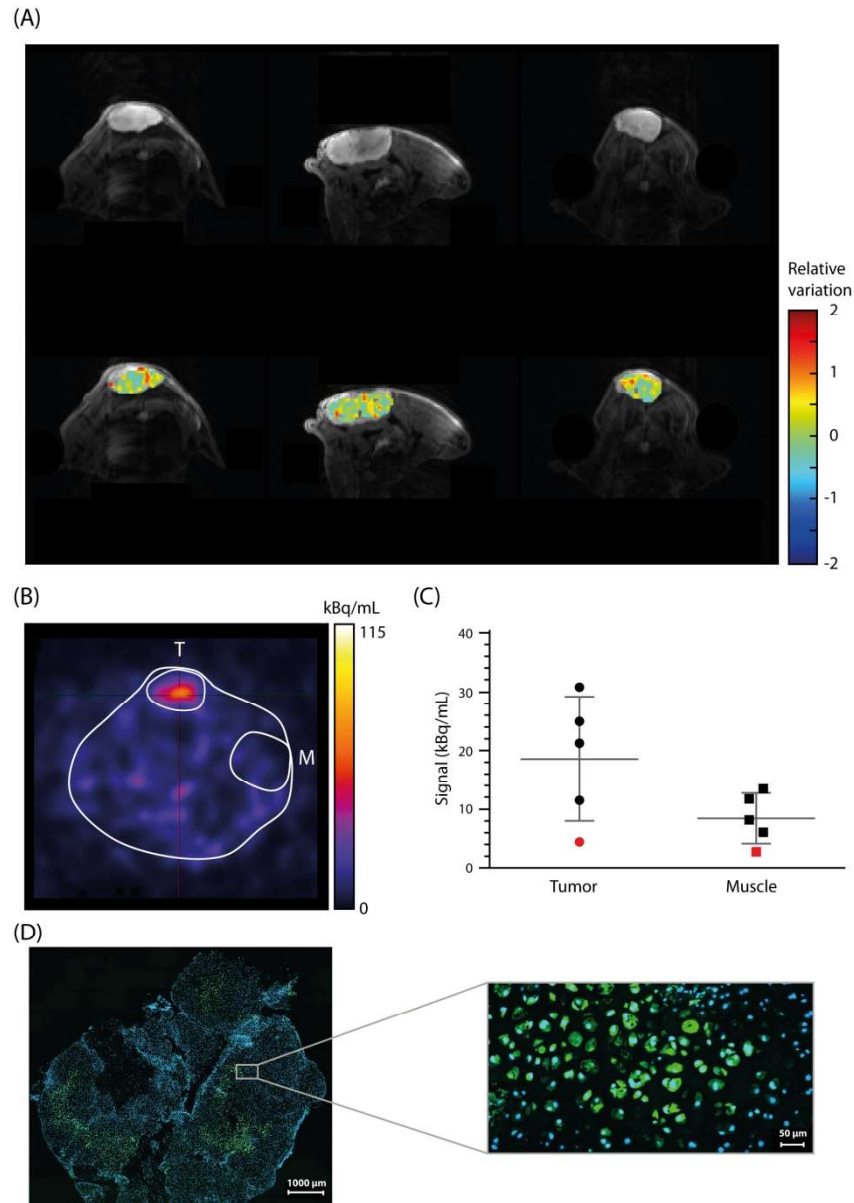


FIGURE 2: In vivo multimodal imaging of GAGs in SRC bearing mice (A) GAG CEST parametric image. To clearly identify the tumor, the high-resolution image was added inside the inset. (C) SPECT-CT imaging with ^{99m}Tc -NTP 15-5. ROI quantitative analysis of GAG CEST and SPECT-CT are presented in (B) and (D), respectively. (E) Ex vivo tumor slice (X20 magnification) stained with both alcian blue and nuclear red. Data were presented by individual values with mean \pm SD. Paired t-test and unpaired t-test (**** $P < 0.0001$) were applied for in vivo and ex vivo quantifications, respectively. Red data points on panels (B), (D) and (F) correspond to the images shown in (A), (C) and (E), respectively. Abbreviations: T: Tumor; M: muscle.



45 **FIGURE 3:** In vivo multimodal imaging of pH acidification (MRI) and hypoxia (PET) in SRC bearing mice. (A)
46 High resolution and relative variation of APT*/guanidyl* ratio images for 3 representative mice. (B) PET
47 imaging with ^{18}F -FMISO. ROI quantitative analysis of PET is presented in (C). (D) Ex vivo tumor slice (X20
48 magnification) stained with pimonidazole and Hoechst. Data were presented by individual values with mean
49 \pm SD. Paired t-test (* $P = 0.0164$) were applied for in vivo quantifications. Red data points on panels (C)
50 correspond to the image shown in (B). Abbreviations: T: Tumor; M: muscle.