



HAL
open science

Sacral hiatus corticosteroid injection in the management of radicular pain in adults

Solène Prost, Kaissar Farah, Simon Mazas, Sébastien Pesenti, Stéphane Fuentes, Patrick Tropiano, Jean-Marc Vital, Benjamin Blondel

► **To cite this version:**

Solène Prost, Kaissar Farah, Simon Mazas, Sébastien Pesenti, Stéphane Fuentes, et al.. Sacral hiatus corticosteroid injection in the management of radicular pain in adults. *Orthopaedics & Traumatology: Surgery & Research*, 2020, 106 (6), pp.1191-1193. 10.1016/j.otsr.2020.05.011 . hal-03187017

HAL Id: hal-03187017

<https://hal.science/hal-03187017>

Submitted on 16 Apr 2021

HAL is a multi-disciplinary open access archive for the deposit and dissemination of scientific research documents, whether they are published or not. The documents may come from teaching and research institutions in France or abroad, or from public or private research centers.

L'archive ouverte pluridisciplinaire **HAL**, est destinée au dépôt et à la diffusion de documents scientifiques de niveau recherche, publiés ou non, émanant des établissements d'enseignement et de recherche français ou étrangers, des laboratoires publics ou privés.

Sacral hiatus corticosteroid injection in the management of radicular pain in adults



Solène Prost^a, Kaissar Farah^a, Simon Mazas^b, Sébastien Pesenti^a, Stéphane Fuentes^a, Patrick Tropiano^a, Jean-Marc Vital^b, Benjamin Blondel^{a,*}

^a Aix-Marseille Université, AP-HM, CNRS, ISM, CHU Timone, Unité de chirurgie rachidienne, 264, rue Saint-Pierre, 13005 Marseille, France

^b Service d'orthopédie unité rachis, hôpital Pellegrin, CHU de Bordeaux, 33000 Bordeaux, France

ARTICLE INFO

Keywords:

Radicular pain
Epidural injection
Sacral hiatus

ABSTRACT

Radicular pain is a common reason for patients to consult at back pain clinics. While epidural steroid injections are widely done, some aspects are still controversial. The epidural space can be accessed via a transforaminal approach, an interlaminar route or by passing through the sacral hiatus. The aim of this article is to describe the epidural injection technique through the sacral hiatus that our team uses and to report our experience with it. Beyond the treatment effect, sacral hiatus corticosteroid injection can be useful as a diagnostic test or as an interim solution. Image-guided injection is recommended to ensure optimal positioning of the needle below S3. Sacral hiatus corticosteroid injection is a relevant alternative for treating lumbar radiculopathy in adults.

1. Introduction

Radicular pain is a very common reason for patients to consult at spine surgery clinics. Among the potential treatment options, epidural steroid injections are widely done, especially in the lumbar area to reduce the inflammation that may be causing the pain.

Several types of injections are feasible in the epidural space, although each has its advantages and disadvantages. A foraminal approach allows a small volume of corticosteroid to be injected as close as possible to the nerve root, while an interlaminar approach is preferred for bilateral conditions [1]. It is also possible to use a caudal approach to the epidural space through the sacral hiatus [2].

Results of sacral hiatus injections have been described for treating radicular pain attributed to the disc [3] or bone (stenosis) [4] and also for axial low back pain [5] with satisfactory results. The aim of this technical note is to describe our epidural injection technique through the sacral hiatus and to report our experience according to the cause of the radicular pain.

2. Anatomy of sacral hiatus

The sacrum consists of five fused vertebrae and is dorsally convex. The coccyx is made up of three to five rudimentary triangular

vertebrae, with the base fixed to the sacrum by the sacrococcygeal ligaments. The sacral hiatus is delimited laterally by the lateral sacral crests and is a natural opening in the junction of the dorsal midline making up the caudal end of the central spinal canal with opening on the epidural space.

Proximally, the sacral canal contains the termination of the dural sac, which varies in its level. However, some anatomical studies [6] have shown a termination across from S2 in 83% of cases, and according to Seroglu et al. [7] – who did an MRI study of 2669 patients – the dural sac finishes below S3 in less than 0.1% of cases.

3. Technique for sacral hiatus corticosteroid injection

The injection can be done blind, with fluoroscopy guidance or with ultrasound guidance. However, not doing an image-guided injection is associated with higher risk of failure and complications and cannot be recommended in practice.

Thus, the injection is typically done with fluoroscopy guidance with a patient in the prone position. Having the patient on his/her side with the hip flexed has also been described; it is relevant in patients with a large abdominal mass and could also increase the analgesic effect on radicular pain [8]. After local anesthesia, the epidural needle is inserted at a 45° angle to horizontal using a lateral fluoroscopy view (Fig. 1) until the hiatus opening. Once the needle has passed the sacrococcygeal ligament, it is gradually horizontalized and gently advanced until it reaches its final position (below S3), still under fluoroscopy guidance (Fig. 2). Before

* Corresponding author.

E-mail address: benjamin.blondel@ap-hm.fr (B. Blondel).

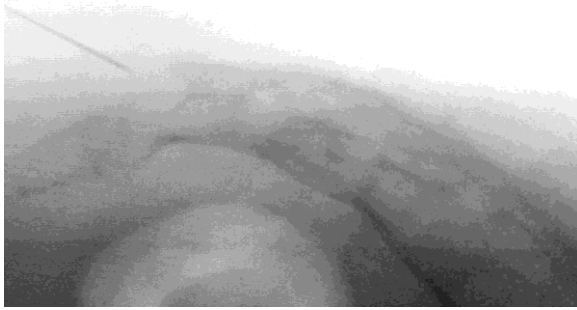

Fig. 1. Initial positioning of the needle at 45° relative to horizontal.

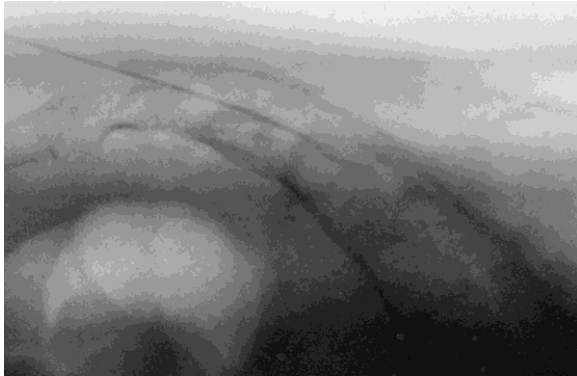


Fig. 2. Final position of the needle after horizontalization.

injecting the corticosteroid mixture, we pull back on the plunger to aspirate the needle and ensure the injection is not intravascular or intrathecal. After the injection, the patient is turned onto their back for cardiorespiratory monitoring.

4. Methods

A retrospective study was done of 62 patients. All underwent sacral hiatus corticosteroid injection to treat radicular pain related to lumbar spine disease. The patient assessment consisted of a clinical examination with MRI scan of the lumbar spine. All injections were done in the operating room, with strict aseptic procedures and lateral fluoroscopy views. Local anesthesia was done on the skin over the sacral hiatus using 1% lidocaine without adrenaline. In all cases, a 15 mL solution combining an ampule of triamcinolone acetonide (80 mg/2 mL) and saline was injected. No anesthetic agent was added to the injected solution. A switch was done in patients undergoing anticoagulant therapy, but not those receiving low-dose antiplatelet drugs (<160 mg/day).

Data analysis consisted of lumbar and radicular pain levels on visual analog scale (VAS) before the procedure, 1 month later and 1 year later. The results were compared relative to the cause of the radicular impingement with one subgroup having a disc origin and another group having a bone origin. All the patients were

Table 1
Change in mean lumbar pain (VAS-L) and radicular pain (VAS-R) over time.

Compression source		Initial	1 month	1 year	Comparison initial/1 month	Comparison initial/1 year	Comparison 1 month/1 year
Bone	VAS-L	6.7 SD = 1.8	5.2 SD = 2.5	4.7 SD = 2.6	0.002	< 0.001	0.204
	VAS-R	5.4 SD = 3.1	3.6 SD = 3.1	3.1 SD = 3.3	0.002	0.001	0.157
Disc	VAS-L	5.9 SD = 3.1	2.9 SD = 2.9	2.8 SD = 2.7	< 0.001	< 0.001	0.744
	VAS-R	6.9 SD = 2.2	3.1 SD = 2.7	2.4 SD = 2.7	< 0.001	< 0.001	0.208

Table 2

Comparison of mean lumbar pain (VAS-L) and radicular pain (VAS-R) by compression source.

		Bone compression	Disc compression	p-value
VAS-L	Initial	6.7 SD = 1.8	5.9 SD = 3.1	0.238
	1 month	5.2 SD = 2.5	2.9 SD = 2.9	0.002
	1 year	4.7 SD = 2.6	2.8 SD = 2.7	0.01
VAS-R	Initial	5.4 SD = 3.1	6.9 SD = 2.2	0.027
	1 month	3.6 SD = 3.1	3.1 SD = 2.7	0.437
	1 year	3.1 SD = 3.3	2.4 SD = 2.7	0.416

contacted by telephone 1 year after the procedure to inquire about their condition.

5. Results

Thirty-two women and 30 men with a mean age of 61 years [24–90] were included in the study: 24 had lumbar or radicular pain with a bone origin (canal stenosis) and 38 had pain due to a disc origin (herniated disc). In the entire cohort, the VAS-L and VAS-R were significantly lower (6.2 vs. 3.5, $p < 0.001$ and 6.6 vs. 3.3, $p < 0.001$, respectively) with stable results at 1 year of follow-up (Table 1). The sub-group analysis (Table 2) found the VAS-R was initially significantly higher in the disc compression group (6.9 vs. 5.4, $p = 0.027$) and the VAS-L was significantly lower at the final follow-up (2.8 vs. 4.7, $p = 0.01$). There were no injection-related complications. At the final review, 33% of patients with bone-related compression and 16% of patients with disc-related compression required surgical treatment.

6. Discussion

The role of corticosteroid injections in the treatment of radicular pain is still debated, although they are very widely used in daily practice. While the sacral hiatus approach is not the most common, it has certain advantages relative to other approaches. In fact, caudal entry into the epidural space is easy and the risk of incorrect needle placement is low for a trained surgeon, thus there is no need for contrast solution to be injected [9]. Furthermore, the risk of accidental dural puncture is low, and the injection is still feasible in patients who have previously undergone lumbar spine surgery [1]. According to Park et al. [10], the needle can be positioned just after passing by the sacrococcygeal ligament, which reduces the risk of intrathecal or intravascular injection with epidural filling and comparable results at 1-month follow-up.

The injection volume is larger than for a foraminal or interlaminar injection. This allows the product to diffuse, reaching the L2-L3 level (Fig. 3), which makes it useful when symptoms are more diffuse (multiple nerve roots or not well defined) [4,5], a scenario that is less well suited to the transforaminal approach.

The results of our study were better when treating disc-related radicular pain, which may also be related to the natural history of disc herniation. However, similar findings were reported by Manchikanti et al. [3] who added a local anesthetic to the corticosteroid being injected. We choose not to include a local anesthetic in the injection mixture; instead, we used a 15 mL volume combining triamcinolone acetonide with sterile saline. The choice not to inject

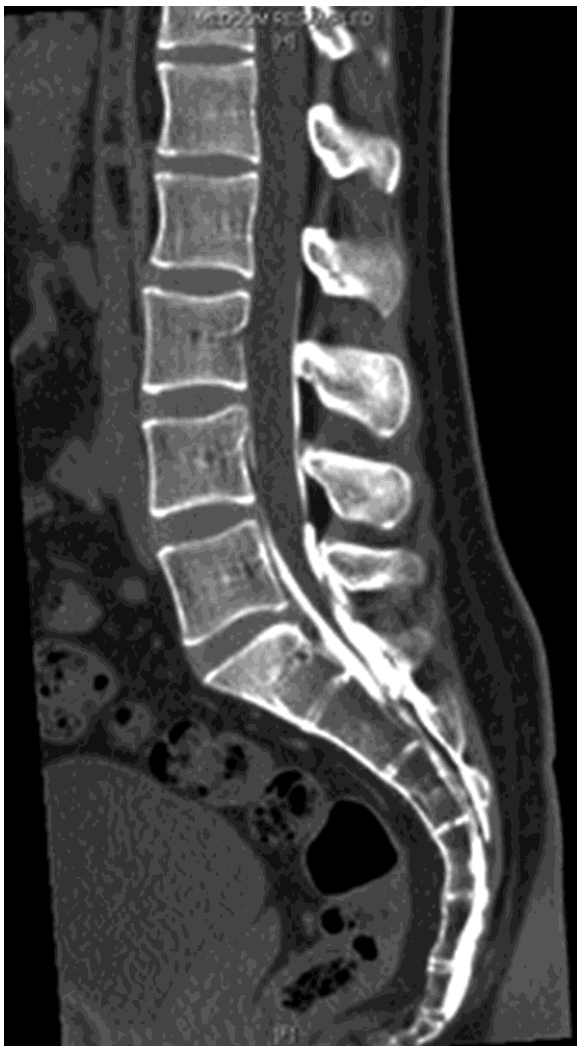

Fig. 3. Example of sacral hiatus corticosteroid injection with contrast solution; CT scan taken after the procedure (sagittal midline slice) showing diffusion toward the L2-L3 disc.

a local anesthetic is related to the two cases of severe complications (one paraplegia and one persistent cauda equina syndrome) attributed to use of local anesthetic [11,12]. Use of certain corticosteroids like triamcinolone acetonide can also be incriminated in the occurrence of serious adverse events, especially with accidental intravascular injection [1]. The triamcinolone acetonide used in this retrospective study was not associated with adverse events and has the benefit of prolonged efficacy. However, this product is not approved for use in this indication, thus caudal epidural injections must be done with prednisolone acetate [1].

More recently, ultrasound-guided injection in the sacral hiatus has been described. The advantage of using ultrasound is the ability to detect injection abnormalities or anatomical variations in the region of interest [13] and to improve the needle placement rate [14]. This would also eliminate the irradiation of the patient and surgeon, and is a reminder of the importance of radioprotective measures [15,16].

This study has its limitations, particularly its retrospective nature and the small number of patients analyzed. Nevertheless, our findings point to sacral hiatus corticosteroid injections being beneficial for treating lumbar radicular pain, especially in patients whose pain is due to disc herniation. Moreover, while the efficacy was not as good when the compression had a bone origin, the injection was still effective in most cases. For us, this is an indication

for sacral hiatus injection with a diagnostic goal and could also be an interim solution in patients who did not respond to surgical treatment.

7. Conclusion

Sacral hiatus corticosteroid injection is a relevant alternative for treating lumbar radiculopathy in adults. It is a low risk method that achieves a treatment effect in patients with lumbar pain having a disc or bone origin. This procedure is relevant as a diagnostic test or an interim treatment solution. Image-guided injection is recommended to ensure optimal positioning of the needle below S3. Additional studies will be required to confirm our findings.

Disclosure of interest

The authors declare that they have no competing interest.

Funding

None.

Author contributions

S. Prost, S. Pesenti, K. Farah, S. Mazas and B. Blondel wrote the manuscript.

S. Fuentes, J.-M. Vital and P. Tropiano provided critical review of the manuscript.

References

- [1] Cotten A, Drapé J-L, Sans N, Feydy A, Bartoli J-M, Meder J-F. Recommendations de la SIMS, SFR et FRI-SFR concernant les corticoïdes injectés en épidual et foraminaux; 2017.
- [2] Sharma PK. Indications, technique and results of caudal epidural injection for lumbar disc retropulsion. *Postgrad Med J* 1977;53:1-6.
- [3] Manchikanti L, Singh V, Cash KA, Pampati V, Damron KS, Boswell MV. A randomized, controlled, double-blind trial of fluoroscopic caudal epidural injections in the treatment of lumbar disc herniation and radiculitis. *Spine* 2011;36:1897-905.
- [4] Manchikanti L, Cash KA, McManus CD, Pampati V, Fellows B. Results of 2-year follow-up of a randomized, double-blind, controlled trial of fluoroscopic caudal epidural injections in central spinal stenosis. *Pain Phys* 2012;15:371-84.
- [5] Manchikanti L, Pampati V, Benyamin RM, Boswell MV. Analysis of efficacy differences between caudal and lumbar interlaminar epidural injections in chronic lumbar axial discogenic pain: local anesthetic alone vs. local combined with steroids. *Int J Med Sci* 2015;12:214-22.
- [6] Aggarwal A, Kaur H, Batra YK, Aggarwal AK, Rajeev S, Sahni D. Anatomic consideration of caudal epidural space: a cadaver study. *Clin Anat* 2009;22:730-7.
- [7] Senoglu N, Senoglu M, Ozkan F, Kesilmez C, Kızıldag B, Celik M. The level of termination of the dural sac by MRI and its clinical relevance in caudal epidural block in adults. *Surg Radiol Anat* 2013;35:579-84.
- [8] Makki D, Nawabi DH, Francis R, Hamed AR, Hussein AA. Is the outcome of caudal epidural injections affected by patient positioning? *Spine* 2010;35:E687-90.
- [9] Naidoo K, Alazzawi S, Montgomery A. The use of contrast in caudal epidural injections under image intensifier guidance: is it necessary? *Clin Orthop Surg* 2017;9:190-2.
- [10] Park SJ, Yoon KB, Shin DA, Kim K, Kim TL, Kim SH. Influence of needle-insertion depth on epidural spread and clinical outcomes in caudal epidural injections: a randomized clinical trial. *J Pain Res* 2018;11:2961-7.
- [11] Seo YT, Kong HH, Lee GJ, Bang HJ. Persistent cauda equina syndrome after caudal epidural injection under severe spinal stenosis: a case report. *J Pain Res* 2017;10:1425-9.
- [12] Somanchi BV, Mohammad S, Ross R. An unusual complication following caudal epidural steroid injection: a case report. *Acta Orthop Belg* 2008;74:720-2.
- [13] Kim DH, Park JH, Lee SC. Ultrasonographic evaluation of anatomic variations in the sacral hiatus: implications for caudal epidural injections. *Spine* 2016;41:E759-63.
- [14] Ahiskalioglu A, Yayik AM, Ahiskalioglu EO, Ekinci M, Göbboyu BE, Celik EC, et al. Ultrasound-guided versus conventional injection for caudal block in children: a prospective randomized clinical study. *J Clin Anesth* 2018;44:91-6.
- [15] Kim S-J, Lee MH, Lee S-W, Chung HW, Lee SH, Shin MJ. Radiation exposure for fluoroscopy-guided lumbosacral epidural steroid injections: comparison of the transforaminal and caudal approaches. *J Spinal Disord Tech* 2014;27:E37-40.
- [16] Kao S-C, Lin C-S. Caudal epidural block: an updated review of anatomy and techniques. *BioMed Res Int* 2017;2017:9217145.