



**HAL**  
open science

## **Does static trunk motion analysis reflect its true position during daily activities in adolescent with idiopathic scoliosis?**

Sébastien Pesenti, Solène Prost, Vincent Pomeroy, Guillaume Authier, Lionel Roscigni, Elke Viehweger, Benjamin Blondel, Jean-Luc Jouve

### ► **To cite this version:**

Sébastien Pesenti, Solène Prost, Vincent Pomeroy, Guillaume Authier, Lionel Roscigni, et al.. Does static trunk motion analysis reflect its true position during daily activities in adolescent with idiopathic scoliosis?. *Orthopaedics & Traumatology: Surgery & Research*, 2020, 106 (7), pp.1251-1256. <10.1016/j.otsr.2019.12.023>. <hal-03187009>

**HAL Id: hal-03187009**

**<https://hal.science/hal-03187009v1>**

Submitted on 16 Apr 2021

**HAL** is a multi-disciplinary open access archive for the deposit and dissemination of scientific research documents, whether they are published or not. The documents may come from teaching and research institutions in France or abroad, or from public or private research centers.

L'archive ouverte pluridisciplinaire **HAL**, est destinée au dépôt et à la diffusion de documents scientifiques de niveau recherche, publiés ou non, émanant des établissements d'enseignement et de recherche français ou étrangers, des laboratoires publics ou privés.



HAL Authorization

# Does static trunk motion analysis reflect its true position during daily activities in adolescent with idiopathic scoliosis?



Sébastien Pesenti<sup>a,b,c,\*</sup>, Solène Prost<sup>a,b,c</sup>, Vincent Pomeroy<sup>a,b</sup>, Guillaume Authier<sup>a,b</sup>, Lionel Roscigni<sup>a,b</sup>, Elke Viehweger<sup>a,b,c</sup>, Benjamin Blondel<sup>a,b,c</sup>, Jean-Luc Jouve<sup>a,b</sup>

<sup>a</sup> Orthopédie infantile, hôpital d'enfants de la Timone, Aix-Marseille université, 264, rue Saint-Pierre, 13005 Marseille, France

<sup>b</sup> Plateforme d'analyse de la motricité, hôpital de la Timone, Aix-Marseille université, Marseille, France

<sup>c</sup> Orthopédie infantile, CNRS, ISM, Aix-Marseille université, hôpital de la Timone, AP-HM, Marseille, France

## ARTICLE INFO

### Keywords:

Adolescent idiopathic scoliosis  
Sagittal balance  
Spine alignment  
Motion analysis  
Dynamic  
Static

## ABSTRACT

**Introduction:** Adolescent idiopathic scoliosis is common condition in pediatric orthopedics that is generally analyzed with standard radiographs. However, the conditions under which the radiographs are made are completely different than the position that patients use during day-to-day activities. We hypothesized that the trunk's static position differs from its dynamic one. The aim of this study was to determine differences between the trunk's static and dynamic positions using motion analysis in adolescents with idiopathic scoliosis.

**Patients and methods:** This prospective, single-center study enrolled adolescents with idiopathic scoliosis who were scheduled to undergo surgical correction. The day before the surgery, radiographs were made and motion analysis was performed (static and dynamic acquisitions). Various parameters were measured on the radiographs and motion analysis, including the coronal vertical axis (CVA), sagittal vertical axis (SVA) and coronal shoulder tilt.

**Results:** The study enrolled 62 patients with a mean age of 15.5 years. There was a significant correlation between the radiographic measurements and the static motion analysis results for most parameters. Conversely, dynamic measurements of CVA, SVA and coronal shoulder tilt were not correlated to their static measurements ( $R = 0.229$ ;  $0.198$  and  $-0.109$  respectively, all  $p > 0.05$ ). The static coronal shoulder tilt was opposite to the one found during walking ( $-0.9^\circ$  vs.  $0.5^\circ$ ,  $p = 0.031$ ).

**Discussion:** Our study is the first to compare the trunk's static position with its dynamic position during walking in a cohort of adolescents with idiopathic scoliosis. Motion analysis provides new information about the trunk's dynamic positions. Based on our findings, radiographic analysis only partially captures the spinal alignment and cannot be used to draw reliable conclusions about the trunk's dynamic balance.

## 1. Introduction

Adolescent idiopathic scoliosis is common condition encountered in pediatric orthopedics affecting 2% to 3% of the pediatric population [1]. This spinal deformity is defined by the presence of vertebral rotation. The rotational deformity leads to spinal deviation in the frontal plane and often alters its sagittal curves [2]. Idiopathic scoliosis is often associated with adolescence, with a potential for major progression during the growth spurt associated

with puberty. Thus it is crucial to diagnose it, and if needed, treat it during this period [3,4].

When using standard radiographic analysis tools, it is not surprising to see that, despite the local deformities in the three planes in space, patients with scoliosis rarely have overall trunk alignment problems. The sagittal alignment, often analyzed using the sagittal vertical axis (SVA) parameter, is rarely described as pathological in these patients [2]. The overall frontal plane alignment is determined using the coronal vertical axis (CVA), which is also deviated only when a considerable lumbar curve is present [5]. However, no study up to now had sought to explore the validity of analyzing the spine's overall alignment on radiographs in a controlled environment and constrained position. Under these conditions, it is highly unlikely the spine's position on radiographs truly reflects the trunk's overall position during activities of daily living.

\* Corresponding author. Orthopédie infantile, hôpital d'enfants de la Timone, Aix-Marseille université, 264, rue Saint-Pierre, 13005 Marseille, France.

E-mail address: [Seb.pesenti@gmail.com](mailto:Seb.pesenti@gmail.com) (S. Pesenti).

Over the past 30 years, more modern analysis tools have been introduced, for example motion analysis [6,7]. Initially used in neuro-orthopedics, its application has been expanded into orthopedic disorders in general, for example hip and knee arthroplasty [8]. Several authors have shown that trunk motion analysis is feasible [9,10]. This tool can be used to analyze the trunk's position during walking. Several protocols have been described to capture the trunk's motion during gait. Ranavolo et al. reported that nine or ten markers were needed on the back to describe the spine's position with motion analysis. In 2012, our team developed a protocol to accurately analyze the trunk's kinematics and kinetics using only six markers on the back placed over C7, T7, T9, T12, L3 and S1 [11,12]. We showed the parameters measured with this protocol are significantly correlated with radiographic parameters [13]. One of the advantages of motion analysis is that it can capture dynamic information (during walking) while also being able to capture static information, comparable to radiographic analysis [13]. With motion analysis, several authors have reported abnormal gait patterns in patients with idiopathic scoliosis; in particular, the trunk is turned to the left during the entire gait cycle [14–16]. This casts doubt on the analysis of overall trunk alignment performed on radiographs.

We hypothesized that overall trunk alignment in a static position does not reflect the spine's dynamic posture during walking. The aim of this study was to determine differences between the trunk's static and dynamic positions using motion analysis in adolescents with idiopathic scoliosis.

## 2. Patients and methods

### 2.1. Study population

After having gained approval from our hospital's research ethics board, we conducted a prospective study. Between January 2014 and December 2017, adolescent patients with idiopathic scoliosis who were scheduled for corrective surgery at our hospital were enrolled. The patients' consent and that of their parents or guardians was obtained before enrollment. The inclusion criteria were (1) idiopathic scoliosis in adolescent or juvenile 3 (diagnosis after 9 years of age) and (2) indication for surgical correction. At our hospital, an indication for surgical correction is made when the Cobb angle is more than 45° in thoracic curvatures (Lenke 1, 2 and 3) and 35° in lumbar or thoracolumbar curvatures (Lenke 5 and 6). Patients with a history of major orthopedic or trauma of the lower limbs, history of spine surgery, or lumbosacral transitional vertebrae were excluded from the study.

### 2.2. Protocol

The day before the surgery, radiographs of the entire spine were made with the patient standing. At our hospital, motion analysis is an element of our standard care protocol. Reflective markers were placed on the patient according to the Plug-in-Gait protocol, supplemented by six markers used to capture the spine's motion (Fig. 1) [11–13]. While three different researchers were involved in marker placement, each was experienced with the protocol. The analysis platform consisted of six high-resolution infrared cameras capturing data at 100 Hz. A static acquisition was made in which the patient was asked to stand motionless in a comfortable position for 2 seconds. Next, dynamic acquisition was performed in which the patient was asked to walk barefoot and at a comfortable speed in a straight line on a 9 m walkway. The mean of four trials was calculated to analyze the position of each marker during the gait cycle.

### 2.3. Parameters evaluated

The radiographs were analyzed using a semi-automated method with spine-specific analysis software (Surgimap, Globus Medical, NY, United States). On AP view, the thoracic and lumbar Cobb angles, coronal shoulder and pelvis tilt and CVA were measured. On the lateral view, the thoracic kyphosis (T4–T12), lumbar lordosis (L1–S1), sagittal pelvic tilt and SVA were measured. The patients' scoliosis was graded using the classification system described by Lenke et al. [17].

Multiple parameters were measured with motion analysis (Fig. 2). The frontal plane parameters were the thoracic Cobb angle (defined as the angle between a line passing through the C7 and T7 markers and a line passing through the T9 and T12 markers in the frontal plane), the lumbar Cobb angle (defined as the angle between a line passing through the T12 and L3, and the L3 and S1 markers in the frontal plane), the coronal shoulder and pelvis tilt, and the CVA. In the sagittal plane, the thoracic kyphosis (defined as the angle between the line passing through the C7 and T7 markers and the line passing through the T9 and T12 markers in the sagittal plane), the lumbar lordosis (defined as the angle between lines passing through the T12 and L3, and L3 and S1 markers in the sagittal plane), the sagittal pelvic tilt and the SVA were measured. Lastly, in the transverse plane, we measured the shoulder line rotation (bi-acromial line vs. perpendicular to the walking progression axis), the pelvic rotation (line joining the anterosuperior iliac spines vs. perpendicular to the walking progression axis) and the acromion-pelvis angle (APA).

### 2.4. Statistical analysis

The results are presented as mean values (standard deviation) and minimum/maximum. The motion analysis parameters were measured in each phase of the gait cycle. When looking for correlations, the mean values of each dynamic parameter was used. Pearson correlation coefficients were used to analyze the relationship between the radiographic parameters and the static and dynamic parameters measured with motion analysis. Mean values were compared using Student's *t* test for paired samples when the data were distributed normally. If not, a Wilcoxon test was used. A *p* value of less than 0.05 was considered statistically significant.

## 3. Results

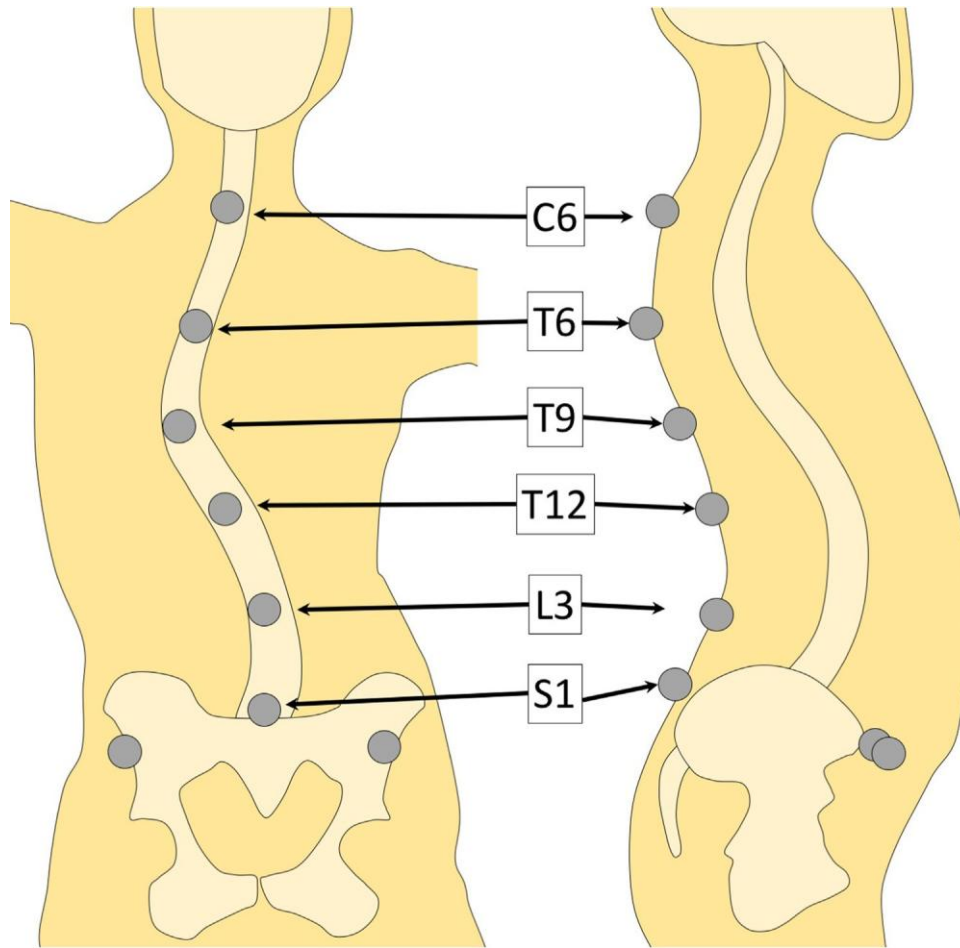
### 3.1. Study population

In all, 62 patients were enrolled in the study. There were 54 girls and 8 boys with a mean age of 15.5 years  $\pm$  2.1; 11.8 to 21.4 years). In these patients, 44 curvatures were classified as Lenke 1 (71%), 5 as Lenke 2 (8%), 1 as Lenke 3 (2%) and 12 Lenke 5 (19%). The radiographic parameters and their correlation with static motion analysis data are summarized in Table 1. Other than the lumbar Cobb angle, all the radiographic parameters were significantly correlated with their equivalent parameter measured with motion analysis in a static position.

### 3.2. Correlations between radiographic parameters and motion analysis findings

Correlations between the radiographic parameters and the parameters measured with dynamic motion analysis are listed in Table 2. There was no significant relationship between radiographs and dynamic motion analysis for the coronal shoulder and pelvic tilt, lumbar Cobb angle and SVA.

The correlations and comparisons between the means of the static and dynamic motion analysis parameters are summarized in



**Fig. 1.** Drawing of the marker locations used for motion analysis of the spine.

Table 3 and Fig. 3. In the transverse plane, all parameters behaved the same during the static and dynamic analysis. Thus, the static position during radiographic acquisition in the transverse plane reflects the static position during motion analysis. Of note, the shoulders and pelvis were angled significantly more to the left in the dynamic analysis than the static one (respectively  $-3.2^\circ$  vs.  $-5.5^\circ$ ,  $p < 0.001$  and  $2.3^\circ$  vs.  $1.1^\circ$ ,  $p = 0.017$ ). Logically, the APA was the same statically and dynamically ( $6.0^\circ$  vs.  $6.2^\circ$ ,  $p = 0.312$ ).

In the frontal plane, the coronal shoulder tilt during walking was opposite to the angle measured statically (left shoulder lower in static position) ( $-0.9^\circ$  vs.  $0.5^\circ$ ,  $p = 0.031$ ). Moreover, the dynamic coronal shoulder tilt was independent of the static coronal shoulder tilt ( $R = -0.109$ ,  $p = 0.455$ ). As for the overall alignment of the trunk in the frontal plane (CVA), the static and dynamic values were not correlated ( $0.8$  vs.  $1.2$  mm,  $p = 0.546$  and  $R = 0.229$ ,  $p = 0.073$ ).

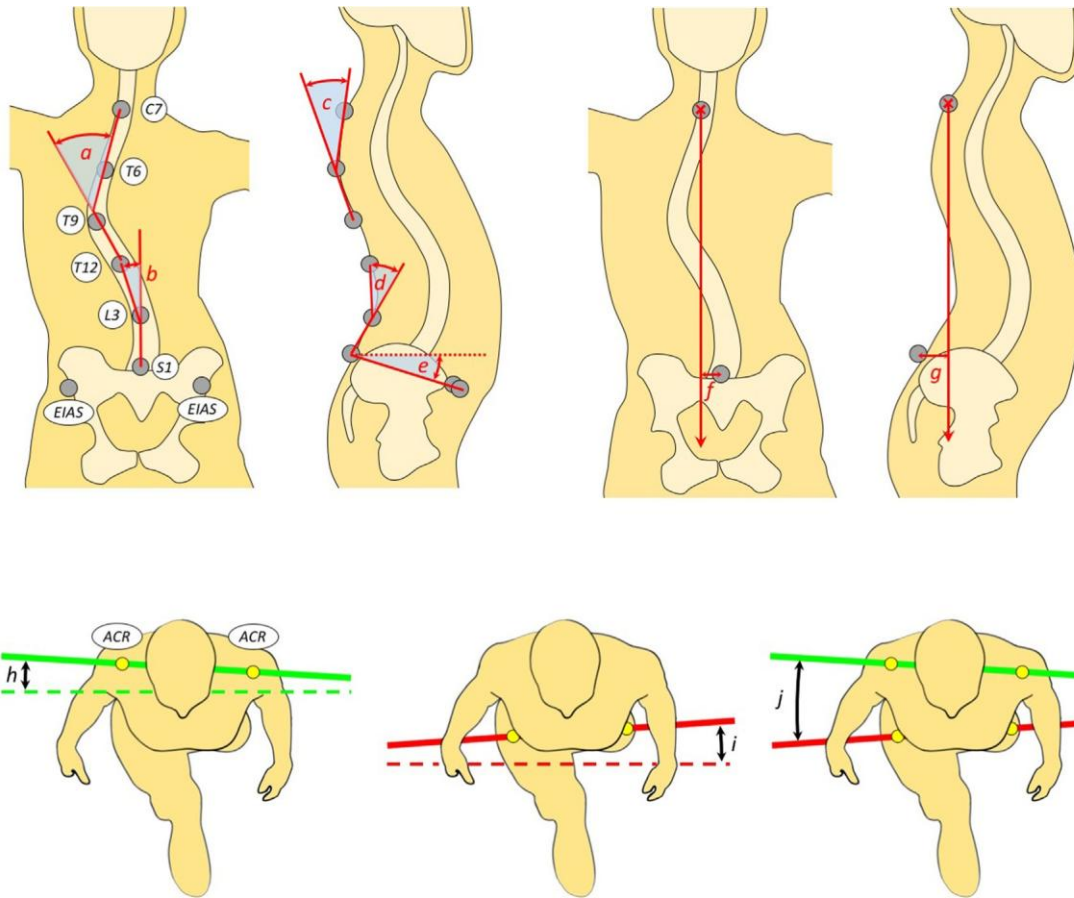
Lastly, in the sagittal plane during walking, the lumbar lordosis decreased ( $21.1^\circ$  vs.  $18.8^\circ$ ,  $p < 0.001$ ) and the thoracic kyphosis increased ( $26.5^\circ$  vs.  $28.4^\circ$ ,  $p = 0.023$ ) with the pelvis tending towards retroversion ( $11.7^\circ$  vs.  $9.9^\circ$ ,  $p < 0.001$ ). The SVA increased significantly, reflecting the fact that the trunk is projected forward during walking ( $5.4$  vs.  $43.6$  mm,  $p < 0.001$ ). The static and dynamic SVA were not correlated, thus the SVA value during walking was independent of the SVA measured statically ( $R = 0.198$ ,  $p = 0.122$ ).

#### 4. Discussion

This is the first study to compare the trunk's static position with its dynamic posture in adolescents with idiopathic scoliosis. Our hypothesis was confirmed, since the trunk's static position was

different than its dynamic one in this population. In fact, the parameters used to analyze the trunk's overall alignment (CVA and SVA) were unrelated in the static and dynamic analyses. This means that static analysis of these parameters based on radiographs is incomplete and does not reflect the trunk's position during activities of daily living. Thus our findings highlight the difference between spinal alignment – which is a static parameter – and spinal balance, which is a dynamic one [18]. Thus, it is risky to draw conclusion about an overall spine alignment defect and its consequences based on standard radiographs. These findings suggest that motion analysis supplement the typical radiographic analysis and could be integrated into the patient's pre- and postoperative evaluation. Of course, it is not very likely that motion analysis, in its current form, will replace radiographic analysis of spinal deformity. However, our findings show that motion analysis captures the dynamic movements of the spine and supplements the information derived from static radiographs.

One of the interesting findings was the inversion of the coronal shoulder tilt. Statically, patients had their left shoulder lower, whereas it was higher during walking. This cast doubt on the analysis of overall trunk balance based on coronal shoulder tilt, which is considered as a major goal of surgical correction of spinal deformities in adolescent idiopathic scoliosis [19]. In fact, the shoulder tilt during walking is different and independent than the one in a static position. This means it is difficult to predict the behavior of the shoulders during walking based on standard radiographs. It would be interesting to transpose this same analysis to the postoperative period and use it to determine the effect of spinal fusion on shoulder position during walking.



**Fig. 2.** Method used to measure the various motion analysis parameters a: thoracic Cobb angle; b: lumbar Cobb angle; c: thoracic kyphosis; d: lumbar lordosis; e: pelvic tilt; f: CVA; g: SVA; h: shoulder line rotation; i: pelvis rotation; j: acromion pelvis angle (APA). ACR: acromion. EIAS: anterosuperior iliac spine.

**Table 1**  
Radiographic and static motion analysis data in adolescents with idiopathic scoliosis.

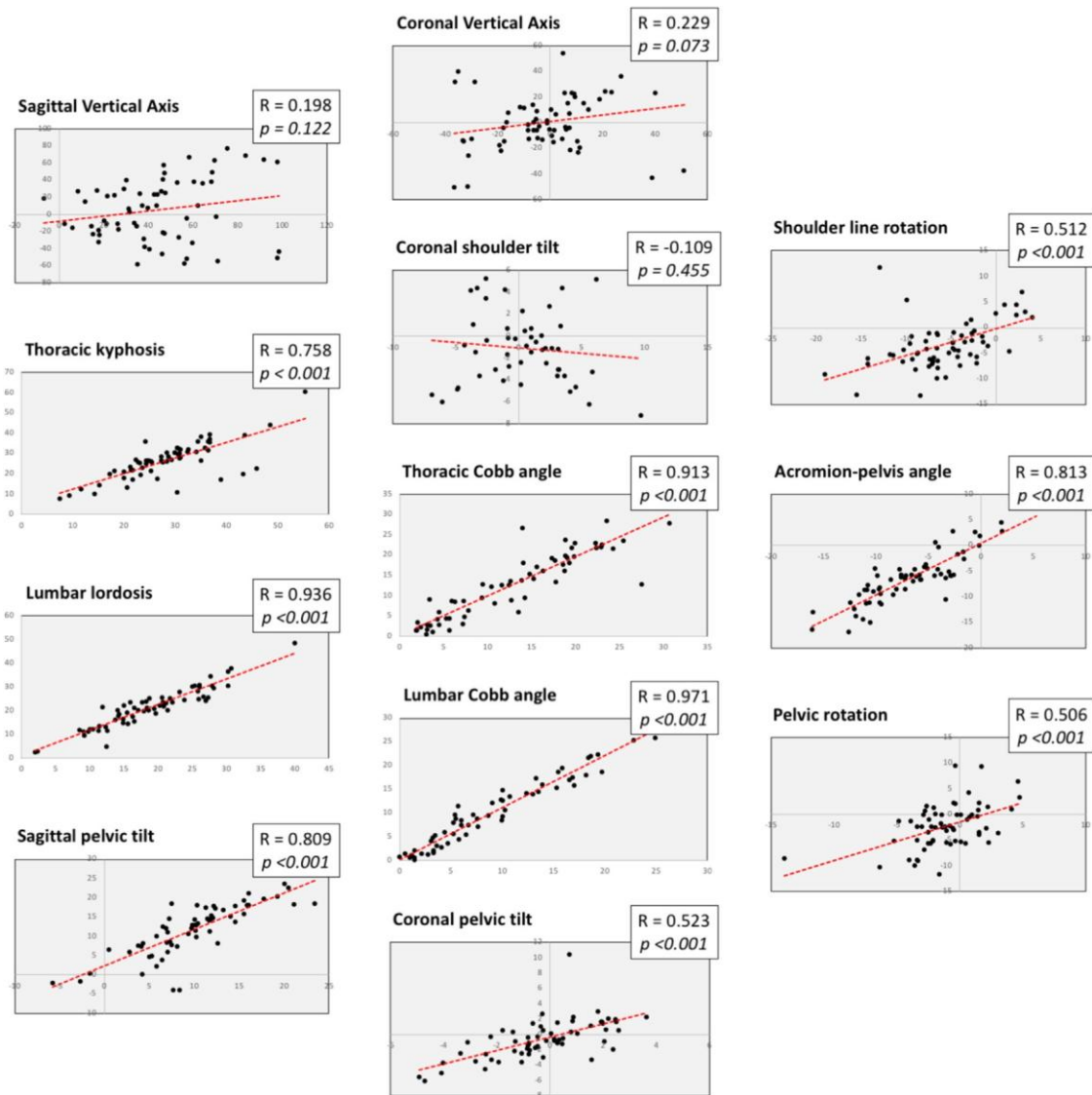
|                             | Radiographs |      | Static motion analysis |      | Correlation coefficient R | R <sup>2</sup> | p       |
|-----------------------------|-------------|------|------------------------|------|---------------------------|----------------|---------|
|                             | Mean        | SD   | Mean                   | SD   |                           |                |         |
| Coronal vertical axis (mm)  | 3.0         | 18.7 | 0.8                    | 21.9 | 0.350                     | 12%            | 0.005   |
| Coronal shoulder tilt       | -1.5        | 3.1  | -0.9                   | 3.3  | 0.512                     | 26%            | < 0.001 |
| Coronal pelvic tilt         | 0.5         | 2.2  | -0.6                   | 2.55 | 0.395                     | 16%            | 0.005   |
| Thoracic Cobb angle         | 48.0        | 15.8 | 13.1                   | 8.6  | 0.579                     | 33%            | < 0.001 |
| Lumbar Cobb angle           | 35.7        | 10.5 | 9.9                    | 7.4  | -0.201                    | 4%             | 0.118   |
| Sagittal vertical axis (mm) | 14.8        | 21.8 | 5.4                    | 36.1 | 0.252                     | 6%             | 0.048   |
| Thoracic kyphosis           | 19.6        | 11.6 | 26.5                   | 9.1  | 0.574                     | 33%            | < 0.001 |
| Lumbar lordosis             | 50.4        | 12.3 | 21.2                   | 8.5  | 0.441                     | 19%            | < 0.001 |
| Sagittal Pelvic tilt        | 6.5         | 8.3  | 11.7                   | 6.6  | -0.351                    | 12%            | 0.005   |

The correlations are given in the last 3 columns. SD: standard deviation.

**Table 2**  
Correlations between radiographic and dynamic motion analysis data in adolescents with idiopathic scoliosis.

| Parameter             | Radiographs | Dynamic motion analysis | Correlation coefficient R | R <sup>2</sup> | p       |
|-----------------------|-------------|-------------------------|---------------------------|----------------|---------|
| CVA                   | 3.0         | -1.18                   | 0.617                     | 38%            | < 0.001 |
| Coronal shoulder tilt | -1.5        | 0.5                     | -0.114                    | 1%             | 0.437   |
| Coronal pelvic tilt   | 0.5         | -0.3                    | 0.198                     | 4%             | 0.172   |
| Thoracic Cobb angle   | 48.0        | 13.4                    | 0.502                     | 25%            | < 0.001 |
| Lumbar Cobb angle     | 35.7        | 8.9                     | -0.207                    | 4%             | 0.107   |
| SVA                   | 14.8        | 43.6                    | 0.224                     | 5%             | 0.118   |
| Thoracic kyphosis     | 19.6        | 28.4                    | 0.594                     | 35%            | < 0.001 |
| Lumbar lordosis       | 50.4        | 18.8                    | 0.417                     | 17%            | < 0.001 |
| Sagittal Pelvic tilt  | 6.5         | 9.9                     | -0.316                    | 10%            | 0.012   |

CVA: coronal vertical axis; SVA: sagittal vertical axis.



**Fig. 3.** Correlation between motion analysis parameters measured statically and dynamically. The dynamic SVA, CVA and coronal shoulder tilt were not correlated to their static measurements.

**Table 3**  
Correlation between motion analysis parameters measured statically and dynamically.

| Parameter             | Static | Dynamic | Comparison of means | Correlation coefficient R | R <sup>2</sup> | p       |
|-----------------------|--------|---------|---------------------|---------------------------|----------------|---------|
| APA                   | -6.4   | -6.7    | 0.312               | 0.873                     | 76%            | < 0.001 |
| Shoulder rotation     | -3.2   | -5.5    | < 0.001             | 0.512                     | 26%            | 0.001   |
| Pelvis rotation       | 2.3    | 1.1     | 0.017               | 0.506                     | 26%            | < 0.001 |
| CVA                   | 0.8    | -1.2    | 0.546               | 0.229                     | 5%             | 0.073   |
| Coronal shoulder tilt | -0.9   | 0.5     | 0.031               | -0.109                    | 1%             | 0.455   |
| Coronal pelvic tilt   | -0.6   | -0.3    | 0.186               | 0.523                     | 27%            | < 0.001 |
| Thoracic Cobb angle   | 13.1   | 13.4    | 0.583               | 0.913                     | 83%            | < 0.001 |
| Lumbar Cobb angle     | 9.9    | 8.9     | < 0.001             | 0.971                     | 94%            | < 0.001 |
| SVA                   | 5.4    | 43.6    | < 0.001             | 0.198                     | 4%             | 0.122   |
| Thoracic kyphosis     | 26.5   | 28.4    | 0.023               | 0.758                     | 57%            | < 0.001 |
| Lumbar lordosis       | 21.1   | 18.8    | < 0.001             | 0.956                     | 91%            | < 0.001 |
| Sagittal Pelvic tilt  | 11.7   | 9.9     | < 0.001             | 0.809                     | 65%            | < 0.001 |

APA: acromion-pelvis angle; CVA: coronal vertical axis; SVA: sagittal vertical axis.

We found a good correlation between most of the radiographic parameters and the static motion analysis parameters. This confirms our team's previously published findings [13] and shows that motion analysis can be used to describe the same parameters measured on radiographs. This is especially true for the overall trunk balance parameters. We also found asymmetry in the transverse plane, with the trunk generally turned to the left, as previously

reported in the literature [1,14,15]. This asymmetry in the transverse plane is more pronounced in patients with idiopathic scoliosis and is likely one of the specific features of patients with the disorder.

Our findings can also be used to describe the alterations in trunk position in the sagittal plane during walking. In fact, walking requires the trunk to be projected forward (increased SVA).

This movement appeared to be initiated by the upper portion of the trunk, with overall flexion of the spine (increased thoracic kyphosis and reduced lumbar lordosis). Conversely, there is pelvic retroversion associated with these mechanisms. Studies in normal populations could help to specify the mechanics used to alter spinal posture during walking.

Given this new information, motion analysis could be used to obtain new information in several cases. In fact, it could help to identify compensatory mechanisms for static balance that would be apparent with motion analysis. Moreover, dynamic analysis of the trunk could improve our understanding of the factors that influence the natural history of idiopathic scoliosis during growth and afterwards. Lastly, evaluating dynamic posture could be key element for understanding certain biomechanical complications related to spinal fusion, such as the occurrence of proximal or distal junctional kyphosis; it is currently hard to determine which factors cause this complication based on simple radiographic analysis [20].

This study has certain limitations. Despite the large number of patients enrolled, we could not perform a subgroup analysis based on the location of the curvature, mainly because thoracic curvatures were over-represented in our cohort. It would have been interesting to compare the changes in spinal alignment during walking based on where the scoliotic curvature is located.

## 5. Conclusion

This preliminary study comparing static trunk alignment to its dynamic posture revealed fundamental differences. Based on our findings, radiographic analysis provides limited information because of how it is performed, especially when it comes to analyzing the spine's overall alignment. Motion analysis can be used to improve our understanding of spinal deformity mechanisms and the effect of intervertebral fusion on spine function. We showed that the trunk's position changes during walking; a study on normal subjects would help to specify the mechanisms.

## Disclosure of interest

The authors declare that they have no competing interest.

## Funding

No funding was received to support of this work.

## Author contribution

Each co-author contributed equally to this work

## References

- [1] Kramers-de Quervain IA, Müller R, Stacoff A, Grob D, Stüssi E. Gait analysis in patients with idiopathic scoliosis. *Eur Spine J* 2004;13:449–56.
- [2] Abelin-Genevois K, Sassi D, Verdun S, Roussouly P. Sagittal classification in adolescent idiopathic scoliosis: original description and therapeutic implications. *Eur Spine J* 2018;27:2192–202.
- [3] Weinstein SL, Dolan LA, Cheng JCY, Danielsson A, Morcuende JA. Adolescent idiopathic scoliosis. *Lancet (London, England)* 2008;371:1527–37.
- [4] Danielsson AJ, Nachemson AL. Radiologic findings and curve progression 22 years after treatment for adolescent idiopathic scoliosis: comparison of brace and surgical treatment with matching control group of straight individuals. *Spine (Phila Pa 1976)* 2001;26:516–25.
- [5] Márkus I, Schlégl ÁT, Burkus M, József K, Niklai B, Than P, et al. The effect of coronal decompensation on the biomechanical parameters in lower limbs in adolescent idiopathic scoliosis. *Orthop Traumatol Surg Res* 2018;104:609–16.
- [6] Gage JR. Gait analysis for decision-making in cerebral palsy. *Bull Hosp Jt Dis Orthop Inst* 1983;43:147–63.
- [7] Riley PO, Paolini G, Della Croce U, Paylo KW, Kerrigan DC. A kinematic and kinetic comparison of overground and treadmill walking in healthy subjects. *Gait Posture* 2007;26:17–24.
- [8] Ollivier M, Parratte S, Lunebourg A, Viehweger E, Argenson J-N. The John Insall Award: no functional benefit after unicompartmental knee arthroplasty performed with patient-specific instrumentation: a randomized trial. *Clin Orthop Relat Res* 2016;474:60–8.
- [9] Negrini S, Piovaneli B, Amici C, Cappellini V, Bovi G, Ferrarin M, et al. Trunk motion analysis: a systematic review from a clinical and methodological perspective. *Eur J Phys Rehabil Med* 2016;52:583–92.
- [10] Konz RJ, Fatone S, Stine RL, Ganju A, Gard SA, Ondra SL. A kinematic model to assess spinal motion during walking. *Spine (Phila Pa 1976)* 2006;31:E898–906.
- [11] Blondel B, Pomero V, Moal B, Lafage V, Jouve JL, Tropiano P, et al. Sagittal spine posture assessment: feasibility of a protocol based on intersegmental moments. *Orthop Traumatol Surg Res* 2012;98:109–13.
- [12] Blondel B, Viehweger E, Moal B, Tropiano P, Jouve J-L, Lafage V, et al. Postural spinal balance defined by net intersegmental moments: results of a biomechanical approach and experimental errors measurement. *World J Orthop* 2015;6:983–90.
- [13] Pesenti S, Prost S, Blondel B, Pomero V, Severyns M, Roscigni L, et al. Correlations linking static quantitative gait analysis parameters to radiographic parameters in adolescent idiopathic scoliosis. *Orthop Traumatol Surg Res* 2019, <http://dx.doi.org/10.1016/j.otsr.2018.09.024>.
- [14] Pesenti S, Prost S, Pomero V, Authier G, Severyns M, Viehweger E, et al. Characterization of trunk motion in adolescents with right thoracic idiopathic scoliosis. *Eur Spine J* 2019;28:2025–33.
- [15] Patel A, Pivec R, Shah NV, Leven DM, Margalit A, Day LM, et al. Motion analysis in the axial plane after realignment surgery for adolescent idiopathic scoliosis. *Gait Posture* 2018;66:181–8.
- [16] Nishida M, Nagura T, Fujita N, Nakamura M, Matsumoto M, Watanabe K. Spinal correction surgery improves asymmetrical trunk kinematics during gait in adolescent idiopathic scoliosis with thoracic major curve. *Eur Spine J* 2019;28:619–26.
- [17] Lenke LG. Lenke classification system of adolescent idiopathic scoliosis: treatment recommendations. *Instr Course Lect* 2005;54:537–42.
- [18] Diebo BG, Varghese JJ, Lafage R, Schwab FJ, Lafage V. Sagittal alignment of the spine: what do you need to know? *Clin Neurol Neurosurg* 2015;139:295–301.
- [19] Yang H, Im GH, Hu B, Wang L, Zhou C, Liu L, et al. Shoulder balance in Lenke type 2 adolescent idiopathic scoliosis: should we fuse to the second thoracic vertebra? *Clin Neurol Neurosurg* 2017;163:156–62.
- [20] Zhong J, Cao K, Wang B, Li H, Zhou X, Xu X, et al. Incidence and risk factors for proximal junctional kyphosis in adolescent idiopathic scoliosis after correction surgery: a meta-analysis. *World Neurosurg* 2019, <http://dx.doi.org/10.1016/j.wneu.2019.01.072>.