



**HAL**  
open science

## Oral care of a patient with a SAPHO syndrome and a nickel allergy

Sophie-Caroline Campana, Thibault Canceill, Rémi Esclassan

► **To cite this version:**

Sophie-Caroline Campana, Thibault Canceill, Rémi Esclassan. Oral care of a patient with a SAPHO syndrome and a nickel allergy. *Special Care in Dentistry*, 2019, 39 (2), pp.231-235. 10.1111/scd.12362 . hal-03184448

**HAL Id: hal-03184448**

**<https://hal.science/hal-03184448>**

Submitted on 29 Mar 2021

**HAL** is a multi-disciplinary open access archive for the deposit and dissemination of scientific research documents, whether they are published or not. The documents may come from teaching and research institutions in France or abroad, or from public or private research centers.

L'archive ouverte pluridisciplinaire **HAL**, est destinée au dépôt et à la diffusion de documents scientifiques de niveau recherche, publiés ou non, émanant des établissements d'enseignement et de recherche français ou étrangers, des laboratoires publics ou privés.




## Open Archive Toulouse Archive Ouverte (OATAO)

OATAO is an open access repository that collects the work of Toulouse researchers and makes it freely available over the web where possible

This is an author's version published in: <http://oatao.univ-toulouse.fr/27626>


**Official URL:** <https://doi.org/10.1111/scd.12362>

**To cite this version:**

Campana, Sophie-Caroline and Canceill, Thibault  and Esclassan, Rémi *Oral care of a patient with a SAPHO syndrome and a nickel allergy*. (2019) *Special Care in Dentistry*, 39 (2). 231-235. ISSN 0275-1879

Any correspondence concerning this service should be sent to the repository administrator: [tech-oatao@listes-diff.inp-toulouse.fr](mailto:tech-oatao@listes-diff.inp-toulouse.fr)

# Oral care of a patient with a SAPHO syndrome and a nickel allergy

Sophie-Caroline Campana<sup>1</sup> | Thibault Canceill DDS<sup>1,2</sup>  | Rémi Esclassan DDS<sup>1,3</sup>

<sup>1</sup>Dental Faculty of Toulouse, Université Paul Sabatier, Hôpitaux de Toulouse, Toulouse Cedex 9, France

<sup>2</sup>CIRIMAT, University of Toulouse, CNRS, INPT, UPS, PPB Team, Université Paul Sabatier, Faculté de Pharmacie, Toulouse Cedex 9, France

<sup>3</sup>Laboratoire AMIS UMR 5288 CNRS, Toulouse, France

## Correspondence

Thibault Canceill, Dental Faculty, Toulouse University Hospital, Paul Sabatier University, UFR Odontologie 3, chemin des Maraîchers 31062 Toulouse Cedex 9, France.  
Email: thibault.canceill@sfr.fr

Sophie-Caroline Campana and Thibault Canceill contributed equally to this work.

## Abstract

SAPHO is an acronym for Synovitis, Acne, Pustulosis, Hyperostosis and Osteitis. The syndrome is difficult to diagnose because it may present many different manifestations in adults and children. Its origin is still unknown, although some infectious, genetic and immune hypotheses have been put forward. We report the case of a 49-year-old woman with SAPHO syndrome, who developed a serious cutaneous allergy following the insertion of a removable partial denture (RPD). The oral care and treatment of this patient are described.

## KEYWORDS

nickel allergy, prosthesis, SAPHO syndrome

## 1 | INTRODUCTION

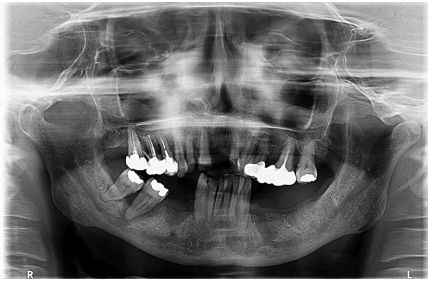
SAPHO syndrome (SAPHO is an acronym for Synovitis, Acne, Pustulosis, Hyperostosis, Osteitis) is a poorly known disease, classified as rare with a prevalence close to 1/10 000.<sup>1–3</sup> It was long considered as a spondylarthrosis because of the spinal manifestations but the association with other symptoms led to a distinction being made between the two diseases.<sup>4</sup>

It was first reported in the late 1980s by Chamot et al who defined some diagnosis criteria for this syndrome at the time.<sup>5–7</sup> The syndrome brings together inflammatory osteitis, osteoarticular features, hyperostosis, and skin manifestations such as severe acne or palmoplantar pustulosis.<sup>1,8</sup> Peripheral arthritis and synovitis are also noted in a third of patients<sup>8</sup> and, in others, cutaneous reactions can resemble. It is often noted that skin features occur before osseous ones but there are strong variations among patients and skin manifestations can also appear later in the evolution of the syndrome.<sup>9</sup> Back pain and anterior chest wall (sternum, clavicle, sternocostoclavicular) involvement<sup>5,8,10</sup> are typical early presentations<sup>1</sup> and considered main diagnostic criteria and distinguished from other types of pathologies (osteitis, spondyloarthritis, or

osteosclerotic metastases of breast cancers).<sup>9–11</sup> Differential diagnosis is complicated by the multiplicity of symptoms and the strong variations in their occurrence.<sup>1,8,12</sup> All of these symptoms of chronic intense pain can affect the patient's quality of life<sup>13</sup> and are associated with a 7.5% risk of depressive episodes.<sup>14</sup> Osseous manifestations explain why scintigraphy and magnetic resonance imaging are commonly used to establish or confirm the diagnosis.<sup>15–17</sup>

The general management of SAPHO syndrome is empirical and the long-term prognosis has not been established.<sup>14</sup> Bisphosphonates are commonly used against osteomyelitis and osteitis<sup>18,19</sup> but they are not efficient in every case and many reports have been published on other treatments attempted in the absence of response to bisphosphonates, such as anti-IL1, Janus kinase inhibitor or, recently, TNF blockers.<sup>1,12,20,21</sup> However, no therapy has demonstrated an effect in all patients and remission may be only partial, with disappearance of skin symptoms but persistence of bone lesions.<sup>21</sup>

Oral manifestations of SAPHO syndrome predominantly concern mandibular osteomyelitis<sup>22–27</sup> but some necrosis may also occur due to dental surgery in concomitance with the administration of bisphosphonate treatments. However, the mandible is affected by osseous manifestations in only 10%



**FIGURE 1** Panoramic radiograph performed during patient's first visit to the dental unit

of cases,<sup>8,22</sup> that is, less often than the anterior chest wall or spine.<sup>1</sup>

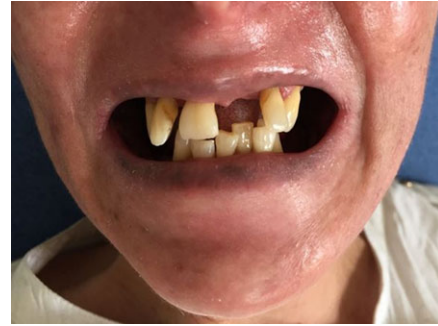In this context, the aim of this case report is to describe the oral care of a SAPHO patient who suffered a sudden allergy after the insertion of a metal removable partial denture (RPD).

## 2 | CASE REPORT

A 49-year-old woman with SAPHO syndrome came to the dental unit of Toulouse Hospital because of acute dental pain and for aesthetic considerations. Because of her long dental history, she “wanted *“to have all her teeth extracted.”* At this time, she had never had a RPD and never reported any allergy.

Her SAPHO syndrome had been discovered some years previously after a work-related accident when she was working as a nurse. She experienced severe pain on attempting to lift a patient and therefore underwent a medical examination including radiography. The diagnosis was based on the full body and long bone radiographs and the concomitant severe back and articular pain. During the first consultation in the dental unit, a medical check-up revealed osteoarticular degeneration, peripheral arthritis and massive cutaneous involvements. The patient was not treated with bisphosphonates but only with anti-inflammatory (Ketoprofen), antalgic (Tramadol, Gabapentin), and psychotropic medicines (Hydroxyzine, Zopiclone). Ketoprofen is commonly used for the symptomatic long-term treatment of chronic inflammatory rheumatism, and Gabapentin may be prescribed not only for its analgesic properties but also its propensity to reduce epileptic and spasmodic seizures. During an oral examination, generalized chronic periodontitis was observed with mobilities and bleeding on probing. A panoramic radiograph confirmed the diminution of the alveolar bone level and the presence of foci of infection, especially on teeth 47 and 48 (Figure 1). The radiograph showed no evidence of osteoarticular degeneration in the jaws and is consistent with the low incidence in the reported in the literature.<sup>22</sup>

All molars exhibited severe periodontitis and the decision was rendered to extract them at this time, owing in part, to the absence of bisphosphonate intake. General anaesthesia was



**FIGURE 2** Perioral eczema observed a few weeks after hypersensitive reaction to nickel contained in prosthesis clasps

preferred because her general osteoarticular pain, joint pain in the temporomandibular articulation and mouth opening limitation made it difficult for the woman to lie down and to keep her mouth open for a long time. Her daily treatment was not modified for the surgery but antibiotics (amoxicillin and clavulanic acid, 7 days) and mouthwashes (chlorhexidine digluconate 0.12%, 10 days) were also prescribed. The patient was happy to brush her teeth with a postsurgical toothbrush and preferred fluid and soft food for a few days. To accustom her to wearing the prosthesis, it was decided not to remove all the teeth at first but to keep teeth 11, 12, 13, 22, 23, 31, 32, 33, 41, 42, and 43. Therefore, two RPDs were made, which would be transformed into complete removable dentures later.

Unfortunately, 3 days after the placing of the first elements, the patient presented severe cutaneous reactions of the face and throat and mucogingival erythema on the palatal and vestibular gingiva under the devices (Figure 2). The dermatology clinician's report (Toulouse Rangueil Hospital, Toulouse, France) described “*a very oedematous perioral eczema with throat diffusion.*” An allergist examined the patient and concluded on a “*possible hypersensitivity reaction.*” The patch test performed revealed an exacerbated nickel-sulphate response at 72 hours (Figure 3). The allergist established a link between the cutaneous reaction and the materials used to make the clasps of the prostheses (nickel, iron, chromium, and molybdenum). Also, the laboratory's prosthesis identification card confirmed that the metal was a quaternary alloy (Figure 4).

The patient's daily treatment was modified by the addition of sterile water and dermal corticoids to apply to the cutaneous reaction. Then, the decision was taken in accordance with the patient to cut all clasps and to speed up the care procedures, which meant extracting the remaining teeth without giving the patient the possibility of a testing period with the RPD. A second general anaesthesia was not performed because the woman's general health was less degraded at the time of the second surgery and also because all teeth to be extracted were mobile and located in the anterior sector, so it was not necessary for her to open her mouth wide. Mouthwashes and advice on food were again given to the patient.

Résultat des Tests effectués							
Batterie	Allergènes	à 20 mn	à 48 H	à 72 H	à J4	à J7	Ultérieur
1 STANDARD EUROPEENNE ELARGIE	Bichromate de Potassium						
2	P-PHENYLENEDIAMINE						
3	Thiuram-mix						
4	Néomycine						
5	Chlorure de cobalt						
6	Benzocaïne						
7	Sulfate de Nickel			+		+++	

FIGURE 3 Cutaneous test report revealing the hypersensitivity reaction to nickel sulfate at 72 hours

Libelle	Type	Teinte
1 303789 proth amovible resine 8 dents	Aucune	
Matière	Catégorie	Classification
Dents du commerce Métal le Cr ni mo Résine	Dents Alliages Cosmétiques	CoCr Résine

FIGURE 4 Extract from the identification card of the prosthesis, confirming the presence of nickel in the composition

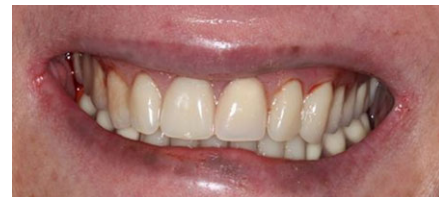

FIGURE 6 Two complete removable prostheses were inserted after tooth extractions

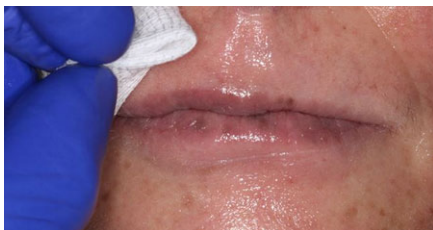

FIGURE 5 Application of sterilized petroleum jelly body lotion to skin irritations during dental care

an appointment and she was satisfied with the aesthetic result, fulfilling her initial motivation to seek care (Figures 6 and 7). In addition, the patient began transition into a more normal diet.

### 3 | DISCUSSION

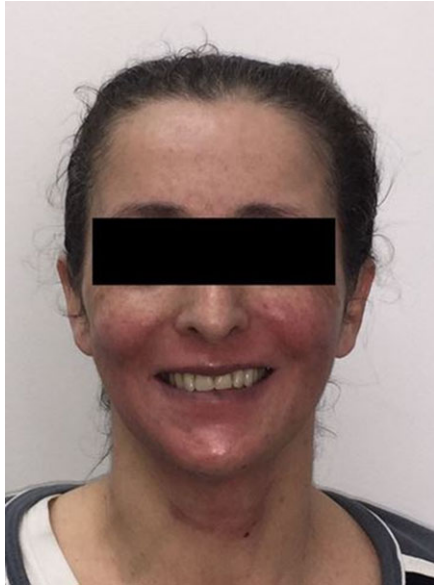In this patient, general osteoarticular pain complicated dental care through the difficulties she experienced in staying in a decubitus position and opening her mouth for a long time. She also presented an articular pain crisis during a dental appointment, which made it necessary to interrupt tooth extractions and wait for a few minutes. In addition, sterilized petroleum jelly body lotion (Vaseline Stérilisée, Cooper, France) was applied to skin irritations all around the oral cavity before each dental appointment, to protect them from dehydration and reduce care-related irritation (Figure 5).

Although it could be expected that SAPHO is infrequently encountered in dental practice,<sup>28</sup> the attending clinician should be familiar with management strategies for oral and perioral allergic reactions.

Forced to stop work several years earlier and fully aware of her state of health, the patient demonstrated extreme motivation and cooperation for care. Despite a lack of healing of the perioral and throat eczema due to her syndrome, she was extremely patient and not emotional. The patient never missed

The patient's demographic information in this case report was consistent with some other epidemiological studies revealing a slight female predominance for SAPHO syndrome<sup>1,3,29</sup> and for nickel allergy.<sup>30</sup> The patient developed a nickel allergy, which is found in 13% of the general population.<sup>31</sup> The literature on SAPHO syndrome includes some reports concerning children<sup>2</sup> but the syndrome is essentially found in adults. Its aetiology and its physiopathological mechanism are still unknown.<sup>14,32,33</sup> A possible association with HLA-B27 was initially suspected<sup>7</sup> (as in spondylarthrosis) but recent studies have dismissed this hypothesis<sup>1,15,34</sup>





**FIGURE 7** Recall appointment 2 months after fitting of prosthesis. Peri-oral and throat eczema still present and has not healed yet due to skin healing difficulties in patients with SAPHO syndrome

given that only a minority of patients present the antigen. Thus SAPHO syndrome may have a genetic or immune origin or occur after a *Propionibacterium Acnes* infection.<sup>9</sup> An antibiotic treatment targeting this bacterium has already shown good results on patients' health<sup>1,8</sup> but disease progression starts again when the treatment is stopped and not all the patients respond well to the antibiotic.<sup>1</sup> Thus, the etiopathogenesis of SAPHO syndrome may be multifactorial and not solely regarded as an infectious process.

Nickel is one of the most common allergens used in dental prostheses<sup>31</sup> and hypersensitivity reactions may develop 24-72 hours after contact with saliva. Manifestations include perioral dermatitis, burning mouth syndrome, lichenoid reactions, cheilitis, gingivitis, and orofacial granulomatosis.<sup>31,35,36</sup>

In the particular case of patients with SAPHO syndrome, the main complications occur in presence of mandibular osteomyelitis and bisphosphonate treatments but all other symptoms of this syndrome must be considered before starting any dental therapy. Because of the low incidence of this syndrome, there are no clear recommendations for its oral management. Nevertheless, it is possible to identify some important principles applicable to dental care in general. When articular pain occurs, modification of dental care may be necessary, such as reducing the length of the patient's dental appointment and their time maintaining an open mouth.

The complexity of these cases makes it essential to coordinate medical and dental care. A multidisciplinary team approach may be warranted within a hospital environment and perhaps augmented with the services of a physiotherapist when an affected patient experiences acute exacerbations.<sup>37</sup>

The onset of oral and perioral allergic reactions, such as nickel (as seen in the featured case report) may further complicate dental therapy. Moreover, the dentist may play integral role in the diagnosis of SAPHO syndrome. In a recent case report, mandibular pain, the first symptom reported, led to SAPHO discovery.<sup>38</sup> Elimination of any other dental cause of pain is essential and, in the case in question, CBCT was performed, revealing a sclerotic change and a periosteal reaction on the affected side of the mandible.<sup>38</sup>

## ACKNOWLEDGMENT

The authors thank Alice Cros for her help in oral surgery.

## CONFLICTS OF INTEREST

The authors declare no conflict of interest.

## ORCID

Thibault Canceill DDS   
<https://orcid.org/0000-0002-0049-7622>

## REFERENCES

1. Aljuhani F, Tournadre A, Tatar Z, et al. The SAPHO syndrome: a single-center study of 41 adult patients. *J Rheumatol*. 2015;42:329-334.
2. Gharsallah I, Souissi A, Dhahri R, et al. [SAPHO syndrome]. *Rev Med Interne*. 2014;35:595-600.
3. Nguyen MT, Borchers A, Selmi C, Naguwa SM, Cheema G, Gershwin ME. The SAPHO syndrome. *Semin Arthritis Rheum*. 2012;42:254-265.
4. Carranco-Medina TE, Hidalgo-Calleja C, Calero-Paniagua I, et al. Thrombotic manifestations in SAPHO syndrome. review of the literature. *Reumatol Clínica Engl Ed*. 2015;11:108-111.
5. Benhamou CL, Chamot AM, Kahn MF. Synovitis-acne-pustulosis hyperostosis-osteomyelitis syndrome (SAPHO). A new syndrome among the spondyloarthropathies? *Clin Exp Rheumatol*. 1988;6:109-112.
6. Chamot AM, Benhamou CL, Kahn MF, Beranek L, Kaplan G, Prost A. Acne-pustulosis-hyperostosis-osteitis syndrome. Results of a national survey. 85 cases. *Rev Rhum Mal Osteoartic*. 1987;54:187-196.
7. Kahn MF, Khan MA. The SAPHO syndrome. *Baillieres Clin Rheumatol*. 1994;8:333-362.
8. Carneiro S, Sampaio-Barros PD. SAPHO syndrome. *Rheum Dis Clin North Am*. 2013;39:401-418.
9. Cianci F, Zoli A, Gremese E, Ferraccioli G. Clinical heterogeneity of SAPHO syndrome: challenging diagnose and treatment. *Clin Rheumatol*. 2017;36:2151-2158.
10. Okuno H, Watanuki M, Kuwahara Y, et al. Clinical features and radiological findings of 67 patients with SAPHO syndrome. *Mod Rheumatol*. 2018;28:703-708.

11. Hagiwara K, Suyama Y, Fukuda K. SAPHO syndrome: synovitis, acne, pustulosis, hyperostosis, and osteitis. *Intern Med Tokyo Jpn*. 2017;56:577-578.
12. Firinu D, Garcia-Larsen V, Manconi PE, Del Giacco SR. SAPHO syndrome: current developments and approaches to clinical treatment. *Curr Rheumatol Rep*. 2016;18:35.
13. Witt M, Meier J, Hammitzsch A, Proft F, Schulze-Koops H, Grunke M. Disease burden, disease manifestations and current treatment regimen of the SAPHO syndrome in Germany: results from a nationwide patient survey. *Semin Arthritis Rheum*. 2014;43:745-750.
14. Lu J, Duan Y, Zuo Z, et al. Depression in patients with SAPHO syndrome and its relationship with brain activity and connectivity. *Orphanet J Rare Dis*. 2017;12:103.
15. Canella C, Costa F, d'Oliveira I, Albuquerque E, Marchiori E. SAPHO syndrome. *Joint Bone Spine*. 2014;81:90.
16. Kundu BK, Naik AK, Bhargava S, Srivastava D. Diagnosing the SAPHO syndrome: a report of three cases and review of literature. *Clin Rheumatol*. 2013;32:1237-1243.
17. Schaub S, Sirkis HM, Kay J. Imaging for synovitis, acne, pustulosis, hyperostosis, and osteitis (SAPHO) syndrome. *Rheum Dis Clin North Am*. 2016;42:695-710.
18. Delattre E, Guillot X, Godfrin-Valnet M, Prati C, Wendling D. SAPHO syndrome treatment with intravenous pamidronate. Retrospective study of 22 patients. *Joint Bone Spine*. 2014;81:456-458.
19. Zwaenepoel T, de Vlam K. SAPHO: treatment options including bisphosphonates. *Semin Arthritis Rheum*. 2016;46:168-173.
20. Daoussis D, Konstantopoulou G, Kraniotis P, Sakkas L, Liossis S-N. Biologics in SAPHO syndrome: a systematic review. *Semin Arthritis Rheum*. 2018. Pii: S0049-0172(18)30058-1
21. Yang Q, Zhao Y, Li C, Luo Y, Hao W, Zhang W. Case report: successful treatment of refractory SAPHO syndrome with the JAK inhibitor tofacitinib. *Medicine (Baltimore)*. 2018;97:e11149.
22. Baba A, Ojiri H, Takahashi S, Katakura A. SAPHO syndrome with mandibular manifestation. *BMJ Case Rep*. 2016. Pii: bcr2015213401
23. Hatano H, Shigeishi H, Higashikawa K, et al. A case of SAPHO syndrome with diffuse sclerosing osteomyelitis of the mandible treated successfully with prednisolone and bisphosphonate. *J Oral Maxillofac Surg*. 2012;70:626-631.
24. Marí A, Morla A, Melero M, Schiavone R, Rodríguez J. Diffuse sclerosing osteomyelitis (DSO) of the mandible in SAPHO syndrome: a novel approach with anti-TNF therapy. Systematic review. *J Cranio-Maxillo-fac Surg*. 2014;42:1990-1996.
25. Pottecher P, Loffroy R, Estivalet L, et al. SAPHO syndrome revealed by sclerosing mandibular osteomyelitis. *Diagn Interv Imaging*. 2014;95:885-887.
26. Suei Y, Taguchi A, Tanimoto K. Diagnostic points and possible origin of osteomyelitis in synovitis, acne, pustulosis, hyperostosis and osteitis (SAPHO) syndrome: a radiographic study of 77 mandibular osteomyelitis cases. *Rheumatology (Oxford)*. 2003;42:1398-1403.
27. Zemann W, Pau M, Feichtinger M, Ferrera-Matschy B, Kaercher H. SAPHO syndrome with affection of the mandible: diagnosis, treatment, and review of literature. *Oral Surg Oral Med Oral Pathol Oral Radiol Endod*. 2011;111:190-195.
28. Cotti E, Careddu R, Schirru E, et al. A case of SAPHO syndrome with endodontic implications and treatment with biologic drugs. *J Endod*. 2015;41:1565-1570.
29. Li C, Zuo Y, Wu N, et al. Synovitis, acne, pustulosis, hyperostosis and osteitis syndrome: a single centre study of a cohort of 164 patients. *Rheumatology (Oxford)*. 2016;55:1023-1030.
30. Magnusson B, Bergman M, Bergman B, Söremark R. Nickel allergy and nickel-containing dental alloys. *Scand J Dent Res*. 1982;90:163-167.
31. Bakula A, Lugović-Mihić L, Situm M, Turcin J, Sinković A. Contact allergy in the mouth: diversity of clinical presentations and diagnosis of common allergens relevant to dental practice. *Acta Clin Croat*. 2011;50:553-561.
32. Carr F. The "hidden" SAPHO syndrome. *BMJ Case Rep*. 2014; Pii: bcr2013201665
33. Rukavina I. SAPHO syndrome: a review. *J Child Orthop*. 2015;9:19-27.
34. Hayem G, Bouchaud-Chabot A, Benali K, et al. SAPHO syndrome: a long-term follow-up study of 120 cases. *Semin Arthritis Rheum*. 1999;29:159-171.
35. Lygre H. Prosthodontic biomaterials and adverse reactions: a critical review of the clinical and research literature. *Acta Odontol Scand*. 2002;60:1-9.
36. Alnazzawi A. Oral diseases associated with fixed prosthodontic restorations. *Saudi Med J*. 2017;38:322-324.
37. Skamagki G, King A, Duncan M, Wählin C. A systematic review on workplace interventions to manage chronic musculoskeletal conditions. *Physiother Res Int J Res Clin Phys Ther*. 2018;e1738.
38. Kikuchi T, Fujii H, Fujita A, Sugiyama T, Sugimoto H. Mandibular osteitis leading to the diagnosis of SAPHO syndrome. *Case Rep Radiol*. 2018;2018:9142362.

**How to cite this article:** Campana S-C, Canceill T, Esclassan R. Oral care of a patient with a SAPHO syndrome and a nickel allergy. *Spec Care Dentist*. 2019;39:231–235. <https://doi.org/10.1111/scd.12362>